



Preintervention lesion remodelling affects operative mechanisms of balloon optimised directional coronary atherectomy procedures: a volumetric study with three dimensional intravascular ultrasound

C von Birgelen, G S Mintz, E A de Vrey, P W Serruys, T Kimura, M Nobuyoshi, J J Popma, M B Leon, R Erbel and P J de Feyter

Heart 2000;83:192-197
doi:10.1136/heart.83.2.192

Updated information and services can be found at:
<http://heart.bmjjournals.com/cgi/content/full/83/2/192>

These include:

References

This article cites 37 articles, 24 of which can be accessed free at:
<http://heart.bmjjournals.com/cgi/content/full/83/2/192#BIBL>

1 online articles that cite this article can be accessed at:
<http://heart.bmjjournals.com/cgi/content/full/83/2/192#otherarticles>

Rapid responses

You can respond to this article at:
<http://heart.bmjjournals.com/cgi/eletter-submit/83/2/192>

Email alerting service

Receive free email alerts when new articles cite this article - sign up in the box at the top right corner of the article

Topic collections

Articles on similar topics can be found in the following collections

[Ischemic heart disease](#) (2079 articles)

Notes

To order reprints of this article go to:
<http://www.bmjjournals.com/cgi/reprintform>

To subscribe to *Heart* go to:
<http://www.bmjjournals.com/subscriptions/>

Preintervention lesion remodelling affects operative mechanisms of balloon optimised directional coronary atherectomy procedures: a volumetric study with three dimensional intravascular ultrasound

C von Birgelen, G S Mintz, E A de Vrey, P W Serruys, T Kimura, M Nobuyoshi, J J Popma, M B Leon, R Erbel, P J de Feyter

Abstract

Aims—To classify atherosclerotic coronary lesions on the basis of adequate or inadequate compensatory vascular enlargement, and to examine changes in lumen, plaque, and vessel volumes during balloon optimised directional coronary atherectomy procedures in relation to the state of adaptive remodelling before the intervention.

Design—29 lesion segments in 29 patients were examined with intravascular ultrasound before and after successful balloon optimised directional coronary atherectomy procedures, and a validated volumetric intravascular ultrasound analysis was performed off-line to assess the atherosclerotic lesion remodelling and changes in plaque and vessel volumes that occurred during the intervention. Based on the intravascular ultrasound data, lesions were classified according to whether there was inadequate (group I) or adequate (group II) compensatory enlargement.

Results—There was no significant difference in patient and lesion characteristics between groups I and II ($n = 10$ and 19), including lesion length and details of the intervention. Quantitative coronary angiographic data were similar for both groups. However, plaque and vessel volumes were significantly smaller in group I than in II. In group I, 9 (4%) (mean (SD)) of the plaque volume was ablated, while in group II 16 (11%) was ablated ($p = 0.01$). This difference was reflected in a lower lumen volume gain in group I than in group II (46 (18) mm^3 *v* 80 (49) mm^3 ($p < 0.02$)).

Conclusions—Preintervention lesion remodelling has an impact on the operative mechanisms of balloon optimised directional coronary atherectomy procedures. Plaque ablation was found to be particularly low in lesions with inadequate compensatory vascular enlargement.

(Heart 2000;83:192–197)

Keywords: intravascular ultrasound; ultrasonics; remodelling; coronary artery disease; atherectomy

Thoraxcenter,
University Hospital
Rotterdam–Dijkzigt,
Netherlands
E A de Vrey
P W Serruys
P J de Feyter

Kokura Memorial
Hospital, Kitakyushu,
Japan
T Kimura
M Nobuyoshi

Washington Hospital
Center, Washington
DC, USA
G S Mintz
J J Popma
M B Leon

Department of
Cardiology, University
Hospital Essen,
Hufelandstr 55,
D-45122 Essen,
Germany
C von Birgelen
R Erbel

Correspondence to:
Dr von Birgelen
email: von.birgelen@
uni-essen.de

Accepted 12 May 1999

Histopathological examination of human coronary artery specimens and data obtained from animal models have shown that atherosclerotic arteries tend to undergo a compensatory remodelling process during the early phase of plaque accumulation^{1,2}; compensatory vascular enlargement accommodates the increasing plaque mass until a critical plaque burden is reached and lumen obstruction starts. Intravascular ultrasound provides transmural images of coronary vessels in vivo and permits accurate measurements of the lumen, vessel, and atherosclerotic plaque dimensions in a way not previously possible.^{3–9} While early studies with intravascular ultrasound underlined the concept of compensatory vascular remodelling with adaptive vessel enlargement,^{10,11} recent intravascular ultrasound studies suggest a larger variability in this mechanism¹² and show inadequate vascular enlargement (paradoxical “shrinkage”) in some advanced atherosclerotic lesions.^{13–20} Inadequacy, failure, or reversal of the compensatory mechanisms may thus at least in part contribute to the development of significant atherosclerotic lesions.²¹

Using a validated three dimensional intravascular ultrasound approach,^{17,22} we recently

showed that plaque volume is smaller in lesions with inadequate compensatory vascular enlargement than in those with adequate compensatory enlargement.¹⁷ This may have implications for the mechanisms of catheter based plaque ablation techniques, such as directional coronary atherectomy.^{23–26} Previous intravascular ultrasound studies mostly focused on the mechanisms of directional coronary atherectomy.^{27–34} In the present intravascular ultrasound study, we classified lesions on the basis of inadequate (group I) or adequate (group II) compensatory vascular enlargement, and examined the changes in lumen, plaque, and vessel volumes during balloon optimised directional coronary atherectomy procedures in relation to the state of adaptive remodelling before the intervention.

Methods

STUDY POPULATION

We examined 29 patients who had been successfully treated by directional coronary atherectomy followed by a routine balloon angioplasty (so called balloon optimised directional coronary atherectomy).²⁶ The study population comprised 26 men and three

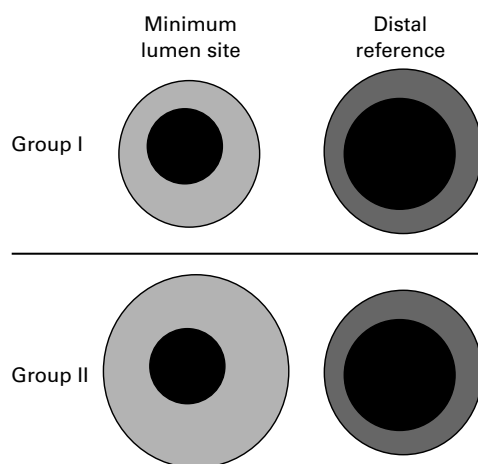


Figure 1 Classification of lesion remodelling based on preintervention intravascular ultrasound images. Compensatory vascular enlargement was considered inadequate (group I) if the vessel cross sectional area at the site of the minimum lumen cross sectional area (at the target site) was smaller than that at the distal reference site. Compensatory vascular enlargement was considered adequate (group II) if the vessel cross sectional area at the site of the minimum lumen cross sectional area was larger than or equal to that at the distal reference site.

women, mean (SD) age 61 (7) years. We included in this study relatively straight lesion segments (angiographically documented) without major side branches, with no more than limited plaque calcification, and without complete occlusion of the lumen during the motorised intravascular ultrasound imaging run. Of the 29 de novo coronary lesions, 23 were located proximally and six were in mid segments. Sixteen lesions (55%) were located in the left anterior descending coronary artery, eight (28%) in the right coronary artery, and five (28%) in the left circumflex coronary artery.

As previously suggested,¹⁷ lesions were divided into two groups based on preintervention intravascular ultrasound (IVUS) measurements. In lesions with inadequate compensatory vascular enlargement (group I), the vessel cross sectional area at the target lesion site (that is, site of smallest lumen cross sectional area) was smaller than that at the distal reference site; in lesions with adequate compensatory vascular enlargement (group II), the vessel cross sectional area at the target lesion site was larger than or equal to that at the distal reference site (fig 1). The groups did not differ in mean age, sex, lesion location, and procedural details.

The study was approved by the local councils on human research, and all patients signed a written informed consent form, approved by the local medical ethics committees.

INTERVENTIONAL PROCEDURE

All patients received 250 mg aspirin and 10 000 U heparin intravenously. If the duration of the entire catheterisation procedure exceeded one hour, the activated clotting time was measured, and intravenous heparin was given in order to maintain an activated clotting time of more than 300 seconds. After an intracoronary injection of 0.2 mg glyceryl trinitrate, the coronary artery was examined with IVUS.

Directional coronary atherectomy was then performed according to standard protocols. Predilatation was done in one patient before the atherectomy (but after the initial IVUS run). Atherectomy was performed using an average of 23 (11) cuts and a mean (SD) pressure of 1.7 (0.8) atm. The maximum cutter size of the atherectomy device (Devices for Vascular Intervention, Redwood City, California, USA) was 7 F in all patients. Subsequently, balloon angioplasty was performed in all patients using a nominal balloon size of 3.8 (0.5) mm at a maximum pressure of 9.4 (4.7) atm. The final IVUS imaging runs were performed after the balloon angioplasty (at the end of the interventional procedure). There was no procedural or postprocedural complication in hospital.

There was no significant difference between group I and II with regard to the characteristics of the interventional procedures: 24 (9) and 23 (10) atherectomy cuts were performed, the balloon size was 3.8 (0.6) mm for both, and the balloon inflation pressure was 9.7 (4.8) atm and 9.4 (4.7) atm, respectively.

INTRAVASCULAR ULTRASOUND IMAGING

Ultrasound imaging was performed after intracoronary injection of 0.2 mg glyceryl trinitrate, starting at least 10 mm distal to the lesion segment. We used a mechanical intravascular ultrasound system (ClearView, CardioVascular Imaging Systems Inc, Sunnyvale, California, USA) and sheath based imaging catheters. The catheter incorporated a 30 MHz bevelled, single element transducer rotating at 1800 rpm (MicroView, CardioVascular Imaging Systems). The catheters were equipped with a 2.9 F 15 cm long sonolucent distal sheath. The sheath avoided direct contact of the imaging core with the vessel wall when the ultrasonic transducer was withdrawn through the stationary imaging sheath, using a motorised pull back device at a constant speed of 0.5 mm/s. The ultrasound examinations were recorded on high resolution (s-VHS) videotape for off-line analysis, using the three dimensional approach.^{17 22}

COMPUTERISED INTRAVASCULAR ULTRASOUND ANALYSIS METHOD

The intravascular ultrasound image analysis was performed off-line using a computerised analysis system.^{17 22 35 36} The analysis system used the Windows (Microsoft, Redmond, Washington, USA) operating system on a personal computer. The computerised analysis required the digitisation of a stack of intravascular ultrasound images from videotape. Two longitudinal sections were automatically reconstructed (fig 2), and the contours corresponding to the lumen-tissue and media-adventitia interfaces were automatically identified. The longitudinal contours were visually checked and, if necessary, edited with computer assistance. The longitudinal contours generated individual edge points on the planar images defining the centre and range of the automated boundary search on the planar images. Subsequently, contour detection of the planar images was performed. The planar contours were

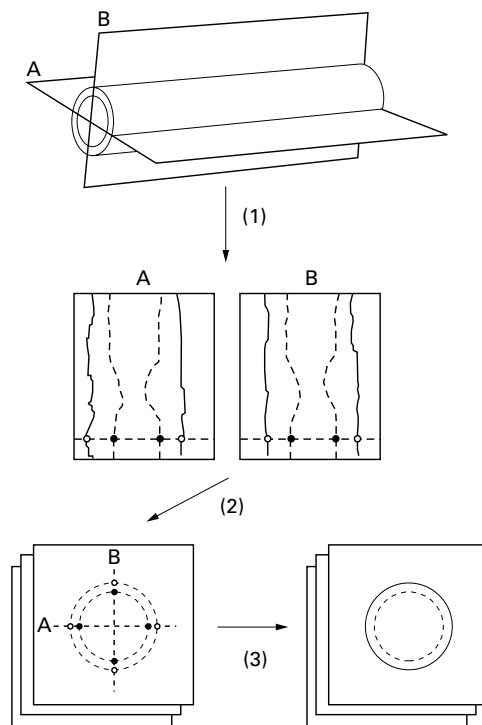


Figure 2 Principle of automated three dimensional intravascular ultrasound image analysis. Detection of the contours corresponding to the lumen-tissue and media-adventitia interfaces (1) is first performed on two perpendicular longitudinal sections (A, B), reconstructed from the image data of the entire three dimensional "stack" of images. Edge information of the longitudinal contours are represented as points on the planar images (2), defining there the centre and range of the final contour detection process (3).

visually checked and, if necessary, edited with computer assistance. Finally, the correct contour data of the planar images were used for the computation of the results.

Further details of the automated contour detection and computer assisted contour editing have been reported previously.^{17 22 35} Validation of the algorithm and analysis approach has been performed in tubular phantoms and atherosclerotic coronary specimen in vitro, and in clinical pullbacks in vivo.^{17 37}

INTRAVASCULAR ULTRASOUND IMAGE ANALYSIS

Lesion segments with a length of about 20 mm (10 images/mm axial arterial length), centred on the target lesion site, were analysed off-line, using the computerised intravascular ultrasound analysis system (fig 2).^{17 22 35} Reference images with the smallest plaque burden were acquired no more than 3 mm distal to the lesion segment. Care was taken to avoid any major side branch between the lesion segment and the reference site. Cross sectional area measurements at the reference site were obtained with the computerised analysis system (single frame mode). Cross sectional area measurements (mm²) included the lumen and vessel cross sectional area. The vessel cross sectional area was measured by tracing the border between the hypoechoic media and the echoreflexive adventitia. As in many previous studies using intravascular ultrasound, the cross sectional area (and thickness) of plaque plus media was used as a measure of

atherosclerotic plaque area (and thickness) because ultrasound cannot measure media thickness accurately. Plaque cross sectional area was calculated as vessel cross sectional area minus lumen cross sectional area. The cross sectional area plaque burden was calculated as plaque cross sectional area divided by vessel cross sectional area.

Compensatory vascular enlargement was considered inadequate (group I) if the vessel cross sectional area at the site of the minimum lumen cross sectional area was smaller than that at the distal reference site (fig 1).¹⁷ If the vessel cross sectional area at the site of the minimum lumen cross sectional area was larger than or equal to the distal reference site, compensatory vascular enlargement was considered adequate (group II).¹⁷

Volume measurements (mm³) of the lumen, vessel, and plaque (based on 10 intravascular ultrasound images/mm axial arterial length) were calculated according to Simpson's rule as

$$\text{Volume} = \sum_{i=1}^n \text{cross sectional area}_i \times H$$

where H = thickness of a coronary artery slice represented by a single tomographic intravascular ultrasound image, and n = number of images in the three dimensional image set. The volume plaque burden (%) was calculated as plaque volume divided by vessel volume.

QUANTITATIVE CORONARY ANGIOGRAPHY

Angiographic measurements were performed off-line on end diastolic frames with homogeneous opacification of the coronary lumen, acquired after intracoronary application of nitrates.²⁹ A computer based coronary angiography analysis system (CAAS, Pie Medical, Maastricht, Netherlands) was used. Measurements were performed by an experienced analyst in at least two projections, obtained from opposite (ideally orthogonal) angiographic views without overlapping side branches or foreshortening. Briefly, automated detection of the coronary artery contours was performed on the basis of the weighted sum of the first and second derivative functions applied to the digitised brightness silhouette. The diameter function of the coronary artery lumen was determined by computing the shortest distances between the edge points of the right and left contours. The absolute angiographic diameter of the stenosis was determined, using the non-tapering part of the contrast-free guiding catheter as a scaling device. The minimal lumen diameter was measured by edge detection; the interpolated reference diameter was based on a computerised estimation of the original arterial dimension at the site of the obstruction. The diameter stenosis (%) was derived from the measured minimal luminal diameter (MLD) and the interpolated reference diameter (RD) as $[(\text{MLD} - \text{RD}) / \text{RD}] \times 100$.

STATISTICAL ANALYSIS

All quantitative data are given as mean (SD). Dichotomous variables are expressed as frequencies. Continuous variables are compared

Table 1 Volumetric intravascular ultrasound data pre- and postintervention

| | Group I | Group II | p Value, group I v II |
|---------------------------|-----------|-------------|-----------------------|
| <i>Preintervention</i> | | | |
| Lumen (mm ³) | 111 (37) | 120 (55) | NS |
| Vessel (mm ³) | 273 (79) | 366 (153) | < 0.04 |
| Plaque (mm ³) | 162 (52) | 246 (120) | < 0.02 |
| Plaque burden (%) | 59 (7) | 66 (9) | < 0.04 |
| <i>Postintervention</i> | | | |
| Lumen (mm ³) | 157 (46)* | 200 (80)* | NS |
| Vessel (mm ³) | 304 (83)‡ | 406 (170) † | < 0.05 |
| Plaque (mm ³) | 147 (45)‡ | 206 (107)* | < 0.05 |
| Plaque burden (%) | 49 (6)* | 50 (9)* | NS |

*p < 0.0001, †p < 0.0005, ‡p < 0.001, v preintervention.

Table 2 Change of volumetric indices during the intervention

| | Group I | Group II | p Value |
|-----------------------------|----------|----------|---------|
| Δ Lumen (mm ³) | 46 (19) | 80 (49) | < 0.02 |
| Δ Vessel (mm ³) | 31 (19) | 39 (36) | NS |
| Δ Plaque (mm ³) | -15 (10) | -41 (35) | < 0.01 |
| Δ Plaque burden (%) | -10 (3) | -17 (8) | < 0.02 |

Δ, difference between pre- and postintervention.

using the two tailed Student *t* test and linear regression analysis. Probability (p) values < 0.05 are considered statistically significant.

Results

PREINTERVENTION REMODELLING

On average, at the minimum lumen site (lumen area, 2.6 (1.3) mm²) the vessel and plaque cross sectional area was 15.9 (5.1) mm² and 13.4 (4.4) mm² (84 (7)% plaque burden); at the (distal) reference segment site, the vessel and plaque cross sectional area was 13.8 (4.8) mm² and 6.5 (2.5) mm² (47 (11)% plaque burden). Ten lesions showed inadequate compensatory vascular enlargement (group I) with a vessel cross sectional area that was smaller at the minimum lumen site than at the reference site (12.8 (3.3) mm² v 13.9 (3.6) mm², p < 0.001). In the other 19 lesions (group II), the vessel cross sectional area at the minimum lumen site was larger than or equal to that at the reference site (17.6 (5.2) mm² v 13.8 (5.5) mm², p < 0.0001). There was no significant difference between the cross sectional area measurements at the reference site of both groups.

VOLUMETRIC INTRAVASCULAR ULTRASOUND DATA

For the entire population, during the intervention plaque volume was reduced by 32 (31) mm³ (from 217 (108) mm³ to 185 (94) mm³, p < 0.001) and the residual plaque burden was 49 (8)%. At the same time, lumen and vessel volume increased from 117 (49) mm³ to 185 (72) mm³ and from 334 (138) mm³ to 371 (152) mm³ (for both p < 0.0005).

Between group I and group II, there was no difference in lesion segment length (19.6 (3.1) v 19.8 (4.5) mm), but both before and after the intervention the plaque and vessel volumes were significantly smaller in group I (p < 0.04 and p < 0.02) than in group II (table 1). In group I, 8.9 (3.8)% of the plaque volume was ablated, whereas in group II, 16.5 (10.8)% was ablated (p = 0.01). The lower plaque ablation in group I (-15 (10) mm³ v -41 (35) mm³ in group I and II, respectively, p < 0.01) was reflected in a lower lumen volume gain (46 (19)

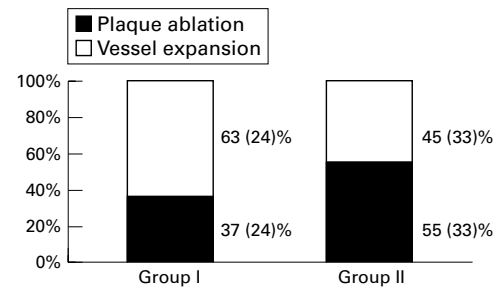


Figure 3 In both groups, plaque ablation and vessel expansion contributed to the increase in lumen volume, but there was a trend towards different proportions of these operative mechanisms for the two groups.

Table 3 Quantitative coronary angiographic data pre- and postintervention

| | Group I | Group II | p Value, group I v II |
|-------------------------|--------------|--------------|-----------------------|
| <i>Preintervention</i> | | | |
| MLD (mm) | 1.07 (0.34) | 1.19 (0.36) | NS |
| RD (mm) | 3.16 (0.53) | 3.32 (0.66) | NS |
| DS (%) | 66 (9) | 62 (16) | NS |
| <i>Postintervention</i> | | | |
| MLD (mm) | 2.72 (0.47)* | 2.74 (0.57)* | NS |
| RD (mm) | 3.26 (0.46) | 3.64 (0.50)† | NS |
| DS (%) | 16 (14)* | 25 (13)* | NS |

*p < 0.0001; †p < 0.02, v preintervention.

DS, diameter stenosis; MLD, minimum lumen diameter; RD, reference diameter.

mm³ v 80 (49) mm³ for group I v II, respectively, p < 0.02) (table 2).

In group I and II, plaque ablation and vessel expansion contributed to the increase in lumen volume, but the proportion of the two operative mechanisms was different (fig 3). For both groups, there was a significant linear relation between the plaque volume present before the intervention and the plaque volume ablated (group I, *r* = 0.75, *y* = 0.14*x* - 8.9, p < 0.02; group II, *r* = 0.48, *y* = 0.14*x* + 6.0, p < 0.04).

QUANTITATIVE CORONARY ANGIOGRAPHIC DATA

Overall the minimum lumen diameter and the reference diameter increased during the intervention from 1.15 (0.35) mm to 2.73 (0.53) mm and from 3.27 (0.62) mm to 3.50 (0.51) mm, respectively. This led to a reduction in diameter stenosis from 64 (14)% to 21 (14)%. There was no significant difference between group I and group II, either before or after the intervention (table 3).

Discussion

Intravascular ultrasound permits the tomographic assessment of coronary arteries in vivo.^{4,5} Accurate cross sectional area measurements of lumen and plaque can be obtained, as the atherosclerotic plaque can be well differentiated from both lumen and adventitia. Indeed, this method is ideal for the thorough assessment of plaque distribution, remodelling of atherosclerotic lesions, and the changes that occur during catheter based coronary interventions.³ The results of our volumetric intravascular ultrasound study confirm previous ultrasonic studies^{4,28,29,31-34} that addressed the mechanisms of directional coronary atherectomy and identified both plaque ablation and vessel expansion as significant operative mechanisms of balloon

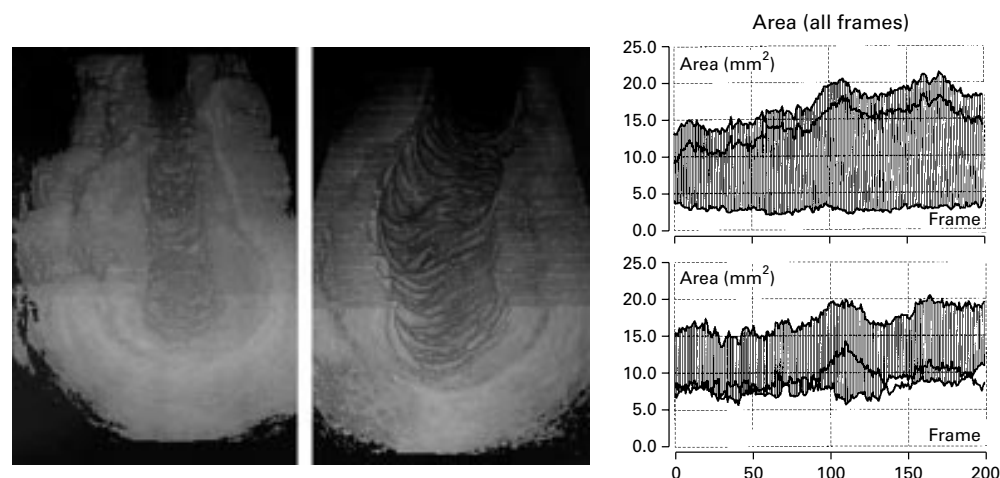


Figure 4 Lesion before and after balloon optimised directional atherectomy. Spatial (three dimensional) views (left and mid panel) are reconstructed from the complete intravascular ultrasound datasets which are used for volumetric analysis, underlining the high spatial resolution of the volumetric measurements in this study. The right panel shows the cross sectional area measurements both before (upper panel) and after the intervention (lower panel). Linear functions of the vessel and lumen cross sectional area form the upper and lower boundaries of the greyish area, which represents the plaque cross sectional area measurements from distal (left) to proximal (right). Alternatively, values of the plaque cross sectional area can be derived directly from a linear function (single black line), which here mostly overlaps the greyish area. Note, that in this example, both plaque ablation and vessel expansion contributed to the increase in lumen volume.

optimised directional coronary atherectomy (fig 4). However, our work enlarges on these previous studies, as it examines the procedure induced changes in lumen, plaque, and vessel volumes in relation to the preintervention remodelling state.

MAIN FINDINGS

Our data show that preintervention lesion remodelling has an impact on the operative mechanisms of balloon optimised directional coronary atherectomy and on the procedure induced changes in lumen, plaque, and vessel volumes. Inadequate compensatory vascular enlargement, which is associated with smaller plaque and vessel volumes,¹⁷ was found in one third of the lesions examined (group I). In these lesions, significantly less plaque was ablated ($p < 0.01$), and this was reflected in a smaller lumen volume gain ($p < 0.02$). Moreover, there was a significant ($p < 0.04$) linear relation between preintervention plaque volume and the plaque volume ablated. Both plaque ablation and vessel expansion contributed in the two groups to the increase in lumen volume. However, in lesions with inadequate compensatory vascular enlargement before the intervention, plaque ablation played a minor role.

THREE DIMENSIONAL INTRAVASCULAR ULTRASOUND ASSESSMENT OF LESION REMODELLING

Reliable assessment of vascular remodelling based on intravascular ultrasound images requires accurate and reproducible measurements at the minimum lumen site (target lesion site) and the reference site.¹⁷⁻³⁵ In the present study, a recently validated intravascular ultrasound analysis system was used, which permits a computer assisted detection of the lumen-tissue and plaque-adventitia interfaces in a three dimensional image set of an entire coronary segment¹⁷⁻²²⁻³⁵⁻³⁶; the analysis system was applied off-line. With the use of ECG gated

image acquisition techniques and further improvement of the computer assisted contour analysis method, such analyses may soon be available online in the catheterisation suite.³⁶ This will ensure the most objective evaluation of the minimum lumen site and remodelling state of coronary lesions before an intervention, to facilitate clinical decision making.

CLINICAL IMPLICATIONS

Our observations in the present study show that plaque ablation by directional atherectomy is significantly reduced in lesions with inadequate compensatory enlargement. This may rationalise recently published data,³⁵ which indicate that lesions with inadequate compensatory vascular enlargement show less favourable angiographic follow up results after successful directional coronary atherectomy. Perhaps directional atherectomy may be inappropriate for the treatment of lesions with inadequate compensatory vascular enlargement, as vessel expansion is the main operative mechanism in lesions with this type of vascular remodelling. Alternatively, the combination of intravascular ultrasound imaging and atherectomy devices in a single tool could lead to an improvement in plaque ablation, which may be particularly useful in lesions with inadequate compensatory vascular remodelling. Nevertheless, answering these questions will certainly require prospective randomised trials in larger study populations.

LIMITATIONS OF THE STUDY

Our study protocol did not allow a direct distinction between the effects of directional atherectomy and balloon angioplasty. Nevertheless, such distinction may not be very interesting, as balloon optimisation following directional atherectomy is common clinical practice.²⁵⁻²⁶ Second, our data were derived from a series of patients with successful balloon optimised directional coronary atherectomy.

Therefore no conclusions can be made regarding the primary success rate of directional coronary atherectomy in lesions with different preintervention remodelling states. Third, because with intravascular ultrasound the external vascular boundary cannot be seen in the acoustic shadow behind calcium, we did not include lesions with severe plaque calcification. Fourth, as in all studies with intravascular ultrasound, intracoronary injections of nitrates were performed before the ultrasound examination in order to prevent vasospasm; no angiographic changes before and after the intravascular ultrasound imaging procedure were observed, but this does not exclude local vasospastic activity. Finally, linear three dimensional systems, as used in the current study, provide only approximate volumetric measures because they do not account for the presence of vascular curvature. In the current study, only relatively straight coronary segments on the angiogram were included to minimise curve induced error in the volume calculation.

CONCLUSIONS

Our data in this volumetric study show an impact of preintervention lesion remodelling on the operative mechanisms of balloon optimised directional coronary atherectomy procedures. Plaque ablation was found to be particularly inadequate in lesions with inadequate compensatory vascular enlargement.

CvB is the recipient of a fellowship of the German Research Society (DFG, Bonn, Germany)

- Armstrong ML, Heistad DD, Marcus ML, *et al*. Structural and hemodynamic response of peripheral arteries of macaque monkeys to atherogenic diet. *Arteriosclerosis* 1985;5:336–46.
- Glagov S, Weisenberg E, Zaris CK, *et al*. Compensatory enlargement of human atherosclerotic coronary arteries. *N Engl J Med* 1987;316:1371–5.
- Di Mario C, Gorge G, Peters R, *et al*. Clinical application and image interpretation in intracoronary ultrasound. *Eur Heart J* 1998;19:207–29.
- Kearney PP, Starkey IR, Sutherland GR. Intracoronary ultrasound: current state of the art. *Br Heart J* 1995;73(suppl 2):16–25.
- Erbel R, Ge J, Bockisch A, *et al*. Value of intracoronary ultrasound and Doppler in the differentiation of angiographically normal coronary arteries: a prospective study in patients with angina pectoris. *Eur Heart J* 1996;17:880–9.
- Hausmann D, Johnson JA, Sudhir K, *et al*. Angiographically silent atherosclerosis detected by intravascular ultrasound in patients with familial hypercholesterolemia and familial combined hyperlipidemia: correlation with high density lipoproteins. *J Am Coll Cardiol* 1996;27:1562–70.
- Peters JC, Kok WEM, Di Mario C, *et al*. Prediction of restenosis after coronary balloon angioplasty: results of PICTURE (Post-IntraCoronary Treatment Ultrasound Result Evaluation), a prospective multicenter intracoronary ultrasound imaging study. *Circulation* 1997;95:2254–61.
- Schwarzacher SP, Lim TT, Wang B, *et al*. Local intramural delivery of L-arginine enhances nitric oxide generation and inhibits lesion formation after balloon angioplasty. *Circulation* 1997;95:1863–9.
- Mudra H, Regar E, Klauss V, *et al*. Serial follow-up after optimized ultrasound-guided deployment of Palmaz-Schatz stents: in-stent neointimal proliferation without significant reference segment response. *Circulation* 1997;95:363–70.
- Ge J, Erbel R, Zamorano J, *et al*. Coronary artery remodeling in atherosclerotic disease: an intravascular ultrasonic study in vivo. *Coron Artery Dis* 1993;4:981–6.
- Gerber TC, Erbel R, Gorge G, *et al*. Extent of atherosclerosis and remodeling of the left main coronary artery determined by intravascular ultrasound. *Am J Cardiol* 1994;73:666–71.
- von Birgelen C, Airian SG, Mintz GS, *et al*. Variations of remodeling in response to left main atherosclerosis assessed with intravascular ultrasound in vivo. *Am J Cardiol* 1997;80:1408–13.
- Pasterkamp G, Wensing PJW, Post MJ, *et al*. Paradoxical arterial wall shrinkage may contribute to luminal narrowing of human atherosclerotic femoral arteries. *Circulation* 1995;91:1444–9.
- Mintz GS, Kent KM, Pichard AD, *et al*. Contribution of inadequate arterial remodeling to the development of focal coronary artery stenoses: an intravascular ultrasound study. *Circulation* 1997;95:1791–8.
- Nishioka T, Luo H, Eigler NL, *et al*. Contribution of inadequate compensatory enlargement to development of human coronary artery stenosis: an in vivo intravascular ultrasound study. *J Am Coll Cardiol* 1996;27:1571–6.
- Wong CB, Porter TR, Xie F, *et al*. Segmental analysis of coronary arteries with equivalent plaque burden by intravascular ultrasound in patients with and without angiographically significant coronary artery disease. *Am J Cardiol* 1995;76:598–601.
- von Birgelen C, Mintz GS, de Vrey EA, *et al*. Atherosclerotic coronary lesions with inadequate compensatory enlargement have smaller plaque and vessel volumes. Observations with three-dimensional intravascular ultrasound in vivo. *Heart* 1998;79:137–42.
- Smits PC, Bos L, Quarles van Ufford MA, *et al*. Shrinkage of human coronary arteries is an important determinant of de novo atherosclerotic luminal stenosis: an in vivo intravascular ultrasound study. *Heart* 1998;79:143–7.
- Vavuranakis M, Stefanadis C, Toutouzas K, *et al*. Impaired compensatory coronary enlargement in atherosclerosis contributes to the development of coronary artery stenosis in diabetic patients. *Eur Heart J* 1997;18:1090–4.
- Varnava A. Coronary artery remodelling. *Heart* 1998;79:109–10.
- Clarkson TB, Prichard RW, Morgan TM, *et al*. Remodeling of coronary arteries in human and nonhuman primates. *JAMA* 1994;271:289–94.
- von Birgelen C, van der Lugt A, Nicosia A, *et al*. Computerized assessment of coronary lumen and atherosclerotic plaque dimensions in three-dimensional intravascular ultrasound correlated with histomorphometry. *Am J Cardiol* 1996;78:1202–9.
- Adelman AG, Cohen EA, Kimball BP, *et al*. A comparison of directional atherectomy with balloon angioplasty for lesions of the left anterior descending coronary artery. *N Engl J Med* 1993;329:228–33.
- Topol EJ, Leya F, Pinkerton CA, Whitlow PL, *et al*, for the CAVEAT Study Group. A comparison of directional atherectomy with coronary angioplasty in patients with coronary artery disease. *N Engl J Med* 1993;329:221–7.
- Simonton CA, Leon MB, Baim DS, *et al*. “Optimal” directional coronary atherectomy: final results of the Optimal Atherectomy Restenosis Study (OARS). *Circulation* 1998;97:332–9.
- Baim DS, Cutlip DE, Sharma SK, *et al*, for the BOAT Investigators. Final results of the balloon vs optimal atherectomy trial (BOAT). *Circulation* 1998;97:322–31.
- Braden GA, Herrington DM, Downes TR, *et al*. Quantitative and qualitative contrasts in the mechanisms of lumen enlargement by coronary balloon angioplasty and directional coronary atherectomy. *J Am Coll Cardiol* 1994;23:40–8.
- De Lezo JS, Romero M, Medina A, *et al*. Intracoronary ultrasound assessment of directional coronary atherectomy: immediate and follow-up findings. *J Am Coll Cardiol* 1993;21:298–307.
- Di Mario C, Gil R, Camenzind E, *et al*. Quantitative assessment with intracoronary ultrasound of the mechanisms of restenosis after percutaneous transluminal coronary angioplasty and directional coronary atherectomy. *Am J Cardiol* 1995;75:772–7.
- Nakamura S, Mahon DJ, Leung CY, *et al*. Intracoronary ultrasound imaging before and after directional coronary atherectomy. *Am Heart J* 1995;129:841–51.
- Matar FA, Mintz GS, Farb A, *et al*. The contribution of tissue removal to lumen improvement after directional coronary atherectomy. *Am J Cardiol* 1994;74:647–50.
- Suneja R, Nair RN, Reddy KG, *et al*. Mechanisms of angiographically successful directional coronary atherectomy: evaluation by intracoronary ultrasound and comparison with transluminal coronary angioplasty. *Am Heart J* 1993;126:507–14.
- Weissman NJ, Palacios IF, Nidorf SM, *et al*. Three-dimensional intravascular ultrasound assessment of plaque volume after successful atherectomy. *Am Heart J* 1995;130:413–19.
- Marsico F, Kubica J, de Servi S, *et al*. Influence of plaque morphology on the mechanism of luminal enlargement after directional coronary atherectomy and balloon angioplasty. *Br Heart J* 1995;74:134–9.
- von Birgelen C, Mintz GS, de Vrey EA, *et al*. Successful directional atherectomy of de novo coronary lesions assessed with three-dimensional intravascular ultrasound and angiographic follow-up. *Am J Cardiol* 1997;80:1540–5.
- von Birgelen C, de Vrey EA, Mintz GS, *et al*. ECG-gated three-dimensional intravascular ultrasound. Feasibility and reproducibility of an automated analysis of coronary lumen and atherosclerotic plaque dimensions in humans. *Circulation* 1997;96:2944–52.
- von Birgelen C, Di Mario C, Li W, *et al*. Morphometric analysis in three-dimensional intracoronary ultrasound: an in-vitro and in-vivo study using a novel system for the contour detection of lumen and plaque. *Am Heart J* 1996;132:516–27.