

# Perforated Peptic Ulcer: new insights

## PROEFSCHRIFT

Ter verkrijging van de graad van doctor  
aan de Erasmus Universiteit Rotterdam,  
op gezag van de rector magnificus  
Prof. Dr. H.G. Schmidt  
en volgens besluit van het College voor Promoties.

De openbare verdediging zal plaatsvinden op  
woensdag 20 april 2011 om 9.30 uur in de Arminius kerk

door

**Mariëtta Johanna Olga Elizabeth Bertleff**

geboren te Zaandam



---

**Promotiecommissie:**

**1ste Promotor:** Prof. dr. J.F. Lange

**2de Promotor:** Prof. dr. J.Ph.A. Nicolai

**Overige leden:** Prof. dr. H.W. Tilanus  
Prof. dr. E.J. Kuipers  
Prof. dr. C.H.J. van Eijck

**Paranimfen:** Prof. dr T. Stegmann

Drs. W.M. Vermeltfoort- Schouten, MBA

# Perforated Peptic Ulcer: new insights

<b>Chapter 1</b>	General introduction and objectives	<b>5</b>
<b>Chapter 2</b>	Perforated peptic ulcer disease: a review of history and treatment	<b>7</b>
<b>Chapter 3</b>	Laparoscopic correction of perforated peptic ulcer: first choice? A review of literature	<b>27</b>
<b>Chapter 4</b>	Randomized clinical trial of laparoscopic versus open repair of the perforated peptic ulcer: the LAMA trial	<b>45</b>
<b>Chapter 5</b>	Laparoscopic closure of perforated peptic ulcer: first choice? Results of a European questionnaire	<b>57</b>
<b>Chapter 6</b>	The “stamp method”: a new treatment for perforated peptic ulcer?	<b>71</b>
<b>Chapter 7</b>	Comparison of closure of gastric perforation ulcers with bio- degradable lactide-glycolid-caprolactone or omental patches	<b>77</b>
<b>Chapter 8</b>	Helicobacter genotyping and detection in peroperative lavage fluid in patients with perforated peptic ulcer	<b>89</b>
<b>Summary</b>		<b>101</b>
<b>Nederlandse samenvatting</b>		<b>105</b>
<b>Curriculum Vitae</b>		<b>109</b>
<b>Dankwoord</b>		<b>110</b>



---

Chapter 1

**General introduction  
and objectives**

Much has been written on perforated peptic ulcer (PPU) during the last hundred years. In 1500, when necropsies were first allowed, often a small hole was found in the anterior wall of the stomach, giving an explanation for symptoms of acute abdominal pain, nausea, vomiting which often led to death within a few hours or days. Laparoscopic surgery, also called minimal invasive surgery or keyhole surgery is a surgical technique in which operations are performed through small incisions as compared to the larger incision needed in traditional surgical procedures. Georg Kelling performed the first laparoscopic procedure in dogs in 1902 and in 1910 Hans Christian Jacobaeus was responsible for the first laparoscopic procedure in humans, but it took till the 80s of the last century before laparoscopic procedures became popular. Benefits of laparoscopic surgery are less postoperative pain, minimal scarring and lower morbidity and mortality. A review of the history of perforated peptic ulcer disease (PUD) has been written in chapter 1 and a review on laparoscopic correction for PPU has been written in Chapter 2. The aim of this thesis was to demonstrate if laparoscopic correction of PPU was feasible and if it was superior to the routine correction of PPU by upper laparotomy. For this a Dutch multicenter trial, the LAMA trial, was performed. During this trial several questions raised, which led to more research. First of all, reviewing literature on this topic, it became clear that consensus on several topics was lacking (Chapter 3, 4). A European questionnaire was sent to get an impression of the current preferred methods of choice (Chapter 5). During the LAMA trial it was discovered that the laparoscopic suture procedure sometimes led to problems. Therefore an alternative technique for closure of the perforation without the need for suturing was tested in rats (Chapter 6 and 7). Finally, during surgery for PPU routinely a biopsy is taken for testing on *Helicobacter pylori* (*H.pylori*), one of the main causes for the occurrence of peptic ulcer disease. It was questioned if testing the abdominal fluid or serum could replace the need for a biopsy, but also it was evaluated if there was one genetic type of the *H.pylori* responsible for the emergence of PPU, which could be an important factor in the prevention of PPU (Chapter 8).

---

Chapter 2

**Perforated Peptic Ulcer disease:  
A review of history and treatment**

### Abstract

In the last hundred years much has been written on peptic ulcer disease and the treatment options for one of its most common complications: perforation. The reason for reviewing literature was evaluating most common ideas on how to treat perforated peptic ulcers in general, opinions on conservative treatment and surgical treatment and summarizing ideas about necessary pre- per and postoperative proceedings . For this all relevant articles found by medline, ovid and pubmed search were used.

### History

For thousands of years healthy people have had acute abdominal pain, nausea, vomiting and diarrhoea followed by death in a few hours or days. Often these symptoms were contributed to poisoning and people have been sent to prison for this [1]. King Charles I's daughter, Henriette-Anne, died suddenly in 1670 (at age 26) after a day of abdominal pain and tenderness. Since poisoning was suspected autopsy was performed and revealing peritonitis and a small hole in the anterior wall of the



*Henriette-Anne*

stomach. However, the doctors had never heard of a perforated peptic ulcer (PPU) and attributed the hole in the stomach to the knife of the dissector [1, 2]. Necropsies were first allowed since 1500 and became more routine between 1600 and 1800 [2, 3]. As a consequence more often perforation of the stomach was observed. Johan Mikulicz-Radecki (1850-1905), often referred to as the first surgeon who closed a perforated peptic ulcer (PPU) by simple closure said: " Every doctor, faced with a perforated duodenal ulcer of the stomach or intestine, must consider opening the abdomen, sewing up the hole, and averting a possible inflammation by careful cleansing of the abdominal cavity" [4]. Surprising enough treatment since has not changed much, still consisting of primary closure of the perforation by single stitch suture and a convenient tag of adjacent omentum on top of this [5-8]. Although this therapy sounds very simple still PPU remains a dangerous surgical condition, associated with high morbidity and mortality, not to be underestimated [9].



## Clinical presentation and investigation

In 1843 Edward Crisp was the first to report 50 cases of PPU and accurately summarized the clinical aspects of perforation; concluding: "The symptoms are so typical, I hardly believe it possible that anyone can fail to make the correct diagnosis." [10]. Patients with PPU have a typical history of sudden onset of acute, sharp pain usually located in the epigastric area and sometimes with referred shoulder pain, indicating free air under the diaphragm [11]. Bases on collected data from 52 papers on PPU clinical characteristics have been summarized in table 1. The typical patient with PPU is male with an average age of 48 years. He may have a history of peptic ulcer disease (29%), or nonsteroidal anti-inflammatory drugs (NSAIDs) usage (20%). Vomiting and nausea are present in 50% of cases. At physical examination pulse might be quickened, but seldom goes beyond 90 beats per minute. About 5-10% of patients experience shock with a mean arterial pressure of less than 80 mmHg [12]. Hypotension is a late finding as is a high fever. Obliteration or complete absence of liver dullness was only noted in 37%, so as a diagnostic tool, this has its limitations [7]. In blood analysis a moderate leucocytoses will be found. Main reason for taking a blood sample is excluding other diagnosis like for instance pancreatitis [4]. An X-ray of the abdomen/thorax in standing position will reveal free air under diaphragm in about 80-85 % [7, 13]. Some centres perform abdominal ultrasonography, or computerized tomography (CT) scans with oral contrast [14]. With current radiological techniques 80-90% of cases are correctly diagnosed [12]. As soon as diagnosis is made resuscitation is started with large volume crystalloids, nasogastric suction to empty the stomach; and administration of broad-spectrum antibiotics [13, 15]. When PPU has been diagnosed, there are a few different therapeutic options to be taken into consideration [12]. First of all it must be evaluated if the patients is suitable for surgery or should conservative treatment be considered instead. If surgery is indicated, is simple closure with or without omentoplasty sufficient or is there a need for definitive ulcer surgery and if there is a need for definitive surgery, which specific operation is indicated? Finally, can the operation be performed laparoscopically or are there risk factors that would made laparotomy a safer option? [12, 16].

**Table 1. Demographics of patients with perforated peptic ulcer disease [12, 13, 16, 31, 41-43, 45, 49, 51, 52, 58-87], [88-100]**

		Total n=2784
Age (years)	48	n=2328
Male (%)	79	n=2678
History of ulcer (%)	29	n=1140
History of NSAID use (%)	20	n=1109
Smokers (%)	62	n=472
Alcohol use (%)	29	n=198
ASA I (%)	35	n=1120
ASA II (%)	37	n=1060
ASA III (%)	20	n=1060
ASA IV (%)	9	n=1030
Boey 0 (%)	59	n=513
Boey 1 (%)	23	n=513
Boey 2 (%)	16	n=513
Boey 3 (%)	2	n=513
Shock at admission (%)	7	n=1107
Symptoms > 24 hrs (%)	11	n=723
Duration of symptoms (hrs)	13.6	n=837
Free air on x-ray (%)	85	n=510
WBC	12.3	n=147

### Pathogenesis

The pathogenesis of PUD may best be considered as representing a complex scenario involving an imbalance between defensive (mucus-bicarbonate layer, prostaglandins, cellular renovation, and blood flow) and aggressive factors (hydrochloric acid, pepsin, ethanol, bile salts, some medications, etc.) [15]. In recent years *Helicobacter pylori* (*H.pylori*) infection and NSAIDs have been identified as the two main causes of peptic ulcer.[17]. The use of crack cocaine has also led to an increase in PPU, but with a different underlying mechanism since PPU secondary to the use of crack cocaine is

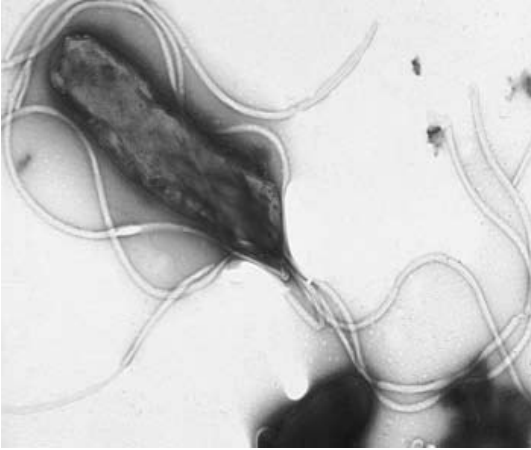caused by ischemia of the gastric mucosa and treatment of these perforations do not require acid reducing definitive surgery [12]. Three clinical phases in the process of PPU can be distinguished [4]. Phase 1: Chemical peritonitis/ contamination: The perforation causes a chemical peritonitis. Acid sterilizes gastroduodenal contents; it is only when gastric acid is reduced by treatment or disease (gastric cancer) that bacteria and fungi are present in the stomach and duodenum. Phase 2: Intermediate stage: after 6-12 hrs many patients obtain some spontaneous relief of the pain. This is probably due to the dilution of the irritating gastroduodenal contents by ensuing peritoneal exudates. Phase 3: Intra-abdominal infection: after 12-24 hrs intra-abdominal infection supervenes.

## Epidemiology

Perforation occurs in 2-10% of patients with PUD and accounts for more than 70% of deaths associated with PUD. Often perforation is the first clinical presentation of PUD [18]. The incidence of duodenal perforation is 7-10 cases/ 100.000 adults per year. [9, 15, 16, 19-22]. The perforation site usually involves the anterior wall of the duodenum (60%), although it might occur antral (20%) and lesser-curvature gastric ulcers (20%) [19]. Duodenal ulcer is the predominant lesion of the western population, whereas gastric ulcers are more frequent in oriental countries, particularly in Japan. Gastric ulcers have a higher associated mortality and a greater morbidity resulting from haemorrhage, perforation and obstruction [17]. PPU used to be a disorder mainly of younger patients (predominantly males), but recently the age of PPU patients is increasing (predominantly females) [16, 20]. Current peak age is 40-60 years [16]. The need for surgery for PPU has remained stable or even increased and the mortality of peptic ulcer surgery have not decreased since the introduction of H<sub>2</sub> receptor antagonists and peptic ulcers are still responsible for about 20.000-30.000 deaths per year in Europe [19, 23]. This may be due to an increase in use of aspirin and/ or NSAID's [12].

## The role of *Helicobacter pylori*

Until the discovery of the role of *H.pylori* in gastric and peptic ulcers by Barry J Marshall and Robin Warren in 1982, stress and life style factors were believed to be the most important factor contributing to PUD and PPU [24]. In more than 90% of duodenal ulcers and up to 80% of gastric ulcers *H.pylori* infection can be hold responsible [17, 24]. *H.pylori* infection and the accompanying inflammation disrupts



the inhibitory control of gastrin release by decreasing antral somatostatin, and this is more marked if the infecting organism is a *cagA*-positive strain [19]. The resulting increase in gastrin release and gastric acid secretion is a key mechanism by which the *H.pylori* infection induces PUD [19]. In most instances infection with *H.pylori* seems to be acquired

in early childhood. In contrast to many other infections, the immune system does not contribute to the healing. [3, 17]. Another problem with eradicating *H.pylori* is that it is not only located on the surface of the gastric mucosa but also in the layer of mucus protecting it. In 1994 the national institutes of Health Consensus Development Panel on *Helicobacter pylori* in PUD recommended that ulcer patients positive for *H.pylori* should be treated with antimicrobial agents [25]. The type, number of drugs given and treatment duration differ enormously [25]. Although the problem of antibiotic resistance of *H.pylori* is increasing, combination therapies such as metronidazole with clindamycin or metronidazole with tetracycline can achieve eradication rates of 80% or more [19, 26]. According to the Maastricht III consensus report first line treatment for *H.pylori* infection should be triple therapy which should comprise a proton pump inhibitor (PPI) plus clarithromycin plus amoxicillin or metronidazole [17, 27]. Monotherapy by just giving antibiotics has proven not to be successful (<30% eradication rate) [17]. Traditionally, peptic ulcer is diagnosed endoscopically, but this is an expensive tool and not well tolerated by patients [22]. Carbon 13-urea breath test is expensive, but represents a reliable indicator of *H.pylori* infection. The preferred method to diagnose *H.pylori* is by taking peroperative biopsies [22]. Even in patients with PPU and NSAID usage, it is advisable to look for the presence of *H.pylori*, since it can be eradicated easily. To avoid missing gastric cancer, gastroendoscopy should be performed in patients > 45 yrs with alarming features like weight loss, anaemia, or dysphagia [17].

## Current management PPU

**a. Non operative management** Conservative treatment is known as the Taylor method and consists of nasogastric aspiration, antibiotics, intravenous fluids and nowadays H.pylori triple therapy [23, 26]. In 1946 Taylor presented the first series of successfully outcome of conservatively treated patients with PPU, based on the theory that effective gastric decompression and continuous drainage will enhance self-healing [9],[26]. The fundamental idea for conservative treatment came from Crisp who in 1843 noted that perforations of the stomach were filled up by adhesions to the surrounding viscera which prevented leakage from the stomach into the peritoneum [26]. Since, many reports have been published on this topic, with different success rates [9]. But still there is an ongoing debate whether PPU generally needs to be operated on or not. It has been estimated that about 40-80% of the perforations will seal spontaneously and overall morbidity and mortality are comparable [19, 23, 26, 28]. However, delaying the time point of operation beyond 12h after the onset of clinical symptoms will worsen the outcome in PPU [9, 19]. Also in patients > 70 years conservative treatment is unsuccessful with a failure rate as high as 67% [9, 28]. Shock at admission and conservative treatment were associated with a high mortality rate (64%) [9, 23]. Patients likely to respond well to conservative treatment can be selected by performing a gastroduodenogram as described by Donovan.[26]. Non surgical treatment in these patients, who had proven sealing of their perforation site was safe, only resulted in 3% intraabdominal abscess formation and < 2% repeat leak [26]. The advantages of conservative treatment are avoidance of operation with associated morbidity caused by surgery and anesthesia, reduction in formation of intra-abdominal adhesion induced by surgery which makes elective surgery for PUD or for other indications in a later phase less complicated and hospital stay might be shorter [29]. However, there are also studies that showed a prolonged hospital stay after conservative treatment [13, 19]. Disadvantages are a higher mortality rate in case conservative treatment fails. Another disadvantage is the lack of the benefit of laparoscopy or laparotomy as a diagnostic tool in case the patient was misdiagnosed. [28, 29]. Finally one always has to bear in mind that PPU can be a symptom of gastric cancer, so if conservative treatment has been chosen after a few weeks endoscopy should be performed [9, 28]. For conclusion one can say that non operative treatment is limited to patients < 70 years, not eligible for surgical repair due to associated morbidity, with documented contrast studies showing that the perforation has

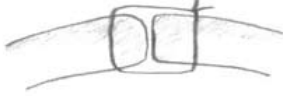
completely sealed. When the patient is in shock or is the time point between perforation and "start treatment" > 12 hours simple closure should be first choice of treatment.

**b. Simple suture Open repair technique:** All surgical procedures start by giving prophylactic antibiotics at induction of anesthesia. In conventional surgery an upper midline incision is performed. Identification of the site of perforation is not always easy: sometimes a perforation has occurred at the dorsal site of the stomach, only to be detected after opening of the lesser sac through the gastrocolic ligament. Also double perforations can occur. In case of a gastric ulcer a biopsy is taken to exclude gastric cancer. Simple closure of the perforation can be done in different ways (figure 1) : simple closure of the perforation by interrupted sutures without omentoplasty or (free) omental patch, simple closure of the perforation with a pedicled omentum sutured on top of the repair, representing omentoplasty, a pedicled omental plug drawn into the perforation after which the sutures are tied over it and finally the free omental patch after Graham. The repair can be tested by either filling the abdomen with warm saline and inflating some air into the nasogastric tube. If no bubbles appear, the perforation has been sealed appropriately. Also dye can be injected through the nasogastric tube [30]. Thorough peritoneal toilet followed is then performed. A drain is not routinely left [31]. The abdominal wound can be infiltrated with bupivacaine 0.25% at the end of the procedure.

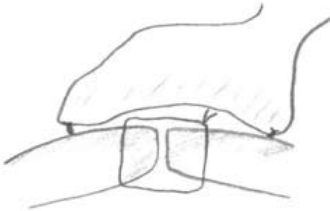

*Cellan Jones*

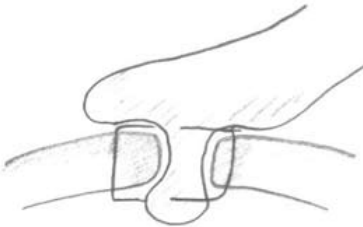
**Omentoplasty or omental patch: necessary or not?** Cellan-Jones published an article in 1929 entitled "a rapid method of treatment in perforated duodenal ulcers". Treatment of choice at that time was, after excision of friable edges if indicated, the application of purse string sutures and on top an omental graft [32]. An encountered problem was narrowing of the duodenum. To avoid this, he suggested omentoplasty without primary closing of the defect. His technique consisted of placing 4-6 sutures, selecting a long omental strand passing a fine suture through it,



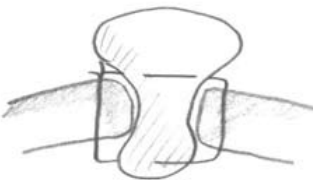Primary closure by interrupted sutures



Primary closure by interrupted suture covered with pedicled omentoplasty



Cellan-Jones repair: plugging the perforation with pedicled omentoplasty



Graham patch: plugging the perforation with free omental plug

Figure 1: Different suture techniques for closing perforation

the tip of the strand is then anchored in the region of the perforation and finally the sutures are tied off [32]. It was not until 1937 that Graham published his results with a free omental graft [33]. He placed three sutures with a piece of free omentum laid over these sutures, which are then tied. No attempt is made to actually close the perforation [33]. The omental graft provides the stimulus for fibrin formation. His approach has been the golden standard since [34]. Very often surgeons mention they used a Graham patch, but they actually mean they used the pedicled omental patch described by Cellan-Jones [33]. Schein could not have outlined it any clearer: "Do not stitch the perforation but plug it with viable omentum and patch a perforated ulcer if you can, if you cannot, then you must resect" [4].

**Irrigation of the peritoneal cavity** Although some surgeons doubt the usefulness of irrigation, nothing has been found in literature supporting this theory. General it is reflected on to be one of the most important parts of the surgery and irrigation with 6-10 litres and even up to 30 litres of warm saline are recommended [16]. However the rationale for routinely use of intra-operative peritoneal lavage seems to be more a historical based custom lacking any evidence based support [35].

**Drainage or not** There seems to be no unanimity of opinion on this topic [16, 30]. In a questionnaire 80% of the responders answered that they would not leave a drain [30]. A drain will not reduce the incidence of intraabdominal fluid collections or abscesses [30]. On the other hand the drain site can become infected (10%) and can cause intestinal obstruction [30, 36]. Often a drain is left as a sentinel. However, in case of suspected leakage a CT- scan will provide all the information needed, probably better than a non-productive drain.

**c. Definitive surgery** Indications for elective surgery are still not defined [19]. The number of elective procedures performed for PUD have declined with more than 70% since the 80's [19, 22]. The results of a questionnaire with 607 responders showed that only 0.3% of the surgeons routinely perform a vagotomy for duodenal ulcer complications and 54.5% mentioned they never include it [37]. Reasons for decline in definitive ulcer surgery are: lower recurrence rate of PUD and PPU because of good results of H.pylori eradication and elimination of NSAID use. Also patients nowadays operated for PPU are older with higher surgical risk which make them less suitable



candidates for definitive ulcer surgery. Finally many surgeons practising today have limited experience with definitive ulcer operations [22]. Patients in which definitive ulcer surgery should be considered are those with PPU who are found to be H.pylori negative, or those with recurrent ulcers despite triple therapy [12, 19, 26, 38, 39]. In these patients a parietal cell vagotomy is recommended if necessary combined with anterior linear gastrectomy [40]. This procedure can be safely and relatively easy performed laparoscopically [19, 22].

**d. Laparoscopy** Since the 90's laparoscopic closure of a perforated peptic ulcer has been described. Laparoscopic surgery offers several advantages. First of all a laparoscopic procedure serves as a minimal invasive diagnostic tool.[41]. Other benefits from laparoscopic repair are postoperative pain reduction and less consumption of analgesics and a reduction in hospital stay [42]. Also a reduction in wound infections, burst abdomen and incisional hernia due to shorter scars has been noted [16, 42]. Avoiding upper laparotomy might lower the incidence of postoperative ileus and chest infections [16, 42]. Drawbacks are a prolonged operating time, higher incidence of re-operations due to leakage at the repair site and a higher incidence of intra-abdominal collection secondary to inadequate lavage [16, 42, 43]. If the presence of these fluid collections have any clinical relevance is unclear. The higher incidence of leakage might be caused by the difficulty of the laparoscopic suturing procedure. First of all this emphasises the need for a dedicated laparoscopically trained surgeon to perform this procedure [13]. Alternative techniques to simplify the suturing process have been thought of. [13, 42]. Some laparoscopic surgeons use omentopexy alone [12, 41]. Suture less techniques have been tried, in which fibrin glue alone or a gelatine sponge has been glued into the ulcer [12]. The downside of this technique is that is only can be used to close small perforations. To overcome this problem a biodegradable patch, that can be cut into any desirable size, has been tested in rats, with good results [44]. Finally, combined laparoscopic-endoscopic repair has been described as well [45].

**Postoperative management** Reviewing literature all patients receive nasogastric probing for at least 48 hrs [16]. This however seems to be more "common practice" than evidence based medicine [46]. A recently published Cochrane review concludes that routine nasogastric decompression does not accomplish any of its attended goals

and should only be applied in selected cases, which has been supported by other trials as well [46-48]. This also means that oral feeding can be started early, as in colorectal surgery and that waiting for three days, as often is done according to protocol, is unnecessary [48, 49]. As can be seen in table 2 wound infections represent the second most common complication after surgery for PPU. Also the incidence of sepsis is 2.5%. Preoperative intravenous administration of antibiotics has proven to lower the overall infection rate [50]. Although for most surgical procedures a single dose seems to be sufficient, in case of *H. pylori* infection triple therapy is recommended consisting of a proton pump inhibitor combined with clarithromycin and amoxicillin for 14 days [16, 27, 49, 50]. Upper gastrointestinal endoscopy is suggested to be performed after eight weeks to assess healing of the ulcers and to evaluate *H. pylori* status [49].

**Postoperative complications** The postoperative complication most common observed was pneumonia, followed by wound infection. An overview of all complications and their incidences, based on reviewing literature are listed in table 2 [13, 16, 19, 20, 42, 43, 51-55].

**Risk factors influencing outcome** Mortality after surgery for perforated peptic ulcer is between 6-10% [20]. There are four main factors which can increase this mortality rate even up to 100%. These are age > 60 years, delayed treatment (>24hrs), shock at admission (systolic BP < 100 mmHg) and concomitant diseases [19, 21]. Also gastric ulcers are associated with a two- to threefold increased mortality risk [19, 22]. Boey's score, which is a score based on scoring factors as shock on admission, confounding medical illness, and prolonged perforation, has been found to be a useful tool in predicting outcome (table 3) [16, 23, 39, 51].

**Perforated peptic ulcer in the elderly** Mortality rate after surgery for PPU is three to five times higher in the elderly up to 50% [56]. This can be explained by the occurrence of concomitant medical diseases but also by difficulties making the right diagnosis resulting into delay > 24 hrs [56]. In case of a perforated gastric ulcer or recurrent PUD (hemi)gastrectomy with vagotomy might be indicated, but overall simple closure is a safe procedure and there seem to be no need for definitive surgery in this group of patients since ulcer recurrence is only 14% [12, 56, 57].

**Conclusion** Surgery for perforated peptic ulcer still is a subject of debate despite more than an era of published expertise. Reviewing different policies regarding for instance the indication for conservative treatment, sense or no sense of drains, the need for omentoplasty or not, performing the procedure laparoscopically and the need for definitive ulcer surgery, might contribute to establishing consensus.

**Table 2. Overview complications after surgery for ppu [13, 16, 19, 20, 42, 43, 51-55]**

Complication	Incidence
Pneumonia	3.6-30%
Wound infection	10-17%
Urinary tract infection	1.4-15%
Suture leak	2-16%
Abscess formation	0-9%
Heart problems (myocardial infarction, heart failure)	5%
Ileus	2-4%
Fistula	0.5-4%
Wound dehiscence	2.5-6%
Biliary leak	4.9%
Bleeding	0.6%
Re-operation	2-9%
Sepsis	2.5%
Stroke	4%
Death	5-11%

**Table 3: Boey's score related to morbidity and mortality**

	Morbidity rate	Mortality rate
Boey 0	17.4%	1.5%
Boey 1	30.1%	14.4%
Boey 2	42.1%	32.1%
Boey 3		100%

### References

1. Baron JH: *Paintress, princess and physician's paramour: poison or perforation?* *J R Soc Med* 1998, 91(4):213-216.
2. Baron JH: *Peptic ulcer. The mount sinai journal of medicine* 2000, 67(1):58-62.
3. Baron JH, Sonnenberg A: *Publications on peptic ulcer in Britain, France, Germany and the US.* *Eur J Gastroenterol Hepatol* 2002, 14(7):711-715.
4. Schein M: *Perforated peptic ulcer. In: Schein's common sense emergency abdominal surgery. vol. part III: Springer Berlin Heidelberg; 2005: 143-150.*
5. Rayner HH: *Treatment of perforated peptic ulcer. The Lancet* 1930(11):107-108.
6. Sangster AH: *Perforated peptic ulcer. An analysis of 100 consecutive cases. The Lancet* 1939, 23:1311-1313.
7. Berson HL: *Acute perforated peptic ulcers. An eighteen-year survey. American journal of surgery* 1942, 16(2):385-394.
8. Hastings N, Machida R: *Perforated peptic ulcer: results after simple surgical closure. American journal of surgery* 1961, 102:136-142.
9. *Conservative management of perforated peptic ulcer. The Lancet* 1989, 16:1429-1430.
10. Lau WY, Leow CK: *History of perforated duodenal and gastric ulcers. World journal of surgery* 1997, 21(8):890-896.
11. Birks PM: *Perforated peptic ulcer treated without operation. The Lancet* 1947(5):467-468.
12. Lagoo S, McMahon RL, Kakihara M, Pappas TN, Eubanks S: *The sixth decision regarding perforated duodenal ulcer. JsIs* 2002, 6(4):359-368.
13. Lau WY: *Perforated peptic ulcer: open versus laparoscopic repair. Asian J Surg* 2002, 25(4):267-269.
14. Fujii Y, Asato M, Taniguchi N, Shigeta K, Omoto K, Itoh K, Suzukawa M: *Sonographic diagnosis and successful nonoperative management of sealed perforated duodenal ulcer. J Clin Ultrasound* 2003, 31(1):55-58.
15. Ramakrishnan K, Salinas RC: *Peptic ulcer disease. Am Fam Physician* 2007, 76(7):1005-1012.
16. Lunevicius R, Morkevicius M: *Management strategies, early results, benefits, and risk factors of laparoscopic repair of perforated peptic ulcer. World journal of surgery* 2005, 29(10):1299-1310.
17. Sivri B: *Trends in peptic ulcer pharmacotherapy. Fundam Clin Pharmacol* 2004, 18(1): 23-31.

18. Druart ML, Van Hee R, Etienne J, Cadiere GB, Gigot JF, Legrand M, Limbosch JM, Navez B, Tugilimana M, Van Vyve E et al: Laparoscopic repair of perforated duodenal ulcer. A prospective multicenter clinical trial. *Surg Endosc* 1997, 11(10):1017-1020.
19. Zittel TT, Jehle EC, Becker HD: Surgical management of peptic ulcer disease today-- indication, technique and outcome. *Langenbecks Arch Surg* 2000, 385(2):84-96.
20. Imhof M, Epstein S, Ohmann C, Roher HD: Duration of survival after peptic ulcer perforation. *World journal of surgery* 2008, 32(3):408-412.
21. Sarosi GA, Jr., Jaiswal KR, Nwariaku FE, Asolati M, Fleming JB, Anthony T: Surgical therapy of peptic ulcers in the 21st century: more common than you think. *American journal of surgery* 2005, 190(5):775-779.
22. Harbison SP, Dempsey DT: Peptic ulcer disease. *Current problems in surgery* 2005, 42(6):346-454.
23. Bucher P, Oulhaci W, Morel P, Ris F, Huber O: Results of conservative treatment for perforated gastroduodenal ulcers in patients not eligible for surgical repair. *Swiss Med Wkly* 2007, 137(23-24):337-340.
24. Ahmed N: 23 years of the discovery of *Helicobacter pylori*: is the debate over? *Ann Clin Microbiol Antimicrob* 2005, 4:17.
25. Fischbach LA, Goodman KJ, Feldman M, Aragaki C: Sources of variation of *Helicobacter pylori* treatment success in adults worldwide: a meta-analysis. *Int J Epidemiol* 2002, 31(1):128-139.
26. Donovan AJ, Berne TV, Donovan JA: Perforated duodenal ulcer: an alternative therapeutic plan. *Arch Surg* 1998, 133(11):1166-1171.
27. Malfertheiner P, Megraud F, O'Morain C, Bazzoli F, El-Omar E, Graham D, Hunt R, Rokkas T, Vakil N, Kuipers EJ: Current concepts in the management of *Helicobacter pylori* infection: the Maastricht III Consensus Report. *Gut* 2007, 56(6):772-781.
28. Crofts TJ, Park KG, Steele RJ, Chung SS, Li AK: A randomized trial of nonoperative treatment for perforated peptic ulcer. *N Engl J Med* 1989, 320(15):970-973.
29. Truscott B, Withycombe JFR: Perforated peptic ulcer. An assessment of the value of nonoperative treatment. *The Lancet* 1950, 13:894-896.
30. Schein M: To drain or not to drain? The role of drainage in the contaminated and infected abdomen: an international and personal perspective. *World journal of surgery* 2008, 32(2):312-321.
31. Siu WT, Leong HT, Law BK, Chau CH, Li AC, Fung KH, Tai YP, Li MK: Laparoscopic repair for perforated peptic ulcer: a randomized controlled trial. *Annals of surgery* 2002, 235(3):313-319.

32. Cellan-Jones CJ: A rapid method of treatment in perforated duodenal ulcer. *BMJ* 1929(36):1076-1077.
33. Graham R, R: The treatment of perforated duodenal ulcers. *Surg gynecol Obstet* 1937(64):235-238.
34. Fallat ME, White MJ, Richardson JD, Flint LM: Reassessment of Graham-Steele closure in acute perforated peptic ulcer. *South Med J* 1983, 76(10):1222-1224.
35. Whiteside OJ, Tytherleigh MG, Thrush S, Farouk R, Galland RB: Intra-operative peritoneal lavage--who does it and why? *Annals of the Royal College of Surgeons of England* 2005, 87(4):255-258.
36. Pai D, Sharma A, Kanungo R, Jagdish S, Gupta A: Role of abdominal drains in perforated duodenal ulcer patients: a prospective controlled study. *Aust N Z J Surg* 1999, 69(3):210-213.
37. Branicki FJ: Abdominal emergencies: diagnostic and therapeutic laparoscopy. *Surg Infect (Larchmt)* 2002, 3(3):269-282.
38. Schwesinger WH, Page CP, Sirinek KR, Gaskill III HV, Melnick G, Strodel WE: Operations for peptic ulcer disease: paradigm lost. *J Gastrointest Surg* 2001, 5:438-443.
39. Chandra SS, Kumar SS: Definitive or conservative surgery for perforated gastric ulcer? -An unresolved problem. *International Journal of Surgery* 2009:1-4.
40. Jordan PH, Jr., Thornby J: Perforated pyloroduodenal ulcers. Long-term results with omental patch closure and parietal cell vagotomy. *Annals of surgery* 1995, 221(5):479-486; discussion 486-478.
41. Ates M, Coban S, Sevil S, Terzi A: The efficacy of laparoscopic surgery in patients with peritonitis. *Surgical laparoscopy, endoscopy & percutaneous techniques* 2008, 18(5):453-456.
42. Lau H: Laparoscopic repair of perforated peptic ulcer: a meta-analysis. *Surg Endosc* 2004, 18(7):1013-1021.
43. Lunevicius R, Morkevicius M: Risk factors influencing the early outcome results after laparoscopic repair of perforated duodenal ulcer and their predictive value. *Langenbecks Arch Surg* 2005, 390(5):413-420.
44. Bertleff MJ, Liem RS, Bartels HL, Robinson PH, Van der Werff JF, Bonjer HJ, Lange JF: The "stamp method": a new treatment for perforated peptic ulcer? *Surg Endosc* 2006, 20(5):791-793.
45. Alvarado-Aparicio HA, Moreno-Portillo M: Multimedia article: management of duodenal ulcer perforation with combined laparoscopic and endoscopic methods. *Surg Endosc* 2004, 18(9):1394.

46. Nelson R, Edwards S, Tse B: Prophylactic nasogastric decompression after abdominal surgery. *Cochrane database of systematic reviews (Online)* 2007(3):CD004929.
47. Daryaei P, Vaghef Davari F, Mir M, Harirchi I, Salmasian H: Omission of nasogastric tube application in postoperative care of esophagectomy. *World journal of surgery* 2009, 33(4):773-777.
48. St Peter SD, Valusek PA, Little DC, Snyder CL, Holcomb GW, 3rd, Ostlie DJ: Does routine nasogastric tube placement after an operation for perforated appendicitis make a difference? *The Journal of surgical research* 2007, 143(1):66-69.
49. Siu WT, Chau CH, Law BK, Tang CN, Ha PY, Li MK: Routine use of laparoscopic repair for perforated peptic ulcer. *The British journal of surgery* 2004, 91(4):481-484.
50. Waddell TK, Rotstein OD: Antimicrobial prophylaxis in surgery. *Committee on Antimicrobial Agents, Canadian Infectious Disease Society. Cmaj* 1994, 151(7):925-931.
51. Lunevicius R, Morkevicius M: Comparison of laparoscopic versus open repair for perforated duodenal ulcers. *Surg Endosc* 2005, 19(12):1565-1571.
52. Lam PW, Lam MC, Hui EK, Sun YW, Mok FP: Laparoscopic repair of perforated duodenal ulcers: the "three-stitch" Graham patch technique. *Surg Endosc* 2005, 19(12):1627-1630.
53. Gupta S, Kaushik R, Sharma R, Attri A: The management of large perforations of duodenal ulcers. *BMC Surg* 2005, 5:15.
54. Rahuman MM, Saha AK, Rahim A: Experience of peptic ulcer perforation over a decade in a teaching hospital of southern Bangladesh. *Ceylon Med J* 2003, 48(2):53-55.
55. Sharma SS, Mamtani MR, Sharma MS, Kulkarni H: A prospective cohort study of postoperative complications in the management of perforated peptic ulcer. *BMC Surg* 2006, 6:8.
56. Feliciano DV, Bitondo CG, Burch JM, Mattox KL, Jordan GL, Jr., DeBakey ME: Emergency management of perforated peptic ulcers in the elderly patient. *American journal of surgery* 1984, 148(6):764-767.
57. Blomgren LG: Perforated peptic ulcer: long-term results after simple closure in the elderly. *World journal of surgery* 1997, 21(4):412-414; discussion 414-415.
58. Agresta F, Mazzarolo G, Ciardo LF, Bedin N: The laparoscopic approach in abdominal emergencies: has the attitude changed? : A single-center review of a 15-year experience. *Surg Endosc* 2008, 22(5):1255-1262.
59. Sanabria AE, Morales CH, Villegas MI: Laparoscopic repair for perforated peptic ulcer disease. *Cochrane database of systematic reviews (Online)* 2005(4):CD004778.

60. Vaidya BB, Garg CP, Shah JB: Laparoscopic Repair of Perforated Peptic Ulcer with Delayed Presentation. *J Laparoendosc Adv Surg Tech A* 2009.
61. Song KY, Kim TH, Kim SN, Park CH: Laparoscopic repair of perforated duodenal ulcers: the simple "one-stitch" suture with omental patch technique. *Surg Endosc* 2008, 22(7):1632-1635.
62. Ates M, Sevil S, Bakircioglu E, Colak C: Laparoscopic repair of peptic ulcer perforation without omental patch versus conventional open repair. *J Laparoendosc Adv Surg Tech A* 2007, 17(5):615-619.
63. Bhogal RH, Athwal R, Durkin D, Deakin M, Cheruvu CN: Comparison between open and laparoscopic repair of perforated peptic ulcer disease. *World journal of surgery* 2008, 32(11):2371-2374.
64. Kirshtein B, Bayme M, Mayer T, Lantsberg L, Avinoach E, Mizrahi S: Laparoscopic treatment of gastroduodenal perforations: comparison with conventional surgery. *Surg Endosc* 2005, 19(11):1487-1490.
65. Lunevicius R, Morkevicius M: Systematic review comparing laparoscopic and open repair for perforated peptic ulcer. *The British journal of surgery* 2005, 92(10):1195-1207.
66. Palanivelu C, Jani K, Senthilnathan P: Laparoscopic management of duodenal ulcer perforation: is it advantageous? *Indian J Gastroenterol* 2007, 26(2):64-66.
67. Sauerland S, Agresta F, Bergamaschi R, Borzellino G, Budzynski A, Champault G, Fingerhut A, Isla A, Johansson M, Lundorff P et al: Laparoscopy for abdominal emergencies: evidence-based guidelines of the European Association for Endoscopic Surgery. *Surg Endosc* 2006, 20(1):14-29.
68. Wong BP, Chao NS, Leung MW, Chung KW, Kwok WK, Liu KK: Complications of peptic ulcer disease in children and adolescents: minimally invasive treatments offer feasible surgical options. *J Pediatr Surg* 2006, 41(12):2073-2075.
69. Aali AYA, Bestoun HA: Laparoscopic repair of perforated duodenal ulcer. *The middle east journal of emergency medicine* 2002.
70. Agresta F, Michelet I, Coluci G, Bedin N: Emergency laparoscopy: a community hospital experience. *Surg Endosc* 2000, 14(5):484-487.
71. Arnaud JP, Tuech JJ, Bergamaschi R, Pessaux P, Regenet N: Laparoscopic suture closure of perforated duodenal peptic ulcer. *Surgical laparoscopy, endoscopy & percutaneous techniques* 2002, 12(3):145-147.
72. Bergamaschi R, Marvik R, Johnsen G, Thoresen JE, Ystgaard B, Myrvold HE: Open vs laparoscopic repair of perforated peptic ulcer. *Surg Endosc* 1999, 13(7):679-682.



73. Bohm B, Ablassmaier B, Muller JM: [Laparoscopic surgery of the upper gastrointestinal tract]. *Chirurg* 2001, 72(4):349-361.
74. Dubois F: New surgical strategy for gastroduodenal ulcer: laparoscopic approach. *World journal of surgery* 2000, 24(3):270-276.
75. Freston JW: Management of peptic ulcers: emerging issues. *World journal of surgery* 2000, 24(3):250-255.
76. Gentileschi P, Rossi P, Manzelli A, Lirosi F, Susanna F, Stolfi VM, Spina C, Gaspari AL: Laparoscopic suture repair of a perforated gastric ulcer in a severely cirrhotic patient with portal hypertension: first case report. *Jsls* 2003, 7(4):377-382.
77. Katkhouda N, Mavor E, Mason RJ, Campos GM, Soroushyari A, Berne TV: Laparoscopic repair of perforated duodenal ulcers: outcome and efficacy in 30 consecutive patients. *Arch Surg* 1999, 134(8):845-848; discussion 849-850.
78. Khoursheed M, Fuad M, Safar H, Dashti H, Behbehani A: Laparoscopic closure of perforated duodenal ulcer. *Surg Endosc* 2000, 14(1):56-58.
79. Lau JY, Lo SY, Ng EK, Lee DW, Lam YH, Chung SC: A randomized comparison of acute phase response and endotoxemia in patients with perforated peptic ulcers receiving laparoscopic or open patch repair. *American journal of surgery* 1998, 175(4):325-327.
80. Lee FY, Leung KL, Lai BS, Ng SS, Dexter S, Lau WY: Predicting mortality and morbidity of patients operated on for perforated peptic ulcers. *Arch Surg* 2001, 136(1):90-94.
81. Lee FY, Leung KL, Lai PB, Lau JW: Selection of patients for laparoscopic repair of perforated peptic ulcer. *The British journal of surgery* 2001, 88(1):133-136.
82. Malkov IS, Zaynutdinov AM, Veliyev NA, Tagirov MR, Merrell RC: Laparoscopic and endoscopic management of perforated duodenal ulcers. *Journal of the American College of Surgeons* 2004, 198(3):352-355.
83. Millat B, Fingerhut A, Borie F: Surgical treatment of complicated duodenal ulcers: controlled trials. *World journal of surgery* 2000, 24(3):299-306.
84. Robertson GS, Wemyss-Holden SA, Maddern GJ: Laparoscopic repair of perforated peptic ulcers. The role of laparoscopy in generalised peritonitis. *Annals of the Royal College of Surgeons of England* 2000, 82(1):6-10.
85. Seelig MH, Seelig SK, Behr C, Schonleben K: Comparison between open and laparoscopic technique in the management of perforated gastroduodenal ulcers. *J Clin Gastroenterol* 2003, 37(3):226-229.
86. Tsumura H, Ichikawa T, Hiyama E, Murakami Y: Laparoscopic and open approach in perforated peptic ulcer. *Hepatogastroenterology* 2004, 51(59):1536-1539.

87. Wemyss-Holden S, White SA, Robertson G, Lloyd D: Color coding of sutures in laparoscopic perforated duodenal ulcer: a new concept. *Surgical laparoscopy, endoscopy & percutaneous techniques* 2002, 12(3):177-179.
88. Bertleff MJ, Halm JA, Bemelman WA, van der Ham AC, van der Harst E, Oei HI, Smulders JF, Steyerberg EW, Lange JF: Randomized Clinical Trial of Laparoscopic Versus Open Repair of the Perforated Peptic Ulcer: The LAMA Trial. *World journal of surgery* 2009, 33(7):1368-1373.
89. Bloechle C, Emmermann A, Zornig C: Laparoscopic and conventional closure of perforated peptic ulcer. *Surg Endosc* 1997, 11(12):1226-1227.
90. Boey J, Wong J: Perforated duodenal ulcers. *World journal of surgery* 1987, 11(3):319-324.
91. Golash V, Willson PD: Early laparoscopy as a routine procedure in the management of acute abdominal pain: a review of 1,320 patients. *Surg Endosc* 2005, 19(7):882-885.
92. Lau WY, Leung KL, Kwong KH, Davey IC, Robertson C, Dawson JJ, Chung SC, Li AK: A randomized study comparing laparoscopic versus open repair of perforated peptic ulcer using suture or sutureless technique. *Annals of surgery* 1996, 224(2):131-138.
93. Lee KH, Chang HC, Lo CJ: Endoscope-assisted laparoscopic repair of perforated peptic ulcers. *Am Surg* 2004, 70(4):352-356.
94. Lohsiriwat V, Prapasrivorakul S, Lohsiriwat D: Perforated peptic ulcer: clinical presentation, surgical outcomes, and the accuracy of the Boey scoring system in predicting postoperative morbidity and mortality. *World journal of surgery* 2009, 33(1):80-85.
95. Matsuda M, Nishiyama M, Hanai T, Saeki S, Watanabe T: Laparoscopic omental patch repair for perforated peptic ulcer. *Annals of surgery* 1995, 221(3):236-240.
96. Memon MA: Laparoscopic omental patch repair for perforated peptic ulcer. *Annals of surgery* 1995, 222(6):761-762.
97. Miserez M, Eypasch E, Spangenberger W, Lefering R, Troidl H: Laparoscopic and conventional closure of perforated peptic ulcer. A comparison. *Surg Endosc* 1996, 10(8):831-836.
98. Rossi S: Laparoscopy in gastrointestinal emergency. *European Surgery* 2005, 36:15-18.
99. So JB, Kum CK, Fernandes ML, Goh P: Comparison between laparoscopic and conventional omental patch repair for perforated duodenal ulcer. *Surg Endosc* 1996, 10(11):1060-1063.
100. Urbano D, Rossi M, De Simone P, Berloco P, Alfani D, Cortesini R: Alternative laparoscopic management of perforated peptic ulcers. *Surg Endosc* 1994, 8(10):1208-1211.

**Laparoscopic correction of  
Perforated Peptic Ulcer: first choice?  
A review of literature**

### **Abstract**

**Background** Perforated peptic ulcer (PPU), despite anti-ulcer medication and *Helicobacter* eradication, is still the most common indication for emergency gastric surgery associated with high morbidity and mortality. Outcome might be improved by performing this procedure laparoscopically, but there is no consensus on whether the benefits of laparoscopic closure of perforated peptic ulcer outweigh the disadvantages such as prolonged surgery time and greater expenses.

**Methods** An electronic literature search was done by using PubMed and EMBASE databases. Relevant papers written between January 1989 and May 2009 were selected and scored according to Effective Public Health Practice Project guidelines.

**Results** Data were extracted from 56 papers, as summarized in tables 1-7. The overall conversion rate for laparoscopic correction of perforated peptic ulcer was 12.4%, with main reason for conversion being the diameter of perforation. Patients presenting with PPU were predominantly men (79%) with an average age of 48 years. One-third had a history of peptic ulcer disease, and one-fifth took nonsteroidal anti-inflammatory drugs (NSAIDs). Only 7% presented with shock at admission. There seems to be no consensus on the perfect setup for surgery and/ or operating technique. In the laparoscopic groups, operating time was significant longer and incidence of recurrent leakage at the repair site was higher. Nonetheless there was significant less postoperative pain, lower morbidity, less mortality, and a shorter hospital stay.

**Conclusion** There are good arguments that laparoscopic correction of PPU should be first treatment of choice. A Boey score of 3, age over 70 years, and symptoms persisting longer than 24 h are associated with higher morbidity and mortality and should be considered contraindications for laparoscopic intervention.

## Introduction

Since the late 1980s, laparoscopy has become increasingly popular. In the beginning laparoscopy was mainly used for elective surgery since it was not clear what the influence was of the pneumoperitoneum on the acute abdomen with peritonitis. However the benefits of laparoscopy with regard to the acute abdomen as a diagnostic tool have been established since, and also its therapeutic possibilities seem to be advantageous [1-3]. The rapid development of laparoscopic surgery has further complicated the issue of the best approach for the management of perforated peptic ulcer (PPU) [4]. PPU is a condition in which laparoscopic repair is an attractive option. Not only is it possible to identify site and pathology of the perforation, but the procedure also allows closure of the perforation and peritoneal lavage, just like in open repair but without a large upper abdominal incision [5,6]. Nonetheless, not all patients are suitable for laparoscopic repair [5].

Despite many trials (mostly non randomized or retrospective) the routine treatment for perforated peptic ulcer still seems to be by upper laparotomy, representing the main motive for reviewing the literature and summarizing all (significant) results.

## Methods

An extensive electronic literature search was done by using PubMed and EMBASE databases. Keywords used for searching were "laparoscopic" "correction" "repair" and "peptic ulcer". All papers in English or German language published between January 1989 and May 2009 were included. Papers were scored according to Effective Public Health Practice Project (EPHPP) guidelines as advised in Jackson's guidelines for systematic reviews [7]. Using this rating system a paper was classified as weak, moderate or strong.

## Results

Fifty-six relevant articles were found by PubMed and EMBASE search. Of these, 36 were prospective or retrospective trials, 5 were review articles, 3 articles described new techniques making laparoscopic correction of PPU more accessible and 12 were general, of which 1 was the European Association for Endoscopic Surgery (EAES) guideline. [1-6,8-57]. Study details are listed in Table 1. Based on patient details and selection criteria as reported in these papers a general overview could be made of the average symptoms of a patient presenting with acute abdominal pain suspected for

PPU and of the results of additional diagnostic tools such as X-ray and blood sample (Table 2). Three papers published results of randomized controlled trials (RCTs) [29,46,57]. Since these were the only RCTs comparing laparoscopic repair with open repair for PPU, their results have been listed separately in Table 3. All three showed significant reduction in postoperative pain in the laparoscopic group, and Siu et al. concluded that morbidity was significantly lower in the laparoscopic group [29]. Two of these RCTs concluded that operating time was significantly longer, though the other group showed a significantly shorter operating time. In 29 studies the surgical technique used for laparoscopic correction of PPU was mentioned in the 'Material and Methods' section. These details are summarized in Table 4. Table 5 gives an overview of the total amount of complications observed after surgery for PPU by either laparoscopic technique or open closure. It is noticeable that the incidence of scar problems after surgery for PPU was as high as 9.9%. Also, mortality after surgery for peptic ulcer disease, despite all technical and medical improvement was still 5.8%. The average conversion rate was 12.4% (Table 1). Reasons for conversion are listed in Table 6. The three most common reasons for conversion were size of perforation (often > 10mm), inadequate ulcer localization and difficulties placing reliable sutures due to friable edges. Table 7 compares results between laparoscopic and open repair with regard to most important parameters such as postoperative pain, bowel action, hospital stay, morbidity and mortality. Finally Table 8 gives an overview of the conclusions drawn by 40 papers.

Table 1. Overview studies

Study	EPHPP	Study design	Number patients	Procedure	Conversion rate (%)
Vaidya 2009	Weak	NRP	31	Lap	6.5
Ates 2008	Moderate	NRP	17	Lap	17.6
Song 2008	Weak	NRP	35	Lap	5.7
Bhogal 2008	Moderate	NRP	19	Lap	0.0
			14	Open	
Ates 2007	Weak	NRP	17	Lap	17.6
			18	Open	
Malkov 2004	Moderate	NRP	42	Lap	0.0
			40	Open	
Siu 2004	Moderate	NRP	172	Lap	21.5
Arnaud 2002	Weak	NRP	30	Lap	16.6
Lee 2001	Weak	NRP	155	Lap	28.5
			219	Open	
Khourseed 2000	Weak	NRP	21	Lap	4.7
Kathkouda 1999	Weak	NRP	30	Lap	17.0
			16	Open	
Bergamaschi 1999	Weak	NRP	17	Lap	23.5
		N	62	Open	
Matsuda 1995	Weak	NRP	11	Lap	21.4
			55	Open	
Lee 2004	Weak	NRP	30	Lap	3.3
Druart	Moderate	NRP	100	Lap	8.0
Siu 2002	Strong	PR	63	Lap	14.2
			58	Open	
Lau 1996	Moderate	PR	52	Lap	23.0
			51	Open	
Bertleff 2009	Strong	PR	52	Lap	7.7
			49	Open	
Palanivelu 2007	Weak	R	120	Lap	0.0
Lunevicius 2005	Moderate	R	60	Lap	23.3
			162	Open	
Lunevicius IV	Weak	R	60	Lap	23.3
Kirshtein 2005	Weak	R	68	Lap	4.4
			66	Open	
Tsumura 2004	Weak	R	58	Lap	12.0
			13	Open	
Seelig 2003	Weak	R	24	Lap	12.5
			31	Open	
Al Aali 2002	Weak	R	60	Lap	6.6
			38	Open	
Lee 2001 I	Weak	R	209	Lap	26.8
			227	Open	
Robertson	Weak	R	20	Lap	10.0
			16	Open	
So 1996	Weak	R	15	Lap	6.6
			38	Open	
Johansson 1996	Weak	R	10	Lap	0.0
			17	Open	
<b>Total</b>			<b>2788</b>		<b>12.4</b>

NRP = non randomized prospective, PR = prospective randomized, R = retrospective  
 EPHPP = Effective Public Health Practice Project

**Table 2. Demographics of patients with perforated peptic ulcer disease**

		Total n=2784	
Age (years)		48	n=2328
Male (%)		79	n=2678
History of ulcer (%)		29	n=1140
History of NSAID use (%)		20	n=1109
Smokers (%)		62	n=472
Alcohol use (%)		29	n=198
ASA I (%)		35	n=1120
ASA II (%)		37	n=1060
ASA III (%)		20	n=1060
ASA IV (%)		9	n=1030
Boey 0		59	n=513
Boey 1		23	n=513
Boey 2		16	n=513
Boey 3		2	n=513
Shock at admission (%)		7	n=1107
Duration of symptoms (hrs)		13.6	n=837
Free air on x-ray (%)		85	n=510
Symptoms > 24 hrs (%)		11	n=723
Size perforation (mm)		5.5	n=691
Manheim peritonitis index		15.1	n=220
WBC		12.3	n=147
Localization ulcer	Duodenal (%)	67	n=1355
	Juxtapyloric (%)	23	n=1355
	Gastric (%)	17	n=1355

WBC = white blood cells



**Table 3. Results of prospective randomized trials**

Laparoscopic correction	Siu 2002	Lau 1996	Bertleff 2009	Average
Operating time (min)	42	94	75	70.3
Nasogastric tube (days)	3.0	2.5	2.0	2.5
Normal diet (days)		4.0		4.0
Postoperative opiate use	0 injections	1.5 days	1 day	
Hospital stay (days)		5.5	6.5	6.0
Morbidity (%)	25	23	18	22.0
Normal daily activities (days)	10.4			10.4
Mortality (%)	1.6	2	3.8	2.5
Ileus (days)			0	0.0
Woundinfection (%)			0	0.0
Leakage (%)		2.1	3.8	3.0
VAS day 1	3.5	4.0	3.8	3.8
VAS day 3	1.6		2.1	1.9

Open correction	Siu 2002	Lau 1996	Bertleff 2009	Average
Operating time (min)	52.3	54	50	52.1
Nasogastric tube (days)	3.0	2.5	3.0	2.8
Normal diet (days)		4.0		4.0
Postoperative opiate use	6 injections	3.5 days	1 day	
Hospital stay (days)		5	8	6.5
Morbidity (%)	50	22	36	36.0
Normal daily activities (days)	26.1			26.1
Mortality (%)	5.2	4.0	8.1	5.8
Ileus (days)			2.0	2.0
Woundinfection (%)			6.1	6.1
Leakage (%)		2.2	0	1.1
VAS day 1	6.4	5.0	5.2	5.5
VAS day 3	3.3		3.0	3.2

VAS visual analog scale

**Table 4. Surgical technique (29 studies)**

Closure of perforation	66% omental patch	24% mixed techniques	10% sutures only
Pneumoperitoneum	26% Hassan trocar	47% veress needle	26% mixed
Pneumoperitoneum	75% 12 mmHG	25% 11 or 14 mmHg	
Cameraposition	35% supraumbilical	35% umbilical	30% infraumbilical
Number of trocars used	60% 4 trocars	40% 3 trocars	
Position surgeon	44% between legs	33% left side patient	16% between of left side 6% right side
Irrigation fluid	45% generous	55% between 2-6 liters	
Camera	80% 30 degrees	10% 40 degrees	10% 0 degrees
Nasogastric tubing	94% yes	6% no	
Abdominal drains	79% yes	21% no	
Suture material	64% resorbable sutures	38% non-resorbable	
Knotting technique	64% intracorporeal	14% extracorporeal	14% mix

**Table 5. Overview of complications (17 studies n=1802)**

Scar problems	9.9 %
Mortality	5.8 %
Intra abdominal collection	5.7 %
Wound infection	4.9 %
Mods	4.7 %
Sepsis	4.6 %
Reoperation	4.5 %
Prolonged ileus	4.1 %
Suture leakage	3.8 %
Pneumonia	3.4 %
Respiratory complications	3.3 %
Ulcer recurrence	3.1 %
Intraabdominal abscess	2.7 %
Heart failure	2.3 %
Hemorrhage	2.0 %
Incisional hernia	1.8 %
Atrial fibrillation	1.7 %
Fistula	1.7 %
Pneumothorax	1.7 %
Urine retention	1.7 %
Urinary tract infection	1.6 %
Cerebral vascular accident	1.0 %
Wound dehiscence	0.8 %

*MODS multiple organ dysfunction syndrome*

**Table 6. Conversion reasons (21 studies, n=2346):**

Perforation size	9.4 %
Inadequate ulcer localization	6.6 %
Friable edges	6.4 %
Adhesions	5.9 %
Perforation galbladder	5.0 %
Cardiavascular instability	4.4 %
Suspected tumor	4.2 %
Severe peritonitis	4.2 %
Posterior localization	3.9 %
Definitive ulcer surgery	3.2 %
Technical difficulties	2.2 %
Pancreatic infiltration	1.0 %

**Table 7. Laparoscopic versus open repair:**

n=1874	Laparoscopic n=843	Open n=1031
Operating time (min.)	70.8	59.3
Nasogastric tube (days)	23	3.0
Intra venous fluids (days)	2.8	3.1
Abdominal drains (days)	2.2	3.8
Urinary catheter (days)	2.3	3.7
Normal diet (days)	3.5	5.7
Prolonged ileus (days)	2.7	3.6
Hospital stay (days)	6.3	10.3
Woundinfection (%)	0.0	5.0
Suture leakage (%)	6.3	2.6
Mobilization (days)	1.9	3.3
Normal daily activity (days)	12.7	16.6
Morbidity (%)	14.3	26.9
Mortality (%)	3.6	7.2
VAS day 1	3.8	6.4
VAS day 3	1.9	3.3

VAS visual analog scale

**Table 8. Conclusions of 40 studies with regards to laparoscopic repair PPU**

The procedure is safe	16x
Significant less pain	19x
Significant less mortality	1x
Significant lower morbidity	4x
Significant shorter operation time	2x
Significant shorter hospital stay	5x
Significant faster resuming normal diet	3x
Significant less wound infection	2x
No difference between laparoscopic repair or open	2x
Significant longer operating time	8x
Significant more suture leakage	3x
Significant more reoperations	1x

*VAS visual analog scale*

**Discussion**

In 2002, Lagoo et al. added the sixth decision for a surgeon to be made regarding PPU to the existing five therapeutic decisions proposed by Feliciano in 1992 [4]. The first decisions were about the need for surgical or conservative treatment, to use omentoplasty or not, the condition of the patient to undergo surgery, and which medication should be given. The sixth decision was: “Are we going to perform this procedure laparoscopically or open?” Is there really a sixth decision to be made, or are there enough proven benefits from laparoscopic correction that this should not be a question anymore? Reviewing literature showed that much research has been done, although not many prospective randomized trials have been performed (n=3). Still, data extracted from these papers are interesting.

Patient characteristics: Often it was mentioned that age of patients presenting with PPU is increasing, due to better medical antiulcer treatment and also because of more NSAID and aspirin usage in the elderly population [4,17,56]. The results in Table 2 show that the average age of patients with PPU was 48 years and that only 20% of these patients had used NSAIDs. One-third of patients had a history of peptic ulcer. Although

*Helicobacter pylori* is known to be present in about 80% of patients with PPU, this might indicate that there are more factors related to PPU for which the pathology is not yet clear [4]. Sixty-seven percent of perforations were located in the duodenum and only 17% were gastric ulcers (Table 2), according to findings in literature[58]. In 85% there was free air visible on X-ray (Table 2), which supports the diagnosis, but free air could be caused by other perforations as well and, although the diagnosis of PPU is not difficult to make, sometimes there is a good indication for diagnostic laparoscopic to exclude other pathology[2]. In 93-98%, definitive diagnosis could be made by performing diagnostic laparoscopy in the patient with an abdominal emergency, of which 86-100% could be treated laparoscopically during the same session.[1,2].

Surgical technique: There seems to be no consensus on how to perform the surgical procedure, which probably means that the perfect setup has not yet been found. Forty-four percent of surgeons preferred to stand between the patient's legs, while 33% performed the procedure at the patient's left side. Also, the number, position and size of trocars differed between surgeons. Placing and tying sutures was more demanding laparoscopically, and two techniques were used (Table 4). Theoretically there is a preference for intracorporeal knotting over extracorporeal suturing, because the latter is likely to cut through the friable edge of the perforation [12]. One of the disadvantages of laparoscopic correction of PPU often mentioned was the significant longer operating time, which causes more costs and may be nonpreferable in a hemodynamic unstable patient [5,16,18,35,42,43,45,46]. Ates et al. presented results with simple suture repair of PPU without using pedicled omentoplasty [11]. This significantly shortened operating time, but the questions remains of whether it is safe to abandon omentoplasty completely. Cellan-Jones emphasized the necessity for omentoplasty [59]. His advised technique, to prevent tearing out of sutures and prevent enlargement of the size of perforation by damaging the friable edges, is to place a plug of pedicled omentum into the "hole" and secure this with three tie-over sutures. His technique is often called the Graham patch, but Graham describes in his article the use of a free omental plug, a technique hardly any surgeon uses nowadays[60]. It might be less confusion to use the term pedicled omentoplasty. The usefulness of pedicled omentoplasty has been emphasized by others, and Schein even stated: "first suturing the hole and then sticking omentum over the repair is wrong, if you cannot patch it, then you must resect"[59,61]. Avoiding omentoplasty might shorten operating time but might be the reason for a higher incidence of

leakage at the repaired ulcer side [5,24]. Another reason for the longer operating time during the laparoscopic procedure might be the irrigation procedure. Peritoneal lavage is one of the key interventions in the management of PPU [4]. Lavage was performed with 2-6 L warm saline, but even up to 10 L has been described (table 3) [4]. By using a 5-mm or even 10-mm suction device, this part of surgery took even up to 58 min [30]. Whether generous irrigation is really necessary has not been proven yet.

Patient selection: Not all patients are suitable for laparoscopic repair, and it is important to preselect patients who are good candidates for laparoscopic surgery [5]. Boey's classification appears to be a helpful tool in decision making [4,56]. The Boey score is a count of risk factors, which are: shock on admission, American Society of Anesthesiologists (ASA) grade III-V, and duration of symptoms [52]. The maximum score is 3, which indicates high surgical risk. Laparoscopic repair is reported only to be safe with Boey score 0 and 1 [16,42]. Since the incidence of patients with Boey score 2 and 3 is low (according to table 2, only 2% of patients were admitted with Boey score 3, 7% were in shock at admission, and 11% had prolonged symptoms for more than 24 h) and Boey 2 and 3 is associated with high morbidity and mortality rate anyway, independent of type of surgery, it is difficult to find significant foundation for this statement. Other reported contra-indications are age > 70 years, and perforation larger than 10mm in diameter [16,17,32,33].

Reasons for conversion: Overall conversion rate was 12.4%, with a range from 0-28.5% (table 1). The most common reason for conversion was the size of perforation, but by using an omental patch this might not necessarily have to be a reason anymore to convert. From literature it was already known that other common reasons for conversion include failure to locate the perforation [17]. Shock at admission was associated with a significant higher conversion rate (50% versus 8%)[4]. Furthermore, time lapse between perforation and presentation negatively influenced conversion rate (33% versus 0%)[4].

Complications: The best parameters to compare two different surgical techniques are morbidity and mortality. PPU is still associated with high morbidity and mortality, with main problems caused by wound infection, sepsis, leakage at the repair site, and pulmonary problems (Table 4) [56]. Comparing results shows a remarkable difference in morbidity (14.3% in the laparoscopic group versus 26.9% in the open group) and mortality (3.6% versus 6.4%) (Table 6). Many trials measured the amount of postoperative opiate usage, but since this was scored in different ways (days used,

number of injection, amount of opiates in mg) these data were not comparable. However, overall, many studies showed significant reduction in pain, mortality, morbidity, wound infection, resuming normal diet and hospital stay (Table 6 and 7). Of course there are some negative results which can not be ignored (Table 7). Three papers reported a significant higher incidence of suture leakage, associated in one with a higher incidence of reoperations, but leakage mainly occurred in the sutureless repair group or in the group in which (pedicled) omentoplasty was not routinely used [18,24,32].

Overall there seems to be significant prove of the benefits of laparoscopic repair, but it is technical demanding surgery which needs a surgeon experienced with laparoscopy [4,17] CO<sub>2</sub> insufflation of the peritoneal cavity in the presence of peritonitis has been shown in rat models to cause an increase in bacterial translocation [4]. This led to the assumption that laparoscopic surgery might be dangerous in patients with prolonged peritonitis. Vaidya et al. performed laparoscopic repair in patients with symptoms of PPU for more than 24 h and concluded that is was safe even in patients with prolonged peritonitis, which has been confirmed by others [4,8,39,44].

Alternative techniques: closing the perforation site using suture repair is challenging, which is why alternative methods have been described [5,15,21,24,25,31]. Examples are represented by the sutureless repair of PPU, in which the perforation is closed by a gelatine sponge glued into the perforation or the perforation is closed by fibrin glue. Song et al. proposed the simple "one-stitch" repair with omental patch [9]. The automatic stapler has been used for perforation site closure, use of running suture was suggested to avoid intracorporeal or extracorporeal knotting, and combined laparoscopic-endoscopic repair has been described as well [21].

Definitive ulcer surgery: the need for definitive surgical management of peptic ulcer disease has markedly decreased, but 0-35% of patients admitted for PPU received definitive ulcer surgery [8,16,20,56]. Definitive ulcer surgery can be performed safely with laparoscopic techniques [4,12,36]. Palanivelu et al. performed definitive surgery in 10% of the cases admitted for PPU. All procedures (posterior truncal vagotomy and anterior highly selective vagotomy) were performed laparoscopically without conversion or mortality [12].

Research: a few aspects regarding laparoscopic repair of PPU are still unclear, and further research on these topics would be interesting. One of the remaining questions is whether there is less formation of intra-abdominal adhesions after laparoscopic

repair [4] . If this is the case, it would be another convincing reason to perform this procedure laparoscopically. Often mentioned as one of the major disadvantages of laparoscopic surgery are the high costs, caused by the need for more surgical staff and laparoscopic equipment. However no specified calculation of per- and postoperative costs have been made so far, and also the costs saved by possible earlier return to work have to be taken into account.

To conclude, the results of this review support the statement of the EAES already made in 2006 that, in case of suspected perforated peptic ulcer, laparoscopy should be advocated as diagnostic and therapeutic tool [14].

### References

1. Ates M, Coban S, Sevil S, Terzi A. The efficacy of laparoscopic surgery in patients with peritonitis. *Surgical laparoscopy, endoscopy & percutaneous techniques* 2008;18:453-456
2. Agresta F, Mazzarolo G, Ciardo LF, Bedin N. The laparoscopic approach in abdominal emergencies: has the attitude changed? : A single-center review of a 15-year experience. *Surg Endosc* 2008;22:1255-1262
3. Sanabria AE, Morales CH, Villegas MI. Laparoscopic repair for perforated peptic ulcer disease. *Cochrane Database Syst Rev* 2005:CD004778
4. Lagoo S, McMahon RL, Kakihara M, Pappas TN, Eubanks S. The sixth decision regarding perforated duodenal ulcer. *Jsls* 2002;6:359-368
5. Lau WY. Perforated peptic ulcer: open versus laparoscopic repair. *Asian J Surg* 2002;25:267-269
6. Druart ML, Van Hee R, Etienne J, et al. Laparoscopic repair of perforated duodenal ulcer. A prospective multicenter clinical trial. *Surg Endosc* 1997;11:1017-1020
7. Jackson N, Waters E. Criteria for the systematic review of health promotion and public health interventions. *Health promotion international* 2005;20:367-374
8. Vaidya BB, Garg CP, Shah JB. Laparoscopic Repair of Perforated Peptic Ulcer with Delayed Presentation. *J Laparoendosc Adv Surg Tech A* 2009
9. Song KY, Kim TH, Kim SN, Park CH. Laparoscopic repair of perforated duodenal ulcers: the simple "one-stitch" suture with omental patch technique. *Surg Endosc* 2008;22:1632-1635
10. Bhogal RH, Athwal R, Durkin D, Deakin M, Cheruvu CN. Comparison between open and laparoscopic repair of perforated peptic ulcer disease. *World journal of surgery*



- 2008;32:2371-2374
11. Ates M, Sevil S, Bakircioglu E, Colak C. Laparoscopic repair of peptic ulcer perforation without omental patch versus conventional open repair. *J Laparoendosc Adv Surg Tech A* 2007;17:615-619
  12. Palanivelu C, Jani K, Senthilnathan P. Laparoscopic management of duodenal ulcer perforation: is it advantageous? *Indian J Gastroenterol* 2007;26:64-66
  13. Wong BP, Chao NS, Leung MW, et al. Complications of peptic ulcer disease in children and adolescents: minimally invasive treatments offer feasible surgical options. *J Pediatr Surg* 2006;41:2073-2075
  14. Sauerland S, Agresta F, Bergamaschi R, et al. Laparoscopy for abdominal emergencies: evidence-based guidelines of the European Association for Endoscopic Surgery. *Surg Endosc* 2006;20:14-29
  15. Lam PW, Lam MC, Hui EK, Sun YW, Mok FP. Laparoscopic repair of perforated duodenal ulcers: the "three-stitch" Graham patch technique. *Surg Endosc* 2005;19:1627-1630
  16. Lunevicius R, Morkevicius M. Comparison of laparoscopic versus open repair for perforated duodenal ulcers. *Surg Endosc* 2005;19:1565-1571
  17. Lunevicius R, Morkevicius M. Management strategies, early results, benefits, and risk factors of laparoscopic repair of perforated peptic ulcer. *World journal of surgery* 2005;29:1299-1310
  18. Lunevicius R, Morkevicius M. Systematic review comparing laparoscopic and open repair for perforated peptic ulcer. *The British journal of surgery* 2005;92:1195-1207
  19. Lunevicius R, Morkevicius M. Risk factors influencing the early outcome results after laparoscopic repair of perforated duodenal ulcer and their predictive value. *Langenbecks Arch Surg* 2005;390:413-420
  20. Kirshtein B, Bayme M, Mayer T, et al. Laparoscopic treatment of gastroduodenal perforations: comparison with conventional surgery. *Surg Endosc* 2005;19:1487-1490
  21. Alvarado-Aparicio HA, Moreno-Portillo M. Multimedia article: management of duodenal ulcer perforation with combined laparoscopic and endoscopic methods. *Surg Endosc* 2004;18:1394
  22. Tsumura H, Ichikawa T, Hiyama E, Murakami Y. Laparoscopic and open approach in perforated peptic ulcer. *Hepatogastroenterology* 2004;51:1536-1539
  23. Malkov IS, Zaynutdinov AM, Veliyev NA, Tagirov MR, Merrell RC. Laparoscopic and endoscopic management of perforated duodenal ulcers. *Journal of the American College of Surgeons* 2004;198:352-355

24. Lau H. Laparoscopic repair of perforated peptic ulcer: a meta-analysis. *Surg Endosc* 2004;18:1013-1021
25. Siu WT, Chau CH, Law BK, et al. Routine use of laparoscopic repair for perforated peptic ulcer. *The British journal of surgery* 2004;91:481-484
26. Gentileschi P, Rossi P, Manzelli A, et al. Laparoscopic suture repair of a perforated gastric ulcer in a severely cirrhotic patient with portal hypertension: first case report. *Jsls* 2003;7:377-382
27. Seelig MH, Seelig SK, Behr C, Schonleben K. Comparison between open and laparoscopic technique in the management of perforated gastroduodenal ulcers. *J Clin Gastroenterol* 2003;37:226-229
28. Aali AYA, Bestoun HA. Laparoscopic repair of perforated duodenal ulcer. *The middle east journal of emergency medicine* 2002
29. Siu WT, Leong HT, Law BK, et al. Laparoscopic repair for perforated peptic ulcer: a randomized controlled trial. *Ann Surg* 2002;235:313-319
30. Arnaud JP, Tuech JJ, Bergamaschi R, Pessaux P, Regenet N. Laparoscopic suture closure of perforated duodenal peptic ulcer. *Surgical laparoscopy, endoscopy & percutaneous techniques* 2002;12:145-147
31. Wemyss-Holden S, White SA, Robertson G, Lloyd D. Color coding of sutures in laparoscopic perforated duodenal ulcer: a new concept. *Surgical laparoscopy, endoscopy & percutaneous techniques* 2002;12:177-179
32. Lee FY, Leung KL, Lai PB, Lau JW. Selection of patients for laparoscopic repair of perforated peptic ulcer. *The British journal of surgery* 2001;88:133-136
33. Lee FY, Leung KL, Lai BS, et al. Predicting mortality and morbidity of patients operated on for perforated peptic ulcers. *Arch Surg* 2001;136:90-94
34. Bohm B, Ablassmaier B, Muller JM. [Laparoscopic surgery of the upper gastrointestinal tract]. *Chirurg* 2001;72:349-361
35. Millat B, Fingerhut A, Borie F. Surgical treatment of complicated duodenal ulcers: controlled trials. *World journal of surgery* 2000;24:299-306
36. Dubois F. New surgical strategy for gastroduodenal ulcer: laparoscopic approach. *World journal of surgery* 2000;24:270-276
37. Freston JW. Management of peptic ulcers: emerging issues. *World journal of surgery* 2000;24:250-255
38. Agresta F, Michelet I, Coluci G, Bedin N. Emergency laparoscopy: a community hospital experience. *Surg Endosc* 2000;14:484-487

39. Robertson GS, Wemyss-Holden SA, Maddern GJ. Laparoscopic repair of perforated peptic ulcers. The role of laparoscopy in generalised peritonitis. *Ann R Coll Surg Engl* 2000;82:6-10
40. Khourshed M, Fuad M, Safar H, Dashti H, Behbehani A. Laparoscopic closure of perforated duodenal ulcer. *Surg Endosc* 2000;14:56-58
41. Kabashima A, Maehara Y, Hashizume M, et al. Laparoscopic repair of a perforated duodenal ulcer in two patients. *Surgery today* 1998;28:633-635
42. Katkhouda N, Mavor E, Mason RJ, et al. Laparoscopic repair of perforated duodenal ulcers: outcome and efficacy in 30 consecutive patients. *Arch Surg* 1999;134:845-848; discussion 849-850
43. Bergamaschi R, Marvik R, Johnsen G, et al. Open vs laparoscopic repair of perforated peptic ulcer. *Surg Endosc* 1999;13:679-682
44. Lau JY, Lo SY, Ng EK, et al. A randomized comparison of acute phase response and endotoxemia in patients with perforated peptic ulcers receiving laparoscopic or open patch repair. *American journal of surgery* 1998;175:325-327
45. So JB, Kum CK, Fernandes ML, Goh P. Comparison between laparoscopic and conventional omental patch repair for perforated duodenal ulcer. *Surg Endosc* 1996;10:1060-1063
46. Lau WY, Leung KL, Kwong KH, et al. A randomized study comparing laparoscopic versus open repair of perforated peptic ulcer using suture or sutureless technique. *Ann Surg* 1996;224:131-138
47. Memon MA. Laparoscopic omental patch repair for perforated peptic ulcer. *Ann Surg* 1995;222:761-762
48. Matsuda M, Nishiyama M, Hanai T, Saeki S, Watanabe T. Laparoscopic omental patch repair for perforated peptic ulcer. *Ann Surg* 1995;221:236-240
49. Lee KH, Chang HC, Lo CJ. Endoscope-assisted laparoscopic repair of perforated peptic ulcers. *Am Surg* 2004;70:352-356
50. Golash V, Willson PD. Early laparoscopy as a routine procedure in the management of acute abdominal pain: a review of 1,320 patients. *Surg Endosc* 2005;19:882-885
51. Rossi S. Laparoscopy in gastrointestinal emergency. *European Surgery* 2005;36:15-18
52. Boey J, Wong J. Perforated duodenal ulcers. *World journal of surgery* 1987;11:319-324
53. Urbano D, Rossi M, De Simone P, et al. Alternative laparoscopic management of perforated peptic ulcers. *Surg Endosc* 1994;8:1208-1211
54. Miserez M, Eypasch E, Spangenberger W, Lefering R, Troidl H. Laparoscopic and conventional closure of perforated peptic ulcer. A comparison. *Surg Endosc* 1996;10:831-836

55. Bloechle C, Emmermann A, Zornig C. Laparoscopic and conventional closure of perforated peptic ulcer. *Surg Endosc* 1997;11:1226-1227
56. Lohsiriwat V, Prapasrivorakul S, Lohsiriwat D. Perforated peptic ulcer: clinical presentation, surgical outcomes, and the accuracy of the Boey scoring system in predicting postoperative morbidity and mortality. *World journal of surgery* 2009;33:80-85
57. Bertleff MJ, Halm JA, Bemelman WA, et al. Randomized Clinical Trial of Laparoscopic Versus Open Repair of the Perforated Peptic Ulcer: The LAMA Trial. *World journal of surgery* 2009
58. Zittel TT, Jehle EC, Becker HD. Surgical management of peptic ulcer disease today-- indication, technique and outcome. *Langenbecks Arch Surg* 2000;385:84-96
59. Cellan-Jones CJ. A rapid method of treatment in perforated duodenal ulcer. *BMJ* 1929:1076-1077
60. Graham R, R. The treatment of perforated duodenal ulcers. *Surg gynecol Obstet* 1937:235-238
61. Schein M. Perforated peptic ulcer. In, *Schein's common sense emergency abdominal surgery: Springer Berlin Heidelberg; 2005:143-150*

**Randomized clinical trial of  
laparoscopic versus open repair  
of the Perforated Peptic Ulcer:  
the LAMA trial**

### Abstract

**Background** Laparoscopic surgery has become popular during the last decade, mainly because it is associated with fewer postoperative complications than the conventional open approach. It remains unclear, however, if this benefit is observed after laparoscopic correction of perforated peptic ulcer (PPU). The goal of the present study was to evaluate whether laparoscopic closure of a PPU is as safe as conventional open correction.

**Methods** The study was based on a randomized controlled trial in which nine medical centres from the Netherlands participated. A total of 109 patients with receive a PPU repair. After exclusion of 8 patients during the operation, outcomes were analyzed for laparotomy (n=49) and for the laparoscopic procedure (n=52).

**Results** Operating time in the laparoscopic group was significantly longer than in the open group (75 min versus 50 min). Differences regarding postoperative dosage of opiates and the visual analog scale (VAS) for pain scoring system were in favor of the laparoscopic procedure. The VAS score on postoperative day 1, 3 and 7 was significant lower ( $p < 0.05$ ) in the laparoscopic group. Complications were equally distributed. Hospital stay was also comparable: 6,5 days in the laparoscopic group versus 8,0 days in the open group ( $p = 0.235$ ).

**Conclusions** Laparoscopic repair of PPU is a safe procedure compared with open repair. The results considering postoperative pain are favor the laparoscopic procedure.

### Introduction

The incidence of perforated peptic ulcer (PPU) has declined over the past several years because of the introduction of anti-ulcer medication and Helicobacter eradication therapy (1,2). Nevertheless the incidence and mortality of PPU is 5-10%. The mortality will increase up to 50% if the perforation exists for more than 24 hours (3,4). There are several options for treatment of PPU, but the preferred treatment is surgery by upper abdominal laparotomy (5,6).

Mouret et al. published the first results of laparoscopic repair in 1990 (7). He concluded that it was a good method, that probably reduced postoperative wound problems and adhesions. After the success of laparoscopic cholecystectomy and other laparoscopic procedures, it was thought that patients would have less pain and a shorter hospital stay after laparoscopic correction of PPU (8,9). Various studies have

shown that laparoscopic suturing of the perforation is feasible, but there is still no proof of real benefits of laparoscopic correction (3,6,10,11,12). Therefore we performed a multicenter randomized trial comparing open correction of PPU with laparoscopic repair.

## Methods

**Participants:** Patients with symptoms of the clinical diagnosis of PPU were included in nine medical centers in the Netherlands participating in the LAMA (LAParoscopische MAagperforatie) trial between March 1999 and July 2005. Eligible patients were informed of the two surgical approaches and were invited to participate in the study. Exclusion criteria were the inability to read the Dutch language patient information booklet, inability to complete informed consent, prior upper abdominal surgery and current pregnancy. The ethics committees of all participating institutions approved the trial.

**Randomization:** Surgeons contacted the study coordinator after the patients had provided informed consent and randomization took place by opening a sealed envelope. The envelope randomization was based on a computer-generated list provided by the trial statistician.

**Surgical procedure:** All patients received intravenous antibiotics prior to the operation and were allocated for *Helicobacter pylori* eradication therapy according to established guidelines (13). The open surgical procedure was performed through an upper abdominal midline incision. Closure of PPU was to be achieved by sutures alone or in combination with an omental patch. After repair of the defect cultures were drawn from the peritoneal fluid, after which the peritoneal cavity was lavaged. During lavage it was permissible to insufflate the stomach to test for leakage of the closed defect. No method was specified for closing the abdomen.

Laparoscopic repair was performed with the patient and the team set up in the "French" position. Trocars were placed at the umbilicus (video scope) and on the left and right midclavicular line above the level of the umbilicus (instruments). If necessary a fourth trocar was placed in the subxiphoid space for lavage or retraction of the liver. Surgeons were free to use either 0° or 30° video scopes for the procedure. The rest of the procedure was identical to that described above for open repair. No method was specified for closing the trocar incisions.

Postoperative follow up: Postoperative pain was scored by means of a visual analogue scale (VAS) for pain on days 1,3,7 and 28 ranging from 0 (no pain) to 10 (severe pain). In addition, the days during which opiates were used by the patients were registered. All complications, minor and major, were monitored. The treating surgeons determined time of discharge on the basis of physical well-being, tolerance of a normal diet and ability to use the stairs. For this reason, this was an unblinded trial. Postoperative hospital stay without correction for time spent in hospital as a result of non-medical reasons (inadequate care at home) was calculated. Patients were invited to attend the outpatient clinic at 4 weeks, 6 months, and one year postoperatively. They were asked to complete forms related to pain and use of analgesics.

Statistical analysis: Data analysis was carried out according to the intention-to-treat principle as established in the trial protocol. Data were collected in a database, and statistical analyses were performed with the Statistical Package for Social Sciences for Windows (SPSS 15.0, SPSS Inc., Chicago, I., USA). A researcher blinded to the nature of the procedures performed all data analyses. The primary outcome of the trial was duration of hospital stay. The power analysis was performed on basis of a reduction in hospital stay by 1.5 days (10 - 8.5 days from admission) in favor of the laparoscopically treated group using a  $\beta$  of 0.80 and an  $\alpha$  of 0.05. This resulted in a trial size of 50 patients per group. Pearson Chi-squared test was used to compare categorical variables and the Mann-Whitney U test was used to compare continuous variables as we could not assume normal distribution because of the relatively small numbers. In Tables 1-6 medians and interquartile ranges (IQR) are reported. All data were analyzed according to the intention-to-treat principle; i.e., patients remained in their assigned group even if during the procedure the surgeon judged the patient not to be suitable for the technique assigned or if conversion was required. Null hypotheses were tested two-sided and a P value of 0.05 or less was considered statistical significant.

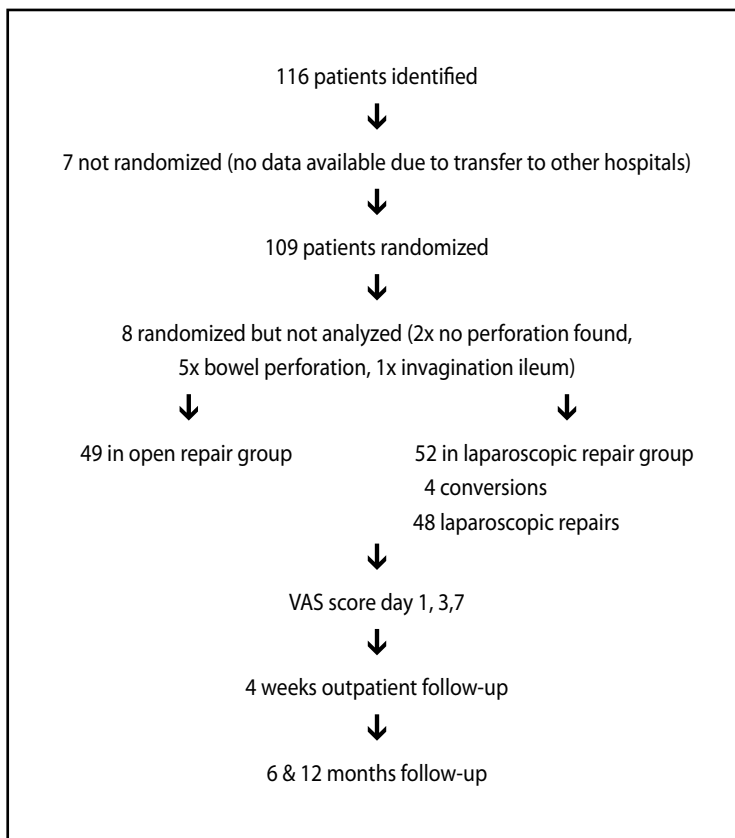
### Results

**Patients.** A total of 109 Patients were included in the trial based on a high suspicion of PPU (Figure 1). Eight patients were excluded during operation because no gastric perforation was detected or a defect in other parts of the digestive tract was uncovered. Data for these patients were not collected and the patients were excluded from further analysis. The remaining 101 patients made up the study population; their baseline parameters are given in Table 1. Fifty-two patients were randomized for



laparoscopic repair and 49 for open repair of the perforation. Forty patients were female. The mean age of the patients was 61 years. The BMI (body mass index) was equally distributed between the groups, with a median of 22.5. Patients in both groups had been suffering from symptoms for a mean duration of 11 hours, and those in the laparoscopic group presented with a median Mannheim Peritonitis index (14) of 19.5, whereas those in the open group had a median Mannheim Peritonitis index of 16. Thirty patients reported the use of non-steroidal anti-inflammatory drugs (NSAIDs; 17 laparoscopic versus 13 open), and 10 patients used proton pump inhibitors (6 laparoscopic versus 4 open). Patient history revealed gastric ulcer disease in 19 patients.

*Figure 1. Patient flow chart*



**Table 1. Baseline parameters**

	Laparoscopic repair n = 52	Open repair N = 49	p
Male: female ratio	1.3:1	1.9:1	
Median age (years) + IQR*	66 (25.8)	59 (29.5)	0.185
Median BMI (kg/m2)* + IQR	23 (4)	22 (5)	0.118
Median duration of symptoms (hours) + IQR	11 (17)	11 (19)	0.948
Median blood pressure systolic (mmHg) + IQR	125 (38.5)	130 (36.5)	0.457
Median blood pressure diastolic (mmHg) + IQR	75 (25.5)	75 (24.5)	0.596
Median heart rate (beats/min) + IQR	88 (34.0)	92 (21)	0.403
Median body temperature (°C) + IQR	36.9 (0.92)	36.8 (1.5)	0.658
Mannheim Peritonitis Index + IQR	19.5 (8.25)	16 (14)	0.386
Median white cell count (x109/L) + IQR	12.1 (8.9)	12.1 (7.75)	0.467
Median ASA score* + IQR	1.0 (1.0)	1.5 (1.0)	0.902

\* IQR = interquartile range, difference between 25th percentile and 75th percentile

\* BMI: body mass index

\* ASA: American Society of Anesthesiologists association score

**Intraoperative findings.** The discovered ulcer perforations were found to have a mean diameter of 10 mm, which did not differ between groups (Table 2). Location of the perforated ulcers was distributed equally between groups. Defects were located in the prepyloric region (n=41), the postpyloric region (n=34) and at the pylorus (n=20). The median volume of lavage fluid used was 1,000 ml (range 100 ml – 5,000 ml). The surgeon decided the amount of lavage used. There was no consensus on how much was necessary. Median blood loss did not differ between groups. Skin-to- skin time differed by 25 minutes, favoring open repair of PPU (table 2).

**Table 2. Intraoperative findings**

	Laparoscopic repair n = 52	Open repair N = 49	p
Median size of perforation (mm) + IQR	10.0 (7.0)	7.0 (6.0)	0.379
Number of patients with defect			
Pyloric	8	12	
Postpyloric	20	14	
Prepyloric	19	22	
Median volume of lavage (ml) + IQR	1000 (1500)	1000 (1425)	1.000
Median bloodloss (ml) + IQR	10.0 (40.0)	10.0 (50.0)	0.423
Skin to skin time (min) + IQR	75 (47.2)	50 (25.5)	0.000

**Intraoperative complications.** Conversion to open surgery was required in four patients (8%). Reasons for conversion included the inability to visualize the ulcer defect because of bleeding (n=1/52; 2%), inability to reach the defect because of perforation in the vicinity of the gastroduodenal ligament and because of a dorsal gastric ulcer (n=2/52, 4%) and inability to find the perforation (n=1/52, 2%).

**Postoperative complications.** Complications were statistically equally distributed between the two groups (Table 4). There were 12 complications in 9 patients in the laparoscopic group and 24 complications in 15 patients in the open group. Mortality was 4% in the laparoscopic group and 8% in the open group. In the laparoscopic group death was caused by sepsis due to leakage at the repair site. In the open group 3 patients died because of pulmonary problems (ARDS, pneumonia) and 1 patient died after complications following a cerebrovascular accident (CVA) combined with respiratory insufficiency.

**Table 3. Duration of hospital stay, nasogastric decompression**

	Laparoscopic repair n = 52	Open repair N = 49	p
Median hospital stay (days) + IQR	6.5 (9.3)	8.0 (7.3)	0.235
Median duration of nasogastric decompression (days) + IQR	2.0 (3.0)	3.0 (1.3)	0.334

**Discharge.** Time to discharge was similar for the two groups, with a median difference of 1,5 days (Table 3). Nasogastric decompression could be stopped after 2-3 days in both groups (Table 3).

*Table 4. Postoperative complications*

	Laparoscopic repair n = 52	Open repair N = 49	p
- pneumonia	2	1	
- respiratory insufficiency	1	3	
- ARDS		1	
- cardiac problems	2	2	
- sepsis	3	1	
- leakage at repair site	2		
- abscess		3	
- ileus		1	
- fascial dehiscence		1	
- wound infection		3	
- urinary tract infection		2	
- incisional hernia		1	
- CVA		1	
- death	2	4	
<b>Total complications</b>	<b>12</b>	<b>24</b>	
<b>Total of patients with complications ≥1</b>	<b>9 (18%)</b>	<b>15 (36%)</b>	<b>p= 0.061</b>

**Pain.** Visual analog pain scores were in favor of laparoscopic repair (Table 5;  $p < 0.005$ ). Although the median duration of opiate use in the two groups was 1.0, the mean duration in the open group was found to be 0.6 days longer than in the laparoscopic group (Table 6).

**VAS appearance of scar.** The VAS score for appearance of the scar left by the respective procedures (subjectively recorded in the same way as pain) differed by 2.3 points, favoring the laparoscopic procedure (7.7 vs. 5.4;  $P = 0.033$ )

**Table 5. Postoperative pain**

	Median VAS Pain score Laparoscopic repair	Median VAS Pain score Open repair	p
day 1+IQR	3.8 (3.0)	5.15 (2.5)	0.001
day 3+IQR	2.1 (2.5)	3.0 (2.4)	0.035
day 7+IQR	1.0 (2.0)	1.85 (2.8)	0.036
day 28+IQR	0.3 (0.7)	0.0 (1.7)	0.748

**Table 6. Postoperative opiate usage**

	Opiate requirement Laparoscopic repair	Opiate requirement Open repair	P value
Median duration (days) + IQR	1.0 (1.25)	1.0 (1.0)	0.007
Mean duration (days) $\pm$ SD	1.0 $\pm$ 0.9	1.6 $\pm$ 0.9	0.007

## Discussion

The need for surgery for PPU has declined enormously in Europe and America with reported rates ranging from 50 to 80%, thanks to effective gastric acid-reducing medication (15). For this reason, as well as because many surgeons prefer upper laparotomy, it took more time than expected to include 100 patients in our study. Reasons given by surgeons who prefer open repair were that it is a more familiar procedure and it can be completed faster than laparoscopy. It was also noted that patients often undergo operation at night, when the surgeon on call was not always laparoscopically trained.

Other randomized trials have already shown the feasibility of laparoscopic repair of PPU (3,4,6,10). Only a few had more than 100 patients, and some emphasized results from subgroups of patients (8,11,12). We did not subdivide our patients and included patients with risk factors for developing sepsis or conversion (10).

In eight of the original 109 patients (7%) it became evident during the operation that the patient had a diagnosis different from PPU. In the patients who were randomized for laparoscopy this discovery revealed the benefit of laparoscopy as a diagnostic procedure indicating either an upper or lower abdominoplasty or continuation of the laparoscopy (16). Conversion rate in the laparoscopy group was 8% (4/52). This is much lower than reported in literature, where conversion rates as high as 60% were found (3,4,6). This maybe partly explained by the fact that only trained and experienced laparoscopic surgeons (those performing at least 50 laparoscopic

procedures a year) participated in this trial, confirming the belief that this procedure should only be done by experienced surgeons (3,4,5). Operating time was significant longer in the laparoscopy group (75 min versus 50 min), which is comparable to reports in the literature (3,10). A possible explanation for the longer operative time is that laparoscopic suturing is more demanding (9,17), especially if the edges of the perforation are infiltrated and friable. Sutures easily tear out and it is more difficult to take large bites and to tie knots properly. Use of a single-stitch method described by Siu et al. (18), fibrin glue, or a patch might solve this problem (12,19). Another reason for the increase in operating time is the irrigation procedure. Irrigating through a 5-mm or even a 10-mm trocar is time consuming, and suction of fluid decreases the volume of gas and reduces the pneumoperitoneum. There is no evidence that irrigation lowers the risk of sepsis (20), so it might only be necessary if there are food remnants in the abdomen; perhaps there is no need for it at all (20). One of the suspected risks of laparoscopic surgery is that of inducing sepsis by increasing bacterial translocation while establishing a pneumoperitoneum (6). This danger could not be confirmed in our trial. Furthermore data suggest that there is a decrease in septic abdominal complications when laparoscopic surgery is used (8).

Evidence already exists that laparoscopic correction of PPU causes less postoperative pain (6,12,17,18). The meta-analysis published by Lau (6) showed that eight out of ten studies showed a significant reduction in dosage of analgesics required in the laparoscopic group. Also, the three studies that had included VAS pain scores showed consistently lower pain scores, as was observed in our study as well. Whether this will lead to a better quality of life for patients, especially during the first weeks after surgery still needs to be analyzed. Although patients in our series who underwent laparoscopy had less postoperative pain, there was no difference in the length of hospital stay in our two groups. In fact, hospital stay overall in our patients was very long. This was most likely caused by the fact that many patients, especially the elderly, could not be discharged because of organizational reasons. Of the 101 patients, 41% were 70 years or older (24 in the laparoscopic group versus 17 in the open group). It appears that the age of PPU patients is increasing, and this will eventually represent a significant problem in the future (2,3). One benefit of the laparoscopic procedure not often mentioned in literature (6) is cosmetic outcome. Nowadays patients are aware of this benefit, and sometimes this is the reason why they demand laparoscopic surgery.

In conclusion, the results of the LAMA trial confirm the results of other trials that laparoscopic correction of PPU is safe, feasible for the experienced laparoscopic surgeon and causes less postoperative pain. Operating time was longer in the laparoscopic group and there was no difference regarding hospital stay or postoperative complications.

## Acknowledgements

The LAMA trial received a research grant from the Gastrostart organisation, The Netherlands. Financial support was provided by Johnson & Johnson (Ethicon) Healthcare. Johnson & Johnson did not have any involvement in the design and conduct of the study, the data analysis or the interpretation of the results. The authors are grateful to Betty Hoogervorst and Hester Lingsma for their help with the statistics.

## References

1. Behrman SW (2005) Management of complicated peptic ulcer disease. *Arch Surg* 140:201-208
2. Svanes C (2000) Trends in perforated peptic ulcer: incidence. Etiology, treatment and prognosis. *World J Surg* 24:277-283
3. Lunevicius R, Morkevicius M (2005) Management strategies, early results, benefits and risk factors of laparoscopic repair of perforated peptic ulcer. *World J Surg* 29:1299-1310
4. Seelig MH, Seelig SK, Behr C, et al (2003) Comparison between open and laparoscopic technique in the management of perforated gastroduodenal ulcers. *J Clin Gastroenterol* 3:226-229
5. Lunevicius R, Morkevicius M (2005) Risk factors influencing the early outcome results after laparoscopic repair of perforated duodenal ulcer and their predictive value. *Langenbecks Arch Surg* 390:413-420
6. Lau H (2004) Laparoscopic repair of perforated peptic ulcer: a meta-analysis. *Surg Endosc* 18:1013-1021
7. Mouret P, Francois Y, Vignal J, et al (1990) Laparoscopic treatment of perforated peptic ulcer. *Br J Surg* 77:1006
8. Sanabria AE, Morales CH, Villegas MI (2005) Laparoscopic repair for perforated peptic ulcer disease. *Cochrane Database Syst Rev* (4) : CD004778
9. Köhler L (1999) Endoscopic surgery: What has passed the test?. *World J Surg* 23:816-824

10. Lunevicius R, Morkevicius M (2005) Comparison of laparoscopic vs open repair for perforated duodenal ulcers. *Surg Endosc* 19:1565-1571
11. Siu WT, Chau CH, Law BKB, et al (2004) Routine use of laparoscopic repair for perforated peptic ulcer. *Br J Surg* 91:481-484
12. Lau WY, Leung KL, Kwong KH, et al (1996) A randomized study comparing laparoscopic versus open repair of perforated peptic ulcer using suture or sutureless technique. *Ann Surg* 224:131-138
13. Nakajima S, Graham DY, Hattori T, et al (2000) Strategy for treatment of *Helicobacter* infections in adults. II. Practical policy in 2000. *Curr Pharm Des* 15:1515-1529
14. Linder MM, Wacha H, Feldmann U, et al (1987) Der Mannheimer peritonitis-index: ein instrument zur intraoperativen prognose der peritonitis. *Chirurg* 58:84-92
15. Sarosi GA, Jaiswal KR, Nwariaku FE, Asolati MA, et al (2005) Surgical therapy of peptic ulcers in the 21st century: more common than you think. *Am J Surg* 190:775-779
16. Sauerland S, Agresta F, Bergamaschi R, et al (2006) Laparoscopy for abdominal emergencies. *Surg Endosc* 20:14-29
17. Kirshtein B, Bayme M, Mayer T, et al (2005) Laparoscopic treatment of gastroduodenal perforations. *Surg Endosc* 19:1487-1490.
18. Siu WT, Leong HT, Bonita KB, et al (2002) Laparoscopic repair for perforated peptic ulcer. A randomized controlled trial. *Ann Surg* 235: 313-319
19. Bertleff MJOE, Liem RSB, Bartels HL, et al (2006) The Stamp method: a new treatment for perforated peptic ulcer? *Surg Endosc* 20:791-793
20. Schein M, Gecelter G, Freinkel W, et al (1990) Peritoneal lavage in abdominal sepsis. A controlled clinical study. *Arch Surg* 125:1132-1135



**Laparoscopic closure of Perforated  
Peptic Ulcer: first choice?  
Results of a European questionnaire.**

### Abstract

**Background** Despite the fact that several studies have been performed on the treatment of perforated peptic ulcer (PPU), there are still no guidelines for this problem. The aim of this study was to identify the current practice on the treatment of perforated peptic ulcer (PPU) amongst laparoscopic surgeons in Europe.

**Methods** Members of the European Association for Endoscopic Surgery (EAES) were surveyed on their opinion about PPU surgery practices. A 21-item questionnaire containing questions about the current incidence of PPU, diagnostic tools, treatment strategies and operative techniques was sent by e-mail to all members of the EAES.

**Results** A total of 2327 questionnaires were delivered with 596 returned. The average number of patients with clinical suspicion on PPU annually seen was 17 per year. Significant differences were found between the number of patients treated and the setting of practice of the respondents ( $p < 0.001$ ). 75% of the respondents reported a constant or increased number of operative procedures for PPU. 64% of the respondents perform CT-scan, when PPU is suspected, against 36% that never performs CT-scan. 81% percent of the respondents prefer to start laparoscopically and 71% percent of them also close the ulcer laparoscopically. The most preferred closure technique (70%) is to suture the perforation first and apply a pedicled omentoplasty on top of it. Only 14% of the respondents perform a "tyre-test" after the repair is established. The majority of the respondents (85%) do not perform definitive anti-ulcer surgery during the same procedure for closing PPU. The setting of practice and experience years of the surgeon does significantly influence the perception of the incidence of PPU and treatment strategies.

**Conclusions** Laparoscopic closure of PPU has become the procedure of first choice for laparoscopic surgeons in case of patients suspected for PPU. In practice definite anti-ulcer surgery seems obsolete.

### Introduction

Due to the established success of laparoscopic cholecystectomy in the 90s, a multicenter trial was started in 1999 comparing laparoscopic closure of perforated peptic ulcer (PPU) to closure by upper laparotomy.<sup>1</sup> Despite the fact it was a multicenter trial, it took six years to randomize 100 patients. One of the reasons for this was represented by the hesitation of some of the surgeons, especially during night-time, to perform this procedure laparoscopically. Longer operating time, the

more time consuming laparoscopic irrigation procedure, more technically demanding suturing, with risk of tearing out of the sutures whilst tying or even enlarging the perforation, were responsible for this unpopularity. Also in literature the benefits of laparoscopic surgery for PPU were not as evident as for laparoscopic cholecystectomy or appendectomy.<sup>2,3,4</sup> A questionnaire was designed to evaluate the current practice with regard to PPU amongst laparoscopic surgeons in Europe.

## Methods

In March 2010 a questionnaire was sent to all members of the European association of Endoscopic Surgery (EAES). After four weeks a reminder was sent. The questionnaire consisted of 21 questions. The first question was about the incidence of PPU in the hospital the surgeon worked, the second question was about the used diagnostic tool. Question 3 and 4 were about conservative treatment. Questions 5-11 were about surgical technique. Twelve and 13 were about postoperative policy. Information about definitive ulcer surgery was asked in 14 and 15 and the final 6 questions were on the surgeon profile.

## Results

**Response** The questionnaire has been sent to 2629 members of the EAES (European Association for Endoscopic Surgery). E-mail delivery failed in 302 cases due to unavailability of the mailboxes. Between March and May 2010, a total number of 596 surgeons responded to the questionnaire. Of these, 56 were incomplete and were excluded from further analysis. This resulted in 540 complete questionnaires that were included in this study.

**Respondents** In table 1 the baseline characteristics of the respondents are enumerated. The majority of the respondents are practising in a non-university teaching hospital (46%), 38% in an academic center and 16% in a private clinic. Of the respondents, 22% had more than 20 years of experience as a consultant, 35% between 10 and 20 years and 43% had less experience than 10 years. Most of the surgeons (66%) performed at least 100 laparoscopic procedures each year. 29% between 20 and 100 laparoscopic procedures and only 5% less than 20.

**Table 1. Baseline characteristics of respondents**

	n (%)
<b>Experience</b>	
<10 years	223 (42.5)
10 - 20 years	186 (35.4)
>20 years	116 (22.1)
<b>Laparoscopic procedures</b>	
<20 procedures	24 (4.6)
20 - 100 procedures	152 (29.0)
>100 procedures	348 (66.4)
<b>Setting of practice</b>	
Academic center	200 (38.1)
General teaching hospital	241 (45.9)
Private hospital	84 (16.0)

**Incidence** All respondents perform open or laparoscopic closure of PPU in their centers. A mean number of 17 patients with clinical suspicion on PPU were treated in the overall group of respondents per year. A significant difference was found between the number of patients treated in academic centers, teaching hospitals and private practices, 22, 17 and 10 respectively ( $p < 0.001$ ). 75% of the respondents reported a constant or even increased number of operative procedures for PPU against 25% that reported a decreased number of patients.

**Preoperative workup** When PPU is suspected, 63% of respondents perform CT-scan with (47%) or without (53%) oral contrast. 37% of respondents never perform CT-scan (Figure 1). Of the respondents, 52% report that they occasionally manage PPU conservatively (Figure 2). In this respect 14% reported that they had a protocol for conservative treatment for PPU, 86% had no guidelines. Some of the reported indications to start conservative treatment were high operative risk due to comorbidities, longer existing complaints and increased age.

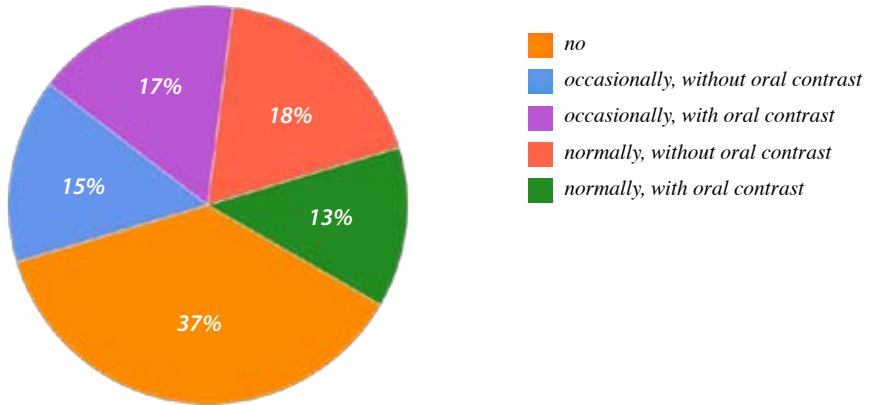


Figure 1. Is a CT scan, when a PPU is suspected, the imaging modality of standard use in your center?

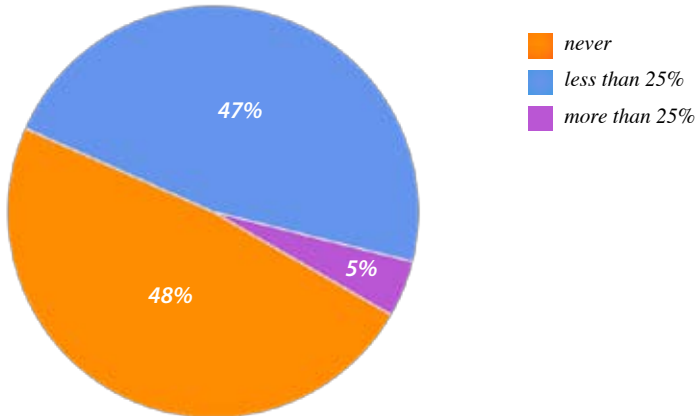


Figure 2. How often is a PPU treated conservatively in your center?

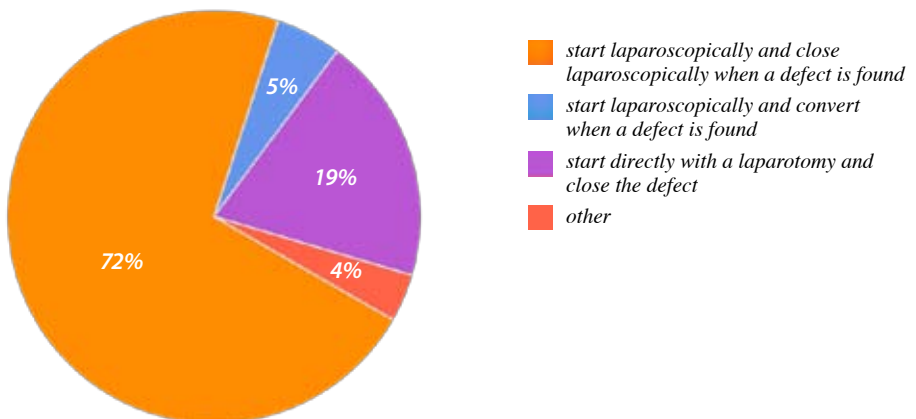


Figure 3. Open or laparoscopic procedure

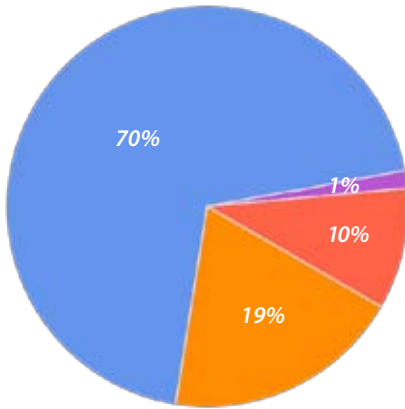


Figure 4. Closure technique

- I prefer to use the pedicled omentoplasty drawn into the perforation
- I prefer to suture the perforation first and after this apply a pedic
- I usually use a free omentum plug
- I approximate the perforation by sutures without using any omentoplasty

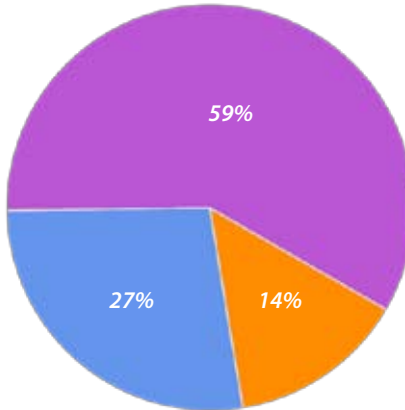


Figure 5. Tyre test

- yes
- sometimes
- never

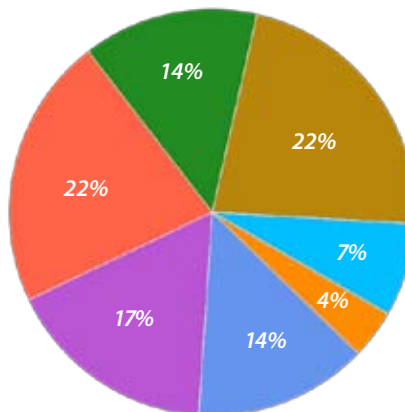
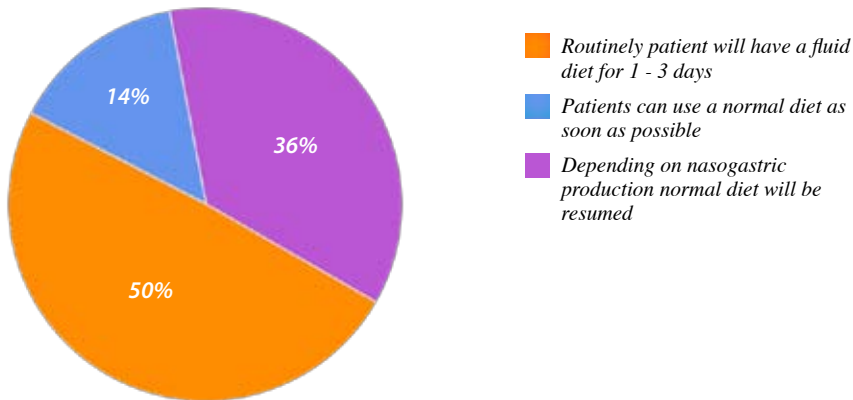


Figure 6. Irrigation fluid

- 0 - 500 ml
- 500 - 1000 ml
- 1000 - 1500 ml
- 1500 - 2000 ml
- 2000 - 2500 ml
- 2500 - 5000 ml
- > 5000 ml



**Figure 7. Postoperative oral intake**

**Operative procedure** Perioperative antibiotic prophylaxis was administered by 96% of responding surgeons. The antibiotics most frequently used were Augmentin (43%) and Kefzol (42%). 4% of respondents did not use prophylactic antibiotics at all. Most of surgeons (72%) prefer to start laparoscopically and close the defect laparoscopically once they have decided to treat PPU operatively. 19% of respondents prefer to start directly with a laparotomy and 9% start laparoscopically and convert when PPU is detected (Figure 3). The majority of surgeons (70%) prefer to suture the perforation first and apply a pedicled omentoplasty on top of it. 19% of surgeons prefer to use the pedicled omentoplasty, drawn into the defect, with sutures knotted on top of the omentoplasty. The defect is closed with sutures without omentoplasty by 10% of respondents and 1% uses a free omentum plug to close the defect. (Figure 4) After repair of the defect only 14% of the surgeons tests the repair site by using the “tire-test” (insufflating some air into the nasogastric tube and filling the abdomen with saline to test for bubbles) (Figure 5).

A biopsy of the PPU is taken by 19%, whilst 81% report that they never take a biopsy of the perforated area. The vast majority of the respondents do not perform definitive anti-ulcer surgery during the same procedure for closing PPU. About 85% of surgeons treat less than 5% of their patients with definitive anti-ulcer surgery. During surgery, 83% of respondents use between 1000-5000 ml of irrigation fluid to clean the abdomen and 71% reported that they routinely leave a (sentinel) drain (Figure 6).

**Postoperative management** Postoperatively, 50% of participants prefer to put their patients on a fluid diet for 1-3 days routinely. 15% of surgeons give their patients a normal diet as soon as possible, whilst 35% let it depend on nasogastric tube production (Figure 7). Routinely *Helicobacter pylori* eradication therapy is administered by 49% of respondents, 51% let it depend on the opinion of the internal medicine specialists.

**Setting of practice (Table 2)** The setting of surgical practice is significantly correlated to the protocol whether a CT-scan should be performed and if oral contrast is administered routinely. Compared to academic hospitals, significantly less patients get oral contrast fluid in private hospitals before they get a CT-scan (15% vs 28.6%,  $p=0.002$ ). Significantly less surgeons who practice in an academic hospital take biopsies of the perforated area for possible malignancy (17.5% vs 29.8%,  $p=0.03$ ). The perception of the academic surgeons also differs from the surgeon working in a private hospital about the incidence of PPU in time. Academic surgeons report a significantly higher increase in the incidence of PPU compared to surgeons working in private clinics (46.2% vs 28.6%,  $p=0.01$ ).

**Table 2. Setting of practice and treatment of PPU**

	Setting of Practice				p-value
	Academic	General	Private	Total (%)	
<b>Standard CT-scan</b>					
No-n(%)	76 (38)	88 (36.5)	28 (33.3)	36.6	
Occasionally, no OC-n(%)	34 (17)	25 (10.4)	19 (22.6)	14.9	
Occasionally, with OC-n(%)	28 (14)	48 (19.9)	10 (11.9)	16.4	
Normally, no OC-n(%)	30 (15)	47 (19.5)	24 (28.6)	19.2	0.002
Normally, with OC-n(%)	32 (16)	33 (13.7)	3 (3.6)	13.0	
<b>Biopsy</b>					
Yes-n(%)	35 (17.5)	42 (17.4)	25 (29.8)	19.4	0.03
No-n(%)	165 (82.5)	199 (82.6)	59 (70.2)	80.6	
<b>Increase incidence of PPU</b>					
Decreased-n(%)	46 (23.1)	56 (23.3)	27 (32.1)	24.7	
Constant-n(%)	61 (30.7)	102 (42.5)	33 (39.3)	37.5	
Increased-n(%)	92 (46.2)	82 (34.2)	24 (28.6)	37.9	0.01



**Experience of the surgeon (Table 3)** The more experienced surgeons are, the less they use oral contrast fluid for CT-scan (10.3% vs 16.6%,  $p=0.04$ ) and the less they decide to treat a suspected patient for PPU conservatively (37.2% vs 60.3%,  $p=0.001$ ). In contrast to academic surgeons, experienced surgeons in other hospitals report a significantly lower increase of the incidence of PPU compared to less experienced surgeons (31% vs 44.6%,  $p=0.04$ ).

**Table 3. Experience as consultant and PPU treatment**

	Experience as consultant				p-value
	<10 years	10-20 years	>20 years	Total (%)	
<b>Standard CT-scan</b>					
No-n(%)	78 (35)	73 (39.2)	41 (35.3)	36.6	
Occasionally, no OC-n(%)	32 (14.3)	27 (14.5)	19 (16.4)	14.9	
Occasionally, with OC-n(%)	46 (20.6)	26 (14.0)	14 (12.1)	16.4	
Normally, no OC-n(%)	30 (13.5)	41 (22.0)	30 (25.9)	19.2	
Normally, with OC-n(%)	37 (16.6)	19 (10.2)	12 (10.3)	13.0	0.04
<b>Conservative treatment</b>					
Never-n(%)	83 (37.2)	99 (53.2)	70 (60.3)	48.0	0.001
Less than 25%-n(%)	129 (57.8)	80 (43.0)	41 (35.3)	47.6	
More than 25%-n(%)	11 (4.9)	7 (3.8)	5 (4.3)	4.4	
<b>Increase incidence of PPU</b>					
Decreased-n(%)	44 (19.8)	55 (29.7)	30 (25.9)	24.7	
Constant-n(%)	79 (35.6)	67 (36.2)	50 (43.1)	37.5	
Increased-n(%)	99 (44.6)	63 (34.1)	36 (31)	37.9	0.04

### Discussion

In literature, laparoscopic correction of PPU does not seem to be as popular as other laparoscopic procedures because of longer operating time, higher costs, the unclear effect of pneumoperitoneum on peritonitis and hemodynamics, especially in a septic patient.<sup>5-8</sup> It is also often mentioned that the incidence and the need for surgery for PPU has declined, both suggesting that laparoscopic correction of PPU is seldomly performed.<sup>9,10</sup> The outcome of this questionnaire gives, with a response rate of 26%, a good impression about the situation in Europe at this moment. The surgeons are equally divided between academic hospitals and other hospitals and 57 % of surgeons has been working for more than 10 years. Annually they see a mean of 17 (range 0-100) patients a year suspected for PPU. The overall impression, in contrast to literature, is that during the last five years the incidence of PPU has been constant or even increased.<sup>9,10</sup> Almost 70% of the responding surgeons perform more than a 100 laparoscopic procedures a year, and since all of them are members of the EAES, this group is not representative for all gastrointestinal surgeons. Despite this, more than half of responding surgeons do not think it to be necessary for PPU to be operated by surgeons specialized in gastrointestinal surgery.

To confirm the diagnosis of PPU, only in 31.3%, a CT scan is used as a routine. On whether this should be with or without the use of oral contrast, opinions are equally divided. Almost 40% does not see any need for using CT scan at all. The majority of surgeons (71.7%) will start with laparoscopic inspection if there is clinical suspicion of PPU and an X-ray with subdiaphragmatic free air. Especially high-volume laparoscopic surgeons choose more frequently for primarily laparoscopic approach. Still though, one out of five laparoscopic surgeons start with an upper laparotomy.

In literature some information can be found on safety of conservative treatment, especially about which patients would be good candidates for it.<sup>11, 12</sup> In this respect, more than half of surgeons (51.7%) does treat patients conservatively once in a while. Apparently conservative treatment still has its indications, but a guideline about patient selection or method of conservative treatment is lacking. Surgeons with more than 20 experience years chose significantly less for primarily conservative treatment. This could possibly be related to negative experiences during their longer career.

In 1937 Graham described the use of a free omental patch for closing PPU. Although in textbooks the Graham patch is often advised as preferred technique for closing PPU, hardly anyone uses this technique nowadays (1.4%). Also the Cellan-Jones patch

(suturing omentum on top of PPU without closing) is hardly ever used. Surgeons apparently prefer to close PPU first and suture a pedicled plug of omentum on top of it (omentoplasty). The overwhelming popularity of the latter technique implies a risk that the Cellon-Jones technique without the possibility of tearing out sutures at the edge of PPU might be forgotten as a safe alternative especially in case of large PPU.<sup>13</sup> Hard evidence for the necessity of irrigating the abdomen is lacking.<sup>14</sup> More than 80% of surgeons prefer to irrigate the abdomen with at least 1L.

There seems to be consensus about the avoidance of taking a biopsy in case of PPU, because the risk of gastric cancer is low.<sup>15, 16</sup> Also the usefulness of prophylactic administration of antibiotics is largely accepted. No consensus on the specific type of antibiotics however exists.<sup>17</sup>

The tire test and the dye test (dye via nasogastric tube) to exclude persistent leakage after closure of PPU are seldomly used. Only 14.1% of surgeons use one of the above-mentioned methods as a standard routine. Both tests are easy to perform, do not take much time and might lower the risk of recurrent leakage.

The results of a questionnaire performed by Schein showed that 80% of the questioned surgeons did not leave a drain after surgery for acute abdomen. Reasons for this are that a drain will not reduce the risk for intraabdominal fluid or abscess formation, and that an intraabdominal drain is associated with higher morbidity because of infection or bowel obstruction. The results from our questionnaire however shows the opposite, still 71.4% of surgeons prefer to place an intraabdominal drain.<sup>18</sup>

Only 14.6% of patients is given a normal diet postoperatively as soon as possible. Nasogastric production still is a leading factor in decision making when to restart normal diet. Helicobacter eradication therapy is routinely given by 48.9% of surgeons. The other half of surgeons will consult an internal medicine specialist first. According to the guidelines, it is recommended that PPU patients positive for *Helicobacter pylori* should be treated with antimicrobial agents, which implicates that testing for *Helicobacter* pre- or postoperatively is necessary.<sup>19,20</sup>

The need for performing definitive anti-ulcer surgery, during the same procedure for closing PPU, is estimated low by the interrogated surgeons.

For conclusion laparoscopic closure of PPU has become the procedure of first choice for laparoscopic surgeons in Europe for PPU, In contrast to literature the incidence of operations for PPU seems not to have been further declined during the last years.

### **Acknowledgement**

We would like to thank Ria Palmen of the EAES office for distributing the questionnaire.

**References:**

1. Bertleff MJ, Halm JA, Bemelman WA, van der Ham AC, van der Harst E, Oei HI, Smulders JF, Steyerberg EW, Lange JF (2009) Randomized clinical trial of laparoscopic versus open repair of perforated peptic ulcer: the LAMA trial. *World J Surg* 33(7):1368-73
2. Sanabria AE, Morales CH, Villegas MI (2005) Laparoscopic repair for perforated peptic ulcer disease. *Cochrane Database Syst Rev* CD004778
3. Ates M, Coban S, Sevil S, Terzi A (2008) The efficacy of laparoscopic surgery in patients with peritonitis. *Surg Laparosc Endosc Percutan Tech* 18:453-456
4. Bertleff MJ, Lange JF (2010) Laparoscopic correction of perforated peptic ulcer: first choice? A review of literature. *Surg Endosc* 24(6):1231-9
5. Lau WY (2002) Perforated peptic ulcer: open versus laparoscopic repair. *Asian J Surg* 25:267-269
6. Lunevicius R, Morkevicius M (2005) Systematic review comparing laparoscopic and open repair for perforated peptic ulcer. *Br J Surg* 92:1195-1207
7. Bergamaschi R, Marvik R, Johnsen G, Thoresen JE, Ystgaard B, Myrvold HE (1999) Open vs laparoscopic repair of perforated peptic ulcer. *Surg Endosc* 13:679-682
8. Lau WY, Leung KL, Kwong KH, Davey JC, Robertson C, Dawson JJ, Chung SC, Li AK (1996) A randomized study comparing laparoscopic versus open repair of perforated peptic ulcer using suture or sutureless technique. *Ann Surg* 224:131-138
9. Bardhan KD, Royston C (2008) Time, change and peptic ulcer disease in Rotherham, UK. *Dig Liver Dis* 40(7):540-6
10. Smith BR, Stabile BE (2005) Emerging trends in peptic ulcer disease and damage control surgery in the *H. pylori* era. *Am Surg* 71(9):797-801
11. Crofts TJ, Park KG, Steele RJ, Chung SS, Li AK (1989) A randomized trial of nonoperative treatment for perforated peptic ulcer. *N Engl J Med* 332(15):970-3
12. [No authors listed] (1989) Conservative management of perforated peptic ulcer. *Lancet* 16;2(8677):1429-30
13. Schein M (2005) Perforated peptic ulcer. In: Schein's common sense emergency abdominal surgery: Springer, Berlin Heidelberg, pp 143-150
14. Lagoo S, McMahon RL, Kakihara M, Pappas TN, Eubanks S (2002) The sixth decision regarding perforated duodenal ulcer. *JSLA* 6(4):359-68
15. Ergul E, Gozetlik EO (2009) Emergency spontaneous gastric perforations: ulcer versus cancer. *Langenbecks Arch Surg* 394(4):643-6
16. Hansson LE, Nyrén O, Hsing AW, Bergström R, Josefsson S, Chow WH, Fraumeni JF Jr, Adami

- HO (1996) The risk of stomach cancer in patients with gastric or duodenal ulcer disease. N Engl J Med 25;335(4):242-9*
17. *Bowater RJ, Stirling SA, Lilford RJ (2009) Is antibiotic prophylaxis in surgery a generally effective intervention? Testing a generic hypothesis over a set of meta-analyses. Ann Surg 249(4):551-6*
  18. *Schein M (2008) To drain or not to drain? The role of drainage in the contaminated and infected abdomen: an international and personal perspective. World J Surg 32(2):312-21*
  19. *Sivri B (2004) Trends in peptic ulcer pharmacotherapy. Fundam Clin Pharmacol 18(1):23-31*
  20. *Fischbach LA, Goodman KJ, Feldman M, Aragaki C (2002) Sources of variation of Helicobacter pylori treatment success in adults worldwide: a meta-analysis. Int J Epidemiol 31(1):128-39*

**The “stamp method”:  
a new treatment for Perforated  
Peptic Ulcer?**

### Abstract

**Background** The aim of this study was to develop a simple method for closure of a perforated peptic ulcer, making it more accessible for laparoscopic surgery.

**Methods** An experimental pilot study was performed using five male Wistar rats. The perforation was closed by a bioabsorbable patch made of lactide–glycolid–caprolactone fixed with glue onto the outside of the stomach.

**Results** Postoperatively, there were no signs of leakage or other complications. Histologically, there were no signs of inflammation on the inside of the stomach, and there was a 50% reduction of the perforation each successive postoperative week. No adverse reactions because of the degradable material or glue were observed.

**Conclusions** Treatment of a perforated peptic ulcer by placing a patch of biodegradable material like a “stamp” on the outside of the stomach is a feasible option.

### Introduction

Laparoscopic correction still is not the gold standard for management of a perforated peptic ulcer<sup>1</sup> although many advantages of laparoscopic procedures have been demonstrated during the recent years with regard to postoperative morbidity and pain<sup>2,4</sup>. During a multicenter Dutch trial (LAMA trial), we compared laparoscopic closure of perforated peptic ulcer with the conventional method using laparotomy. It seemed that one of the problems with the laparoscopic procedure involves the suturing technique<sup>5</sup>. It is especially difficult for surgeons to take big bites, to prevent cutting out of the sutures<sup>4</sup>, and to exert sufficient tension on the knot during intra- or extracorporal knotting. The operation time for laparoscopic correction often is prolonged<sup>5,6</sup>, which is mainly due to the learning curve with regard to suturing technique. This may be the reason why many surgeons (especially during the night) are not even starting up laparoscopically or soon convert to laparotomy. A new method has been developed in which perforation of the stomach in rats was closed with a biodegradable patch fixed with glue, similar to putting a “stamp” on the outside of the stomach. In the current experiment, this “stamp” method was evaluated.



## Methods

Five adult male Wistar rats with an average weight of 255 grams were used in this trial. With the rats under general anesthesia (isofluranas 2% with oxygen), a median laparotomy was performed. At a fixed point on the ventral side of the stomach, a perforation was created with a diameter of 0.5 cm. A patch, made of lactide–glycolid–caprolactone (LGC) (Polyganics, B.V., Groningen, The Netherlands) was cut into a circle with a diameter of 1 cm and an overlap of 0.5 cm all around the perforation. The patch was glued on the outside of the stomach with Glubran 2 (n-butyl [2] cyanoacrylate, methacryloxysulfolane). The abdomen was closed in two layers with Polysorb 4-0. After 1 week, the first rat underwent relaparotomy under general anesthesia. After inspection of the abdomen, the patch, including the full thickness of the stomach wall, was resected and sent for histology. Each successive postoperative week, one rat underwent the same procedure, resulting in a total clinical and histologic follow-up period of 5 weeks. For histology, tissue specimens were rinsed in saline and placed into a fixative containing 2% glutardialdehyde buffered with 0.1 mol/ phosphate buffer, pH 7.4. Then, the specimens were dehydrated through a graded concentration of ethanol and embedded in glycol methacrylate. From all samples, 2- $\mu$ m-thick sections were prepared using a disposable histoknife and a Reichert–Jung “2050 supercut” microtome. The sections were mounted on glass slides and stained with toluidine blue and alkaline fuchsin (Merck, Darmstadt, Germany). All the sections were evaluated and photomicrographed using a Olympus BX-50 microscope (Olympus Optical Co., Japan)

## Results

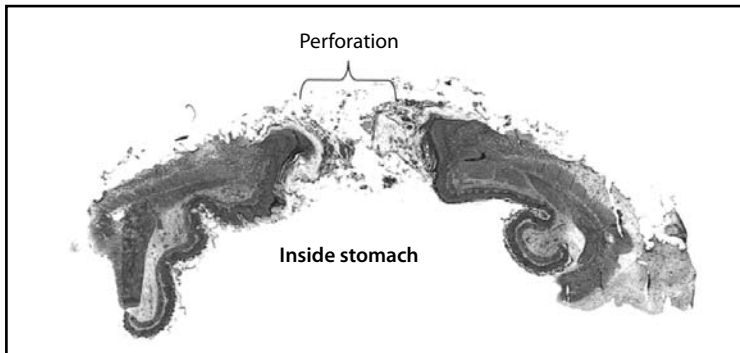
All the rats survived the first operation without complications. The mean operating time was 10 min. At relaparotomy, there were neither signs of leakage nor evidence of peritonitis. There were small adhesions, mainly to the liver, and in the first two rats there also were small adhesions between the spleen and the stomach. From week 1, the patch was covered by omentum. Biodegradation of the patch was visible at week 5. The diameter of the perforation, as observed from the inside of the stomach, decreased by 50% every week. After 5 weeks, only a pinpoint perforation could be found. All the rats gained weight during their weeks of follow-up evaluation, with an average weight of 348 g (range, 313–392 g), on the day of re-operation meaning they were in good condition.

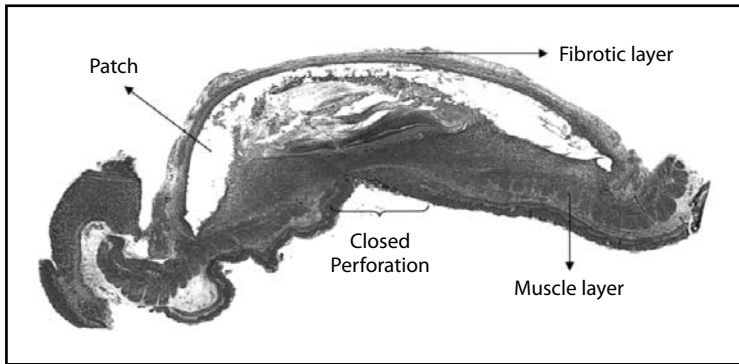
### Histology

At 1 week postoperatively, no inflammatory cells were detected on the inside of the stomach. Bacteria were found in the superficial mucous layer of the epithelium, and among the microvilli of epithelial cells. They were distributed irregularly, patchy and with heavy colonization, in some areas but did not invade the epithelium. The mucosa consisted of dense connective tissue and numerous blood vessels. The basement membrane underlying the epithelial basal cells was clearly visible. The muscular layer and submucosal glands were present, but did not continue, as was to be expected. At 2 weeks postoperatively, cellular ingrowth of inflammatory cells, especially granulocytes, was seen lying against the LGC patches. Multinucleated giant cells also were seen at the interface of the patches. At 3 weeks postoperatively, the LGC patches were covered by a capsule of fibrotic tissue. This capsule consisted of 14 to 15 layers of fibroblasts, collagen fibers, extracellular matrix, and numerous blood vessels. Still, some multinucleated giant cells were observed in the patches, and degradation of the LGC patches had begun. At 4 weeks postoperatively, the amount of inflammatory infiltrate had increased, while other cells such as macrophages and multinucleated giant cells were seen infiltrating the LGC-patches. The capsule of fibrotic layer became thicker. Fibroblasts as well as collagen fibers and blood vessels were found more frequently and denser, as compared with findings 3weeks postoperatively. At 5 weeks postoperatively, the fibrotic layer on the patch had increased Macrophages and giant cells still were found infiltrating and phagocytosing the LGC patches. There were epithelial cells close to the perforation. The muscular layer still showed perforation. There were no signs of rejection (Figs. 1 and 2).

74

*Fig. 1. Histology at week 1*



*Fig. 2. Histology at week 5*

## Discussion

A new method for closure of peptic ulcer perforation was tested in rats, and the first results seem promising. Sealing of the perforation with a glued biodegradable patch seemed sufficient because no leakage occurred. Furthermore, no inflammation or other side effects to the abdominal wall were observed. It was decided that at this phase, the use of an iatrogenically made perforation would be sufficient, because we wanted only to evaluate whether this new technique would work. Of course, this test did not completely mimic the clinical situation. There was no edema, no fibrin deposition, and no inflammation of surrounding tissue. However, no clinical evidence so far had proved that a perforation of any longer duration with fibrin deposition has a worse outcome with regard to healing of the perforation itself and a higher risk for reperforation. It could even be suggested that fibrin deposition helps in sealing the perforation, but more research on this topic is needed. Closure of a perforated peptic ulcer by a Graham omental patch or mere sutures has been performed for many years<sup>3,7</sup>. Several alternative techniques have been tried<sup>4,7</sup>. The incentive for introducing these new operations was to simplify the procedure and make it suitable for minimal invasive therapy<sup>4</sup>. A few procedures can be accomplished by endoscopy, but often it still is necessary to combine it with laparotomy or laparoscopy<sup>6,8</sup>. Lau et al. described a method for closing the perforation using spongostan fixed with fibrin glue<sup>9</sup>. This seemed to be suitable only for smaller perforations. The patch used in this study can be introduced through a trocar and unfolded with ease because it has no memory. Glubran 2, the glue used in this trial, is a synthetic surgical glue European Conformity (CE) certified for internal use. It is liquid, does not need any preparation and can be

applied to the patch inside the abdomen using a laparoscopic needle. The size of the perforation does not matter because the patches can be cut easily into any desired size.

In conclusion we propose a simple technique for closure of a perforated peptic ulcer, making laparoscopic correction of a perforated peptic ulcer more accessible. A randomized clinical trial will be initiated in due course.

### Acknowledgement

The authors thank Polyganics, BV (Groningen, The Netherlands) for providing the patches and (Global Entrepreneurship Monitor) GEM (Italy) for providing the glue and Mr. G. Kors for the technical assistance.

### References

1. *Lagoo SA, Pappas TN. Laparoscopic repair for perforated peptic ulcer. Ann Surg 2002; 235(3):320-1.*
2. *Agresta F, Michelet I, Coluci G, Bedin N. Emergency laparoscopy: a community hospital experience. Surg Endosc 2000; 14(5):484-7.*
3. *So JB, Kum CK, Fernandes ML, Goh P. Comparison between laparoscopic and conventional omental patch repair for perforated duodenal ulcer. Surg Endosc 1996; 10(11):1060-3.*
4. *Wemyss-Holden S, White SA, Robertson G, Lloyd D. Color coding of sutures in laparoscopic perforated duodenal ulcer: a new concept. Surg Laparosc Endosc Percutan Tech 2002; 12(3):177-9.*
5. *Bertleff MJOE, W. B, Oei I, et al. Laparoscopic correction versus open surgery of perforated peptic ulcer: first results of the LAMA trial. Surg Endosc 2002; 16:53.*
6. *Pescatore P, Halkic N, Calmes JM, et al. Combined laparoscopic-endoscopic method using an omental plug for therapy of gastroduodenal ulcer perforation. Gastrointest Endosc 1998; 48(4):411-4.*
7. *Siu WT, Leong HT, Law BK, et al. Laparoscopic repair for perforated peptic ulcer: a randomized controlled trial. Ann Surg 2002; 235(3):313-9.*
8. *Hashiba K, Carvalho AM, Diniz G, Jr., et al. Experimental endoscopic repair of gastric perforations with an omental patch and clips. Gastrointest Endosc 2001; 54(4):500-4.*
9. *Lau WY, Leung KL, Kwong KH, et al. A randomized study comparing laparoscopic versus open repair of perforated peptic ulcer using suture or sutureless technique. Ann Surg 1996; 224(2):131-8.*

**Comparison of closure  
of gastric Perforation  
Ulcers with biodegradable  
lactide-glycolid-caprolactone  
or omental patches**

### Abstract

**Background** The current treatment of perforated peptic ulcer is primary closure, supported by the application of an omental patch. It is difficult and time-consuming to perform this procedure by laparoscopic surgery, largely because of the required suturing. It was our aim to develop and test a new method of closure for gastric perforation that is similar in efficacy and safety to a traditional repair. This technique could have utility in laparoscopic repair, as it does not require sutures or mobilization of the omentum.

**Method** The new method, called “stamp” method consists of closure of the perforation by gluing a biodegradable patch made of lactide-glycolide-caprolacton (LGC, Polyganics, B.V. Groningen, The Netherlands) on the outside of the stomach. It was compared with the omental patch procedure. Perforations were made in the stomach of 20 rats and closed by either method (10 rats in each group). The rats were followed for 10 weeks.

**Results** No complications were seen in any of the rats. In both groups, histological degradation of the patch by giant cells started at week 2. There were no signs of inflammation in either group. Signs of closure of the mucosa were seen after 2 weeks, and the muscular layer started to regenerate after 8 weeks in both groups.

**Conclusion** Results of both methods were similar, which means that treatment of a gastric perforation through the application a biodegradable patch to the outside of the stomach is a feasible option and might be even be an interesting technique for closure of other perforations in the digestive tract.

### Introduction

The current treatment of perforated peptic ulcer is primary closure, covered by omentoplasty. The classical Graham patch technique, described by Cellan-Jones in 1929 and in 1937 by Graham can be applied<sup>1-3</sup>. The idea in closing the perforation not only by sutures but also with an omental plug is the sealing and tamponade effect of the plug. Adding an omental plug also reduces the risk of tearing out sutures, accelerates ulcer healing, and inhibits ulcer recurrence<sup>4,5</sup>. Laparoscopic surgery has gained in popularity, because there seems to be a decrease of postoperative complications, pain, and length of hospital stay<sup>6-9</sup>. Despite this, laparoscopic correction of a perforated peptic ulcer (PPU) still is not the first treatment of choice for many surgeons. One of the disadvantages of laparoscopic closure of perforated peptic ulcer

is that it takes more operating time and requires more operating skills, which makes the procedure more costly and less popular<sup>9,10</sup>. The prolonged operating time might be caused by the laparoscopic suturing procedure<sup>6,10</sup>. There is a learning curve for laparoscopic intracorporeal or extracorporeal suture techniques, and because of the fragile edges of the peptic ulcer walls, sutures tear out easily<sup>10</sup>. An alternative technique for closing the perforation, avoiding the necessity to use stitches, might facilitate the laparoscopic procedure. An alternative to omentoplasty and stitching could be the use of a glued patch of biodegradable material on the outside of the stomach. Besides reducing operating time, another advantage of using a glued patch instead of suturing is that touching of the friable edges is avoided, which lowers the risk of enlarging the perforation. Also the patch method might be the solution for closing larger peptic ulcers. Performing an omentoplasty in these patients is difficult, and alternative techniques have been tried<sup>7, 11-13</sup>. Previously the “stamp method,” closing a gastric perforation with a biodegradable stamp, was tested in a pilot study in 5 rats, showing that it was a safe procedure<sup>14</sup>. In this pilot study there was no control group and the follow up period was only 5 weeks. Therefore, a new rat study has been performed in which we compare closing an iatrogenic perforation in rats’ stomachs by Graham omentoplasty with the application of a glued biodegradable (lactide-glycolide-caprolacton) patch to the outside of the stomach. The aim of this study was to test the stamp method, which has to be a technique of a similar safety profile as primary closure and omentopexy but could allow the laparoscopic procedure to be done more easily so operating time can be reduced.

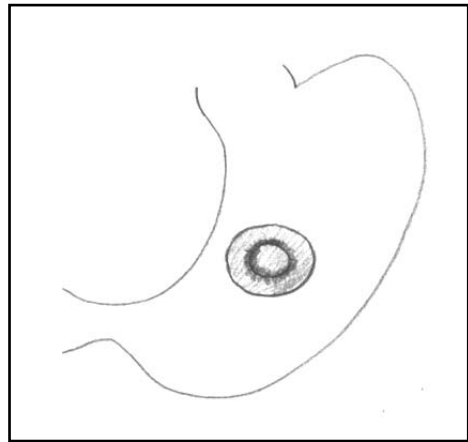
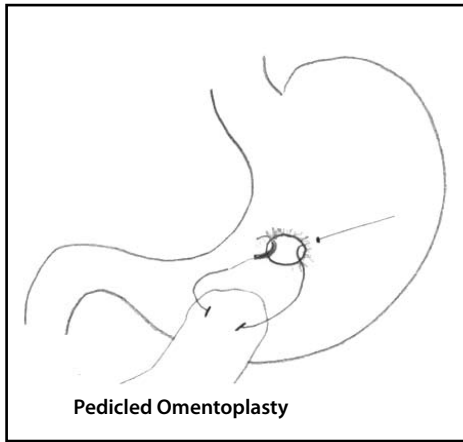
## Methods

Twenty male Wistar rats, 12 weeks to 13 weeks old (Harlan, The Netherlands) were used in this trial, which was approved by the animal ethical committee of the University Medical Center Groningen. Ten rats were in the omentum group, and 10 in the stamp group. All procedures were performed with the rats under general anaesthesia by using isoflurane gas at 2% with oxygen. In both groups, an upper laparotomy was performed, and a perforation was created on a fixed point on the ventral side of the stomach. Because this was located underneath the liver lobe, careful retraction of the liver lobe was necessary. The perforation was made by cutting a small hole, with a diameter of 0.5 cm in the gastric wall. In the omentum group, the perforation was closed by using a Graham patch. For this, the omentum nearby the

perforation side was mobilized and fixed, pedicled, into the perforation with mattress stitches. A 6-0 Vicryl suture was used (Figure 1). In the stamp group, a circular shaped patch made of lactide-glycolide-caprolacton (LGC, Polyganics, B.V. Groningen, The Netherlands) with a diameter of 1 cm was glued on top of the perforation (Figure 2), ensuring an overlap of 0.25 cm around the perforation.

**Figure 1: Drawing of Graham omentoplasty.** A suture runs through the gastric wall first; than takes a bit bite of pedicled omentum en runs back to the other site of the perforation.

**Figure 2: The stamp method: the biodegradable patch is glued on the outside of the stomach with 0.25 cm overlap.**



The glue used was Glubran 2 made of NBCA (n- butyl 2 cyanoacrylate) OCA (2- octyl cyanoacrylate), which has been approved for intracorporeal usage (GEM, Italy). Only a few drops needed to be applied on the dry biodegradable patch, which then was glued onto the gastric wall surrounding the perforation. After repair of the perforation by either one of the above techniques, the abdomen was irrigated with saline 0.9% and closed in 2 layers with Polysorb 4.0. Directly postoperatively, one subcutaneous dosage of 0.1 ml Temgesic (0.3 mg/ml) was given as analgesic. Rats were fed standard rat chow and received nonacidified tap water. After one week, one rat, from either group was brought under general anesthesia again and underwent relaparotomy. After inspection of the abdomen, the rats were first perfused transcardially with "perinse" containing 0.9% NaCl and 1% heparin, followed by 200 mL 2% glutaraldehyde buffered with 0.1 mol/L phosphate buffer, pH 7.4. A full-thickness biopsy with a diameter of 2 cm was then taken from the perforation site and postfixed for several days in the same fixative. The specimens were then dehydrated through a graded



concentration of ethanol and embedded in glycol methacrylate. From all specimens, 2- $\mu\text{m}$  thick slices were prepared using a disposable histoknife and a Reichert-Jung "2050 supercut" microtome. The sections were mounted on glass slides and stained with toluidine blue. In addition, some sections were evaluated and photomicrographed using an Olympus BX-50 microscope (Olympus optical Co, Japan). Every following week one rat from each group underwent the above mentioned procedure.

## Results

All 20 rats survived the operations without complications; none of the rats died or showed any signs of peritonitis, sepsis, or wound infection. The most important clinical sign of peritonitis due to leakage, caused by insufficient sealing of the perforation, is that the rats do not eat and will not gain or even loose weight. The weight on the day of the first surgery (creating the perforation and closure by stamp method or omentum patch) was measured. On the day of relaparotomy, the weight was measured again. All rats, except one in both groups gained weight. The rat in the stamp group that did not gain any weight and the one in the omentum group that lost some weight were rats that already had their second surgery after one and two weeks so had less time to recover from their first surgery.

During relaparotomy in both groups, no signs of leakage or peritonitis were found. Some adhesions of the liver to the stomach were found, mainly in the omentum group, but no official scoring system for classifying the number or severity of adhesions was used. If adhesions were present, adhesiolysis needed to be performed to get a proper accessibility to the perforation site. This caused slightly more bleeding.

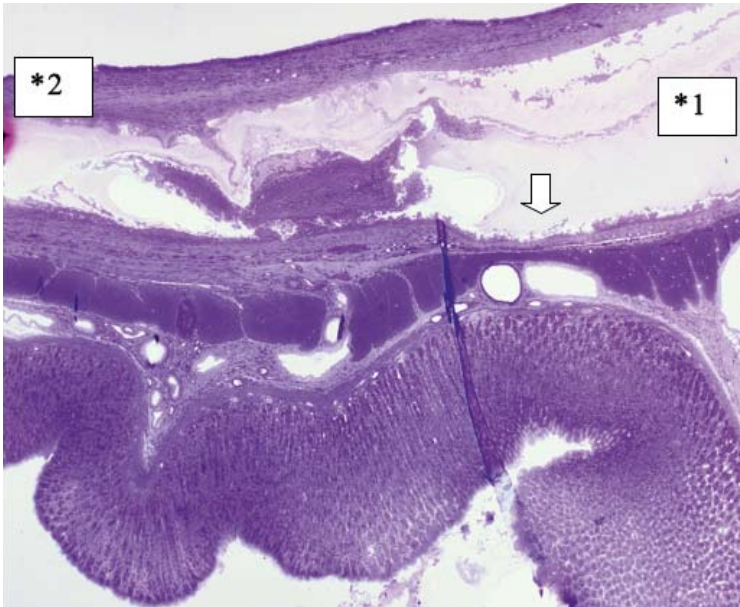## Histology

In the first week in both groups, a sign of infiltration of the area by granulocytes was observed. At the start of week 2, invasion of the biodegradable patch by giant cells was observed, indicating that degradation of the patch was started. Also in both groups, closure of the epithelioid layer of the mucosa was seen. In week 3, a fibrotic layer started to form on the outside of the biodegradable patch (Figure 3).

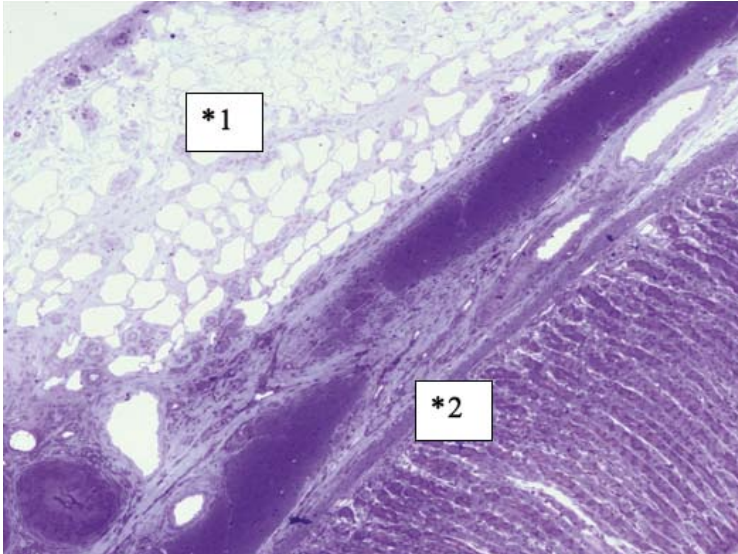
In the following weeks, this developed into a well-organized, vascularized and structured layer. This phenomenon was not seen in the rats in which the omental patch was used (Figure 4). In this group, the fat cells of the omentum were covering the perforation site. In week 6, newly formed muscle cells crossing the perforation site

were found (Figure 5). In the following weeks, the perforation site was slowly narrowing. The collagen was getting organized, and giant cells (Figure 6) were filled with patch material. These giant cells were only found in the group with the biodegradable patch. The muscle layer seemed to be repaired and continuous after 8 weeks (Figure 7), comparable in both groups. In both groups granulocytes were found during the complete period, slightly more in the patch group, but in none of the groups were there any signs of inflammation or rejection. In the ninth week, the amount of giant cells started to decrease. At week 10, the patch was almost completely absorbed.

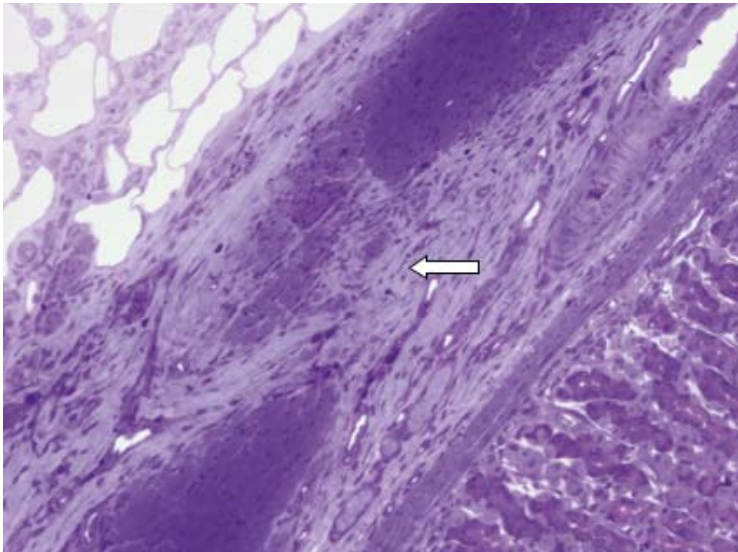
*Figure 3: Week 6. Biodegradable patch (\*1), covering defect. Patch is covered with a well-organized fibrotic layer (\*2). Giant cells invading patch (↓).*



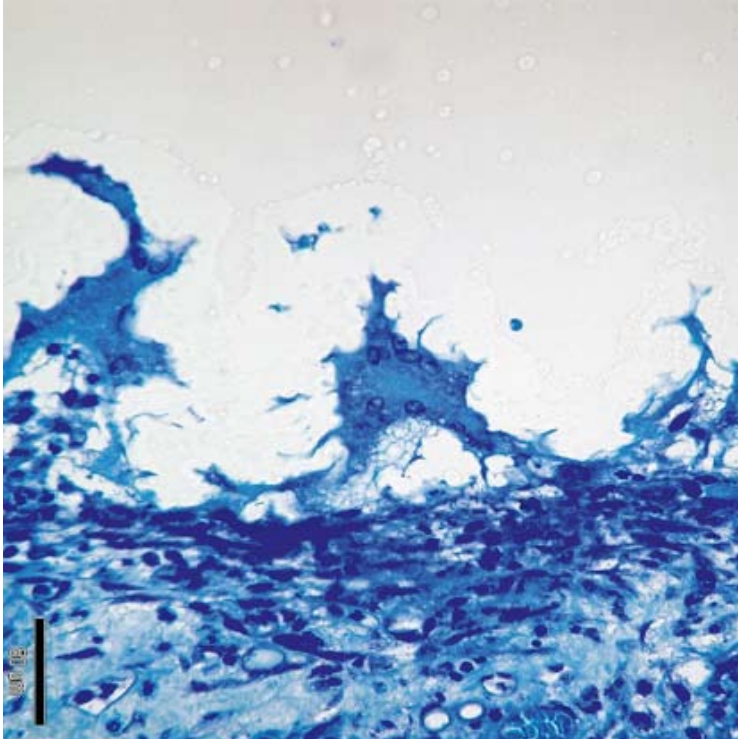
**Figure 4:** Week 8. Omentum covering the perforation side (\*1).  
The perforation can still be seen in the noncontinuity of the muscle (\*2).



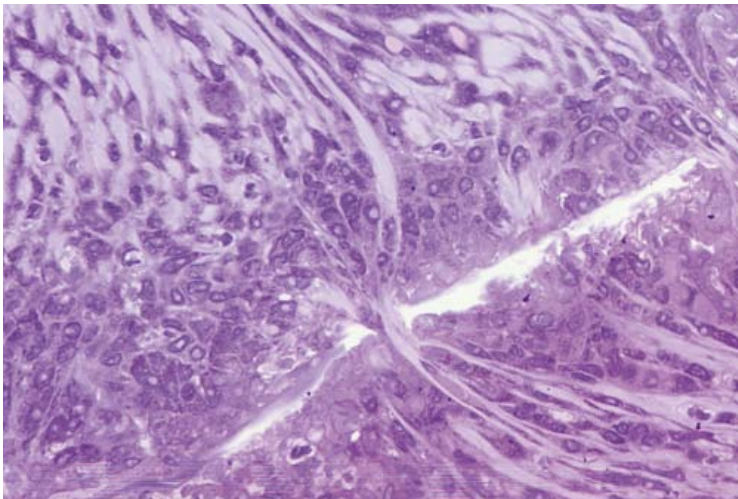
**Figure 5:** Perforation site at week 6 covered with omentum.  
New muscle cells start filling up the perforation.



*Figure 6: Three giant cells invading "stamp".  
Giant cells are filled with small particles of patch material.*



*Figure 7: Young muscle fibers closing old perforation side.  
White line is remaining on biodegradable patch at week 8.*



## Discussion

This new method for closure of a perforated peptic ulcer has previously been tested in a pilot study of 5 rats<sup>10</sup>. In the literature, we found no information on the histological phases of recovery of the stomach after perforation, and because of this, there was no guideline in what the follow-up period should have been to observe full healing. In the pilot study, there was only a follow-up of five weeks, and the muscle layer still showed signs of perforation after this period. To get more information on the healing process of the gastric wall, a longer follow-up period was necessary. Therefore in the new study, 10 rats were allocated to each group; one rat from each group was terminated weekly, which provided an overview of the healing process of 10 weeks. The histology results from this study have shown that after 1 week in both groups the epithelioid layer of the gastric mucosa already has been repaired. The muscular layer takes longer. After 6 weeks, in-growth of muscle fibres is seen, but the perforation site is still recognizable. After 8 weeks, the muscle layer in both groups was continuous. There were no signs clinical or histological of inflammation or rejection in either groups. The biodegradable patch is absorbed by giant cells, and this process already starts after 1 week. But the giant cells filled with patch material were disappearing after 10 weeks. One of the great advantages of using a stamp to cover the perforation is that the size of the perforation does not seem to matter, because the patch can be cut into any desirable size. Using glue instead of stitches simplifies and speeds up the procedure. The use of a degradable patch replaces the need for omentoplasty. Apparently the necessity for the omental plug considering its sealing and tamponade effect is arguable<sup>4, 5</sup>. Ates et al have already suggested simple laparoscopic repair without an omental patch<sup>15</sup>. Avoiding an omentoplasty might lower the formation of intraperitoneal adhesion, but unfortunately, this was not officially scored and needs further research. Because it is not necessary to mobilize the well-perfused omentum, the risk of peri- and postoperative bleeding will be lower. An interesting histological feature found in the patch group was the formation of a well-organized and vascularized collagen layer on top of the perforation. Kung describes this observation as an outer shield formed by fibrosis on top of a Teflon-felt graft, which was tested in dogs<sup>12</sup>. Whether this has any clinical importance remains unclear, but it might lower the risk of leakage or recurrence of the perforation. No approval from the animal ethical committee was given for a control group in which the spontaneous sealing of a perforation by liver or omentum could have been investigated. It is estimated that



about 40% of the perforations in humans, with an average size of 5 mm, seal by themselves <sup>16</sup>. The perforation made in our rat model had a diameter of 5 mm which would be comparable to a giant ulcer in a human stomach. Spontaneous healing of a giant ulcer is less likely to happen and associated with high morbidity and mortality <sup>17</sup>.

### **Conclusion**

The closure of a perforated peptic ulcer by using a biodegradable patch is feasible. It might even have advantages, such as less adhesion formation, lower recurrence rate and less hematoma formation. The lactide-glycolide-caprolacton patch has proven to be resistant to gastric acid. Also the biodegradation process did not go too fast; the patch material started disappearing after the perforation was healed, but also didn't stay too long. After 10 weeks, the material microscopically was almost completely degraded. This makes the material suitable for other parts of the digestive tract. That's why the stamp method might be an interesting method to close small bowel perforations. Realizing that the stamp method has not been tested on a real perforated peptic ulcer with associated peritonitis and also needs to be tested laparoscopically, further research will be interesting and necessary.

## References

1. Böhm B, Ablassmaier B, Müller J, M. *Laparoskopische Chirurgie am oberen gastrointestinaltrakt. Chirurg* 2001(72): 349-361.
2. Cellan-Jones CJ. *A rapid method of treatment in perforated duodenal ulcer. BMJ* 1929(36): 1076-1077.
3. Graham R, R. *The treatment of perforated duodenal ulcers. Surg gynecol Obstet* 1937(64): 235-238.
4. *Mastery of Surgery. In, vol Third edition.*
5. Matoba Y, Katayama H, Ohami H. *Evaluation of omental implantation for perforated gastric ulcer therapy: findings in a rat model. J Gastroenterol* 1996;31(6): 777-784.
6. Lam PW, Lam MC, Hui EK, Sun YW, Mok FP. *Laparoscopic repair of perforated duodenal ulcers: the "three-stitch" Graham patch technique. Surg Endosc* 2005;19(12): 1627-1630.
7. Lau WY, Leung KL, Zhu XL, Lam YH, Chung SC, Li AK. *Laparoscopic repair of perforated peptic ulcer. The British journal of surgery* 1995;82(6): 814-816.
8. So JB, Kum CK, Fernandes ML, Goh P. *Comparison between laparoscopic and conventional omental patch repair for perforated duodenal ulcer. Surg Endosc* 1996;10(11): 1060-1063.
9. Bertleff MJ, Halm JA, Bemelman WA, van der Ham AC, van der Harst E, Oei HI, Smulders JF, Steyerberg EW, Lange JF. *Randomized Clinical Trial of Laparoscopic Versus Open Repair of the Perforated Peptic Ulcer: The LAMA Trial. World journal of surgery* 2009;33(7): 1368-1373.
10. Matsuda M, Nishiyama M, Hanai T, Saeki S, Watanabe T. *Laparoscopic omental patch repair for perforated peptic ulcer. Annals of surgery* 1995;221(3): 236-240.
11. Gupta S, Kaushik R, Sharma R, Attri A. *The management of large perforations of duodenal ulcers. BMC Surg* 2005;5: 15.
12. Kung SP. *Teflon-felt grafting of giant gastroduodenal perforation in a canine model. Surg Today* 2004;34(2): 145-149.
13. Sharma D, Saxena A, Rahman H, Raina VK, Kapoor JP. *'Free omental plug': a nostalgic look at an old and dependable technique for giant peptic perforations. Dig Surg* 2000;17(3): 216-218.
14. Bertleff MJ, Liem RS, Bartels HL, Robinson PH, Van der Werff JF, Bonjer HJ, Lange JF. *The "stamp method": a new treatment for perforated peptic ulcer? Surg Endosc* 2006;20(5): 791-793.

15. Ates M, Sevil S, Bakircioglu E, Colak C. Laparoscopic repair of peptic ulcer perforation without omental patch versus conventional open repair. *J Laparoendosc Adv Surg Tech A* 2007;17(5): 615-619.
16. Donovan AJ, Berne TV, Donovan JA. Perforated duodenal ulcer: an alternative therapeutic plan. *Arch Surg* 1998;133(11): 1166-1171.
17. Shyu JF, Chen TH, Shyr YM, Su CH, Wu CW, Lui WY. Gastric body partition for giant perforated peptic ulcer in critically ill elderly patients. *World journal of surgery* 2006;30(12): 2204-2207; discussion 2208-2209.



**Helicobacter genotyping  
and detection in peroperative  
lavage fluid in patients with  
Perforated Peptic Ulcer**

### Abstract

**Background** Certain *Helicobacter pylori* genotypes are associated with peptic ulcer disease; however, little is known about associations between the *H. pylori* genotype and perforated peptic ulcer (PPU). The primary aim of this study was to evaluate which genotypes are present in patients with PPU and which genotype is dominant in this population. The secondary aim was to study the possibility of determining the *H. pylori* status in a way other than by biopsy.

**Methods** Serum samples, gastric tissue biopsies, lavage fluid, and fluid from the nasogastric tube were collected from patients operated upon for PPU. By means of PCR, DEIA, and LIPA the presence of the “cytotoxin associated gene” (*cagA*) and the genotype of the “vacuolating cytotoxin gene” were determined.

**Results** Fluid from the nasogastric tube was obtained from 25 patients, lavage fluid from 26 patients, serum samples from 20 patients and biopsies from 18 patients. Several genotypes were found, of which the *vacA s1 cagA* positive strains were predominant. Additionally, a correlation was found between the *H. pylori* presence in biopsy and its presence in lavage fluid ( $p=0.015$ ), rendering the latter as an alternative for biopsy. Sensitivity and specificity of lavage fluid analysis were 100% and 67%, respectively.

**Conclusion** This study shows the *vacA s1 cagA* positive strain is predominant in a PPU population. The correlation found between the *H. pylori* presence in biopsy and its presence in lavage fluid suggests that analysis of the lavage fluid is sufficient to determine the *H. pylori* presence. Risks associated with biopsy taking may be avoided.

### Introduction

Over the past decades the incidence of perforated peptic ulcer (PPU) has declined in the western world. However, with an incidence varying between two and 10 per 100.000, it still is a problem in modern society <sup>1</sup>. Moreover, mortality rates caused by gastric and duodenal ulcer perforation vary between 10 and 40% and zero and 10% respectively, and is higher among elderly patients <sup>2,3</sup>. Several risk factors for PPU have been described like smoking, alcohol abuse, and history of peptic ulcer disease (PUD) <sup>2</sup>. However the main pathogenic factors are considered to be the use of non-steroidal anti-inflammatory drugs (NSAID) and the presence of *H. pylori* <sup>2</sup>.

*Helicobacter pylori* are widespread bacteria, with a prevalence ranging from 25% in

the industrialized world to more than 70% in developing countries <sup>4,5</sup>. Most infected people remain asymptomatic; however, a small group of carriers will develop PUD. Of patients who have developed PPU, 70% will test positive for *H. pylori* <sup>2</sup>, suggesting the pathogenesis of perforation is associated with the presence of *H. pylori*. In addition, it is shown that different genotypes of *H. pylori* are associated with different clinical manifestations like PUD and gastric cancer <sup>6,7</sup>. Two well-known *H. pylori* genes that have been associated with PUD are the cytotoxin-associated gene (*cagA*) and the vacuolating cytotoxin gene (*vacA*) <sup>6,8-10</sup>.

*VacA* is present in all *H. pylori* strains and is associated with gastritis, PUD and gastric carcinoma <sup>10-12</sup>. It encodes for a vacuolating cytotoxin that causes epithelial cell injury and interferes with the immune system <sup>13, 14</sup>. *VacA* contains at least two variable regions, the signal peptide (s)-region and the middle (m)-region. The s-region contains two allelic types, s1 and s2. The s1 strain has several subtypes, being s1a, s1b and s1c <sup>15</sup>. Two allelic types exist for the m-region, m1 and m2. The latter has two subtypes, m2a and m2b <sup>16</sup>. *CagA* is considered a marker for a genomic pathogenicity (*cag*) island that is associated with enhanced virulence <sup>17</sup>.

If PPU is associated with a specific *H. pylori* genotype it may be feasible to limit the patients undergoing antibiotic therapy to those who have this genotype. When this specific type is not present, another cause of PPU should be looked for and antibiotic therapy should not be started. This would mean cost reduction and, probably, a reduction in the development of antibiotic resistance.

Currently, gastric biopsy during endoscopy is a generally accepted method to diagnose *H. pylori* infection. However, patients with PPU will not undergo endoscopy but will generally be operated upon immediately. Taking a biopsy intraoperatively implicates a higher risk of bleeding and more difficult closure of the defect. Therefore, surgeons are reluctant to take a biopsy. The primary aim of this study was to evaluate which genotypes are present in patients with PPU and if a genotype is dominant in this population. The secondary aim was to study the possibility of determining the *H. pylori* status in a fashion other than by gastric tissue biopsy.

## Methods

From 30 consecutive patients operated upon for PPU serum samples, gastric tissue biopsies, lavage fluid and fluid from the nasogastric tube were collected. These patients were treated in five different medical centers throughout the Netherlands. In

each of these centers approval of the medical ethical committee was obtained. Immediately after collection, the materials were frozen at  $-20^{\circ}\text{C}$ . One researcher performed the analysis and genotyping. For *H. pylori* genotyping, the presence of cytotoxin-associated gene (*cagA*) and the *s*- and *m*-region genotypes of the vacuolating cytotoxin gene (*vacA*), were determined.

DNA was isolated according to Boom's method as described previously<sup>18</sup>. A guanidine thiocyanate (GuSCN) solution was added to the collected material to induce lysis of the bacteria, releasing their DNA. After addition of the silica particles (Celite) the suspension was centrifuged. The silica particles, with the attached DNA, were washed with subsequently GuSCN-containing washing buffer, ethanol 70 % and acetone. After drying, the DNA was eluted in an aqueous low salt buffer. The isolated DNA was amplified by means of polymerase chain reaction (PCR) and subsequently the presence of *cagA* and different types of *vacA* were analyzed by means of reverse hybridization on a strip (32). This assay consists of a nitrocellulose strip that contains dT-tailed oligonucleotide probes immobilized as parallel lines. For each strain, 10  $\mu\text{l}$  of each PCR product (containing biotin at the 5' end of each primer) was denatured by the addition of an equal amount of 400 mM NaOH–10 mM EDTA in a plastic trough. After 5 min, 1 ml of prewarmed hybridization solution (2x SSC [1x SSC is 0.15 M NaCl plus 0.015 M sodium citrate], 50 mM Tris-HCl [pH 7.5], 0.1% SDS) was added, and a strip was submerged and incubated in a shaking water bath at  $50^{\circ}\text{C}$  for 1 h. The strips were washed with 2 ml of 2x SSC–0.1% SDS for 30 min at  $50^{\circ}\text{C}$ . Subsequently, the strips were rinsed three times in phosphate buffer, and conjugate (streptavidin-alkaline phosphatase) was added. After incubation at room temperature for 30 min, the strips were rinsed again and 4-nitroblue tetrazolium chloride and 5-bromo-4-chloro-3-indolylphosphate substrate was added. Hybrids are visible as purple probe lines. Interpretation of the hybridization patterns was performed visually. As a control a  $\beta$ -globin PCR was performed. Patient related factors were obtained prospectively. Statistical analysis was performed with SPSS for Windows, version 11.0.

### Results

A total of 30 patients were included of whom nine were women. The average age was 65 years, varying between 40 and 87. Ten patients (33.3%) were operated laparoscopically. The perforation was found prepyloric in 11 patients, at the site of the pylorus in eight patients and postpyloric in 11 patients. A total of five (16.7%) patients

Patient	Fluid from nasogastric tube	Lavage fluid	Serum	Gastric tissue biopsy
1	s1a/m2a/cag			
2	s1a/m2a/cag	s1a/m2a/cag		s1a/m2a/cag
3	s1b	s1a/m2a/cag		
4		s1a/s2/m2a		
5		s1a		s1a/m1
6				
7	s1a/m2a			
8				
9	s1b/m1/cag	s1b/m1/cag		
10				
11				
12		s1a/m2a/cag		
13				
14	s1a/m1/cag			s1a/m1/cag
15		s1a/m1/cag		s1a
16	s1a/m1/cag	s1a/m1/cag		
17	s1a/m1/cag			
18				
19	s1a/m1/cag	s1a/m1/cag		
20	s1a/m1/cag	s1a/m1/cag		
21	s1a/m1/cag	s1a/m1/cag		
22				
23		s1a/m1/cag		
24	s1a/s1b/m1/cag	s1a/s1b/m1/cag		s1b/m1
25		s1a/m1/cag		s1b/m1/cag
26		s1a/m2a/cag		
27		s1a/m2a		s1a/m1/cag
28	s1a/s2/m2a/cag	s1a/s2/m2a/cag		s1a/s2/m2a/cag
29		s2/m2a		s2/m2a
30				
	<b>β-globin and <i>H. pylori</i> positive</b>			
	<b>β-globin and <i>H. pylori</i> negative</b>			
	<b>β-globin positive and <i>H. pylori</i> negative</b>			
	<b>β-globin negative and <i>H. pylori</i> positive</b>			
	<b>No materials</b>			

Table 1. *H. pylori* status and genotype.  
The colors represent the β-globin and *H. pylori* status of the patient.

had a history of PUD. Ten patients (33.3%) used NSAIDs, two patients (6.7%) used steroids, three patients (10.0%) used acid reducers and one patient (3.3%) used a proton pump inhibitor (PPI) before admission to the hospital. The average hospital stay was 11.9 days, varying between 3 and 37 days. Fluid from the nasogastric tube was obtained from 25 patients, lavage fluid from 26 patients, serum samples from 20 patients and ulcer biopsies from 18 patients. The results of the genotyping are depicted in Table 1. The  $\beta$ -globin determination was performed as a control. In nine samples of nasogastric tube fluid and in two samples of lavage fluid it was negative, rendering these results as unreliable. Therefore these results were excluded from further analysis. Table 2 represents the frequency of the individual genes, the allelic types and subtypes found in the different samples by means of PCR and LiPA. These tables show that for *vacA* the allelic type s1 is predominantly present in all three types of samples. In the s1 positive strains, subtype s1a is predominant as depicted in table 3. With regard to the middle region of *vacA* the incidence of m1 allelic type is slightly higher; however the difference is less outspoken compared to s1. The m2a was the only subtype that was found in the samples. In three samples, the genotyping was incomplete (Table 1 and 2), meaning that determination of the middle region was not possible. This was most likely caused by the small number of bacteria present in those samples. With regard to the secondary aim of this study, analyzing possibilities to diagnose *H. pylori* presence in another fashion than through biopsy, the *H. pylori* status found in each type of sample was compared. A correlation was found between the *H. pylori* presence in biopsy and its presence in lavage fluid (Fisher's exact test,  $p=0.015$ ), indicating lavage fluid is a valid alternative for determination of *H. pylori* infection. The sensitivity and specificity of the lavage fluid analysis was calculated, considering biopsy as a golden standard. Fourteen patients, of which the lavage fluid as well as the biopsy were analyzed, were included into this calculation (patients 2,4,5,6,8,10,15,23-25,27-30, Table 1), which is shown in Table 4. Of the remaining patients, either the biopsy or the lavage fluid was missing; therefore, these data cannot be used in the sensitivity/ specificity calculation. The sensitivity was 100 %, which means that in case of presence of *H. pylori* in the biopsy specimen, the lavage fluid analysis detected it in 100% of cases. The specificity was 66.7%, which means the chance for false-positives is over 30%. With regard to gender, age, BMI, history of PUD, location of perforation, complications after procedure and use of steroids, PPI, or antihistaminic medication, no statistically significant correlation was found.

Genotype	Fluid from naso-gastric tube		Lavage fluid		Gastric tissue biopsy		Control non-ulcer
	no	%	no	%	no	%	%
vacA s1	10	90.9	14	77.8	7	77.8	46.9
vacA s2	0	0	1	5.5	1	11.1	38.4
vacA multiple	1	9.1	3	16.7	1	11.1	14.7
Total	11	100	18	100	9	100	100
vacA m1	6	54.5	9	50.0	5	55.6	29.4
vacA m2	4	36.4	8	44.4	3	33.3	55.9
vacA incomplete genotype	1	9.1	1	5.6	1	11.1	0 (14.7 % incomplete)
Total	11	100	18	100	9	100	100
cagA positive	9	81.8	14	77.8	5	55.6	47.1
Total	11	100	18	100	9	100	100

**Table 2. Frequencies of individual genes, allelic types and subtypes. “VacA multiple” means that more than one allelic type or subtype have been found in one sample. In each different type of sample one incomplete genotype occurred, which is indicated as “vacA incomplete”. The “Control non ulcer” column represents the frequencies, found by van Doorn et al., in a population without PUD and is added to allow easy comparison.**

VacA Subtype	Fluid from naso-gastric tube		Lavage fluid		Gastric tissue biopsy		Control non-ulcer
	no	%	no	%	no	%	%
s1a	8	80.0	13	92.9	5	71.4	81.3
s1b	2	20.0	1	7.1	2	28.6	18.7
s1c	0	0	0	0	0	0	0
Total	10	100	14	100	7	100	100

**Table 3. Distribution of the vacA s1 subtypes. The s1a subtype is predominant in all types of samples. The “Control non ulcer” column represents the frequencies, found by van Doorn et al., in a population without PUD and is added to allow easy comparison.**

Biopsy			
Lavage fluid	+	-	Total
+	8	2	10
-	0	4	4
Total	8	6	14
	Sens 8/8 = 1	Spec 4/6 = 0.67	

**Table 4.** Calculation of sensitivity and specificity of lavage fluid analysis, considering the biopsy to be the golden standard

### Discussion

Concerning the role of *H. pylori* in the pathogenesis of PPU, some studies have been reported comparing the prevalence of *H. pylori* infection in patients with PPU with the prevalence in controls. They appear to be similar suggesting that other factors like NSAID use play a role<sup>19-21</sup>. However, the substantial genetic heterogeneity of *H. pylori* that has been revealed over the years leads to the hypothesis of a specific genotype causing PPU<sup>5</sup>. Controls might test positive for *H. pylori*, but not develop PPU because it would not be this specific genotype that is isolated. This study of a selected population of patients, all with PPU, shows a limited diversity of *H. pylori* genotypes as represented by Table 1.

VacA s1 strains are predominantly present in the three sample types of which s1a is the predominant subtype. Concerning the vacA m-region, the m1 strains are found in a majority of cases, however, the difference is less convincing than for vacA s1. Except for the biopsy samples, the cagA positive strains were predominantly present in this population. In the biopsy samples, the frequency of cagA positive strains seemed to be low, however this number is distorted because in two of nine positive biopsies, a decent comparison with the other samples was not possible. In patient 5, genotyping of the lavage fluid and nasogastric tube fluid was incomplete and for patient 15, the opposite was the case. This means that the actual incidence should be 71.4% (5/7).

Summarizing, these results show that the vacA s1, cagA positive strains were predominant in this population of patients with PPU. This finding is in accordance with literature reporting correlations between the presence of vacA s1, cagA positive strains and PUD<sup>6,10</sup>. Therefore, detection of the genotype vacA s1 does not specifically predict PPU; nevertheless, clinicians should be aware of this association.

In Tables 2 and 3 the genetic distribution in a Dutch population without PUD, as found



by van Doorn et al., are added for comparison. The frequencies found in this study for *vacA* s1, m1 and *cagA* positive strains are clearly higher than in the non-PUD group, confirming the before mentioned hypothesis. However, with regard to the subtypes, Table 3 shows an almost similar distribution of frequencies, suggesting that determination of the allelic subtype is of less importance.

In only 60% of patients biopsies could be analyzed. Reasons for missing 40% is the restraint of the surgeon to take a biopsy when risk of bleeding and more difficult closure of the defect was estimated to be too high, which emphasizes the importance of finding an alternative. To do so, the *H. pylori* status of the patient as determined by biopsy was compared to the status as determined by analysis of nasogastric tube fluid, lavage fluid, and serum. A statistically significant correlation was found between the *H. pylori* status in biopsy and its status in lavage fluid (Fisher's exact test,  $p=0.015$ ). This finding suggests that determination of the *H. pylori* status can be done with lavage fluid as well, obviously without any risk of bleeding and closure related difficulties. The sensitivity is 100%, but the specificity is 66.7%. This could mean the chance for false-positives is over 30 %, which is not optimal and could lead to therapy overshoot. However, considering the fact that with the lavage a larger area is sampled, rendering the chance of positive test results higher than in biopsy, it is more likely to find false negative biopsy results. This could lead to a therapy undershoot, which obviates the importance having an alternative for a biopsy.

In only two samples, both nasogastric tube fluids, a *H. pylori* genotype was isolated, while  $\beta$ -globin tested negative. In nine samples (seven nasogastric tube fluid, two lavage fluid) both  $\beta$ -globin and *H. pylori* tested negative. This means that either no humane cells were present in the samples, which is unlikely, or that an error in the PCR procedure had occurred. Because this was unclear these results were considered unreliable. Therefore, it still could be possible that nasogastric tube fluid is a good alternative for determining the *H. pylori* status as well.

Overall, these results are positive, however they should be confirmed in a larger population.

## Conclusion

This study shows that in a population of 30 patients with PPU, *vacA* s1, *cagA* positive strains are predominant. This finding is in accordance with literature reporting correlations between the presence of *vacA* s1, *cagA* positive strains and PUD. Therefore

detection of this genotype does not specifically predict PPU. Nevertheless, clinicians should be aware of this association.

This study shows as well that it is feasible to use intraoperative lavage fluid to determine the *H. pylori* status of the patient, implicating that biopsies, with a risk of bleeding and more difficult closure of the defect, are not necessary anymore. In addition, considering the fact that a larger area is sampled with lavaging, biopsies may result in more false negative results leading to insufficient therapy.

### Acknowledgements

The authors would like to thank W.A. Bemelman (Department of Surgery, University of Amsterdam, Amsterdam, The Netherlands), A. van der Ham (Department of Surgery, Sint Franciscus Gasthuis, Rotterdam, The Netherlands) and I. Oei (Department of Surgery, Reinier de Graaf Gasthuis, Delft, The Netherlands) for their input in this study.

### References

1. Higham J, Kang JY, Majeed A. Recent trends in admissions and mortality due to peptic ulcer in England: increasing frequency of haemorrhage among older subjects. *Gut* 2002; 50(4):460-4.
2. Gisbert JP, Pajares JM. *Helicobacter pylori* infection and perforated peptic ulcer prevalence of the infection and role of antimicrobial treatment. *Helicobacter* 2003; 8(3):159-67.
3. Sarosi GA, Jr., Jaiswal KR, Nwariaku FE, et al. Surgical therapy of peptic ulcers in the 21st century: more common than you think. *Am J Surg* 2005; 190(5):775-9.
4. Holcombe C, Omotara BA, Eldridge J, Jones DM. *H. pylori*, the most common bacterial infection in Africa: a random serological study. *Am J Gastroenterol* 1992; 87(1):28-30.
5. van Doorn LJ. Detection of *Helicobacter pylori* virulence-associated genes. *Expert Rev Mol Diagn* 2001; 1(3):290-8.
6. Erzin Y, Koksall V, Altun S, et al. Prevalence of *Helicobacter pylori* *vacA*, *cagA*, *cagE*, *iceA*, *babA2* genotypes and correlation with clinical outcome in Turkish patients with dyspepsia. *Helicobacter* 2006; 11(6):574-80.
7. Tham KT, Peek RM, Jr., Atherton JC, et al. *Helicobacter pylori* genotypes, host factors, and gastric mucosal histopathology in peptic ulcer disease. *Hum Pathol* 2001; 32(3):264-73.
8. Chen XJ, Yan J, Shen YF. Dominant *cagA/vacA* genotypes and coinfection frequency of *H. pylori* in peptic ulcer or chronic gastritis patients in Zhejiang Province and correlations among different genotypes, coinfection and severity of the diseases. *Chin Med J (Engl)* 2005; 118(6):460-7.

9. Atherton JC. *H. pylori* virulence factors. *Br Med Bull* 1998; 54(1):105-20.
10. van Doorn LJ, Figueiredo C, Sanna R, et al. Clinical relevance of the *cagA*, *vacA*, and *iceA* status of *Helicobacter pylori*. *Gastroenterology* 1998; 115(1):58-66.
11. Marshall BJ, Warren JR. Unidentified curved bacilli in the stomach of patients with gastritis and peptic ulceration. *Lancet* 1984; 1(8390):1311-5.
12. Parsonnet J, Hansen S, Rodriguez L, et al. *Helicobacter pylori* infection and gastric lymphoma. *N Engl J Med* 1994; 330(18):1267-71.
13. Yamasaki E, Wada A, Kumatori A, et al. *Helicobacter pylori* vacuolating cytotoxin induces activation of the proapoptotic proteins Bax and Bak, leading to cytochrome c release and cell death, independent of vacuolation. *J Biol Chem* 2006; 281(16):11250-9.
14. Sundrud MS, Torres VJ, Unutmaz D, Cover TL. Inhibition of primary human T cell proliferation by *Helicobacter pylori* vacuolating toxin (VacA) is independent of VacA effects on IL-2 secretion. *Proc Natl Acad Sci U S A* 2004; 101(20):7727-32.
15. van Doorn LJ, Figueiredo C, Sanna R, et al. Expanding allelic diversity of *Helicobacter pylori* *vacA*. *J Clin Microbiol* 1998; 36(9):2597-603.
16. Atherton JC, Cao P, Peek RM, Jr., et al. Mosaicism in vacuolating cytotoxin alleles of *Helicobacter pylori*. Association of specific *vacA* types with cytotoxin production and peptic ulceration. *J Biol Chem* 1995; 270(30):17771-7.
17. van Doorn LJ, Schneeberger PM, Nouhan N, et al. Importance of *Helicobacter pylori* *cagA* and *vacA* status for the efficacy of antibiotic treatment. *Gut* 2000; 46(3):321-6.
18. Boom R, Sol CJ, Salimans MM, et al. Rapid and simple method for purification of nucleic acids. *J Clin Microbiol* 1990; 28(3):495-503.
19. Reinbach DH, Cruickshank G, McColl KE. Acute perforated duodenal ulcer is not associated with *Helicobacter pylori* infection. *Gut* 1993; 34(10):1344-7.
20. Lanan A, Serrano P, Bajador E, et al. Evidence of aspirin use in both upper and lower gastrointestinal perforation. *Gastroenterology* 1997; 112(3):683-9.
21. Kate V, Ananthkrishnan N, Badrinath S. Effect of *Helicobacter pylori* eradication on the ulcer recurrence rate after simple closure of perforated duodenal ulcer: retrospective and prospective randomized controlled studies. *Br J Surg* 2001; 88(8):1054-8.



---

**Summary**  
**Samenvatting**  
**Curriculum Vitea**  
**Dankwoord**

### Summary

#### Chapter 1

It all started with the LAMA trial, a Dutch multicentre trial, in which the laparoscopic suturing of a perforated peptic ulcer was compared with suturing by upper laparotomy, at that time first treatment of choice. During this trial questions raised about general operation techniques considering this procedure, alternative suturing techniques, screening methods for *Helicobacter pylori* and which routine steps to take in the pre- and postoperative phase. In this thesis a review is given about all decisions and steps needed to be taken if a patient presents with acute abdominal pain, suspected for a perforated peptic ulcer.

#### Chapter 2

Stress is often mentioned as being responsible for the emergence of a perforated peptic ulcer, but PPU is not a typical phenomenon of nowadays- stressful lifestyles. Already in 1600 the clinical symptoms were described, but still up to now this acute disease is associated with high morbidity and mortality. The article in chapter 2 gives an overview of the epidemiology throughout the centuries, underlying pathology, possible treatment options (conservative versus surgical) and the surgical techniques for management of the perforation.

#### Chapter 3

During the 80s laparoscopic surgery became more popular. It was possible to remove a gallbladder laparoscopically with good results, less postoperative pain and fewer complications. Since, several articles (mainly retrospective) have been published about laparoscopic suturing of a perforated peptic ulcer, but unfortunately this procedure still not is first method of choice. All publications regarding this topic have been evaluated according to the Effective Public Health Practice Project guidelines. Concluding, there are several convincing arguments for treating patient, suspected for having a perforated peptic ulcer laparoscopically. Relative contra-indications are a Boey score of 3, patients over 70 years old and symptoms existing for more than 24 hours.

#### Chapter 4

This chapter reports the results of a randomized trial, started in the Netherlands in 1999, in which nine hospitals participated. A total of 101 patients were randomized, of

which 52 were treated by laparoscopic surgery and 49 patients received an upper laparotomy. Results show that the laparoscopic procedure takes longer surgery time, but patients in this group had less postoperative pain. Concluding laparoscopic closure of perforated peptic ulcer was a safe procedure.

### **Chapter 5**

To get an impression about the golden standard in Europe a questionnaire was sent to all members considering their routine procedures according the treatment of PPU in collaboration with the European Association of Endoscopic Surgery (EAES)

The results of 540 completed questionnaires were evaluated and summarized. One of the outstanding results was that, unlike a few years ago, laparoscopic correction of a PPU is first method of choice nowadays. Also the incidence of PPU, despite adequate anti ulcer therapy seems not to have declined. Due to the fact that many surgeons, especially the experienced ones, start surgery laparoscopically as a diagnostic tool, the necessity of performing a CT scan preoperatively has diminished.

### **Chapter 6**

During meetings with the surgeons participating in the LAMA trial, several times it was mentioned that the laparoscopically positioning and tying of the sutures was a difficult and time consuming part of the procedure, with the risk of tearing out of the sutures and the possibility of enlarging the perforation hole.

Because of this, an alternative method was thought of ,avoiding the suturing process. A biodegradable patch, consisting of lactide-glycolide-caprolactone was made, which could be glued like a 'stamp' on the outside of the stomach, covering the perforation site. The method was tested on animals and the results showed that the rats had no adverse side effects of the material, there were no postoperative complications and histological no sign of rejection.

### **Chapter 7**

Because of the positive results of the pilot study with the 'stamp' method a randomized trial was started in rats, comparing the patch method with the conventional method for closing a perforated gastric perforation by suturing the perforation with a Graham patch. Histological the healing process was observed with a follow-up of ten consecutive weeks. The healing process of the stomach wall was observed as well as

any adverse effects due to the lactide-glycolide-caprolactone. There were no postoperative complications. Histological giant cells started degradation of the patch at week 2. There were no signs of rejection. The mucosal layer was closed after 2 weeks, the muscular layer after 8 weeks. Both methods were comparable.

### **Chapter 8**

Since the discovery of the role of *Helicobacter pylori* in the emergence of peptic ulcer disease in 1982 by Barry J. Marshall and Robin Warren, many patients are prophylactically treated with antibiotics, to prevent occurrence of complications like perforations. It is known that *Helicobacter* has different genotypes, which not all are responsible for causing symptoms and because of this not all carriers need prophylactic treatment. In this study, material was collected from patients who had surgery for PPU. The material was tested for *Helicobacter* and DNA typing was done if *Helicobacter* was present. It appeared to be possible to test *Helicobacter* from abdominal irrigation fluid, making a biopsy from the stomach wall unnecessary. Several genotypes were found, of which *vacA*s1 *cagA* was dominant.

### **'Future perspectives'**

According to the review articles from chapter 2 and 3 there are still many controversies according to the treatment for perforated peptic ulcer disease. Research addressing for example the necessity of the omental patch, the need for thorough irrigation of the abdominal cavity or the benefits of using abdominal drains might be useful in establishing consensus on surgery for perforated peptic ulcers.

One of the great advances of laparoscopic surgery, besides less operative pain and complications on the short term, probably is less intra-abdominal adhesion formation. In literature, it is not known if this is the case in PPU.

The 'stamp method' has proven that it is possible to close a perforation of the stomach with a bioabsorbable patch. The material can resist the acid environment and it does not cause any side effects. Because of this, very likely the patch can be used for other perforations as well, like bowel perforations and it would be interesting to know if for instance a bowel resection could be avoided by using the patch. Also the patch could be used for protecting newly made anastomoses or prevent leakage. It could be used for treatment of a cervical esophageal anastomotic complications and making a myocutaneous flap redundant.



## Samenvatting

### Hoofdstuk 1

Het is allemaal met de LAMA trial begonnen, een Nederlandse multicenter trial waarin het laparoscopisch overhechten van een maagperforatie werd vergeleken met de op dat moment gangbare standaard techniek i.e. het overhechten door middel van een bovenbuiklaparotomie. Tijdens deze studie werden er vragen opgeroepen over algemene operatietechnieken en alternatieve hechttechnieken, screeningsmethodes voor *Helicobacter pylori* en over het te volgen pre-, per en postoperatieve beleid. In dit proefschrift is geprobeerd een overzicht te geven over het hele traject en keuzes die gemaakt moeten worden met betrekking tot een patiënt die zich presenteert met een acute buik, verdacht voor een maagperforatie.

### Hoofdstuk 2

Een maagperforatie wordt, zoals men lang dacht vaak veroorzaakt door stress, maar is echter geen typisch verschijnsel van de huidige stressvolle tijd. Het klinisch beeld werd immers al in 1600 beschreven, maar tot op heden is deze acute aandoening nog steeds geassocieerd met een hoge morbiditeit en mortaliteit. Dit artikel geeft een overzicht van de epidemiologie door de jaren heen, de pathologie en mogelijke behandelingen (conservatief versus operatief) en chirurgische technieken om de perforatie te behandelen.

### Hoofdstuk 3

In de jaren 80 werd het laparoscopisch opereren steeds meer populair. Het bleek dat het laparoscopisch mogelijk was om een galblaas te verwijderen met goede resultaten, minder postoperatieve pijn en minder complicaties. Sindsdien zijn er ook verschillende (met name retrospectieve) studies gepubliceerd over het laparoscopisch overhechten van een maagperforatie, maar helaas is deze ingreep meestal nog geen eerste keus van behandeling. Met behulp van de Effective Public Health Practice Project richtlijnen zijn deze publicaties geëvalueerd. Concluderend blijken er genoeg argumenten te zijn om bij een patiënt verdacht voor maagperforatie, laparoscopisch de maagperforatie te sluiten. Relatieve contra-indicaties zijn een Boey score van 3, een patiënt ouder dan 70 jaar en indien de symptomen al langer dan 24 uur bestaan.

### Hoofdstuk 4

Dit hoofdstuk beschrijft de resultaten van een gerandomiseerde studie, gestart in 1999 in negen ziekenhuizen in Nederland. 101 patiënten werden gerandomiseerd, waarvan 52 laparoscopisch werden geopereerd en 49 door middel van een bovenbuiklaparotomie. De resultaten lieten zien dat de laparoscopische ingreep langer duurde, maar de patiënten uit deze groep hadden minder postoperatieve pijn. Samenvattend bleek het laparoscopisch overhechten van een maagperforatie een veilige ingreep.

### Hoofdstuk 5

Om een indruk te krijgen over het huidige beleid in Europa, is met behulp van de European Association of Endoscopic Surgery (EAES) een enquête over het laparoscopisch hechten van PPU rondgestuurd. Resultaten werden berekend op grond van 540 compleet ingevulde enquêtes. Opvallende uitkomsten zijn, dat in tegenstelling tot enkele jaren geleden het laparoscopisch overhechten van PPU nu de eerste keus van behandeling is en dat de incidentie van PPU, ondanks adequate anti-ulcer medicatie, niet lijkt te zijn afgenomen. Tevens lijkt het starten met behulp van diagnostische laparoscopie, zeker bij ervaren chirurgen de noodzaak tot het preoperatief maken van een CT scan te doen afnemen.

### Hoofdstuk 6

Tijdens besprekingen met de participerende chirurgen van de LAMA trial kwam ter sprake dat het laparoscopisch overhechten van een maagperforatie een lastig onderdeel van de ingreep was, met als risico uitscheuren van de hechtingen, waardoor mogelijk kans op vergroten van de perforatie. Derhalve werd gezocht naar een alternatief voor de hechtprocedure, te weten het plakken van een bioafbreekbare 'postzegel' (patch van lactide-glycolide-caprolactone) op de buitenzijde van de maag, welke de perforatie zou bedekken. Deze methode werd hier experimenteel getest. Het bleek dat het materiaal goed door de ratten werd verdragen, er waren postoperatief geen complicaties en histologisch ook geen tekenen van afstoting.

### Hoofdstuk 7

Daar de pilotstudy van de "postzegelmethode" succesvol was, werd aanvullend een gerandomiseerde studie bij ratten verricht waarin de stamp methode werd vergeleken

met het overhechten van de maagperforatie op de conventionele manier via het gebruik van een Graham patch. Tevens werd het genezingsproces histologisch bekeken, met een follow-up van tien op één volgende weken. Beoordeeld werd hoe de maagwand ter plaatste van de perforatie herstelde en wat het effect was van de lactide-glycolide-caprolactone. Er traden geen postoperatieve complicaties op. Histologisch werd gezien dat de afbraak van de patch door reuscellen na 2 weken werd gestart. Er waren geen afstoting reacties. De mucosa was na 2 weken gesloten en de spierlaag na 8 weken. Beide methodes waren vergelijkbaar.

### **Hoofdstuk 8**

Sinds de ontdekking van de rol van *Helicobacter pylori* bij het ontstaan van peptic ulcer disease in 1982 door Barry J. Marshall en Robin Warren, worden veel patiënten profylactisch behandeld met antibiotica, ter voorkoming van complicaties zoals perforatie. Het is inmiddels gebleken dat *Helicobacter* verschillende genotypes heeft, welke niet allemaal ziekteverschijnselen veroorzaken en dus behandeld behoeven te worden. In deze studie is materiaal van patiënten verzameld, welke geopereerd werden in verband met een maagperforatie. Dit materiaal werd onderzocht op aanwezigheid van *Helicobacter pylori* en hiervan werd DNA typering gedaan. Uit de studie bleek dat *Helicobacter* kon worden bepaald in buikspoelvoelstof en dat een biopt van de plaats van perforatie onnodig bleek. Er werden verschillende genotypen gevonden, waarvan de *vacAs1cagA* variant dominant aanwezig was.

### **Toekomstig onderzoek**

Uit de review artikelen van hoofdstuk 2 en 3 blijkt dat er nog heel wat discussie punten bestaan over de juiste behandeling van een maagperforatie. Gerichte studies naar bijvoorbeeld de zin of onzin van een omentumpatch, het wel of niet uitgebreid spoelen van een buik of het gebruik van drains zouden een waardevolle bijdrage kunnen leveren tot de vorming van een consensus.

Een groot voordeel van laparoscopisch opereren, naast het optreden van minder postoperatieve pijn en complicaties op korte termijn, zou kunnen zijn dat er minder intra-abdominale adhesies optreden. In de literatuur is hier bij maagperforaties nog weinig over bekend.

De 'stamp method' heeft aangetoond dat het gebruik van een bioafbreekbare patch bij een maagperforatie mogelijk is. Het materiaal is bestand tegen de lage pH van de maag en geeft geen afstotingsreacties. Dit maakt het zeer waarschijnlijk dat de patch ook bruikbaar is bij andere perforaties, zoals bijvoorbeeld bij darmperforaties en het zou interessant zijn om dierexperimenteel uit te zoeken of dit bijvoorbeeld een darmresectie kan voorkomen. Tevens zou dit materiaal gebruikt kunnen worden als een beschermlaag rondom anastomoses in de tractus digestivus om de kans op lekkage te verkleinen of zelfs als behandeling kunnen dienen bij een naadlekkage van een slokdarmanastomose, waarbij de noodzaak voor een huid-spierslap misschien onnodig blijkt.

## Curriculum Vitae

Mariëtta Johanna Elizabeth Bertleff werd geboren op 12 september 1971 te Zaandam. Ze is opgegroeid in Almelo, alwaar ze het VWO voltooide op de Rijksscholen-gemeenschap Erasmus. Erasmus bleek daarna een rode draad in haar leven. Ze ging geneeskunde studeren op de Erasmus universiteit in Rotterdam en is in 2010 begonnen aan de parttime opleiding bedrijfskunde op de Rotterdam School of Management (RSM) van de Erasmus universiteit.

In 1997 behaalde zij het artsexamen en ging als arts assistent niet in opleiding (AGNIO) in het Dijkzigt ziekenhuis werken, waar ze reeds werkte in de onderzoeksgroep van Prof. Bruining van de afdeling Heelkunde. In 1999 begon ze de opleiding tot algemeen chirurg in het (voormalig) Clara ziekenhuis met als opleider Dr. Yo. In 2002 besloot ze over te stappen naar de plastische chirurgie en vervolgde deze opleiding in het academisch ziekenhuis te Groningen bij Prof. J.P. Nicolai. Na de opleiding in 2005 te hebben afgerond ging ze als fellow handchirurgie werken in het Broomfield ziekenhuis te Chelmsford, Engeland. In 2006 vestigde ze zich als plastisch chirurg in het Diaconessenhuis te Leiden.

Sinds 1 mei 2010 is ze werkzaam als hand- en polschirurg in de Xpertclinic te Hilversum, Rotterdam en Velp.



### Dankwoord

Misschien wel het belangrijkste hoofdstuk van het boekje. Het hoofdstuk wat iedereen altijd leest, naast je curriculum vitae en de stellingen. Het is een voldongen feit dat het boekje nooit tot stand was gekomen zonder de lange adem en hulp van een heleboel mensen.

Prof. Lange (1ste promotor), beste Johan. In 1999 werd het idee geboren voor de LAMA trial bij de postvakjes op het secretariaat van de chirurgie in het Clara ziekenhuis. Jij, vol enthousiast over de laparoscopie, wist mij ook hiervoor te enthousiasmeren. Daarbij was het ook weer tijd voor een nieuwe trial met een beestennaam. Dankzij je goede contacten met andere enthousiaste laparoscopisten (veelal oud-Clarianen) kon al vrij snel een multicenter trial gestart worden. Er werden meerdere LAMA avonden georganiseerd, waarbij er goede discussies waren en de studie vorm kreeg. Dat dit het begin was van een lang traject, konden we toen nog niet weten. Mijn overstap naar de plastische chirurgie maakte het er niet makkelijker op, maar ik geloof dat je het me vergeven hebt. Dank voor je steun, af en toe kritische feedback en het vertrouwen in mij.

Prof. Nicolai (2de promotor), beste Jean-Philippe. Ik heb het enorm gewaardeerd dat je vanaf het begin, als plastisch chirurg enthousiast was over een studie over maagperforaties. Ik kreeg alle vrijheid om in Groningen mijn promotie af te maken en er werd zelfs hard meegedacht over de stamp methode en andere toepassingen voor de "postzegel". De basis voor de link tussen het dichtplakken van maagperforaties met een postzegel en oesofageale fistels werd gelegd en klinisch zelfs toegepast. Een onvergetelijk deel van mijn opleiding en een mooie afsluiting was onze reis met Interplast naar India. Het was bijzonder om je opleider in een hele andere setting te zien.

Prof. Robinson, beste Peter, een minder op de voorgrond, maar toch zeker belangrijke rol heb je gespeeld bij het tot stand komen van mijn onderzoek, want zonder jou hadden we het dier experimentele deel niet kunnen uitvoeren.

Graag wil ik de groep mensen bedanken die me geholpen hebben bij het dier-experimentele onderzoek: Hans Bartels, Robert Liem en Geert Kors. Het was een bijzonder leerzame periode, ondanks de nauwgezette en lastige planning maar met mooie resultaten. Jullie hebben me echter nog niet van mijn angst voor ratten kunnen genezen.

Jens, Niels en Hasan uit de onderzoeksgroep van Johan Lange. Dank voor jullie bijdrage en succes met jullie carrières.

Hoe langer een promotietraject duurt, des te belangrijker worden de mensen die je op het juiste moment er weer door heen slepen. Mijn paranimf Wilma heeft het vanaf het prille begin meegemaakt. Bleef me het hele traject motiveren. Paranimf Toon leerde mij kritisch naar het dierexperimentele deel te kijken. Daarnaast hebben ook Carla, Marjoleine, Marc en Roy me geholpen de marathon uit te lopen.

Zonder mijn ouders had ik natuurlijk nooit deze weg kunnen bewandelen. Zij hebben me alle mogelijkheid gegeven om te studeren, 15x te verhuizen en hebben nooit gemopperd omdat ik veel te weinig in Almelo op bezoek kwam. Tijd om het advies van Herman Finkers op te volgen: "Heanig an en rap wat".

