

Circulation

JOURNAL OF THE AMERICAN HEART ASSOCIATION



Two-Year Angiographic and Intravascular Ultrasound Follow-Up After Implantation of Sirolimus-Eluting Stents in Human Coronary Arteries

J. Eduardo Sousa, Marco A. Costa, Amanda G.M.R. Sousa, Alexandre C. Abizaid, Ana C. Seixas, Andrea S. Abizaid, Fausto Feres, Luiz A. Mattos, Robert Falotico, Judith Jaeger, Jeffrey J. Popma and Patrick W. Serruys

Circulation 2003;107:381-383; originally published online Jan 13, 2003;

DOI: 10.1161/01.CIR.0000051720.59095.6D

Circulation is published by the American Heart Association, 7272 Greenville Avenue, Dallas, TX 75214

Copyright © 2003 American Heart Association. All rights reserved. Print ISSN: 0009-7322. Online ISSN: 1524-4539

The online version of this article, along with updated information and services, is located on the World Wide Web at:

<http://circ.ahajournals.org/cgi/content/full/107/3/381>

Subscriptions: Information about subscribing to *Circulation* is online at
<http://circ.ahajournals.org/subscriptions/>

Permissions: Permissions & Rights Desk, Lippincott Williams & Wilkins, 351 West Camden Street, Baltimore, MD 21202-2436. Phone 410-5280-4050. Fax: 410-528-8550. Email:
journalpermissions@lww.com

Reprints: Information about reprints can be found online at
<http://www.lww.com/static/html/reprints.html>

Two-Year Angiographic and Intravascular Ultrasound Follow-Up After Implantation of Sirolimus-Eluting Stents in Human Coronary Arteries

J. Eduardo Sousa, MD, PhD; Marco A. Costa, MD, PhD; Amanda G.M.R. Sousa, MD, PhD; Alexandre C. Abizaid, MD, PhD; Ana C. Seixas, MD; Andrea S. Abizaid, MD; Fausto Feres, MD, PhD; Luiz A. Mattos, MD, PhD; Robert Falotico, PhD; Judith Jaeger, BA; Jeffrey J. Popma, MD; Patrick W. Serruys, MD, PhD

Background—The safety and efficacy of sirolimus-eluting stenting have been demonstrated, but the outcome of patients treated with this novel technology beyond the first year remains unknown. We sought to evaluate the angiographic, intravascular ultrasound (IVUS), and clinical outcomes of patients treated with sirolimus-eluting stents 2 years after implantation.

Methods and Results—This study included 30 patients treated with sirolimus-eluting Bx Velocity stenting (slow release [SR], n=15, and fast release [FR], n=15) in São Paulo, Brazil. Twenty-eight patients underwent 2-year angiographic and IVUS follow-up. No deaths occurred during the study period. In-stent late loss was slightly greater in the FR group (0.28 ± 0.4 mm) than in the SR group (-0.09 ± 0.23 mm, $P=0.007$). No patient had in-stent restenosis. At 2-year follow-up, only 1 patient (FR group) had a 52% diameter stenosis within the lesion segment, which required repeat revascularization. The target-vessel revascularization rate for the entire cohort was 10% (3/30) at 2 years. All other patients had $\leq 35\%$ diameter stenosis. Angiographic lumen loss at the stent edges was also minimal (in-lesion late loss was 0.33 ± 0.42 mm [FR] and 0.13 ± 0.29 mm [SR]). In-stent neointimal hyperplasia volume, as detected by IVUS, remained minimal after 2 years (FR = 9.90 ± 9 mm³ and SR = 10.35 ± 9.3 mm³).

Conclusions—This study demonstrates the safety and efficacy of sirolimus-eluting Bx Velocity stents 2 years after implantation in humans. In-stent lumen dimensions remained essentially unchanged at 2-year follow-up in the 2 groups, although angiographic lumen loss was slightly higher in the FR group. Restenosis “catch-up” was not found in our patient population. (*Circulation*. 2003;107:381-383.)

Key Words: stents ■ angiography ■ ultrasonics ■ restenosis

A new generation of drug-eluting coronary stents designed to limit restenosis has been developed recently. The clinical success of these novel technologies will depend on a complex interaction between stent, coating matrix, drug, and the vessel wall. Stents coated with sirolimus, a natural macrocyclic lactone with immunosuppressive and anti-inflammatory action, represented the first successful attempt to abolish restenosis in human coronary arteries.¹⁻³ A virtual absence of neointimal proliferation was observed 1 year after implantation of sirolimus-eluting Bx Velocity stents in a pilot study.² Subsequently, the RAVEL (a RANdomized comparison of a sirolimus-eluting Bx VELOCITY stent with a standard stent for coronary revascularization) investigators reported an absence of both angiographic restenosis at 6 months and target-lesion revascularization 1 year after the implantation of sirolimus-eluting stents in a multicenter randomized trial.³

Although encouraging, potential late side effects of these drug-eluting coronary stents may pose limitations. Lessons from intracoronary brachytherapy include the development of late thrombosis and neointimal proliferation that may occur beyond the first year after treatment.⁴⁻⁶ In the present study, we evaluated the clinical, angiographic, and intravascular ultrasound (IVUS) outcomes of the first series of patients treated with sirolimus-eluting stents 2 years after the index procedure.

Methods

Study Population

From December 1999 to February 2000, 30 consecutive patients were implanted with a single sirolimus-eluting Bx VELOCITY stent at the Institute Dante Pazzanese of Cardiology, São Paulo, Brazil.

Received September 25, 2002; revision received November 21, 2002; accepted November 25, 2002.

From the Institute Dante Pazzanese of Cardiology (J.E.S., A.G.M.R.S., A.C.A., A.C.S., A.S.A., F.F., L.A.M.), São Paulo, Brazil; University of Florida-Shands (M.A.C.), Jacksonville, Fla; Thoraxcenter (P.W.S.), Dijkzigt University Hospital, Rotterdam, the Netherlands; Cordis (R.F., J.J.), a Johnson & Johnson Company, Warren, NJ; and Brigham and Women's Hospital (J.J.P.), Boston, Mass.

Correspondence to Prof J. Eduardo Sousa, MD, PhD, Director of the Institute Dante Pazzanese of Cardiology, Av. Dr Dante Pazzanese, 500, Ibirapuera, 04012180, São Paulo, Brazil.

© 2003 American Heart Association, Inc.

Circulation is available at <http://www.circulationaha.org>

DOI: 10.1161/01.CIR.0000051720.59095.6D

Fifteen patients received a fast-release (FR) formulation (<15-day drug release), and 15 received a slow-release (SR) formulation (\geq 28-day drug release). All stents were 18 mm long and 3.0 to 3.5 mm in diameter. The stent procedure and drug-elution kinetics have been described previously.^{1,2} Patients received aspirin (325 mg/d, indefinitely) started at least 12 hours before the procedure and a 300-mg loading dose of clopidogrel immediately after stent implantation and then clopidogrel 75 mg/d for 60 days. The Medical Ethics Committee at Institute Dante Pazzanese approved the protocol, and every patient provided informed consent.

Quantitative Measurements

Quantitative coronary angiography and IVUS imaging were performed after bolus infusion of intracoronary nitrates as described previously. IVUS images were acquired by motorized pullback at a constant speed of 0.5 mm/s. Quantitative angiographic and volumetric IVUS analyses were performed by independent core laboratories (Brigham and Women's Hospital, Boston, Mass, and Cardialysis BV, Rotterdam, the Netherlands, respectively). Validation of volumetric IVUS quantification has been described elsewhere.⁷ Two coronary segments were subjected to quantitative angiography: (1) in-stent and (2) in-lesion segments. The in-stent analysis encompassed only the 18-mm-long segment covered by the stent. The in-lesion segment was defined as the stent plus 5 mm proximal and 5 mm distal to the edge or the nearest side branch. In-stent and in-lesion restenosis was defined as \geq 50% diameter stenosis (DS) at follow-up located within the stent and target lesion, respectively. Minimal lumen diameter (MLD) and %DS were measured for each segment. In-lesion and in-stent late lumen loss (LL) were calculated as postprocedure MLD minus 2-year follow-up MLD. LL between 1- and 2-year follow-up was also calculated. Intimal hyperplasia volume was calculated as stent volume minus luminal volume. Percent intimal hyperplasia was defined as intimal hyperplasia volume divided by stent volume.

Statistical Analysis

Continuous variables are expressed as mean \pm SD. Comparisons between postintervention and follow-up measurements were performed with a 2-tailed paired *t* test. Comparisons between groups were performed with an unpaired Student's *t* test. A probability value <0.05 was considered statistically significant.

Results

Both patient groups (FR and SR) had similar baseline characteristics, as reported previously.^{1,2} Angiographic and IVUS imaging were performed in 28 patients at 2-year follow-up. No deaths occurred during the study period. As reported previously,² 1 patient had myocardial infarction secondary to target-vessel occlusion at 14-month follow-up, which precluded further angiographic assessment. Another patient developed pneumonia the week preceding the scheduled 2-year follow-up angiogram, and angiographic assessment was therefore deferred.

The majority of patients (71% in the FR and 85% in the SR group) had <0.5-mm LL (Figure 1) 2 years after stent implantation. Although the average in-lesion LL was not significantly different between the FR (0.33 ± 0.42 mm) and SR (0.13 ± 0.29 mm) groups, in-stent LL was statistically lower in the SR population (-0.09 ± 0.24 versus 0.28 ± 0.41 mm, $P=0.007$). No patient in the SR group had >0.2 mm in-stent LL. In-lesion MLD remained essentially unchanged between 1 and 2 years in the FR group and actually increased in the SR group ($P=0.001$ for MLD at 1 year versus MLD at 2 years; Figure 2). In-lesion and in-stent MLD were greater in the SR group than in the FR group

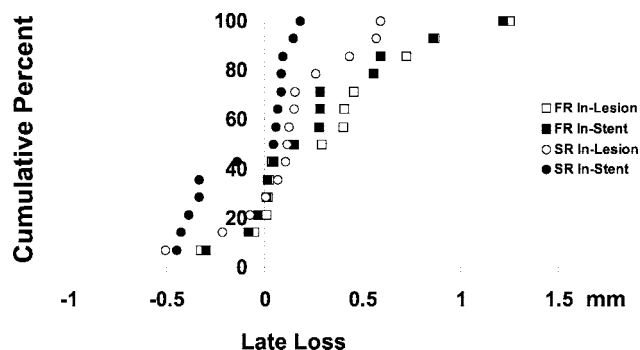


Figure 1. Cumulative distribution curves of in-stent and in-lesion LL in FR and SR groups after 2 years' follow-up.

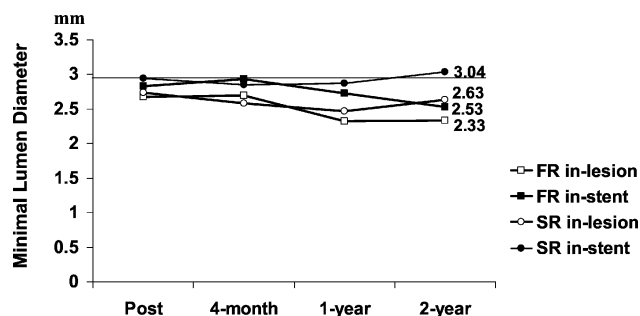
(Figure 2) at 2-year follow-up. Plaque volume by IVUS was 9.90 ± 9 mm³ (FR) and 10.35 ± 9.3 mm³ (SR), whereas the percent intimal hyperplasia along the entire length of the stent was only $6.3\pm 5.5\%$ in the FR group and $7.5\pm 7.3\%$ in the SR group.

No patient had in-stent restenosis (\geq 50% DS). Only 1 patient (FR group) had a 52% DS proximal to the stent. He was successfully treated with the implantation of a sirolimus-eluting stent at 24 months. Another patient developed an ostial lesion in the left circumflex coronary artery and underwent coronary bypass surgery (target-vessel revascularization) 24.5 months after the index procedure. The sirolimus-eluting stent implanted in the midportion of the left circumflex coronary artery was patent, with minimal neointimal proliferation. Two patients underwent percutaneous interventions in vessels other than the target coronary (nontarget-vessel revascularization) after 24 months.

Discussion

The present study demonstrates the long-term safety and efficacy of the sirolimus-eluting stent 2 years after implantation. There were no deaths, and only 1 patient developed in-lesion restenosis by angiography. After 2 years, no patient developed in-stent restenosis, and 90% of patients were free of repeat target-vessel revascularization. Neointimal proliferation remained minimal at 2 years after stent implantation.

Sirolimus acts specifically on the late G1 phase of the cell cycle, unlike ionizing radiation. Because of its early action on



$p=0.053$, in-lesion MLD FR vs. SR
 $p=0.003$, in-stent MLD FR vs. SR

Figure 2. Temporal changes in angiographic in-lesion and in-stent MLD.

the cell cycle, sirolimus may block cellular proliferation without inducing cell death and necrosis, with its potential late vascular sequelae.^{8,9} In addition, sirolimus has been shown to stimulate apoptosis and reduce inflammation.^{10,11} The striking efficacy and safety 2 years after stent implantation in the present study are likely due to these unique cellular effects of sirolimus.

Previous investigations have shown the long-term safety of bare metallic stents.^{12–14} In serial angiographic studies, in-stent lumen diameter was shown to be similar between 6 months and 1 year and even improved slightly 3 years after initial stent implantation.¹² In the present study, similar angiographic findings were observed. However, only minimal lumen reduction was observed in the first 4 months.¹ Furthermore, unlike previous studies, the 2-year lumen diameters of most patients remained virtually unchanged from the initial postimplantation measurements (Figures 1 and 2).^{5,6,15} There was no (early or late) stent malapposition or flow behind the stent struts depicted by IVUS. It remains to be determined whether arterial spasm immediately after the procedure that disappeared at 2-year follow-up explains the increase in MLD observed by quantitative coronary angiography in some patients.

Although both types of drug-eluting stent formulation were safe and effective at 2-year follow-up, the SR stents had a slightly better angiographic outcome than the FR stents. The amount of drug, type of polymer, and size of stents used were identical in the 2 groups. The only differences between the 2 groups were the extra layer of polymer coating in the SR formulation and the drug-release profile of each stent formulation (≥ 28 -day drug release in the SR versus 14 days in the FR formulation). Whether a prolonged drug release confers longer and better antirestenosis protection remains to be determined. Neointimal hyperplasia volume as determined by IVUS was similar between groups. Furthermore, the major studies to date with the sirolimus-eluting stent (eg, the RAVEL and SIRIUS [a multicenter randomized double-blind study of the SIRoImUS-eluting Bx Velocity stent in the treatment of patients with de novo coronary artery lesions] trials) have all used the SR formulation.

Among the patients who underwent 2-year follow-up angiography, 1 patient had a borderline (52% DS) in-lesion stenosis. It is difficult to determine whether this lesion was secondary to restenosis or plaque progression. Regardless of the underlying mechanism, this case may underscore the importance of complete stent coverage of the treated lesion or injured segments when drug-eluting stents are implanted. The protocol in the present study allowed the implantation of only one 18-mm-long stent in each patient, which may have limited our ability to completely cover the entire atherosclerotic plaque in some patients.

In conclusion, the present study demonstrates the 2-year safety and efficacy of sirolimus-eluting stents for inhibiting

restenosis after percutaneous coronary interventions. These long-term angiographic and IVUS results 2 years after the index procedure lend further credence to the recently reported absence of restenosis after 1 year among patients treated with sirolimus-eluting stents in the multicenter randomized RAVEL study.³ Although the vexing problem of restenosis after angioplasty may be largely solved by this new generation of drug-eluting stents, there is clearly a need for new therapies to prevent the progression of atherosclerosis and techniques to identify and treat non-flow-limiting vulnerable plaques.

Acknowledgments

The authors thank Drs Brett Sasseen, Brian Firth, and Dennis Donohoe for their careful review of the manuscript.

References

1. Sousa JE, Costa MA, Abizaid A, et al. Lack of neointimal proliferation after implantation of sirolimus-coated stents in human coronary arteries: a quantitative coronary angiography and three-dimensional intravascular ultrasound study. *Circulation*. 2001;103:192–195.
2. Sousa JE, Costa MA, Abizaid AC, et al. Sustained suppression of neointimal proliferation by sirolimus-eluting stents: one-year angiographic and intravascular ultrasound follow-up. *Circulation*. 2001;104:2007–2011.
3. Morice MC, Serruys PW, Sousa JE, et al. A randomized comparison of a sirolimus-eluting stent with a standard stent for coronary revascularization. *N Engl J Med*. 2002;346:1773–1780.
4. Costa MA, Sabat M, van der Giessen WJ, et al. Late coronary occlusion after intracoronary brachytherapy. *Circulation*. 1999;100:789–792.
5. Teirstein PS, Massullo V, Jani S, et al. Three-year clinical and angiographic follow-up after intracoronary radiation: results of a randomized clinical trial. *Circulation*. 2000;101:360–365.
6. Kay IP, Wardeh AJ, Kozuma K, et al. Radioactive stents delay but do not prevent in-stent neointimal hyperplasia. *Circulation*. 2001;103:14–17.
7. von Birgelen C, de Vrey EA, Mintz GS, et al. ECG-gated three-dimensional intravascular ultrasound: feasibility and reproducibility of the automated analysis of coronary lumen and atherosclerotic plaque dimensions in humans. *Circulation*. 1997;96:2944–2952.
8. Marx SO, Jayaraman T, Go LO, et al. Rapamycin-FKBP inhibits cell cycle regulators of proliferation in vascular smooth muscle cells. *Circ Res*. 1995;76:412–417.
9. Powell JD, Lerner CG, Schwartz RH. Inhibition of cell cycle progression by rapamycin induces T cell clonal anergy even in the presence of costimulation. *J Immunol*. 1999;162:2775–2784.
10. Roque M, Cordon-Cardo C, Fuster V, et al. Modulation of apoptosis, proliferation, and p27 expression in a porcine coronary angioplasty model. *Atherosclerosis*. 2000;153:315–322.
11. Suzuki T, Kopia G, Hayashi S-i, et al. Stent-based delivery of sirolimus reduces neointimal formation in a porcine coronary model. *Circulation*. 2001;104:1188–1193.
12. Kimura T, Yokoi H, Nakagawa Y, et al. Three-year follow-up after implantation of metallic coronary-artery stents. *N Engl J Med*. 1996;334:561–566.
13. Laham RJ, Carrozza JP, Berger C, et al. Long-term (4- to 6-year) outcome of Palmaz-Schatz stenting: paucity of late clinical stent-related problems. *J Am Coll Cardiol*. 1996;28:820–826.
14. Kiemeneij F, Serruys PW, Macaya C, et al. Continued benefit of coronary stenting versus balloon angioplasty: five-year clinical follow-up of Benestent-I trial. *J Am Coll Cardiol*. 2001;37:1598–1603.
15. Liistro F, Stankovic G, Di Mario C, et al. First clinical experience with a paclitaxel derivate-eluting polymer stent system implantation for in-stent restenosis: immediate and long-term clinical and angiographic outcome. *Circulation*. 2002;105:1883–1886.