

01000011 01101000 01100001 01110000  
01110100 01100101 01110010 00100000  
00110010 00101110 00110110 00001010

## Chapter 2.6

The surgical anatomy of the small saphenous vein and adjacent nerves in relation to endovenous thermal ablation.

Kerver, A.L.A., Van Der Ham, A.C., Theeuwes, H.P., Eilers, P.H.C., Poublon, A.R., Kerver, A.J.H., Kleinrensink, G.-J.

J Vasc Surg. 2012 Apr 12.

## ABSTRACT

**Background:** Thermal damage to peripheral nerves is a known complication of endovenous thermal ablation (EVA) of the small saphenous vein (SSV). Therefore, the main objective of this anatomic study was to define a safe zone in the lower leg where EVA of the SSV can be performed safely.

**Methods:** The anatomy of the SSV and adjacent nerves was studied in 20 embalmed human specimens. The absolute distances between the SSV and the sural nerve (SN) (closest/nearest branch) were measured over the complete length of the leg (>120 data points per leg), and the presence of the interlaying deep fascia was mapped. The distance between the SSV and the tibial nerve (TN) and the common peroneal nerve was assessed. A new analysis method, computer-assisted surgical anatomy mapping, was used to visualize the gathered data.

**Results:** The distance between the SSV and the SN was highly variable. In the proximal one-third of the lower leg, the distance between the vein and the nerve was <5 mm in 70% of the legs. In 95%, the deep fascia was present between the SSV and the SN. In the distal two-thirds of the lower leg, the distance between the vein and the nerve was <5 mm in 90% of the legs. The deep fascia was present between both structures in 15%. In 19 legs, the SN partially ran beneath the deep fascia. In the saphenopopliteal region, the average shortest distance between the SSV and the TN was 4.4 mm. In 20%, the distance was <1 mm. The average, shortest distance between the SSV and the common peroneal nerve was 14.2 mm. The distance was <1 mm in one leg.

**Conclusions:** At the saphenopopliteal region, the TN is at risk during EVA. In the distal two-thirds of the lower leg, the SN is at risk for (thermal) damage due to the small distance to the SSV and the absence of the deep fascia between both structures. The proximal one-third of the lower leg is the optimal region for EVA of the SSV to avoid nerve damage; the fascia between the SSV and the SN is a natural barrier in this region that could preclude (thermal) damage to the nerve.

## INTRODUCTION

### Clinical Relevance

Iatrogenic damage to peripheral nerves is a known, incapacitating complication of endovenous thermal ablation (EVA) of the small saphenous vein (SSV). Although EVA is quickly replacing conventional surgery as the treatment of choice for saphenous ablation, no consensus has been reached regarding the surgical landmarks for a safe EVA of the SSV. This study describes and visualizes the anatomic limits in relation to the sural nerve and deep crural fascia, the tibial nerve, and the common peroneal nerve using a new anatomy mapping tool, computer-assisted surgical anatomy mapping. The results offer the surgeon a better understanding of the complex anatomy of the SSV and thereby provide surgical guidelines to reduce complications of EVA of the SSV.

### General introduction

Thermal damage to peripheral nerves is a known complication of endovenous thermal ablation (EVA) of the small saphenous vein (SSV). Therefore, the main objective of this anatomic study is defining a safe zone in the lower leg where EVA of the SSV can be performed safely. Although surgical stripping is still considered the gold standard for saphenous vein ablation,<sup>1</sup> EVA, such as endovenous laser therapy and radiofrequency ablation, has become a more recognized alternative in common practice.<sup>1,2</sup> Therefore, the need for thorough research on complications, recurrence rates, and relevant anatomy becomes greater. Many publications have established the role of EVA for ablation of the great saphenous vein,<sup>3-5</sup> but studies on EVA of the SSV are still scarce. Short-term and midterm results are promising and show low recurrence rates and fewer complications with EVA than with conventional surgery.<sup>6-9</sup> Nevertheless, no consensus has been reached regarding the surgical anatomic landmarks for a safe approach of the SSV.

Many complications of surgical stripping of the SSV have been described, along with damage to the sural nerve (SN), the tibial nerve (TN), and the common peroneal nerve (CPN).<sup>10,11</sup> The anatomic course of these nerves is important because of new, extra risks caused by EVA coagulation temperatures and the insertion of a needle when injecting tumescent anesthesia around the vein.

The SSV mainly runs a course between the superficial (saphenous) and the deep crural (muscular) fascia of the lower leg.<sup>12</sup> The proximal part of the SN, however, courses under the deep fascia; therefore, it could well function as a natural barrier to prevent the SN from excessive heat during EVA. The deep fascia could also prove to be a good barrier between the nerve and vein during

the injection of tumescent anesthesia. The fluid being entrapped within the fascial “tube” could perform its function longer. Consequently, the main question to be answered is: Is there an anatomic zone in the leg where EVA of the SSV can be performed safely?

## METHODS

### Materials

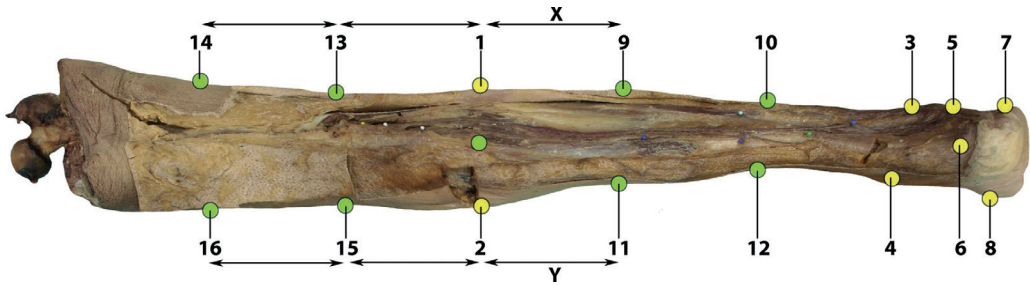
This study used 20 legs (nine left, 11 right) from 20 embalmed human bodies. The bodies were embalmed at room temperature and perfused at low pressure with a mixture of 6% formaldehyde and 5% phenol to minimize shrinkage. None of the limbs demonstrated shrinkage artefacts, (external) macroscopic signs of venous disease, or scarring. The SN and the SSV were dissected. Measurements were taken using flexible scale bars. Owing to postmortem rigidity and fixation in 19 legs, the Achilles tendon was cut to flex the ankle 90°.

### Computer-Assisted Surgical Anatomy Mapping (CASAM)

Computer-assisted surgical anatomy mapping (CASAM) is a new anatomic method developed by two of the authors (A.K., G.K.) to map and visualize surgical anatomic details relevant for safe surgical approaches.<sup>13</sup> All dissected legs were photographed using a Canon 350D with a Canon EF-S (Canon USA, Inc, San Jose, Calif) 18- to 55-mm lens. The camera was positioned perpendicular to the leg at a distance of 95 cm. Landmarks 1 and 3 were used to horizontally position each leg in line with the camera, and landmark 9 was used to center each leg (Figure 1). Each picture was then processed using the CASAM method, which consists of three phases.

- 1 Magic Morph 1.9510 software<sup>14</sup> was used to define the shape and size of each leg using landmarks (Figure 1), followed by a calculation of the average shape and size of all legs.
- 2 The 20 legs in all 20 pictures were warped (reshaped) to exactly match the shape and size of the created and calculated average leg. As a result, all 20 legs in all 20 pictures now had the exact same shape and size. Magic Morph uses a thin plate spline transformation as a warping algorithm.<sup>14</sup>

- 3 Photoshop CS-4 (Adobe Inc, San Jose, Calif)<sup>15</sup> was used to compile all warped pictures in one image, renditions of which were generated to highlight the relevant anatomic structures and landmarks. No measurements were made using Photoshop CS-4.



**Figure 1.** Bony and nonbony landmarks used for computer-assisted surgical anatomy mapping (CASAM). Bony ultrasound landmarks commonly used in endovenous thermal ablation (EVA) of the small saphenous vein (SSV): the tibia plateau (1) and (2) and the lateral malleolus (3) and (5). Yellow: bony landmarks; the most lateral (1) and most medial (2) part of the tibia plateau, the proximal (3) and distal (5) border of the lateral malleolus, the proximal border of the medial malleolus (4), the insertion of the Achilles tendon (6), the tuberosity of the fifth metatarsal (7), and the tuberosity of the first metatarsal (8). Green: nonbony landmarks, halfway between landmarks 1 and 2, at one-third (9) and two-thirds (10) between landmarks 1 and 3, and at one-third (11) and two-thirds (12) between landmarks 2 and 4. Distance X was used to create the upper lateral landmarks (13, 14). Distance Y was used to create the upper medial landmarks (15, 16). Distance X = one-third of the distance between landmark 1 and 3. Distance Y = one-third of the distance between landmark 2 and 4.

## General Assessments

The distance between the tibia plateau and the proximal lateral malleolus was measured to define the length of each lower leg. Bony landmarks were used as reference points for intrinsic measurements and the CASAM assessment (Figures 1 and 2). To map the relevant anatomy with CASAM, eight nonbony or soft tissue landmarks were created in addition to the bony landmarks (Figure 1).

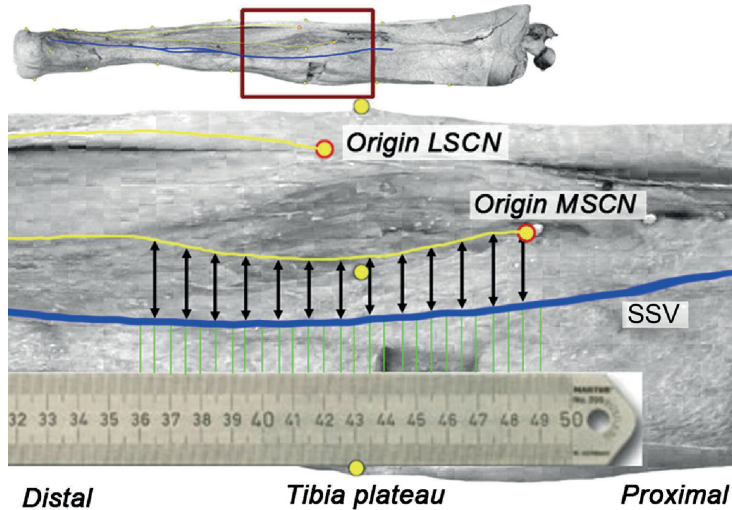
## Basic Anatomy

**SSV:** CASAM was used to map and warp the course of each individual SSV. The courses of the 20 SSVs were compiled into one area of distribution. The most distal saphenopopliteal junction (SPJ) in each leg was identified and marked. The area in which each SSV ran above the superficial fascia was colored blue with 5% opacity. The following distances were manually measured in each specimen:

- 1 The length of the SSV from its most distal SPJ to the proximal tip of the lateral malleolus.

- 2 The most distal SPJ to the nearest part of the dermis (depth of the SPJ).
- 3 The distances from the tibia plateau to the most distal SPJ, the entrance of the SSV into the superficial fascia, and the entrance of the SSV into the deep fascia.

**SN:** CASAM was used to map and warp the course of each individual SN. Each SN was categorized, and the medial sural cutaneous nerve (MSCN), the lateral sural cutaneous nerve (LSCN), and combined sural nerve (CSN) were identified. The courses of the 20 SNs were compiled into one area of distribution. The area in which each SN ran under the deep fascia was colored green with 5% opacity. The distances from the tibia plateau to the entrance of the SN into the superficial fascia and into the deep fascia were manually measured in each specimen.



**Figure 2.** Measurements.

Yellow line: lateral and medial sural cutaneous nerve sural nerve (LSCN, MSCN). Blue line: small saphenous vein (SSV). Black arrows: measurements taken with a 5-mm interval from the most distal saphenopopliteal junction (SPJ) to the most proximal part of the lateral malleolus: the absolute distance between the SSV and the closest branch of the sural nerve (MSCN, LSCN, or combined sural nerve [CSN]); the presence of a fascia layer between the SSV and the SN.

### Relative anatomy

**SSV in relation to the SN and deep crural fascia:** The areas of distribution of the SSV and the SN were overlaid and compared using CASAM. The following

manual measurements were performed with a 5-mm interval from the most distal SPJ to the most proximal part of the lateral malleolus (Figure 2):

- 1 The absolute distance between the SSV and the SN (MSCN, LSCN, CSN).
- 2 The presence of a fascia layer between the SSV and the SN.

**SSV in relation to the TN:** The distance between the SSV to the nearest point on the TN was measured, and the presence of a fascia layer between both structures was noted.

**SSV in relation to the CPN:** The distance between the SSV to the nearest point on the CPN was measured.

## RESULTS

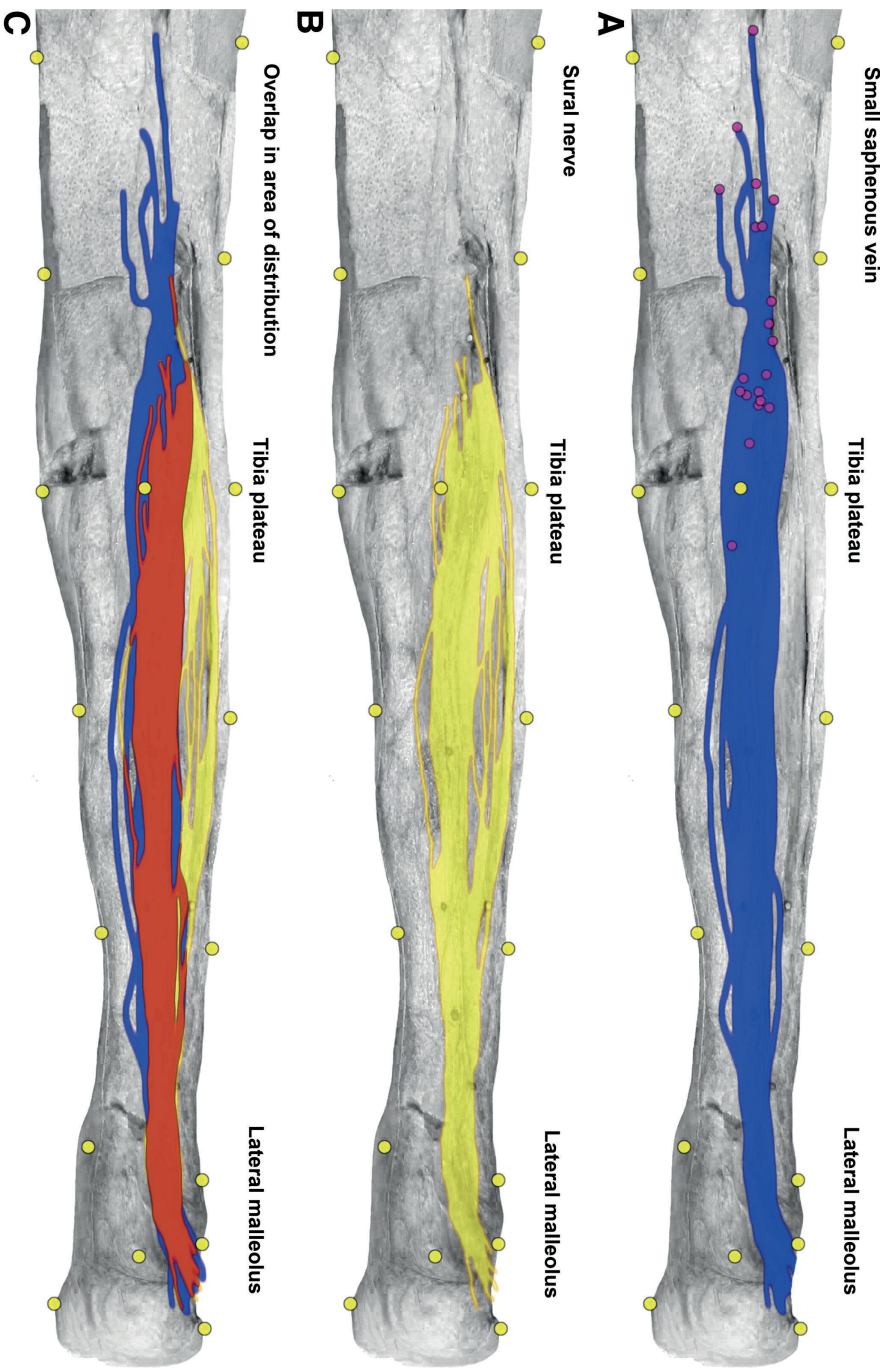
The mean distance between the tibia plateau and the most proximal part of the lateral malleolus was 404.2 mm (range, 345-471 mm).

### Basic Anatomy

**SSV:** The course of the SSV is highly variable (Figure 3, A). The area of distribution is therefore large. It is mainly located in the axial part of the calf and runs a course just lateral to the Achilles tendon. Near the lateral malleolus, it curves toward the lateral side of the foot. The most distal SPJ is also highly variable (Figure 3, A) and, on average, located at 92 mm (range, 18-248 mm) proximal of the tibia plateau. In one leg, the most distal SPJ is situated distal (-18 mm) to the tibia plateau. The depth of the SPJ in relation to the upper part of the skin is 34.1 mm (range, 15-67 mm).

The SSV penetrates the superficial fascia in all 20 legs. The SSV runs under the superficial fascia until 330 mm distal from the tibia plateau (range, 254-404 mm distal from the tibia plateau) (Figure 4, A). In two specimens, the SSVs penetrate the deep fascia layer, respectively, at 91 and 105 mm proximal to the tibia plateau.

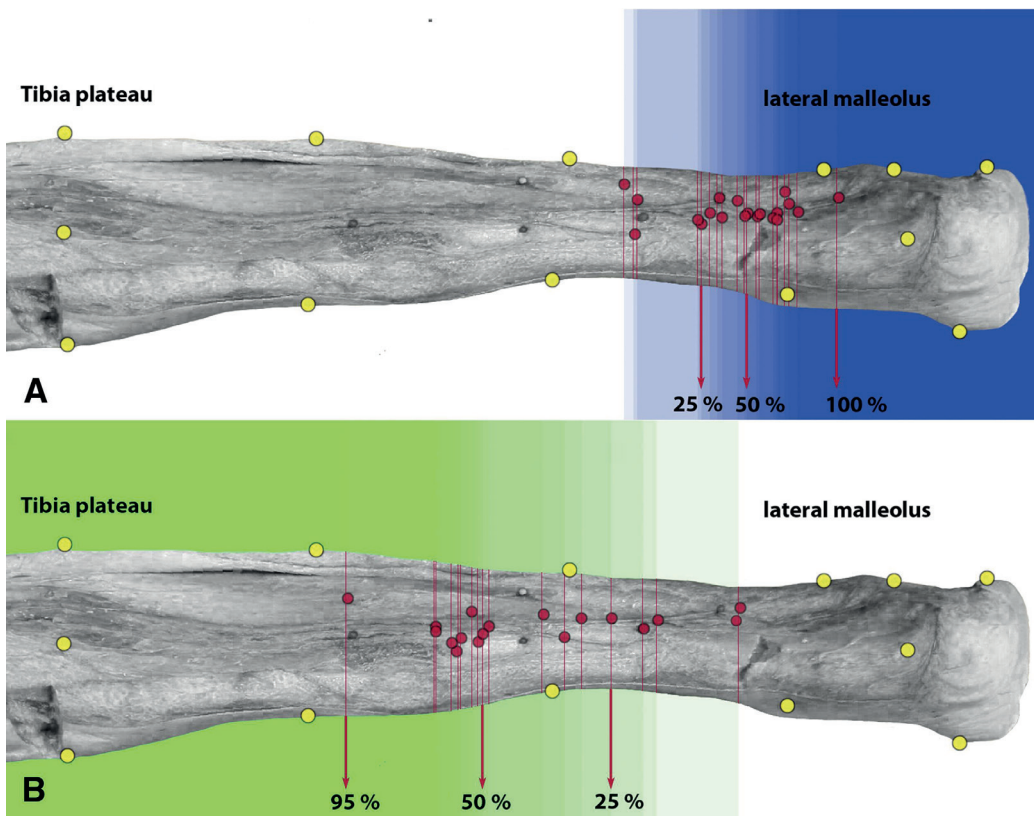
**SN:** The course of the SN is highly variable (Figure 3, B) and has a large area of distribution located both in the middle part of the calf (mainly the MSCN) as well as in the lateral part of the calf (mainly the LSCN). Although the anatomy is highly variable, the SN in most cases consists of two branches: the MSCN and the LSCN. The MSCN originates from the TN and the LSCN originates from the CPN. Both branches conjoin in the calf to form the CSN. In seven specimens, the



**Figure 3.** Areas of distribution for the (A) small saphenous vein (SSV), (B) sural nerve (SN), and (C) overlap in area of distribution shown on a computer-assisted surgical anatomy mapping (CASAM)-generated image depicting an average leg in which the SSV and the SN of all 20 legs were warped. Yellow dots: landmarks used for CASAM. A, Purple dots: most distal saphenopopliteal junction (SPJ) of each specimen. Blue: area of distribution of the SSV. Yellow: area of distribution of the SN. Orange: overlap between both distribution areas.

branches never join and each either runs a highly variable course to the lateral side of the foot ( $n = 5$ ) or the MSCN or the LSCN have not been formed ( $n = 2$ ).

The SN penetrates the superficial fascia in all 20 legs at the same point as the SSV (Figure 4, A), 331 mm distal from the tibia plateau (range, 254-404 mm). In 19 legs (95%), the SN partially runs under the deep fascia (Figure 4, B), 233 mm distal from the tibia plateau (range, 139-399 mm; Figure 5). In one specific leg without a fascia layer between the SSV and the SN, only an LSCN and no MSCN are present. The distance between the SSV and LSCN is  $>5$  mm until a point 220 mm distal from the tibia plateau.



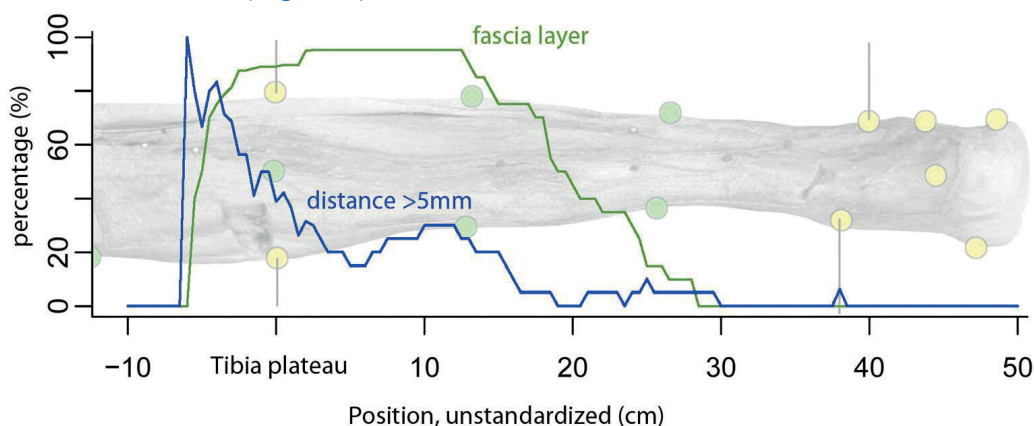
**Figure 4.** Small saphenous vein (SSV) and sural nerve (SN) are shown in relation to the fascia layers, with computer-assisted surgical anatomy mapping (CASAM)-generated image depicting an average leg in which relevant areas regarding the deep (crural) and superficial fascia (of all 20 legs) were warped. **A**, Area in which both the SSV and SN run superficial. **B**, Area in which the SN runs beneath the deep (crural) fascia. Yellow dots: landmarks used for CASAM. Blue area: progressive percentage of legs in which both the SSV and SN run superficial. Green area: digressive percentage of legs in which the SN runs beneath the deep crural fascia.

## Relative Anatomy

**SSV in relation to the SN:** The areas of distribution of the SSV and the SN show much overlap: 63% of the distribution area of the SSV is covered by the distribution area of the SN (Figure 3, C). Up to 71% of the SN distribution area is covered by the distribution area of the SSV. Most LSCN trunks, however, have no overlap with any of the variations of the SSV, whereas almost all MSCN trunks show overlap with multiple SSV variations. The manually measured distance between the SSV and the closest part of the SN ranges from 19 to <1 mm (Figure 5).

At the level of the tibia plateau, the distance between the SSV and the closest trunk of the SN is <5 mm in 60% of the legs. At 100 mm distal of the tibia plateau, the distance between the SSV and the SN is <5 mm in 70% of the legs. From 200 mm distal of the tibia plateau to the lateral malleolus, the distance between the SSV and the SN is <5 mm in all legs (Figure 5).

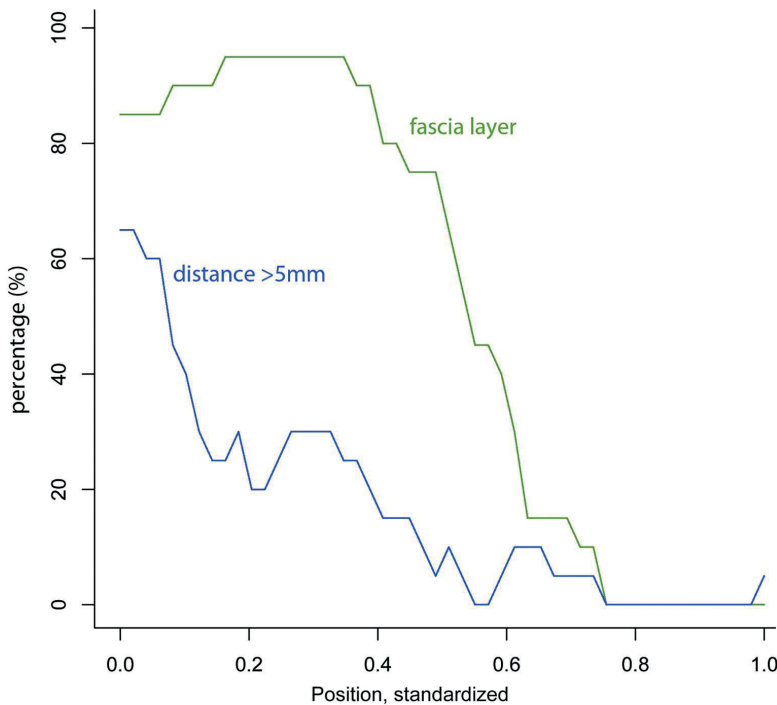
All measurements have also been corrected for the length of the SSV (measured from the most distal SPJ to the most proximal part of the lateral malleolus). At the SPJ in 35% of the legs, the distance between the SSV and the closest trunk of the SN is <5 mm. At the proximal one-third of the length of the SSV in 65% of the legs, the distance between the SSV and the SN is <5 mm. At the distal two-third of the length of the SSV in 85% of the legs, the distance between the SSV and the SN is <5 mm. At the lateral malleolus, the distance between the SSV and the SN is <5 mm in 95% (Figure 6).



**Figure 5.** Standardized distance between small saphenous vein (SSV) and sural nerve (SN) and interlying fascia. X axis: 0.0 = start measurements, 1.0 = stop measurements (proximal part of the lateral malleolus) standardized for the length of the SSV. Y axis: percentage of legs; blue line: percentage of legs in which the distance between the SSV and the SN is more than 5 mm; green line: percentage of legs with a fascia present between the SSV and the SN.

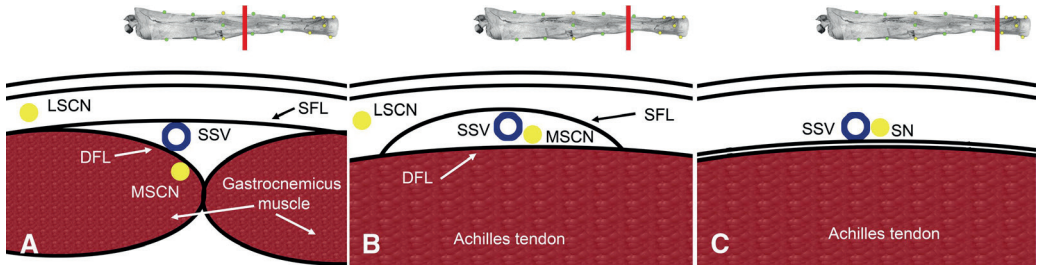
**SSV and SN in relation to the deep crural fascia:** At the level of the tibia plateau in 90% of the legs, a fascia layer is present between the SSV and the closest part of the SN. At 100 mm distal to the tibia plateau, a fascia layer between the SSV and the closest part of the SN is present in 95% of the legs. At 200 mm distal to the tibia plateau, a fascia layer between the SSV and the SN is present in 50% of the legs. From 300 mm distal of the tibia plateau to the lateral malleolus, a fascia layer between the SSV and the SN is present in 0% of the legs (Figure 5).

All measurements have been corrected for the length of the SSV. At the SPJ in 85% of the legs, a fascia layer is present between the SSV and the SN. At the proximal one-third of the length of the SSV in 95% of the legs, a fascia layer is present between the SSV and the SN. In the distal two-third of the length of the SSV in 15% of the legs, a fascia layer is present between the SSV and the SN. At the lateral malleolus in none of the legs, a fascia is present between the SSV and the SN (Figure 6).



**Figure 6.** Distance between the small saphenous vein (SSV) and sural nerve (SN) and the interlaying fascia. The X axis: 10 = 100 mm proximal to the tibia plateau, 0.0 = tibia plateau, and 50 = 500 mm distal from the tibial plateau. Y axis: percentage of legs. Blue line: percentage of legs in which the distance between the SSV and the SN is >5 mm. Green line: percentage of legs with a fascia present between the SSV and the SN.

To summarize the data schematically: in the proximal part of the lower leg, the SSV runs an interfascial course, whereas the SN (mainly the MSCN) runs a course under the deep crural fascia and above the gastrocnemius muscle (Figure 7,A). More distal, the SN penetrates the deep crural fascia and the SSV and SN both run an interfascial course between the superficial and deep fascia (Figure 7, B). In the distal part of the lower leg, the SSV and the SN have penetrated the superficial fascia and run a superficial course above the superficial fascia (Figure 7, C).



**Figure 7.** Schematic transverse drawing of the general course of the small saphenous vein (SSV) and the sural nerve (SN) in relation to the fascia layers. **A**, Proximal part of the lower leg until the saphenopopliteal junction (SPJ). The SSV runs an interfascial course. The medial sural cutaneous nerve (MSCN) runs under the deep fascia layer (DFL) above the medial or lateral gastrocnemius muscle. The lateral sural cutaneous nerve (LSCN) runs a superficial course. **B**, The SSV and the MSCN both run an interfascial course under the superficial fascia layer (SFL) and above the DFL. The LSCN runs a superficial course. **C**, In the distal part of the lower leg, the SSV and the SN both run a superficial course.

**SSV in relation to the TN:** The average distance between the SSV and the TN is 4.4 mm (range, 1-12 mm). In 55% of the legs, the distance between the SSV and the TN is <5 mm, and in 20%, it was even  $\leq 1$  mm (Figure 8). In 85% of the legs, a clear and thick epineurium is present around the TN; however, no clearly visible epineurium is observed in 15%.

**SSV in relation to the CPN:** The average distance between the SSV and the CPN is 14.3 mm (range, 1-26 mm) as measured in 19 legs. In three legs, the distance between the SSV and the CPN was <5 mm.

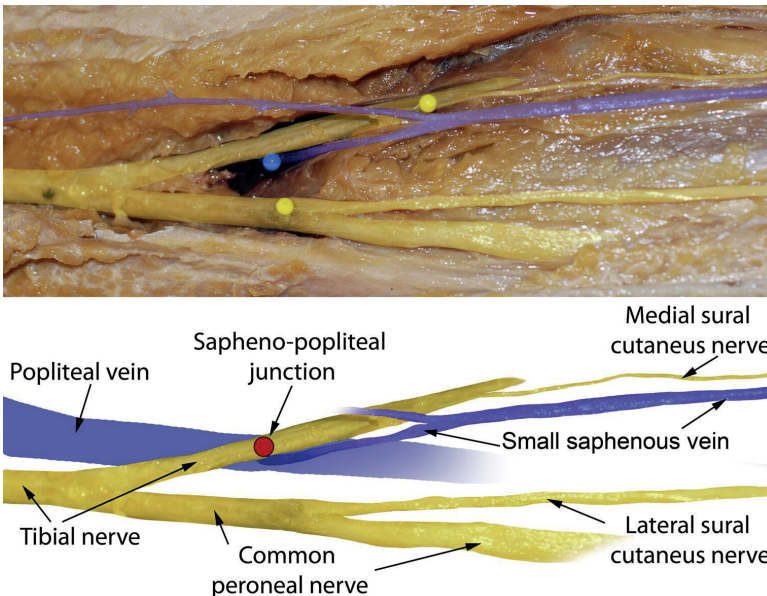
## DISCUSSION

The purpose of this study is to clearly define and describe the three-dimensional relation between the SSV and surrounding nerves in order to define a zone in which EVA can be performed safely.

**Regarding the SN:** Three variables are prominent in our data: the distance between the SSV and the SN, the presence of a fascia between the SSV, and the SN, and the highly variable SPJ.

**1** The distance between the SSV and the closest part of the SN is highly variable.

**2** The presence of a fascia between the SSV and the SN is less variable. In 95% of the legs, a fascia between the SN and the SSV is present in a zone from the tibia plateau until a point 130 mm distal to the tibia plateau. In one leg, no fascia is present between the SSV and the SN, but in this case, no MSCN is present (only an LSCN, which was located far more than 5 mm laterally from the SSV). Proximal to the tibia plateau, the percentage of legs that have a deep fascia between the SSV and the SN drops from 90% to 0%, but the percentage of legs



**Figure 8.** An original photograph was enhanced with Photoshop CS-4 to highlight the relevant anatomy of the saphenopopliteal fossa. The small saphenous vein (SSV) actually curls under the tibial nerve (TN) to conjoin in the popliteal vein.

that have a distance between the SSV and the SN of  $>5$  mm increases from 50% to 100% (Figures 5 and 6). This suggests that although a fascia layer is not always present between the SSV and the SN, the area proximal to the tibia plateau is still relatively “safe” for EVA.

When these measurements are combined, the new safe zone for EVA of the SSV can be defined as a zone in which:

- Either the distance between the SSV and surrounding nerves is such that it is safe to use heat-generating therapy,
- Or a fascia layer is present between the SSV and the SN.

**3** Because the location of the SPJ shows no correlation with the tibia plateau, all measurements are corrected for the length of the SSV instead of the length of the lower leg. Defining a safe zone proves to be more reliable when the most distal SPJ is used as a defining landmark rather than the tibia plateau (Figures 5 and 6).

**Regarding the deep fascia and the use of tumescent anesthesia:** Local tumescent anesthesia is known to protect surrounding tissue from high coagulation temperatures.<sup>16</sup> When the distance between the SSV and SN is  $<1$  mm, the SN runs immediately next to or partly under the SSV. Insertion of tumescent anesthesia exactly between the SSV and the SN might therefore be difficult, if not impossible. Because the deep fascia layer is a natural barrier between the SSV and the SN, it can be seen as a very effective separation between the SSV and the SN.

**Regarding the TN and the CPN:** Surprisingly, the distance between the SSV and the TN is extremely small. Because permanent TN damage after EVA has not been reported, we can only assume that the fascia between the SSV and the TN or the admission of tumescent anesthesia provides enough protection against high coagulation temperatures. However, the SSV was observed to curl around the TN to conjoin with the popliteal vein, as described by Tuveri M et al,<sup>17</sup> thereby making it impossible to completely surround the SSV with tumescent anesthesia. Also, the CPN runs surprisingly close to the SSV. These data suggest that extra care should be taken when performing EVA at the saphenopopliteal area.

The risk of damaging the TN and CPN might be reduced by placing the catheter tip at the portion of the SSV where it begins its dive into the popliteal fossa. During dissection, however, it was observed that at this point, especially in

thinner legs, the TN could still be close to the SSV. Also, in SSVs that had a more lateral course, the shortest distance between the SSV and the CPN was measured just distal from its dive into the popliteal fossa. Finally, this would also leave important tributaries near the SPJ untreated, and consequently, recurrence rates might rise. In our opinion, special emphasis must instead be placed on prudent tumescent anesthesia (cooling) near the SPJ.

**Comparison of data with known literature and future research:** In the literature, the SSV is also not considered to be a superficial vein.<sup>18-22</sup> However, we found that the dissected SSV penetrated the superficial fascia in the distal part of the lower leg; this contrasts with the findings of Caggiati et al<sup>18</sup> and Cavezzi et al<sup>20</sup> and is in accordance to the findings of Schweighofer et al.<sup>21</sup> Caggiati<sup>23</sup> argued that this might be due to the use of embalmed specimen. The wide variability of the course of the SSV and the location of the SPJ has been well described.<sup>18-22</sup> In accordance with the literature,<sup>21, 22</sup> multiple SPJs per specimen were observed in 20% of the specimens, and the SPJ was not the end of the SSV in most cases.

The relation between the SSV and the SN has been mentioned<sup>2, 18, 21</sup> as well as the presence of the deep fascia layer<sup>18, 22</sup> but neither had been quantified. The proximity of the SSV to the CPN<sup>2</sup> and the TN<sup>18, 21, 22</sup> was mentioned but as yet has also not clearly been quantified. The proximity of the SSV to surrounding nerves may have its origin in embryology, as the genesis of the SSV is induced by angioguiding nerves of the embryo.<sup>22</sup>

The use of the suggested safe zones in the clinic could increase the recurrence rate of EVA because this would necessarily leave many tributaries untreated. Therefore, presently a more detailed study is being performed on the anatomy of the SSV regarding the SPJ, tributaries, and duplications. Consequently, the traditional open surgical ligation should still be considered as the gold standard for SSV ablation.<sup>1</sup>

**Regarding CASAM:** Because the CASAM method relies on image adjustments and computer calculations, it is not 100% accurate. However, the CASAM method proved to be a great asset to visualize the complex anatomy and can be used in addition to conventional means of documenting anatomic data for surgical purposes. Furthermore, data acquired with CASAM were comparable to data gathered in a conventional way.

## CONCLUSION

To define a safe zone for EVA of the SSV, the distance between the SSV and surrounding nerves as well as the presence of a fascia layer between the SSV and SN should be taken into account. Defining a safe zone proves to be more reliable when the most distal SPJ is used as a reference point rather than the tibia plateau.

The distal two-third of the SSV is a dangerous zone for EVA: the distance between the SSV and the SN is  $\leq 1$  mm in many legs, and no fascia layer is present between the SSV and the SN. The proximal one-third of the SSV is the best zone for EVA; the deep fascia layer between the SSV and the SN provides a natural barrier.

The region around the SPJ should be handled with extra care, because of many variations and the proximity to the TN and the CPN, it is a dangerous location for EVA of the SSV.

A protocol, based on these results would then be:

- 1 Locate the most distal SPJ (duplex scan).
- 2 Measure the distance to the lateral malleolus.
- 3 Introduce ablation device only in the proximal one-third of the latter distance. Take extra care in the saphenopopliteal area or follow the superficial part of the SSV instead of coagulating until the SPJ.

## ACKNOWLEDGEMENTS

We acknowledge the work of Jorn de Vlieger who also contributed to this research. We also thank Yvonne Steinvoot for embalming and looking after the specimens used in this study.

## REFERENCES

- 1) Enzler, M.A., van den Bos, R.R. A New Gold Standard for Varicose Vein Treatment? (2010) *European Journal of Vascular and Endovascular Surgery*, 39 (1), pp. 97-98.
- 2) McBride, K.D. Changing to endovenous treatment for varicose veins: How much more evidence is needed (2011) *Surgeon*, 9 (3), pp. 150-159.
- 3) Nordon, I.M., Hinchliffe, R.J., Brar, R., Moxey, P., Black, S.A., Thompson, M.M., Loftus, I.M. A prospective double-blind randomized controlled trial of radiofrequency versus laser treatment of the great saphenous vein in patients with varicose veins (2011) *Annals of Surgery*, 254 (6), pp. 876-881.
- 4) Nesbitt, C., Eiffel, R.K., Coyne, P., Badri, H., Bhattacharya, V., Stansby, G. Endovenous ablation (radiofrequency and laser) and foam sclerotherapy versus conventional surgery for great saphenous vein varices (2011) *Cochrane Database Syst Rev*, 10 (10), pp. CD005624.
- 5) Rasmussen, L.H., Lawaetz, M., Bjoern, L., Vennits, B., Blemings, A., Eklof, B. Randomized clinical trial comparing endovenous laser ablation, radiofrequency ablation, foam sclerotherapy and surgical stripping for great saphenous varicose veins (2011) *British Journal of Surgery*, 98 (8), pp. 1079-1087.
- 6) Kontothanassis, D., Di Mitri, R., Ferrari Ruffino, S., Zambrini, E., Camporese, G., Gerard, J.L., Labropoulos, N. Endovenous laser treatment of the small saphenous vein (2009) *Journal of Vascular Surgery*, 49 (4), pp. 973-979.e1.
- 7) Park, S.J., Yim, S.B., Cha, D.W., Kim, S.C., Lee, S.H. Endovenous laser treatment of the small saphenous vein with a 980-nm diode laser: Early results (2008) *Dermatologic Surgery*, 34 (4), pp. 517-524.
- 8) Agus, G.B., Mancini, S., Magi, G., Santuari, D., Mondani, P., Brambilla, S., Mancini, S., Botta, G., Spartera, C., Mastromarino, A., Magi, G., Antonelli, P., Nardoiani, V., D'Amico, D., Kontothanassis, D., Scuro, A., Spreafico, G., Baccaglini, U., Salfi, R., Monaca, V., Vinciguerra, D., Amicucci, G., De Donato, G., Plati, S., Farina, M., Pignatelli, F. The first 1000 cases of Italian Endovenous-laser Working Group (IEWG). Rationale, and long-term outcomes for the 1999-2003 period (2006) *International Angiology*, 25 (2), pp. 209-215.
- 9) Gibson, K.D., Ferris, B.L., Pepper, D. Endovenous Laser Treatment of Varicose Veins (2007) *Surgical Clinics of North America*, 87 (5), pp. 1253-1265.
- 10) Atkin, G.K., Round, T., Vattipally, V.R., Das, S.K. Common peroneal nerve injury as a complication of short saphenous vein surgery (2007) *Phlebology*, 22 (1), pp. 3-7.

- 11) Van Groenendaal, L., Flinkenflögel, L., Van Der Vliet, J.A., Roovers, E.A., Van Sterkenburg, S.M.M., Reijnen, M.M.P.J. Conventional surgery and endovenous laser ablation of recurrent varicose veins of the small saphenous vein: A retrospective clinical comparison and assessment of patient satisfaction (2010) *Phlebology*, 25 (3), pp. 151-157.
- 12) Caggiati, A., Bergan, J.J., Gloviczki, P., Jantet, G., Wendell-Smith, C.P., Partsch, H. Nomenclature of the veins of the lower limbs: An international interdisciplinary consensus statement (2002) *Journal of Vascular Surgery*, 36 (2), pp. 416-422.
- 13) Kerver, A.L.A., Kleinrensink, G.J., Smit, N.N., Rabbelier, S., Sedee, B.M.W., Botha, C.P. Web-based 'computer assisted surgical anatomy mapping' (2010) *Proceedings from the Webist 2010: Sixth International Conference on Web Information Systems and Technologies*.
- 14) EffectMatrix Software Studio Magic Morph 1.95. <http://www.effectmatrix.com/morphing/>
- 15) Adobe Photoshop CS5. Cited 3 times. <http://www.adobe.com/nl/products/photoshop/photoshop/>
- 16) Beale, R.J., Mavor, A.I.D., Gough, M.J. Heat dissipation during endovenous laser treatment of varicose veins - Is there a risk of nerve injury? (2006) *Phlebology*, 21 (1), pp. 32-35.
- 17) Tuveri, M., Borsezio, V., Argiolas, R., Medas, F., Tuveri, A. Ultrasonographic venous anatomy at the popliteal fossa in relation to tibial nerve course in normal and varicose limbs. (2009) *Chirurgia italiana*, 61 (2), pp. 171-177.
- 18) Caggiati, A. Fascial relationships of the short saphenous vein (2001) *Journal of Vascular Surgery*, 34 (2), pp. 241-246.
- 19) Warwick, R., Williams, P.L. (1973) *Gray's Anatomy*, p. 705.
- 20) Cavezzi, A., Labropoulos, N., Partsch, H., Ricci, S., Caggiati, A., Myers, K., Nicolaides, A., Smith, P.C. Duplex ultrasound investigation of the veins in chronic venous disease of the lower limbs - UIP consensus document. Part II. Anatomy (2006) *European Journal of Vascular and Endovascular Surgery*, 31 (3), pp. 288-299.
- 21) Schweighofer, G., Mühlberger, D., Brenner, E. The anatomy of the small saphenous vein: Fascial and neural relations, saphenofemoral junction, and valves (2010) *Journal of Vascular Surgery*, 51 (4), pp. 982-989.
- 22) Uhl, J.-F., Gillot, C. Embryology and three-dimensional anatomy of the superficial venous system of the lower limbs (2007) *Phlebology*, 22 (5), pp. 194-206.
- 23) Caggiati, A. Regarding "the anatomy of the small saphenous vein: Fascial and neural relations, saphenofemoral junction, and valves" (2010) *Journal of Vascular Surgery*, 52 (5), pp. 1428-1429.



