

# Clinical Characteristics and Management of Coronary Artery Perforations: A Single-Center 11-Year Experience and Practical Overview

Miguel E. Lemmert, MD, PhD; Rutger J. van Bommel, MD, PhD; Roberto Diletti, MD, PhD; Jeroen M. Wilschut, MD; Peter P. de Jaegere, MD, PhD; F. Zijlstra, MD, PhD; Joost Daemen, MD, PhD; Nicolas M. Van Mieghem, MD, PhD

**Background**—Coronary artery perforation (CAP) is a potentially lethal complication of percutaneous coronary intervention. We report on the incidence, clinical characteristics, and management of iatrogenic coronary perforations based on an 11-year single-center experience.

**Methods and Results**—From February 9, 2005, through November 20, 2016, 150 CAP cases were identified from our percutaneous coronary intervention database of 21 212 procedures (0.71%). Mean age of CAP patients was  $66 \pm 11$  years, and 62.7% were male. Treated lesion type was B2/C in 94.6%, and 31.3% were chronic total occlusions. Nonworkhorse guidewires were applied in 74.3%. CAP types were Ellis type I in 2.9%, Ellis type II in 40.4%, Ellis type III in 54.8%, and Ellis type III cavity spilling in 1.9%. CAP treatment was conservative (including prolonged balloon inflation) in 73.3%. Covered stents, coiling, and fat embolization were used in 24.0%, 0.7%, and 2.0%, respectively. Pericardiocentesis for tamponade was required for 72 patients (48.0%), of whom 28 were initially unrecognized. Twelve patients (12.7%) required emergency cardiac surgery to alleviate tamponade. Periprocedural myocardial infarction occurred in 34.0%, and in-hospital all-cause mortality was 8.0%. All-cause mortality accrued to 10.7% at 30 days and 17.8% at 1 year.

**Conclusions**—CAP is a rare complication of percutaneous coronary intervention, but morbidity and mortality are considerable. Early recognition and adequate management are of paramount importance. (*J Am Heart Assoc.* 2017;6:e007049. DOI: 10.1161/JAHA.117.007049.)

**Key Words:** complication • coronary perforation • coronary repair • percutaneous coronary intervention • pericardiocentesis

Iatrogenic coronary artery perforation (CAP) is a rare but potentially lethal complication of percutaneous coronary intervention (PCI). The risk of CAP is associated with female and older patients but also with complex coronary anatomy, use of oversized balloons or stents, excessive postdilatation, and use of atheroablative devices and hydrophilic guidewires.<sup>1</sup> CAP risk is directly proportional to the complexity of the PCI procedure. The incidence of CAP is 0.43% with PCI<sup>1</sup> but rises to 2.9% in chronic total occlusion interventions.<sup>2</sup>

The imminent lethal outcome of CAP stems from the hemodynamic compromise of ensuing cardiac tamponade.

The most commonly used classification scheme of CAP is the Ellis classification.<sup>3</sup> It assesses the angiographic severity and determines the risk of adverse events such as emergent cardiac surgery, myocardial infarction, tamponade, or death. Interventional cardiologists should be able to recognize CAP and know available treatment options. So far, treatment options are mostly described as case reports, and the sporadic review articles may not cover the entire armamentarium.<sup>4–6</sup> Our objective was to report our single-center experience with CAP in terms of incidence, clinical characteristics, treatment options, and outcome.

From the Thoraxcenter, Erasmus Medical Center, Rotterdam, Netherlands.

**Correspondence to:** Nicolas M. Van Mieghem, MD, PhD, Thoraxcenter, Ad-342, 's-Gravendijkwal 230, 3015 CE Rotterdam, Netherlands. E-mail: n.vanmieghem@erasmusmc.nl

Received July 6, 2017; accepted August 3, 2017.

© 2017 The Authors. Published on behalf of the American Heart Association, Inc., by Wiley. This is an open access article under the terms of the Creative Commons Attribution-NonCommercial License, which permits use, distribution and reproduction in any medium, provided the original work is properly cited and is not used for commercial purposes.

## Methods

### Study Design

This study was a single-center, retrospective analysis of the overall prospective PCI database between February 9, 2005, and November 20, 2016. During this period, a total of 150 cases of iatrogenic CAP occurred. The respective PCI

## Clinical Perspective

### What Is New?

- This is a detailed and comprehensive overview of a large-volume, single-center experience with regard to the incidence, characteristics, management, and outcome of iatrogenic coronary artery perforations.

### What Are the Clinical Implications?

- Iatrogenic coronary artery perforation is a rare but potentially lethal complication of percutaneous coronary intervention that requires prompt recognition and treatment.
- We provide an overview of contemporary treatment options.

procedures were subsequently analyzed. This study was performed in accordance with the Declaration of Helsinki. Because this is a retrospective analysis, the local medical ethics committee waived the requirement to obtain informed consent.

## Baseline Characteristics

PCI indication, age, sex, the presence of multivessel coronary artery disease, and kidney function were collected in a dedicated database. Lesion characteristics were obtained from the respective angiographic studies by experienced reviewers and classified according to the American College of Cardiology (ACC) and American Heart Association (AHA) lesion classification.<sup>7</sup> CAPs were classified using the Ellis classification, which is based on the angiographic appearance of the CAP: type I indicates extraluminal crater without extravasation, type II indicates pericardial or myocardial blush without contrast jet extravasation, type III indicates contrast jet extravasation through frank ( $\geq 1$  mm) perforation, and type III cavity spilling (CS) indicates contrast jet extravasation into an anatomic cavity (eg, cardiac chamber or coronary sinus).<sup>3</sup> A detailed overview of the materials used during each PCI was gathered by review of the original procedure reports. For this analysis, the Balance Middle Weight (Abbott Laboratories), Sion (Asahi Intecc), and the Pilot 50 (Abbott Laboratories) were considered workhorse guidewires, and all other guidewires were considered nonworkhorse escalation wires. Because there is a distinction between possible etiology and treatment of proximal perforations (ie, those typically caused by aggressive balloons or devices) and distal perforations (ie, those typically caused by guidewire exits), the occurrence of guidewire exits was registered. Preprocedural use of glycoprotein 2b/3a inhibitors, protamine, predilatation, postdilatation, stenting, and atheroablative devices and use of the largest balloon or stent size were registered.

## End Point Definitions

The co-primary end points were pericardiocentesis to alleviate (imminent) clinical tamponade, emergency cardiac surgery for treatment of tamponade, secondary “bail-out” coronary artery bypass grafting (ie, to treat the coronary artery disease, instead of PCI), and in-hospital death. Periprocedural myocardial infarction was defined as a rise in cardiac markers 5 times the upper limit of normal, according to the European Society of Cardiology’s third universal definition.<sup>8</sup> Thirty-day and 1-year survival data for all patients were obtained from the municipal civil registry, and general practitioners were contacted for additional information if necessary.

## Statistical Analyses

Descriptive analyses were performed using IBM SPSS Statistics version 24.0. Continuous variables are presented as mean $\pm$ SD. Categorical variables are expressed as percentages. For comparison of categorical variables, the Pearson  $\chi^2$  test or Fisher exact test was used, as appropriate. All statistical tests are 2-tailed, and  $P < 0.05$  is considered statistically significant. The authors take responsibility for the integrity of the data and the accuracy of the analyses.

## Results

During the study period, a total of 21 212 percutaneous coronary procedures were performed including PCI, fractional flow reserve, intravascular ultrasound, and optical coherence tomography procedures, of which 150 (0.71%) were complicated by CAP. Baseline and procedural characteristics of the CAP patients are shown in Table 1, and clinical outcomes are shown in Table 2.

## Baseline and Procedural Characteristics

Mean age of the CAP patients was  $66 \pm 11$  years, and 62.7% were male. Renal impairment was present in 18.5% of patients, and multivessel disease was present in 53.7%. Target lesions were classified as ACC/AHA type B2 or C in 94.6%, and angiographic calcifications were present in 61.6% of patients. Overall, 31.3% of the CAP cases involved chronic total occlusions. Three cases of CAP occurred without a frank PCI: CAP occurred in 1 patient who underwent analysis of the perfusion of an intrapericardial glomus tumor, in 1 patient during a fractional flow reserve measurement, and in 1 patient during intravascular ultrasound imaging.

Predilatation and stenting were performed in most patients (67.6% and 75.3%), whereas rotablation and cutting balloons were used in 4 patients (2.7%) and 1 patient (0.7%), respectively. A nonworkhorse guidewire was used in 74.3%,

**Table 1.** Baseline and Procedural Characteristics of the CAP Patients

Patient characteristic	Result
Age, y	65.6 (10.7)
Male sex	62.7
Renal impairment (n=146)	18.5
Multivessel disease (n=149)	53.7
Indication for procedure	
Stable angina	45.3
NSTE-ACS	28.7
STEMI	24.7
Ischemic heart failure	0.7
Analysis of intrapericardial glomus tumor	0.7
Treated vessel (n=141)	
LAD	39.0
LCX	19.1
RCA	36.2
LMCA	1.4
SVG	4.3
Lesion type (n=147)	
A	0.7
B1	3.4
B2	29.9
C	64.6
B2/C	94.6
Calcification (n=136)	
CTO	31.3
FFR only	0.7
IVUS only	0.7
Procedure characteristics	
Stenting	75.3
Use of nonworkhorse wire (n=140)	74.3
Predilatation (n=145)	67.6
Predilatation NC balloon (n=140)	20.7
Postdilatation (n=115)	39.1
Largest balloon/stent, mm (n=118)	3.16 (0.78)
Use of glycoprotein 2b/3a inhibitor	8.7
Use of protamine (n=146)	13.7
Rotablator	2.7
Burr size, mm	1.4 (0.1)
Cutting balloon	0.7
Wire exit (n=148)	61.5
CAP type (n=104)	
Ellis I	2.9

Continued

**Table 1.** Continued

Patient characteristic	Result
Ellis II	40.4
Ellis III	54.8
Ellis III-CS	1.9
CAP treatment on table	
Unrecognized CAP	24.7
Conservative	41.3
Balloon	7.3
Covered stent(s)	24.0
Coils	0.7
Fat embolism	2.0

Figures are presented as percentages or as mean (SD), as appropriate. The numbers in the table are based on the complete sample of CAP patients (n=150), unless indicated otherwise. CAP indicates coronary artery perforation; CS, cavity spilling; CTO, chronic total occlusion; FFR, fractional flow reserve; IVUS, intravascular ultrasound; LAD, left anterior descending coronary artery; LCX, left circumflex coronary artery; LMCA, left main coronary artery; NC, non-complaint; NSTE-ACS, non-ST-segment-elevation acute coronary syndrome; RCA, right coronary artery; STEMI, ST-segment-elevation myocardial infarction, SVG, saphenous vein graft.

and guidewire exit was the underlying etiology of CAP in 61.5% of cases.

In 37 patients (24.7%), CAP was unrecognized during the PCI procedure. For 9 patients, the available angiograms did not allow proper application of the Ellis classification. Among the 104 patients in whom the CAP was visible during angiography, most CAPs were Ellis types II (40.4%) and III (54.8%). The immediate treatment in the catheterization

**Table 2.** Clinical Outcomes of the CAP Patients

In-hospital course	Result, %
Tamponade treated by pericardiocentesis	48.0
Tamponade treated only by surgery	2.7
Pericardiocentesis after unrecognized CAP	75.7
Pericardiocentesis after initially conservative/balloon	32.9
Pericardiocentesis after covered stent	52.8
Pericardiocentesis after coils	100
Pericardiocentesis after fat embolism	0
Cardiac surgery	12.7
Periprocedural MI	34.0
“Bail-out” CABG	5.3
Death	8.0
Post-hospital course	
30-d mortality (n=149)	10.7
1-y mortality (n=135)	17.8

CAP indicates coronary artery perforation; CABG, coronary artery bypass grafting; MI, myocardial infarction.

Downloaded from <http://jaha.ahajournals.org/> by guest on June 28, 2018

laboratory was most often conservative (73.3%), including use of prolonged balloon inflation, which was performed in 7.3% of patients. Placement of  $\geq 1$  covered stents was necessary in 24.0%. Among the patients with guidewire exit as the etiology of the CAP, 32.0% had Ellis type III CAP and 1.1% were treated with a covered stent; among the patients without guidewire exit, 75.9% had Ellis type III CAP and 57.9% were treated with a covered stent (both  $P < 0.001$ , not shown in table). Coiling of the coronary artery was performed in 1 patient (0.7%), and autologous fat embolization was applied in 3 patients (2.0%).

## Clinical Outcomes

Clinical tamponade occurred in 50.7% of CAP patients. The tamponade was treated by pericardiocentesis in 48.0% of cases. Late drainage for tamponade was required in one-third of the patients with initial conservative management and half of patients treated with a covered stent (Figure 1). Emergency cardiac surgery to alleviate the tamponade was required in 12.7% of cases, with the tamponade being treated primarily by cardiac surgery in 4 CAP patients (in 1 patient after initial conservative therapy, in 1 patient after covered stent, and in 2 patients with initially unrecognized CAPs).

Periprocedural myocardial infarction was present in 34%, and in 5.3% of patients, a bail-out coronary artery bypass grafting was performed. The all-cause mortality rate of CAP patients was 8.0% in hospital, 10.7% at 30 days, and 17.8% at 1 year. In-hospital and 1-year mortality rates were not

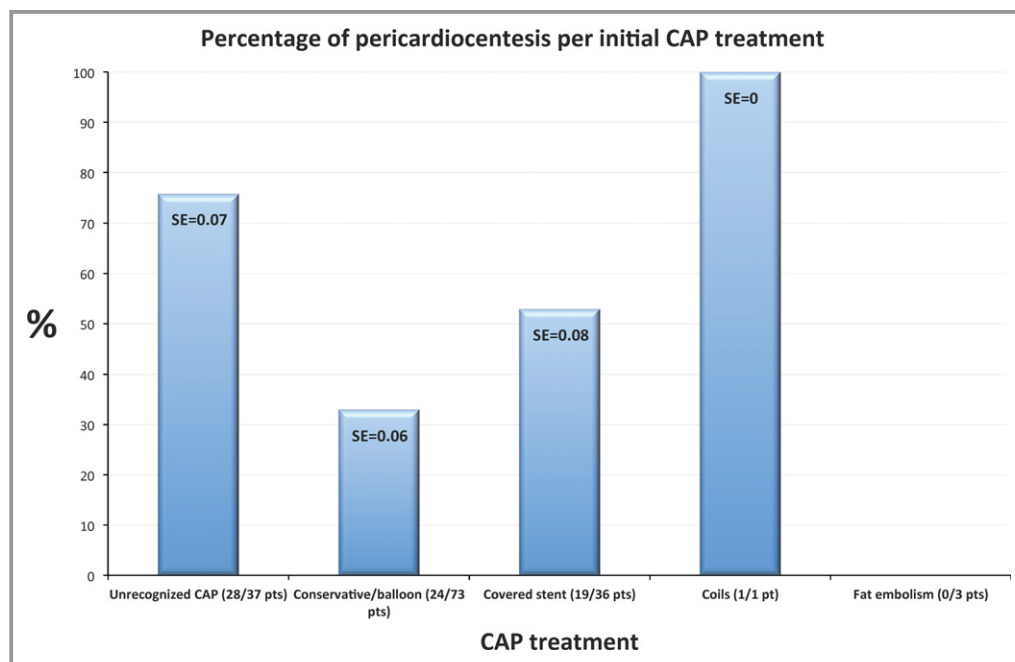
significantly different in patients with and without guidewire exit as the underlying etiology, but the 30 day-mortality rate was significantly higher in patients without a guidewire exit (16.1% versus 5.5%;  $P = 0.034$ , not shown in table). The mortality rates per initial treatment modality are shown in Figure 2.

## Discussion

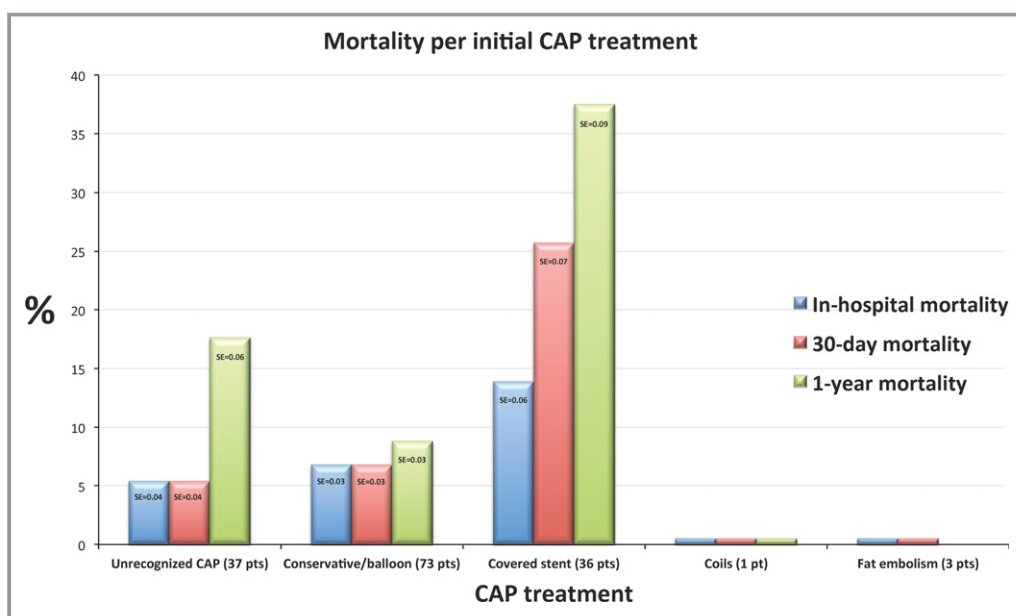
The CAP incidence of 0.71% in our population is in accordance with large contemporary registries, in which CAP incidences were 0.33%,<sup>9</sup> 0.22%,<sup>10</sup> and 0.19%,<sup>11</sup> respectively. CAP incidence may be somewhat higher because of greater lesion complexity in our procedures, reflected, for instance, by the high prevalence of chronic total occlusion treatment of 31.3% (compared with 21%,<sup>9</sup> 28.6%,<sup>10</sup> and 18%<sup>11</sup> in the aforementioned registries). In general, invasive imaging may guide complex PCI strategy in terms of device selection including rotational atherectomy and balloon selection. This may reduce the incidence of CAP but needs further study.

CAP is associated with considerable morbidity and mortality. In our CAP cohort, 30-day mortality was 10.7%. For the remainder of the 1-year follow-up, the mortality rate was comparable to the 7.1% 1-year mortality rate in the overall cohort of patients undergoing PCI at our center during the same time window.

Al-Lamee et al reported an in-hospital mortality rate of 14.8% among patients with an Ellis type III CAP.<sup>10</sup> Without



**Figure 1.** Percentage of patients treated with pericardiocentesis after each CAP treatment. CAP indicates coronary artery perforation; pt(s), patient(s).



**Figure 2.** Mortality rates after each CAP treatment. CAP indicates coronary artery perforation; pt(s), patient(s).

stratifying for Ellis type, the in-hospital mortality rate described by Javaid et al was 16.7%.<sup>11</sup> In comparison, our mortality rates are somewhat lower and more in line with a recent registry, in which the in-hospital, 30-day, and 1-year mortality rates were 8%, 11%, and 15%, respectively.<sup>9</sup> As shown in Figure 2, the mortality rates in our cohort were highest in patients initially treated with a covered stent.

## Treatment Options

Similar to our cohort, Al-Lamee et al describe infrequent use of coils in 1.8% of cases and a relatively frequent use of covered stents in 46.4%. Acute pericardiocentesis was performed in 28.6% of their patients.<sup>10</sup> In the cohort of Javaid et al, coils were used in 4.2% of cases, covered stents in 18.1% and tamponade occurred in 19.4%.<sup>11</sup>

Compared with those cohorts, tamponade and subsequent treatment consisting of pericardiocentesis or surgery were more frequent in our series. Need for pericardiocentesis after an initially unrecognized CAP or initially conservative treatment was substantial, but the in-hospital mortality rates of these patients—respectively, 5.4% and 6.8%—are lower than the rates described by Al-Lamee et al and Javaid et al.<sup>10,11</sup> This might imply earlier recognition and treatment of tamponade in our cohort, which could translate to improved acute survival. As shown in Figure 1, in 19 of the 36 patients who were initially treated with a covered stent, pericardiocentesis still became necessary. Unfortunately, we do not have detailed documentation of the reasons for lack of success after covered stent placement. In theory, some

reasons are conceivable: (1) incomplete coverage of the perforated area, which might not be immediately evident after placement of the covered stent (geographical miss); (2) development of tamponade already, before but only clinically evident after the placement of the covered stent; or (3) incomplete apposition or underexpansion of the covered stent.

Our data underscore the importance of systematic echocardiographic monitoring to screen for pericardial effusion and fast pericardiocentesis in case of tamponade. Echocardiography should be repeated during the next 24 hours to rule out late tamponade, as described by Ellis in 1994<sup>3</sup> and as illustrated in our cohort by the need for pericardiocentesis in 32.9% of patients after an initial conservative approach and in 52.8% of patients after placement of a covered stent. When further actions are required, CAP location and severity play decisive roles. In general, proximal CAPs require covered stents or surgical repair, and distal CAPs caused by wire exits can be treated with embolization therapies including coils, microspheres, thrombin, and autologous fat or blood.

## Universal Treatment Approach

Prolonged proximal balloon inflation (1:1 balloon:vessel size) allows the operator to gain time, and multiple runs of prolonged balloon inflation may be required. Intravenous anticoagulant and antiplatelet therapy need to be discontinued, and activated clotting time should be corrected with protamine. If glycoprotein IIb/IIIa antagonists were



administered, platelet transfusions may be reasonable. Most Ellis type I and II CAPs can be treated with this minimal, relatively conservative approach, especially more distal CAPs caused by guidewire exits. Rapidly increasing pericardial effusion and frank tamponade justify early pericardial drainage.

### Covered Stents

Originally designed to tackle in-stent restenosis,<sup>12,13</sup> covered stents have an important role as bail-out treatment of CAP, especially when located in the proximal vessel segments with a diameter  $\geq 2.75$  mm, that is, more proximal CAPs that are more likely caused by oversized or aggressive use of balloons or devices. The main objective of a covered stent is to seal the perforation with a layer impermeable to blood. Table 3 shows currently available covered stents. Stents covered with the biocompatible polymer PTFE (polytetrafluoroethylene) are the most commonly used. Although survival after CAP has improved and the need for emergent cardiac surgery has decreased since the application of covered stents, there are intrinsic limitations.<sup>14</sup> First, all covered stents carry the inherent risk of side branch occlusion; therefore, when a major side branch is likely to be occluded, an alternative treatment option, such as cardiac surgery, must be considered. Second, there are concerns about late thrombogenicity of PTFE-covered stents<sup>15</sup> that might be overcome with prolonged dual-antiplatelet therapy.<sup>16</sup> Newer generation covered stents contain graft material made from autologous veins or equine pericardium to improve stent flexibility and decrease thrombogenicity.<sup>17–19</sup>

### Coiling

Coils are permanent metallic (stainless steel or platinum) agents with a wired structure of synthetic wool or Dacron fibers and thrombogenic properties. Coils can be delivered through normal guide catheters or through microcatheters for distal and more precise placement. The chosen coil size should be larger than the target vessel size to ensure complete vessel adherence and embolization. Coils that are too large may inadvertently be deployed too proximally, and coils that are too small may migrate too distally. Coils are generally used for CAPs in more distal and smaller caliber segments.<sup>5</sup>

### Microspheres

Microspheres are spherical, hydrophilic, nonabsorbable particles that come in sizes ranging from 1 to 1500  $\mu\text{m}$  and that can be delivered through a microcatheter. The variety of sizes makes microspheres suitable for embolization of a wide range of vessels. Similar to coils, microspheres are chiefly applied in peripheral vasculature, for instance, to occlude blood supply of vascularized tumors or arteriovenous malformations.

Recently, microsphere embolization was described as an alternative to alcohol in percutaneous transluminal septal myocardial ablation as treatment of hypertrophic cardiomyopathy.<sup>20</sup> Shortly thereafter, successful treatment of CAP using microspheres was described.<sup>21,22</sup> Although the evidence supporting the safety and efficacy of microspheres in the management of CAP is still scarce, microspheres allow more precise sealing of the perforation, limiting collateral damage.

**Table 3.** Covered Stents

Name	Graftmaster Jostent	ProGraft	Autologous Vein	Over and Under
Manufacturer	Abbott	Vascular concepts	Assembled by operator on metal stent	ITGI Medical
Stent material	Stainless steel (BMS)	BMS	Any stent	Stainless steel (BMS)
Graft material	Expandable PTFE single layer	Expandable PTFE	Vein from patient	Equine pericardium
Minimum guide catheter	$\geq 6\text{F}$ (2.8–4.0 mm) $\geq 7\text{F}$ (4.5–4.8 mm)	$\geq 6\text{F}$ (3.0–3.5 mm) $\geq 7\text{F}$ (recommended)		$\geq 6\text{F}$ (2.5–3.5 mm) $\geq 7\text{F}$ (3.5–4.0 mm)
Length, mm	16, 19, 26	15, 20, 25, 30		13, 18, 23, 27
Diameter, mm (max)	2.8 (3.25) 3.5 (3.95) 4.0 (4.48) 4.5 (4.94) 4.8 (5.29)	3.0 (3.14) 3.5 (3.61) 4.0 (4.04) 4.5 (4.60)		2.5 3.0 3.5 4.0
Disadvantages	High crossing profile and low flexibility	High crossing profile and low flexibility	Requires time and expertise to assemble	Requires washing before use

BMS indicates bare metal stent; PTFE, polytetrafluoroethylene.

## Thrombin Injection

Thrombin is a potent platelet activator, and it directly promotes the formation of fibrin clots. Local and precise administration of thrombin containing solutions and a commercially available glue containing thrombin and fibrinogen, administered through a microcatheter or an over-the-wire balloon, have been described to seal distal perforations.<sup>23–26</sup>

## Autologous Blood Clots

Contrary to the methods mentioned, autologous blood is universally available and biocompatible in every patient. Furthermore, it does not entail additional costs. The successful sealing of CAPs with autologous blood clots suspended in contrast media and saline has been described.<sup>27,28</sup> One case report describes normal blood flow in the treated coronary branch 6 months later, owing to clot lysis after sealing of the perforation.<sup>28</sup>

## Fat Embolization

Autologous subcutaneous fat has the same advantages of universal availability and biocompatibility without additional costs. Fat particles can form a physical barrier to leakage from blood, but they also activate the coagulation pathway, thereby sealing the coronary perforation. To obtain radiopacity, the particles must either be dipped into contrast or be delivered using contrast. Delivery of fat particles as CAP treatment was performed in our population and has been described previously.<sup>29,30</sup>

## Conclusion

CAP is a rare complication of PCI, but it is associated with high morbidity and mortality. Hemodynamic status, CAP location, the individual coronary anatomy, the amount of myocardium at risk, and a patient's ability to undergo cardiac surgery determine the treatment strategy.

## Disclosures

None.

## References

- Shimony A, Joseph L, Mottillo S, Eisenberg MJ. Coronary artery perforation during percutaneous coronary intervention: a systematic review and meta-analysis. *Can J Cardiol*. 2011;27:843–850.
- Patel VG, Brayton KM, Tamayo A, Mogabgab O, Michael TT, Lo N, Alomar M, Shorrock D, Copher D, Abdullah S, Banerjee S, Brilakis ES. Angiographic success and procedural complications in patients undergoing percutaneous coronary chronic total occlusion interventions: a weighted meta-analysis of 18,061 patients from 65 studies. *JACC Cardiovasc Interv*. 2013;6:128–136.
- Ellis SG, Ajluni S, Arnold AZ, Popma JJ, Bittl JA, Eigler NL, Cowley MJ, Raymond RE, Safian RD, Whitlow PL. Increased coronary perforation in the new device era. Incidence, classification, management, and outcome. *Circulation*. 1994;90:2725–2730.
- Rogers JH, Lasala JM. Coronary artery dissection and perforation complicating percutaneous coronary intervention. *J Invasive Cardiol*. 2004;16:493–499.
- Pershad A, Yarkoni A, Biglari D. Management of distal coronary perforations. *J Invasive Cardiol*. 2008;20:E187–E191.
- Lee MS, Shamouelian A, Dahodwala MQ. Coronary artery perforation following percutaneous coronary intervention. *J Invasive Cardiol*. 2016;28:122–131.
- Ryan TJ, Faxon DP, Gunnar RM, Kennedy JW, King SB III, Loop FD, Peterson KL, Reeves TJ, Williams DO, Winters WL Jr. Guidelines for percutaneous transluminal coronary angioplasty. A report of the American College of Cardiology/American Heart Association Task Force on Assessment of Diagnostic and Therapeutic Cardiovascular Procedures (Subcommittee on Percutaneous Transluminal Coronary Angioplasty). *Circulation*. 1988;78:486–502.
- Thygesen K, Alpert JS, Jaffe AS, Simoons ML, Chaitman BR, White HD; Writing Group on the Joint ESC/ACCF/AHA/WHF Task Force for the Universal Definition of Myocardial Infarction, Thygesen K, Alpert JS, White HD, Jaffe AS, Katus HA, Apple FS, Lindahl B, Morrow DA, Chaitman BA, Clemmensen PM, Johanson P, Hod H, Underwood R, Bax JJ, Bonow RO, Pinto F, Gibbons RJ, Fox KA, Atar D, Newby LK, Galvani M, Hamm CW, Uretsky BF, Steg PG, Wijns W, Bassand JP, Menasché P, Ravkilde J, Ohman EM, Antman EM, Wallentin LC, Armstrong PW, Simoons ML, Januzzi JL, Nieminen MS, Gheorghide M, Filippatos G, Luepker RV, Fortmann SP, Rosamond WD, Levy D, Wood D, Smith SC, Hu D, Lopez-Sendon JL, Robertson RM, Weaver D, Tendera M, Bove AA, Parkhomenko AN, Vasilieva EJ, Mendis S; ESC Committee for Practice Guidelines (CPG). Third universal definition of myocardial infarction. *Eur Heart J*. 2012;33:2551–2567.
- Kinnaird T, Kwok CS, Kontopantelis E, Ossei-Gerning N, Ludman P, deBelder M, Anderson R, Mamas MA; British Cardiovascular Intervention S and the National Institute for Cardiovascular Outcomes R. Incidence, determinants, and outcomes of coronary perforation during percutaneous coronary intervention in the United Kingdom between 2006 and 2013: an analysis of 527 121 cases from the British Cardiovascular Intervention Society Database. *Circ Cardiovasc Interv*. 2016;9:e003449.
- Al-Lamee R, Ielasi A, Latib A, Godino C, Ferraro M, Mussardo M, Arioli F, Carlino M, Montorfano M, Chieffo A, Colombo A. Incidence, predictors, management, immediate and long-term outcomes following grade III coronary perforation. *JACC Cardiovasc Interv*. 2011;4:87–95.
- Javadi A, Buch AN, Satler LF, Kent KM, Suddath WO, Lindsay J Jr, Pichard AD, Waksman R. Management and outcomes of coronary artery perforation during percutaneous coronary intervention. *Am J Cardiol*. 2006;98:911–914.
- Schachinger V, Hamm CW, Munzel T, Haude M, Baldus S, Grube E, Bonzel T, Konorza T, Koster R, Arnold R, Haase J, Probst P, vom Dahl J, Neumann FJ, Mudra H, Hennen B, Thiele L, Zeiher AM; Investigators S. A randomized trial of polytetrafluoroethylene-membrane-covered stents compared with conventional stents in aortocoronary saphenous vein grafts. *J Am Coll Cardiol*. 2003;42:1360–1369.
- Stankovic G, Colombo A, Presbitero P, van den Branden F, Inglese L, Cernigliaro C, Niccoli L, Bartorelli AL, Rubartelli P, Reifart N, Heyndrickx GR, Saunamaki K, Morice MC, Sgura FA, Di Mario C; Randomized Evaluation of polytetrafluoroethylene CsiSvgi. Randomized evaluation of polytetrafluoroethylene-covered stent in saphenous vein grafts: the Randomized Evaluation of polytetrafluoroethylene COVERed stent in Saphenous vein grafts (RECOVERS) Trial. *Circulation*. 2003;108:37–42.
- Romaguera R, Waksman R. Covered stents for coronary perforations: is there enough evidence? *Catheter Cardiovasc Interv*. 2011;78:246–253.
- Lee WC, Hsueh SK, Fang CY, Wu CJ, Hang CL, Fang HY. Clinical outcomes following covered stent for the treatment of coronary artery perforation. *J Interv Cardiol*. 2016;29:569–575.
- Ly H, Awaida JP, Lesperance J, Bilodeau L. Angiographic and clinical outcomes of polytetrafluoroethylene-covered stent use in significant coronary perforations. *Am J Cardiol*. 2005;95:244–246.
- Colombo A, Almagor Y, Gaspar J, Vonderwalde C. The pericardium covered stent (PCS). *EuroIntervention*. 2009;5:394–399.
- Wykrzykowska JJ, Gutierrez-Chico JL, van Geuns RJ. “Over-and-under” pericardial covered stent with paclitaxel balloon in a saphenous vein graft. *Catheter Cardiovasc Interv*. 2010;75:964–966.
- Chen S, Lotan C, Jaffe R, Rubinshtein R, Ben-Assa E, Roguin A, Varshitzky B, Danenberg HD. Pericardial covered stent for coronary perforations. *Catheter Cardiovasc Interv*. 2015;86:400–404.
- Vriesendorp PA, Van Mieghem NM, Vlietter WB, Ten Cate FJ, de Jong PL, Schinkel AF, Michels M. Microsphere embolisation as an alternative for alcohol in percutaneous transluminal septal myocardial ablation. *Neth Heart J*. 2013;21:245–248.

21. Meincke F, Kuck KH, Bergmann MW. Cardiac tamponade due to coronary perforation during percutaneous interventions successfully treated with microspheres. *Clin Res Cardiol*. 2014;103:325–327.
22. Politi L, Iaccarino D, Sangiorgi GM, Modena MG. Huge coronary perforation during percutaneous intervention sealed by injection of polyvinyl alcohol microspheres. *J Cardiovasc Med (Hagerstown)*. 2015;16(suppl 2):S130–S132.
23. Fischell TA, Korban EH, Lauer MA. Successful treatment of distal coronary guidewire-induced perforation with balloon catheter delivery of intracoronary thrombin. *Catheter Cardiovasc Interv*. 2003;58:370–374.
24. Fischell TA, Moualla SK, Mannem SR. Intracoronary thrombin injection using a microcatheter to treat guidewire-induced coronary artery perforation. *Cardiovasc Revasc Med*. 2011;12:329–333.
25. Goel PK. Delayed and repeated cardiac tamponade following microleak in RCA successfully treated with intra arterial sterile glue injection. *Catheter Cardiovasc Interv*. 2009;73:797–800.
26. Storger H, Ruef J. Closure of guide wire-induced coronary artery perforation with a two-component fibrin glue. *Catheter Cardiovasc Interv*. 2007;70:237–240.
27. Cordero H, Gupta N, Underwood PL, Gogte ST, Heuser RR. Intracoronary autologous blood to seal a coronary perforation. *Herz*. 2001;26:157–160.
28. Tanaka S, Nishigaki K, Ojio S, Yasuda S, Okubo M, Yamaki T, Kubota T, Takasugi N, Ishihara Y, Kawasaki M, Minatoguchi S. Transcatheter embolization by autologous blood clot is useful management for small side branch perforation due to percutaneous coronary intervention guide wire. *J Cardiol*. 2008;52:285–289.
29. George S, Cotton J, Wrigley B. Guidewire-induced coronary perforation successfully treated with subcutaneous fat embolisation: a simple technique available to all. *Catheter Cardiovasc Interv*. 2015;86:1186–1188.
30. Shemisa K, Karatasakis A, Brilakis ES. Management of guidewire-induced distal coronary perforation using autologous fat particles versus coil embolization. *Catheter Cardiovasc Interv*. 2017;89:253–258.



## Clinical Characteristics and Management of Coronary Artery Perforations: A Single–Center 11–Year Experience and Practical Overview

Miguel E. Lemmert, Rutger J. van Bommel, Roberto Diletti, Jeroen M. Wilschut, Peter P. de Jaegere, F. Zijlstra, Joost Daemen and Nicolas M. Van Mieghem

*J Am Heart Assoc.* 2017;6:e007049; originally published September 22, 2017;

doi: 10.1161/JAHA.117.007049

The *Journal of the American Heart Association* is published by the American Heart Association, 7272 Greenville Avenue, Dallas, TX 75231  
Online ISSN: 2047-9980

The online version of this article, along with updated information and services, is located on the World Wide Web at:

<http://jaha.ahajournals.org/content/6/9/e007049>