

Nodular regenerative hyperplasia rarely leads to liver transplantation: A 20-year cohort study in all Dutch liver transplant units

United European Gastroenterology Journal
2017, Vol. 5(5) 658–667

© Author(s) 2016

Reprints and permissions:

sagepub.co.uk/journalsPermissions.nav

DOI: 10.1177/2050640616680550

journals.sagepub.com/home/ueg



Berrie Meijer^{1,*}, Melek Simsek^{1,*}, Hans Blokzijl², Robert A de Man³,
Minneke J Coenraad⁴, Gerard Dijkstra², Carin MJ van Nieuwkerk¹,
Chris JJ Mulder¹ and Nanne KH de Boer¹

Abstract

Background: Nodular regenerative hyperplasia is an uncommon liver condition associated with several autoimmune disorders and drugs. The clinical symptoms of nodular regenerative hyperplasia vary from asymptomatic to severe complications of portal hypertension (nodular regenerative hyperplasia-syndrome).

Objective: The purpose of this study was to identify the prognosis and optimal management, as well as the role of liver transplantation, in nodular regenerative hyperplasia.

Methods: The pathology databases of all three Dutch liver transplant units were retrospectively scrutinised for explanted livers diagnosed with nodular regenerative hyperplasia or without clear diagnosis. Pre- and post-transplantation clinical, biochemical, radiological and histological information was obtained from electronic and paper records.

Results: In total, 1886 patients received a liver transplant. In 255 patients, nodular regenerative hyperplasia could not be excluded. After detailed chart review, the native livers of 11 patients (0.6%) (82% male, median age: 44 years) displayed nodular regenerative hyperplasia. Seven patients (64%) had underlying disorders or drug exposure which possibly caused nodular regenerative hyperplasia. Laboratory and imaging abnormalities were present in all patients but did not contribute to the diagnosis of nodular regenerative hyperplasia. Five-year survival was 73% (median follow-up: four years, range: 2–248 months).

Conclusion: Nodular regenerative hyperplasia is a rare finding in patients, predominantly young males, transplanted for end-stage liver disease with unknown aetiology. Nonetheless, liver transplantation may have an important role in end-stage nodular regenerative hyperplasia-syndrome.

Keywords

Liver transplantation, hepatotoxicity, drug-induced liver injury, portal hypertension, nodular regenerative hyperplasia

Received: 25 August 2016; accepted: 18 October 2016

Introduction

Nodular regenerative hyperplasia (NRH) is an uncommon condition of the liver which can cause intrahepatic portal hypertension in the absence of liver cirrhosis.^{1–3} Recently, it has been shown that NRH is frequently asymptomatic and that the histological diagnosis has to be distinguished from the NRH-syndrome, in which patients present with symptoms from portal hypertension.⁴

The pathophysiology of NRH is still poorly understood, but seems to be related to alterations in the

¹Department of Gastroenterology and Hepatology, VU University Medical Center Amsterdam, The Netherlands

²Department of Gastroenterology and Hepatology, University Medical Center Groningen, Groningen, The Netherlands

³Department of Gastroenterology and Hepatology, Erasmus University Medical Center, Rotterdam, The Netherlands

⁴Department of Gastroenterology and Hepatology, Leiden University Medical Center, Leiden, The Netherlands

*Both authors contributed equally

Corresponding author:

Berrie Meijer, VU University Medical Center, Department of Gastroenterology and Hepatology, De Boelelaan 1118, 1081HZ Amsterdam, The Netherlands.

Email: b.meijer1@vumc.nl

hepatic blood flow due to obliterative vasculopathy and/or secondary to damage of the sinusoids.⁵ The development of NRH has been associated with a variety of systemic disorders including myelo- and lymphoproliferative diseases, autoimmune diseases, inflammatory and immunodeficiency disorders as well as certain medications.⁶ Drugs associated with NRH are highly active anti-retroviral therapy,⁷ platin-based chemotherapy⁸ and thiopurines, in particular azathioprine (AZA) and thioguanine (TG).^{9–11}

The diagnosis of NRH is challenging since the clinical presentation is variable and the majority of patients present without symptoms or abnormalities in laboratory parameters.¹² If symptoms are present, these are mainly due to portal hypertension, such as thrombocytopenia, oesophageal varices, splenomegaly and ascites.¹³ Mildly increased liver enzymes, in particular alkaline phosphatase (AP), have been reported in one out of 10 patients.⁶ Imaging methods, such as magnetic resonance imaging (MRI) and computed tomography (CT) could demonstrate nodularity and heterogeneous hepatic parenchyma suggestive of NRH. Nevertheless, diagnosis has to be confirmed with histological evaluation and a reticulin stain is necessary to characterise the transformation of the hepatic parenchyma into hyperplasia and atrophy.¹⁴ Interestingly, the level of interobserver agreement on the histopathologic diagnosis of NRH is poor, even between experienced liver pathologists, confirming that NRH should be diagnosed using the combination of clinical presentation and histopathologic findings.¹⁵

The clinical significance and prognosis, as well as the optimal management of NRH are still not completely clarified. In a large cohort study by Wanless in 1990, NRH was present in 64 of 2500 (2.6%) consecutive autopsies.¹⁶ Among these 64 persons, only one had symptoms of portal hypertension and the other cases were asymptomatic. It seems that the prognosis in NRH patients is more related to the severity of the underlying condition than to liver involvement itself.¹⁷ Therefore, treatment should be focused on the associated diseases and complications of non-cirrhotic portal hypertension (NCPH), in particular variceal bleeding which is the main cause of NCPH-related mortality.^{1,18}

Liver transplantation might be indicated in NRH-syndrome and should be considered in patients with severe complications of NCPH or hepatic failure.¹⁹ Frequently, it occurs that the diagnosis of NRH-syndrome is missed before transplantation and patients undergo liver transplantation due to a presumptive diagnosis of liver cirrhosis.¹³ Overall, there is limited data available on the natural course of NRH and the role of liver transplantation as a treatment. Therefore, we aimed to determine the number of patients transplanted due to NRH-syndrome in a retrospective study in The

Netherlands and to evaluate the indications and limitations of this treatment. Here, we describe the clinical characteristics of the patients and the histological features of the explanted livers affected with NRH.

Methods

Patient selection

In this retrospective database study we collected data from the three liver transplant units in The Netherlands; University Medical Center Groningen (UMCG) in Groningen, Erasmus University Medical Center (EMC) in Rotterdam and Leiden University Medical Center (LUMC) in Leiden. Access to the surgical pathology databases was obtained and the records of patients transplanted in the period from January 1995–April 2016 were searched for explanted livers diagnosed with either NRH, non-cirrhotic or cryptogenic liver disease on post-transplant histological evaluation. We included all adult patients in our initial analysis. Explanted livers with hepatic malignancy, hepatitis B/C virus infection, alcoholic liver disease, primary biliary tract disease, autoimmune hepatitis or metabolic liver diseases were excluded. Furthermore, cases of pre- and posthepatic (e.g. Budd-Chiari syndrome) portal hypertension were excluded. Cases with liver failure due to other causes of NCPH, such as hepatoportal sclerosis, perisinusoidal fibrosis or incomplete septal cirrhosis were excluded, unless NRH co-existed in the major part of the explanted liver. Cases with acute liver failure related to (recreational) drugs and medication were included.

Data extraction

Pre- and post-transplantation clinical, biochemical, radiological and histological information obtained from electronic and paper records were analysed. We collected data on demographics, clinical presentation, medical and surgical history and (historical) lifestyle (i.e. smoking and alcohol usage) of the patients. Biochemical parameters we collected were: haemoglobin (Hb), white blood cell count (WBC), platelet count (PC), alanine aminotransferase (ALT), aspartate aminotransferase (AST), alkaline phosphatase (AP), gamma-glutamyl transferase (GGT), serum bilirubin, serum creatinine, prothrombin time (PT), international normalised ratio (INR) and Model for End-Stage Liver Disease (MELD) scores. Human immunodeficiency virus (HIV) serology was obtained. Further collected data were macro- and microscopic histological liver features related to NRH and characteristics of NCPH, defined as liver atrophy, heterogeneous parenchyma, presence of ascites, portal vein thrombosis, portosystemic collateral veins or splenomegaly at ultrasonography

(US), CT or MRI. The use of potential hepatotoxic medications (e.g. thiopurines, platin based chemotherapy and highly active anti-retroviral therapy) was recorded.

NRH-syndrome

To distinguish histopathological diagnosis of NRH without symptoms of portal hypertension from patients with NCPH due to NRH, patients having symptomatic NRH are classified as having NRH-syndrome.

Histological analysis

Diagnosis of NRH was based on reports of the histological assessment of the explanted livers. The macro- and microscopic features of the liver were explored and searched for NRH characteristics as defined by Jharap et al.¹⁵ The definitive diagnosis of NRH based on the histological reports was made by the pathologist at the liver transplantation centre.

Data analysis

Categorical variables were described as absolute and relative numbers. The continuous variables were

described as mean \pm standard deviation (for normal distribution) or median with range (for skewed distribution). Due to the (expected) low number of patients, no further statistical analysis was performed.

Ethical considerations

This study was approved by the Medical Ethics Review Committee (METC) of the VU University Medical Center (file number 2016-095).

Results

Patient characteristics

In the past 20 years, 1886 transplantations (UMCG: 660, EMC: 905 and LUMC: 321) have been performed in adult patients in the three Dutch liver transplant units. The database of the LUMC was initiated in 2000. A total of 255 transplanted patients (UMCG: 79, EMC: 128 and LUMC: 48) matched the inclusion criteria for this study and their charts were reviewed. NRH was histologically diagnosed in 11 patients (0.6%) (UMCG: seven, EMC: three and LUMC: one) (Figure 1).

One of these 11 patients was re-transplanted 14 years after the initial liver transplantation, both times due to

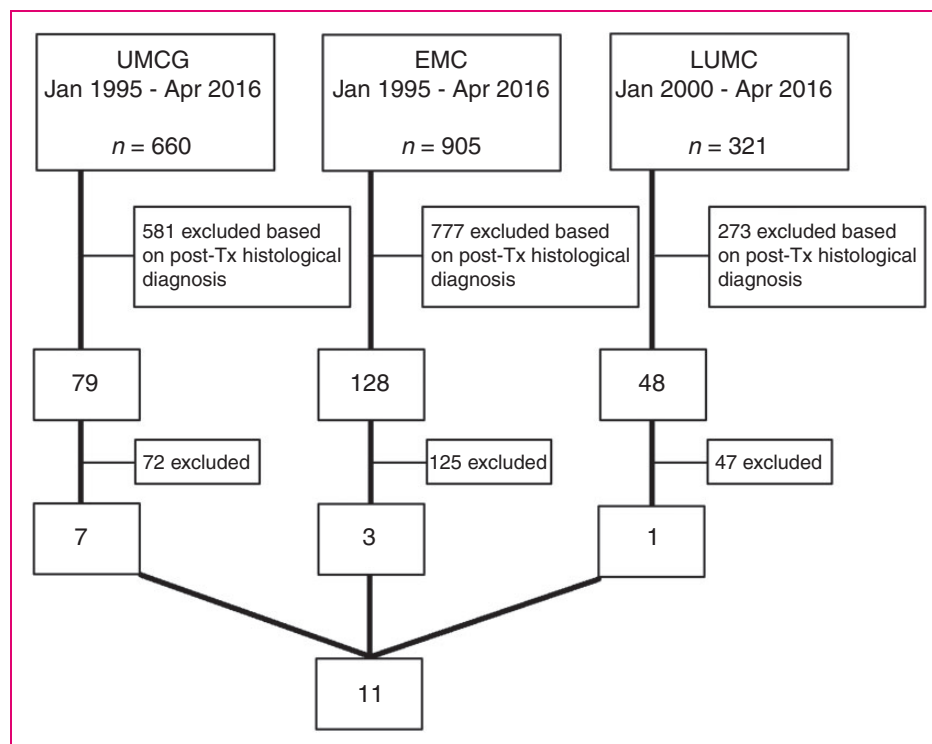


Figure 1. Flowchart of patient selection. Post-transplantation diagnoses causing exclusion were: hepatic malignancy, hepatitis B/C virus infection, alcohol abuse, primary biliary tract disease, autoimmune hepatitis and metabolic liver diseases. EMC: Erasmus Medical Center Rotterdam; LUMC; Leiden University Medical Center; Tx: transplantation; UMCG: University Medical Center Groningen.

NRH-syndrome. In this study, we only describe the second liver transplantation, since the first transplantation was before 1995. One case has been published before.²⁰

Among these cases, nine patients were males (82%; Table 1). The median age at first presentation with liver disease was 27 years (range: 18–60 years) and 44 years at time of the liver transplantation (22–69 years). The delay between first presentation and liver transplantation ranged from 4–20 years with a median delay time of nine years.

The pre-transplantation diagnosis was cryptogenic cirrhosis for seven patients (7/11; 64%), alcoholic cirrhosis for two patients (2/11; 18%), autoimmune hepatitis (AIH) for one patient (1/11; 9%) and one patient was diagnosed with antimitochondrial antibody (AMA)-negative primary biliary cirrhosis (PBC) (1/11; 9%).

Clinical presentation of the NRH patients

Four patients (4/11; 36%) had unexplained liver test abnormalities, four patients (4/11; 36%) were bleeding from gastro-oesophageal varices and three patients (3/11; 28%) had thrombocytopenia at first clinical presentation (Table 1). Therapeutic management to treat the acute variceal bleeding was endoscopic band ligation (2/4; 50%) or sclerotherapy followed by a surgical portocaval shunt (1/4; 25%) or splenorenal shunt (1/4;

25%). During the pre-transplantation course, more complications of portal hypertension occurred in all patients. The most frequently occurring complications were gastro-oesophageal varices (11/11; 100%), splenomegaly (10/11; 91%), portal vein thrombosis (7/11; 64%), ascites (7/11; 64%) and hepatic encephalopathy (4/11; 36%). Furthermore, three patients had spontaneous bacterial peritonitis (3/11; 28%) and three patients developed hepatopulmonary syndrome (HPS, 3/11; 28%), which is an important cause of dyspnoea and hypoxia in the setting of end-stage liver disease.

Diseases and drugs associated with NRH

An associated disease and/or drug use with NRH was observed in seven of 11 patients (7/11; 64%), of which five patients (5/11; 45%) were treated with thiopurines. These seven patients together had a median age of 27 years (23–46 years) when first liver symptoms developed and a median age of 44 years (30–54 years) when orthotopic liver transplantation (OLT) was performed. Patient #3 underwent OLT for the second time, both times due to NRH-syndrome. After first OLT, this patient was treated with AZA for nine years and eventually developed liver failure 14 years after initial OLT. Patient #4 was previously diagnosed with autoimmune hepatitis (AIH) and was treated with AZA 150 mg/day for six months before manifestation of NRH-

Table 1. Clinical findings in the patients with nodular regenerative hyperplasia (NRH) before orthotopic liver transplantation (OLT).

Case no.	Sex	Age ^a	Associated diseases and medication	Symptoms first presentation	Varices, grade:	Spleno-megaly ^b	Ascites ^c	Other complications	Diagnosis pre-OLT
1	M	26–45	ITP	Thrombopaenia	III	Yes	Yes	PVT	Cryptogenic cirrhosis
2	F	23–41	ITP, AIHA	Thrombopaenia	III	N/A ^d	No	HPS, PVT	Cryptogenic cirrhosis
3	M	61–63 ^e	MGUS, AZA, post-OLT	Bleeding varices	I	Yes	Yes	HPS	Cryptogenic cirrhosis
4	F	46–54	MGUS, AZA	Thrombopaenia	I	Yes	Yes	HE	Autoimmune hepatitis
5	M	27–44	Renal Tx, AZA	ELE	III	Yes	Yes	PVT	Cryptogenic cirrhosis
6	M	41–46	UC, AZA, MP	ELE	II	Yes	Yes	SBP, PVT	Alcoholic liver cirrhosis
7	M	26–30	ALL, UC, TG, MTX, cytoxan, doxorubicin	Bleeding varices	I	Yes	No	PVT, HE	Cryptogenic cirrhosis
8	M	24–43	Idiopathic	ELE	II	Yes	No	None	AMA-PBC
9	M	18–22	Idiopathic	ELE	II	Yes	No	HE	Cryptogenic cirrhosis
10	M	27–37	Idiopathic	Bleeding varices	III	Yes	Yes	SBP, HPS, PVT, HE	Alcoholic liver cirrhosis
11	M	60–69	Idiopathic	Bleeding varices	II	Yes	Yes	SBP, PVT	Cryptogenic cirrhosis

AIHA: autoimmune haemolytic anaemia; ALL: acute lymphoblastic leukaemia; AMA-PBC: antimitochondrial antibody-negative primary biliary cirrhosis; AZA: azathioprine; ELE: elevated liver enzymes; F: female; HE: hepatic encephalopathy; HPS: hepatopulmonary syndrome; ITP: immune-mediated thrombocytopenia; M: male; MP: mercaptopurine; MGUS: monoclonal gammopathy of undetermined significance; MTX: methotrexate; PVT: portal vein thrombosis; SBP: spontaneous bacterial peritonitis; TG: thioguanine; Tx: transplantation; UC: ulcerative colitis.

^aAge at first presentation and age of OLT; ^bsplenomegaly was defined as a longest diameter above 11 cm; ^cascites was evaluated using abdominal ultrasound; ^dthis patient underwent a splenectomy prior to the development of NRH; ^ethis patient underwent a liver transplantation for the second time due to NRH.

syndrome. Revision of the histology did not confirm AIH, and AZA was subsequently discontinued. The remaining four patients (36%) were neither diagnosed with an associated disease nor treated with hepatotoxic drugs and presumably developed idiopathic NRH. Three of them (#8–10) were transplanted at a median age of 37 years (22–43 years).

Biochemical and imaging results in the NRH patients

In all patients, laboratory abnormalities were present at time of referral for OLT. As depicted in Table 2, the most frequently described abnormalities were anaemia (10/11, 91%) and thrombocytopenia (10/11, 91%). WBC was mildly increased in one patient. Serum ALT was over two times the upper limit of normal (ULN) in three patients (28%), in which serum AST was ≥ 2 ULN as well. Serum AP was (mildly) increased in eight patients (73%), out of which three patients (28%) had levels ≥ 2 ULN and GGT was ≥ 2 ULN in four patients (36%). Total bilirubin was increased in all patients, out of which eight patients (73%) had levels over two times ULN. The international normalised

ratio was ≥ 1.5 in five patients (46%) and serum creatinine was ≥ 100 $\mu\text{mol/l}$ in three patients (27%).

The MELD scores at time of referral for OLT varied from 8–24 with a median of 18. In all patients Hepatitis B virus (HBV), Hepatitis C virus (HCV) and HIV serology, rheumatoid factor, protein C and antibodies for autoimmune liver diseases were negative. Furthermore, levels of ferritin, copper, α -foetoprotein and $\alpha 1$ -antitrypsin were within normal limits.

In the pre-transplantation course, signs of portal hypertension were observed by imaging methods in all patients, but NCPH and/or NRH was not diagnosed in any of the patients by the radiologist (Table 2). The most frequent characteristics of portal hypertension, detected at US or CT were splenomegaly (10/11, 91%), portal vein thrombosis (7/11, 64%), portosystemic collateral veins (7/11, 64%), ascites (7/11, 64%), heterogeneous liver parenchyma (5/11, 46%) and an atrophic liver (4/11, 36%).

Histological analysis of the explanted livers

Results of histological analysis at liver biopsy before OLT were available in nine patients (absent in #5 and #9).

Table 2. Laboratory and imaging findings in the patients with nodular regenerative hyperplasia (NRH) before orthotopic liver transplantation (OLT).

Case no.	1	2	3	4	5	6	7	8	9	10	11
Laboratory findings (normal value)											
Hb (7.5–11 mmol/l)	8.1	5.9	6.2	6.2	3.8	5.6	6.6	6.2	4.8	6.0	6.1
WBC ($3.5\text{--}10 \times 10^9/\text{l}$)	4.7	2.7	7.7	7.5	13.1	6.6	7.1	2.8	2.7	4.6	6.6
PC ($150\text{--}400 \times 10^9/\text{l}$)	47	30	68	188	75	126	57	38	33	60	81
ALT (<45 U/l)	19	47	42	52	40	118	300	36	582	37	86
AST (<40 U/l)	27	60	78	67	45	131	600	31	438	62	60
AP (<120 U/l)	101	156	276	144	69	133	77	131	1356	267	182
GGT (<55 U/l)	61	149	148	90	56	200	63	44	16	53	218
Bilirubin (<20 $\mu\text{mol/l}$)	24	25	203	23	115	311	47	132	41	60	197
Albumin (35–50 g/l)	38	28	31	28	30	22	15	38	31	24	43
INR	1.3	1.3	1.3	1.1	1.5	1.8	1.3	1.8	1.7	1.5	1.1
Creatinine (50–100 $\mu\text{mol/l}$)	86	40	109	70	216	46	100	52	45	25	95
MELD score	11	11	20	8	26	24	16	21	16	16	26
Findings at US/CT abdomen											
Splenomegaly	Yes	N/A ^a	Yes	Yes	Yes	Yes	Yes	Yes	Yes	Yes	Yes
Ascites	Yes	No	Yes	Yes	Yes	Yes	No	No	No	Yes	Yes
Atrophy liver	Yes	Yes	No	No	No	Yes	No	No	Yes	No	No
Heterogeneous liver	No	No	Yes	Yes	No	Yes	Yes	No	No	No	Yes
PVT	Yes	Yes	No	No	Yes	Yes	Yes	No	No	Yes	Yes
PSCV	Yes	No	No	No	Yes	Yes	Yes	Yes	Yes	Yes	No

ALT: alanine aminotransferase; AP: alkaline phosphatase; AST: aspartate aminotransferase; CT: computed tomography; GGT: gamma-glutamyl transferase; INR: international normalised ratio; Hb: haemoglobin; MELD: Model for End-Stage Liver Disease; N/A: not applicable; PC: platelet count; PSCV: portosystemic collateral veins; PVT: portal vein thrombosis; US: ultrasonography; WBC: white blood cell count.

^aThis patient had a splenectomy in the surgical history.

Table 3. Histopathological findings in the livers at liver biopsy and orthotopic liver transplantation (OLT).

Case no.	Liver biopsy pre-OLT ^a	Histological features explanted liver	Diagnosis	Weight (g)
1	OLT-1: No abnormality	Micronodularity, sinusoidal dilatation, atrophy of hepatocytes and increased hepatocyte layers	Pure NRH	950
2	OLT-6: No abnormality	Micronodularity without fibrosis, dilated intrahepatic veins, atrophic hepatic cell plates, PVT	Pure NRH	760
3	OLT-2: NRH	Micronodularity, sinusoidal dilatation, atrophy of hepatocytes, increased hepatocyte layers, minimal fibrosis ^b	Pure NRH	1352
4	OLT-6: NRH	Nodularity without fibrosis, dilated intrahepatic veins, sinusoidal dilatation and atrophy of hepatocytes	Pure NRH	794
5	Not available	Nodules distinguished by hepatocytes with atrophy, increased hepatocyte layers, minimal fibrosis and sinusoidal dilatation and PVT	Pure NRH	944
6	OLT-5: No cirrhosis	Lesions with sclerosis, obliteration of portal venules and lesions with nodules without fibrosis	NRH co-existing with focal hepatoportal sclerosis	1275
7	OLT-3: No cirrhosis ^c	Micronodularity, minimal fibrosis, sinusoidal dilatation, atrophy of hepatocytes and increased hepatocyte layers	Pure NRH	974
8	OLT-7: NRH	Nodules with incomplete septa, focal lesions of micronodularity, atrophy, increased hepatocyte layers and sinusoidal dilatation	NRH co-existing with focal incomplete septal cirrhosis	1145
9	Not available	Nodules distinguished by hepatocyte with atrophy, increased hepatocyte layers, sinusoidal dilatation and PVT	Pure NRH	1017
10	OLT-5: NRH/PNT	Varying micro- and macronodules with minimal fibrosis, dilated intrahepatic veins, sinusoidal dilatation and PVT	Pure NRH	990
11	OLT-0: No cirrhosis	Micronodularity with minimal fibrosis, increased hepatocyte layers, focal cholestasis and steatosis	NRH with focal hepatitis	1020

NRH: nodular regenerative hyperplasia; PNT: partial nodular transformation; PVT: portal vein thrombosis.

^aOLT-x: x = number of years between the time of liver biopsy and OLT; ^bpatient with re-transplantation due to NRH, the same histological features were seen in the first as second explanted liver; ^cthis patient was treated with methotrexate for acute lymphoblastic leukaemia, there were no signs of liver damage due to methotrexate in particular.

As summarised in Table 3, suggestive presence of NRH was reported by the local pathologist in four patients (4/9; 44%). In three patients (3/9; 33%) histological features of non-cirrhotic liver disease were seen, but NRH was not reported. There were no histological signs of non-cirrhotic liver disease or NRH reported in the liver biopsies of the remaining two patients (2/9; 22%).

Histopathological examination of the explanted livers was performed in all 11 cases. Histological criteria of cirrhosis was lacking in all explanted livers. Explanted livers were atrophic with a mean weight of 1020 ± 110 g. In liver #6 NRH co-existed with focal hepatoportal sclerosis and in liver #8 NRH co-existed with focal incomplete septal cirrhosis. The other nine livers (9/11; 82%) were diagnosed with pure NRH. Dysplasia or neoplasia was not reported in any of the explanted livers.

Post transplantation; mortality and follow-up

Six out of 11 patients (6/11; 55%) are currently alive. Two patients (#2 and #10) died shortly after liver transplantation and three patients died during follow-up

(#1, #3 and #5, median follow up: 10 years). The one-year and five-year survival rate in this population of patients was 82% and 73%, respectively. In all three patients who died within five years after transplantation, HPS co-existed with end-stage liver disease. Clinical follow-up in the nine patients who recovered well from OLT ranged from two months to 21 years, with a median follow-up of four years. These results are summarised in Table 4.

During the follow-up, no acute rejection was observed in any of the patients. Recurrence of severe NCPH complications did occur in patient #3 due to NRH, 14 years after initial OLT. In the 14 months after his second OLT, no recurrence of liver disease has been observed. Complications of NCPH did not re-occur in the other patients, nor was histological recurrence of NRH observed in the patients who underwent liver biopsy.

Discussion

This is the largest study reported to date, describing the number of patients transplanted due to

Table 4. The post-transplantation course in the patients with nodular regenerative hyperplasia (NRH).

Case no.	Post transplantation course	Status	Follow-up (time in months)	Recurrence NRH
1	Successful recovery, normal follow-up, died 10 years after OLT	Dead	118	No
2	Died seven days after OLT due to ARDS	Dead	-	-
3	Died 14 months after OLT due to cerebral haemorrhage	Dead	14	Yes ^a
4	Successful recovery, normal follow-up	Alive	2	No
5	Relaparotomy due to leakage, normal follow-up, died 15 years after OLT	Dead	180	No
6	Relaparotomy due to leakage, normal follow-up	Alive	6	No
7	Successful recovery, normal follow-up	Alive	187	No
8	Prolonged recovery due to anastomotic stenosis, suspected sarcoidosis	Alive	44	No
9	Successful recovery, normal follow up	Alive	248	No
10	Relaparotomy due to leakage, died 2 months after OLT due to sepsis	Dead	-	-
11	TB in transplanted liver activated in 4 months after OLT	Alive	31	No

ARDS: acute respiratory distress syndrome; OLT: orthotopic liver transplantation; TB: tuberculosis.

^aThis patient had a recurrence of symptomatic NRH at 14 years after first liver transplantation, there was no recurrence of NRH after second OLT.

NRH-syndrome in a 20-year cohort study amongst all liver transplant centres in the Netherlands. Out of 1886 performed liver transplantations, records of 255 patients who underwent OLT for NRH, non-cirrhotic or cryptogenic liver disease were scrutinised. Eleven patients with NRH on histological evaluation of their explanted livers were identified, suggesting a percentage of 0.6% of liver transplantations due to NRH-syndrome based on nationwide pathology data.

We reported clinical, biochemical, radiological and histological findings of 11 patients and their explanted livers. A male predominance (9/11; 82%) with a median age of 44 years at OLT was detected, similar to the numbers which are reported on NRH and liver transplantation in the literature.^{21–23} This male predominance in severe NRH-syndrome needing OLT has been reported before, however the explanation remains unclear. All our presented patients had a progressive clinical course including severe complications of NCPH. The abnormalities in biochemical and imaging studies were not suggestive for NCPH or NRH and all of our patients were presumed to have liver cirrhosis in the pre-transplantation course. The majority of our patients (55%) did not have elevated liver enzymes, but anaemia (91%) and thrombocytopenia (91%) were present in almost all of them. Six patients (55%) had portal vein thrombosis alongside NRH, which is consistent with other reports showing coagulation disorders in NRH patients.²⁴

To our knowledge, this is the first study describing the number of patients transplanted due to NRH-syndrome in a nationwide database of liver transplants in The Netherlands in a time period of over 20 years. Comparable studies assessed smaller cohorts

(maximum of four patients) and a review described 33 patients transplanted due to NRH-syndrome^{19,31–34} as depicted in Table 5.

The MELD score at referral for OLT was highly variable and varied from 8–24, without predicting progression and severity of NRH-syndrome, probably due to the fact that liver synthesis function in NRH patients remains normal in severe NRH, which was underlined in the systematic review on liver transplantation for NRH by Manzia et al.¹⁹ before. One of the suggestions for further research is to determine mortality in NRH patients on the waiting list for liver transplantation, to justify modifying the MELD score for NRH patients.

Histological NRH is associated with several autoimmune diseases and drug exposure. Interestingly, not all patients in our cohort had a medical history of diseases and/or drug use related to NRH and we presume that NRH occurred idiopathically in some of the patients (36%). Five patients (45%) were treated with chemotherapy and thiopurines, in line with other reports.^{10,11,35} In one of these studies, an NRH incidence rate of 62% in patients treated with high-dose TG was reported and it was concluded that TG should not be considered as a therapy for patients with inflammatory bowel disease (IBD).¹⁰ However, in some studies, it was shown that the formation of NRH appears to be dose dependent and that histopathological liver abnormalities are relatively common in IBD patients, even without exposure to thiopurines.^{36–38} Lastly, two of our patients were known with immune-mediated thrombocytopenia (ITP) without exposure to thiopurines or other NRH-related drugs, a relation which has been described previously.³⁹

Table 5. Published studies on patients transplanted due to nodular regenerative hyperplasia (NRH) and their patient characteristics.

Authors	Year	<i>n</i>	Sex	Age ^a	Follow-up (months)	Status	Risk factors
McDonald et al. ¹³	1990	1	M	47	4	Dead	Alo, NepS
Elariny et al. ²⁵	1994	1	F	44	24	Alive	HepC, HS
Gane et al. ²⁶	1994	3	M	23	-	Alive	AZA
			F	20	-	Alive	AZA
			F	28	-	Alive	AZA
Loinaz et al. ²²	1998	4	M	37	84	Alive	Alcohol
			M	41	65	Alive	AZA
			M	37	3	Dead	HepC
			M	25	1	Dead	None
Dumortier et al.	1999	2	M	59	33	Alive	None
			M	40	10	Alive	None
Radomski et al. ²¹	2000	4	M	45	48	Alive	None
			M	48	46	Alive	None
			M	54	43	Alive	None
			F	39	24	Alive	None
Dumortier et al. ²³	2001	3	M	49	102	Alive	Unknown ^b
			M	41	24	Alive	Unknown ^b
			M	63	48	Alive	Unknown ^b
Jawaid et al. ²⁷	2003	1	M	51	24	Alive	None
Buchel et al. ²⁸	2005	1	M	51	24	Alive	HHC
Krasinskas et al. ^{34 c}	2005	-	-	-	-	-	-
Devarbhavi et al. ²⁹	2007	3	F	55	-	Dead	Tac/P/MMF
			M	56	1	Dead	Cys/P/AZA
			M	48	48	Alive	Cys/P/AZA
Tateo et al. ³⁰	2008	3	F	38	9	Alive	HAART
			F	38	4	Alive	HAART
			M	43	7	Alive	HAART
Maganty et al. ³¹	2011	1	F	26	15	Alive	None
Sultanik et al. ³²	2013	4	F	38	77	Alive	HAART
			F	38	9	Dead	HAART
			M	43	63	Alive	HAART
			M	44	27	Alive	HAART
Gorgy et al. ³³	2015	2	M	35	7	Dead	STS
			M	39	1	Dead	STS

Alo: alopecia totalis; AZA: azathioprine; Cys: cyclosporin; F: female; HAART: highly active anti-retroviral therapy; HepC: chronic hepatitis C infection; HHC: hyperhomocysteinaemia; HS: haemosiderosis; M: male; MMF: micophenolate mofetil; NepS: nephrotic syndrome; P: prednisone; STS: short telomere syndrome; Tac: tacrolimus.

This table is modified from the systematic review on liver transplantation for NRH by Manzia et al.¹⁹ and completed till April 2016 with the studies by Maganty et al.,²⁵ Sultanik et al.,²⁶ Gorgy et al.²⁷ and Krasinskas et al.²⁸

^aAge at time of liver transplantation; ^brisk factors not mentioned in article; ^cthis study was neither included in the systematic review by Manzia et al., nor in our analysis due to the lack of significant data.

One of the limitations of our study design is the fact that we recruited our patients based on the histological evaluations made by the pathologists on location in the participating centres. Whereas all our included patients had symptoms of portal hypertension, the histological diagnosis of NRH remains challenging due to different

interpretations of histological features by pathologists, as demonstrated in a study by Jharap et al.¹⁵ For our study, we did not histologically reassess the explanted liver specimens of our patients. Reviewing the liver specimens by an experienced pathologist would improve the methodological power of this study.

In our study, we determined a small number (0.6%) of patients transplanted due to NRH-syndrome, which is lower than reported in several other studies, especially in thiopurine users.^{10,11,35} Many of these studies reported the incidence rate of histological NRH, which was not associated with a clinically significant liver disease.^{4,40} However, our study is not comparable to these studies since we only assessed patients with a clinically significant liver disease needing OLT. Nevertheless, some patients with NRH-syndrome are appropriate candidates for liver transplantation, but may have absolute or relative contraindications for OLT. These individuals were not included in our study, probably leading to selection bias and an underestimation of the incidence of disease.

Conclusion

In conclusion, a small number of patients, predominantly young males, were transplanted due to severe NRH-syndrome, concluding that this is a rare treatment indication for liver transplantation. The clinical manifestation of progressive NRH-syndrome is mainly revealed by severe complications of portal hypertension. Furthermore, non-specific abnormalities in laboratory parameters and imaging studies could reveal the presence of NRH. Whilst it is known that NRH is associated with several diseases and drugs, the diagnosis should also be considered in patients without a related medical history. Liver transplantation may have an important role in NRH-syndrome but vigilance is required, especially in patients suffering from HPS and other severe portal hypertension complications.

Acknowledgements

NdB designed and was the guarantor of the article. RdM, MC, HB, GD and MS collected the data. BM and MS drafted the first manuscript of the article. RdM, MC, HB, GD, CvN, CM and NdB critically revised the manuscript. BM completed the manuscript after author's revisions. All authors agreed to the final version of the manuscript.

Conflicts of interest

None declared.

Funding

This research received no specific grant from any funding agency in the public, commercial, or not-for-profit sectors.

References

- Naber AH, Van Haelst U and Yap SH. Nodular regenerative hyperplasia of the liver: An important cause of portal hypertension in non-cirrhotic patients. *J Hepatol* 1991; 12: 94–99.
- Steiner PE. Nodular regenerative hyperplasia of the liver. *Am J Pathol* 1959; 35: 943–953.
- Reshamwala PA, Kleiner DE and Heller T. Nodular regenerative hyperplasia: Not all nodules are created equal. *Hepatology* 2006; 44: 7–14.
- Van Asseldonk DP, Jharap B, Verheij J, et al. The prevalence of nodular regenerative hyperplasia treated with thioguanine in inflammatory bowel disease is not associated with clinical significance. *Inflamm Bowel Dis* 2016; 22: 2112–2120.
- Wanless IR, Godwin TA, Allen F, et al. Nodular regenerative hyperplasia of the liver in hematologic disorders: A possible response to obliterative portal venopathy. A morphometric study of nine cases with an hypothesis on the pathogenesis. *Medicine (Baltimore)* 1980; 59: 367–379.
- Hartleb M, Gutkowski K and Milkiewicz P. Nodular regenerative hyperplasia: Evolving concepts on underdiagnosed cause of portal hypertension. *World J Gastroenterol* 2011; 17: 1400–1409.
- Sood A, Castrejon M and Saab S. Human immunodeficiency virus and nodular regenerative hyperplasia of liver: A systematic review. *World J Hepatol* 2014; 6: 55–63.
- Takaya H, Kawaratani H, Nakanishi K, et al. Development of nodular regenerative hyperplasia (NRH) with portal hypertension following the administration of oxaliplatin for the recurrence of colon cancer. *Intern Med* 2015; 54: 383–387.
- Gisbert JP, Gonzalez-Lama Y and Mate J. Thiopurine-induced liver injury in patients with inflammatory bowel disease: A systematic review. *Am J Gastroenterol* 2007; 102: 1518–1527.
- Dubinsky MC, Vasiliauskas EA, Singh H, et al. 6-Thioguanine can cause serious liver injury in inflammatory bowel disease patients. *Gastroenterology* 2003; 125: 298–303.
- Vernier-Massouille G, Cosnes J, Lemann M, et al. Nodular regenerative hyperplasia in patients with inflammatory bowel disease treated with azathioprine. *Gut* 2007; 56: 1404–1409.
- Arvanitaki M and Adler M. Nodular regenerative hyperplasia of the liver. A review of 14 cases. *Hepato-gastroenterology* 2001; 48: 1425–1429.
- McDonald JA, Painter DM, Gallagher ND, et al. Nodular regenerative hyperplasia mimicking cirrhosis of the liver. *Gut* 1990; 31: 725–727.
- International Working Party. Terminology of nodular hepatocellular lesions. *Hepatology* 1995; 22: 983–993.
- Jharap B, van Asseldonk DP, de Boer NK, et al. Diagnosing nodular regenerative hyperplasia of the liver is thwarted by low interobserver agreement. *PLoS One* 2015; 10: e0120299.
- Wanless IR. Micronodular transformation (nodular regenerative hyperplasia) of the liver: A report of 64 cases among 2,500 autopsies and a new classification of benign hepatocellular nodules. *Hepatology* 1990; 11: 787–797.
- Colina F, Alberti N, Solis JA, et al. Diffuse nodular regenerative hyperplasia of the liver (DNRH). A clinicopathologic study of 24 cases. *Liver* 1989; 9: 253–265.

18. Morikawa S, Kumada K, Fukui K, et al. Closure of interposition mesocaval shunt in a case of idiopathic portal hypertension. *Am J Gastroenterol* 1989; 84: 548–551.
19. Manzia TM, Gravante G, Di Paolo D, et al. Liver transplantation for the treatment of nodular regenerative hyperplasia. *Dig Liver Dis* 2011; 43: 929–934.
20. Buster EH, van Vuuren HJ, Zondervan PE, et al. Thiopurine-methyltransferase and inosine triphosphate pyrophosphatase polymorphism in a liver transplant recipient developing nodular regenerative hyperplasia on low-dose azathioprine. *Eur J Gastroenterol Hepatol* 2008; 20: 68–72.
21. Radomski JS, Chojnacki KA, Moritz MJ, et al. Results of liver transplantation for nodular regenerative hyperplasia. *Am Surg* 2000; 66: 1067–1070.
22. Loinaz C, Colina F, Musella M, et al. Orthotopic liver transplantation in 4 patients with portal hypertension and non-cirrhotic nodular liver. *Hepato-gastroenterology* 1998; 45: 1787–1794.
23. Dumortier J, Bizollon T, Scoazec JY, et al. Orthotopic liver transplantation for idiopathic portal hypertension: Indications and outcome. *Scand J Gastroenterol* 2001; 36: 417–422.
24. Barge S, Grando V, Nault JC, et al. Prevalence and clinical significance of nodular regenerative hyperplasia in liver biopsies. *Liver Int* 2015; 36: 1059–1066.
25. Elariny HA, Mizrahi SS, Hayes DH, et al. Nodular regenerative hyperplasia: a controversial indication for orthotopic liver transplantation. *Transpl Int* 1994; 7: 309–313.
26. Gane E, Portmann B, Saxena R, et al. Nodular regenerative hyperplasia of the liver graft after liver transplantation. *Hepatology* 1994; 20(1 Pt 1): 88–94.
27. Jawaid Q, Saeed ZA, Di Bisceglie AM, et al. Biliary-venous fistula complicating transjugular intrahepatic portosystemic shunt presenting with recurrent bacteremia, jaundice, anemia and fever. *Am J Transplant* 2003; 3: 1604–1607.
28. Buchel O, Roskams T, Van Damme B, et al. Nodular regenerative hyperplasia, portal vein thrombosis, and avascular hip necrosis due to hyperhomocysteinaemia. *Gut* 2005; 54: 1021–1023.
29. Devarbhavi H, Abraham S and Kamath PS. Significance of nodular regenerative hyperplasia occurring de novo following liver transplantation. *Liver Transpl* 2007; 13: 1552–1556.
30. Tateo M, Sebagh M, Bralet MP, et al. A new indication for liver transplantation: nodular regenerative hyperplasia in human immunodeficiency virus-infected patients. *Liver Transpl* 2008; 14: 1194–1198.
31. Maganty K, Ghanta R, Bejarano P, et al. Liver transplantation for hepatopulmonary syndrome due to noncirrhotic portal hypertension. *Transplant Proc* 2011; 43: 2814–2816.
32. Sultanik P, Coilly A, Sebagh M, et al. Lengthy follow-up after liver transplantation for nodular regenerative hyperplasia in human immunodeficiency virus-infected patients: Does the disease recur? *Transplantation* 2013; 96: e79–e81.
33. Gorgy AI, Jonassaint NL, Stanley SE, et al. Hepatopulmonary syndrome is a frequent cause of dyspnea in the short telomere disorders. *Chest* 2015; 148: 1019–1026.
34. Krasinskas AM, Egthesad B, Kamath PS, et al. Liver transplantation for severe intrahepatic noncirrhotic portal hypertension. *Liver Transpl* 2005; 11: 627–634; discussion: 610–11.
35. De Boer NK, van Bodegraven AA, Jharap B, et al. Drug insight: Pharmacology and toxicity of thiopurine therapy in patients with IBD. *Nat Clin Pract Gastroenterol Hepatol* 2007; 4: 686–694.
36. De Boer NK, Tuynman H, Bloemena E, et al. Histopathology of liver biopsies from a thiopurine-naïve inflammatory bowel disease cohort: Prevalence of nodular regenerative hyperplasia. *Scand J Gastroenterol* 2008; 43: 604–608.
37. De Boer NK, Zondervan PE, Gilissen LP, et al. Absence of nodular regenerative hyperplasia after low-dose 6-thioguanine maintenance therapy in inflammatory bowel disease patients. *Dig Liver Dis* 2008; 40: 108–113.
38. Gisbert JP, Luna M, Gonzalez-Lama Y, et al. Liver injury in inflammatory bowel disease: Long-term follow-up study of 786 patients. *Inflamm Bowel Dis* 2007; 13: 1106–1114.
39. Mahamid J, Misevich I, Attias D, et al. Nodular regenerative hyperplasia associated with idiopathic thrombocytopenic purpura in a young girl: A case report and review of the literature. *J Pediatr Gastroenterol Nutr* 2005; 41: 251–255.
40. Van Asseldonk DP, Jharap B, Kuik DJ, et al. Prolonged thioguanine therapy is well tolerated and safe in the treatment of ulcerative colitis. *Dig Liver Dis* 2011; 43: 110–115.