


# Evaluation of treatment results in multifocal primary cutaneous anaplastic large cell lymphoma: report of the Dutch Cutaneous Lymphoma Group

R.C. Melchers <sup>1</sup>, R. Willemze,<sup>1</sup> M.W. Bekkenk,<sup>2</sup> E.R.M. de Haas,<sup>3</sup> B. Horvath,<sup>4</sup> M.M. van Rossum,<sup>5</sup> C.J.G. Sanders,<sup>6</sup> J.C.J.M. Veraart,<sup>7</sup> M.H. Vermeer<sup>1</sup> and K.D. Quint<sup>1</sup>

<sup>1</sup>Department of Dermatology, Leiden University Medical Center, the Netherlands

<sup>2</sup>Department of Dermatology, Academic Medical Center and Vrije University Medical Center, Amsterdam, the Netherlands

<sup>3</sup>Department of Dermatology, Erasmus Medical Center, Rotterdam, the Netherlands

<sup>4</sup>Department of Dermatology, University Medical Center of Groningen, the Netherlands

<sup>5</sup>Department of Dermatology, Radboud University Medical Center, Nijmegen, the Netherlands

<sup>6</sup>Department of Dermatology, University Medical Center Utrecht, the Netherlands

<sup>7</sup>Department of Dermatology, Maastricht University Medical Center, the Netherlands

**Linked Comment:** Kempf. *Br J Dermatol* 2018; **179**:565–566.

## Summary

### Correspondence

Rutger C. Melchers.

E-mail: r.c.melchers@lumc.nl

### Accepted for publication

22 February 2018

### Funding sources

None.

### Conflicts of interest

None to declare.

DOI 10.1111/bjd.16501

**Background** There is no consensus on the treatment of multifocal primary cutaneous anaplastic large cell lymphoma (C-ALCL). Radiotherapy (RT) and methotrexate (MTX) are the current treatment options, but their efficacy is unknown. Recently, targeted therapies showed promising results in C-ALCL, and may therefore be an attractive first choice of treatment.

**Objectives** To assess the efficacy of conventional treatment strategies for patients with multifocal C-ALCL, and to define which patients may require novel targeted therapies.

**Methods** In this multicentre study, treatment was evaluated in patients initially presenting ( $n = 24$ ) or relapsing with multifocal C-ALCL ( $n = 17$ ; 23 relapses). Distinction was made between patients with five or less lesions ( $n = 36$ ) and more than five lesions ( $n = 11$ ).

**Results** Treatments most commonly used were RT ( $n = 21$ ), systemic chemotherapy ( $n = 9$ ) and low-dose MTX ( $n = 7$ ) with complete response rates of 100%, 78% and 43%, respectively, and an overall response rate of 100%, 100% and 57%, respectively. Four patients showed complete spontaneous regression. In total, 16 of 24 patients (67%) first presenting with multifocal C-ALCL relapsed, including all five patients initially treated with CHOP (cyclophosphamide, hydroxydaunorubicin, oncovin and prednisone). Compared with patients presenting with two to five skin lesions, patients presenting with more than five lesions had a higher chance of developing extracutaneous relapse (56% vs. 20%) and more often died of lymphoma (44% vs. 7%).

**Conclusions** Patients with five or less lesions should be treated with low-dose RT ( $2 \times 4$  Gy). Maintenance low-dose MTX (20 mg weekly) is a suitable option in patients with more than five lesions. Targeted therapies may be considered in rare patients who are refractory to MTX or patients developing extracutaneous disease.

### What's already known about this topic?

- There is no consensus on the treatment of multifocal primary cutaneous anaplastic large cell lymphoma (C-ALCL).
- New targeted therapies are evaluated without knowledge of the efficacy of conventional therapies.

### What does this study add?

- This study evaluated the efficacy of conventional therapies for multifocal C-ALCL.
- Radiotherapy and low-dose methotrexate are suitable options in patients with five or less and more than five lesions, respectively.
- Targeted therapies may be considered in rare patients who are refractory to methotrexate or developing extracutaneous disease.

Primary cutaneous anaplastic large cell lymphoma (C-ALCL) is an indolent T-cell lymphoma, comprising about 10% of all cutaneous T-cell lymphomas.<sup>1</sup> Most patients present with solitary or localized nodules or tumours, which often show ulceration.<sup>2</sup> Approximately 15–20% of the patients with C-ALCL present with multifocal lesions involving multiple anatomical areas.<sup>2–4</sup> Although there is broad consensus that radiotherapy is the first choice of treatment in solitary or localized C-ALCL, there is uncertainty about the optimal treatment of patients with multifocal C-ALCL.<sup>1,2,5–8</sup> Initial studies suggested that these patients should be treated with doxorubicin-based chemotherapy.<sup>9</sup> However, in more recent studies of our group, it was found that all patients treated with multiagent chemotherapy developed relapses during follow-up.<sup>2</sup> It was therefore concluded that multiagent chemotherapy should no longer be considered as first-choice therapy in patients with multifocal C-ALCL, but should be reserved for patients developing extracutaneous disease.<sup>2</sup> In that study, in which 17 of 79 patients presented with multifocal C-ALCL, we suggested that patients with multifocal C-ALCL can best be treated with radiotherapy in the case of few lesions or with low-dose methotrexate (MTX) in the case of more widespread disease.<sup>2</sup> These guidelines were adopted by the International Society for Cutaneous Lymphomas and by the European Society for Medical Oncology, but have not been substantiated by further publications.<sup>5,10</sup> In particular, studies on MTX are scarce and restricted to a few case reports.<sup>11–14</sup>

Recent studies reported high response rates to brentuximab vedotin (BV), an antibody–drug conjugate composed of an anti-CD30 monoclonal antibody conjugated to the microtubule-disrupting agent monomethyl auristatin E, in the treatment of primary cutaneous CD30-positive lymphoproliferations.<sup>7,15–20</sup> Consequently, National Comprehensive Cancer Network guidelines have already incorporated BV as a primary treatment option in multifocal C-ALCL.<sup>21</sup> However, to decide which treatment should be selected, it is essential that more data on the results of treatments currently used for multifocal C-ALCL be made available. In the present study we therefore evaluated the treatment results of 35 patients initially presenting with multifocal C-ALCL or relapsing with multifocal skin lesions. The main goal of this study was to define which patients with multifocal C-ALCL should be treated with conventional therapies, and which patients may require novel targeted therapies. In

addition, long-term follow-up data of 24 patients with multifocal C-ALCL at first presentation are presented.

## Patients and methods

### Patient selection

From 283 patients with C-ALCL, who had been included in the Dutch registry for cutaneous lymphomas between October 1985 and December 2016, 28 patients (10%) presented with skin lesions on multiple anatomical regions. After exclusion of patients with an ALK-positive C-ALCL ( $n = 1$ ), insufficient follow-up data ( $n = 1$ ), underlying immunodeficiency ( $n = 1$ ) or patients who had died before initial therapy ( $n = 1$ ), 24 patients with multifocal C-ALCL at first presentation were selected for the present study. Furthermore, we selected 17 patients who developed multifocal skin relapses ( $n = 23$ ) during follow-up. This group included six of the initial 24 patients, who developed multifocal relapses 4–78 months (median, 20 months) after initial treatment, and 11 patients, who relapsed with multifocal skin lesions 3–96 months (median, 13 months) after initial treatment with excision or radiotherapy for a solitary lesion.

A total of 23 histologically confirmed skin relapses without concurrent extracutaneous localizations were included: 14 of 17 patients experienced one multifocal skin relapse and three patients had each of two, three or four multifocal skin relapses, respectively. All multifocal relapses occurred at different localizations and at least 3 months after preceding lesions, and thus were not considered as continuations of previous treatment. In all cases, the diagnosis was made by an expert panel of dermatologists and pathologists of the Dutch Cutaneous Lymphoma Group and all cases met the clinicopathologic criteria of the World Health Organization–European Organization for Research and Treatment of Cancer classification.<sup>1</sup>

Extracutaneous disease was excluded by routine staging procedures, including complete blood count, biochemical analysis, computed tomography scan of chest, abdomen and neck and, if applicable, bone marrow examination. None of the patients showed waxing and waning of the lesions, characteristic of lymphomatoid papulosis (LyP). Follow-up data, which are collected yearly by the Dutch Cutaneous Lymphoma group, were retrieved from the Dutch registry of cutaneous lymphomas or, if incomplete, from referring medical centres.

The following characteristics were recorded: age at time of diagnosis, sex, type and number of skin lesions, spontaneous remission, type and result of treatment, occurrence and site of relapse and status at the time of last follow-up. Using the TNM classification for primary cutaneous lymphomas other than mycosis fungoides and Sézary syndrome, distinction was made between stage T3a (multiple lesions involving two non-contiguous body regions) and T3b (multiple lesions involving three or more body regions).<sup>22</sup> For the purpose of this study, the number of skin lesions was scored as 2, 3–5, 6–10 and > 10. However, few clustered lesions fitting within a radiation field with a diameter of 15 cm were not counted separately, but considered as one lesion. Since patients with up to five lesions are still considered eligible for radiotherapy, distinction was made between multifocal C-ALCL with two to five lesions and multifocal C-ALCL with more than five lesions.

Response assessments were performed 4–6 weeks after treatment and follow-up visits were scheduled every 3–6 months, and more frequently during chemotherapy. Complete response (CR) was defined as complete disappearance of the skin lesions, partial response (PR) as > 50% regression of the skin lesions, stable disease was defined as < 50% regression or < 25% increase of the skin lesions and progressive disease as > 25% increase in skin lesions. CR and PR were taken together as overall response. This retrospective study was evaluated by the ethics committee of the Leiden University Medical Center and provided with a waiver of consent.

## Results

### Multifocal cutaneous anaplastic large cell lymphoma at first presentation (*n* = 24)

#### Clinical characteristics

Main clinical characteristics of the 24 patients initially presenting with multifocal lesions are summarized in Table 1, and presented in more detail in Table 2. The study group included 19 men and five women with a median age at diagnosis of 56 years (range, 25–88 years). Fifteen of 24 patients had two to five lesions and nine patients had more than five lesions at first presentation. Most patients presented with mainly tumorous lesions (*n* = 18), three patients with plaques and three patients had papules without waxing and waning typical of LyP. Skin lesions were located on the trunk (*n* = 13), arms (*n* = 17), legs (*n* = 15) and on the head/neck to a lesser extent (*n* = 6). Partial or even complete spontaneous regression of all skin lesions was observed in seven and four patients, respectively.

#### Treatment response

The type and result of initial treatment are presented in Tables 2 and 3. Initial therapy consisted of radiotherapy in seven patients, low-dose MTX in four patients and multiagent chemotherapy with CHOP (cyclophosphamide, hydroxydaunorubicin, oncovin and prednisone) in five patients. All

**Table 1** Clinical characteristics of patients initially presenting with multifocal cutaneous anaplastic large cell lymphoma (*n* = 24)

Characteristic	Variable
Sex, men : women	19 : 5
Age, years	
Median	56
Range	25–88
Spontaneous remission	
Partial	7 (29)
Complete	4 (17)
Number of skin lesions	
2	6
3–5	9
6–10	4
> 10	5
T-score <sup>a</sup>	
3a	12
3b	12
Initial therapy	
CHOP (like)	5
Radiotherapy (+ excision)	7
Methotrexate	4
Other	4
None (spontaneous remission)	4
Results of initial therapy	
Complete response	20 (83)
Partial response	2 (8)
No response/progression	2 (8)
Relapse	
No relapse	8 (33)
Skin only	8 (33)
Skin and extracutaneous disease	8 (33)
Current status	
Alive without disease	12 (50)
Alive with disease	4 (17)
Died of lymphoma	5 (21)
Died of other cause	3 (12)
Median follow-up, months (range)	44 (11–283)
5-year disease-specific survival, %	78
5-year overall survival, %	66

Values are *n* (%) unless otherwise indicated. CHOP, cyclophosphamide, hydroxydaunorubicin, oncovin and prednisone. <sup>a</sup>T-score from the TNM classification for primary cutaneous lymphomas other than mycosis fungoides and Sézary syndrome;<sup>22</sup> T3, generalized skin lesions involving 2 (T3a) or ≥ 3 (T3b) noncontiguous body regions.

seven patients treated with radiotherapy (median dose: 25 Gy; range: 8–40 Gy) had presented with less than five lesions and CR was observed in all of them. Also, all five patients treated with CHOP courses reached CR. Treatment with low-dose MTX (median dose: 23.75 mg, range: 10–35 mg) resulted in CR in one of four patients and a PR in another (Fig. 1). Remaining patients were variously treated with psoralen–ultraviolet A (PUVA) (*n* = 2; 1 CR, 1 PR), etoposide (*n* = 1; CR) or excision (*n* = 1; CR) (Table 2). Four patients, including two patients presenting with more than five lesions, showed complete remission of all lesions without any treatment 4, 4, 8 and 20 weeks after initial presentation.

Table 2 Clinical characteristics initial multifocal cutaneous anaplastic large cell lymphoma (n = 24)

Patient	Sex	Age, years	Clinical presentation <sup>a</sup>	Spontaneous regression	Received therapy	Result therapy	Relapse/progression (months)	Follow-up (months)
1	M	55	> 10 partial ulcerating tumours and papules/plaques on the extremities and lower back (T3b)	Partial	CHOP	CR	Skin (10), lymph node (38), pulmonary (40)	D+ (42)
2	M	56	Tumour left axilla, right forearm and elbow (T3a)	No	CHOP	CR	Skin (19)	Ao (118)
3	M	38	4 papules on left knee, left side, bilateral glute (T3b)	Partial	PUVA	PR	Skin (13) and lymph node (15)	Ao (168)
4	M	54	8 ulcerating tumours on the back and upper arms (T3b)	No	CHOP+RT	CR	Skin (12), skin (60), lymph node (115), pulmonary (120)	D+ (132)
5	M	31	Ulcerating tumour right hand, right upper arm, left foot (T3b)	Complete	Expectative	CR	No	Ao (72)
6	M	88	30 partial ulcerating papules and tumours trunk and arms (T3b)	No	Etoposide	CR	No	Do (19)
7	F	40	Tumour on left shoulder, two plaques back and left arm (T3a)	No	CHOP	CR	Skin (13), lymph node (133)	Ao (283)
8	M	46	Ulcerating tumour right wrist, papule right knee and groin (T3a)	No	RT	CR	Skin (13)	Ao (61)
9	F	85	Tumour left upper arm and tumour right gluteus (T3a)	No	RT	CR	No	Ao (21)
10	M	57	Plaque head and papules right axilla (T3a)	No	CHOP	CR	Skin (20)	Ao (46)
11	M	25	Tumour left eye, abdominal, back and left side (T3b)	Partial	MTX 25 mg	CR	Skin (18)	A+ (19)
12	M	40	10 papules and tumours on trunk, arms and legs (T3b)	Complete	Expectative	CR	No	Ao (164)
13	M	44	8 partial ulcerating tumours left hand, left forearm, left axilla and left forehead (T3b)	Complete	Expectative	CR	Skin (18), skin (78) lymph node (78)	A+ (205)
14	F	86	Tumour left elbow and right upper leg (T3a)	Partial	RT leg	CR	Skin (19)	Do (21)
15	F	85	Disseminated plaques on trunk, arms and legs (T3b)	No	PUVA	CR	No	Do (25)
16	M	65	Ulcerating tumours trunk, arms and legs (T3b)	Partial	MTX 22.5 mg	SD	Skin and lymph node (8)	D+ (24)
17	M	63	2 ulcerating tumours parietal right and right groin (T3a)	No	Excision	CR	Skin (4), skin and lymph node (31)	D+ (32)
18	M	45	6 partial ulcerating papules, lower leg, lower back (T3b)	No	MTX 7.5–35 mg	PD	Skin (5), pulmonary and renal (13)	D+ (20)
19	M	80	3 tumours neck, occipital, left arm (T3a)	Partial	RT and excision	CR	Skin (10)	Ao (27)
20	M	50	3 plaques right knee, upper right leg, upper right arm (T3a)	Complete	Expectative	CR	No	Ao (55)
21	M	79	6 localized papules right knee and papule abdominal (T3a)	No	RT and excision	CR	No	Ao (50)
22	M	59	Tumour right knee and papule right wrist (T3a)	No	RT	CR	Skin (12)	Ao (48)
23	F	61	Tumour and plaque upper left leg, papule on left shoulder and upper right arm (T3a)	No	RT	CR	Skin (5)	A+ (40)
24	M	27	> 30 partial ulcerating tumours disseminated over body (T3b)	Partial	MTX 10 mg	PR	–	A+ (11)

M, male; F, female; CHOP, cyclophosphamide, hydroxydaunorubicin, oncovin and prednisone; RT, local radiotherapy; MTX, methotrexate; PUVA, psoralen–ultraviolet A; CR, complete response; PR: partial response; Ao, alive without lymphoma; A+, alive with lymphoma; Do, died of unrelated disease; D+, died of lymphoma; SD, stable disease; PD, progressive disease. <sup>a</sup>T-score from the TNM classification for primary cutaneous lymphomas other than mycosis fungoides and Sézary syndrome;<sup>22</sup> T3, generalized skin lesions involving 2 (T3a) or ≥ 3 (T3b) noncontiguous body regions.

## Follow-up

During follow-up, 16 of 24 patients (67%) developed one or multiple cutaneous relapses, including all five patients initially treated with CHOP (Table 2). Eight of these 16 patients developed extracutaneous disease as well. Median time to relapse was 12.5 months (range, 4–20 months). Compared with patients presenting with two to five lesions, patients presenting with more than five lesions more often developed extracutaneous disease (3/15 patients; 20% vs. 5/9 patients; 56%) and more often died of lymphoma (1/15 patients; 7% vs. 4/9 patients; 44%). Interestingly, three of four patients with complete spontaneous resolution of all skin lesions did not show relapse 32, 53 and 72 months after diagnosis. After a median follow-up of 44 months, 12 patients were alive without disease, four patients were alive with disease, five patients died of their lymphoma and three patients died of another cause. Five-year disease-specific survival (DSS) was 78%, five-year overall survival (OS) was 66%, and median time to progression (development of extracutaneous disease) was 34.5 months (range 8–133 months).

## Multifocal relapse (n = 23)

Results of treatment of 23 multifocal skin relapses in 17 patients with C-ALCL were evaluated. In total, 21 of 23 relapses presented in individuals with five or less lesions. Radiotherapy (median dose: 20 Gy; range: 8–40 Gy) was used in 14 of 21 cases relapsing with two to five skin lesions and resulted in CR in all of them. Three patients were treated with MTX, resulting in a CR in two patients and stable disease in one patient. Treatment with CHOP showed two CRs and two PRs. Treatment of the remaining two patients, both presenting with three distant skin lesions, with acitretin or intralesional steroids resulted in PR and CR, respectively.

## Cumulative results of treatment

Cumulative results of treatment of 47 clinical presentations of multifocal C-ALCL, including 24 at first presentation and 23 during follow-up are presented in Table 4. Multifocal C-ALCL concerned two to five skin lesions in 36 patients and more than five lesions in 11 patients. Local radiotherapy, in some

cases combined with excision, was used in 21 of 36 patients presenting with two to five lesions and resulted in CR in all of them. Methotrexate was administered to seven individuals, including four with five or less lesions, and showed a CR rate and an overall response rate (ORR) of 43% and 57%, respectively. Seven patients, including four with more than five lesions, received maintenance treatment with MTX for 6–23 months (median, 10.5 months).

The results showed a CR in three of seven patients and a PR in one of seven patients (ORR 57%), whereas the effect was insufficient in the other three patients. From the four responders, two patients, including the patient with PR still receive low-dose MTX, one patient developed a skin relapse 18 months after cessation of MTX treatment, which was successfully treated with radiotherapy, and one patient has been in complete remission for 24 months after cessation of MTX treatment. CHOP was used in nine patients and resulted in a CR in seven of nine patients (78%) and PR in the other two patients. Remaining patients were treated with PUVA (n = 2; 1 CR and 1 PR), etoposide (n = 1; CR), acitretin (n = 1; PR), excision (n = 1; CR), intralesional corticosteroids (n = 1; CR) or did not receive treatment because of spontaneous remission of all skin lesions (n = 4).

## Discussion

The current multicentre study describes the largest series of patients with multifocal C-ALCL published thus far. Although the main focus of this study was to establish the efficacy of recommended therapies for patients with C-ALCL with multifocal skin lesions and to define which patients are eligible for novel targeted therapies, we will first summarize other important findings of this study, which are relevant to the choice of treatment. First of all, our study suggests that multifocal C-ALCL is much more uncommon than reported previously. Previous studies reported that approximately 15–20% of the patients with C-ALCL have multifocal lesions.<sup>2–4</sup> However, from the 283 patients with C-ALCL that had been included in the Dutch Cutaneous Lymphoma Registry between 1985 and 2017, only 28 had multifocal skin lesions at first presentation (10%), and only nine of them had first presented with more than five affected skin sites (3%). Consistent with previous

**Table 3** Treatment results in multifocal cutaneous anaplastic large cell lymphoma at first diagnosis (n = 24)

Therapy	Patients	Complete response	Relapse only skin	Extracutaneous relapse	Total relapse
CHOP	5	5/5 (100)	2/5	3/5	5/5 (100)
Methotrexate	4	1/4 (25)	1/4	2/4	3/4 (75)
RT (+ excision)	7	7/7 (100)	5/7	0/7	5/7 (71)
Spontaneous remission	4	4/4 (100)	0/4	1/4	1/4 (25)
PUVA	2	1/2 (50)	0/2	1/2	1/2 (50)
Etoposide	1	1/1 (100)	0/1	0/1	0/1 (0)
Excision	1	1/1 (100)	0/1	1/1	1/1 (100)
Total	24	20/24 (83)	8/24 (33)	8/24 (33)	16/24 (67)

Values are n/N (%). CHOP, cyclophosphamide, hydroxydaunorubicin, oncovin and prednisone; RT, local radiotherapy; PUVA, psoralen-ultra-violet A.

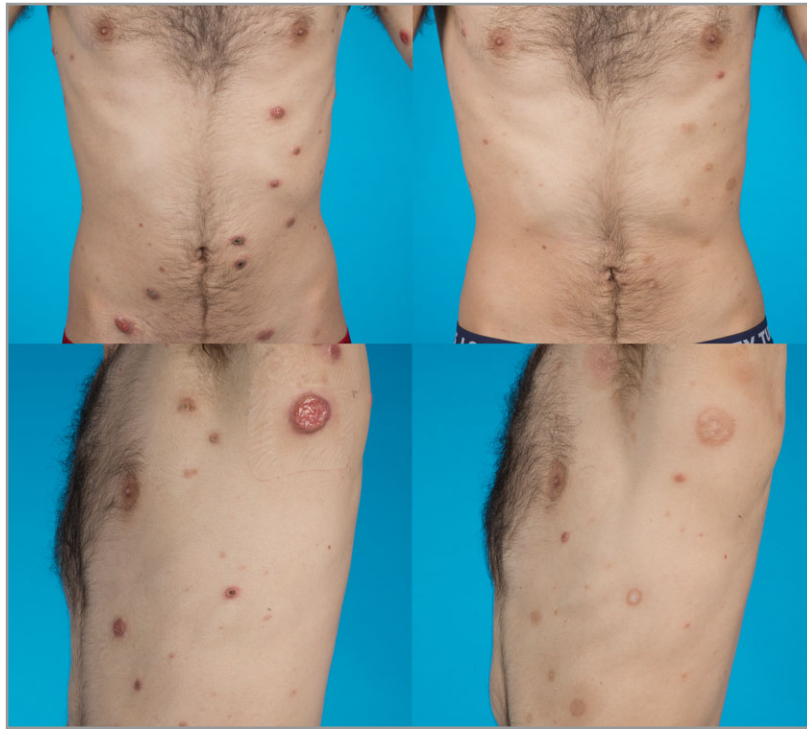

Fig 1. Patient with multifocal cutaneous anaplastic large cell lymphoma before (left) and 5 months after (right) treatment with methotrexate 10 mg showing partial response (patient 24, Table 2).

Table 4 Treatment results in multifocal cutaneous anaplastic large cell lymphoma (n = 47)

Therapy	Patients	> 5 lesions	Complete response	Overall response rate
CHOP	9	3/9 (33)	7/9 (78)	9/9 (100)
Methotrexate	7	4/7 (57)	3/7 (43)	4/7 (57)
RT (+ excision)	21	0/21 (0)	21/21 (100)	21/21 (100)
Spontaneous remission	4	2/4 (50)	4/4 (100)	4/4 (100)
Other	6	2/6 (33)	4/6 (66)	6/6 (100)
Total	47	11/47 (23)	39/47 (83)	44/47 (94)

Values are n/N (%). CHOP, cyclophosphamide, hydroxydaunorubicin, oncovin and prednisone; RT, local radiotherapy. Other: psoralen-ultra-violet A (n = 2), etoposide (n = 1), acitretin (n = 1), steroids (n = 1) and excision (n = 1).

studies, patients with multifocal C-ALCL had a much higher relapse rate (67%), more often developed extracutaneous disease (33%) and had a lower 5-year DSS (78%) and 5-year OS (66%) compared with patients with solitary or localized C-ALCL (40% relapse rate: 10% extracutaneous relapse rate; 5-year DSS 95% and 5-year OS 85%).<sup>2,4,23,24</sup> The high relapse rate was irrespective of administered therapy. Interestingly, compared with patients presenting with two to five skin lesions, patients presenting with more than five lesions had a higher chance of developing extracutaneous relapse (56% vs. 20%) and more often died of lymphoma (44% vs. 7%).

Current guidelines suggest that patients with C-ALCL presenting with multifocal skin lesions can best be treated with radiotherapy in the case of few lesions or with low-dose MTX in the case of more widespread disease.<sup>2,5,10</sup> To establish the efficacy of these therapies, we evaluated the results of initial

treatment in 24 patients with multifocal C-ALCL at first presentation and 23 multifocal skin relapses. Taken together, 36 of 47 patients had two to five lesions and 11 more than five lesions. Therapies most commonly applied were radiotherapy (n = 21), CHOP (n = 9) and low-dose MTX (n = 7), whereas four cases had not received any treatment because of spontaneous resolution of all skin lesions. Other patients were treated with PUVA in two cases, and etoposide, acitretin, intralesional corticosteroids and excision, each in one case.

Radiotherapy was successfully used in 21 patients with two to five skin lesions and resulted in a CR in all of them. Recent studies of our group suggest that for patients with multifocal or relapsing skin lesions a radiation dose of 8 Gy (2 × 4 Gy) suffices.<sup>25</sup> Combination therapy with CHOP resulted in a CR in seven of nine patients and in a PR in the other two. As reported previously, all patients developed cutaneous and/or

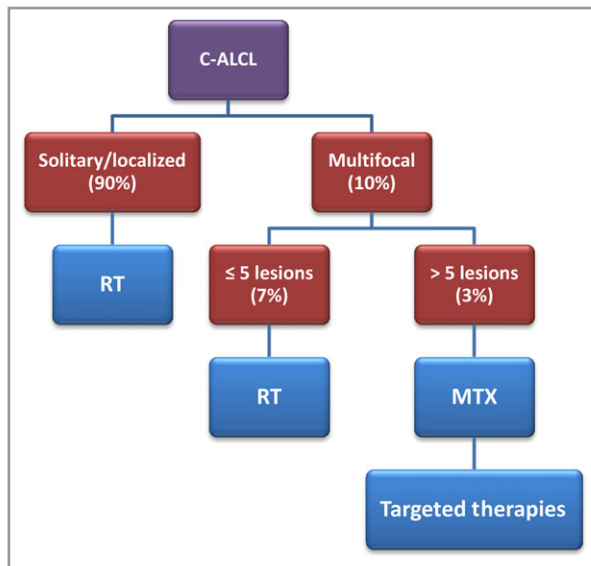


Fig 2. Flowchart of treatment of (multifocal) cutaneous anaplastic large cell lymphoma (C-ALCL). In patients showing signs of spontaneous remission, an expectant policy should be considered for a period of 4–6 weeks. RT, local radiotherapy; MTX, methotrexate.

extracutaneous relapses during follow-up.<sup>2</sup> Following our publication in 2000, CHOP was therefore no longer used for patients with only multifocal skin lesions and has been largely replaced by low-dose MTX.

Low-dose MTX is effective in patients with LyP with response rates up to 93%,<sup>26,27</sup> and has been proposed as first-line therapy for multifocal C-ALCL.<sup>2,5,10</sup> However, evidence for this recommendation is scarce. Vonderheid *et al.* suggested that low-dose MTX is an effective and well-tolerated treatment in patients with primary cutaneous CD30-positive lymphoproliferative disorders, but only four of the 45 patients included in that study had typical (multifocal) C-ALCL.<sup>11</sup> In addition, few case reports described CRs or PRs in patients with multifocal C-ALCL.<sup>12–14,28–30</sup> In the present study seven patients were treated with low-dose MTX, including four with more than five lesions. Four patients obtained a CR or PR (ORR 57%) during maintenance therapy with MTX, whereas three patients experienced insufficient effect. These data suggest that low-dose MTX may be effective in multifocal C-ALCL, although the response rate is lower than reported in LyP.<sup>26,27</sup> Moreover, relapses are common and continued or repeated maintenance treatment is often required. Apart from MTX, anecdotal case reports and small series suggest that etoposide, vinblastine and retinoids (bexarotene, acitretin and isotretinoin) alone, or in combination with interferon alpha may represent alternative effective and well-tolerated options for refractory multifocal C-ALCL.<sup>7,8,31–35</sup>

Recent studies report high response rates of BV in patients with primary cutaneous CD30-positive lymphoproliferations, including patients with relapsed and extracutaneous (multifocal) C-ALCL.<sup>15,16,18–20</sup> A recent phase III trial compared the efficacy of BV in 16 patients with C-ALCL, including 12

patients with multifocal skin lesions and seven patients with extracutaneous disease, to MTX or bexarotene in 15 patients with C-ALCL including six with multifocal skin lesions and four with extracutaneous disease.<sup>20</sup> Patients treated with BV showed an ORR lasting at least 4 months and an CR rate of 75% and 31%, respectively, compared with 20% and 7%, respectively, in the control group. Grade 3–4 adverse events were reported in 41% and peripheral neuropathy in 67% of the patients in the BV group. Because of the favourable results, BV was included in the National Comprehensive Cancer Network guidelines as a primary treatment option in multifocal C-ALCL.<sup>21</sup>

In conclusion, the results of our study suggest that multifocal C-ALCL is much more uncommon than reported previously, and most of these patients present with few scattered skin lesions. In patients showing signs of spontaneous remission, an expectant policy should be considered, at least for a short period of 4–6 weeks. In case of complete spontaneous remission, no further treatment is required. For patients presenting with, arbitrarily, up to five skin lesions, low-dose radiotherapy ( $2 \times 4$  Gy) is the preferred treatment with CR in virtually all cases. For rare patients presenting with extensive skin lesions, radiotherapy is less attractive and systemic therapy is indicated. Maintenance treatment with low-dose MTX (10–25 mg weekly) may achieve objective response rates of 57% and is still advised as the first option. BV may be considered in rare patients with more than five affected skin sites refractory to MTX or patients with extracutaneous disease (Fig. 2). However, BV is expensive, long-term effects are still unknown and the cumulative neuropathy is a matter of concern.<sup>20</sup> It would be interesting to find out if dose reduction and prolonged treatment intervals can overcome these issues.<sup>36</sup> Multiagent chemotherapy is only indicated in patients with extracutaneous disease, who do not respond to less aggressive therapies.

## References

- 1 Willemze R, Jaffe ES, Burg G *et al.* WHO-EORTC classification for cutaneous lymphomas. *Blood*. 2005; **105**:3768–85.
- 2 Bekkenk MW, Geelen FA, van Voorst Vader PC *et al.* Primary and secondary cutaneous CD30(+) lymphoproliferative disorders: a report from the Dutch Cutaneous Lymphoma Group on the long-term follow-up data of 219 patients and guidelines for diagnosis and treatment. *Blood* 2000; **95**:3653–61.
- 3 Haggood G, Pickles T, Sehn LH *et al.* Outcome of primary cutaneous anaplastic large cell lymphoma: a 20-year British Columbia Cancer Agency experience. *Br J Haematol* 2016; **176**:234–40.
- 4 Woo DK, Jones CR, Vanoli-Storz MN *et al.* Prognostic factors in primary cutaneous anaplastic large cell lymphoma: characterization of clinical subset with worse outcome. *Arch Dermatol* 2009; **145**:667–74.
- 5 Kempf W, Pfaltz K, Vermeer MH *et al.* EORTC, ISCL, and USCLC consensus recommendations for the treatment of primary cutaneous CD30-positive lymphoproliferative disorders: lymphomatoid papulosis and primary cutaneous anaplastic large-cell lymphoma. *Blood* 2011; **118**:4024–35.
- 6 Specht L, Dabaja B, Illidge T *et al.* Modern radiation therapy for primary cutaneous lymphomas: field and dose guidelines from the

- International Lymphoma Radiation Oncology Group. *Int J Radiat Oncol Biol Phys* 2015; **92**:32–9.
- 7 Shehan JM, Kalaaji AN, Markovic SN, Ahmed I. Management of multifocal primary cutaneous CD30 anaplastic large cell lymphoma. *J Am Acad Dermatol* 2004; **51**:103–10.
  - 8 French LE, Shapiro M, Junkins-Hopkins JM *et al.* Regression of multifocal, skin-restricted, CD30-positive large T-cell lymphoma with interferon alfa and bexarotene therapy. *J Am Acad Dermatol* 2001; **45**:914–18.
  - 9 Willemze R, Beljaards RC. Spectrum of primary cutaneous CD30 (Ki-1)-positive lymphoproliferative disorders. A proposal for classification and guidelines for management and treatment. *J Am Acad Dermatol* 1993; **28**:973–80.
  - 10 Willemze R, Hodak E, Zinzani PL *et al.* Primary cutaneous lymphomas: ESMO Clinical Practice Guidelines for diagnosis, treatment and follow-up. *Ann Oncol* 2013; **24** (Suppl. 6):vi149–54.
  - 11 Vonderheid EC, Sajjadian A, Kadin ME. Methotrexate is effective therapy for lymphomatoid papulosis and other primary cutaneous CD30-positive lymphoproliferative disorders. *J Am Acad Dermatol* 1996; **34**:470–81.
  - 12 Oliveira LS, Nobrega MP, Monteiro MG, Almeida WL. Primary cutaneous anaplastic large-cell lymphoma—case report. *An Bras Dermatol* 2013; **88** (Suppl. 1):132–5.
  - 13 Nandini A, Mysore V, Sacchidanand S, Chandra S. Primary cutaneous anaplastic large cell lymphoma arising from lymphomatoid papulosis, responding to low dose methotrexate. *J Cutan Aesthet Surg* 2009; **2**:97–100.
  - 14 Parajuli S, Gurung D, Paudel U *et al.* Primary cutaneous CD30-positive anaplastic large cell lymphoma in an 80-year-old man: a case report from Nepal. *Int J Dermatol* 2014; **53**:1498–500.
  - 15 Mody K, Wallace JS, Stearns DM *et al.* CD30-positive cutaneous T-cell lymphoma and response to Brentuximab Vedotin: 2 illustrative cases. *Clin Lymphoma Myeloma Leuk* 2013; **13**:319–23.
  - 16 Patsinakidis N, Kreuter A, Moritz RK *et al.* Complete remission of refractory, ulcerated, primary cutaneous CD30+ anaplastic large cell lymphoma following brentuximab vedotin therapy. *Acta Derm Venereol* 2015; **95**:233–4.
  - 17 Desai A, Telang GH, Olszewski AJ. Remission of primary cutaneous anaplastic large cell lymphoma after a brief course of brentuximab vedotin. *Ann Hematol* 2013; **92**:567–8.
  - 18 Kaffenberger BH, Kartono Winardi F *et al.* Periocular cutaneous anaplastic large cell lymphoma clearance with brentuximab vedotin. *J Clin Aesthet Dermatol* 2013; **6**:29–31.
  - 19 Duvic M, Tetzlaff MT, Gangar P *et al.* Results of a phase II trial of Brentuximab Vedotin for CD30+ cutaneous t-cell lymphoma and lymphomatoid papulosis. *J Clin Oncol* 2015; **33**:3759–65.
  - 20 Prince HM, Kim YH, Horwitz SM *et al.* Brentuximab vedotin or physician's choice in CD30-positive cutaneous T-cell lymphoma (ALCANZA): an international, open-label, randomised, phase 3, multicentre trial. *Lancet* 2017; **390**:555–60.
  - 21 Horwitz S. NCCN Clinical Practice Guidelines in Oncology (NCC Guidelines) T-Cell Lymphomas. Fort Washington, PA: National Comprehensive Cancer Network, 2018.
  - 22 Kim YH, Willemze R, Pimpinelli N *et al.* TNM classification system for primary cutaneous lymphomas other than mycosis fungoides and Sezary syndrome: a proposal of the International Society for Cutaneous Lymphomas (ISCL) and the Cutaneous Lymphoma Task Force of the European Organization of Research and Treatment of Cancer (EORTC). *Blood* 2007; **110**:479–84.
  - 23 Liu HL, Hoppe RT, Kohler S *et al.* CD30+ cutaneous lymphoproliferative disorders: the Stanford experience in lymphomatoid papulosis and primary cutaneous anaplastic large cell lymphoma. *J Am Acad Dermatol* 2003; **49**:1049–58.
  - 24 Benner MF, Willemze R. Applicability and prognostic value of the new TNM classification system in 135 patients with primary cutaneous anaplastic large cell lymphoma. *Arch Dermatol* 2009; **145**:1399–404.
  - 25 Melchers RC, Willemze R, Daniels LA *et al.* Recommendations for the optimal radiation dose in patients with primary cutaneous anaplastic large cell lymphoma: a report of the Dutch Cutaneous Lymphoma Group. *Int J Radiat Oncol Biol Phys* 2017; **99**:1279–85.
  - 26 Bruijn MS, Horvath B, van Voorst Vader PC *et al.* Recommendations for treatment of lymphomatoid papulosis with methotrexate: a report from the Dutch Cutaneous Lymphoma Group. *Br J Dermatol* 2015; **173**:1319–22.
  - 27 Newland KM, McCormack CJ, Twigger R *et al.* The efficacy of methotrexate for lymphomatoid papulosis. *J Am Acad Dermatol* 2015; **72**:1088–90.
  - 28 Blume JE, Stoll HL, Cheney RT. Treatment of primary cutaneous CD30+ anaplastic large cell lymphoma with intralesional methotrexate. *J Am Acad Dermatol* 2006; **54** (Suppl. 5):S229–30.
  - 29 Yokoi I, Ishikawa E, Koura A *et al.* Successful treatment of primary cutaneous anaplastic large cell lymphoma with intralesional methotrexate therapy. *Acta Derm Venereol* 2014; **94**:319–20.
  - 30 Turrion-Merino L, Perez-Gala S, Hermosa-Zarza E *et al.* Primary cutaneous CD30+ anaplastic large cell lymphoma treated with radiotherapy and methotrexate with development of xanthomas at the sites of prior disease. *J Cutan Pathol* 2016; **43**:400–5.
  - 31 Yamane N, Kato N, Nishimura M *et al.* Primary cutaneous CD30+ anaplastic large-cell lymphoma with generalized skin involvement and involvement of one peripheral lymph node, successfully treated with low-dose oral etoposide. *Clin Exp Dermatol* 2009; **34**:e56–9.
  - 32 Chou WC, Su IJ, Tien HF *et al.* Clinicopathologic, cytogenetic, and molecular studies of 13 Chinese Patients with Ki-1 anaplastic large cell lymphoma. Special emphasis on the tumor response to 13-cis retinoic acid. *Cancer* 1996; **78**:1805–12.
  - 33 Sheehy O, Catherwood M, Pettengell R, Morris TC. Sustained response of primary cutaneous CD30 positive anaplastic large cell lymphoma to bexarotene and photopheresis. *Leuk Lymphoma* 2009; **50**:1389–91.
  - 34 Keun YK, Woodruff R, Sanguenza O. Response of CD30+ large cell lymphoma of skin to bexarotene. *Leuk Lymphoma* 2002; **43**:1153–4.
  - 35 Laly P, Ingen-Housz-Oro S, Beylot-Barry M *et al.* Efficacy of vinblastine in primary cutaneous anaplastic large cell lymphoma. *JAMA Dermatol* 2015; **151**:1030–1.
  - 36 Stranzenbach R, Dippel E, Schlaak M, Stadler R. Brentuximab vedotin in CD30(+) cutaneous lymphoma: how do we treat, how shall we treat? A review of the literature. *Br J Dermatol* 2017; **177**:1503–9.

## Supporting Information

Additional Supporting Information may be found in the online version of this article at the publisher's website:

**Powerpoint S1** Journal Club Slide Set.