

Cam morphology in young male football players mostly develops before proximal femoral growth plate closure: a prospective study with 5-year follow-up

P. van Klij¹, MD, M.P. Heijboer¹, MD, A.Z. Ginai², MD, PhD, J.A.N. Verhaar¹, MD, PhD, J.H. Waarsing¹, PhD, R. Agricola¹, MD, PhD

Research performed at:

¹ Department of Orthopaedics, Erasmus Medical Centre Rotterdam, The Netherlands

² Department of Radiology, Erasmus Medical Centre Rotterdam, The Netherlands

Correspondence:

Erasmus Medical Centre

Pim van Klij

's-Gravendijkwal 230

3015CE Rotterdam

The Netherlands

+31 (0)6 41 84 62 60

p.vanklij@erasmusmc.nl

Word count: 3066 / 3000

Key words: FAI syndrome, cam morphology, growth plate, hip, football

ABSTRACT

Objectives

Cam morphology is not completely understood. The aim of this study was threefold, (1) to investigate if cam morphology development is associated with growth plate status, (2) to examine whether cam morphology continues to develop after growth plate closure, (3) to qualitatively describe cam morphology development over 5-year follow-up.

Methods

Academy male football players (n=49) participated in this prospective 5-year follow-up study (baseline 12-19 years old). Anteroposterior and frog-leg lateral views were obtained at baseline (142 hips), 2.5-year (126 hips) and 5-year follow-up (98 hips). Cam morphology on these time-points was defined as:

1. Visual scores of the anterior head-neck junction, classified as: (1) normal, (2) flattening, (3) prominence
2. Alpha-angle $\geq 60^\circ$

Proximal femoral growth plates were classified as open or closed. Cam morphology development was defined as every increase in visual score and/or increase in alpha angle from $<60^\circ$ to $\geq 60^\circ$, between two time-points. This resulted in 224 measurements for cam morphology development analysis.

Results

Cam morphology development was significantly associated with open growth plates based on visual score (OR: 10.03, 95%CI: 3.49-28.84, $P<0.001$) and alpha angle (OR: 2.85, 95%CI: 1.18-6.88, $P=0.020$). With both definitions combined, cam developed in 104 of 142 hips during follow-up. Of these 104 hips, cam developed in 86 hips (82.7%) with open growth plate and in 18 hips (17.3%) with a closed growth plate. Cam morphology developed from 12-13 years of age until growth plate closure around 18 years.

Conclusion

Cam morphology of the hip is more likely to develop with an open growth plate.

Word count: 252

SUMMARY BOX (WHAT ARE THE NEW FINDINGS)

- Cam morphology mainly develops when the proximal femoral growth plate is open.
- Development of cam morphology after closure of the proximal femoral growth plate was very rare.

SUMMARY BOX (HOW MIGHT IT IMPACT ON CLINICAL PRACTICE IN THE NEAR FUTURE)

- Possible interventions to prevent development of cam morphology might only be useful during skeletal growth.

INTRODUCTION

Femoroacetabular impingement (FAI) syndrome is a symptomatic motion-related disorder resulting from a premature contact between the proximal femur and acetabulum.¹ This is often due to pincer and/or cam morphology. Cam morphology is characterised by extra bone formation mostly located in the anterolateral head-neck junction, which can be forced into the acetabulum during hip flexion and internal rotation. In general, cam morphology does not necessarily lead to symptoms, but has a strong relationship with reduced function and future hip osteoarthritis (OA).²⁻⁷

The aetiology of cam morphology is not fully understood. It is more prevalent in athletes than in non-athletes^{8,9}, with prevalence reported above 60% in high impact sports such as football^{8,10-13}, basketball⁹ and ice hockey.¹⁴⁻¹⁶ Finite element analysis revealed that repetitive movements of deep flexion and external rotation in hips with an open growth plate are possible triggers for extra bone formation in the anterolateral head-neck junction.¹⁷ Cam morphology is first visible on radiographs from the age of twelve to thirteen years and gradually increases in size during skeletal growth.^{8,9,18} During this pre-pubertal phase, bone is more responsive to loading. This might be due to nutrients, sex steroids, growth hormone peaks, insulin-like growth factors and genetic factors.¹⁹ Bone is likely to change to meet the demands of mechanical loading during childhood.²⁰ Interestingly, cam morphology typically develops at the location where the growth plate extends into the femoral neck.¹⁰ Data from the 2.5-year follow-up of the current cohort suggested that cam morphology might only develop when the growth plate is open, but only a small number of hips had closed growth plates at 2.5-year follow-up.¹⁰ If this observation proves correct, interventions to prevent cam morphology development are probably only useful during skeletal growth. To the best of our knowledge, no other prospective follow-up data is available on this topic.

This study aimed to assess the association between growth plate status and future cam morphology development during a minimum of 5-years follow-up, to investigate if cam morphology continues to develop after proximal femoral growth plate closure, and to qualitatively describe cam morphology development in this five year time period.

METHODS

Participants

All 89 academy male football players of Feyenoord Rotterdam (the Netherlands) who attended at baseline were invited to participate again and 49 of 89 (55.1%) joined this 5-year follow-up study. The football players were aged between 12 and 19 years at baseline. Recruitment for 5-year follow-up took place between June and October 2015. Inclusion criteria for the initial inclusion were playing in selection teams of Feyenoord Rotterdam (the Netherlands). Exclusion criteria were any hip disorder.^{8,10} This study was approved by the Medical Ethical Committee

of Erasmus Medical Centre (Rotterdam, the Netherlands). Each participant gave written consent. For individuals younger than 18 years, written consent was also obtained from at least one parent.

Radiographs

The standardised radiographic protocol used for this 5-year follow-up was the same as at baseline and 2.5-year follow-up.^{8 10} In short, three radiographs of the hip were obtained: A standardised anteroposterior (AP) view of the pelvis and a frog-leg lateral view of each hip. Using these projections we were able to examine the lateral (on AP-view) and anterosuperior (on frog-leg lateral view) femoral head-neck junction to detect cam morphology. For the AP-view, 15° internal rotation was ensured by positioning the participant supine with his feet in a special frame. For the frog-leg lateral view, the participant was placed in the supine position with the hip in flexion and abduction, using a 45° wedge under the knee to secure standardised position.

Visual scores

The anterolateral head-neck junction in all radiographs were semiquantitatively scored (ordinal variable) as (1) normal, (2) flattening or (3) prominence.

1. Normal: slight symmetric concavities of the anterior head-neck junction with respect to the posterior head-neck junction;
2. Flattening: moderate decrease in the anterior head-neck offset with respect to the posterior head-neck junction;
3. Prominence: convexity in the anterior head-neck junction, as opposed to a concavity.

Cam morphology was defined as the presence of either a flattening or prominence of the proximal femur. An experienced orthopaedic surgeon and musculoskeletal radiologist determined the visual scores of all hips, based on consensus. Each hip was scored with the available radiographs of all three time-points in one session. The visual scores showed a kappa of 0.68 for intra-observer reliability in the baseline study.⁸

Alpha angle

The proximal femoral shape was outlined by a set of points that were manually positioned on anatomical landmarks using Statistical Shape Modelling software (ASM tool kit, Manchester University, Manchester, UK). Images of left-sided joints were mirrored to appear as right-sided joints. Using MATLAB v7.1.0 (MathWorks Inc, Natick, Massachusetts, USA), the alpha angle was automatically calculated in all radiographs from a set of points that were manually positioned on predefined anatomical landmarks of the proximal femur.^{8 10} An alpha angle $\geq 60^\circ$ was defined as cam morphology.²¹ The highest alpha angle value on the AP or frog-leg lateral

views of each hip was used for analysis. When a hip had an alpha angle $\geq 60^\circ$ at a certain point, we defined this hip as having cam morphology at the subsequent follow-up time-point as well. For alpha angle, the intraclass correlation coefficient (ICC) for interobserver reliability was 0.73. Intra-observer reliability ICC ranged between 0.85-0.99.⁶ The measurement error is calculated by the Root Mean Square Error (RMSE). This resulted in a RMSE between 1.68 and 1.99.⁶

Growth plate status

The growth plate status (open or closed) was scored at the same time, based on consensus. The growth plate was scored as closed, if the full growth plate was totally fused and visible as a sclerotic line. If only a small part of the growth plate remained open in any radiographic view, that growth plate was scored as open. Growth plate status was scored in 126 radiographs during 2.5-year follow-up, and those radiographs were scored again during 5-year follow-up, resulting in a kappa of 0.94 for intra-observer reliability.

Definition of cam morphology development

Every increase in visual scores (dichotomous scale) and/or increase of alpha angle from $<60^\circ$ to $\geq 60^\circ$ (dichotomous scale) was defined as cam morphology development. As presented in *Figure 1*, we assessed the development of cam morphology by pairwise comparison between baseline and 2.5-year follow-up (63 participants, 126 hips), between baseline and 5-year follow-up, if participants did not attend the 2.5-year follow-up (8 participants, 16 hips), and between 2.5-year follow-up and 5-year follow-up (41 participants, 82 hips). This resulted in a total of 224 different pairwise comparisons.

Statistical analysis

Differences in baseline characteristics between included participants and dropouts were tested using an independent-samples t-test. Cam morphology prevalence was described per hip. Development of cam morphology is analysed blinded on hips of participants who attended at least two time-points. This resulted in radiographs of 142 hips at baseline, 126 hips at 2.5-year follow-up and 82 and 16 hips at 5-year follow-up (*Figure 1*). Cam morphology development was analysed twice (for visual score and alpha angle) in 224 radiographs, which included repeated measurements. Growth plate status is presented in 71 persons (142 hips). The association between growth plate status and cam morphology development was calculated by means of logistic regression. By using logistic regression in a 'Generalized Estimated Equations' model, we were able to take into account the correlation that exists within a person regarding follow-up time and side. A sensitivity analysis was performed to see, if defining hips with alpha angle $<60^\circ$ as cam morphology, when a previous time-point had alpha angle $\geq 60^\circ$,

affected the results (*supplemental Table 1*). The statistical evaluation was performed using SPSS21.0 (Windows).

RESULTS

Patient characteristics

Demographic data are presented in *Table 1*. The mean follow-up time was 5.3 ± 0.1 years (range 5.0-5.6 years). In total, 224 radiographs were analysed in 71 different football players with multiple time-points (*Figure 1*). Of 89 participants at baseline, 40 participants did not participate at 5-year follow-up (44.9%). Of these 40, 24 rejected the invitation, 4 were playing football abroad, 11 were unreachable and 1 person did not show up. At 5-year follow-up, all 49 participants were still playing football. Of those, 28 (57.1%) were still active in the first or second team or youth academy of a professional football club. The remaining 21 players (42.9%) were active at an amateur football level. There were no significant differences in baseline demographic data between the 49 participants who attended the 5-year follow-up and the drop-outs (*Table 2*).

Cam morphology prevalence

Cam morphology based on visual scores was found in 77 of 142 hips (54.2%, 35 left and 42 right) at baseline. In 99 of 126 hips (78.6%, 47 left and 52 right) at 2.5-year follow-up and in 80 of 98 hips (81.6%, 39 left and 41 right) at 5-year follow-up. Cam morphology based on alpha angle was found in 70 of 142 hips (49.3%, 31 left and 39 right) at baseline. In 86 of 126 hips (68.3%, 42 left and 44 right) at 2.5-year follow-up and in 78 of 98 hips (79.6%, 37 left and 41 right) at 5-year follow-up. The highest visual scores and alpha angles were mostly (ranging between 90.1 and 94.5% during follow-up) found on frog-leg lateral views compared to anteroposterior views during follow-up.

Growth plate status

In total, 42 of 142 (29.6%) growth plates were closed at baseline, 72 of 126 (57.1%) at 2.5-year follow-up and 92 of 98 (93.9%) at 5-year follow-up.

Association between cam morphology development and growth plate status

Cam morphology development based on visual scores was observed in 80 of 142 (56.3%) hips. Of these 80 hips, 14 hips had development from normal to flattening and from flattening to prominence during follow-up. Of these 80 hips, 71 had an open and 9 had a closed growth plate. This resulted in a strong association between cam morphology development based on visual scores and open growth plate status (OR: 10.03, 95%CI: 3.49-28.84, $P < 0.001$), as portrayed in *Figure 2*. Cam morphology development based on alpha angle was observed in 43 of 142

(30.3%) hips. Of these 43 hips, 34 had an open and 9 had a closed growth plate. This resulted in a significant association between cam morphology development based on alpha angle and open growth plate status (OR: 2.85 95%CI: 1.18-6.88, $P=0.020$). Of the hips with a closed growth plate that developed cam morphology, 7 were only classified by the visual score, 8 only by the alpha angle and 1 hip was classified as development of cam morphology after growth plate closure by both the visual score and the alpha angle. This resulted in 16 hips (11.3%, in 10 persons) with a closed growth plate that developed cam morphology by either the visual score and/or the alpha angle.

Qualitative description of cam morphology

Some anatomical changes not captured in quantifiable measures were observed during follow-up. In this study, a normal spherical anterolateral head-neck junction of the hip joint based on visual scoring was found in almost all (83.3%) 12 year old boys. From around the age of 12 to 13 years, the first appearances of cam morphology became visible. Development of cam morphology can be observed via a change in the anterolateral head-neck junction, resulting in extra bone formation in that region. This extra bone formation gradually increased during growth until the age of around 18 years. Cam morphology development is demonstrated in several hips in *Figure 2*. Together with cam morphology development, the lateral side of the growth plate was positioned more distally, appearing like an extension of the growth plate bending towards the greater trochanter. The site of this extension also corresponds with the location of bone where the cam morphology forms. In hips which did not develop cam morphology, the head-neck junction does not undergo major changes. In most cases (82.7%) cam morphology developed in hips with an open growth plate and also when a small part of the growth plate remained open. Conversely, cam morphology development was also observed in 16 different hips with a closed growth plate. Of these 16 hips, 14 had signs of external hip rotation per time point on the radiographic projection during follow-up. These differences in hip rotation could be observed via the differences in projection of the greater trochanter over the neck and the appearance of the lesser trochanter (*Figure 3*). During follow-up, 2 hips (in one person), with a closed growth plate status, showed cam morphology development without signs of rotation differences (*Figure 4*). These 2 hips followed the outlined pattern of cam morphology development, more similar to cam morphology development when the growth plate is open.

DISCUSSION

Cam morphology development was strongly associated with growth plate status in this study, which represents the 5-year follow-up data of a cohort with football players. Gradual formation of additional bone at the femoral head-neck junction that ultimately forms cam morphology is

mainly observed in participants with an open proximal femoral growth plate. After the growth plate closed, we observed no or little cam morphology development. Due to the prospective design of this study we were able to investigate cam morphology development throughout adolescence and young adulthood, with a sufficient follow-up of hips with closed growth plates.

Aetiology and prevention

The aetiology of cam morphology development is not fully understood. Our results show that cam morphology develops almost exclusively during growth. Cam morphology development is first observed from an age of 12 to 13 years and the prevalence substantially increased during growth. A recent study by Palmer et al.¹⁸ investigated cam morphology development in 103 professional male football players and 107 age-matched controls (52 males and 55 females). Corresponding with our results, they found that cam morphology first developed between 12-14 years of age. The likely explanation for cam morphology development around this age could be that the skeleton is highly responsive to mechanical loading during this period of growth.¹⁹ ²⁰ Formation of cam morphology is probably triggered by high impact sports, providing the potential for the implementation of preventative strategies. A dose-response relationship on training frequency in football players is described previously.^{18 22} A training schedule with lower impact sports could therefore be a theoretical option to prevent development of cam morphology. A personalised schedule adapted to an individuals' safe activity threshold, training frequency and intensity can be implemented. However, to date, the influence of low impact sporting activities on cam morphology development is not exactly known and advice regarding preventative strategies for cam morphology remains premature.

Cam morphology development after growth plate closure

Cam morphology development after growth plate closure was found in 8 hips based on visual score and 9 hips based on alpha angle. From 6 of 8 hips scored by visual score and 7 of 9 hips scored by alpha angle and, it was uncertain if cam morphology truly developed or whether it was quantified as such due to a slight different position of the radiographic view, despite the strict radiographic protocol (*Figure 3*). Another explanation for cam morphology development after growth plate closure might be the use of radiographs instead of MRI. If the growth plate appears closed on a radiograph, it is unsure whether the growth plate is really closed or if there might still be growth potential. In only 2 hips of one person, development of cam morphology after growth plate closure was observed with certainty. These hips had nearly identical position on the radiographs at all time-points (*Figure 4*). These cam morphologies appear more sclerotic and this might possibly be a result of a bony response due to impingement, the shape of head-neck junction or acetabular shape, rather than an adaptive response to loading. This could

possibly be explained by the fact that repetitive stimulation of cortical bone due to the impingement may be a stimulus for bone formation.

Limitations

Some limitations of this study need acknowledgement. A high drop-out rate of 44.9% is observed during follow-up which potentially has introduced bias. However, baseline characteristics were not statistically different between included football players and drop-outs (*Table 2*). Results of this study in male football players might not automatically be generalised to female soccer players. Given that 6 of 98 growth plates were still open at 5-year follow-up, the prevalence is expected to even increase slightly. Another limitation is the use of radiographs leading to an underestimation of both cam morphology prevalence, and amount of open growth plates. Differences in rotation of the hip, especially external rotation, could potentially have influenced the results, but due to the same standardised radiographic protocol used at every time-point, this effect is likely limited.

Visual scores

Due to limitations of the alpha angle, the anterolateral head-neck junction was also semi-quantitatively scored. All the available radiographs over time were presented and scored in one series, which could have introduced bias but also resulted in more reliable prospective visual scores. Bias could have been introduced because the observers were not blinded for growth plate status. However, by showing each hip of one person at the multiple follow-up times at once, the hips could be more reliably categorised into normal, flattening or prominence.

Alpha angle

Although the alpha angle is the most commonly used quantitative measure for cam morphology, this measure does have its limitations. First, the alpha angle might be less valid in hips with an open growth plate since it results in a higher rate of false positive findings, as described previously in this cohort and also observed by others.^{8 18} Another restriction is that the alpha angle, like every measurement method, has its measurement uncertainty. The values for the minimal detectable change are not available for the alpha angle. For example, of 43 hips that developed cam morphology based on alpha angle, 21 (48.8%) increased in alpha angle less than 10° and 9 (20.9%) of these 21 even less than 5°. This might very well be within the measurement uncertainty. It might therefore be possible that hips were misclassified as having or not having cam morphology. A dichotomous definition of cam morphology based on the alpha angle is used, with the risk of misclassifying hips that have alpha angles around 60°. Lastly, the risk of a false positive or false negative quantification of cam morphology is increased due to repetitive measurements during follow-up.

CONCLUSION

Cam morphology of the hip develops mainly when the growth plate is open in young male football players. This suggests that cam morphology is a bony adaptation resulting from stimulating of the growth plate by sporting activities, which has implications for possible future preventative measures for cam morphology formation.

COMPETING INTERESTS

None declared.

CONTRIBUTORSHIP

PK: study conception/design, data acquisition, data analysis and interpretation, drafting of manuscript. MPH: data acquisition, data interpretation, critical revision. AZG: data acquisition, data interpretation, critical revision. JANV: study conception/design, data acquisition, critical revision. JHW: study conception/design, data acquisition, data analysis and interpretation, critical revision. RA: study conception/design, data acquisition, data analysis and interpretation, drafting of manuscript.

ACKNOWLEDGEMENT

The authors thank Raymond van Meenen, Rob Kurvers, Marcel de Geus and the other staff members of Feyenoord Football Academy for their collaboration in this study. This study would not have been possible without study participants and their families, to whom we offer our sincerest gratitude.

FUNDING INFO

None.

ETHICAL APPROVAL INFORMATION

Approved by the Medical Ethical Committee of Erasmus Medical Centre (Rotterdam, the Netherlands), METC: 2009-235.

DATA SHARING STATEMENT

No data will be available.

PATIENT INVOLVEMENT

Yes, 49 persons joined this 5-year follow-up study and were all non-identifiable.

REFERENCES

1. Griffin DR, Dickenson EJ, O'Donnell J, et al. The Warwick Agreement on femoroacetabular impingement syndrome (FAI syndrome): an international consensus statement. *Br J Sports Med* 2016;**50**(19):1169-76.
2. Agricola R, Waarsing JH, Arden NK, et al. Cam impingement of the hip: a risk factor for hip osteoarthritis. *Nat Rev Rheumatol* 2013;**9**(10):630-4.
3. Thomas GE, Palmer AJ, Batra RN, et al. Subclinical deformities of the hip are significant predictors of radiographic osteoarthritis and joint replacement in women. A 20 year longitudinal cohort study. *Osteoarthritis Cartilage* 2014;**22**(10):1504-10.
4. Glyn-Jones S, Palmer AJ, Agricola R, et al. Osteoarthritis. *Lancet* 2015;**386**(9991):376-87.
5. Saberi Hosnijeh F, Zuiderwijk ME, Versteeg M, et al. Cam Deformity and Acetabular Dysplasia as Risk Factors for Hip Osteoarthritis. *Arthritis Rheumatol* 2017;**69**(1):86-93.
6. Agricola R, Heijboer MP, Bierma-Zeinstra SM, et al. Cam impingement causes osteoarthritis of the hip: a nationwide prospective cohort study (CHECK). *Ann Rheum Dis* 2013;**72**(6):918-23.
7. Agricola R, Weinans H. Femoroacetabular impingement: what is its link with osteoarthritis? *Br J Sports Med* 2016;**50**(16):957-8.
8. Agricola R, Bessems JH, Ginai AZ, et al. The development of Cam-type deformity in adolescent and young male soccer players. *Am J Sports Med* 2012;**40**(5):1099-106.
9. Siebenrock KA, Ferner F, Noble PC, et al. The cam-type deformity of the proximal femur arises in childhood in response to vigorous sporting activity. *Clin Orthop Relat Res* 2011;**469**(11):3229-40.
10. Agricola R, Heijboer MP, Ginai AZ, et al. A cam deformity is gradually acquired during skeletal maturation in adolescent and young male soccer players: a prospective study with minimum 2-year follow-up. *Am J Sports Med* 2014;**42**(4):798-806.
11. Johnson AC, Shaman MA, Ryan TG. Femoroacetabular impingement in former high-level youth soccer players. *Am J Sports Med* 2012;**40**(6):1342-6.
12. Gerhardt MB, Romero AA, Silvers HJ, et al. The prevalence of radiographic hip abnormalities in elite soccer players. *Am J Sports Med* 2012;**40**(3):584-8.
13. Mosler AB, Crossley KM, Waarsing JH, et al. Ethnic Differences in Bony Hip Morphology in a Cohort of 445 Professional Male Soccer Players. *Am J Sports Med* 2016;**44**(11):2967-74.
14. Philippon MJ, Ho CP, Briggs KK, et al. Prevalence of increased alpha angles as a measure of cam-type femoroacetabular impingement in youth ice hockey players. *Am J Sports Med* 2013;**41**(6):1357-62.
15. Lerebours F, Robertson W, Neri B, et al. Prevalence of Cam-Type Morphology in Elite Ice Hockey Players. *Am J Sports Med* 2016;**44**(4):1024-30.
16. Siebenrock KA, Kaschka I, Frauchiger L, et al. Prevalence of cam-type deformity and hip pain in elite ice hockey players before and after the end of growth. *Am J Sports Med* 2013;**41**(10):2308-13.
17. Roels P, Agricola R, Oei EH, et al. Mechanical factors explain development of cam-type deformity. *Osteoarthritis Cartilage* 2014;**22**(12):2074-82.
18. Palmer A, Fernquest S, Gimpel M, et al. Physical activity during adolescence and the development of cam morphology: a cross-sectional cohort study of 210 individuals. *Br J Sports Med* 2017.
19. Mirtz TA, Chandler JP, Eysers CM. The effects of physical activity on the epiphyseal growth plates: a review of the literature on normal physiology and clinical implications. *J Clin Med Res* 2011;**3**(1):1-7.
20. Tan VP, Macdonald HM, Kim S, et al. Influence of physical activity on bone strength in children and adolescents: a systematic review and narrative synthesis. *J Bone Miner Res* 2014;**29**(10):2161-81.
21. Agricola R, Waarsing JH, Thomas GE, et al. Cam impingement: defining the presence of a cam deformity by the alpha angle: data from the CHECK cohort and Chingford cohort. *Osteoarthritis Cartilage* 2014;**22**(2):218-25.
22. Tak I, Weir A, Langhout R, et al. The relationship between the frequency of football practice during skeletal growth and the presence of a cam deformity in adult elite football players. *Br J Sports Med* 2015;**49**(9):630-4.

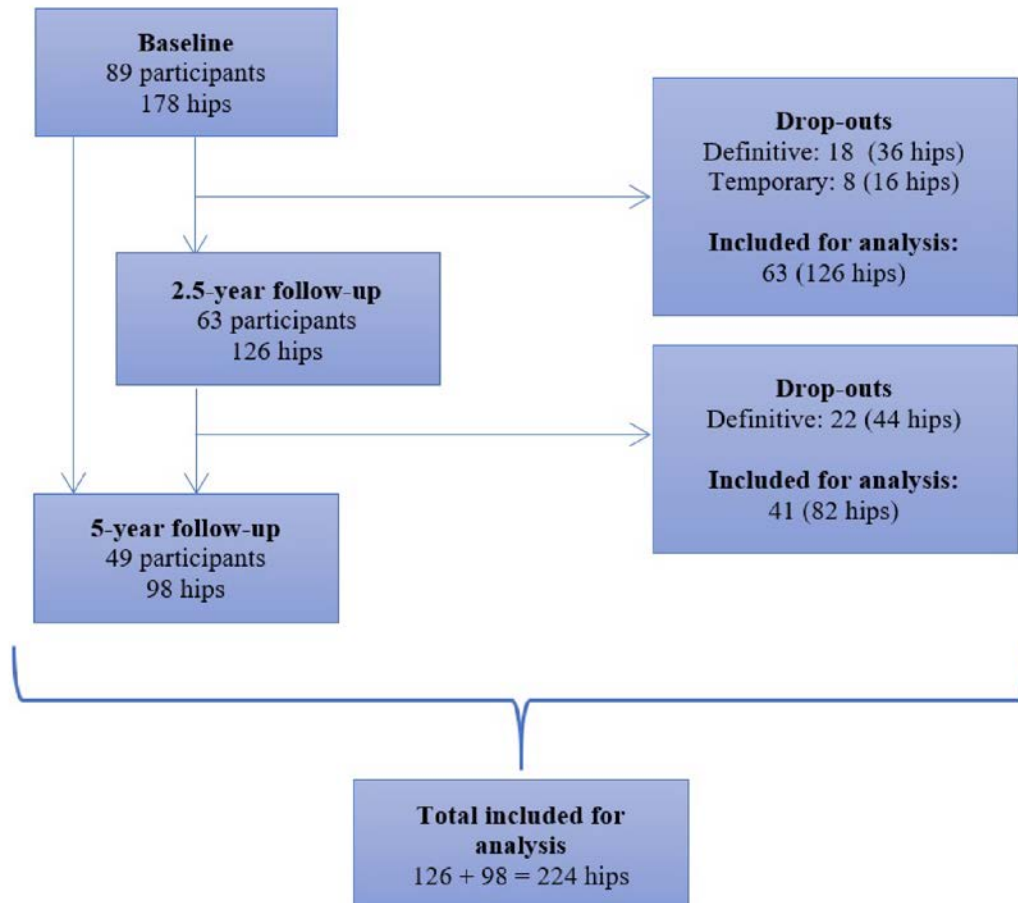
Table 1: Demographic data during follow-up.

Demographic data of baseline, 2.5-year follow-up and 5-year follow-up (n = participants)*			
	Baseline (n = 89)	2.5-year follow-up (n = 63)	5-year follow-up (n = 49)
Age, y	15.22 ± 1.97	17.25 ± 1.99	20.53 ± 2.17
Weight, kg	59.37 ± 13.82 [^]	68.36 ± 11.11 [#]	73.77 ± 7.87
Height, cm	170.28 ± 12.15 [^]	177.44 ± 7.96 [#]	180.33 ± 6.63
Body mass index, kg/m ²	20.13 ± 2.25 [^]	21.58 ± 2.21 [#]	22.65 ± 1.59
Football experience, y	8.97 ± 2.54 [^]	11.10 ± 2.49 [#]	14.29 ± 2.58
Training intensity, h/wk	7.96 ± 1.77 [^]	8.68 ± 1.91 ^{##}	9.30 ± 2.92
- * Values are expressed as mean ± standard deviation.			
- Due to missing data, data of n = 87 ([^]), n = 58 ([#]) and n = 57 (^{##}) are presented.			

Table 2: Demographic baseline data of 5-year follow-up participants compared to drop-outs.

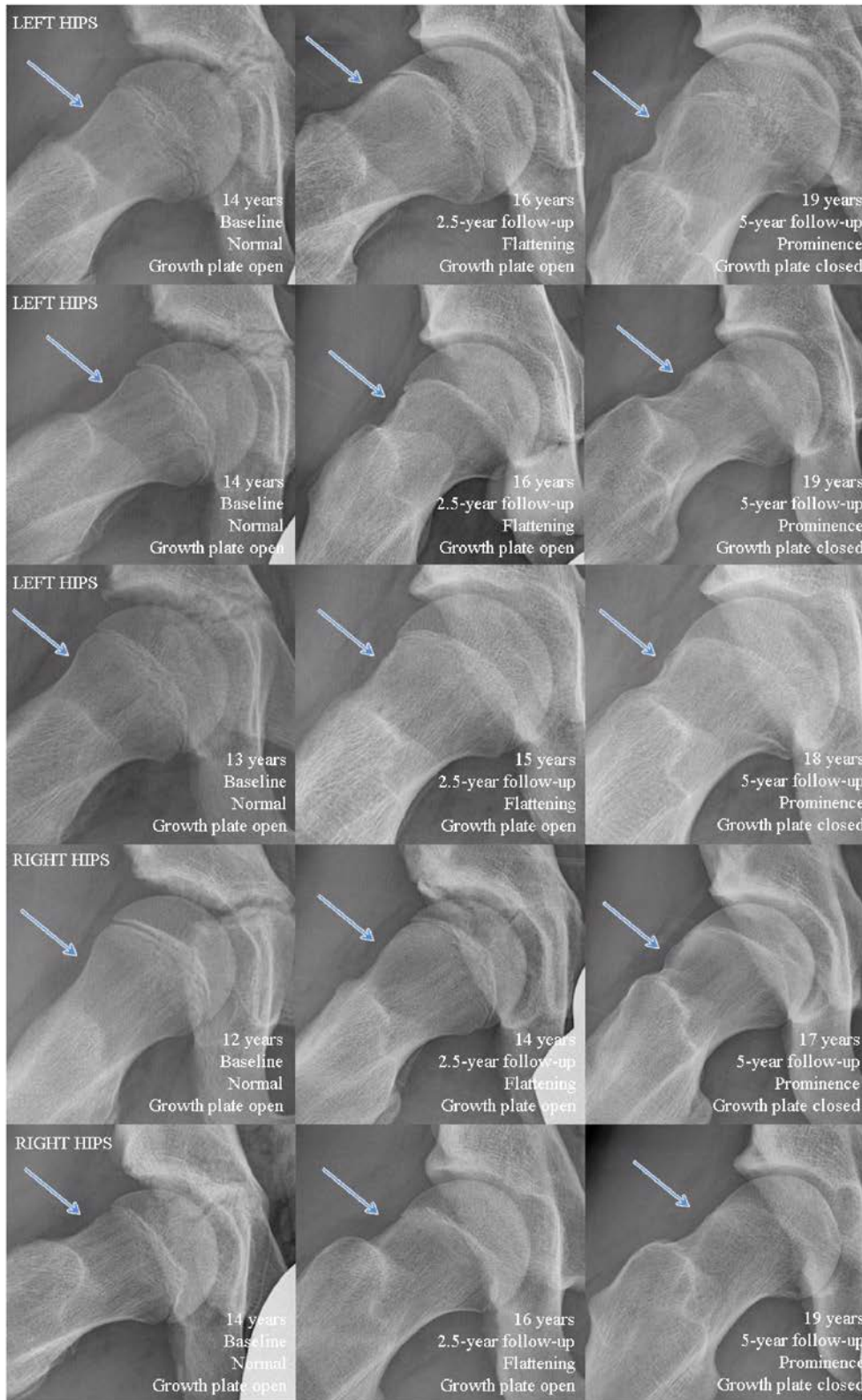
Demographic baseline data with 5-year follow-up participants compared to drop-outs (n = participants)*			
	Baseline (n = 49)	Baseline (n = 40)	P
	5-year follow-up participants	5-year follow-up drop-outs	
Age, y	15.20 ± 2.13	15.25 ± 1.77	.875
Weight, kg	58.54 ± 14.71	60.43 ± 12.60 [#]	.372
Height, cm	169.35 ± 13.16	171.47 ± 10.67 [#]	.253
Body mass index, kg/m ²	20.01 ± 2.32	20.29 ± 2.17 [#]	.416
Football experience, y	8.84 ± 2.65	9.13 ± 2.40 [#]	.449
Training intensity, h/wk	7.87 ± 1.57	8.08 ± 2.00 [#]	.446
- * Values are expressed as mean ± standard deviation.			
- Due to missing data, data of n = 38 ([#]) are presented.			

Figure 1: Flowchart of all analysed participants at baseline, 2.5-year follow-up and 5-year follow-up.



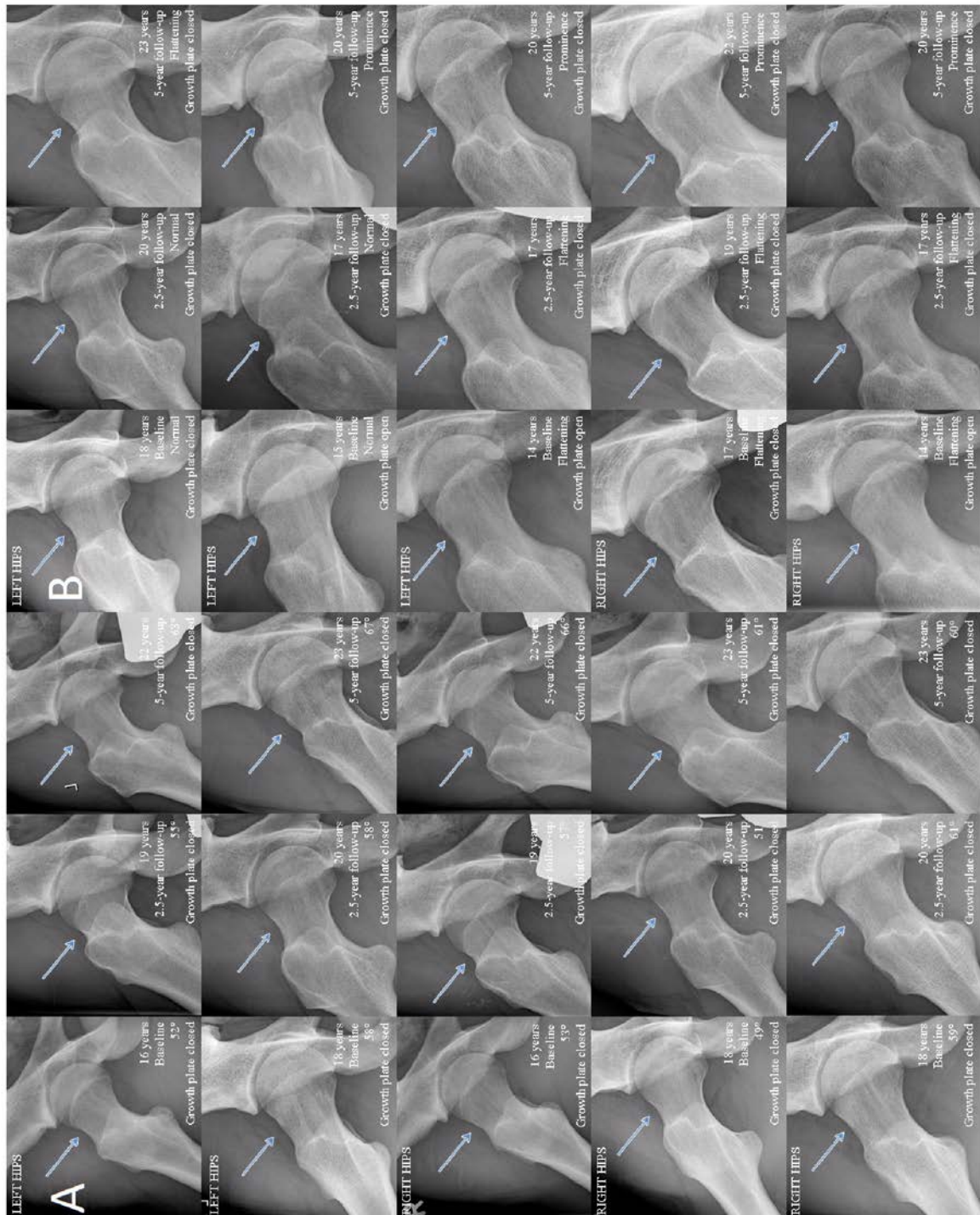
Note: Temporary drop-outs are drop-outs which did not attend at 2.5-year follow-up. Definitive drop-outs are drop-outs who were not included in the next time-point. Cam morphology development was measured between baseline and 2.5 years follow-up ($n = 126$), between 2.5-year follow-up and 5-year follow-up ($n = 82$) and between baseline and 5-year follow-up in case participants did participate at 5-year follow-up but not at 2.5-year follow-up ($n = 16$). This resulted in $n = 224$ measurements of cam morphology development.

Figure 2: Cam morphology development based on visual scores during follow-up in 5 different hips of 5 persons on frog-leg lateral radiographs.



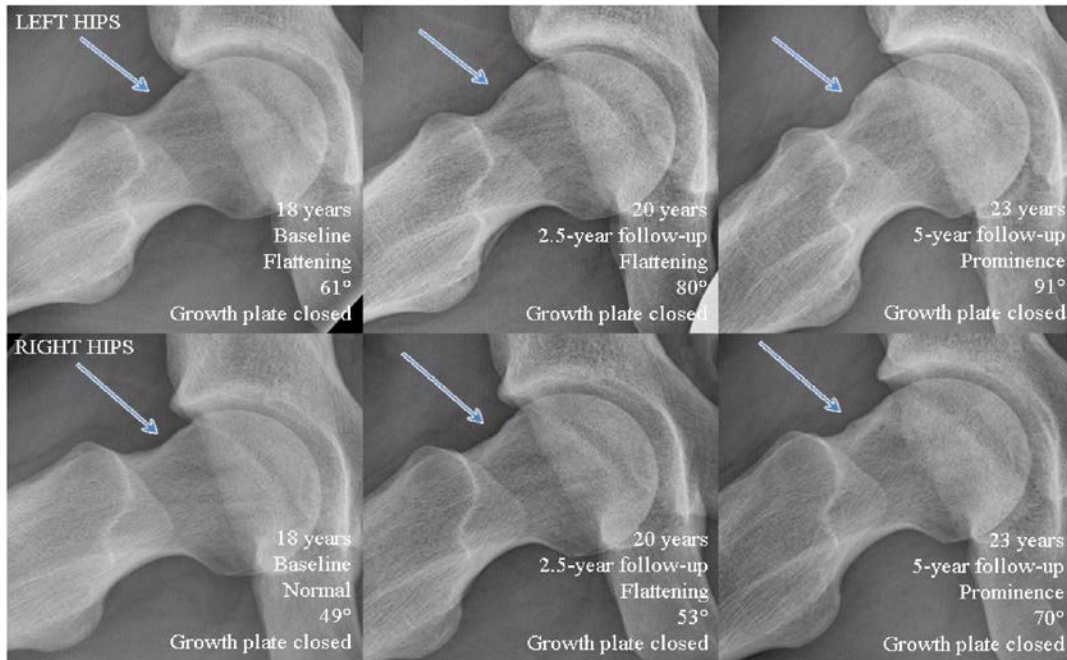
Note: In all presented hips, cam morphology development based on visual score from baseline to 2.5-year follow-up, and from 2.5-year follow-up to 5-year follow-up, is observed.

Figure 3: Cam morphology development (based on alpha angle (A) and based on visual score (B)) possibly caused by hip rotation (visible via greater trochanter projection) on frog-leg lateral radiographs. (A)



Note: Besides differences in rotation, the alpha angle increased with $\leq 10^\circ$ from 2.5-year follow-up to 5-year follow-up in these hips. (B) Note: Very subtle change in visual score was observed at 5-year follow-up while the femoral head-neck junction was normal or flattened at baseline and 2.5-year follow-up. This change in visual score is possibly due to the slight difference in rotation during the follow-up times.

Figure 4: Cam morphology development based on alpha angle and visual score on frog-leg lateral radiographs of one person during follow-up. All presented hips have closed growth plates.



Note: From baseline (normal) to 2.5-year follow-up (flattening) and from 2.5-year follow-up to 5-year follow-up (prominence), cam morphology development is observed. Cam morphology development based on alpha angle is noticed in the right hip from 2.5-year follow-up (53°) to 5-year follow-up (70°).