

Case Series

Efficacy of lateral eyelid-block excision with canthoplasty and full-thickness skin grafting in lower eyelid cicatricial ectropion

Ilse Mol^{1,2}  and Dion Paridaens²¹Department of Ophthalmology, Erasmus Medical Center, Rotterdam, The Netherlands²Department of Oculoplastic and Orbital Surgery, Rotterdam Eye Hospital, Rotterdam, The Netherlands**ABSTRACT.**

Purpose: To report on the outcomes of our preferred surgical technique for the correction of lower eyelid cicatricial ectropion

Methods: We conducted a retrospective, nonrandomized, interventional analysis of a consecutive case series of patients with cicatricial lower lid ectropion treated with adhesiolysis, lateral eyelid-block excision with canthoplasty and full-thickness skin grafting. Donor sites included the ipsi- or contralateral upper eyelid and pre- or retroauricular skin. All patients were treated by one of our oculoplastic surgeons in the period from January 2005 to January 2017 in the Rotterdam Eye Hospital/Focus Clinic Rotterdam. We assessed postoperative lower eyelid apposition, the occurrence of intra- and postoperative complications and the reoperation rate.

Results: We included 38 eyelids of 32 patients, of whom 17 were male and 15 were female. The minimal postoperative follow-up was 3 months. A total of 27 of 38 eyelids showed good postoperative apposition. Skin graft donor sites were the ipsi- or contralateral upper eyelid (47% and 16%, respectively) and the pre- or retroauricular skin (26% and 11%, respectively). No intraoperative complications occurred, but one patient developed a transient allergic contact dermatitis in the early postoperative phase. Two of 38 eyelids (two of 32 patients) required another surgical intervention (block excision) for residual or recurrent ectropion, with favourable outcomes. There was 100% viability of the skin grafts.

Conclusion: Repair of lower eyelid ectropion with lateral block excision, canthoplasty and full-thickness skin grafting is an effective procedure with minimal donor site morbidity, excellent graft survival rates and a low reoperation rate.

Key words: cicatricial ectropion – full-thickness skin graft – lateral eyelid-block excision – lower eyelid ectropion

Acta Ophthalmol.

© 2018 Acta Ophthalmologica Scandinavica Foundation. Published by John Wiley & Sons Ltd

doi: 10.1111/aos.13958

Introduction

Cicatricial ectropion of the lower eyelid occurs following loss of skin secondary to thermal or chemical burns, mechanical trauma, surgical trauma or chronic

actinic skin damage. Cicatricial ectropion can also be caused by chronic inflammation of the eyelid from dermatologic conditions. Treatment of the underlying cause, along with

conservative medical protection of the cornea, is essential as primary management. In addition, surgical treatment aims to restore the proper anatomic relationship of the lid margin with the globe. This can be achieved by surgically releasing the vertical cicatricial traction, horizontally tightening the eyelid and reconstruction of the lower lid with a full-thickness skin graft (American Academy of Ophthalmology 2016–2017). The aim of this study was to retrospectively review the outcomes in a series of patients with cicatricial lower eyelid ectropion who underwent the abovementioned surgical treatment.

Materials and Methods

A retrospective interventional analysis of a consecutive case series of patients surgically treated for lower eyelid cicatricial ectropion was conducted. Patients were treated between January 2005 and January 2017 in the Rotterdam Eye Hospital/Focus Clinic Rotterdam. Cicatricial ectropion was defined as (lower) lid malposition with palpebral conjunctival exposure with or without lower lid retraction (or horizontal laxity) due to an acquired shortage of anterior lamella. Patients who needed posterior lamellar grafts were excluded. Patient lists were generated using billing codes for repair of ectropion and full-thickness skin graft as well as by reviewing photography request forms and surgical logs. The medical records were reviewed for baseline patient information, primary

surgical procedure and additional procedures, skin graft donor site, follow-up information and surgical outcomes.

The surgical technique consisted of adhesiolysis, lateral eyelid-block excision with canthoplasty and full-thickness skin grafting.

Surgical technique

A subciliary incision 2–4 mm below the lash line was drawn in the lateral part of the eyelid. This incision was extended lateral from the lateral canthus parallel to (or in) the frown lines, for about 10 mm or any involved cicatricial change (Fig. 1A). Local anaesthetic (lidocaine 1% with epinephrine, 1:200 000) was infiltrated. The wound and donor sites were cleaned with a povidone-iodine (Betadine) solution.

A number 15 blade was used to make the previously marked subciliary incision and to release the cicatrized tissues. A blade or Westcott scissors were used to continue sharp dissection of the scar tissue until the eyelid margin easily returned to its normal position apposing the globe. Haemostasis was achieved with bipolar cautery.

The next step was to perform a lateral block excision. A skin-muscle flap was dissected with blunt spreading,

and the orbital septum was opened close to its insertion on the tarsal plate (Fig. 1B). The lower eyelid was cut perpendicular to the eyelid margin over about 6.0 mm (Fig. 1C). The cut was placed as far as possible laterally, where the upper eyelid starts.

The scissors were rotated 90 degrees, and a second cut was made parallel to the eyelid margin and 4–5 mm below it. The disinserted margin of the lower eyelid was pulled laterally and shortened, depending on the amount of laxity to be corrected (Fig. 1D). The lateral (cut) margin of the lower eyelid was reinserted to the lateral canthal ligament with two 5.0 vicryl sutures. The overlying lower eyelid skin was sutured with a vicryl or prolene 6.0 suture.

Because of the skin shortage, a free full-thickness skin graft was harvested to suture into the defect. The graft was slightly oversized. Donor sites included the ipsi- or contralateral upper eyelid, the preauricular and retroauricular area. Any remaining muscle or fat tissue was removed from the posterior surface of the graft before transferring. The graft was sutured into place with fast absorbing 6.0 vicryl, and topical antibiotic ointment was placed over the graft. Steri-Strips were placed

horizontally over the graft and in a diagonal direction lateral of the canthus for superolateral support. Then, a patch was taped over the eye. The patch and Steri-Strips were removed after 5–7 days. The harvest sites of the pre- and retroauricular area were closed with running, interlocked prolene 5.0 sutures. The harvest site of the upper eyelid skin was closed with a running prolene 6.0 suture. Hereafter, Steri-Strips were applied for protection. Procedures in patients who required bilateral treatment were performed at different sessions with a time interval of more than 4 weeks.

Preoperative assessment of these patients included evaluation of the anterior lamellar deficit, horizontal lid and canthal tendon laxity. The main outcome measures of this study included postoperative lower eyelid apposition, the occurrence of intraoperative or postoperative complications and the reoperation rate. Specific postoperative complications recorded were keratitis, infection or bleeding with haematoma formation beneath the graft, graft failure or contraction, graft discoloration, wound dehiscence, granuloma formation, displaced punctal position and recurrence of ectropion. Each patient was reviewed at 1 week and 3 months postoperatively, if indicated thereafter. Medical photographs were taken preoperatively and postoperatively.

Results

We included 38 eyelids of 32 patients who underwent adhesiolysis, lateral eyelid-block excision with canthoplasty and full-thickness skin grafting between January 2005 and January 2017. A total of 17 right lower eyelids and 21 left lower eyelids were included. Of the 32 patients, 17 were male and 15 female. The age at the time of surgery ranged from 54 to 90 years (mean 74). Baseline patient characteristics are presented in Table 1.

The commonest cause of cicatricial ectropion was the previous excision of skin malignancy (iatrogenic changes following excisional surgery), followed by chronic inflammation of the eyelid from dermatologic conditions, previous involutional ectropion correction and trauma. Finally, cicatricial ectropion was the result of scarring following cosmetic surgery (elsewhere) in one

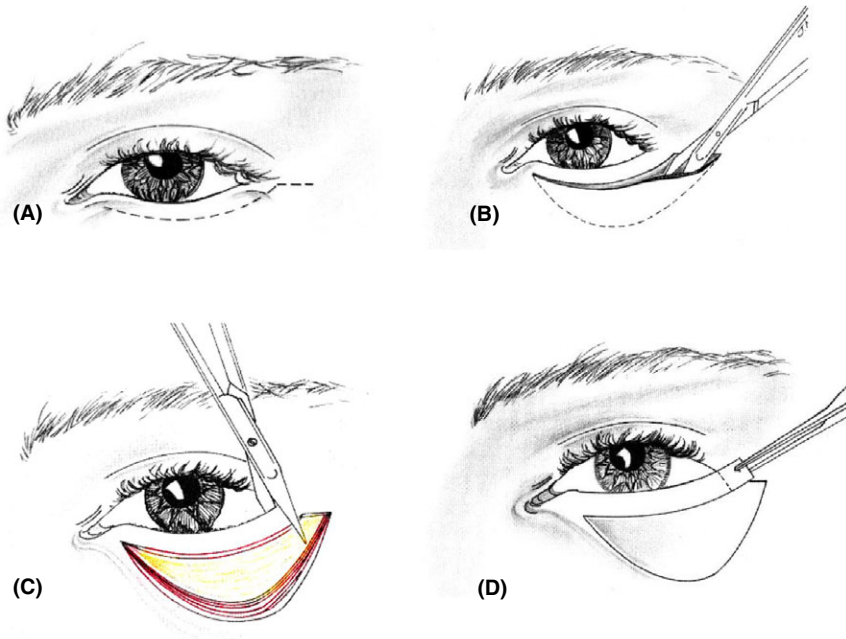


Fig. 1. Schematic drawing of a lateral block excision. (A) Subciliary incision, extended lateral from the lateral canthus; (B) creation of a skin-muscle flap with blunt spreading; (C) disinserting the lower eyelid by a cut perpendicular to the eyelid margin and a second cut fornix parallel below the tarsal plate; (D) the eyelid is pulled laterally under mild traction to determine the amount of laxity to be corrected. A full-thickness block is removed from the lateral part of the eyelid.

Table 1. Baseline patient characteristics ($n = 32$, 6 bilateral cases).

Age \pm SD	74 \pm 9
Eyelid	
Right	17
Left	21
Sex	
Male	17
Female	15
Donor site	
Upper eyelid	24
Preauricular	10
Retroauricular	4
Supraclavicular	0

patient (Table 2). Of the total of 32 patients, 11 patients had undergone surgery elsewhere and 13 patients had undergone surgical treatment of the affected lid(s) in our hospital. Previous surgery, performed by a dermatologist, plastic surgeon or ophthalmologist, dealt with the horizontal component alone.

The most common donor site was the ipsilateral upper eyelid in 18 patients (47%), followed by the preauricular region in 10 patients (26%), the contralateral upper eyelid in six patients (16%) and retroauricular skin in four patients (11%). Two patients underwent additional procedures during cicatricial ectropion repair, consisting of a midface lift in one patient and a medial conjunctival/retractor muscle spindle excision in another patient.

Patients were seen at approximately 1 week and 3 months postoperatively. At the end of follow-up, 27 of 38 eyelids (22 of 32 patients) showed a good apposition. An early postoperative complication was seen in one patient who developed contact dermatitis from the adhesive on the Steri-Strips. This was noted 3 days postoperatively, and the adhesive plasters were removed without consequences. There were no cases of keratitis, infection or bleeding with haematoma formation beneath the graft.

The overall surgical success rate was 71% with resolution of ectropion and stable eyelid position in 27 of 38 eyelids (as shown in Fig. 2.1 and 2.2). Recurrent ectropion was noted in 11 eyelids of 10 patients, resulting in an overall recurrence rate of 29%. In eight of these patients (nine eyelids, bilateral in one patient), asymptomatic recurrent ectropion was reported at 3 months postoperatively and observed without further need for intervention (Fig. 2.3).

The remaining two patients underwent additional surgeries including repeat lateral block excision without skin grafts, with favourable outcomes (Table 3, Fig. 2.4).

Good colour match was seen in all patients, and no graft hypopigmentation was noted. There was 100% viability of the original skin grafts, no contraction or need for removal occurred.

Discussion

This study shows favourable results of horizontal shortening using the lateral block excision technique in combination with adhesiolysis and skin grafting in patients with cicatricial ectropion. Surgery to correct any malposition of the lower lid must address the underlying anatomic factors responsible for the condition (Salgarelli et al. 2012). In our case series, cicatricial ectropion resulted from a number of anatomic factors, including acquired vertical cicatricial traction, increased horizontal lid laxity and shortening of the anterior lamella. Therefore, treatment consisted of a combined procedure.

The benefits of a full-thickness skin graft have long been recognized; however, its use in combination with lateral block excision (with direct canthoplasty) for lower eyelid cicatricial ectropion has, to our knowledge, not previously been reported. Lateral block excision for the correction of horizontal laxity (as part of a combined procedure) for patients with lower lid entropion was recently highlighted by our group (Lai A Fat et al. 2018).

A commonly used alternative technique for ectropion correction is the lateral tarsal strip (Anderson & Gordy 1979). Despite its popularity, this technique has, in our opinion, some disadvantages compared to the lateral block technique. Difficulty related to suture placement, disruption of the lateral canthal angle leading to dehiscence, alterations of the eyelid contour, rounding of the canthus, loss of cilia and overlapping of the eyelids with failure of proper eyelid positioning are some of the problems of the lateral tarsal strip (Knize 2002; Doxanas 1994; Moe & Linder 2000). On the other hand, Lai A Fat et al. (2018) showed that minor postoperative complications and side-effects occurred rarely and in only 5.3% (15/281) after lateral block

excision. These cases included possible wound infection in 2.1% (6/281) painful granuloma in 0.7% (2/281) and other, like bleeding and chronic inflammation, in 2.5% (7/281).

Pascali et al. (2014) described an alternative tarsal belt technique with a double mattress nonabsorbable suture. Despite the achieved results, they stated that this technique may not be sufficient enough to restore normal anatomy when lid malposition is caused by scar contracture and tissue deficiency in any of the three lamellae.

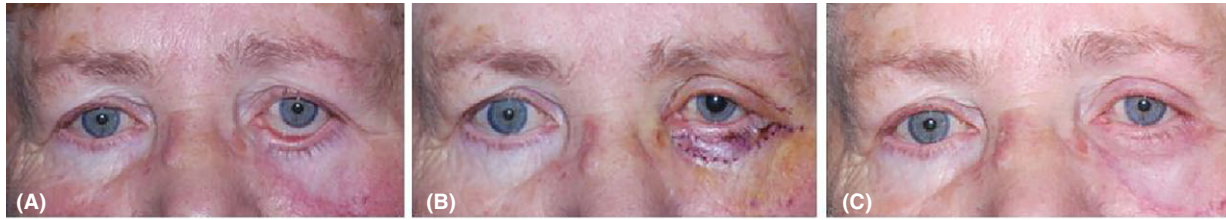Liebau et al. (2006) used an individual modified therapeutic concept and a surgical algorithm for the management of cicatricial ectropion, depending on the situation after release of the scar traction in the lower lid area. Frequently, combined procedures were performed and recurrent operations were often necessary. In their study, eight of 58 patients (13.8%) had to be reoperated because of recurrence of ectropion. While this exceeds the percentage of reoperations in our case series (5%), this difference could be explained by chance alone.

We found that full-thickness skin grafts placed in lower eyelids to correct cicatricial ectropion were viable, with graft survival observed in all of the 38 grafts. None of the grafts required removal or replacement for the duration of each patient's postoperative follow-up. There were no graft complications of bleeding, haematoma formation, graft infection, hypertrophy or failure. The majority of patients had improvement in the degree of cicatricial lower eyelid ectropion and had good appearance of the skin graft.

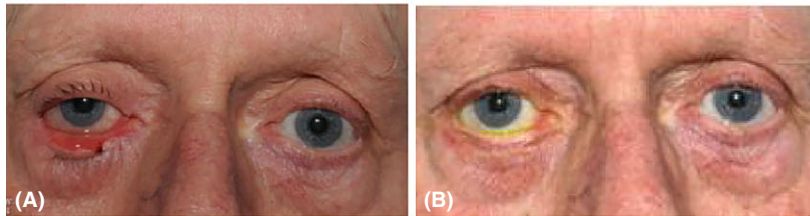
The success of the skin grafts in our study is likely due to the small size of the grafts and the abundant blood supply of the periocular region. Furthermore, there were no cases of early postoperative wound infection, haematoma formation or wound dehiscence which would have contributed to late graft failure. The excellent viability of skin grafts corresponds to previous studies, describing graft failure rate (including partial and complete failure) ranging from 0% to 2% (Leibovitch et al. 2005).

Good colour match was seen in all patients, and no graft hypopigmentation was noted. This is in agreement with the findings of Rathore et al. (2014) where these complications were

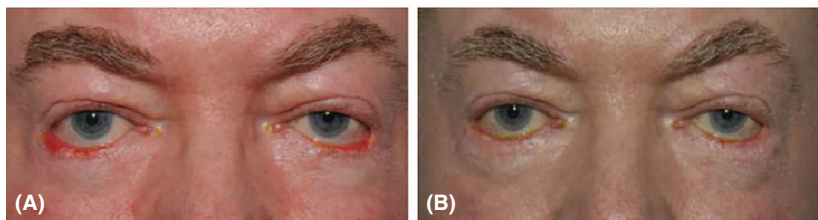
1.



2.



3.



4.

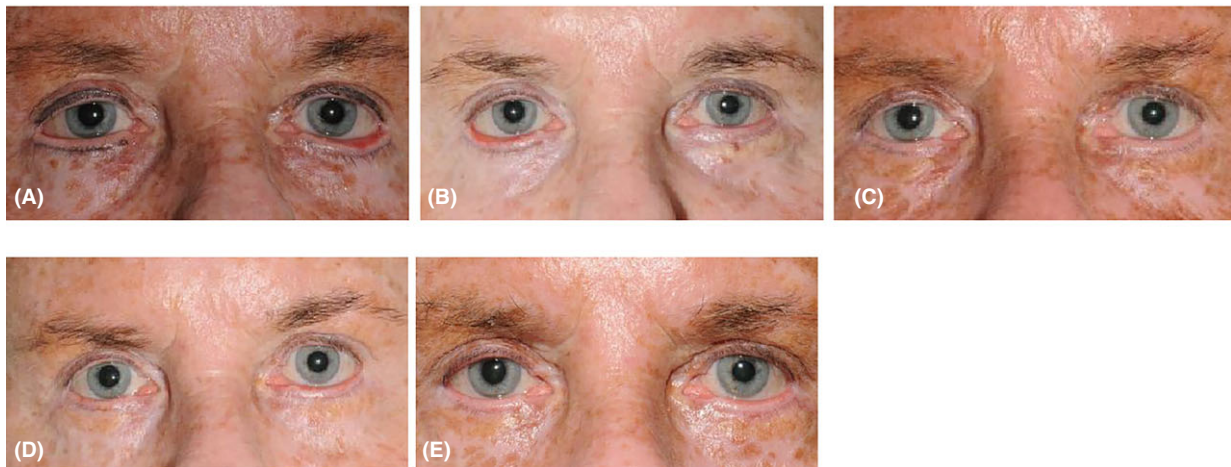


Fig. 2. Surgical outcomes. 1. Seventy-five-year-old patient with cicatricial ectropion of her left lower eyelid after excision of a basal cell carcinoma. (A) Preoperative view; (B) 1 week after ectropion repair with a free graft from the ipsilateral upper eyelid and (C) 3 months postoperatively. 2. Sixty-one-year-old patient with cicatricial ectropion of his right lower eyelid after correction of an involutional ectropion elsewhere (medial spindle and wedge excision). (A) Preoperative view; (B) 3 months postoperatively. 3. Seventy-year-old patient with bilateral cicatricial lower lid ectropion and dermatitis. (A) Preoperative view; (B) 8 months postoperatively with residual lagophthalmos and hyperaemia of the eyelid margin. 4. Sixty-two-year-old patient with cicatricial lower lid ectropion and dermatitis. (A) Preoperative view; (B) 3 months after correction of the left lower eyelid with visible contralateral ectropion; (C) 4 months after correction of the right lower eyelid; (D) recurrent ectropion of the left lower lid; (E) 4 months after reoperation (lateral block excision) of the left lower eyelid

seen only after supraclavicular and inner brachial donor sites. None of our patients received a full-thickness skin graft from these nonfacial donor sites.

Only two patients underwent additional procedures during cicatricial

ectropion repair, consisting of a mid-face lift in one patient and a medial conjunctival/retractor muscle spindle excision in another patient. The contribution of each of these concurrent procedures to the final outcome of the

full-thickness skin graft is likely variable. Furthermore, two patients with symptomatic recurrence requiring repeat ectropion repairs had grafts from preauricular regions. The significance of this finding is unclear, given

Table 2. Aetiology of cicatricial ectropion.

Iatrogenic	
Following excision of skin malignancy	16
After involutinal ectropion correction	8
Scarring following cosmetic surgery	1
Trauma	2
Dermatologic conditions	11

Table 3. Complications.

Recurrent ectropion	
Asymptomatic	9 (24%)
Requiring repair	2 (5%)
Contact dermatitis	1 (3%)
Graft failure	0

the small sample size and the limitations of a retrospective chart review.

The authors acknowledge the average recorded mean follow-up period may be relatively short, as recurrences may occur at a later stage. However, in our referral hospital, we have a policy to ask every patient to return to the clinic when problems occur at later stage than the last follow-up visit. It would be most probable that patients with a significant recurrence would contact our service again. Furthermore, the overall surgical success rate in our study was 71% with resolution of ectropion and stable eyelid position in 27 of 38 eyelids. This corresponds to the results of Choi et al. (2015), reporting an overall success rate of 76%. All of their recurrences requiring intervention were observed at 2 and 3 months postoperatively. Only asymptomatic recurrent ectropion was reported at a later stage, even up to 2.5 years postoperatively. Late recurrences could reflect the continued ageing changes in the lid tissues, rather than undercorrection at the time of initial surgery (McKelvie et al. 2018).

Conclusion

Within the limitations of a non-comparative case series, this study on the use of the lateral block technique combined with full-thickness skin grafts demonstrates promising results with fairly high overall surgical success rates. We feel that this procedure generally provides satisfactory results in patients with cicatricial lower eyelid ectropion and horizontal lid laxity.

References

- American Academy of Ophthalmology (AAO), Basic and Clinical Science Course (BCSC) Section 07 (2016-2017): Orbit, Eyelids, and Lacrimal System. Foster JA (ed.). San Francisco, CA: American Academy of Ophthalmology 201.
- Anderson RL & Gordy DD (1979): The tarsal strip procedure. *Arch Ophthalmol* **97**: 2192–2196.
- Choi CJ, Bauza A, Yoon MK, Sobel RK & Freitag SK (2015): Full-Thickness Skin Graft as an Independent or Adjunctive Technique for Repair of Cicatricial Lower Eyelid Ectropion Secondary to Actinic Skin Changes. *Ophthalmic Plast Reconstr Surg* **31**: 474–477.
- Doxanas MT (1994): The lateral canthus in lower eyelid blepharoplasty. *Facial Plast Surg* **10**: 84–89.
- Knize DM (2002): The superficial lateral canthal tendon. *Plast Reconstr Surg* **109**: 1149–1157.
- Lai A Fat NNJ, Paridaens D & van den Bosch WA (2018): Surgical correction of involutinal lower lid entropion with lateral canthal eyelid block excision and imbrication of the capsulopalpebral ligament using non-buried non-resorbable imbricating sutures versus buried resorbable imbricating sutures. *Orbit* **2**: 1–6.
- Leibovitch I, Huilgol SC, Hsuan JD & Selva D (2005): Incidence of host site complications in periocular full thickness skin grafts. *Br J Ophthalmol* **89**: 219–222.
- Liebau J, Schulz A, Arens A, Tilkorn H & Schwipper V (2006): Management of lower lid ectropion. *Dermatol Surg* **32**: 1050–1056.
- McKelvie J, Papchenko T, Carroll S & Ng SG (2018): Cicatricial ectropion surgery: a prospective study of long-term symptom control, patient satisfaction and anatomical success. *Clin Exp Ophthalmol*. <https://doi.org/10.1111/ceo.13338> [Epub ahead of print].
- Moe KS & Linder T (2000): The lateral transorbital canthopexy for correction and prevention of ectropion. *Arch Facial Plast Surg* **2**: 9–15.
- Pascali M, Corsi A, Brinci L, Corsi I & Cervelli V (2014): The tarsal belt procedure for the correction of ectropion. *Br J Ophthalmol* **98**: 1691–1696.
- Rathore DS, Chickadasarahilli S, Crossman R, Mehta P & Ahluwalia HS (2014): Full Thickness Skin Graft in Periocular Reconstructions. *Ophthal Plast Reconstr Surg* **30**: 517–520.
- Salgarelli AC, Francomano M, Magnoni C & Bellini P (2012): Cicatricial iatrogenic lower eyelid malposition in skin cancer surgery: results of a combined approach. *J Craniofacial Surg* **40**: 579–583.

Received on May 14th, 2018.

Accepted on September 27th, 2018.

Correspondence:

Ilse Mol, MD
 Department of Ophthalmology
 Erasmus Medical Center's
 Gravendijkwal 230
 3015 CE
 Rotterdam
 The Netherlands
 Tel: +31 10 7040135
 Fax: +31 10 7033692
 Email: i.mol@erasmusmc.nl

The authors gratefully acknowledge the artistic work by Jessica Leenen and thank Willem van den Bosch, PhD MD for allowing us to use the schematic figures (presented in Fig. 1). The authors alone are responsible for the content and writing of the paper.