

A multidisciplinary review of triphalangeal thumb

Jacob W. P. Potuijt¹, Robert-Jan H. Galjaard²,
Peter J. van der Spek^{3,4}, Christianne A. van Nieuwenhoven¹,
Nadav Ahituv^{5,6}, Kerby C. Oberg⁷ and Steven E. R. Hovius¹

Journal of Hand Surgery
(European Volume)
2019, Vol. 44(1) 59–68
© The Author(s) 2018



Article reuse guidelines:
sagepub.com/journals-permissions
DOI: 10.1177/1753193418803521
journals.sagepub.com/home/jhs



Abstract

Despite being a rare congenital limb anomaly, triphalangeal thumb is a subject of research in various scientific fields, providing new insights in clinical research and evolutionary biology. The findings of triphalangeal thumb can be predictive for other congenital anomalies as part of an underlying syndrome. Furthermore, triphalangeal thumb is still being used as a model in molecular genetics to study gene regulation by long-range regulatory elements. We present a review that summarizes a number of scientifically relevant topics that involve the triphalangeal thumb phenotype. Future initiatives involving multidisciplinary teams collaborating in the field of triphalangeal thumb research can lead to a better understanding of the pathogenesis and molecular mechanisms of this condition as well as other congenital upper limb anomalies.

Keywords

Triphalangeal thumb, polydactyly, congenital limb deformities, hedgehog protein, genetic enhancer elements

Date received: 25th February 2018; revised: 27th August 2018; accepted: 2nd September 2018

Introduction

Triphalangeal thumb (TPT) is a congenital anomaly in which the thumb consists of three instead of two phalanges. Although TPT is relatively rare, it has been the central focus of a number of scientific disciplines in the past. Ever since the pathogenic locus of TPT was identified as the ZPA-regulatory sequence (ZRS), the long range control of the zone of polarizing activity (ZPA), genetic and molecular research on this regulatory element has expanded tremendously. Finally, TPT and other limb anomalies remain a popular model for studies by developmental biologists, especially in long-range gene regulation (Letelier et al., 2018; Lettice et al., 2017).

A number of reviews in the past have separately explored these research topics in which TPT is involved (Hill and Lettice, 2013; Petit et al., 2017; Qazi and Kassner, 1988). However, an overview that encompasses the variety of disciplines involved in TPT-research remains lacking. This review summarizes a range of relevant topics and underlines the importance of a multidisciplinary approach for both the clinical and scientific field in TPT management.

Clinical aspects

Phenotype

TPT most frequently presents as an isolated congenital upper limb anomaly (Figure 1a). In our series of 187 hands within the local Dutch population, 38%

¹Department of Plastic and Reconstructive Surgery and Hand Surgery, Erasmus MC, University Medical Center Rotterdam, Rotterdam, The Netherlands

²Department of Clinical Genetics, Erasmus MC, University Medical Center Rotterdam, Rotterdam, The Netherlands

³Department of Bioinformatics, Erasmus MC, University Medical Center Rotterdam, Rotterdam, The Netherlands

⁴Department of Pathology, Erasmus MC, University Medical Center Rotterdam, Rotterdam, The Netherlands

⁵Department of Bioengineering and Therapeutic Sciences, University of California San Francisco, SF, USA

⁶Institute for Human Genetics, University of California San Francisco, SF, USA

⁷Department of Pathology and Human Anatomy, Loma Linda University, Loma Linda, USA

Corresponding Author:

Jacob W. P. Potuijt, Department of Plastic, Reconstructive and Hand Surgery, Erasmus MC, University Medical Center Rotterdam, Ee-1589 Postbus 2040, 3015 GE Rotterdam, The Netherlands.

Email: j.potuijt@erasmusmc.nl

thumbs were isolated TPT without any other congenital hand anomalies (unpublished data). In the remaining cases (62%), other congenital limb anomalies like radial polydactyly are also present (Figure 1b). TPT with radial polydactyly is strongly associated with a positive family history when compared with cases of isolated TPT (OR: 3.8, CI 95%: 2.0 to 7.4, Supplementary Table 1 available online) (unpublished data). Therefore, in contrast to an isolated TPT that is observed in both sporadic and familial cases, we would consider TPT with radial polydactyly as predominantly an inherited disease.

Although isolated TPT and TPT with radial polydactyly remain the two most commonly reported TPT-phenotypes (Table 1), in recent years, however, we found that the number of cases with more severe TPT-phenotypes with thumb triplication and anomalies on the ulnar side has also increased. In addition, we have found that even when family members of a large genetic isolate share the same mutation, 71% of the patients from the youngest generations demonstrated more severe TPT-phenotypes than their ancestors (Figure 1c) (Baas et al., 2017; Zuidam et al., 2008).

The observation in the Dutch population is remarkable as it challenges the distinctions suggested by Wieczorek et al. (2010). This article

suggested that point mutations in the ZRS which, as mentioned, is a regulatory sequence of the ZPA controlling digit patterning, only causes TPT (with radial polydactyly) while genomic duplications of the ZRS cause more severe phenotypes like Triphalangeal Thumb-Polysyndactyly Syndrome (TPT-PS) (Figure 1d), Haas-type Polysyndactyly and Laurin-Sandrow Syndrome (LSS). Another problem is the inconsistency of nomenclature when it comes to phenotyping patients with anomalies; for example, Sato et al. (2007) used the term syndactyly type IV, a synonym of Haas-type polysyndactyly (OMIM:186200) for a phenotype that clearly resembles LSS, with patients exhibiting cup-shaped hands, polydactyly and mirror-image duplications of the lower limb. For consistent phenotyping, we propose the following definition of these hand anomalies.

- *TPT-PS*: TPT with pre- and postaxial polydactyly and syndactyly. A radial and ulnar 'block' of conjoined digits can be identified. Syndactyly or polydactyly of the feet can also be present.
- *Haas-Type Synpolydactyly*: complete syndactyly of all digits with polydactyly. Syndactyly or polydactyly of the feet can also be present.

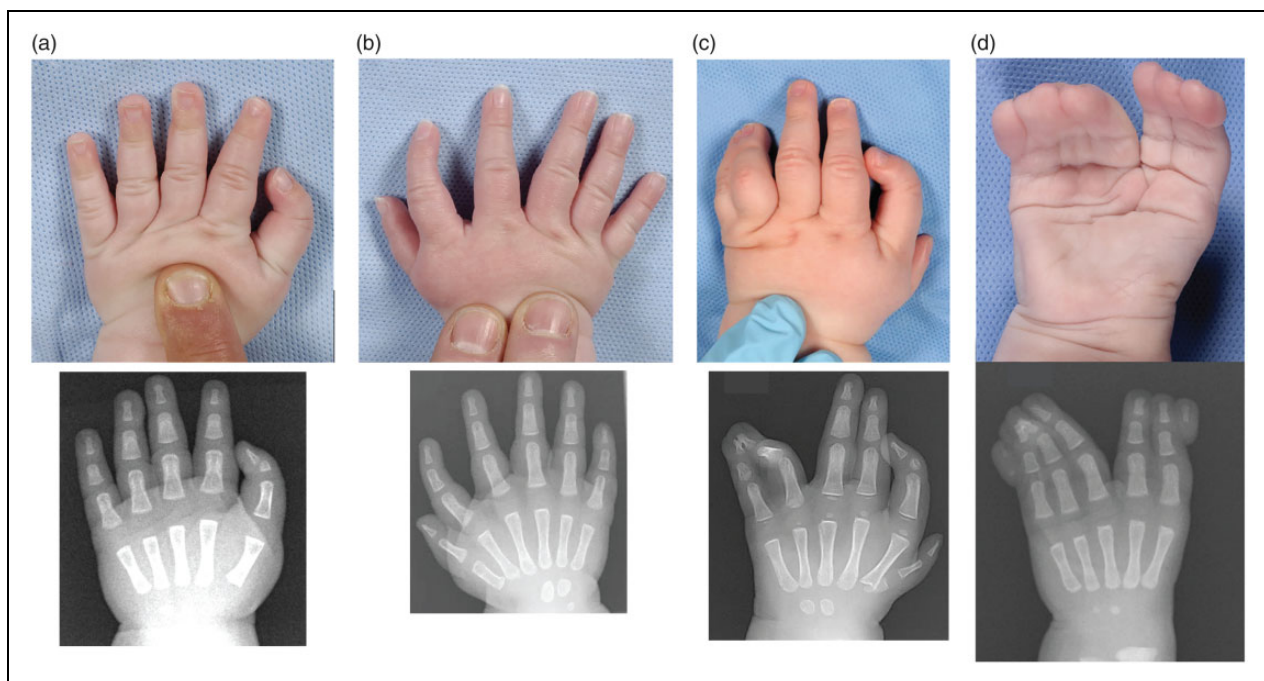


Figure 1. Clinical and radiological images show phenotypic variation in TPT. (a) Patient with an isolated TPT. (b) TPT with radial polydactyly. (c) TPT with radial polydactyly and ulnar syndactyly. (d) Triphalangeal thumb-polysyndactyly syndrome (TPT-PS), with radial and ulnar polysyndactyly.

Table 1. List of point mutations in the ZRS.

Author	Mutation	Phenotype
Lettice et al. (2003)	105 C > G	1+2+3+4+5
Zhao et al. (2016)	105 C > G	2
VanderMeer. (2012)	287 C > A	3+4+5
Furniss et al. (2008)	295 T > C	1+2
Albuisson et al. (2011)	297 G > A	2
Lettice et al. (2003)	305 A > T	2
Lettice et al. (2003)	323 T > C	1
Albuisson et al. (2011)	334 T > G	2+3
Semerci et al. (2009)	396 C > T	2
VanderMeer et al. (2014)	402 C > T	1+2+3
Lettice et al. (2003)	404 G > A	2+tibial hypoplasia
Cho et al. (2013)	404 G > A	2+tibial hypoplasia
Wieczorek et al. (2010)	404 G > C	1+tibial hypoplasia
Girisha et al. (2014)	404 G > T	2+RLD+tibial hypoplasia
Norbnop et al. (2014)	406 A > G	2+tibial hypoplasia
Zhao et al. (2016)	406 A > G	2
Wu et al. (2016)	428 T > A	1+2
Farooq et al. (2010)	463 T > G	2
Al-Qattan et al. (2012)	619 C > T	1+2+RLD
Gurnett et al. (2007)	621 C > G	2+3
Gurnett et al. (2007)	739 A > G	1

Phenotypes are classified as: (1) isolated TPT; (2) TPT+radial polydactyly; (3) TPT+radial polydactyly+feet anomalies; (4) TPT+radial polydactyly+ulnar poly(syn)dactyly; (5) TPT+radial polydactyly+ulnar poly(syndactyly)+feet anomalies. RLD: radial longitudinal deficiency

- *Laurin-Sandrow Syndrome*: complete syndactyly of all digits with polydactyly. Mirror-image duplications of the feet with tibia hypoplasia and duplication of the fibula can also be present.

Clinical assessment

Even though a supernumerary phalanx is the most evident aberration in a radiograph, TPT is often seen with other hypoplastic and absent structures; tendons, ligaments, intrinsic musculature and osseous fragments can all be abnormally formed in these patients. These aberrations eventually result in decreased thumb strength with TPT patients demonstrating decreased grip strength (69%) and opposition strength (63%) as compared with the control population [Zuidam et al., 2012].

Similar to children with TPT, adults who did not undergo an operation continue to show decreased thumb strength (77% grip strength and 62% opposition strength as compared with the control population), although function remains good for daily activities (visual analogue scale (VAS)-score for

function: 7.7 out of 10) [Zuidam et al., 2010]. The major concern in these patients, however, appears to be the aesthetic appearance of TPT (VAS-score for appearance: 2.2 out of 10).

The surgical procedure for correcting TPT depends on the specific phenotype. Reconstruction of a very hypoplastic TPT will not lead to satisfactory results and requires a more advanced procedure like pollicization of the second digit [Hovius et al., 2004]. For patients with stronger polydactylous types of TPT, direct reconstruction of the thumb can improve function and provides better aesthetic results. If the only anomaly is an additional triangular phalanx, removal of the supernumerary phalanx and ligament reconstruction might suffice [Zuidam et al., 2016]. Alternatively, when a TPT patient has a full-grown rectangular phalanx associated with lack of opposition, a more extensive procedure, such as a distal phalangeal joint reduction and arthrodesis combined with a rotation osteotomy and arthrodesis of the first metacarpal may be required [Hovius et al., 2004].

Epidemiology

The prevalence of TPT varies widely in regions around the world, with TPT-families mostly of European or Asian descent. Goldfarb et al. (2017) reported less than 10 patients with TPT in a series of 653 patients with upper limb anomalies in the USA. In contrast, studies from Sweden, Australia and the Netherlands have shown much higher rates of TPT [Ekblom et al., 2014; Tonkin et al., 2013; Vasluian et al., 2013]. The prevalence of TPT reported by Lapidus et al. (1943) is still regularly used as a standard; he reported a low prevalence of three cases among 75,000 military draftees in the USA. In contrast, our outpatient clinic has registered 130 cases of TPT since 1972 and currently, an average of seven patients with TPT visit our clinic annually. Therefore, when taking the proportional volume of our outpatient clinic into account, the nationwide prevalence of TPT in the Netherlands can be estimated at around 1 in 16,000 live births [Vasluian et al., 2013].

Associated malformations and syndromes

TPT is predominantly present without any anomalies other than in the limbs. However, several syndromes have been associated with TPT and although these are relatively rare, the presence of TPT can be predictive for the presence of other congenital malformations.

CulaPhen (Congenital Upper Limb Anomaly Phenotyping), an open-access software package developed by our research group, enables us to

associate other congenital anomalies and syndromes with limb anomalies in patients with TPT (Baas et al., 2017). The associated congenital anomalies for each syndrome are visualized in a heatmap (Figure 2) with the strength of association between different groups of congenital anomalies and a specific anomaly illustrated in a ratio from white to bright red. For example, ZRS-associated upper limb anomalies are associated with lower limb anomalies, while Holt-Oram syndrome (OMIM:142900) is well known for the association between limb and heart anomalies.

This heatmap shows that TPT can be differentiated in two main groups: a polydactylous group in which limb malformations are dominantly present (ZRS-associated and *GLI3*-associated anomalies) and a hypoplastic group, with different combinations of congenital anomalies (for example in Fanconi Anaemia and VACTERL). Notably, although *GLI3* has been associated with TPT by CulaPhen, none of the patients with *GLI3* mutations who have been examined in our outpatient clinic had TPT (unpublished data). Therefore, using this information, we can expect a low yield for detecting pathogenic variants in *GLI3* among patients with TPT.

The distinction between polydactylous and hypoplastic TPT can also be made using other approaches. Ingenuity Pathway Analysis visualizes the different molecular pathways for the origins of these different syndromes (Kramer et al., 2014). The pathway shows that the polydactylous group is caused by specific developmental genes involved in limb patterning, whereas in the hypoplastic group, two major pathways are involved. The first pathway has a role in cell growth and differentiation, with malfunctioning genes within this pathway leading to either overgrowth syndromes (like *PIK3CA*) or hypoplasia (*FGFR3*); whereas the second involves ribosomal protein subunits and manage translation and breakdown of protein, with Diamond-Blackfan Anaemia (OMIM:105650) as one of the syndromes caused by a disruption in this pathway. Furthermore, in the classification of genetic skeletal disorders, ZRS and *GLI3*-associated diseases are categorized under the 'Polydactyly-syndactyly-triphalangism group' and the other syndromes are categorized under the 'Limb hypoplasia-reduction defects' group (Bonafe et al., 2015).

The final way of analysing associated syndromes with TPT is through clinical observation and review. From our own series of TPT patients, we discovered that hypoplastic TPT is highly associated with multiple congenital malformations compared with patients with a polydactylous type of TPT (OR: 14.4, CI 95%: 4.7 to 44.4, Supplementary Table 2, available

online) (unpublished data). Furthermore, the surgical treatment for both types of TPT differs as well. TPT with polydactylous features can be reconstructed to become a functioning thumb, but hypoplastic TPT may preclude reconstruction and require more advanced surgical interventions like pollicization of the second digit (Hovius et al., 2004).

TPT as a dysregulation of normal thumb development

The biphalangeal thumb is the last digit to form and develops at the anterior or radial border of the handplate. The thumb is strikingly different from the other four digits and develops in a disparate molecular environment (Oberg, 2014; Oberg et al., 2010) (Figure 3). Sonic hedgehog (Shh) proteins emanating from the ZPA generates a posterior diffusion gradient across the handplate that regulates the development of the other triphalangeal ulnar digits. Shh manifests its action through the Gli3 transcription factor, which is expressed throughout the handplate and in its absence, Gli3 is processed into a repressive form, Gli3r, inhibiting the targets of Shh (te Welscher et al., 2002; Wang et al., 2000). The thumb domain is considered Shh independent and therefore Gli3r dependent (Harfe et al., 2004). In the homozygote Gli3-deficient mouse mutant extra toes (Xt), the handplate paddle expands and triphalangeal polydactyly develops (Chen et al., 2004; Hui and Joyner, 1993), while in the heterozygote with reduced Gli3, the limb paddle width continues to expand, resulting in the radial polydactyly phenotype. Gli3r expression, although reduced in these heterozygote mice, still persists and thus the extra radial digits formed are biphalangeal (Chen et al., 2004). The thumb domain also lacks the expression of HoxD11-12 that are critical to the triphalangeal character of the ulnar digits (Montavon et al., 2008). Therefore, if HoxD12 is over expressed in the thumb domain, especially with reduced Gli3, a TPT is formed (Chen et al., 2004). Ectopic expression of Shh in the anterior or radial aspect of the handplate, as occurs with many point mutations of the limb specific *SHH/ZPA* regulatory region (see below), would therefore be expected to reduce or eliminate Gli3r expression and thus promote the formation of TPT.

Genetic aspects

In the early 1990s, it was discovered that large families with limb anomalies like polydactyly and TPT were highly suitable for the localization of genes involved in limb development. The zone of

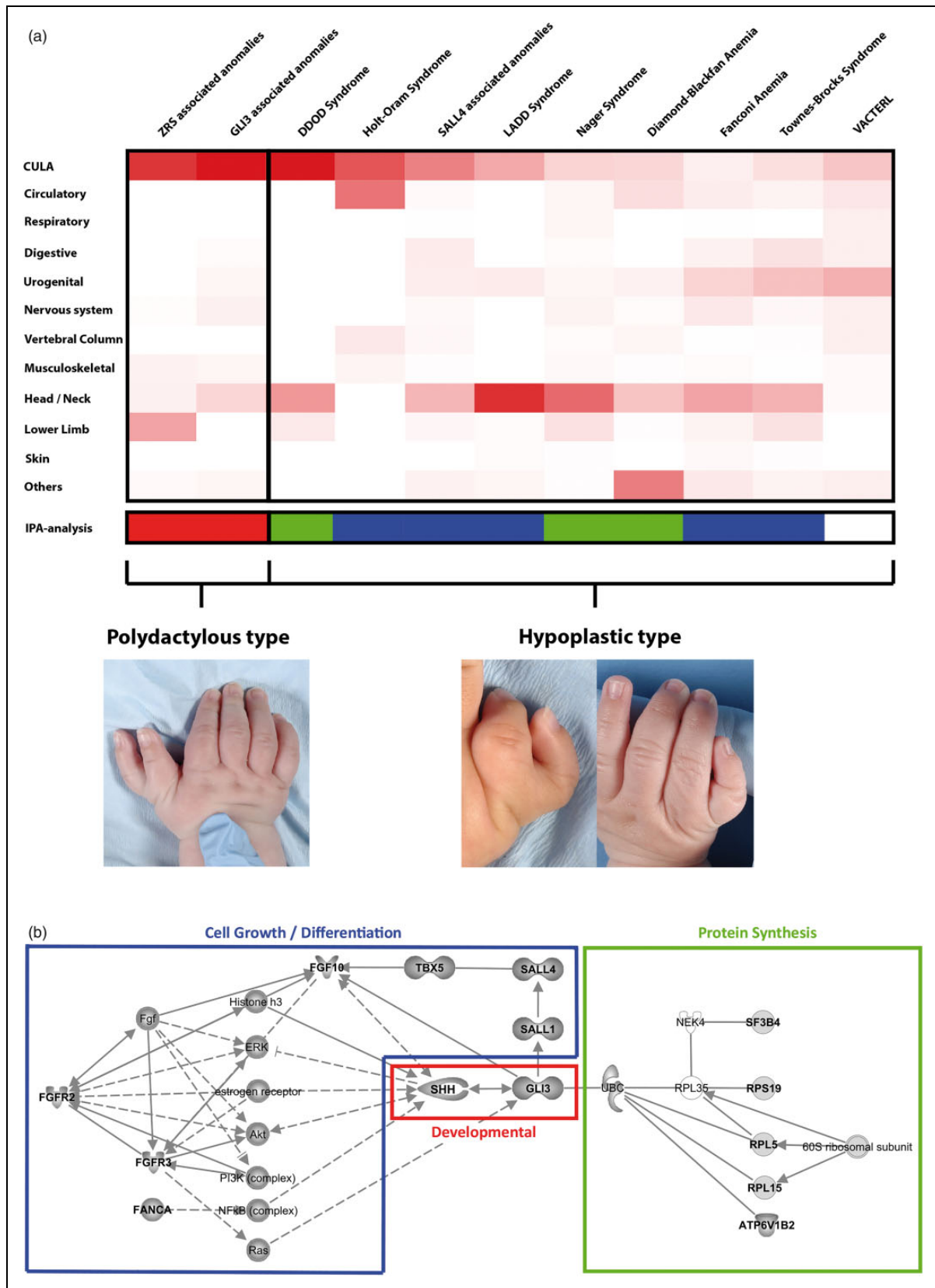


Figure 2. Heatmap, generated by CulaPhen, visualizing the relation between TPT-associated syndromes and different groups of congenital anomalies. The strength of association between each syndrome and each anomaly group is depicted on a scale from white to bright red. ZRS and GLI3 associated anomalies predominantly result in a polydactylous phenotype (a) and other syndromes are mainly seen with hypoplastic TPT phenotypes (b).

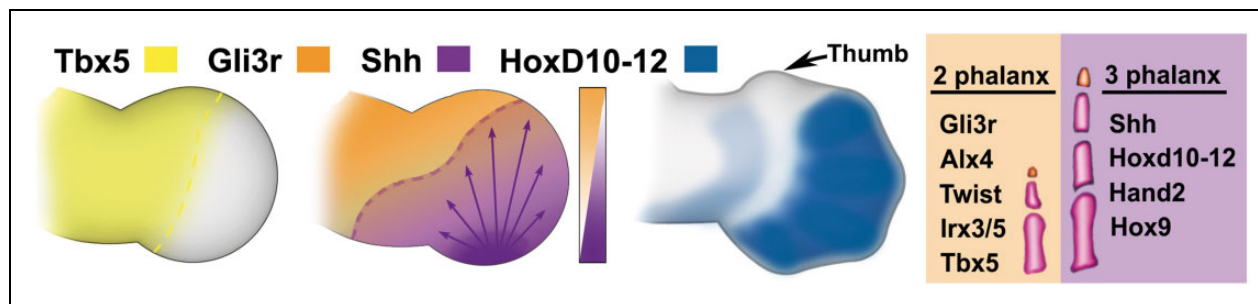


Figure 3. Thumb and digit development. Key molecules that differentiate the thumb from the ulnar digits. Tbx5 is involved in limb induction and forelimb patterning. Tbx5 persists in the thumb domain (murine embryonic Day 12 similar to Carnegie Stage 16). Along the radioulnar axis Gli3r and Shh form counter gradients that define digit morphology. Subsequently (murine embryonic Day 13 similar to Carnegie stage 18) HoxD10-12 transcription factors are expressed in ulnar digits, but not the thumb domain. The far right panel lists the different genes expressed within biphalangeal (2 phalanx) and triphalangeal (3 phalanx) digits. The backgrounds reflect the suspected primary genes responsible – orange (Gli3r) for the thumb domain and purple (Shh) for the ulnar digits. (Modified from Oberg et al. (2004) and Oberg, (2014)).

polarizing activity (ZPA) regulatory sequence, otherwise known as the ZRS, a limb-specific regulatory element for *SHH*, has been the main focus for genetic research in TPT-families. As mentioned, point mutations in the ZRS cause TPT (with polydactyly), whereas large duplications encompassing the ZRS cause more severe phenotypes like TPT-PS and Haas-type polysyndactyly.

Identification of the ZRS

Heutink et al. (1994) and Tsukurov et al. (1994) simultaneously published results of linkage studies in two Dutch TPT-families to mutations in chromosome 7q36. Heus et al. (1999) additionally mapped chromosome 7q36 and narrowed the critical disease region to 450 kb. Owing to the presence of a chromosomal translocation with a breakpoint in intron 5 of *LMBR1* in a patient with TPT with preaxial polydactyly (PPD) and a 2 bp insertion in polydactylous mice at the same location, intron 5 of *LMBR1* was identified as the critical location responsible for limb deformities (Lettice et al., 2002). Previous studies suggested that polydactyly in mice was caused by ectopic expression of *SHH* in the anterior or radial limb bud (Riddle et al., 1993; Sharpe et al., 1999). Therefore, the authors hypothesized that a regulatory element in intron 5 of *LMBR1* is responsible for TPT/PPD by disrupting expression of *SHH*, a gene that lies approximately 950 kb downstream.

The critical region of the ZRS was confined to a size of 774 bp through comparative genomics (Lettice et al., 2003). Further studies have shown that point mutations in the ZRS cause ectopic *SHH* expression in the anterior or radial part of the limb bud, resulting in TPT and polydactyly in human, mice

and cats (Hill and Lettice, 2013; Lettice et al., 2003, 2008).

Point mutations

Since the identification of the ZRS, 19 different point mutations have been described in TPT-families (Al-Qattan et al., 2012; Albuissou et al., 2011; Cho et al., 2013; Farooq et al., 2010; Furniss et al., 2008; Girisha et al., 2014; Gurnett et al., 2007; Lettice et al., 2003; Norbnoop et al., 2014; Semerci et al., 2009; VanderMeer et al., 2012; VanderMeer et al., 2014; Wieczorek et al., 2010; Wu et al., 2016; Zhao et al., 2016) (Table 1). These point mutations cause a wide phenotypic spectrum of limb anomalies; some mutations only result in mild presentations of TPT with reduced penetrance (Albuissou et al., 2011; Farooq et al., 2010; Furniss et al., 2008; Gurnett et al., 2007), whereas complex anomalies like TPT accompanied with tibial hypoplasia have been observed in families with point mutations between positions 402 and 406 of the ZRS (Cho et al., 2013; Girisha et al., 2014; Lettice et al., 2003; Norbnoop et al., 2014; VanderMeer et al., 2014; Wieczorek et al., 2010).

As TPT/PPD follows an autosomal-dominant trait in affected families, most patients with TPT are heterozygous for these point mutations. Homozygosity of ZRS mutations have been described in three cases (Furniss et al., 2008; Semerci et al., 2009; VanderMeer et al., 2014), with two of these homozygous patients sharing a similar TPT/PPD phenotype with their heterozygous family members. However, Vandermeer et al. (2012) demonstrated that one homozygous patient had a more severe phenotype than heterozygous family members, suggesting the presence of a dosage effect. As these three cases

have different observations and conclusions, the presence of a dosage effect in point-mutations of the ZRS remains uncertain.

Genomic duplications

Compared with point mutations in the ZRS, genomic duplications overlapping the ZRS lead to more severe phenotypes such as TPT-PS, Haas-Type Polysyndactyly and Laurin-Sandrow Syndrome (LSS). It has been suggested that duplications smaller than 80 kb cause LSS and mutations larger than 80 kb result in TPT-PS and Haas-type polysyndactyly (Lohan et al., 2014). Although the duplication size and severity of the phenotype are clearly correlated, these three phenotypes cannot be typed as single entities as these different phenotypes are observed in families with the same duplication size (Table 2). Therefore, these three phenotypes should be viewed

in a gradual spectrum of phenotypic expression associated with duplications of the ZRS rather than different phenotypic entities caused by different sizes of genomic duplications.

The mechanism by which duplications of the ZRS occur and that result in severe TPT-phenotypes remains unknown. One theory could be that genomic duplications affect the dose sensitivity of regulatory elements as shown in other loci like *Indian Hedgehog (IHH)* (Will et al., 2017). Another known feature of genomic duplications is their ability to rearrange the three-dimensional chromatin architecture of the genome (Franke et al., 2016). Considering the severity of the phenotypes of TPT-PS, Haas-type Polysyndactyly and LSS, the ability of genomic duplications to disrupt the boundary of the topological associated domain (TAD) of *SHH* and *LMBR1* can be regarded as a valid hypothesis. These duplications can disrupt the entire chromosomal architecture and leads to difficulties in the folding of regulatory elements towards *SHH*, which is required for appropriate gene regulation (Lupianez et al., 2016).

Table 2. List of genomic duplications encompassing the ZRS.

Authors	Duplication size	Phenotype
Lohan et al. (2014)	16 kb	LSS
Lohan et al. (2014)	47 kb	LSS
Lohan et al. (2014)	75 kb	LSS
Wieczorek et al. (2010)	73 kb	Haas type
Wu et al. (2009)	97 kb	LSS + Haas type
Dai et al. (2013)	115 kb	Haas type
Sun et al. (2008)	160 kb	TPT-PS
Lohan et al. (2014)	179 kb	Haas type
Lohan et al. (2014)	255 kb	TPT-PS
Wieczorek et al. (2010)	276 kb	TPT-PS + Haas type
Liu et al. (2017)	290 kb	TPT + radial polydactyly + cardiac anomalies
Sun et al. (2008)	293 kb	TPT-PS + Haas type
Sun et al. (2008)	334 kb	TPT-PS + Haas type
Sun et al. (2008)	378 kb	TPT-PS
Sun et al. (2008)	437 kb	TPT-PS + Haas type
Xing et al. (2014)	442 kb	TPT-PS
Sun et al. (2008)	459 kb	TPT-PS
Klopocki et al. (2008)	589 kb	TPT-PS
Wang et al. (2016)	?	TPT + radial polydactyly
Furniss et al. (2009)	? (Triplication)	Haas type

The phenotypes are categorized as Laurin-Sandrow Syndrome (LSS), Haas-type Polysyndactyly and Triphalangeal Thumb-Polysyndactyly Syndrome (TPT-PS).

Beyond the ZRS?

The ZRS is the best known *SHH* enhancer as it has been extensively used as a model for long-range regulation of gene expression. However, several other regulatory elements besides the ZRS are known in the *SHH-LMBR1* topological domain (Anderson et al., 2014). These regulatory elements do not regulate *SHH*-expression in the limbs, but are responsible for expression in other structures like the brain, pharynx or larynx (Sagai et al., 2009). These enhancers can also drive *SHH*-expression at the same time in a single tissue. Therefore, the question arises if the ZRS is the only limb-specific enhancer within this TAD. Petit et al. (2016) reported a large family with TPT and hypertrichosis with a 2 kb deletion in the gene desert between *SHH* and *LMBR1*, possibly pointing to another element in this TAD that might be involved. Furthermore, several studies have associated mutations in the pZRS, a region approximately 800 bp upstream from the ZRS, with TPT in humans and dogs (Park et al., 2008; Xiang et al., 2017). Recently, molecular research in transgenic mice showed that disruption of the pZRS caused differential enhancer activity in the embryonic limb, underlining the functional role of the pZRS in limb development (Potuijt et al., 2018) (Table 3).

TPT families without mutations in the ZRS are of major importance to unfold the entire regulatory landscape of *SHH* in the limbs. Massive parallel sequencing with a focus on the *SHH-LMBR1* TAD is a valid strategy to identify the pathogenic locus in

Table 3. List of other aberrations on chromosome 7q36 that are associated with TPT.

Authors	Genetic aberration	Phenotype
Lettice et al. (2002)	translocation(5,7)(q11,q36), ZRS included	TPT + radial polydactyly
Laurell et al. (2012)	13 bp insertion in the ZRS	TPT + radial polydactyly
Vanlerberghe et al. (2015)	417A > G point mutation in ZRS (somatic mosaicism)	Mirror image polydactyly
Petit et al. (2016)	2 kb Deletion between SHH and ZRS	TPT + radial polydactyly + hypertrichosis
Potuijt et al. (2018)	Point mutation in the pre-ZRS	TPT-PS
Xiang et al. (2017)	Point mutations in the pre-ZRS	Radial polydactyly

ZRS: zone of polarizing activity–regulatory sequence; TPT: triphalangeal thumb; SHH: Sonic hedgehog; TPT-PS: Triphalangeal Thumb-Polysyndactyly Syndrome

these TPT-families and could point to new limb-specific regulatory elements in this TAD.

Summary

The multidisciplinary approach of TPT affirms the relevance of this congenital anomaly in scientific research. Clinically, research on the best techniques used in TPT continues, focusing on the measure of pre- and postoperative thumb function, in combination with patient-reported outcomes in order to achieve better functional and aesthetic outcomes. In addition, the phenotype of TPT not only determines choice of treatment, but also aids the clinician in genetic counselling. TPT accompanied with PPD is highly associated with a positive family history. Important information can be obtained during clinical examination that advocates for additional clinical work-up. In case of a polydactylous TPT, usually no other congenital malformations are present. Patients with a hypoplastic type of TPT, however, should be considered for further clinical work-up.

For genetic work-up of a polydactylous TPT phenotype, the ZRS and pZRS are currently the candidate loci to be examined. As hypoplastic TPT is associated with a variety of syndromes, next-generation sequencing techniques are valid options to identify the disease-causing mutation in these patients.

The cause of the large phenotypic variability in ZRS mutations and duplications is yet to be unravelled in the genetic and developmental field. Both the intrafamilial and interfamilial variability in affected families hypothesize that subtle variations in the location, timing and levels of *SHH* expression can result in a variety of phenotypes. The mechanism that drives these slight phenotypic variations, however, is not well understood. As it has been demonstrated that non-coding elements occupy an essential role in embryonic development, future initiatives with either a biological, molecular approach or a clinical genetic approach can lead to the

identification of new limb-specific non-coding elements in the *SHH-LMBR1* topological domain.

Declaration of conflicting interests The authors declared no potential conflicts of interest with respect to the research, authorship, and/or publication of this article.

Funding The authors received no financial support for the research, authorship, and/or publication of this article.

Supplementary material Additional supplemental information may be found with the online version of this article.

References

- Al-Qattan MM, Al Abdulkareem I, Al Haidan Y, Al Balwi M. A novel mutation in the SHH long-range regulator (ZRS) is associated with preaxial polydactyly, triphalangeal thumb, and severe radial ray deficiency. *Am J Med Genet A*. 2012, 158: 2610–5.
- Albuissou J, Isidor B, Giraud M et al. Identification of two novel mutations in Shh long-range regulator associated with familial pre-axial polydactyly. *Clin Genet*. 2011, 79: 371–7.
- Anderson E, Devenney PS, Hill RE, Lettice LA. Mapping the Shh long-range regulatory domain. *Development*. 2014, 141: 3934–43.
- Baas M, Potuijt JWP, Hovius SER, Hoogeboom AJM, Galjaard RH, van Nieuwenhoven CA. Intrafamilial variability of the triphalangeal thumb phenotype in a Dutch population: evidence for phenotypic progression over generations? *Am J Med Genet A*. 2017, 173: 2898–905.
- Bonafe L, Cormier-Daire V, Hall C et al. Nosology and classification of genetic skeletal disorders: 2015 revision. *Am J Med Genet A*. 2015, 167: 2869–92.
- Chen Y, Knezevic V, Ervin V, Hutson R, Ward Y, Mackem S. Direct interaction with Hoxd proteins reverses Gli3-repressor function to promote digit formation downstream of Shh. *Development*. 2004, 131: 2339–47.
- Cho TJ, Baek GH, Lee HR, Moon HJ, Yoo WJ, Choi IH. Tibial hemimelia-polydactyly-five-fingered hand syndrome associated with a 404 G>A mutation in a distant sonic hedgehog cis-regulator [ZRS]: a case report. *J Pediatr Orthop B*. 2013, 22: 219–21.
- Dai L, Guo H, Meng H et al. Confirmation of genetic homogeneity of syndactyly type IV and triphalangeal thumb-polysyndactyly syndrome in a Chinese family and review of the literature. *Eur J Pediatr*. 2013, 172: 1467–73.

- Eklblom AG, Laurell T, Arner M. Epidemiology of congenital upper limb anomalies in Stockholm, Sweden, 1997 to 2007: application of the Oberg, Manske, and Tonkin classification. *J Hand Surg Am.* 2014, 39: 237–48.
- Farooq M, Troelsen JT, Boyd M et al. Preaxial polydactyly/triphalangeal thumb is associated with changed transcription factor-binding affinity in a family with a novel point mutation in the long-range cis-regulatory element ZRS. *Eur J Hum Genet.* 2010, 18: 733–6.
- Franke M, Ibrahim DM, Andrey G et al. Formation of new chromatin domains determines pathogenicity of genomic duplications. *Nature.* 2016, 538: 265–9.
- Furniss D, Kan SH, Taylor IB et al. Genetic screening of 202 individuals with congenital limb malformations and requiring reconstructive surgery. *J Med Genet.* 2009, 46: 730–5.
- Furniss D, Lettice LA, Taylor IB et al. A variant in the sonic hedgehog regulatory sequence (ZRS) is associated with triphalangeal thumb and deregulates expression in the developing limb. *Hum Mol Genet.* 2008, 17: 2417–23.
- Girisha KM, Bidchol AM, Kamath PS et al. A novel mutation (g.106737g>t) in zone of polarizing activity regulatory sequence (ZRS) causes variable limb phenotypes in Werner mesomelia. *Am J Med Genet A.* 2014, 164: 898–906.
- Goldfarb CA, Shaw N, Steffen JA, Wall LB. The prevalence of congenital hand and upper extremity anomalies based upon the New York Congenital Malformations Registry. *J Pediatr Orthop.* 2017, 37: 144–8.
- Gurnett CA, Bowcock AM, Dietz FR, Morcuende JA, Murray JC, Dobbs MB. Two novel point mutations in the long-range SHH enhancer in three families with triphalangeal thumb and preaxial polydactyly. *Am J Med Genet A.* 2007, 143: 27–32.
- Harfe BD, Scherz PJ, Nissim S, Tian H, McMahon AP, Tabin CJ. Evidence for an expansion-based temporal Shh gradient in specifying vertebrate digit identities. *Cell.* 2004, 20: 517–28.
- Heus HC, Hing A, van Baren MJ et al. A physical and transcriptional map of the preaxial polydactyly locus on chromosome 7q36. *Genomics.* 1999, 57: 342–51.
- Heutink P, Zguricas J, Van Oosterhout L et al. The gene for triphalangeal thumb maps to the subtelomeric region of chromosome 7q. *Nat Genet.* 1994, 6: 287–92.
- Hill RE, Lettice LA. Alterations to the remote control of Shh gene expression cause congenital abnormalities. *Philos Trans R Soc Lond B Biol Sci.* 2013, 368: 20120357.
- Hovius SE, Zuidam JM, de Wit T. Treatment of the triphalangeal thumb. *Tech Hand Up Extrem Surg.* 2004, 8: 247–56.
- Hui CC, Joyner AL. A mouse model of Greig cephalopolysyndactyly syndrome: the extra-toes mutation contains an intragenic deletion of the *Gli3* gene. *Nat Genet.* 1993, 3: 241–6.
- Klopocki E, Ott CE, Benatar N, Ullmann R, Mundlos S, Lehmann K. A microduplication of the long range SHH limb regulator (ZRS) is associated with triphalangeal thumb-polysyndactyly syndrome. *J Med Genet.* 2008, 45: 370–5.
- Kramer A, Green J, Pollard J Jr, Tugendreich S. Causal analysis approaches in ingenuity pathway analysis. *Bioinformatics.* 2014, 30: 523–30.
- Lapidus PW, Guidotti FP, Colletti CJ. Triphalangeal thumb. Report of 6 cases. *Surg Gynecol Obstet.* 1943, 77: 178–86.
- Laurell T, Vandermeer JE, Wenger AM et al. A novel 13 base pair insertion in the sonic hedgehog ZRS limb enhancer (ZRS/LMBR1) causes preaxial polydactyly with triphalangeal thumb. *Hum Mutat.* 2012, 33: 1063–6.
- Letelier J, de la Calle-Mustienes E, Pieretti J et al. A conserved Shh cis-regulatory module highlights a common developmental origin of unpaired and paired fins. *Nat Genet.* 2018, 50: 504–9.
- Lettice LA, Devenney P, De Angelis C, Hill RE. The conserved sonic hedgehog limb enhancer consists of discrete functional elements that regulate precise spatial expression. *Cell Rep.* 2017, 20: 1396–408.
- Lettice LA, Heaney SJ, Purdie LA et al. A long-range Shh enhancer regulates expression in the developing limb and fin and is associated with preaxial polydactyly. *Hum Mol Genet.* 2003, 12: 1725–35.
- Lettice LA, Hill AE, Devenney PS, Hill RE. Point mutations in a distant sonic hedgehog cis-regulator generate a variable regulatory output responsible for preaxial polydactyly. *Hum Mol Genet.* 2008, 17: 978–85.
- Lettice LA, Horikoshi T, Heaney SJ et al. Disruption of a long-range cis-acting regulator for Shh causes preaxial polydactyly. *Proc Natl Acad Sci USA.* 2002, 99: 7548–53.
- Liu Z, Yin N, Gong L et al. Microduplication of 7q36.3 encompassing the SHH longrange regulator (ZRS) in a patient with triphalangeal thumbpoly-syndactyly syndrome and congenital heart disease. *Mol Med Rep.* 2017, 15: 793–7.
- Lohan S, Spielmann M, Doelken SC et al. Microduplications encompassing the Sonic hedgehog limb enhancer ZRS are associated with Haas-type polydactyly and Laurin-Sandrow syndrome. *Clin Genet.* 2014, 86: 318–25.
- Lupianez DG, Spielmann M, Mundlos S. Breaking tads: How alterations of chromatin domains result in disease. *Trends Genet.* 2016, 32: 225–37.
- Montavon T, Le Garrec JF, Kerszberg M, Duboule D. Modeling Hox gene regulation in digits: reverse collinearity and the molecular origin of thumbness. *Genes Dev.* 2008, 22: 346–59.
- Norbnop P, Srichomthong C, Suphapeetiporn K, Shotelersuk V. ZRS406A>G mutation in patients with tibial hypoplasia, polydactyly and triphalangeal first fingers. *J Hum Genet.* 2014, 59: 467–70.
- Oberg KC. Review of the molecular development of the thumb: digit primera. *Clin Orthop Relat Res.* 2014, 472: 1101–5.
- Oberg KC, Feenstra JM, Manske PR, Tonkin MA. Developmental biology and classification of congenital anomalies of the hand and upper extremity. *J Hand Surg Am.* 2010, 35: 2066–76.
- Oberg KC, Greer LF, Naruse T. Embryology of the upper limb: the molecular orchestration of morphogenesis. *Handchir Mikrochir Plast Chir.* 2004, 36: 98–107.
- Park K, Kang J, Subedi KP, Ha JH, Park C. Canine polydactyl mutations with heterogeneous origin in the conserved intronic sequence of LMBR1. *Genetics.* 2008, 179: 2163–72.
- Petit F, Jourdain AS, Holder-Espinasse M et al. The disruption of a novel limb cis-regulatory element of SHH is associated with autosomal dominant preaxial polydactyly-hypertrichosis. *Eur J Hum Genet.* 2016, 24: 37–43.
- Petit F, Sears KE, Ahituv N. Limb development: a paradigm of gene regulation. *Nat Rev Genet.* 2017, 18: 245–58.
- Potuijt JWP, Baas M, Sukenik-Halevy R et al. A point mutation in the pre-ZRS disrupts sonic hedgehog expression in the limb bud and results in triphalangeal thumb-polysyndactyly syndrome. *Genet Med.* Epub ahead of print, 15 March 2018. DOI: 10.1038/gim.2018.18.
- Qazi Q, Kassner EG. Triphalangeal thumb. *J Med Genet.* 1988, 25: 505–20.
- Riddle RD, Johnson RL, Laufer E, Tabin C. Sonic hedgehog mediates the polarizing activity of the ZPA. *Cell.* 1993, 75: 1401–16.
- Sagai T, Amano T, Tamura M, Mizushima Y, Sumiyama K, Shiroishi T. A cluster of three long-range enhancers directs regional Shh expression in the epithelial linings. *Development.* 2009, 136: 1665–74.
- Sato D, Liang D, Wu L et al. A syndactyly type IV locus maps to 7q36. *J Hum Genet.* 2007, 52: 561–4.

- Semerci CN, Demirkan F, Ozdemir M et al. Homozygous feature of isolated triphalangeal thumb-preaxial polydactyly linked to 7q36: no phenotypic difference between homozygotes and heterozygotes. *Clin Genet*. 2009, 76: 85–90.
- Sharpe J, Lettice L, Hecksher-Sorensen J, Fox M, Hill R, Krumlauf R. Identification of sonic hedgehog as a candidate gene responsible for the polydactylous mouse mutant Sasquatch. *Curr Biol*. 1999, 9: 97–100.
- Sun M, Ma F, Zeng X et al. Triphalangeal thumb-polysyndactyly syndrome and syndactyly type IV are caused by genomic duplications involving the long range, limb-specific SHH enhancer. *J Med Genet*. 2008, 45: 589–95.
- te Welscher P, Kuijper S, Drenth T et al. Shh counteracts repression by Gli3 to enable progression of limb bud patterning. *Dev Biol*. 2002, 247: LB40.
- Tonkin MA, Tolerton SK, Quick TJ et al. Classification of congenital anomalies of the hand and upper limb: development and assessment of a new system. *J Hand Surg Am*. 2013, 38: 1845–53.
- Tsukurov O, Boehmer A, Flynn J et al. A complex bilateral polysyndactyly disease locus maps to chromosome 7q36. *Nat Genet*. 1994, 6: 282–6.
- VanderMeer JE, Afzal M, Alyas S, Haque S, Ahituv N, Malik S. A novel ZRS mutation in a Balochi tribal family with triphalangeal thumb, pre-axial polydactyly, post-axial polydactyly, and syndactyly. *Am J Med Genet A*. 2012, 158: 2031–5.
- VanderMeer JE, Lozano R, Sun M et al. A novel ZRS mutation leads to preaxial polydactyly type 2 in a heterozygous form and Werner mesomelic syndrome in a homozygous form. *Hum Mutat*. 2014, 35: 945–8.
- Vanlerberghe C, Faivre L, Petit F et al. Intrafamilial variability of ZRS-associated syndrome: characterization of a mosaic ZRS mutation by pyrosequencing. *Clin Genet*. 2015, 88: 479–83.
- Vasluian E, van der Sluis CK, van Essen AJ et al. Birth prevalence for congenital limb defects in the northern Netherlands: a 30-year population-based study. *BMC Musculoskelet Disord*. 2013, 14: 323.
- Wang B, Diao Y, Liu Q et al. An increased duplication of ZRS region that caused more than one supernumerary digits preaxial polydactyly in a large Chinese family. *Sci Rep*. 2016, 6: 38500.
- Wang B, Fallon JF, Beachy PA. Hedgehog-regulated processing of Gli3 produces an anterior/posterior repressor gradient in the developing vertebrate limb. *Cell*. 2000, 100: 423–34.
- Wieczorek D, Pawlik B, Li Y et al. A specific mutation in the distant sonic hedgehog (SHH) cis-regulator (ZRS) causes werner mesomelic syndrome (WMS) while complete ZRS duplications underlie Haas type polysyndactyly and preaxial polydactyly (PPD) with or without triphalangeal thumb. *Hum Mutat*. 2010, 31: 81–9.
- Will AJ, Cova G, Osterwalder M et al. Composition and dosage of a multipartite enhancer cluster control developmental expression of *Ihh* (Indian hedgehog). *Nat Genet*. 2017, 49: 1539–45.
- Wu L, Liang D, Niikawa N et al. A ZRS duplication causes syndactyly type IV with tibial hypoplasia. *Am J Med Genet A*. 2009, 149: 816–8.
- Wu PF, Guo S, Fan XF et al. A novel ZRS mutation in a Chinese patient with preaxial polydactyly and triphalangeal thumb. *Cytogenet Genome Res*. 2016, 149: 171–5.
- Xiang Y, Jiang L, Wang B, Xu Y, Cai H, Fu Q. Mutational screening of GLI3, SHH, preZRS, and in 102 Chinese children with nonsyndromic polydactyly. *Dev Dyn*. 2017, 246: 392–402.
- Xing XS, Zhu HW, Chen C, Wang SS, Luo Y, Zhang X. Mutation analysis of a Chinese pedigree with triphalangeal thumb-polydactyly syndrome. *Genet Mol Res*. 2014, 13: 246–54.
- Zhao X, Yang W, Sun M, Zhang X. [ZRS mutations in two Chinese Han families featuring triphalangeal thumbs and preaxial polydactyly]. *Zhonghua Yi Xue Yi Chuan Xue Za Zhi*. 2016, 33: 281–5.
- Zuidam JM, Ananta M, Hovius SER. Triplicated thumbs: a rarity? *J Plas Reconstr Aesth Surg*. 2008, 61: 1078–84.
- Zuidam JM, de Kraker M, Selles RW, Hovius SER. Evaluation of function and appearance of adults with untreated triphalangeal thumbs. *J Hand Surg Am*. 2010, 35: 1146–52.
- Zuidam JM, Selles RW, de Kraker M, Hovius SE. Outcome of two types of surgical correction of the extra phalanx in triphalangeal thumb: is there a difference? *J Hand Surg Eur*. 2016, 41: 253–7.
- Zuidam JM, Selles RW, Hovius SE. Thumb strength in all types of triphalangeal thumb. *J Hand Surg Eur*. 2012, 37: 751–4.