Ultrasound Obstet Gynecol 2019; **53**: 779–787
Published online in Wiley Online Library (wileyonlinelibrary.com). **DOI:** 10.1002/uog.19182.
This is an open access article under the terms of the Creative Commons Attribution-NonCommercial License, which permits use, distribution and reproduction in any medium, provided the original work is properly cited and is not used for commercial purposes.

Fetal megacystis: a lot more than LUTO

F. FONTANELLA[1], L. MAGGIO[1], J. B. G. M. VERHEIJ[2], L. K. DUIN[1], P. N. ADAMA VAN SCHELTEMA[3], T. E. COHEN-OVERBEEK[4], E. PAJKRT[5], M. BEKKER[6,7], C. WILLEKES[8], C. J. BAX[9], V. GRACCHI[10], D. OEPKES[3] and C. M. BILARDO[1]

[1]*Department of Obstetrics, Gynaecology and Prenatal Diagnosis, University Medical Center Groningen, University of Groningen, Groningen, The Netherlands;* [2]*Department of Genetics, University Medical Center Groningen, University of Groningen, Groningen, The Netherlands;* [3]*Department of Obstetrics, Gynaecology and Prenatal Diagnosis, Leiden University Medical Center, Leiden, The Netherlands;* [4]*Division of Obstetrics and Prenatal Medicine, Department of Obstetrics and Gynecology, Erasmus MC, University Medical Center Rotterdam, Rotterdam, The Netherlands;* [5]*Department of Obstetrics, Academic Medical Center Amsterdam, Amsterdam, The Netherlands;* [6]*Department of Obstetrics, Gynaecology and Prenatal Diagnosis, Radboud University Medical Center, Nijmegen, The Netherlands;* [7]*Department of Obstetrics, Gynaecology and Prenatal Diagnosis, University Medical Center Utrecht, Utrecht, The Netherlands;* [8]*Department of Obstetrics, Gynaecology and Prenatal Diagnosis, Maastricht University Medical Center, Grow School for Oncology and Medical Biology, Maastricht, The Netherlands;* [9]*Department of Obstetrics, Gynaecology and Prenatal Diagnosis, VU University Medical Center, Amsterdam, The Netherlands;* [10]*Department of Pediatrics, University Medical Center Groningen, University of Groningen, Groningen, The Netherlands*

KEYWORDS: anorectal malformation; fetal megacystis; lower urinary tract obstruction

ABSTRACT

Objective *Fetal megacystis presents a challenge in terms of counseling and management because of its varied etiology and evolution. The aim of this study was to present a comprehensive overview of the underlying etiologies and structural anomalies associated with fetal megacystis.*

Methods *This was a retrospective multicenter study of cases referred to the fetal medicine unit of one of the eight academic hospitals in The Netherlands with a diagnosis of fetal megacystis. For each case, data on and measurements of fetal urinary tract and associated structural anomalies were collected. All available postmortem examinations and postnatal investigations were reviewed in order to establish the final diagnosis. In the first trimester, fetal megacystis was defined as longitudinal bladder diameter (LBD) ≥ 7 mm, and in the second and third trimesters as an enlarged bladder failing to empty during an extended ultrasound examination lasting at least 40 min.*

Results *Of the 541 pregnancies with fetal megacystis, it was isolated (or solely accompanied by other signs of lower urinary tract obstruction (LUTO)) in 360 (67%) cases and associated with other abnormal ultrasound findings in 181 (33%) cases. The most common associated ultrasound anomaly was an increased nuchal translucency thickness (22%), followed by single umbilical artery (10%) and cardiac defect (10%). A final diagnosis was established in 418 cases, including 222 (53%) cases with isolated LUTO and 60 (14%) infants with normal micturition or minor isolated urological anomalies. In the remaining 136 (33%) cases, concomitant developmental or chromosomal abnormality or genetic syndrome was diagnosed. Overall, 40 chromosomal abnormalities were diagnosed, including trisomy 18 (n = 24), trisomy 21 (n = 5), Turner syndrome (n = 5), trisomy 13 (n = 3) and 22q11 deletion (n = 3). Thirty-two cases presented with anorectal malformations involving the anus, rectum and urogenital tract. In cases with confirmed urethral and anal atresia, megacystis occurred early in pregnancy and the bladder appeared severely distended (the LBD (in mm) was equal to or greater than twice the gestational age (in weeks)). Fetal macrosomia was detected in six cases and an overgrowth syndrome was detected in four cases, comprising two infants with Beckwith–Wiedemann syndrome and two with Sotos syndrome. Megacystis-microcolon-intestinal hypoperistalsis syndrome was diagnosed in five (1%) cases and prenatally suspected only in one case.*

Conclusions *Although the main cause of fetal megacystis is LUTO, an enlarged fetal bladder can also be present as a concomitant finding of miscellaneous genetic syndromes, developmental disturbances and chromosomal abnormalities. We provide an overview of the structural*

Correspondence to: Dr F. Fontanella, University Medical Center Groningen, University of Groningen, Hanzeplein 1, Groningen, The Netherlands (e-mail: federica.fontanella@gmail.com)

Accepted: 9 July 2018

© 2018 The Authors. *Ultrasound in Obstetrics & Gynecology* published by John Wiley & Sons Ltd on behalf of the International Society of Ultrasound in Obstetrics and Gynecology.

anomalies and congenital disorders associated with fetal megacystis and propose a practical guide for the differential diagnosis of genetic syndromes and chromosomal and developmental abnormalities in pregnancies presenting with fetal megacystis, focusing on the morphological examination of the fetus. © *2018 The Authors. Ultrasound in Obstetrics & Gynecology published by John Wiley & Sons Ltd on behalf of the International Society of Ultrasound in Obstetrics and Gynecology.*

INTRODUCTION

Fetal urine production begins at about 10 weeks' gestation, when the urinary bladder can be identified as an anechoic structure within the fetal pelvis, surrounded by the two umbilical arteries[1]. The finding of a distended urinary bladder, also known as fetal megacystis, is easily accomplished on ultrasound but difficult to manage owing to its varied etiology and uncertain evolution. In the first trimester, fetal megacystis is defined as longitudinal bladder diameter (LBD) $\geq$ 7 mm, and is present in 0.06% of pregnancies[2]. Beyond the first trimester, the prevalence of megacystis remains unclear and its definition is still ambiguous[3].

The main cause of fetal megacystis, diagnosed in any trimester of pregnancy, is bladder outlet obstruction, also known as lower urinary tract obstruction (LUTO)[4–6]. In cases with severe early megacystis, parents often choose to terminate the pregnancy. In less severe cases with early megacystis (LBD $\leq$ 12 mm) and negative work-up, a spontaneous resolution often occurs[4,6,7]. In fetuses surviving the second half of pregnancy, LUTO commonly leads to hydronephrosis, renal dysplasia and severe oligohydramnios, with a known poor prognosis. However, besides isolated LUTO, the differential diagnosis of fetal megacystis should also include chromosomal abnormalities, genetic syndromes and developmental anomalies. The wide spectrum of etiologies and prognoses makes the counseling and management of this condition particularly challenging[8]. Given the low prevalence of fetal megacystis[9,10] and the main focus on LUTO as etiology, the other causes of enlarged fetal bladder have, thus far, been poorly investigated.

The main aim of this study was to present a comprehensive overview of the underlying etiologies and structural anomalies associated with fetal megacystis and to identify patterns of anomalies and ultrasound features related to specific complex anomalies and syndromes, beyond LUTO.

METHODS

This study was part of a large retrospective multicenter study carried out at the fetal medicine units (FMUs) of all eight academic hospitals in The Netherlands that act as referral centers for fetal anomalies detected on ultrasound examination. Data on cases with a diagnosis of fetal megacystis were retrieved from local databases, from the time at which registration in each database had started (between 2000 and 2014 at Erasmus Medical Center and Academic Medical Center, Amsterdam, and at University Medical Center, Maastricht; between 2004 and 2015 at University Medical Center Groningen, Groningen, and at Radboud University Medical Center, Nijmegen; and between 2007 and 2014 in the remaining centers). In the first trimester, fetal megacystis was defined as a fetal bladder with LBD of $\geq$ 7 mm, and in the second and third trimesters as an enlarged bladder failing to empty during an extended ultrasound examination lasting at least 40 min[2,11].

In The Netherlands, all cases suspected of fetal megacystis are referred to the FMU of one of the eight academic hospitals for confirmation of the diagnosis and further investigation. Cases were referred after either a dating scan, first-trimester scan, 20-week anomaly scan or after a scan performed for other indications later in pregnancy. All cases had undergone a detailed anomaly scan, except for those pregnancies that did not reach the 18th week of gestation ($n = 142$, including 115 terminated pregnancies and 27 miscarriages). Parents were counseled about the prognosis of the condition and informed about the possibility of *in-utero* treatment. Vesicoamniotic shunt placement was only offered to chromosomally normal male fetuses with isolated signs of LUTO and with concomitant oligohydramnios.

For each case, prenatal data regarding gestational age (GA) at diagnosis, LBD and associated ultrasound findings were retrieved. The LBD was obtained from a midsagittal view of the fetus, by measuring the distance from the fetal bladder dome to the bladder neck. Ultrasound findings typically associated with LUTO, such as hydronephrosis, abnormal renal cortical appearance, keyhole sign and oligohydramnios (with eventual compression deformities), were not regarded as associated ultrasound anomalies. Nuchal translucency (NT) was considered increased if it was greater than the 95th percentile according to GA[12]. For cases referred in the first trimester of pregnancy, we considered NT measured at referral, while in fetuses referred later in pregnancy, we collected the NT measurement retrospectively.

All available postmortem examinations and postnatal investigations were reviewed in order to establish a final diagnosis. LUTO was defined as a bladder outlet obstruction caused by urethral valves, urethral stenosis or urethral atresia. The term anorectal malformation (ARM) was used to describe a group of complex congenital anomalies characterized by an abnormal development of the urorectal septum, resulting in congenital abnormalities of the distal anus, rectum and genitourinary tract[13]. In this group, cloacal dysgenesis or cloacal malformation was characterized by the absence of anal, genital and urinary orifices[14]. VACTERL association was diagnosed if three of the following criteria were met: vertebral defects, anal atresia/imperforate anus, cardiovascular anomalies, tracheoesophageal fistula or esophageal atresia, renal anomalies and limb defects (including radial anomalies) in at least two of the three

© 2018 The Authors. *Ultrasound in Obstetrics & Gynecology* published by John Wiley & Sons Ltd on behalf of the International Society of Ultrasound in Obstetrics and Gynecology.

regions involved (thorax, pelvis/lower abdomen and limb)[15]. Caudal regression spectrum was defined as the presence of abnormalities at the level of the caudal spinal segments, ranging from minor sacrococcygeal malformations to complete absence of sacrum and lumbar spine[16]. Omphalocele-exstrophy-imperforate anus-spinal defect (OEIS) complex was diagnosed in cases of omphalocele associated with bladder exstrophy, imperforate anus and spinal defect[17]. Infants without LUTO or other severe congenital abnormality or congenital syndrome were included in the group with normal urinary tract or isolated urological anomaly, such as vesicoureteral reflux or duplex collecting system. Neonatal death was defined as death of a liveborn during the first 28 completed days postpartum. In case of isolated LUTO, the postnatal renal function was evaluated based on the estimated glomerular filtration rate (eGFR); this was calculated using the Schwartz formula, taking into account the infant's length and the creatinine nadir in the first year of age[18].

RESULTS

During the study period, 541 pregnancies (25 twin and 516 singleton pregnancies) were referred to one of the eight FMUs in The Netherlands owing to the finding of fetal megacystis. Of the 541 pregnancies, 233 (43%) were referred before the 18th week of gestation (early megacystis) and 308 (57%) at or after the 18th week of gestation (late megacystis) (Figure 1). This study deals with structural anomalies, genetic syndromes and developmental or chromosomal abnormalities associated with fetal megacystis. Other outcome measures relative to this cohort have been reported on in different studies[4–6].

Fetal megacystis was isolated (or solely associated with other signs of LUTO) in 360 (67%) pregnancies and associated with other abnormal ultrasound findings in 181 (33%). More than a single associated anomaly was found in 70 cases, while a total of 292 associated ultrasound findings were observed (Table 1). The most common associated ultrasound anomaly was increased NT (22%), followed by single umbilical artery (10%) and cardiac defect (10%).

Overall 188 (35%) pregnancies were terminated, 50 (9%) resulted in intrauterine demise, 68 (13%) in neonatal death and 235 (43%) children were alive beyond 28 days after birth. Of the terminated pregnancies, the parents did not consent to postmortem examination in 117 (62%) cases. Moreover, six cases were lost to follow-up (Figure 1). Therefore, a final causal diagnosis was possible in 418 (77%) cases. These included 222 (53%) cases with isolated LUTO, 60 (14%) infants with a minor isolated urological anomaly or normal micturition at birth, and 136 (33%) 'syndromic' cases with miscellaneous chromosomal abnormality, genetic syndrome or developmental anomaly (Table 2). The latter group consisted of four categories: (1) fetuses with major chromosomal abnormality ($n = 40$); (2) fetuses with ARM ($n = 32$); (3) fetuses with macrosomia or overgrowth genetic syndrome ($n = 10$); and (4) cases with multiple congenital abnormalities or other miscellaneous genetic syndrome ($n = 54$). Table 3 summarizes GA at referral, LBD, fetal gender, pregnancy outcome and findings at postnatal or postmortem investigation in the syndromic cases. The outcome and postnatal renal

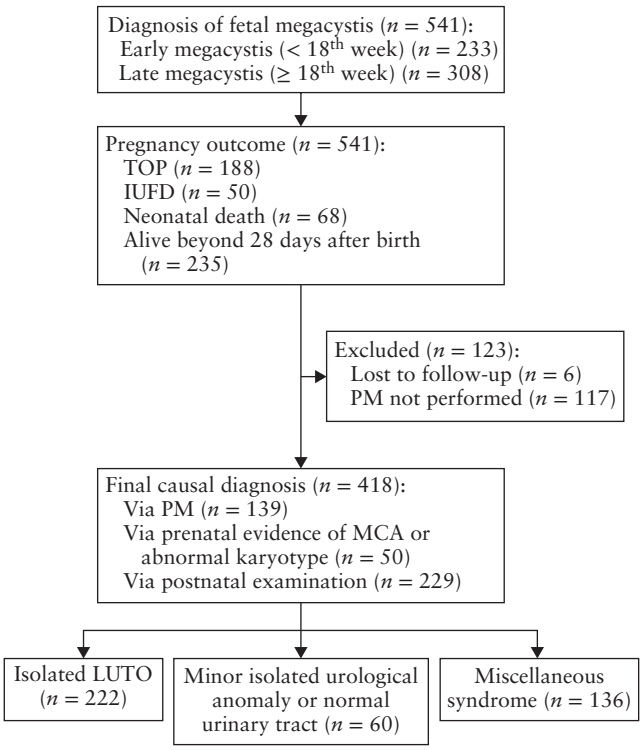

Figure 1 Flowchart showing clinical diagnosis and outcome of 541 fetuses with fetal megacystis. IUFD, intrauterine fetal demise; LUTO, lower urinary tract obstruction; MCA, multiple congenital anomalies; PM, postmortem; TOP, termination of pregnancy.

Table 1 Details of additional 292 abnormal ultrasound findings observed in 181 fetuses diagnosed with megacystis

Ultrasound finding	n *(%)*
Nuchal translucency ≥ 95th centile	64 (22)
Single umbilical artery	30 (10)
Cardiac defect	30 (10)
Ventricular septal defect	3 (1)
Umbilical cord cyst	27 (9)
Spinal or skeletal anomaly	19 (6)
Sacrococcygeal teratoma	1 (0.3)
Abdominal wall defect	18 (6)
Urogenital anomaly	15 (5)
Intrauterine growth restriction	7 (2)
Macrosomia	6 (2)
Macroglossia	1 (0.3)
Central nervous system anomaly	5 (2)
Cleft lip/palate	3 (1)
Fetal hydrops	8 (3)
Diaphragmatic hernia	3 (1)
Choroid plexus cyst	15 (5)
Echogenic bowel	11 (4)
Short long bones	6 (2)
Ventriculomegaly	2 (0.7)
Echogenic intracardiac focus	2 (0.7)
Miscellaneous syndromal marker*	16 (5)

More than one finding was present in some fetuses. *Including hypertelorism, strawberry skull, micrognathia and clubfoot.

© 2018 The Authors. *Ultrasound in Obstetrics & Gynecology* published by John Wiley & Sons Ltd on behalf of the International Society of Ultrasound in Obstetrics and Gynecology.

Table 2 Final diagnosis and gestational age (GA) at initial diagnosis, in 418 pregnancies with fetal megacystis

Final diagnosis	n *(%)*	*GA (weeks)*
LUTO	222 (53)	22.6 ± 7
Normal micturition at birth or minor isolated urological anomaly	60 (14)	21.7 ± 10
Miscellaneous congenital syndrome	136 (33)	18.8 ± 7
Major chromosomal abnormality	40 (10)	15.3 ± 4
Anorectal malformation	32 (8)	15.9 ± 5
Fetal macrosomia or overgrowth syndrome	10 (2)	22.7 ± 8
MCA or other syndrome	54 (13)	20.0 ± 7

GA is given as mean ± SD. LUTO, lower urinary tract obstruction; MCA, multiple congenital anomalies.

function of cases with isolated LUTO are reported in Table 4.

In total, 40 chromosomal abnormalities were diagnosed (Tables 2 and 3), with a predominance of trisomy 18 (24 cases, including 22 with trisomy 18 and two with trisomy 18 mosaicisms), followed by trisomy 21 (five cases), Turner syndrome (five cases: one with Turner syndrome and four with Turner mosaicism), trisomy 13 (three cases) and deletion 22q11 (three cases). In the chromosomally abnormal fetuses, megacystis was diagnosed at a mean GA of 17 weeks and was associated with increased NT or other severe structural anomalies. Amniotic fluid volume was normal in 70% of cases. In addition, five fetuses presented with miscellaneous chromosomal abnormalities of uncertain

Table 3 Antenatal characteristics, outcome and postnatal/postmortem findings in pregnancies with fetal megacystis and associated chromosomal or developmental abnormalities or genetic syndrome

Finding	*GA at referral (weeks)*	*Mean LBD (mm)*	*Cases with LUTO signs*	*Oligo-/an-hydramnios*	*Male sex*	*Outcome*	*Associated anomalies at antenatal US*	*Findings at postmortem/ postnatal examination*
Chromosomal abnormality								
Trisomy 18 or mosaicism (*n* = 24)	17 (12–29)	25	21 (88)	7 (29)	21 (88)	15 TOP; 9 PD	Increased NT, CHD, UCC, omphalocele, skeletal/spinal defect	CHD, agenesis of cerebellar vermis, omphalocele, clubfoot
Trisomy 21 (*n* = 5)	16 (13–22)	26	3 (60)	3 (60)	5 (100)	4 TOP; 1 PD	Increased NT, skeletal anomaly	NA
Turner syndrome or mosaicism (*n* = 5)	15 (11–21)	15	2 (40)	1 (20)	2 (40)	3 TOP; 1 PD; 1 AL	UCC, increased NT	Imperforate anus, facial dysmorphism, CHD
Trisomy 13 (*n* = 3)	12 (12–13)	9	3 (100)	0 (0)	3 (100)	3 TOP	CHD, labiopalatoschisis, SUA, polydactyly	NA
Deletion 22q11 syndrome (*n* = 3)	25 (12–37)	31	3 (100)	1 (33)	3 (100)	1 TOP; 2 AL	CHD	Unilateral renal agenesis, CHD, VUR
Total (*n* = 40)	17 (11–37)	23	32 (80)	12 (30)	34 (85)	26 TOP; 11 PD; 3 AL	Common features: increased NT	Common features: CHD
Additional chromosomal abnormality with doubtful clinical significance								
46,XY, 1.9 Mb duplication, 19q13.33 *de novo* (*n* = 1)	NA	NA	0 (0)	0 (0)	1 (100)	AL	UCC	Delayed motor development, muscular hypotonia, gastroesophageal reflux; ectopic testis, epiphyseal dysplasia, short stature
46,XY, 22q11.2 microduplication + 14q31 duplication (*n* = 1)	37	NA	1 (100)*	1 (100)	1 (100)	AL	None	PUV, severe VUR (grades III–IV)
46,XX, deletion 5q.35.2 (*n* = 1)	19	NA	1 (100)†	1 (100)	0 (0)	AL	None	Tethered cord, neurogenic bladder, VUR, multidysplastic kidneys, psychomotor disability
46,X, der (X) t (X; Y) (p22.33; p11.31) (*n* = 1)	21	13	1 (100)*	1 (100)	1 (100)	AL	None	VUR, bilateral renal dysplasia, renal insufficiency, 46XX male
46,XY, t (14;16) (q24.3; q24.1)pat (*n* = 1)	22	NA	1 (100)‡	1 (100)	NA	TOP	Unilateral renal agenesis (left) and renal dysplasia (right)	Unilateral renal agenesis (left) and renal dysplasia (right)
Anorectal malformation								
VACTERL (*n* = 13)	17 (11–31)	24	10 (77)	10 (77)	11 (85)	10 TOP; 3 PD	CHD, unilateral renal agenesis, increased NT, SUA, UCC, FEB	Anal atresia, cloacal anomaly, unilateral renal agenesis, CHD, colon-vesical fistula, limb anomaly, esophageal atresia, tethered cord, spina bifida, vertebral defect
Cloacal malformation (*n* = 6)	17 (13–22)	48	4 (67)	3 (50)	1 (17)	5 TOP; 1 PD	VSD, cystic hygroma, UCC	Cloacal anomaly

Continued over.

© 2018 The Authors. *Ultrasound in Obstetrics & Gynecology* published by John Wiley & Sons Ltd on behalf of the International Society of Ultrasound in Obstetrics and Gynecology.

Table 3 *Continued*

Finding	*GA at referral (weeks)*	*Mean LBD (mm)*	*Cases with LUTO signs*	*Oligo-/an-hydramnios*	*Male sex*	*Outcome*	*Associated anomalies at antenatal US*	*Findings at postmortem/ postnatal examination*
OEIS ($n = 7$)	12 (11–14)	19	2 (29)	2 (29)	5 (71)	6 TOP; 1 PD	Omphalocele, SUA, increased NT	Cloacal anomaly, cloacal exstrophy, limb anomaly, spina bifida, renal agenesis
CRS ($n = 4$)	14 (12–17)	25	1 (25)	4 (100)	2 (50)	3 TOP; 1 PD	Unilateral renal agenesis, sirenomelia, spina bifida, SUA	Sacral agenesis, hypoplasia of lower extremities
Fraser syndrome ($n = 2$)	21 (21–22)	68	2 (100)	2 (100)	1 (50)	2 TOP	Overgrowth, hypertelorism, clubfoot, increased NT, renal agenesis	Renal agenesis, syndactyly, imperforate anus, facial dysmorphism
Total ($n = 32$)	16 (11–22)	29	23 (72)	21 (66)	20 (63)	26 TOP; 6 PD	Common features: SUA, increased NT, UCC, renal agenesis	Common features: imperforate anus/anal agenesis, cloacal anomaly, spinal defect, limb anomaly
Overgrowth syndrome or fetal macrosomia								
BWS ($n = 2$)	22 (21–22)	35	2 (100)	1 (50)	2 (100)	1 TOP; 1 AL	Fetal overgrowth, macroglossia, hepatomegaly, skeletal dysplasia	PUV, skeletal dysplasia
Sotos syndrome ($n = 2$)	24 (17–30)	NA	0 (0)	1 (50)§	2 (100)	1 TOP; 1 AL	Polyhydramnios	NA
Unknown cause ($n = 5$)	17 (12–35)	20	2 (40)	1 (20)¶	5 (100)	2 TOP; 3 AL	EFW > 90th centile	VUR, congenital megaureter
Cantu syndrome ($n = 1$)	21	15	1 (100)	0 (0)§	1 (100)	1 AL	Polyhydramnios, EFW > 90th centile	VUR, facial dysmorphism, PAS
Total ($n = 10$)	22 (12–35)	27	5 (50)	6 (60)	10 (100)	4 TOP; 6 AL	Common features: fetal overgrowth, polyhydramnios	Common features: VUR, PUV
Other miscellaneous syndrome								
MMIHS ($n = 5$)	16 (12–21)	42	5 (100)	1 (20)	3 (60)	5 PD	Increased NT, clubfoot	NA
Smith–Lemli–Opitz syndrome ($n = 2$)	22 (16–28)	NA	2 (100)	2 (100)	2 (100)	1 TOP; 1 AL	Shortened long bones, increased NT	Urethral atresia, hypospadia, ureteropelvic stenosis, polydactyly, CHD, cleft palate, micrognathia
Morris syndrome ($n = 1$)	35	57	0 (0)	0 (0)	1 (100)	AL	None	
Ochoa syndrome ($n = 1$)	33	54	0 (0)	0 (0)	1 (100)	AL	None	
Spinal muscular atrophy ($n = 1$)	16	35	1 (100)**	0 (0)	1 (100)	AL	Increased NT, UCC, absent DV, hydrops	Arthrogryposis, neurogenic bladder
Marcus Gunn jaw winking syndrome ($n = 1$)	21	NA	0 (0)	0 (0)	1 (100)	AL	None	PUV, VUR, duplex collecting system

Data are given as mean (range) or *n* (%). *Keyhole sign, hydronephrosis, oligohydramnios. †Abnormal renal cortical appearance, oligohydramnios. ‡Keyhole sign, abnormal renal cortical appearance, hydronephrosis, oligohydramnios. §Plus one case of polyhydramnios. ¶Plus two cases of polyhydramnios. **Keyhole sign, abnormal renal cortical appearance. AL, alive beyond 28 days after birth; BWS, Beckwith–Wiedemann syndrome; CHD, congenital heart defect; CRS, caudal regression syndrome; DV, ductus venosus; EFW, estimated fetal weight; FEB, fetal echogenic bowel; GA, gestational age; LBD, longitudinal bladder diameter; LUTO, lower urinary tract obstruction; MMIHS, megacystis-microcolon-intestinal hypoperistalsis; NA, not available; NT, nuchal translucency; OEIS, omphalocele-exstrophy-imperforate anus-spinal defect; PAS, pulmonary artery stenosis; PD, perinatal death including intrauterine fetal demise and neonatal death; PUV, posterior urethral valves; SUA, single umbilical artery; TOP, termination of pregnancy; UCC, umbilical cord cyst; US, ultrasound; VSD, ventricular septal defect; VUR, vesicoureteral reflux.

clinical significance, but probably unrelated to the observed phenotypes (Table 3).

Thirty-two cases presented with a wide spectrum of developmental abnormalities involving the anus, rectum and urogenital tract, and were classified as having ARM. This group included 13 fetuses with VACTERL associations, six with cloacal malformations, seven with OEIS complex, two with Fraser syndrome and four with caudal regression spectrum. In fetuses with ARM, megacystis was detected early in pregnancy (mean GA at referral, 16 weeks). In all cases with urethral and anal atresia, the fetal bladder was severely distended, with LBD (in mm) equal to or greater than twice the GA (in weeks). In cases of moderate bladder distension, with LBD lower than GA × 2 (mm), a spinal or vertebral anomaly was found either at the antenatal scan or at the postmortem examination. In this group, the amniotic fluid volume was reduced in 66% of cases.

© 2018 The Authors. *Ultrasound in Obstetrics & Gynecology* published by John Wiley & Sons Ltd on behalf of the International Society of Ultrasound in Obstetrics and Gynecology.

Fetal macrosomia was detected in six cases and an overgrowth syndrome in four cases, which comprised two infants with Beckwith–Wiedemann syndrome (BWS) and two with Sotos syndrome. Five fetuses were diagnosed with megacystis-microcolon-intestinal hypoperistalsis syndrome (MMIHS), four of which had normal amniotic fluid volume during pregnancy. Moreover, a similar phenotype with intestinal hypoperistalsis and detrusor hypotonia was observed in one infant with Ochoa syndrome. Other miscellaneous genetic and structural anomalies observed in our cohort are reported in Table 3.

Based on the antenatal findings and final diagnosis in our cohort, a flowchart was designed to guide the differential diagnosis of fetal megacystis and rule out major genetic syndromes and developmental abnormalities (Figure 2).

In our study population, 360 fetuses had isolated megacystis (megacystis without other associated ultrasound abnormality or solely with associated signs of LUTO). This subgroup of fetuses had a better outcome, as shown in Figure 3. Their GA at onset of oligo- or anhydramnios was related to the fetal outcome; this was 17 weeks in the pregnancies that were terminated ($n = 116$), 20 weeks in pregnancies that ended in intrauterine fetal demise ($n = 19$), 24 weeks in those that resulted in a neonatal death ($n = 28$) and 30 weeks in children that survived ($n = 197$). Among the 197 surviving children, LUTO was confirmed in 129 cases, while in 60, normal micturition or an isolated urological anomaly (including vesicoureteral reflux or duplex collecting system) was diagnosed. Impaired renal function (eGFR < 60 mL/min/1.73m^2) within the first year of age was observed in 36 children with confirmed LUTO and in only one child without LUTO, but with severe vesicoureteral reflux.

Table 4 Pregnancy outcome and postnatal renal function in 222 fetuses diagnosed with isolated lower urinary tract obstruction (LUTO)

Outcome	*Value*
Termination of pregnancy	54 (24)
Perinatal death*	39 (18)
Alive beyond 28 days after birth	129 (58)
Cause of obstruction ($n = 181$)	
Posterior urethral valves	83 (46)
Urethral atresia	5 (3)
Urethral stenosis and other	93 (51)
Postnatal renal function ($n = 80$)	
eGFR (mL/min/1.73 m^2)	63 (3–162)
Severely impaired renal function (eGFR < 30 mL/min/1.73 m^2)	16 (20)

Data are expressed as n (%) or median (range). *Perinatal death includes intrauterine demise and neonatal death. eGFR, estimated glomerular filtration rate.

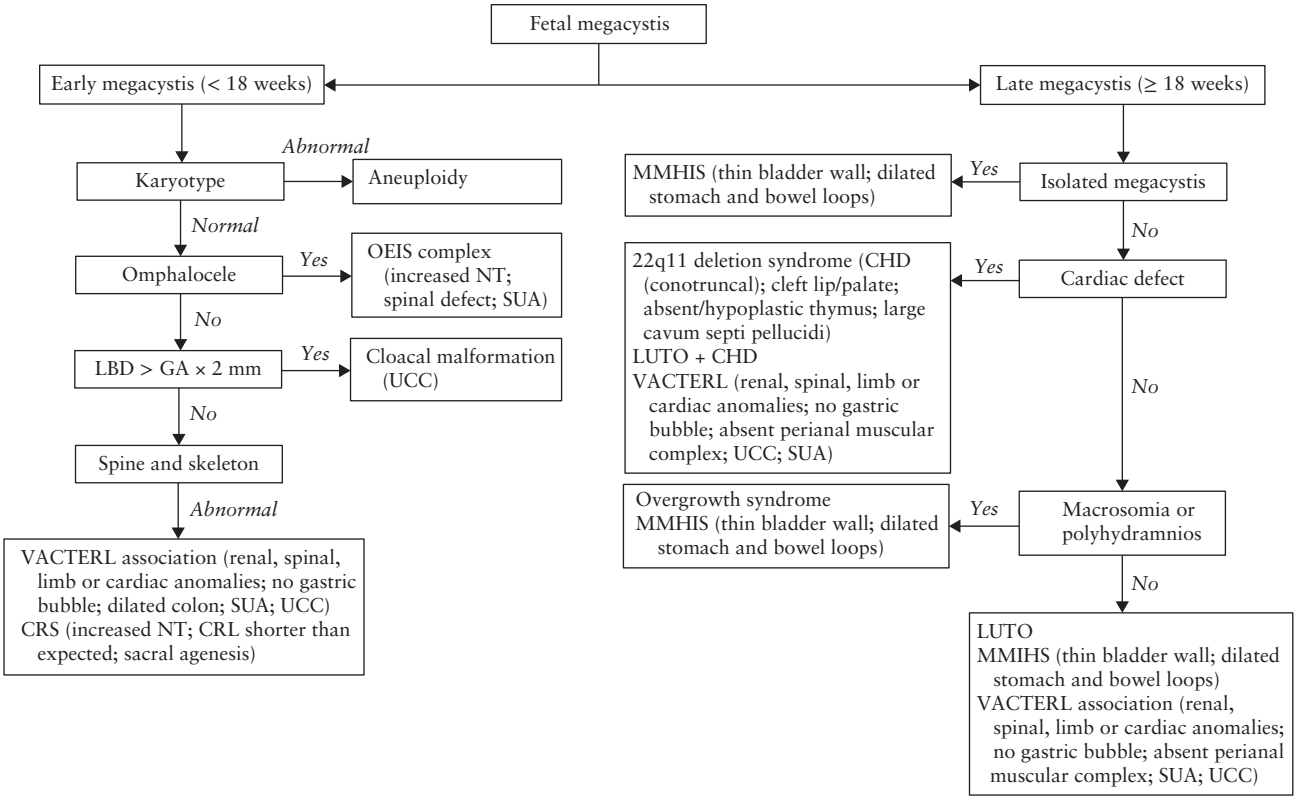

Figure 2 Practical guide for differential diagnosis of fetal megacystis. CHD, congenital heart defect; CRL, crown–rump length; CRS, caudal regression syndrome; GA, gestational age; LBD, longitudinal bladder diameter; LUTO, lower urinary tract obstruction; MMIHS, megacystis-microcolon-intestinal hypoperistalsis; NT, nuchal translucency; OEIS, omphalocele-exstrophy-imperforate anus-spinal defect; SUA, single umbilical artery; UCC, umbilical cord cyst.

© 2018 The Authors. *Ultrasound in Obstetrics & Gynecology* published by John Wiley & Sons Ltd on behalf of the International Society of Ultrasound in Obstetrics and Gynecology.

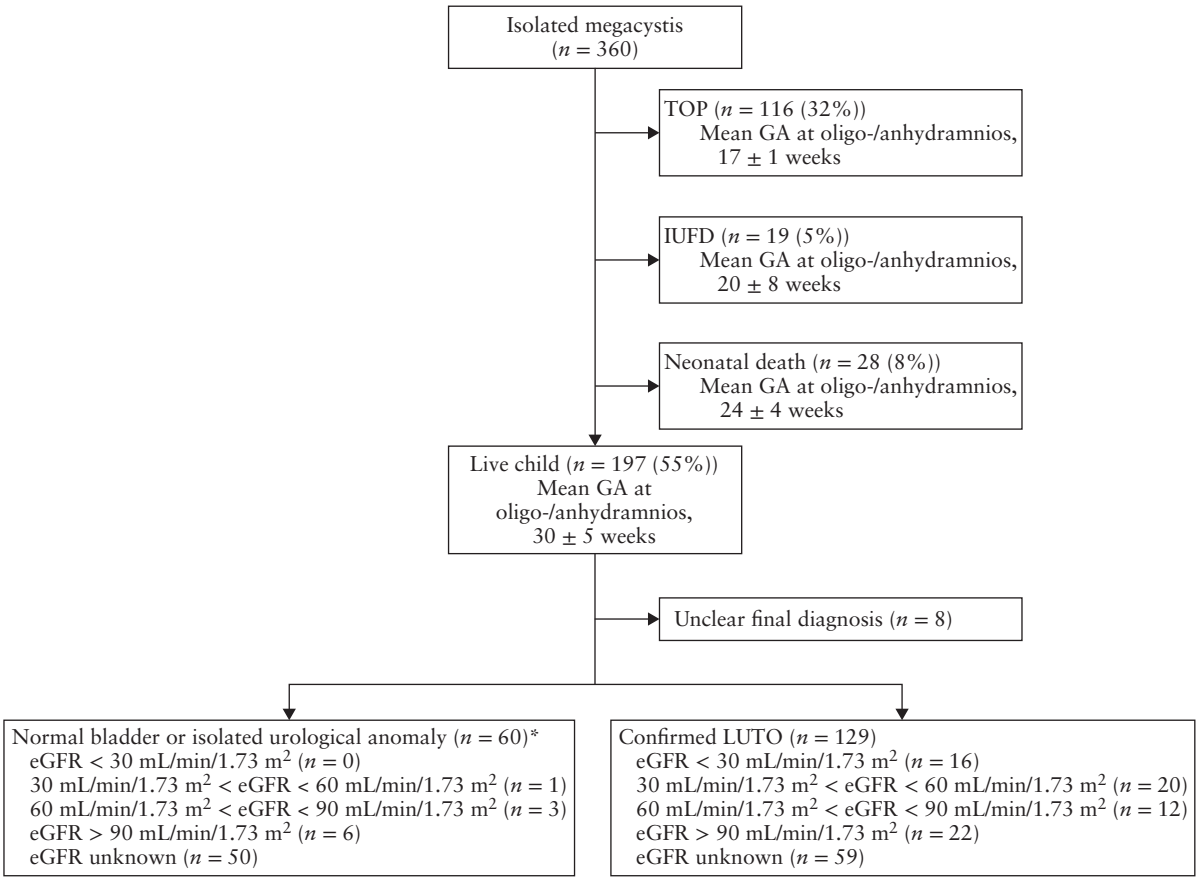

Figure 3 Flowchart showing outcome of 360 fetuses with isolated megacystis. *Includes fetuses without postnatal evidence of lower urinary tract obstruction (LUTO), but normal micturition, vesicoureteral reflux or duplex collecting system. eGFR, estimated glomerular filtration rate; GA, gestational age; IUFD, intrauterine fetal demise; TOP, termination of pregnancy.

DISCUSSION

This study shows that, although the main cause of fetal megacystis is LUTO, an enlarged fetal bladder can also be present as a concomitant finding in miscellaneous genetic syndromes, developmental anomalies and chromosomal abnormalities. The main problem in the work-up of fetal megacystis remains its definition and the lack of a standardized antenatal management approach[3]. In this study, we provide an overview of the underlying etiologies and propose a practical guide for the differential diagnosis of fetuses with isolated megacystis or associated bladder enlargement.

Fetal megacystis was an associated finding in one-third of our cases. After exclusion of chromosomal anomalies, the most frequently observed complex anomaly was an ARM, diagnosed in 8% of cases. In this group, fetuses with a cloacal malformation typically presented with severe and early megacystis, with a LBD larger than twice the GA. This anomaly is typically suspected in female fetuses with distended bladder and, behind it, a single or septate anechoic area corresponding to the vagina[19–22]. In spite of a predominance in female fetuses, we confirm, similarly to other studies[14,19], that a cloacal malformation can also occur in male fetuses.

In 81% (26/32) of cases, ARM was part of multisystemic anomalies, such as VACTERL association, caudal regression spectrum, OEIS complex and Fraser syndrome. Similarly to Bornes *et al.*[11], we diagnosed VACTERL association and OIES complex in 20/418 (5%) of fetuses with fetal megacystis. VACTERL association is rarely diagnosed prenatally as the key features, such as anorectal and esophageal atresia (with absence of gastric bubble) are not easily detected prenatally[20,21]. In fact, absent or small stomach bubble is present in less than 10% of fetuses with esophageal atresia, owing to the presence of a tracheoesophageal fistula in the majority of cases[22]. Similarly, absence of the perianal muscular complex in anorectal atresia is more commonly observed from 23 weeks' gestation onwards and is not seen on the routine 20-week scan[23,24]. In light of this study, we advocate that this condition be considered in the differential diagnosis of fetal megacystis, particularly if this occurs early in pregnancy with associated spinal, renal, limb or cardiac defects, single umbilical artery and umbilical cord cysts.

A second striking result of this study was the association of fetal megacystis with fetal macrosomia and with overgrowth syndromes, such as BWS and Sotos syndrome. In this group, megacystis may occur owing to a variety of causes such as obstructive polyps or posterior urethral valves in BWS[25–27] and urethral stenosis in Sotos syndrome[28], or simply owing to polyuria. Typical

© 2018 The Authors. *Ultrasound in Obstetrics & Gynecology* published by John Wiley & Sons Ltd on behalf of the International Society of Ultrasound in Obstetrics and Gynecology.

antenatal ultrasound features of overgrowth syndromes have been described in detail before[29], and Vora and Bianchi proposed an algorithm to assist in the differential diagnosis of these syndromes[30]. However, it should be borne in mind that overgrowth/macrosomia is rarely detected at the 20-week scan and in the majority of cases the diagnosis occurs only after birth[30].

MMIHS was observed in 1% of cases in our cohort. This is a rare syndrome with poor prognosis characterized by a distended non-obstructed bladder and intestinal hypoperistalsis[31]. MMIHS is considered the most severe form of a spectrum of chronic intestinal pseudo-obstructive disorders, such as the more common Hirschsprung's disease[31]. The genetic basis of MMIHS has been ascribed to a number of different autosomal dominant and recessive mutations (*ACTG2*, *MYH11* and *LMOD1* genes)[32–34]. In our study, this syndrome was suspected in only one affected fetus, while in the remaining cases LUTO was suspected. Prenatal diagnosis of MMIHS is indeed challenging and successful in less than one-third of cases[35]. However, discriminating MMIHS from LUTO remains crucial because MMIHS, although usually lethal, is rarely associated with significant renal impairment and thus any form of prenatal bladder drainage would be inappropriate[35].

The majority of MMIHS cases in our cohort presented with typical LUTO signs, such as megacystis and bilateral hydronephrosis. This further highlights the importance of considering MMIHS in the differential diagnosis of megacystis with LUTO. To date, this syndrome is typically suspected in female fetuses with coexisting megacystis and normal to increased amniotic fluid volume. However, in our cohort, fetal gender was not so relevant in predicting MMIHS, as three out of five cases were male fetuses. This is in keeping with a systematic review showing that 32% of MMHIS cases occur in boys and polyhydramnios is reported in only 27% of cases[35]. For this purpose, we suggest a new clinical score to discriminate LUTO from cases with non-obstructive megacystis (such as MMIHS), and Tuzovic *et al.*[35] suggested a set of typical ultrasound signs of MMIHS, such as dilated fetal stomach, large atonic bladder with a thin wall and dilated bowel loops in the third trimester. As the gastrointestinal anomalies of MMIHS are scarcely amenable to ultrasound diagnosis, fetal magnetic resonance imaging can be of help in detecting microcolon and dilated esophagus[36]. Although the genetic basis of MMHIS is heterogeneous and most cases are sporadic, we would recommend that, in the presence of the abovementioned criteria, genetic testing for MMHIS should be carried out, especially before prenatal bladder drainage is considered.

In the subgroup of fetuses with isolated megacystis, our outcome data support the findings of Bornes *et al.*, with about half (55%) surviving and about one in six (15%) being diagnosed with vesicoureteral reflux after birth[11]. However, the most important message of this study is that fetal megacystis can be the common denominator of many conditions other than LUTO, including complex conditions with a poor prognosis such as chromosomal abnormalities or ARM, while it can also be merely a sign of isolated urological anomalies with an overall good prognosis.

A limitation of this study is its retrospective nature. In fact, we describe a set of fetal abnormalities and syndromes diagnosed based on local protocols without following a systematic protocol for invasive testing or genetic analysis. This implies that other syndromic cases may have been overlooked, resulting in an underestimation of the real prevalence of syndromal associations.

In conclusion, this study provides an overview of a range of disorders associated with fetal megacystis and proposes a practical guide for the prenatal differential diagnosis of genetic syndromes and chromosomal and developmental abnormalities in pregnancies presenting with fetal megacystis, focusing on the morphological examination of the fetus. This may be of help in the antenatal work-up and counseling of fetal megacystis.

REFERENCES

1. McHugo J, Whittle M. Enlarged fetal bladders: aetiology, management and outcome. *Prenat Diagn* 2001; **21**: 958–963.
2. Sebire NJ, Von Kaisenberg C, Rubio C, Snijders RJM, Nicolaides KH. Fetal megacystis at 10–14 weeks of gestation. *Ultrasound Obstet Gynecol* 1996; **8**: 387–390.
3. Taghavi K, Sharpe C, Stringer MD. Fetal megacystis: A systematic review. *J Pediatr Urol* 2017; **13**: 7–15.
4. Fontanella F, Duin L, Adama van Scheltema PN, Cohen-Overbeek TE, Pajkrt E, Bekker M, Willekes C, Bax CJ, Oepkes D, Bilardo CM. Antenatal Workup of Early Megacystis and Selection of Candidates for Fetal Therapy. *Fetal Diagn Ther* 2019; **45**: 155–161.
5. Fontanella F, Duin LK, Adama van Scheltema PN, Cohen-Overbeek TE, Pajkrt E, Bekker M, Willekes C, Bax CJ, Gracchi V, Oepkes D, Bilardo CM. Prenatal diagnosis of LUTO: improving diagnostic accuracy. *Ultrasound Obstet Gynecol* 2018; **52**: 739–743.
6. Fontanella F, Duin L, Adama van Scheltema PN, Cohen-Overbeek TE, Pajkrt E, Bekker M, Willekes C, Bax CJ, Bilardo CM. Fetal megacystis: prediction of spontaneous resolution and outcome. *Ultrasound Obstet Gynecol* 2017; **50**: 458–463.
7. Liao AW, Sebire NJ, Geerts L, Cicero S, Nicolaides KH. Megacystis at 10–14 weeks of gestation: chromosomal defects and outcome according to bladder length. *Ultrasound Obstet Gynecol* 2003; **21**: 338–341.
8. Montemarano H, Bulas DI, Rushton HG, Selby D. Bladder distention and pyelectasis in the male fetus: causes, comparisons, and contrasts. *J Ultrasound Med* 1998; **17**: 743–749.
9. Malin G, Tonks AM, Morris RK, Gardosi J, Kilby MD. Congenital lower urinary tract obstruction: a population-based epidemiological study. *BJOG* 2012; **119**: 1455–1464.
10. Al-Hazmi H, Dreux S, Delezoide AL, Dommergues M, Lortat-Jacob S, Oury JF, El-Ghoneimi A, Muller F. Outcome of prenatally detected bilateral higher urinary tract obstruction or megacystis: sex-related study on a series of 709 cases. *Prenat Diagn* 2012; **32**: 649–654.
11. Bornes M, Spaggiari E, Schmitz T, Dreux S, Czerkiewicz I, Delezoide AL, El-Ghoneimi A, Oury JF, Muller F. Outcome and etiologies of fetal megacystis according to the gestational age at diagnosis. *Prenat Diagn* 2013; **33**: 1162–1166.
12. Sharifzadeh M, Adibi A, Kazemi K, Hovsepian S. Normal reference range of fetal nuchal translucency thickness in pregnant women in the first trimester, one center study. *J Res Med Sci* 2015; **20**: 969–973.
13. Alamo L, Meyrat BJ, Meuwly JY, Meuli RA, Gudinchet F. Anorectal Malformations: Finding the Pathway out of the Labyrinth. *Radiographics* 2013; **33**: 491–512.
14. Qureshi F, Jacques SM, Yaron Y, Kramer RL, Evans MI, Johnson MP. Prenatal diagnosis of cloacal dysgenesis sequence: differential diagnosis from other forms of fetal obstructive uropathy. *Fetal Diagn Ther* 1998; **13**: 69–74.
15. Carli D, Garagnani L, Lando M, Fairplay T, Bernasconi S, Landi A, Presecepe A. VACTERL (vertebral defects, anal atresia, tracheoesophageal fistula with esophageal atresia, cardiac defects, renal and limb anomalies) association: disease spectrum in 25 patients ascertained for their upper limb involvement. *J Pediatr* 2014; **164**: 458–462.e1–2.
16. Boulas MM. Recognition of caudal regression syndrome. *Adv Neonatal Care* 2009; **9**: 61–69; quiz 70–71.
17. Carey JC, Greenbaum B, Hall BD. The OEIS complex (omphalocele, exstrophy, imperforate anus, spinal defects). *Birth Defects Orig Artic Ser* 1978; **14**: 253–263.
18. Schwartz GJ, Muñoz A, Schneider MF, Mak RH, Kaskel F, Warady BA, Furth SL. New equations to estimate GFR in children with CKD. *J Am Soc Nephrol* 2009; **20**: 629–637.

© 2018 The Authors. *Ultrasound in Obstetrics & Gynecology* published by John Wiley & Sons Ltd on behalf of the International Society of Ultrasound in Obstetrics and Gynecology.

19. Banu T, Chowdhury TK, Hoque M, Rahman MA. Cloacal malformation variants in male. *Pediatr Surg Int* 2013; **29**: 677–682.
20. Solomon BD. VACTERL/VATER Association. *Orphanet J Rare Dis* 2011; **6**: 56.
21. Solomon BD, Raam MS, Pineda-Alvarez DE. Analysis of genitourinary anomalies in patients with VACTERL (Vertebral anomalies, Anal atresia, Cardiac malformations, Tracheo-Esophageal fistula, Renal anomalies, Limb abnormalities) association. *Congenit Anom (Kyoto)* 2011; **51**: 87–91.
22. De Jong EM, De Haan MAM, Gischler SJ, Hop W, Cohen-Overbeek TE, Bax NM, de Klein A, Tibboel D, Grijseels EW. Pre- and postnatal diagnosis and outcome of fetuses and neonates with esophageal atresia and tracheoesophageal fistula. *Prenat Diagn* 2010; **30**: 274–279.
23. Ochoa JH, Chiesa M, Vildoza RP, Wong AE, Sepulveda W. Evaluation of the perianal muscular complex in the prenatal diagnosis of anorectal atresia in a high-risk population. *Ultrasound Obstet Gynecol* 2012; **39**: 521–527.
24. Moon MH, Cho JY, Kim JH, Min JY, Yang JH, Kim MY. In-utero development of the fetal anal sphincter. *Ultrasound Obstet Gynecol* 2010; **35**: 556–559.
25. Buyukcelik M, Satar N, Dursun H, Bayazit Y, Bayazit AK, Soran M, Noyan A, Anarat A. A child with Beckwith–Wiedemann syndrome and posterior urethral valves. *Genet Couns* 2005; **16**: 41–44.
26. Anzai Y, Koshida S, Yanagi T, Johnin K, Takeuchi Y. Neonatal urethral polyps associated with Beckwith–Wiedemann syndrome. *Pediatr Int* 2013; **55**: 658–661.
27. Bockrath JM, Maizels M, Firlit CF. Benign bladder neck polyp causing tandem obstruction of the urinary tract in a patient with Beckwith–Wiedemann syndrome. *J Urol* 1982; **128**: 1309–1312.
28. Tatton-Brown K, Rahman N. Sotos syndrome. *Eur J Hum Genet* 2007; **15**: 264–271.
29. Chen CP. Prenatal findings and the genetic diagnosis of fetal overgrowth disorders: Simpson–Golabi–Behmel syndrome, Sotos syndrome, and Beckwith–Wiedemann syndrome. *Taiwan J Obstet Gynecol* 2012; **51**: 186–191.
30. Vora N, Bianchi DW. Genetic considerations in the prenatal diagnosis of overgrowth syndromes. *Prenat Diagn* 2009; **29**: 923–929.
31. Wymer KM, Anderson BB, Wilkens AA, Gundeti MS. Megacystis microcolon intestinal hypoperistalsis syndrome: Case series and updated review of the literature with an emphasis on urologic management. *J Pediatr Surg* 2016; **51**: 1565–1573.
32. Tuzovic L, Tang S, Miller RS, Rohena L, Shahmirzadi L, Gonzalez K, Li X, LeDuc CA, Guo J, Wilson A, Mills A, Glassberg K, Rotterdam H, Sepulveda AR, Zeng W, Chung WK, Anyane-Yeboa K. New Insights into the Genetics of Fetal Megacystis: ACTG2 Mutations, Encoding γ-2 Smooth Muscle Actin in Megacystis Microcolon Intestinal Hypoperistalsis Syndrome (Berdon Syndrome). *Fetal Diagn Ther* 2015; **38**: 296–306.
33. Gauthier J, Ouled Amar Bencheikh B, Hamdan FF, Harrison SM, Baker LA, Couture F, Thiffault I, Ouazzani R, Samuels ME, Mitchell GA, Rouleau GA, Michaud JL, Soucy JF. A homozygous loss-of-function variant in MYH11 in a case with megacystis-microcolon-intestinal hypoperistalsis syndrome. *Eur J Hum Genet* 2015; **23**: 1266–1268.
34. Halim D, Wilson MP, Oliver D, Brosens E, Verheij JB, Han Y, Nanda V, Lyu Q, Doukas M, Stoop H, Brouwer RW, van IJcken WF, Slivano OJ, Burns AJ, Christie CK, de Mesy Bentley KL, Brooks AS, Tibboel D, Xu S, Jin ZG, Djuwantono T, Yan W, Alves MM, Hofstra RM, Miano JM. Loss of LMOD1 impairs smooth muscle cytocontractility and causes megacystis microcolon intestinal hypoperistalsis syndrome in humans and mice. *Proc Natl Acad Sci USA* 2017; **114**: E2739–E2747.
35. Tuzovic L, Anyane-Yeboa K, Mills A, Glassberg K, Miller R. Megacystis-microcolon-intestinal hypoperistalsis syndrome: case report and review of prenatal ultrasonographic findings. *Fetal Diagn Ther* 2014; **36**: 74–80.
36. Munch EM, Cisek LJ Jr, Roth DR. Magnetic resonance imaging for prenatal diagnosis of multisystem disease: megacystis microcolon intestinal hypoperistalsis syndrome. *Urology* 2009; **74**: 592–594.

© 2018 The Authors. *Ultrasound in Obstetrics & Gynecology* published by John Wiley & Sons Ltd on behalf of the International Society of Ultrasound in Obstetrics and Gynecology.