CHAPTER 1

GENERAL INTRODUCTION AND OUTLINE OF THE THESIS

Adapted (in part) from:

Schouten WR, Zimmerman DDE, Meuwissen SGM

Nederlands Tijdschrift voor Geneeskunde, 2001 July; 145 (29): 1398-1402

INTRODUCTION

Definition

'Fistula' is the Latin word for a reed, pipe or flute. In medicine it implies a chronic granulating track connecting two epithelium lined surfaces. These surfaces may be cutaneous or mucosal. Perianal fistulas run from the anal canal to the perianal skin or perineum. Perianal fistulas are associated with considerable discomfort and morbidity to the patient.

History

Hippocrates

The first treatise regarding the treatment of perianal fistulas was probably written by Hippocrates of Cos (460 B.C. – 370 B.C.). In his book entitled *'De Fistulis'* Hippocrates clearly recognizes the relation between anorectal abscesses and fistulas[1,2]. He recommends the cutting open of the abscess before it suppurates and bursts into the rectum. Some of the techniques used in surgery for perianal fistulas today, were already utilized by Hippocrates. For example, he examined the depth of the fistula by probing it. (He used a stalk of fresh garlic). Furthermore, Hippocrates also advocated the use of the cutting seton method. He used a 'horsehair wrapped around a lint thread' which was advanced through the fistula with a tin guide (the 'specillum'). The ends of this seton were then tied around the enclosed sphincter tissue and the patient was told to 'go and attend to his matters'. When the thread got loose, 'owing to the fistula becoming putrid' Hippocrates twisted and tightened the seton 'until the flesh was eaten through'. This technique is probably the origin of the name of this technique since 'seta' is the Latin word for bristle.

John of Arderne

In medieval times many medical practitioners offered a mix of Hippocratic treatment modalities and those based on magic and/ or religion. A notable exception was the famous British surgeon John of Arderne (1307 - 1390) who wrote the well-known treatise *'Treatises of Fistula in Ano, Haemorrhoids and Clysters'*. In this document he describes a gruesome treatment for anal fistulas[3]. The patient was placed in lithotomy position. Four threads were taken through the fistulous tract and their ends were drawn down through the anus. These threads were knotted to stop the bleeding. Next, he pushed a grooved instrument through the fistula into the rectum, where it made contact with another instrument. He then made a bold cut with his knife to remove the entire intervening segment. The bleeding between the ligatures was stopped with a hot sponge. The wound was cared for by cleaning and the patient was given daily enemas.

King Louis XIV and Charles-François Félix de Tassy

During the 17th and 18th century, European surgeons were organized into guilds. Firm, almost impenetrable lines existed between medicine and surgery, and medicine was clearly dominant. Because of this, surgeons did not reach the social and academic level of physicians (Lyons 1987). Physicians in those days took an oath not to demean themselves by performing surgical treatment[4], but the faculty of medicine did claim the exclusive control of the teaching of surgical theory. Because of this, many conflicts occurred between the surgical guilds and the medical faculties. King Louis XIV became a great proponent of the French surgeons after he developed a perianal abscess in 1686. The abscess was 'lanced' but recurred three times within three months. After several months, the court physicians and surgeons alike had to recognize that Louis XIV suffered of a perianal fistula. Even the court physicians

realized that surgical treatment was the only option. Charles-François Félix de Tassy, who was at that time the first surgeon to the king, was called upon. Even though he was an experienced and skillful operator, he had never before performed operations on anal fistulas. After reading all the ancient and contemporary literature on the treatment of fistula in ano, Félix made arrangements to have all patients in the hospitals of Paris, who were suffering of anal fistulas sent to one hospital in the city where he could perfect his technique. He also designed a special silver instrument dubbed *'le bistouri a la royale'* (front cover). Félix then performed a classical fistulotomy, in almost the exact way it would have been performed by colorectal surgeons today. The king recovered within a month. Louis XIV showed his appreciation to Félix in a generous way; he was awarded 300.000 francs, given a large estate and was elevated to the nobility. The effect on the status of surgery extended far beyond the borders of Paris and France[4-6]. Another, rather amusing, consequence of Louis XIV having a fistula was that the French surgeons of that time actually complained that they were being incessantly teased by people, who pretended, whatever their complaints were, that they proceeded from an anal fistula[6].

Charles Dickens and Sir Frederic Salmon

Not only kings suffer of perianal fistulas. Charles Dickens (1812 – 1870) also had a perianal fistula which bothered him a lot. He was operated by Sir Frederic Salmon on 8 October 1841. In a letter to his friend Beard he describes the operation as follows: "*…last Friday morning (I) was obliged to submit to a cruel operation and the cutting out root and branch of a disease caused by working over much, which has been gathering it seems for many years…"* The operation was successful[7] and Dickens felt tremendous gratitude to Salmon, so much so that he persuaded Lord Iveagh (of the Guinness brewing empire) to help sir Frederic to fund the building of the '*Benevolent dispensary for the relief of the poor afflicted with fistula, piles and other diseases of the rectum and lower intestines'* which

was to become the well known St. Marks Hospital in London. Salmon attributed Dickens' fistula to "*the consequence of too much sitting*". In these days, perianal fistulas were viewed upon as an occupational hazard. Especially tailors were so subject to anal fistulas that they set up their own *'fistula clubs'* [6].

The opinion of Sir Hugh Lockhart-Mummery

Early in the 20th century, the renowned surgeon Hugh Lockhart-Mummery adequately expressed the frustration that many surgeons encounter in the treatment of perianal fistulas: *"Probably more surgical reputations have been damaged by the unsuccessful treatment of fistula than by excision of the rectum or gastroenterostomy"* [8]. Several years later he stated: *"The bad results of laparotomy are generally buried with flowers, while the fistulae go about the world exhibiting the unsuccessful results of the treatment."* [9].

Etiology

Most perianal fistulas originate in the anal glands. These anal glands are located in the subepithelial layer of the anal canal at the level of the dentate line. The duct of each gland has a direct opening into an anal (Morgagni's) crypt. Since the internal anal sphincter is a competent barrier against bacterial contamination, chronic infection of an anal gland can only lead to a perianal abscess or fistula when it extends into the intersphincteric plane. It has been shown that 30-50 percent of the anal glands branch out into the intersphincteric plane. Occlusion of the drainage duct, secondary to fecal material, foreign bodies, or trauma, may result in stasis and infection. This infection can lead to an intersphincteric abscess. When the size of the abscess increases, it will invariably follow one of two avenues of extension. It can either follow the fibro muscular fibers running downward between the internal and external anal sphincter or through the external anal sphincter into the ischiorectal

space. Consequently, a perianal abscess, located at the anal verge has an intersphincteric origin while an abscess located further from the anus, usually has a transsphincteric origin.

A perianal abscess, like all abscesses in other parts of the body, must be adequately drained. To minimize of the risk of a fulminant infection of perianal and perirectal tissues operative drainage must be performed as soon as possible. The risk of such an infection is especially high in diabetics and immunocompromised patients. There is little, if any, use for antibiotics in the primary management of perianal suppuration. Adjunctive antibiotic therapy is only indicated in patients with rheumatic or acquired valvular heart disease and in those who are immunosuppressed. It is wise to make a generous elliptical incision, rather than a small incision with or without contra incision. In about half of all cases, the abscess will recur either as a recurrent abscess or as a perianal fistula, even after adequate drainage[10].

Classification

In 1976, Parks, Gordon and Hardcastle published their article entitled *'A classification of fistula-in-ano'* [11]. Their classification was based on the identification of four types of fistula; inter-, trans-, supra- and extrasphincteric. These different types of fistula are depicted in figure 1.1. An intersphincteric fistula (figure 1.1a) runs downward between the internal and external anal sphincter. The transsphincteric fistula (figure 1.1a) runs from the intersphincteric space, through the external anal sphincter into the ischiorectal space.

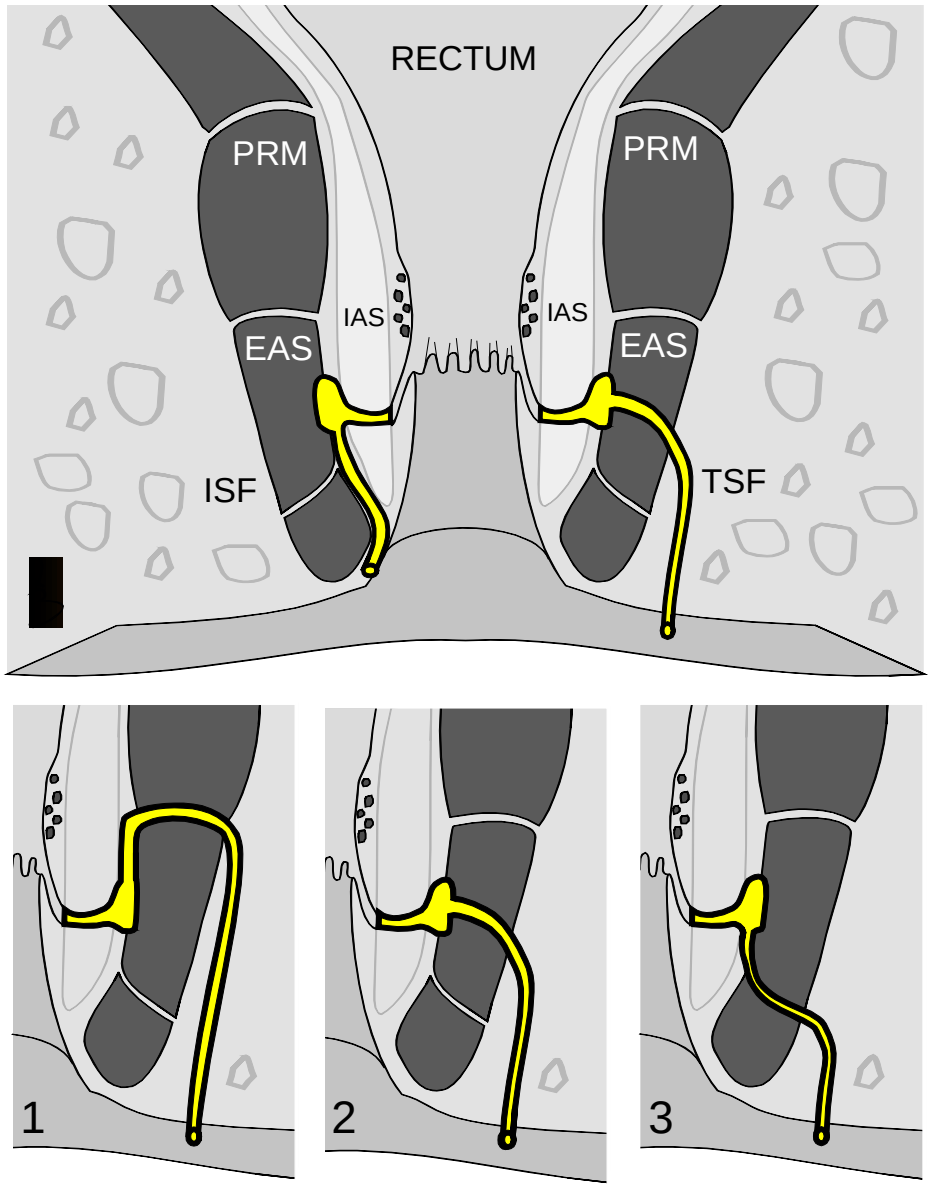

Figure 1.1a; *Schematic drawing of the classification of perianal fistulas according to Parks; PRM=Puborectalis muscle, EAS=External anal sphincter, IAS=Internal anal sphincter, ISF=Intersphincteric fistula, TSF=Transsphincteric fistula, 1 and 2=High transsphincteric fistula, 3=low transsphincteric fistula*

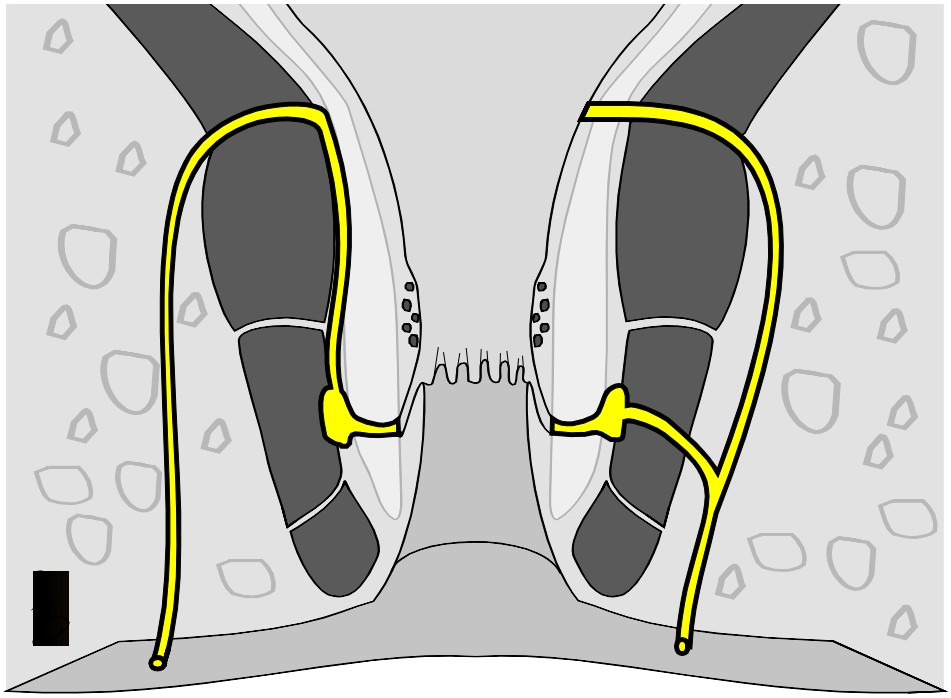

Figure 1.1b; *Schematic drawing of the classification of perianal fistulas according to Parks; PRM=Puborectalis muscle, EAS=External anal sphincter, IAS=Internal anal sphincter, SSF=Suprasphincteric fistula, ESF=Extrasphincteric fistula*

Usually the external opening of an intersphincteric fistula is located near the anal verge, whereas the external opening of a transsphincteric fistula is almost always located several centimeters from the anal verge. In everyday practice, further distinction is made between transsphincteric fistulas that traverse the upper two-thirds of the external anal sphincter (*high* transsphincteric fistulas) and transsphincteric fistulas that traverse the lower third of the external anal sphincter

(*low* transsphincteric fistulas). The suprasphincteric fistula (figure 1.1b) runs upward between the internal and external anal sphincters, then bends around the puborectalis muscle and penetrates the pelvic floor, to traverse downwards through the ischiorectal space. An extrasphincteric fistula (figure 1.1b) passes through the external anal sphincter and then branches out into two tracts; one extending cephalad, penetrating the pelvic floor (finally ending in the rectum) and one caudal (ending in the external opening). Although this classification does not take circumferential extensions into account, it is widely used. One reason is the relative simplicity. Another reason is that this classification relates the anatomical location of the fistulous tract to the anal sphincters, which is relevant for the choice of surgical treatment.

Epidemiology

Most patients who present with a perianal fistula are between 30 and 50 years old. Perianal fistulas are rare in patients younger than 20 or older than 60 years[12]. Men are 2 to 5 times more likely to develop a perianal fistula than women[13,14]. This phenomenon is probably due to the fact that men possess more anal glands than women. Sainio et al. report that the incidence of perianal fistulas is about 12,3 per 100.000 in men and 5,6 per 100.000 in women[15]. According to the Dutch National Medical Registration (Prismant) in the year 2001, 2848 patients were treated in Dutch hospitals for perianal fistulas. Of these 2848 patients, 2024 (71 percent) were male.

Symptoms

Most perianal fistulas are associated with periodical episodes of pain, especially when the external opening of the fistula is occluded. Under these circumstances, symptoms

may also include pyrexia. These complaints will usually subside after the external opening reopens. Some patients will report a continuous purulent discharge, either from the anus or the external opening, necessitating the wearing of pads. Pruritus and anal bleeding are frequently reported but are highly aspecific symptoms.

ASSESSMENT

Inspection

The location of the external opening provides important information regarding the type of fistula. Usually the external opening of an intersphincteric fistula is localized near the anal canal whereas the distance between the external opening of a transsphincteric fistula and the anal verge is several centimeters or more.

Goodsall's rule

Early in the 20th century, Goodsall observed a tendency in the relation between the location of the external opening and the internal opening of perianal fistulas. If the external opening is located posteriorly to the coronal plane, the fistula probably originates from the dorsal midline. If the opening is anterior, it probably runs directly to the nearest crypt. If the distance to the anal verge is more than 3 centimeters (on either side of the anus) the tract is likely to run in a curved tract to the posterior commissure (Figure 1.2). This tendency is recorded in the rule commonly known as Goodsall's rule[16]. Recently, several studies have cast doubt on the reliability of this rule. Cirocco and Reilly[17] conducted a prospective study in a consecutive series of 216 patients with a perianal fistula of cryptoglandular origin. Goodsall's rule was found to be accurate in only 50 percent of all patients. Similar findings have been reported by others[18].

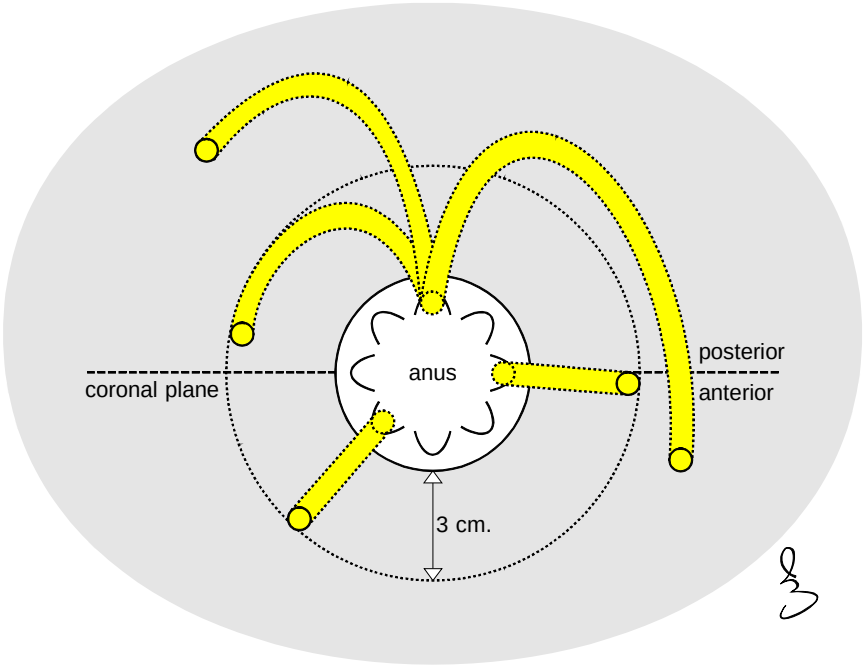

Figure 1.2; *Schematic drawing of Goodsall's rule; showing relation of external opening to internal opening in perianal fistulas*

Digital examination

Although it has been suggested that digital examination enables the identification of the internal opening, it is questionable whether this is reliable or not. Digital examination remains to be an important examination however, since a tender palpable mass in the pelvis may reveal a supralevator abscess. It also provides an indication of the quality of the sphincter complex, by assessing sphincter tone, although it has to be noted that Eckhardt and coworkers have shown that the sensitivity and specificity in assessing anal sphincter competence is only 63 and 57 percent, even when performed by an experienced proctologist[19].

Probing

Sometimes the route of a perianal fistula can be identified by introducing a probe into the external opening. It is however not advocated to probe a fistulous tract on an outpatient basis, since probing can be extremely painful. Furthermore there is a considerable risk of making a false passage.

Injection of Methylene Blue

It has been suggested that peroperative injection of a diluted solution of methylene blue into the external opening can be helpful in localizing the internal opening. Many surgeons criticize this technique because of the staining of tissues. Dunphy described the use of methylene blue as follows; *"Injection of methylene blue would be as sensible as to pour ink in a newspaper in order to facilitate reading"* [20]. Injection of hydrogen peroxide into the external anal opening would seem to be a good alternative to the injection of methylene blue. Hydrogen peroxide does not stain the operative field and can often be helpful in identifying the internal anal opening[18].

Fistulography

Until the early nineties, the preoperative classification of perianal fistulas, including the localization of their internal opening, was mainly based on inspection, digital examination, probing and fistulography. Fistulography used to be the only imaging modality, and is still often utilized. It is remarkable that data, regarding the accuracy of fistulography are scarce. In a retrospective study, Kuijpers and coworkers showed that fistulography accurately predicted the location of the internal opening in only 28 percent of all patients. The investigation was false-negative and false-positive

respectively in 64 and 8 percent of the cases[21]. Ahlbäck and co-workers utilized a specially manufactured balloon-catheter to demarcate the upper and lower boundary of the canal. Using this catheter, they were able to localize the internal opening correctly in 72 percent of their patients[22]. In this study, the result was false-negative and false-positive respectively in 10 and 18 percent. Weisman[23] conducted a retrospective study in 27 patients. According to this author, fistulography resulted in a correct classification of the fistula in 89 percent of the cases patients. Based on the limited data on fistulography, it is impossible to assess the exact role of fistulography in preoperative imaging of perianal fistulas.

Endoanal Sonography

Since the introduction of endoanal sonography in the early nineties, this imaging modality is used in the preoperative work-up of patients with a perianal fistula with increasing frequency. Despite its frequent use, there is still substantial controversy concerning the efficacy value of this investigation. Graf and Eberhard performed preoperative endoanal sonography in 35 patients, presenting with a perianal fistula[24] . Peroperatively, an internal opening was found in seventeen subjects. In 9 patients (53 percent) this opening had been correctly identified by endoanal sonography. According to other investigators, the additional value of conventional endoanal sonography is not as high as expected. They were able to identify the internal opening of the fistula in only 5 to 28 percent of their patients[25-27]. Regarding the classification of perianal fistulas, conventional endoanal sonography seems to be more accurate. Deen and colleagues were able to correctly classify the fistula in 94 percent of their patients. In three other studies, endoanal sonography resulted in correct classification of the fistula in about 60 percent of all patients (table 1.1).

Based on these data, Choen and co-workers stated that endoanal sonography has no added value over digital examination and careful probing[29].

Author	*Year*	*No. of Patients*	*Correct Classification of the Fistula (%)*	*Correct Localization Internal Opening (%)*
Cataldo [26]	1993	19	63	28
Deen [25]	1994	18	94	11
Graf [24]	1995	17	not stated	53
Hussain [28]	1996	28	61	43
Poen [27]	1998	19	57	5
Ratto [94]	2000	26	50	54

Table 1.1; *Classification of perianal fistulas and correct localization of their internal opening using conventional endoanal sonography (**WITHOUT** hydrogen peroxide enhancement)*

When utilizing conventional endoanal sonography, it is virtually impossible to differentiate between a fistulous tract and scar tissue[30]. This can be a major problem in patients who have undergone prior attempts at surgical repair.

In 1993, Cheong et al. have suggested that the accuracy of preoperative classification, using endoanal sonography can be improved by using hydrogen peroxide as a contrast medium [31]. Their retrospective study in 38 patients revealed that the preoperative classification of the fistula corresponded with peroperative findings in 92 percent of all cases. Furthermore it has been suggested that hydrogen peroxide enhanced endoanal sonography is able to accurately depict circumferential branches [32]. Poen and co-workers showed that the location of the internal opening could be accurately predicted in only 5 percent of all cases when using conventional endoanal sonography.

When hydrogen peroxide was used as a contrast agent, endoanal sonography correctly identified the location of the internal opening in 48 percent. Correct

classification of the fistula was possible in 98 percent of all cases[27]. Other authors have substantiated the benefit of the addition of hydrogen peroxide (table 1.2).

Author	*Year*	*No. of Patients*	*Correct Classification of the Fistula (%)*	*Correct Localization Internal Opening (%)*
Poen[27]	1998	19	95	48
Joo[33]	1998	25	76	64
Navarro[34]	1998	55	85	96
Ratto[94]	2000	26	73	54

Table 1.2; *Classification of perianal fistulas and correct localization of their internal opening using hydrogen peroxide enhanced endoanal sonography.*

Hydrogen peroxide enhanced endoanal sonography is quick, the technique is easy and the 'learning curve' to correct interpretation is relatively short. Furthermore, the investigation is relatively cheap and, even though hydrogen peroxide instillation can cause a passing sensation of pain, not very burdening to the patient. Unfortunately, hydrogen peroxide cannot be used in patients in whom the external opening is closed. Based on these findings, it seems likely that hydrogen peroxide enhanced endoanal sonography is an important tool in the preoperative assessment of perianal fistulas.

Magnetic Resonance Imaging (MRI)

When using magnetic resonance imaging, the complete sphincter complex, including the external anal sphincter and fistulous tracts is adequately visualized. Initially, MR imaging of perianal fistulas was performed using a body coil or external surface coil. The initial report on this technique in 16 patients showed concordance between MRI and surgical exploration in 92 percent of the patients[35]. Van Beers and co-workers also found a concordance of 92 percent between conventional MRI and surgery,

whereas they only found concordance between digital examination and surgical exploration in 67 percent of all cases[36].

The introduction of endoanal coils is viewed upon by some as a major advance in the imaging of perianal fistulas[37]. However, there is considerable debate about which modality yields superior imaging results. When comparing MRI with endoanal coil to MRI with external surface coil, Stoker and co-workers[38] showed endoanal coils to be superior (accuracy 86 percent versus 43 percent). Halligan and colleagues, however, compared these two different kinds of MR imaging and found the use of the external surface coil to be superior. In 30 patients, he found concordance between MRI and surgery in 96 percent of all cases when using the external surface coil, whereas concordance was only 68 percent when using the endoanal coil[39]. Unfortunately, the results of this comparative study are influenced by differences in imaging sequences for both coils as the more sensitive sequence (fat suppression technique) was only used for body coil[37]. Since the results of the study by Stoker and coworkers were reproduced by DeSouza and colleagues[44], it would seem that magnetic resonance imaging, using an endoanal coil is the superior technique in preoperative imaging of perianal fistulas.

In most studies, surgical exploration is considered to be the 'golden standard'. Several authors have suggested that surgical exploration is actually less accurate than MR Imaging[40-43]. Barker and coworkers showed that 9 percent of all fistulas do not heal, because fistulous tracts that were identified by endoanal MRI were not recognized during surgery. Until now, four studies have compared preoperative imaging using conventional endoanal sonography to preoperative imaging using either body coil MRI[43,45] or endoanal MRI[28,46]. Three of these four studies clearly show that imaging of perianal fistulas gives rise to a correct classification significantly

more often using MRI than when using conventional endoanal ultrasound (table 1.3). Only Orsoni and coworkers found that EUS was a more sensitive modality for imaging of perianal fistulas than endoanal MRI. It has to be mentioned however, that all his 22 patients had fistulas due to Crohn's disease. Furthermore, the results reported by Orsoni are disputed by some workers because in their opinion the MRI technique utilized by Orsoni was suboptimal[47].

Author	*Year*	*Sensitivity EUS*	*Sensitivity MRI*
Lunniss [43]	1994	65	89
Hussain [28]	1996	61	85
Maier [45]	2001	60	85

Table 1.3; *Accuracy (Sensitivity) for preoperative correct classification in studies directly comparing Ultrasound to MRI.*

Unfortunately, no prospective trials have been conducted, comparing hydrogen peroxide enhanced endoanal ultrasound and MRI. Magnetic Resonance Imaging is a relatively expensive investigation. Expensive equipment is necessary and the investigation may take up to one hour. Furthermore, patients with metal implants or pacemakers cannot undergo MR imaging. Patients who have a tendency to claustrophobia also have to be excluded from this type of investigation.

Assessment of fecal continence

Fecal incontinence is also referred to as leakage, seeping, anal incontinence and incontinentia alvi. The latter is the official Latin denomination meaning that the abdomen is uncontrollable. The following definition of fecal incontinence is generally accepted; fecal incontinence is the impaired ability to control gas or stool[48].

One of the reasons for the wide variety in reported functional outcomes after surgery for perianal fistulas is the inability to accurately characterize and assess fecal continence. Therefore a precise system of scoring and grading fecal continence is extremely important in surgery for perianal fistulas. Such a system allows an assessment of fecal continence before and after the operation, as well as comparisons to be made between different series. Parks[49] was one of the first to describe such a system (table 1.4).

Grade	
Parks I	Fully continent
Parks II	Soiling or incontinence for gas
Parks III	Incontinence for liquid stool
Parks IV	Incontinence for solid stool

Table 1.4; *Grading of fecal incontinence according to Parks [49].*

Because this system is so simple, it is the one most frequently utilized. Unfortunately, this system does not take into account the frequency of symptoms. Because of this, other systems have been proposed[50-53]. Unfortunately, apart from the system devised by Parks[49], none of these systems is widely accepted.

Recently, several new grading systems have been introduced[54,55]. Both these systems attempt to quantify the severity of fecal incontinence by awarding a score based on the type of incontinence and the frequency at which it occurs. The Vaizey score has been shown to correlate very well with clinical assessment. The Rockwood score however was shown to have an excellent correlation with various quality of life measures[56]. The system produced by Rockwood uses two basic components; the type of incontinence (gas, mucus, liquid or solid) and the frequency of occurrence. To ascertain the weighting scores, 34 patients were asked to complete a 20-cell matrix, similar to the one shown in table 4 and instructed to rank the severity of the

items relative to each other, assigning a “1” to the most severe cell and a “20” to the least severe cell. In this manner, a type x frequency matrix showing separate severity scores was developed (table 1.5).

	2 or more times per day	*Once per day*	*2 or more times per week*	*Once per week*	*1 to 3 times per week*	*never*
Gas	12	11	8	6	4	0
Mucus	12	10	7	5	3	0
Liquid	19	17	13	10	8	0
Solid	18	16	13	10	8	0

Table 1.5; *Grading of fecal incontinence according to Rockwood* [55,57]

This system has been validated[55-57] and seems to find wide appraisal. A major advantage of the Rockwood fecal incontinence severity index over the Vaizey score is that it uses validated weighting scores, that are based on patients input, whereas the Vaizey score utilizes randomly assigned scores (“1”, “2”, “3” and “4” in order of increasing severity). Furthermore, the Vaizey score does not incorporate soiling, which is often a major complaint, especially in patients who have undergone surgery for perianal fistulas. Therefore, at the moment, the Rockwood fecal incontinence severity index seems to be the incontinence scoring system of choice.

TREATMENT MODALITIES

Seton technique

The use of a seton in the treatment of perianal fistulas was first described by Hippocrates and is still an important tool in the management of perianal fistulas. Setons are used in the treatment of perianal fistulas in many different ways and in many

different forms. Materials that are reported to date are silk, nylon, polyester, rubber, silicone, plastic, wire and even herbal medicated thread[58].

Cutting seton

After initial loose placement, the seton can be tightened at two- to four- week intervals. Gradual pressure necrosis will result in slow, yet controlled division of the enclosed anal sphincters. This type of seton is usually referred to as the 'cutting seton'. As the muscle is transected, a wake of residual fibrosis, adjacent to the sphincter muscles, ensures that minimal separation of the cut muscle occurs[58,59]. According to Corman this method is analogous to a wire cutting slowly through an ice cube[60]. The ice remains intact once the wire has passed through. Despite this theoretical advantage, it is unknown whether the remaining defect after the use of a cutting seton is smaller than the defect after common fistulotomy or not. Of the different seton techniques, the cutting seton is most often utilized in treatment for perianal fistula.

Author	*Year*	*No. of Pts.*	*Impaired Continence (%)*
Christensen[62]	1986	21	62
Eitan[63]	1990	21	15
Williams[64]	1991	13	54
Graf[65]	1995	29	44
McCourtney[66]	1996	27	19
Walfisch[61]	1997	20	0
Hämäläinen[67]	1997	35	63
Garcia[68]	1998	12	67

Table 1.6a; *Incidence of impaired continence after cutting seton treatment for transsphincteric fistulas.*

There is a wide variation in the reported incidence of impaired continence after treatment with a cutting seton. Some authors find no continence impairment whatsoever[61]. Most authors however report a considerably higher (and more realistic?)

incidence of minor continence disorders, such as soiling, incontinence for gas or liquid stool between 15 and 67 percent[62-68] (table 1.6a). Another disadvantage of this technique is that it is very painful and takes a relatively long time to achieve total healing.

Staged seton fistulotomy

A seton can also be used prior to a fistulotomy at a second stage, 6-8 weeks after initial loose placement of the seton. During this period, the seton can act as a drain. Furthermore it will stimulate local fibrosis, so that when the fistulotomy is completed, the sphincter muscles will not be separated widely. This technique is said to be far less painful than the classic cutting seton technique. Furthermore the sphincter muscle is divided in a more controlled way than with the cutting seton technique. It remains unclear whether or not staged seton fistulotomy is preferable to the cutting seton technique or not. In a study performed by Van Tets[69], 58 percent of all patients encountered impaired continence. Pearl and coworkers[70] find significantly better functional results after the use of the staged seton fistulotomy (Table 1.6b).

Author	*Year*	*No. of Pts.*	*Impairment of Continence (%)*
Pearl[67]	1993	65	3
Van Tets[69]	1995	16	50
Garcia[68]	1998	47	66

Table 1.6b; *Incidence of impaired continence after staged seton fistulotomy of transsphincteric fistulas.*

They report an incidence of impaired continence of only 3 percent. In a retrospective study, comparing the staged seton fistulotomy to the classic cutting seton technique in 59 patients, Garcia-Aguilar and colleagues find that there is no difference between the functional results the recurrence rates of these techniques[68]. Furthermore they report that both techniques have a healing rate of 92 percent[68].

Drainage seton (Indwelling seton)

A seton can also be used for long-term drainage (in order to prevent acute perianal abscess formation). This type of seton is most often referred to as an 'indwelling seton' or 'long term drainage seton'. This technique is most often utilized in patients with chronic sepsis secondary to perianal Crohn's disease. However, some surgeons utilize this technique in high transsphincteric fistulas of cryptoglandular origin as well.

Fibrin glue treatment

The use of fibrin glue for the treatment of perianal and rectovaginal fistulas was introduced in 1991 by Hjörtrup and co-workers from Denmark[71]. They used commercially available fibrin glue in 23 patients with a perianal fistula or persistent perineal sinus after proctectomy. Their success rate was 74 percent. Aitola attempted to reproduce these results in 10 patients with perianal fistulas[72]. The fistula healed in only one of these 10 patients. In the United States, several investigators treated perianal fistulas with fibrin glue, but since commercially available fibrin glue was not approved by the Food and Drugs Administration, they had to revert to autologous fibrin glue. The healing rates of the treatment with autologous fibrin glue seemed to be encouraging, varying between 60 and 80 percent[73,74]. In a later study, Cintron and co-workers showed that there was no significant difference between the healing rates after using commercially available fibrin glue (Tissucol; Baxter Healthcare Corporation) and autologous fibrin glue[75]. In this study, 79 patients were treated with fibrin glue. All patients underwent examination under anesthesia in the operating room, with an attempt to identify internal and external openings. The fistulous tract was then thoroughly curetted, using a blunt curette or a gauze strip, which was threaded through the tract. Fibrin glue was then injected into the external opening until it was seen coming from the internal opening. Using this technique; they

reported a moderate overall healing rate of 62 percent[75]. How much of the success in this study was due to the thorough curettage and how much of the success was due to the injection of fibrin glue is unclear. The use of fibrin glue seems to offer a unique treatment modality, because sphincter muscles are not damaged, nor are anatomical planes divided. Fibrin glue injection obliterates the fistulous tract without cutting open or cutting out the fistula itself. There does not seem to be a risk of postoperative impaired continence. Therefore, even if the fistula persists the patient is left no worse than before. However, the reported success rates seem to be moderate and vary considerably. This type of treatment can definitely be worthwhile if acceptable healing rates can be obtained. Possibly, it can even be performed in an outpatient situation. However, further investigations of the added benefit of this technique over curettage alone are called for.

Fistulotomy and Fistulectomy

The classical treatment of perianal fistulas is to either lay the fistula open (fistulotomy) or to excise it (fistulectomy). In the past century, considerable debate existed as to whether the lay-open technique or excision of the fistula was the most appropriate treatment for perianal fistulas. Nowadays, fistulotomy is recommended by most authors. Complete excision of the fistulous tract, with removal of adjacent scar tissue results in a larger wound and a larger separation of the ends of the sphincter muscles. Subsequently, healing time is longer and the chance of impaired continence is greater. Kronberg performed a randomized trial comparing these two techniques in 37 patients[76]. He concluded that healing times were considerably shorter in the group of patients undergoing fistulotomy. Furthermore the incidence of impaired continence was lower in this group, whereas the recurrence rates were similar. Kronberg concluded the fistulotomy to be superior to fistulectomy[76].

Almost all fistulas can be cured by fistulotomy, with a low recurrence rate. Initially, it was stated that fecal continence could be preserved, as long as the puborectalis muscle remained intact[11]. However, over time, it has become clear that division of a substantial part of the external anal sphincter can lead to impaired continence. Only the fistulous tract can only be laid open without subsequent risk of incontinence for solid stool in patients with an intersphincteric fistula. During fistulotomy, only the distal part of the internal anal sphincter is divided, whereas the external anal sphincter remains intact. Although incontinence for solid stool is rare, the reported incidence of minor continence disorders such as soiling, incontinence for gas or liquid stool varies between 8 and 50 percent[77-80] (table 1.7a).

Author	*Year*	*No. of Pts.*	*Impairment of Continence (%)*
Belliveau[77]	1983	12	8
Lunniss[78]	1994	22	50
Van Tets[79]	1994	86	13
Garcia[80]	1996	180	39

Table 1.7a; *Incidence of impaired continence after fistulotomy of* ***intersphincteric*** *fistulas.*

Author	*Year*	*No. of Pts.*	*Impairment of Continence (%)*
Belliveau[77]	1983	18	33
Lunniss[78]	1994	15	53
Van Tets[79]	1994	166	31
Garcia[80]	1996	108	54

Table 1.7b; *Incidence of impaired continence after fistulotomy of* ***transsphincteric*** *fistulas.*

When performing a fistulotomy for a (low) transsphincteric fistula, damage to the external anal sphincter is unavoidable. Consequently, the reported incidences are generally higher than those reported after fistulotomy for intersphincteric fistula and vary between 30 and 50 percent[77-80] (table 1.7b).

surgical technique

Fistulotomy can be performed in lithotomy position or with the patient in the prone jack-knife position (figure 1.3). Nowadays, most colorectal surgeons prefer prone jack-knife position, since it provides better access, improved hemostasis and a more comfortable position for the surgeon. Since identification of the internal opening of the fistula is crucial, adequate exposure by means of an anal retractor is indispensable. The fistulous tract is then identified using a Lockhart-Mummery probe, which is inserted through the fistulous tract. Using a diathermy device, all the tissue proximal to the probe (including the distal part of the internal and/ or external anal sphincter) is then divided. By dividing the distal part of the internal and/ or the external anal sphincter, the infected glandular tissue can be reached and curetted and the intersphincteric abscess can be adequately drained. The roof of the fistula is then curetted.

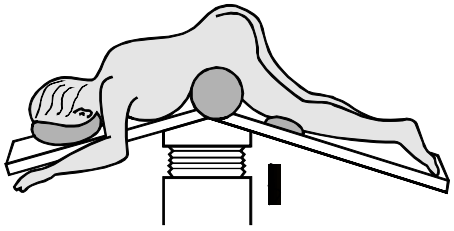

figure 1.3; *prone jack-knife position*

Transanal advancement flap repair

Noble[81] first described the use of advancement flaps for surgical repair of rectovaginal fistulas. Ten years later Elting[82] applied this technique to the treatment of trans-sphincteric fistulas. In his paper he outlined the following principles: “separation of the fistulous tract from the communication with the bowel and adequate closure of that communication with removal of all the diseased tissue in the rectum”. In 1948 Laird[83] described a flap of mucosa, submucosa and some fibers of the internal anal sphincter.

In recent years the transanal advancement flap repair has been advocated as an attractive alternative for patients with transsphincteric perianal fistulas. It has been stated that this procedure is advantageous because it enables the healing of almost all fistulas without sphincter damage and without continence disturbance. Initially, the reported healing rates varied between 84 and 100 percent[84-88] (table 1.8).

Author	*Year*	*No. of Patients*	*Healing rate (%)*	*Impairment of continence (%)*
Oh [84]	1982	15	84	not stated
Aguilar [85]	1985	151	98	10
Wedell [86]	1987	27	100	0
Kodner [87]	1993	31	87	not stated
Ozuner [88]	1996	19	68	not stated

Table 1.8; *Success rate and incidence of impaired continence after transanal advancement flap repair.*

Recently, however, less favorable results have been reported in patients with a transsphincteric fistula of cryptoglandular origin[88]. It is still unclear which factors affect the outcome of transanal advancement flap repair. The surgical technique for this procedure is described in detail in chapter 3.

Anocutaneous advancement flap repair

A few years ago, anocutaneous advancement flaps were introduced in the treatment of transsphincteric perianal fistulas by Del Pino and Coworkers[89]. They reported a small number of patients with promising results. According to these authors, this procedure does not result in anatomic alteration of the anal canal, so all other operative choices are still feasible. The results, reported so far, seem to be comparable with those obtained after transanal mucosal advancement flap repair[90-93] (Table 1.9).

Author	*Year*	*No. of Patients*	*Healing rate (%)*	*Impairment of continence (%)*
Del Pino[89]	1996	8	88	not stated
Kohler[90]	1996	21	90	0
Robertson[91]	1998	14	78	7
Jun[92]	1993	40	95	none
Nelson[93]	2000	53	74	not stated

Table 1.9; *Success rate and incidence of impaired continence after anocutaneous advancement flap repair.*

The anocutaneous advancement flap repair can be performed without deep intra-anal dissection. This might be a major advantage, resulting in less sphincter damage. Robertson and Mangione performed an anocutaneous advancement flap in 14 patients[91]. Only one patient experienced a diminished continence for gas after the procedure. The surgical technique for this procedure is described in detail in chapter 4.

OUTLINE OF THE THESIS

This thesis is aimed at evaluating the outcome of different surgical procedures in the treatment of transsphincteric perianal fistulas. In addition, the efficacy of one of these techniques in the management of fistulas that extend into the vagina was also investigated. Another purpose of this thesis was to study the role of endoanal magnetic resonance imaging (MRI) and hydrogen peroxide enhanced endoanal sonography in the preoperative evaluation of perianal fistulas. Prior to surgical treatment of a perianal fistula, it is important to acquire detailed information about the course of the fistulous tract, the exact location of the internal opening and the existence of circumferential extensions. This information can be obtained by performing endoanal MRI. However, if the same information can be obtained by performing hydrogen peroxide-enhanced endoanal sonography this would be preferable because of the limited costs and burden to the patient. These two imaging modalities are compared, in order to investigate their relative value.

Until recently, fistulotomy was the 'golden standard' in the treatment of perianal fistulas. This procedure is associated with a relatively high incidence of impaired continence. The transanal advancement flap repair was introduced as a 'sphincter preserving' alternative. The clinical outcome after this operation, with special emphasis on the impact of this procedure on fecal continence is investigated. Furthermore, a study aimed at identifying variables affecting the outcome of transanal advancement flap repair for perianal fistulas was performed. Initially, quite promising results were reported, with healing rates up to 100 percent, even in patients with Crohn's disease. Recently less favorable results have been reported especially in patients who had undergone two or more previous repairs. Furthermore it has been

reported that continence deteriorates in quite a number of patients after transanal mucosal advancement flap repair. It has been suggested that the anocutaneous advancement flap repair is a viable alternative. The clinical outcome after this procedure and its impact on fecal continence are investigated.

Since the external anal sphincter is not divided in transanal advancement flap repair, the relatively high incidence of impaired continence after this procedure is surprising. It has been suggested that this impaired continence is caused by overstretching the fibers of the anal sphincter complex, due to the use of a Parks' anal retractor. An investigation, whether the use of other instruments (such as the more modern Scott retractor) can diminish this deteriorating effect, is conducted.

Rectovaginal fistulas are a difficult surgical problem. Initially, transanal advancement flap repair of these fistulas seemed to yield good results. However, later on, less favorable results were reported. Our attempt to improve the healing rate after transanal advancement flap repair by performing an additional labial fat flap transposition is described.

AIMS OF THE THESIS

The questions this thesis attempts to answer are:

- Is the preoperative evaluation of perianal fistulas with hydrogen peroxide enhanced endoanal sonography comparable to the evaluation with endoanal magnetic resonance imaging?
- What is the healing rate after transanal mucosal advancement flap repair?
- What is the incidence of impaired continence after transanal mucosal advancement flap repair?
- Is it possible to identify variables affecting the outcome of transanal mucosal advancement flap repair?
- What is the healing rate after anocutaneous advancement flap repair?
- What is the incidence of impaired continence after anocutaneous advancement flap repair?
- Is it possible to reduce the incidence of impaired fecal continence after transanal advancement flap repair by using a different type of anal retractor?
- What is the healing rate after transanal mucosal advancement flap repair of rectovaginal fistulas?
- Is it possible to improve the outcome after transanal mucosal advancement flap repair of rectovaginal fistulas by addition of a labial fat flap?

REFERENCES

1. Adams F. The genuine works of Hippocrates translated from the Greek with a preliminary discourse and annotation. New York, William Wood Company, 1849)
2. Corman M. Hippocrates: On fistulae. Dis Colon Rectum 1980;23:56-59
3. Corman M. Treatises of Fistula in Ano, Haemorrhoids and Clysters. Dis Colon Rectum 1983; 26:197-210
4. Lyons AS, Petrucelli RJ. Medicine, an illustrated history. Abredale Press, Harry N. Abrams, Inc. Publisher, 1987, New York
5. Bodemer CW, France, the fundament, and the rise of surgery. Dis Colon Rectum. 1983 Nov;26(11):743-50
6. Porter R. The Greatest benefit to mankind. Harper Collins Publishers: London 1997: 279
7. Bowen WH. Charles Dickens and his family. W. Heffer and sons: Cambridge 1956:138
8. Lockhart-Mummery JP. Discussion on fistula-in-ano. Proc R Soc Med 1929;22:1331-58
9. Lockhart-Mummery JP. Fistula in ano. Lancet 1936; 657
10. Schouten WR, van Vroonhoven TJ. Treatment of anorectal abscess with or without primary fistulectomy. Dis Colon Rectum 1991 Jan;34(1):60-3
11. Parks AG, Gordon PH, Hardcastle JD. A classification of fistula in ano. Br J Surg 1976; 63: 1-12
12. Vasilevsky CA, Gordon PH. Results of treatment of fistula in ano. Dis Colon Rectum 1984; 28: 225-31
13. Marks CG, Ritchie JK. Anal fistulas at St. Mark's Hospital. Br J Surg 1977; 64: 84-91
14. Shouler PJ, Grimley RP, Keighley MRB, Alexander-Williams J. Fistula in ano is usually simple to manage surgically. Int J Colorect Dis 1986; 1: 113-5
15. Sainio P. Fistula in ano in a defined population. Incidence and epidemiologic aspects. Ann Chir Gynaecol 1984; 73: 219-24
16. Goodsall DH, Miles WE. Diseases of the anus and rectum, Part I, p. 121 (Longmans, Green and Co., 1900)
17. Cirocco WC, Reilly JC. Challenging the predictive accuracy of Goodsall's rule for anal fistulas. Dis Colon Rectum. 1992 Jun;35(6):537-42.
18. Gunawardhana PA, Deen KI. Comparison of hydrogen peroxide instillation with Goodsall's rule for fistula-in-ano. Aust N Z J Surg. 2001 Aug;71(8):472-474.
19. Eckardt VF, Kanzler G. How reliable is digital examination for the evaluation of anal sphincter tone? Int J Colorectal Dis 1993 Jul;8(2):95-7
20. Dunphy JE, Pikula J. Fact and Fancy about fistula in ano. Surg Clin North Am. 1955;35:1469
21. Kuijpers HC, Schulpen T. Fistulography for fistula in ano. Dis Colon Rectum 1985; 28: 103-4
22. Ahlbäck S, Holmström B, Syk B. Anal fistulography. Acta Radiol 1974; 15: 282-7

23. Weisman RI, Orsay CP, Pearl RK, Abcarian H. The role of fistulography in fistulo in ano. Dis Colon Rectum 1991; 34: 181-4
24. Graf D, Aeberhard P. Imaging of perianal and perirectal abscesses and fistulae using intraluminal ultrasound diagnosis. Swiss Surg 1995; 6: 294-7
25. Deen KI, Williams JG, Hutchinson R, et al. Fistulas in ano: endoanal ultrasonographic assessment assists decision making for surgery. Gut;1994; 35: 391-4
26. Cataldo PA, Senagore A, Luchtefeld MA. Intrarectal ultrasound in the evaluation of perirectal abscesses. Dis Colon Rectum 1993; 36: 554-8
27. Poen AC, Felt-Bersma RJF, Eijsbouts QAJ, et al. Hydrogen peroxide-enhanced transanal ultrasound in the assessment of fistulo-in-ano. Dis Colon Rectum 1998; 41: 1147-52
28. Hussain SM, Stoker J, Schouten WR, Hop WCJ, Laméris JS. Fistula in ano: endoanal sonography versus endoanal MR imaging in classification. Radiology 1996; 200: 475-81
29. Choen S, Burnett S, Bartram CI, Nicholls RJ. Comparison between anal endosonography and digital examination in the evaluation of anal fistulae. Br J Surg 1991; 78: 445-7
30. Halligan S. Review: Imaging fistula-in-ano. Clin Radiol 1998; 53: 85-95
31. Cheong DM, Nogueras JJ, Wexner SD, Jagelman DG. Anal endosonography for recurrent anal fistulas: image enhancement with hydrogen peroxide. Dis Colon Rectum 1993; 36: 1158-60
32. Iroatulam A, Nogueras , Chen H. Accuracy of endoanal ultrasonography in evaluating anal fistulas. Gastroenterology 1997; 112: A1450
33. Joo JS, Son KS, Lee HS, Lee SK. Preoperative evaluation of anal fistula by endorectal ultrasonography. Dis Colon Rectum 1998; 41 : A46-7
34. Navarro A, Rius J, Collera P, Garcia MI, Marco C. Anal fistulas: Results of ultrasonographic studies. Dis colon Rectum 1998; 41: A57
35. Lunniss JL, Armstrong P, Barker PG, Rezenek RH, Phillips RK. Magnetic Resonance Imaging of anal fistulae. Lancet 1992; 340: 394-96
36. Van Beers B, Grandin C, Kartheuser A, Hoang P, Mahieu P, Detry P, Vanheuverzwijn R, Pringot J. MRI of complicated anal fistulae: comparison with digital examination. J Comput Assist Tomogr 1994; 18: 87-90
37. Stoker J, Rociu E, Wiersma TG, Lameris JS. Imaging of anorectal disease. Br J Surg 2000;87:10-27
38. Stoker J, Hussain SM, van Kempen D et al. Endoanal coil in MR imaging of anal fistulas. AJR 1996; 166: 360-2
39. Halligan S, Bartram CI. MR imaging of fistulo in ano: are endoanal coils the gold standard? Am J Roentgenol 1998; 171: 407-12
40. Beckingham IJ, Spencer JA, Ward J, Dyke GW, Adams C, Ambrose NS. Prospective evaluation of dynamic contrast enhanced magnetic resonance imaging in the evaluation of fistula on ano. Br J Surg 1996; 83: 1396-8
41. Spencer JA, Ward J, Beckingham IJ, Adams C, Ambrose NS. Dynamic contrast enhanced MR imaging of perianal fistulas. Am J Roentgenol 1996; 167: 735-41

42. Barker PG, Lunniss PJ, Armstrong P, Reznek RH, Cottam K, Phillips RK. Magnetic resonance imaging of fistula in ano: technique, interpretation and accuracy. Clin Radiol 1994; 49: 7-13
43. Lunniss PJ, Barker PG, Sultan AH, Armstrong P, Reznek RH, Bartram CI, Cottam KS, Phillips RK. Magnetic resonance imaging of fistula-in-ano. Dis Colon Rectum 1994; 37: 708-18
44. DeSouza NM, Gilderdale DJ, Coutts GA, Puni R, Steiner RE. MRI of fistula-in-ano: a comparison of endoanal coil with external phased array coil techniques. J Comput Assist Tomogr 1998; 22: 357-63
45. Maier AG, Funovics MA, Kreuzer SH, Herbst F, et al. Evaluation of perianal sepsis:comparison of anal endosonography and magnetic resonance imaging. J Magn Reson Imaging 2001; 14: 254-60
46. Orsoni P, Barthet M, Portier F, et al. Prospective comparison of endosonography, magnetic resonance imaging and surgical findings in anorectal fistula and abscess complicating Crohn's disease. Br J Surg 1999;86:360-4
47. Zbar AP, deSouza NM. Prospective comparison of endosonography, magnetic resonance imaging and surgical findings in anorectal fistula and abscess complicating Crohn's disease. Br J Surg 1999;86:1093-94
48. Briel JW. Treatment of Faecal Incontinence. Academic Dissertation (Rotterdam, NL). 2000
49. Parks AG. Anorectal incontinence. J R Soc Med 1975; 68:21-30
50. Miller R, Bartolo DCC, Locke JC, Mortensen NJ. Prospective study of conservative and operative treatment for faecal incontinence. Br J Surg 1988; 75: 101-5
51. Pescatori M, Anastasio G, Bottini C, Mentasti A. New grading and scoring for anal incontinence. Evaluation of 335 patients. Dis Colon Rectum 1992; 35: 482-7
52. Jorge JM, Wexner SD. Etiology and management of fecal incontinence. Dis colon rectum 1993; 36(1):77-97)
53. Osterberg A, Graf W, Karlbom U, Pahlman L. Evaluation of a questionnaire in the assessment of patients with faecal incontinence and constipation. Scand J Gastroenterol 1996; 31: 575-80
54. Vaizey CJ, Carapeti E, Cahill JA, Kamm MA. Prospective comparison of faecal incontinence grading systems. Gut 1999;44:77-80
55. Rockwood TH, Church JM, Fleshman JW, et al. Patient and surgeon ranking of the severity of symptoms associated with fecal continence. Dis Colon Rectum 1999; 42:1525-1532
56. Cavanaugh M, Hyman N, Osler T. Fecal Incontinence Severity Index After Fistulotomy: A Predictor of Quality of Life. Dis Colon Rectum 2002 Mar;45(3):349-353.
57. Rockwood TH, Church JM, Fleshman JW et al. Fecal incontinence quality of life scale: quality of life instrument for patients with fecal incontinence. Dis Colon Rectum 2000; 43:9-17
58. McCourtney JS, Finlay IG, Setons in the surgical management of fistula in ano. Br J Surg 1995, 82, 448-52
59. Choen SF, Nicholls RJ, Anal fistula. Br J Surg, 1992; 79: 197-205

60. Corman ML. Colon and Rectal Surgery. 2nd edition, Philadelphia, Pennsylvania: JB Lippincott, 1989:146
61. Walfisch S, Menachem Y, Koretz M. Double seton: a new modified approach to high transsphincteric anal fistula. Dis Colon Rectum 1997; 40: 731-2
62. Christensen A, Nilas L, Christiansen J. Treatment of transsphincteric anal fistulas by the seton technique. Dis Colon Rectum 1986; 29: 454-5
63. Eitan A, Duek DS, Barzilai A. The seton in the treatment of transsphincteric anal fistulas. Harefuah 1990; 119: 134-6
64. Williams JG, MacLeod CA, Rothenberger DA, Goldberg SM. Seton treatment of high anal fistulae. Br J Surg 1991; 78: 1159-61
65. Graf W, Pahlman L, Ejerblad S. Functional results after seton treatment of high transsphincteric anal fistulas. Eur J Surg 1995; 161: 289-91
66. McCourtney JS, Finlay IG. Cutting seton without preliminary internal sphincterotomy in management of complex high fistula-in-ano. Dis Colon Rectum 1996; 39: 55-8
67. Hämäläinen KP, Sainio AP. Cutting seton for anal fistulas: high risk of minor control defects. Dis Colon Rectum 1997; 40: 1443-6
68. García-Aguilar J, Belmonte C, Wong D, Goldberg SM, Madoff RD, Cutting seton versus two-stage seton fistulotomy in the surgical management of high anal fistula. Br J Surg 1998;85:243-5
69. Van Tets WF, Kuijpers JH. Seton treatment of perianal fistula with high anal or rectal opening. Br J Surg 1995; 82: 895-7
70. Pearl RK, Andrews JR, Orsay CP, Weisman RI, Prasad ML, Nelson RL, Cintron JR, Abcarian H. Role of seton in the management of anorectal fistulas. Dis Colon Rectum 1993; 36: 573-7
71. Hjörtrup A, Moesgaard F et al. Fibrin adhesive in the treatment of perineal fistulas. Dis Colon rectum 1991;34:752-4
72. Aitola P, Hiltunen KM, Matikainen M. Fibrin glue in perianal fistulas—a pilot study. Ann Chir Gynecol 1999;88(2);136-8
73. Venkatesh KS, Ramanujam P. Fibrin glue application in the treatment of recurrent anorectal fistulas. Dis Colon Rectum 1999; 42:1136-1139
74. Cintron JR, Park JJ, Orsay CP et al. Repair of Fistulas in ano using autologous fibrin tissue adhesive. Dis Colon Rectum 1999;42:607-13
75. Cintron JR, Park JJ, Orsay CP et al. Repair of Fistulas in ano using fibrin adhesive. Dis Colon Rectum 2000;43:944-50
76. Kronberg O. To lay open or excise a fistula-in-ano: a randomized trial. Br J Surg 1985 (72) 970
77. Belliveau P, Thomson JP, Parks AG. Fistula in ano, a manometric study. Dis Colon Rectum 1983;26:152-54
78. Lunniss PJ, Kamm MA, Phillips RKS. Factors affecting continence after surgery for anal fistula. Br J Surg 1994; 81: 1382-5
79. Van Tets WF, Kuijpers HC. Continence disorders after fistulotomy. Dis Colon Rectum 1994; 37: 1194-7

80. Garcia-Aguilar J, Belmonte C, Wong WD, Goldberg SM, Madoff RD. Anal fistula surgery: factors associated with recurrence and incontinence. Dis Colon Rectum 1996; 39: 723-9
81. Noble GH. A new operation for complete laceration of the perineum designed for the purpose of eliminating danger of infection from the rectum. Trans Am Gynecol Soc 1902; 27: 357-63
82. Elting AW. The treatment of fistula in ano with special reference to the Whitehead operation. Ann Surg 1912; 56: 744-52
83. Laird DR. Procedures used in the treatment of complicated fistulas. Am J Surg 1948; 76: 701-8
84. Oh, C. Management of high recurrent anal fistula. Surgery 1983: 93; 330-2
85. Aguilar PS, Plasencia G, Hardy TG, Hartman RF and Stewart WRC. Mucosal advancement in the treatment of anal fistula. Dis Colon Rectum 1985; 28: 496-8
86. Wedell J, Meier zu Eissen P, Banzhaf G and Kleine L. Sliding flap advancement for the treatment of high level fistulae. Br J Surg 1987; 74: 390-1
87. Kodner IJ, Mazor A, Shemesh EI, Fry RD and Fleshman JW and Birnbaum EH. Endorectal advancement flap repair of rectovaginal and other complicated anorectal fistulas. Surgery 1993; 114: 682-90
88. Ozuner G, Hull TL, Cartmill J, Fazio VW. Long-term analysis of the use of transanal rectal advancement flaps for complicated anorectal/ vaginal fistulas. Dis Colon Rectum 1996 Jan;39(1):10-4
89. Del Pino A, Nelson RL, Pearl RK, Abcarian H. Island flap anoplasty for treatment of transsphincteric fistula-in-ano. Dis Colon Rectum 1996; 39: 224-6.
90. Kohler A, Athanasiadis S. Anodermal advancement flap-plasty as alternative treatment method to endorectal closure techniques in therapy of high anal fistulas. A prospective study of 31 patients [in German]. Chirurg 1996; 67: 1244-50.
91. Robertson WG, Mangione JS. Cutaneous advancement flap closure: alternative method for treatment of complicated anal fistulas. Dis Colon Rectum 1998; 41: 884-6.
92. Jun SH, Choi GS. Anocutaneous advancement flap closure of high anal fistulas. Br J Surg 1999; 86: 490-2
93. Nelson RL, Cintron J, Abcarian H. Dermal island flap anoplasty for transsphincteric fistula in ano. Dis Colon Rectum 2000;43:681-84
94. Ratto C, Gentile E, Merico M, Spinazzola C, Mangini G, Sofo L, Doglietto G. How can the assessment of fistula-in-ano be improved? Dis Colon Rectum 2000;43:1375-1382.