

Chemokine Receptor Expression Pattern Correlates to Progression of Conjunctival Melanocytic Lesions

Jolique A. van Ipenburg,¹ Nadine E. de Waard,² Nicole C. Naus,³ Martine J. Jager,² Dion Paridaens,^{3,4} and Robert M. Verdijk^{1,4,5}

¹Department of Pathology, Erasmus University Medical Center, Rotterdam, The Netherlands

²Department of Ophthalmology, Leiden University Medical Center, Leiden, The Netherlands

³Department of Ophthalmology, Erasmus University Medical Center, Rotterdam, The Netherlands

⁴The Rotterdam Eye Hospital, Rotterdam, The Netherlands

⁵Department of Pathology, Leiden University Medical Center, Leiden, The Netherlands

Correspondence: Robert M. Verdijk, Department of Pathology, Erasmus University Medical Center, Doctor Molewaterplein 50, Rotterdam 3015 GE, The Netherlands; r.verdijk@erasmusmc.nl

Submitted: March 24, 2019

Accepted: June 10, 2019

Citation: van Ipenburg JA, de Waard NE, Naus NC, Jager MJ, Paridaens D, Verdijk RM. Chemokine receptor expression pattern correlates to progression of conjunctival melanocytic lesions. *Invest Ophthalmol Vis Sci*. 2019;60:2950-2957. <https://doi.org/10.1167/iops.19-27162>

PURPOSE. Chemokines play a role in the progression and metastatic spread of both cutaneous and uveal melanomas. The aim of this study was to examine the prognostic value of expression of chemokine receptors CCR7, CXCR4, and CCR10 in conjunctival melanocytic lesions.

METHODS. In total, 44 conjunctival nevi, 21 cases of primary acquired melanosis (PAM) with atypia and 35 conjunctival melanomas, were included. After immunohistochemical staining for CCR7, CXCR4, and CCR10 the immunoreactive score (IRS) was determined. The findings were correlated for association with melanoma and development of metastasis. For mechanistic evaluation, we used a mouse melanoma metastasis model using two human conjunctival melanoma cell lines, CM2005.1 and CRMM1.

RESULTS. All tested chemokines showed a significantly higher expression in conjunctival melanoma than conjunctival nevi. There was a statistically significant difference between the IRS in nevi and PAM with atypia for nuclear IRS in CCR10 ($P = 0.03$) and both nuclear and cytoplasmic IRS in CXCR4 ($P < 0.01$ and $P = 0.03$, respectively); this was also true evaluating the groups PAM with atypia and melanoma all together ($P < 0.01$). Furthermore, a trend for lower IRS was seen in cases of melanoma without metastasis, with a suggestive pattern of a higher IRS in cases that did develop metastases, supported for CXCR4 using the mouse melanoma metastasis model.

CONCLUSIONS. Expression of specific chemokines changes during the progression and metastatic spread of conjunctival melanocytic lesions. Differential chemokine profiles may hold prognostic value for patients with conjunctival melanomas and might be considered as a therapeutic target.

Keywords: conjunctiva, melanoma, nevus, metastatic, mouse model

Conjunctival melanomas comprise 5% of all ocular melanomas¹ and show an increase in incidence. The majority of these melanomas is derived from primary-acquired melanosis (55%), while 25% arises de novo, and a minority of the conjunctival melanomas derives from nevi.² Conjunctival melanoma is associated with morbidity due to the frequent recurrences, with a 10-year mortality rate due to metastasis up to 30% to 39% in 10 years.^{2,3} Once metastasized, there are only limited treatment options. This emphasizes the need for identification of biomarkers for early detection, prediction, and as potential treatment targets of lesions with more aggressive behavior. Many attempts have been made to predict the metastatic behavior of a conjunctival melanocytic lesion searching for prognostic parameters, including clinical and histopathologic parameters⁴ and molecular changes, such as BRAF and TERT promoter mutations.⁵ Nevertheless, the exact mechanism of metastasis has not been elucidated yet. Chemokines are thought to be involved in tumor proliferation, invasion, and angiogenicity,⁶⁻⁸ and to play an important role in the metastatic process in different types of cancer,⁹

including cutaneous and uveal melanoma.⁹⁻¹² Furthermore, chemokines play a role in inflammatory responses,^{13,14} which might be involved in tumor progression.^{14,15} Chemokine receptors are cytokine receptor-like G-linked proteins on the cell surface and are classified into four different groups, depending on the position of the cysteine residues.^{10,11,14} It is suspected that tumor cells that express specific chemokine receptors tend to migrate toward the specific organ that produces the complementary ligand.^{7,10,14,16,17} In this metastatic process, a role of a chemokine gradient is suggested^{6,18} as well as an interaction between different chemokines and their receptors, matrix metalloproteinases, VEGF, and EGFR.⁷ In melanocytic tumors, CXCR4, with its ligand CXCL12 (also known as stromal cell-derived factor 1 [SDF-1]^{7,17}), CCR7 with ligands CCL19 and CCL21,^{9,18} and CCR10 with ligand CCL27 are thought to play a role in the metastatic spread.¹⁸ So far little is known regarding chemokine receptor expression in conjunctival melanoma.³

The aim of this study was to examine the prognostic value of tumor cell expression of chemokine receptors CCR7, CXCR4,



TABLE 1. Patient Characteristics for Nevi, PAM With Atypia, and Melanoma, Respectively

	Sex M/F	Mean Age at Time of Diagnosis (y)	Mean Follow-up (y)
Nevi	20 (45%)/24 (55%)	41 (6-84)	0 (0-0)
PAM with atypia	12 (57%)/9 (43%)	63 (33-86)	5.2 (0-18.5)
Melanoma	25 (71%)/10 (29%)	64 (41-87)	4.8 (0-21.4)

and CCR10 in conjunctival melanocytic lesions, with emphasis on chemokines predicting progression toward melanoma and melanoma metastasis, in order to provide a basis for more precise selection of patients in need of follow-up.

MATERIALS AND METHODS

Tissue Samples

Formalin-fixed paraffin-embedded samples of 44 conjunctival nevi, 21 cases of PAM with moderate to severe atypia and 35 conjunctival melanomas, were collected at the Erasmus MC, Department of Pathology, The Netherlands, between 1987 and 2013. All relevant slides were revised by an ophthalmic pathologist (RVE). For every case of PAM with atypia, information about the presence of melanoma at some point in the patients' history was collected from the patient records (in The Rotterdam Eye Hospital and Erasmus MC, Rotterdam, The Netherlands) and the nationwide pathology network and registry system (PALGA). In a similar manner information about melanoma metastasis was collected. Medical Ethics Committee approval was obtained (Medisch Ethische Toetsingscommissie reference 67865). Patient characteristics are displayed in Table 1. Depending on the size of the lesion one to three representative 5-mm cores were selected from the relevant blocks of the formalin-fixed paraffin embedded material, in order to produce a tissue microarray (TMA).¹²

Immunohistochemistry (IHC) CCR7, CXCR4, and CCR10

The samples were stained using an automated IHC staining system (Ventana Benchmark ULTRA; Ventana Medical System Inc., Tucson, AZ, USA), using alkaline phosphatase method for all antibodies, as described by Van den Bosch et al.¹² In short, after deparaffinization and heat-induced antigen retrieval (CCR7, CCR10) or protease treatment (CXCR4), the tissue sections were incubated with primary mouse antibody against CCR7 for 64 minutes at 97°C (clone 150503, 1:5000; R&D Systems, Minneapolis, MN, USA), CXCR4 for 36 minutes at 97°C (clone 44716, 1:128,000; R&D Systems), and primary rabbit antibody CCR10 for 64 minutes at 97°C (ab30718, 1:400; Abcam, Cambridge, UK). The tissue was counterstained with

hematoxylin II followed by bluing reagent, according to the manufacturer's instructions. Liver, tonsil, intestinal, and breast tissue was used as a control.

For every TMA core an immunoreactive score (IRS) was determined. We first determined the intensity of the staining (absent, mild, moderate, and intense, scored as 0, 1, 2, or 3, respectively). For CCR10 and CXCR4, the intensity of the nuclear and the cytoplasmic staining was determined separately; for CCR7 only cytoplasmic staining was observed (Fig. 1). Next, the percentage of stained cells that showed the predominant intensity, was determined; no positive cells were scored as 0% and less than 10%, 10% to 50%, 51% to 80%, and more than 80% were scored as 1, 2, 3, or 4, respectively. Then, IRS was calculated by multiplying the score for percentage of stained cells with the score for the intensity of the staining. The IHC staining was evaluated by an ophthalmic pathologist (RVE), a senior pathology resident (JIP), and medical student (KBA) trained in the assessment of conjunctival lesions and IRS evaluation, using light microscopy; in case of a difference consensus was reached by joint re-evaluation. It was not possible to determine the IRS for all chemokines in every case, either due to detachment of the core during the staining procedure or due to lack of material. For the 32 cases where multiple cores per chemokine staining were available for review, the highest IRS for each case was used for further analysis. No age-related differences in staining intensity were observed.

Cell Lines

To validate our data, we used two conjunctival melanoma (CM) cell lines, CRMM-1 and CM2005.1 in an in vivo mouse metastasis model, as described by De Waard et al.¹⁹ Human CM cell line CRMM1 was established by Gordon Nareyeck (Essen, Germany; kindly provided by Michele Madigan, Sydney, Australia). CM2005.1 was established by Sander Keijser (LUMC, Leiden, The Netherlands).^{20,21} In short, the cell lines of CRMM-1 and CM2005.1 were separately administered to mice by injecting the cells into the nasal subconjunctival space. These mice developed local malignant melanocytic tumors, as confirmed by histopathology, but no metastases. The local tumor tissues were harvested and culture passages were produced. These passages were then separately administered to other mice. In addition to local tumor growth, those latter mice did develop metastases. The tissue of the orbital exenterations as well as the tissue of the metastasis was examined by light microscopy. All tissues were stained with CCR10, CCR7, and CXCR4 antibodies and the IRS was determined as described before.

Statistical Analysis

The Wilcoxon rank sum test was used to determine whether there was a statistical difference in expression of the different chemokines between the different melanocytic lesions (nevi compared with PAM with atypia, nevi versus melanoma, PAM with atypia with versus without occurrence of melanoma,

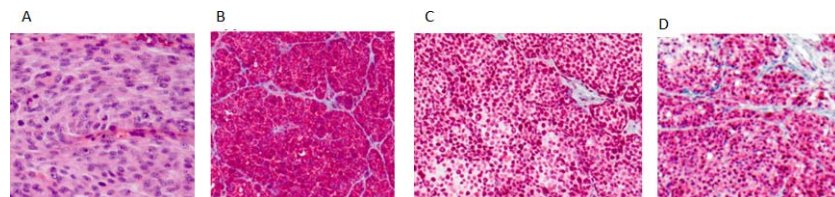


FIGURE 1. Melanoma, hematoxylin and eosin staining (A, magnification $\times 10$), immunohistochemical chemokine expression of CCR7 (B, IRS 12, magnification $\times 10$), CXCR4 (C, nuclear IRS 12, cytoplasmic IRS 8; magnification $\times 10$), and CCR10 (D, nuclear IRS 12, cytoplasmic IRS 8; magnification $\times 50$).

TABLE 2. *P* Values of the Chemokine Receptor Expression (CCR7, CCR10, CXCR4). When Comparing the Different Subgroups (Conjunctival Nevi, Primary Acquired Melanosis With Atypia [PAM+], and [Metastasized] Conjunctival Melanoma)

	CCR7	CCR10		CXCR4	
		Cytoplasm	Nuclear	Cytoplasm	Nuclear
Nevi versus PAM+	0.97	0.46	0.03	0.03	< 0.01
Nevi versus melanoma	0.02	< 0.01	0.01	< 0.01	< 0.01
PAM+ versus melanoma	0.02	0.046	0.86	0.84	0.06
Nevi versus (pre-)malignant lesions	0.10	< 0.01	< 0.01	< 0.01	< 0.01
Melanoma associated PAM+ versus not melanoma associated PAM+	1	0.52	0.92	0.51	0.15
Metastasized melanoma versus non metastasized melanoma	0.12	0.82	0.59	0.44	0.38

Bold values indicate statistical significance, $P < 0.05$.

melanoma with versus without development of metastasis and comparison of nevi versus the not benign lesions [precursor and melanoma lesions all together]). A $P < 0.05$ was considered significant.

RESULTS

Immunohistochemistry

Nevi Versus PAM With Atypia. The IRS in nevi could be determined for CCR7 in 32 cases (72%) and for CXCR4 and CCR10 in respectively 39 (89%) and 33 cases (75%). In the PAM with atypia IRS could be determined for CCR7 in 20 cases (95%), CXCR4 in 15 cases (71%), and CCR10 in 11 cases (52%). The IRS pattern of PAM with atypia showed a different chemokine receptor expression pattern when compared with the nevi group, with a nuclear IRS less than 4 only observed in nevi for both CCR10 and CXCR4. The difference between nevi and PAM with atypia was significant for nuclear IRS in CCR10 ($P = 0.03$) and both cytoplasmic and nuclear IRS in CXCR4 ($P = 0.03$ and $P < 0.01$ respectively; Table 2). CCR7 did not prove to be differentially expressed.

Nevi Versus Melanoma. For the melanoma IRS could be determined for both CCR7 and CXCR4 in 34 cases (97%) and for CCR10 in 33 cases (94%). For all tested chemokines, in general a high IRS was more frequently found in the melanoma group. For CCR7 medium to low IRS (IRS < 8) was only seen in nevi and not in the melanoma group (Fig. 2), with a significant

difference in IRS score ($P = 0.02$; Table 2). This difference in both cytoplasmic and nuclear IRS also showed statistical significance for CXCR4 and CCR10 (maximum $P = 0.01$; Table 2).

PAM With Atypia and Association With Melanoma.

Eleven (52%) of the cases of PAM with atypia were associated with melanoma. IRS could be determined in eleven (100%), eight (73%), and five (45%) cases for CCR7, CXCR4, and CCR10, respectively, with IRS determined for cases without melanoma association in nine (90%), seven (70%), and five (50%) cases for CCR7, CXCR4, and CCR10, respectively. Low to medium IRS (IRS < 9) for nuclear expression in CXCR4 was only found in the precursor lesion without melanoma association; strikingly the opposite was seen for cytoplasmic IRS for CXCR4 with more frequently a low IRS in cases that were associated with melanoma. For CCR10 only a relatively high IRS (IRS > 8) was seen for nuclear expression in cases without an association with melanoma, with a tendency of an opposite effect in the cytoplasmic IRS for CCR10 (see also Fig. 3). For CCR7 a medium to low IRS (IRS < 8) was only seen in PAM with atypia without melanoma association. However, none of these findings proved to be statistically significant (Table 2).

Melanoma and Development of Metastasis. IRS could be determined for all chemokines in all the metastasized melanoma cases ($n = 5$) and for 29 (97%), 28 (93%), and 29 (97%) nonmetastasized melanomas in CCR7, CCR10, and CXCR4, respectively. IRS 0 was only seen in cases of melanoma




FIGURE 2. Boxplots IRS chemokine receptor expression in conjunctival nevi and melanoma.

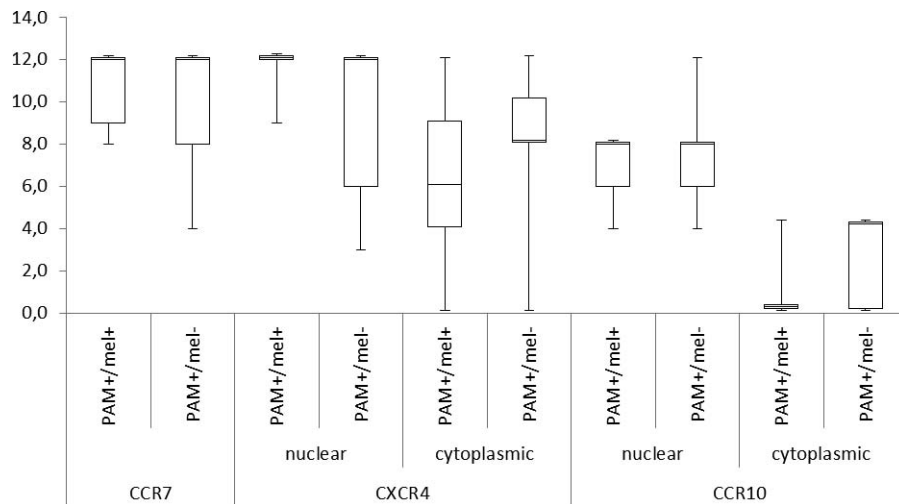


FIGURE 3. Boxplots IRS chemokine receptor expression in primary acquired melanosis with atypia (PAM+) associated with conjunctival melanoma (PAM+/mel+) and PAM+ not associated with melanoma (PAM+/mel-).

without metastasis for chemokine CXCR4 and CCR10 expression (both nuclear and cytoplasmic expression), with a suggestive pattern of high IRS in cases that did develop metastases, as was seen for CXCR4 (Fig. 4). Yet, none of these findings proved to be statistically significant. Next, we tested if we could find a differential expression pattern between the primary melanoma and the metastasized lesion, because of the theory that melanoma with high chemokine expression would be attracted to the target organ. Given the results for skin melanoma,²² one might expect a higher chemokine expression in the metastatic lesion. For none of the tested chemokines, either cytoplasmic or nuclear expression, a differential pattern was found between the chemokine expression in the primary tumor and the corresponding metastatic lesion (data not shown). In light of this discrepancy between the results for skin melanoma and conjunctival melanoma we used a mouse model to provide further insight in the mechanism of metastatic spread of conjunctival melanoma.

We also evaluated whether the above-mentioned findings for CCR10 and CXCR4 would change by taking into account

only the highest IRS, without distinction between cytoplasmic or nuclear IRS. No new insights were gained.

Cell Lines

After the first administration, both conjunctival melanoma cell lines CRMM-1 and CM2005.1 gave rise to a local subconjunctival melanoma, but none of the mice developed metastases. After culture passage and administration of these passages to new mice, both cell lines (hereafter mentioned as passaged tumor) gave rise to metastasis to the lungs. For CXCR4 there was an increased expression in the passaged tumor and the metastasized lesion relative to the primary inoculated tumor (Figs. 5, 6). We observed no further increase in chemokine receptor expression in the metastatic lesion compared with the passaged tumor. Neither of the two cell lines showed a difference in expression for CCR10 or CCR7 comparing the primary tumor, the passaged tumor, and the metastatic lesion (Figs. 5, 6).

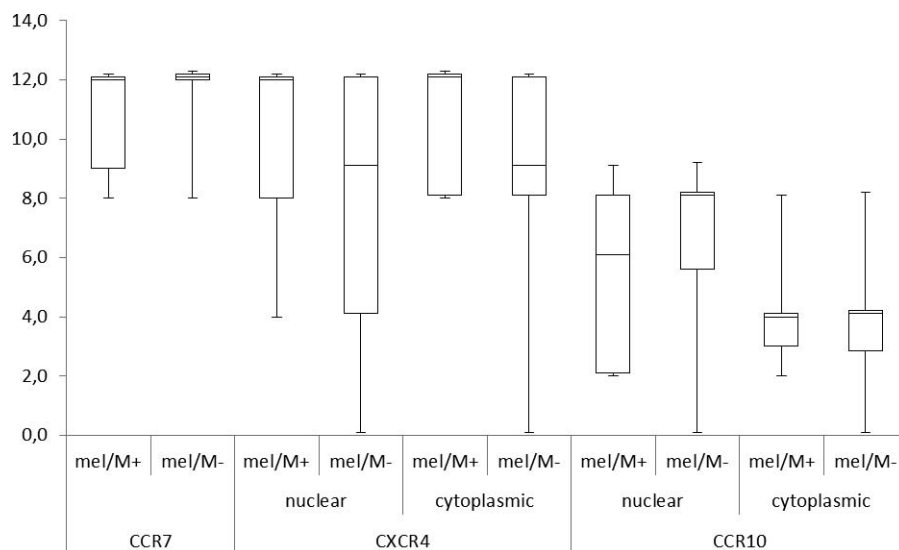


FIGURE 4. Boxplots IRS chemokine receptor expression in conjunctival melanoma with metastasis (mel/M+) and melanoma without metastasis (mel/M-).

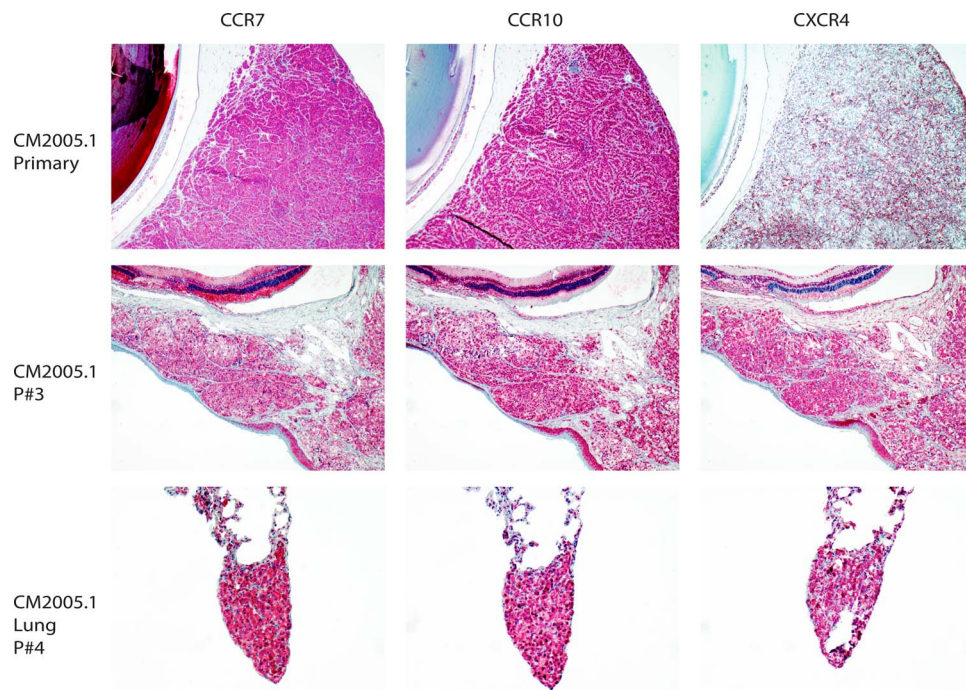


FIGURE 5. Chemokine receptor expression in the mouse metastasis model using conjunctival melanoma cell line CM2005 (*upper* and *middle* figures being the primary tumour [primary tumor and passaged tumor (P#3), respectively]) and the *lower* figures being the metastatic lesion (lung P#4), with the figures on the *left side* depicting CCR7 expression, the *middle* figures depicting CCR10 expression and on the *right side* figures depicting CXCR4 expression.

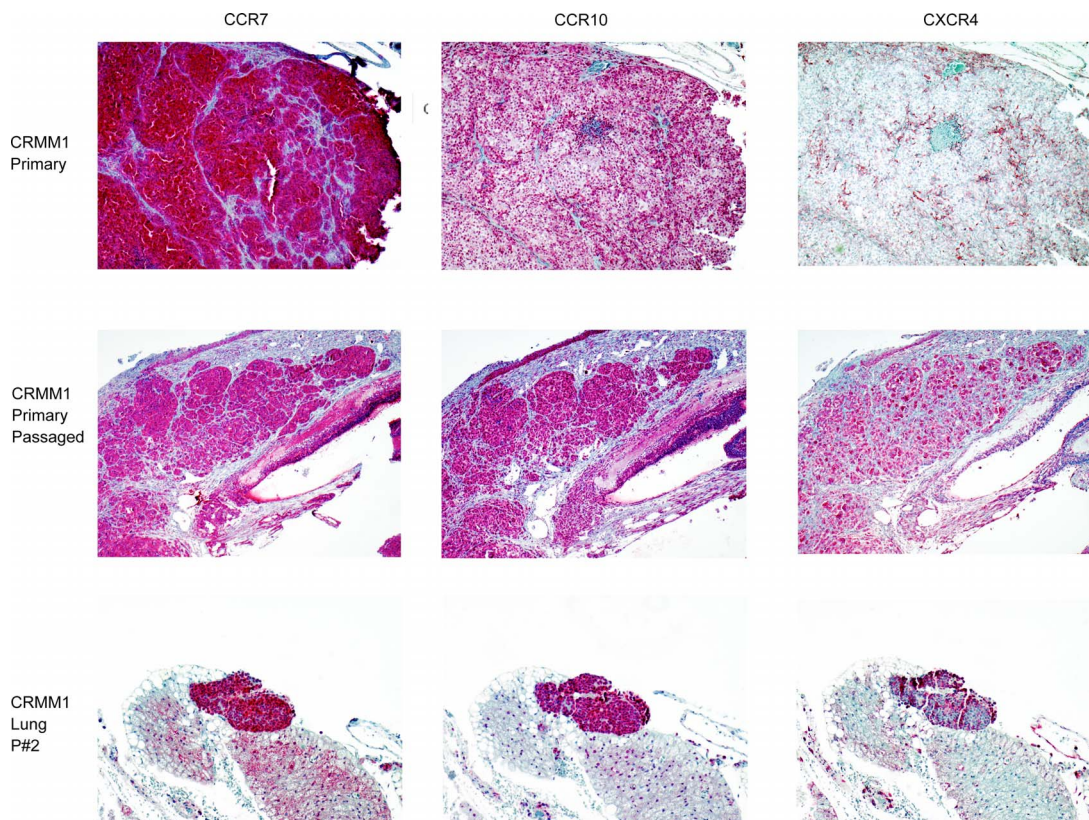


FIGURE 6. Chemokine receptor expression in the mouse metastasis model using conjunctival melanoma cell line CRMM1 (*upper* and *middle* figures being the primary tumor [primary tumor and passaged tumor (P#3), respectively]) and the *lower* figures being the metastatic lesion (lung P#4), with the figures on the *left side* depicting CCR7 expression, the *middle* figures depicting CCR10 expression and on the *right side* figures depicting CXCR4 expression.

Chemokine Expression in Human Primary Melanoma and Related Metastatic Lesions

Chemokine expression was analyzed for all described chemokines in the tissue of four patients, whose primary lesion as well as the corresponding metastatic lesion were available for analysis. The IRS was determined as described in the primary lesion and the corresponding metastasis subsequently. No specific pattern was found evaluating the IRS in the primary lesion and the corresponding metastatic lesion.

DISCUSSION

CCR10, CCR7, and CXCR4 are known to play an important role in the tumorigenesis of cutaneous melanomas.²³ Because of the resemblance of skin melanoma and conjunctival melanoma in many ways²⁴ we aimed to evaluate the prognostic value of chemokine expression in conjunctival melanocytic lesions.

In this study, we found significant differences in chemokine profile in nevi versus primary acquired melanosis with atypia and melanoma, with a low chemokine level for all tested chemokines in the nevus group. This was also true when evaluating the chemokine analysis in the nevi versus the premalignant lesions and the malignant lesions combined.

CXCR4 is known to be highly involved in the carcinogenesis of various tumors,⁹ with CXCR4/CXCL12 (SDF-1) pathway described to be involved in skin melanoma,¹⁷ colorectal cancer,²⁵ and uveal melanoma,^{26,27} among others. Binding of CXCR4 to CXCL12 induces the phosphoinositide 3-kinase (PI3K)-Akt and mitogen-activated protein kinase (MAPK) pathways^{9,14,26} resulting in tumor cell survival and migration.⁹ PI3K-Akt activation combined with the MEK pathway also induces matrix metalloproteinase expression giving rise to degradation of the extracellular matrix, while the PI3K-pathway combined with extracellular signal-regulated kinases 1/2 (ERK1/2) results in cell invasiveness. Furthermore, the production of proangiogenic factors, including VEGF, in response to CXCL12 contributes to the carcinogenic effect.⁹ Petit et al.²⁸ suggest a vicious circle with hypoxia induced by the tumor resulting in upregulation of VEGF, which not only tumor cells and tumor stroma cells, but also endothelial progenitor cells expressing and secreting SDF1, the expression of SDF-1 directly being linked to the magnitude of the hypoxia. These pathways may also explain our results concerning both cytoplasmic and nuclear IRS for CXCR4 in nevi versus (pre-)malignant lesions. Different results were found in the study of chemokine receptor expression in uveal melanoma by Van den Bosch et al.,¹² which might be explained by the difference in location and well-known involvement of other (epi)genetic factors.⁵

The CCR7/CCL21 axis is also involved in the tumor progression via the aforementioned pathways,⁹ with a high expression of CCR7 associated with an adverse prognosis in both cutaneous and uveal melanoma.¹² Therefore, one might presume that the lower the expression of CCR7 the more unlikely the cells are to migrate and invade, explaining our findings of low IRS in nevi, in contrast to the lesions with frank malignant behavior (i.e., melanoma). Furthermore, this pathway is known to be involved in attracting specific inflammatory cells toward the tumor in vicinity of CCL21 of that tumor, resulting in inhibition of the melanoma.¹⁵ Because all but one of the melanoma cases in this study ($n = 34$) did have a lymphocytic infiltrate associated with the tumor, one might expect some influence of this infiltrate on the tumor behavior. One might assume that higher expression of CCR7 of the tumor leads to higher levels of CCL21 in the environment of the tumor, thereby influencing the behavior of the tumor by

the lymphocytic infiltrate, leading to a more favorable course. We were not able to confirm this assumption with the results of our study, may be because of the influence of high (co-)expression of CXCR4, which is also suggested to play a role in tumorigenesis via lymphocyte infiltration.^{14,15}

Overexpression of CCR10 is associated with a worse prognosis, as described in cutaneous melanoma.¹⁷ Adverse behavior of melanocytic lesions with CCR10 overexpression was also found in our study.

Although clear differences were observed between the benign and the (pre-)malignant groups, no statistical differences were found when comparing PAM with atypia associated with melanoma versus PAM with atypia without association with melanoma. The relatively small sample size of the group PAM with atypia might explain this lack in statistical significance. On the other hand, PAM with atypia is interpreted by some as melanoma in situ²⁹ and only cases showing moderate to severe atypia comparable to a minimal conjunctival melanocytic intraepithelial neoplasia (C-MIN) score of 5 have been selected for this study. According to this newly proposed grading system a C-MIN score of 5 and higher can be interpreted as melanoma in situ.²⁹ In view of this, it may not be surprising that the chemokine expression between melanoma in situ and melanoma shows no statistically significant differences.

Another aim of this study was to evaluate whether it would be possible to make a prediction about the metastatic potential of a malignant lesion on the basis of chemokine expression. In this study we frequently found a high IRS for CXCR4 in lesions that did metastasize, congruent with findings in other studies where CXCR4 overexpression is said to enhance invasive capacity.^{7,11,25,30} Of particular interest is the very low IRS of CXCR4 that was seen in the cases that did not develop metastasis. This is in line with the suggestion of Ehtesham et al.³⁰ that silencing of CXCR4 could inhibit the metastatic potential of the tumor cells and the statement of CXCR4 being very important in metastatic capacity as was also confirmed in other studies.^{7,30} This also explains our finding of a higher metastatic potential of melanomas with a higher CXCR4 expression compared with melanomas with less expression of CXCR4. Although this is a suggestive pattern, in our cohort no statistical significance could be found comparing the chemokine expression in the melanomas that proved to have metastatic capacity and the melanomas without metastasis, probably because of the small group size of the metastasized group. Given these results, in combination with the results described by others in skin melanoma,²² we tested if a differential chemokine receptor expression pattern could be observed in a mouse metastasis model for conjunctival melanoma. In this model, we show that at primary inoculation the tumors that developed from the human conjunctival melanoma cell lines have low expression of CXCR4 and no metastasis were seen. In contrast, after passaging and inoculation into new mice, melanomas with high CXCR4 expression developed metastases to the lungs. This is in concordance with the known beneficial environment in the lungs for CXCR4 expressing melanoma cells.²³ Such findings were not seen for CCR7 and CCR10 and appeared to be limited to CXCR4 expression, where both nuclear and cytoplasmic expression were increased in the passaged tumor and the metastatic lesion. The increase in nuclear expression is interesting, because CXCR4 is a membranous protein. Increased nuclear expression of CXCR4 has been explained by either a mutation in CXCR4, leading to misfolding and mistranslocation of the protein or elevated levels of SDF-1 causing internalization of CXCR4, resulting in nuclear CXCR4 expression, as suggested by Wang et al.²⁵ The enhanced metastatic capacity caused by increased CXCR4 expression, and the absence of similar results for CCR10 and CCR7, might

be explained by a combined pathway with involvement of a mutation (either in SDF-1 or CXCR4) in (synergistic) combination with an alternative pathway with CXCR4 involvement. This hypothesis has yet to be explored.

Consistent with the pattern observed in the mouse model, in human tissue the chemokine expression in the primary tumor when compared with the corresponding metastatic lesion did not show further upregulation in the metastatic lesion versus the primary tumor. This finding might be due to the small sample size. Another explanation might be that evaluation of protein expression by (only) immunohistochemistry is not sensitive enough and that alterations on mRNA level have to be evaluated as well to show further upregulation of chemokine receptor expression after metastasis. Discrepancies between chemokine expression by immunohistochemical evaluation and mRNA level have been reported.^{18,31} Last, and most important, increased chemokine receptor expression in the primary tumor may be sufficient for homing to the metastatic site with no need for further upregulation upon arrival.

Although we were not able to find a statistically significant predictive chemokine expression pattern in the tumor cells that could discriminate the melanoma associated PAM with atypia from the PAM with atypia not associated with melanoma progression, we did find a significant difference when comparing the PAM with atypia and melanoma with the nevi, suggesting a clear role for CCR7, CCR10, and CXCR4 overexpression in the melanoma tumorigenesis. The mouse conjunctival melanoma metastasis model showed upregulation of CXCR4 to be related to metastatic potential of two human conjunctival melanoma cell lines. This implies that suppression of the expression of those chemokine receptors, for example by means of medication (CCR7, CCR10, and CXCR4 antagonists), might either prevent or possibly reduce the tumor progression, by influencing the tumor environment, angiogenesis, and proliferation capacity of the tumor cells, and might prevent recurrences or metastasis. Of course, this has to be examined in further studies and caution is required, given the results of Wendt et al.³² suggesting that interruption of the CXCR4-CXCL12 axis can favor metastatic disease.

CONCLUSIONS

Our results confirm the involvement of CCR7, CCR10, and CXCR4 in neoplastic melanocyte biology of the conjunctiva. Especially CCR10 and CXCR4 changes during the progression and metastatic spread of conjunctival melanocytic lesions. Differential chemokine profile may hold prognostic value for patients with conjunctival melanomas and might be considered as a therapeutic target.

Acknowledgments

The authors thank Kiran Baran, BSc, for performing the immunohistochemical stainings and IRS evaluation, Quincy C. C. van den Bosch, BSc, for making photographs of the immunohistochemical stainings and review of the manuscript, Elisa M. Barroso, PhD (Erasmus MC, Department of Pathology, The Netherlands) for her aid with the statistical analysis and Leendert H. J. Looijenga, PhD (Erasmus MC, Department of Pathology, and Princess Maxima Center for Pediatric Oncology, Utrecht, The Netherlands) for critical review of the manuscript.

Disclosure: **J.A. van Ipenburg**, None; **N.E. de Waard**, None; **N.C. Naus**, None; **M.J. Jager**, None; **D. Paridaens**, None; **R.M. Verdijk**, None

References

- Larsen AC, Dahmcke CM, Dahl C, et al. A retrospective review of conjunctival malignant melanoma presentation, treatment, and outcome and an investigation of features associated with BRAF mutations. *JAMA Ophthalmol*. 2015;133:1295–1303.
- Missotten GS, Keijser S, De Keizer RJ, De Wolff-Rouendaal D. Conjunctival melanoma in The Netherlands: a nationwide study. *Invest Ophthalmol Vis Sci*. 2005;46:75–82.
- Briceño CA, Elnor VM, Demirci H. Lymphangiogenic and chemotactic factors in conjunctival malignant melanoma. *Ophthalmic Plast Reconstr Surg*. 2016;32:428–433.
- Esmaeli B, Roberts D, Ross M, et al. Histologic features of conjunctival malignant melanoma predictive of metastasis and death (an American Ophthalmological thesis). *Trans Am Ophthalmol Soc*. 2012;110:64–73.
- Koopmans AE, Ober K, Dubbink HJ, et al. Prevalence and implications of TERT promoter mutation in uveal and conjunctival melanoma and in benign and premalignant conjunctival melanocytic lesions. *Invest Ophthalmol Vis Sci*. 2014;55:6024–6030.
- Gilbert DC, Chandler I, McIntyre A, et al. Clinical and biological significance of CXCL12 and CXCR4 expression in adult testes and germ cell tumours of adults and adolescents. *J Pathol*. 2009;217:94–102.
- Hung CS, Su HY, Liang HH, et al. High-level expression of CXCR4 in breast cancer is associated with early distant and bone metastases. *Tumour Biol*. 2014;35:1581–1588.
- Müller A, Homey B, Soto H, et al. Involvement of chemokine receptors in breast cancer metastasis. *Nature*. 2001;410:50–56.
- Mishan MA, Ahmadiankia N, Bahrami AR. CXCR4 and CCR7: two eligible targets in targeted cancer therapy. *Cell Biol Int*. 2016;40:955–967.
- Dobner BC, Riechardt AI, Jousen AM, Englert S, Bechrakis NE. Expression of haematogenous and lymphogenous chemokine receptors and their ligands on uveal malignant melanoma in association with liver metastasis. *Acta Ophthalmol*. 2012;90:e638–e644.
- Mitchell B, Mahalingam M. The CXCR4/CXCL12 axis in cutaneous malignancies with an emphasis on malignant melanoma. *Histol Histopathol*. 2014;29:1539–1546.
- Van den Bosch T, Koopmans AE, Vaarwater J, van den Berg M, de Klein A, Verdijk RM. Chemokine receptor CCR7 expression predicts poor outcome in uveal melanoma and relates to liver metastasis whereas expression of CXCR4 is not of clinical relevance. *Invest Ophthalmol Vis Sci*. 2013;54:7354–7361.
- Novak L, Igoucheva O, Cho S, Alexeev V. Characterization of the CCL21-mediated melanoma-specific immune responses and in situ melanoma eradication. *Mol Cancer Ther*. 2007;6:1755–1764.
- Neagu M, Constatin C, Longo C. Chemokines in the melanoma metastasis biomarkers portrait. *J Immunoassay Immunochem*. 2015;36:559–566.
- Gezgin G, Dogrusöz M, van Essen TH, et al. Genetic evolution of uveal melanoma guides the development of an inflammatory microenvironment. *Cancer Immunol Immunother*. 2017;66:903–912.
- Liu Y, Ji R, Li J, et al. Correlation effect of EGFR and CXCR4 and CCR7 chemokine receptors in predicting breast cancer metastasis and prognosis. *J Exp Clin Cancer Res*. 2010;29:16.
- Kühnelt-Leddihn L, Müller H, Eisendle K, Zelger B, Weinlich G. Overexpression of the chemokine receptors CXCR4, CCR7, CCR9, and CCR10 in human primary cutaneous melanoma: a potential prognostic value for CCR7 and CCR10? *Arch Dermatol Res*. 2012;304:185–193.

18. Monteagudo C, Ramos D, Pellin-Carcelen A, et al. CCL27-CCR10 and CXCL12-CXCR4 chemokine ligand- receptor expression ratio: new predictive factors of tumor progression in cutaneous malignant melanoma. *Clin Exp Metastasis*. 2012;29:625-637.
19. De Waard NE, Cao J, McGuire SP, et al. A murine model for metastatic conjunctival melanoma. *Invest Ophthalmol Vis Sci*. 2015;56:2325-2333.
20. Nareyeck G, Wuestemeyer H, von der Haar D, Anastassiou G. Establishment of two cell lines derived from conjunctival melanomas. *Exp Eye Res*. 2005;81:361-362.
21. Keijser S, Maat W, Missotten GS, de Keizer RJ. A new cell line from a recurrent conjunctival melanoma. *Br J Ophthalmol*. 2007;91:1566-1567.
22. Murakami T, Maki W, Cordones AR, et al. Expression of CXC chemokine receptor-4 enhances the pulmonary metastatic potential of murine B16 melanoma cells. *Cancer Res*. 2002;62:7328-7334.
23. Murakami T, Cardones AR, Hwang ST. Chemokine receptors and melanoma metastasis. *J Dermatol Sci*. 2004;36:71-78.
24. Cao J, Heijkants RC, Jochemsen AG, et al. Targeting of the MAPK and AKT pathways in conjunctival melanoma shows potential synergy. *Oncotarget*. 2016;8:58021-58036.
25. Wang SC, Lin JK, Wang HS, Yang SH, Li AF, Chang SC. Nuclear expression of CXCR4 is associated with advanced colorectal cancer. *Int J Colorectal Dis*. 2010;25:1185-1191.
26. Bakalian S, Marshall JC, Logan P, et al. Molecular pathways mediating liver metastasis in patients with uveal melanoma. *Clin Cancer Res*. 2008;14:951-956.
27. Di Cesare S, Marshall JC, Fernandes BF, et al. In vitro characterization and inhibition of the CXCR4/CXCL12 chemokine axis in human uveal melanoma cell lines. *Cancer Cell Int*. 2007;7:17.
28. Petit I, Jin D, Rafii S. The SDF-1-CXCR4 signaling pathway: a molecular hub modulating neo-angiogenesis. *Trends Immunol*. 2007;28:299-307.
29. Damato B, Coupland SE. Conjunctival melanoma and melanosis: a reappraisal of terminology, classification and staging. *Clin Exp Ophthalmol*. 2008;36:786-795.
30. Ehtesham M, Winston JA, Kabos P, Thompson RC. CXCR4 expression mediates glioma cell invasiveness. *Oncogene*. 2006;25:2801-2806.
31. Nikkhoo B, Jalili A, Fakhari S, et al. Nuclear pattern of CXCR4 expression is associated with a better overall survival in patients with gastric cancer. *J Oncol*. 2014;2014:808012.
32. Wendt MK, Johannesen PA, Kang-Decker N, Binion DG, Shah V, Dwinell MB. Silencing of epithelial CXCL12 expression by DNA hypermethylation promotes colonic carcinoma metastasis. *Oncogene*. 2006;25:4986-4997.