

Intrathecal baclofen as emergency treatment alleviates severe intractable autonomic dysreflexia in cervical spinal cord injury

Elmar M. Delhaas, Sander P.G. Frankema & Frank J.P.M. Huygen

To cite this article: Elmar M. Delhaas, Sander P.G. Frankema & Frank J.P.M. Huygen (2019): Intrathecal baclofen as emergency treatment alleviates severe intractable autonomic dysreflexia in cervical spinal cord injury, The Journal of Spinal Cord Medicine, DOI: [10.1080/10790268.2019.1695080](https://doi.org/10.1080/10790268.2019.1695080)

To link to this article: <https://doi.org/10.1080/10790268.2019.1695080>



© 2019 The Author(s). Published with license by Taylor & Francis Group, LLC



Published online: 09 Dec 2019.



Submit your article to this journal [↗](#)



Article views: 417



View related articles [↗](#)



View Crossmark data [↗](#)

Case Report

Intrathecal baclofen as emergency treatment alleviates severe intractable autonomic dysreflexia in cervical spinal cord injury

Elmar M. Delhaas, Sander P.G. Frankema, Frank J.P.M. Huygen

Center for Pain Medicine, Erasmus MC University Medical Center, Rotterdam, The Netherlands

Context: Episodic attacks of autonomic dysreflexia (AD) are regularly experienced by patients with a spinal cord injury (SCI) on T6 or higher levels. The episodes can result in a pounding headache, flushing, blurred vision, anxiety, a stroke, posturing, hyperthermia, retinal bleeding, seizures, myocardial ischemia, cardiac arrhythmias, and death. The observed associated bradycardia is explained as a baroreceptor reflex response to the high blood pressure. Intrathecal baclofen (ITB) has been used to treat chronic AD. This case highlights the occurrence of intractable AD after removal of the ITB delivery system because of a pump pocket infection. We describe the benefit of ITB as an emergency treatment for intractable AD.

Findings: A 53-year-old male suffered from spasticity and AD after a C5 ASI B SCI in 2002 was successfully treated with ITB for 14 years. He developed *Staphylococcus aureus* and *Pseudomonas aeruginosa* cellulitis at the orifice of his suprapubic catheter, which caused an abscess in the pump pocket. To prevent a withdrawal syndrome, the medication was reduced in three steps of 25%, and the pump was explanted. Postoperatively, he experienced severe AD and was treated with clonazepam, clonidine, and urapidil. The next day, the severely fluctuating blood pressure and pulse rate were no longer controllable with the medication. At L2-3, a temporary external intrathecal catheter for reinitiating ITB was inserted. With this treatment, the AD and the spasticity symptoms could be controlled.

Conclusion/Clinical Relevance: The case demonstrated that refractory AD could be managed with ITB in an emergency.

Keywords: Spinal cord injury, Spasticity, Intractable autonomic dysreflexia, Intrathecal baclofen, Emergency, Sympathetic storm

Introduction

Episodic attacks of autonomic dysreflexia (AD) (“sympathetic storm”) are regularly experienced by patients with a spinal cord injury (SCI) on T6 or higher levels (above the outflow to the splanchnic and renal vascular beds).^{1–5} Noxious or innocuous visceral or somatic stimuli below the SCI lesion such as bladder and bowel irritation^{1,3,6} can lead to a sudden excessive sympathetic response. Spasticity, pain, sexual activity, pregnancy, delivery, pressure sores, and iatrogenic medical procedures are also known to trigger AD.^{1,3,7} Loss of descending inhibition results in higher levels of

norepinephrine release, which is responsible for cold, pale skin vasoconstriction below the level of injury.^{3,8} The observed associated bradycardia is explained as a baroreceptor reflex response to the high blood pressure.^{2,3,6} The AD syndrome varies from silent, mild forms with diaphoresis above the lesion and piloerection to a severe, life-threatening situation.^{2,7} These attacks can happen up to 40 times a day.⁴ The episodes can result in a pounding headache, flushing, blurred vision, anxiety, a stroke, posturing, hyperthermia, retinal bleeding, seizures, myocardial ischemia, cardiac arrhythmias, and death.^{1–3} Intrathecal baclofen (ITB) has been used to treat chronic AD.^{9,10} We report the application of ITB in an emergency case of acute intractable sympathetic storm. After the approval of the medical ethics committee of Erasmus Medical

Correspondence to: Elmar M. Delhaas, Center for Pain Medicine, Erasmus MC University Medical Center, Rotterdam, The Netherlands. E-mail: e.delhaas@erasmusmc.nl

Color versions of one or more of the figures in the article can be found online at www.tandfonline.com/yscm.

Center (MEC-2017-326), we retrospectively studied the case. The requirement to obtain informed consent was waived.

Presentation of the case

A 53-year-old male suffered from spasticity and AD after a C5 ASI B SCI in 2002. Initially this complaint was controlled with oral baclofen. Due to progression of spasticity, ITB was administered after two years. For fourteen years, the patient was treated with ITB using an implanted infusion system (SynchroMed II, Medtronic Inc., Minneapolis, MN, USA). During that time, a neuropathic pain developed below the level of the SCI and morphine was added to the ITB. Complaints were again under control with intrathecal morphine of 1.2 mg/day and ITB of 192 mcg/day. More recently, the patient developed a cellulitis at the orifice of his suprapubic catheter. Initially, we started with flucloxacillin 4 g/day. After the bacteriological culture revealed both *Staphylococcus aureus* and a *Pseudomonas aeruginosa*, the antibiotic treatment was changed to piperacillin/tazobactam 16/2 g/day, and vancomycin 2g/day. The local infection quickly subsided with the antibiotic treatment, but the development of erythema and swelling around the pump in the left abdominal wall indicated that the infection had spread to the device. We feared that the abscess would force the infection to spread along the catheter to the epidural and intrathecal space in a matter of days.

Explantation of the pump was thus deemed necessary. To prevent a withdrawal syndrome, we reduced the medication in three steps by 25%. Concomitantly, as a cross titration we started with oral baclofen and transdermal fentanyl (50 mcg). As intrathecal baclofen was still administered, we started with a low oral baclofen dose of 40 mg, which was increased to 80 mg while concomitantly reducing the intrathecal administration. At day four we removed the entire device. We did not find any sign of an infection dorsally at the catheter insertion site, but we identified an abscess in the abdominal pump pocket. The day thereafter, the

patient developed episodic a severe headache, excess perspiration and piloerection in the upper part of the body, and severely varying blood pressures (BP), and pulse rates (PR), without pain, fever, respiratory insufficiency, and with except for a C-reactive protein of 73 mg/ml and an alkaline phosphatase of 135 U/l all laboratory values were normal and remained unchanged in the following days (Fig. 1). Thereby was his spasticity under control with oral baclofen and intravenous clonazepam. With a diagnosis of AD, related with a withdrawal syndrome, the patient was admitted to the ICU and initially was successfully treated with a mixture of clonazepam, clonidine and urapidil. However, the next day the clinical situation was complicated by the patient's diminished consciousness, later diagnosed as a posterior reversible encephalopathy syndrome (PRES).¹¹ The severely fluctuating BP and PR returned, and the maximum tolerable oral and intravenous substitution was insufficient to compensate for the prior highly efficient route of administration of his baclofen.

A distinct subarachnoid hemorrhage (SAH) in the left frontal lobe was identified with MRI (Fig. 2). To alleviate the AD, we inserted at L2-3 a temporary external catheter (Perifix 19G, B. Braun, Oss, The Netherlands) 30 cm intrathecal for reinitiating ITB. After a positive 50 mcg single bolus, we titrated ITB up to 240 mcg/day using a standard syringe pump. With this treatment, we could manage the AD and the spasticity symptoms. After one week, we removed the temporarily external catheter and replaced it with a definite intrathecal Ascenda catheter (Medtronic Inc., Minneapolis, MN, USA). In order to bridge the time until the pump pocket infection was cured, we temporarily connected the catheter to a subcutaneously implanted portal system (Porthales 4000, Tricumed Medizintechnik GmbH, Kiel, Germany) at the opposite site (costal 10–11 level). After a dose titration ITB up to 384 mcg/day using a CADD-Solis external pump (Smiths Medical ASD, Inc., St. Paul, MN, USA), we discharged the patient from the hospital. Ten weeks later, we removed the portal system and connected the catheter

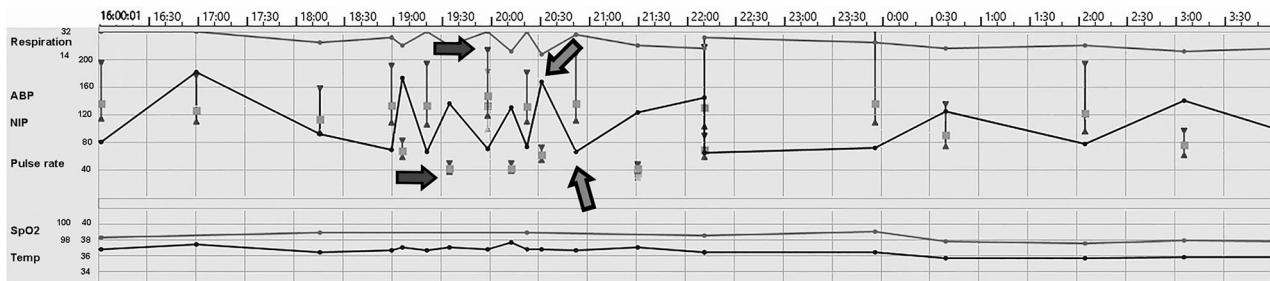


Figure 1 Autonomic Dysreflexia: Severe fluctuations in blood pressure (black arrow) and pulse rate (gray arrow).

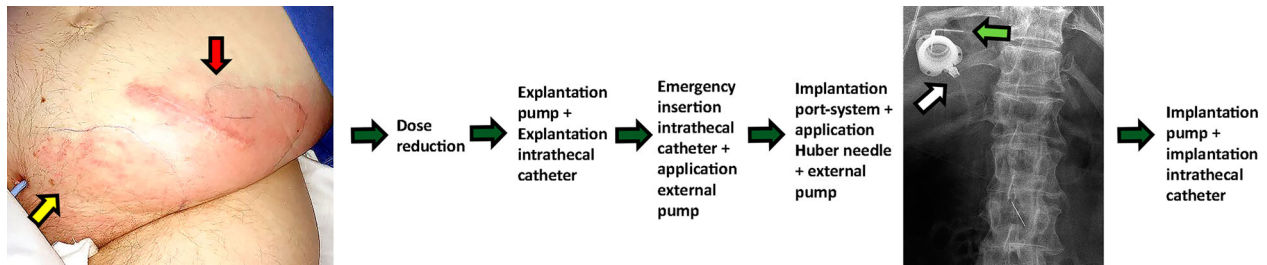


Figure 2 The approach of the treatment of the infected pump pocket (A, red arrow) as a complication of cellulitis at the orifice of a suprapubic urine catheter (A, yellow arrow). The implanted port system (B, white arrow) connected with the hardly visible Ascenda intrathecal catheter percutaneously punctured with a 90° Huber needle (B, green arrow).

to a new pump in the lower right abdominal quadrant. The patient gradually recovered from the PRES. His spasticity and AD were brought under control with ITB of 384 mcg/day, and his pain by intrathecal morphine of 1.2 mg/day.

Discussion

To our review, emergency resumption of ITB as treatment of life-threatening withdrawal syndrome with AD that has not been reported before. The cyclic character, the excessive regional perspiration, piloerection in the absence of pain and missing symptom control by an additional administered opioid, we assumed opioid withdrawal was not likely. To preempt or minimize a withdrawal syndrome,¹² we performed a cross titration initially with only oral baclofen, and later with the addition of clonazepam; furthermore, to prevent an opioid withdrawal, we used transdermal fentanyl. In our practice, we wean the intrathecal medication arbitrarily in steps of 25% while concomitantly starting oral and transdermal treatment. This manner of weaning is the compromise to prevent a withdrawal syndrome versus the potential for development of meningitis. Based on our experience, we assume the same clinical aggravation would have emerged after a slower weaning protocol. Thereby, it should be taken into consideration that the fear the abscess would force the infection to spread along the catheter to the epidural and intrathecal space in a matter of days is the reason for other physicians deciding upon the immediate removal of the implanted infusion system, thus preferring to take the risk of a withdrawal syndrome instead of the development of severe meningitis. The symptomatology, in this case, differed from the regular ITB withdrawal syndrome, as his spasticity was under control with no signs without fever, respiratory insufficiency, or a multi-organ failure. Our patient was previously diagnosed with severe AD that was successfully suppressed with ITB. The patient exhibited intractable sympathetic storms as a result of a spasticity exacerbation. Possible

confounding factors could be the cessation of intrathecal morphine and the presence of an infection, which itself could lead to an autonomic disturbance. However, AD did not occur in the previous cellulitis at the orifice of the suprapubic catheter period, but developed several days later. Per protocol, we explored the common causes of an autonomic disturbance, including bowel, bladder, and skin problems. Also, a physical examination and computed tomography did not reveal additional treatable disorders to remove the triggers. Also, to our best knowledge a relation between the presence of morphine in the ITB pump and the development of AD is unknown. A primary concern is the paucity of knowledge of the syndrome AD among caregivers⁸ and additionally the limited knowledge of ITB, in particular its value in preventing AD.^{9,10} We observed a protracted duration of the syndrome over hours, which is consistent with prior studies.^{13,14} The patient revealed an excessive fluctuating BP and PR. the patient's varying systolic BP of 90 to 155 mmHg exceeds the norm of 150 mmHg^{5,7} as well as the sudden 20–40 mmHg elevation^{7,15} and should therefore also be considered excessive. Moreover, the associated HR of 149/min was extreme. Because we could not control the clinical situation with the applied medication, we were forced to reinitiate ITB. With no sign of a local dorsal infection, clear CSF, and a CSF Gram examination that had not revealed microorganisms at the removal of the implanted device, we decided upon a catheter insertion, although we were at that time not informed about the bacterial culture. We regarded the insertion of a foreign body such as the temporary intrathecal catheter into a potentially infected area as a calculated risk for the introduction of meningitis. We considered the development of PRES and SAH as a direct complication of the frequently repeated hypertensive crises.

Based on this case, we propose that ITB infusion using a temporary intrathecal catheter during emergency situations could be possible in every hospital. In

our experience, the higher ITB dose at the end after a catheter replacement is not uncommon. We are not aware of a clear explanation. A different intrathecal catheter tip level or other ventral/lateral/dorsal position could be an option. Also, it is not excluded that the clinical situation has worsened the spasticity and AD complication, resulting in the need for a higher dose. A limitation of this study is the retrospective design and the experience in only one patient.

Conclusion/clinical relevance

The premise of the case is the rapid reintroduction of ITB (as opposed to IV and oral antispasmodics) in the setting of ITB withdrawal in particular when associated with AD to prevent complications (in this case, PRES, SAH). Further in-depth study is necessary to validate our observation.

Disclaimer statements

Contributors None.

Conflicts of Interest ED reports fees from Medtronic Inc.; FH reports grants and fees from Abbott, Grünenthal; all outside the submitted work.

References

- Eldahan KC, Rabchevsky AG. Autonomic dysreflexia after spinal cord injury: systemic pathophysiology and methods of management. *Auton Neurosci*. Jan 2018;209:59–70.
- Wan D, Krassioukov AV. Life-threatening outcomes associated with autonomic dysreflexia: a clinical review. *J Spinal Cord Med*. Jan 2014;37(1):2–10.
- Blackmer J. Rehabilitation medicine: 1. autonomic dysreflexia. *Cmaj* Oct. 28 2003;169(9):931–35.
- Hubli M, Gee CM, Krassioukov AV. Refined assessment of blood pressure instability after spinal cord injury. *Am J Hypertens*. Feb 2015;28(2):173–81.
- Kirshblum SC, House JG, O'Connor K C. Silent autonomic dysreflexia during a routine bowel program in persons with traumatic spinal cord injury: a preliminary study. *Arch Phys Med Rehabil*. Dec 2002;83(12):1774–76.
- Teasell RW, Arnold JM, Krassioukov A, Delaney GA. Cardiovascular consequences of loss of supraspinal control of the sympathetic nervous system after spinal cord injury. *Arch Phys Med Rehabil*. Apr 2000;81(4):506–16.
- Kupfer M, Kucer BT, Kupfer H, Formal CS. Persons with chronic spinal cord injuries in the emergency department: a review of a unique population. *J Emerg Med*. 2018;55(2):206–12.
- Krassioukov A, Tomasone JR, Pak M, *et al*. The ABCs of AD[®]: A prospective evaluation of the efficacy of an educational intervention to increase knowledge of autonomic dysreflexia management among emergency health care professionals. *J Spinal Cord Med*. 2016;39(2):190–96.
- Kofler M, Poustka K, Saltuari L. Intrathecal baclofen for autonomic instability due to spinal cord injury. *Auton Neurosci-Basic Clin*. Mar 2009;146(1-2):106–10.
- Vaidyanathan S, Oo T, Soni BM, Hughes PL, Severe SG. Protracted spasm of urinary bladder and autonomic dysreflexia caused by changing the suprapubic catheter in a cervical spinal cord injury patient: treatment by a bolus dose and increased total daily dose of intrathecal baclofen. *Clin Med Insights Case Rep*. 2016;9:119–121.
- Hinchey J, Chaves C, Appignani B, *et al*. A reversible posterior leukoencephalopathy syndrome. *N Engl J Med*. Feb. 22 1996;334(8):494–500.
- Saulino M, Anderson DJ, Doble J, *et al*. Best practices for intrathecal baclofen therapy: troubleshooting. *Neuromodulation*. Aug 2016;19(6):632–41.
- Popok DW, West CR, Hubli M, Currie KD, Krassioukov AV. Characterizing the severity of autonomic cardiovascular dysfunction after spinal cord injury using a novel 24 h ambulatory blood pressure analysis software. *J Neurotrauma*. Feb 2017;34(3):559–66.
- Elliott S, Krassioukov A. Malignant autonomic dysreflexia in spinal cord injured men. *Spinal Cord*. Jun 2006;44(6):386–92.
- Huang YH, Bih LI, Chen GD, Lin CC, Chen SL, Chen WW. Autonomic dysreflexia during urodynamic examinations in patients with suprasacral spinal cord injury. *Arch Phys Med Rehabil*. Sep 2011;92(9):1450–54.