

**HOSPITAL IMPLEMENTATION AND ACCEPTANCE
OF MINIMALLY INVASIVE AUTOPSY**



IVO MICHIEL WAGENSVELD

Hospital Implementation and Acceptance of Minimally Invasive Autopsy

Ziekenhuis implementatie en acceptatie van minimaal invasieve autopsie

Ivo Michiel Wagenveld

ISBN: 978-94-6380-705-0

Printed by: ProefschriftMaken

© Ivo Michiel Wagenveld

All rights reserved. No part of this publication may be reproduced in any form by any electronic or mechanical means (including photocopying, recording, or information storage and retrieval) without the prior permission of the author.

Hospital Implementation and Acceptance of Minimally Invasive Autopsy

Ziekenhuis implementatie en acceptatie van minimaal invasieve autopsie

Proefschrift

Ter verkrijging van de graad doctor aan de
Erasmus Universiteit Rotterdam
op gezag van de rector magnificus

Prof. dr. R.C.M.E Engels

En volgens besluit van het College voor Promoties.

De openbare verdediging zal plaatsvinden op 4 maart 2020 om 11:30

door

Ivo Michiel Wagenveld
geboren te Vlissingen

Promotiecommissie

Promotor:

Prof. dr. M.G.M. Hunink

Overige leden:

Prof. dr. G.P. Krestin

Prof. dr. F.J. van Kemenade

Prof. dr. V.T.H.B.M. Smit

Co-promotoren:

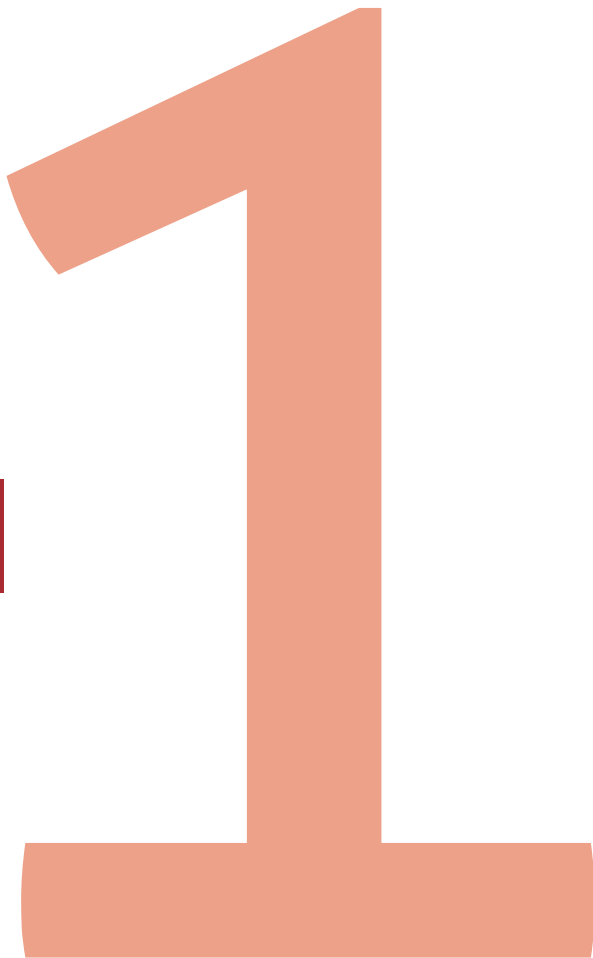Prof. dr. J.W. Oosterhuis

Dr. A.C. Weustink

Contents

Chapter 1:	General introduction	7
Chapter 2:	Non-invasive or minimally invasive autopsy compared to conventional autopsy of suspected natural deaths in adults: a systematic review	19
Chapter 3:	Total-body CT and MR features of postmortem change in in-hospital deaths	53
Chapter 4:	Conventional autopsy versus minimally invasive autopsy with postmortem MRI, CT, and CT-guided biopsy: comparison of diagnostic performance	89
Chapter 5:	Diagnostic accuracy of postmortem computed tomography, magnetic resonance imaging, and computed tomography-guided biopsies for the detection of ischaemic heart disease in a hospital setting	123
Chapter 6:	Hospital implementation of minimally invasive autopsy: a prospective cohort study of clinical performance and costs	147
Chapter 7:	Effect of minimally invasive autopsy and ethnic background on consent rate for postmortem investigation in adult deceased patients: a prospective single center before-after study	175
Chapter 8:	General discussion	193
	English summary	211
	Nederlandse samenvatting	215
	Curriculum Vitae	219
	PhD Portfolio	221
	Dankwoord	224

CHAPTER 1



General introduction

Autopsy in ancient times

The autopsy is an ancient technique for investigating the body of a deceased. Its origins go back to ancient Egyptian times. In fact, the practice of opening the body of the deceased goes back nearly to the beginning of recorded history; Egyptians started mummifying their dead as early as 3000 B.C. During mummification all internal organs, except the heart, were removed and stored apart from the body. This procedure was mainly used for religious reasons, but in-depth knowledge of the normal anatomy and by extension deviations from the normal situation were learned by this practice. (1-3) The old tradition of embalming the body led to a situation where opening the body after death was not prohibited. In Alexandria, in the third century B.C. ancient Egyptians started using autopsies not only for religious, magical and superstitious reasons but also for medical, legal and scientific purposes. (4-6)

The most famous name attributed to autopsies in the Roman empire was Galen of Pergamum (second century A.D.). Galen was a student of Hippocrates and was heavily influenced by the dominant theory that imbalances in the four humors (blood, black bile, yellow bile and phlegm) were the cause of all diseases. It is unclear if human dissection was prohibited in the Roman world, but it seems likely that social stigmas led to reluctance of autopsies on humans. This is why Galen's knowledge of anatomy in part comes from the dissection of animals. This led to some interesting erroneous ideas about human anatomy, such as the presence of holes in the interventricular septum of the heart and the existence of a rete mirabile (wonderful network) in the head of humans. (3, 6, 7)

Medieval times, the renaissance and the rise of the modern autopsy

In Medieval Europe autopsies were sporadically performed on the bodies of criminals who were sentenced to death, as a form of extra punishment after death. (8) Furthermore, dissection of the body was carried out as a means of eviscerating and dividing the body of saints to obtain relics. (9, 10) However, dissection for scientific purposes was almost unheard of in Western Europe. As a result, Galen's work remained unsurpassed until the sixteenth century A.D., when Andreas Vesalius (1514–1564), a Flemish anatomist and physician, both challenged and added to the work of Galen. In 1543, Vesalius published one of the most influential books on human anatomy 'De humani corporis fabrica' (*On the Fabric of the Human Body*). (1, 11-13)

Vesalius's dissections and those of his contemporaries were mainly performed to gain insight into human anatomy, but the autopsy as a means of understanding the process

of disease and finding the cause of death was developed and gained popularity later. (14) In the eighteenth century, famous physicians like Herman Boerhaave (1668–1732) and Giovanni Battista Morgagni (1682–1771) wrote extensive and detailed autopsy reports, describing pathological processes. The autopsy methods described by them are still very similar to those performed today. (7, 15) Marie-François-Xavier Bichat (1771–1802), and Rudolf Virchow (1821–1902) brought the autopsy one step closer to the modern-day procedure by shifting the focus from macroscopic examination of organs to microscopic evaluation of all tissues. The autopsy entered the twentieth century as a well-documented and effective procedure and reached its peak in the 1960's when roughly half of all deaths were followed by a clinical or forensic autopsy. (7)

The decline in autopsy rates

In the second half of the twentieth century the autopsy has seen a steady decline in consent rates. Worldwide autopsy rates have dropped considerably. (16, 17) In the Netherlands we have seen a decrease in autopsy rates in academic hospitals from 31% in 1977 to just about 11% in 2011, and the most recent data (presented in chapter 7 of this dissertation) suggest that the downwards trend is still ongoing. (18) The exact reason of this decline is not certain, and it seems likely that the cause is multifactorial. One likely aspect deserves mention though: there is a pervasive belief that modern diagnostic tests can accurately detect all diagnoses during life, and therefore the value of postmortem diagnostics decreases. There is no denying that advances in radiology and molecular medicine have led to spectacular improvements in medicine, and an important meta-analysis in JAMA confirmed that the chance of finding unexpected diagnoses with autopsies have indeed decreased, but the authors stress that the rate of autopsy-detected errors remains high enough (a major error rate of 8.4% to 24.4% in the USA) to still encourage the use of autopsies. (19, 20)

Attitudes towards the autopsy have varied widely since the early days of autopsy and are strongly influenced by the dominating religious, cultural and political discourse. Although most religious scriptures such as the Bible and the Quran do not specifically prohibit autopsy, many religious people feel that the integrity of the body should remain intact after death and the body needs to be buried as soon as possible (usually within 24 hours). Therefore, delays in funerary practices can cause restraints in autopsy acceptance. (21–23) This is a possible reason for denying autopsy consent, although it doesn't accurately explain the decline in autopsy rates, since the proportion of religious people has not increased in the period when autopsies were declining globally. However, because around 38% of Rotterdam's inhabitants are of a non-western ethnic background, and these ethnic groups very rarely give consent for autopsy, post-mortem diagnostics are only performed

in a low percentage of cases. (24) This subsequently leads to a lack in mortality statistics for this specific ethnic group.

Ultimately, if nothing is done, it seems likely that the declining trend will continue and eventually the practice might go all but extinct. One strategy to turn the tide for the autopsy is to find alternative methods that might be more acceptable for next-of-kin, such as imaging based autopsy methods. In the next section we will look at autopsy methods that use radiologic modalities. These methods are less invasive than a conventional autopsy and therefore it seems likely that they are more acceptable for next-of-kin.

Imaging based autopsy techniques

Plain radiography has been used since shortly after its discovery in forensic autopsies for diagnosing skeletal pathology and locating metallic foreign objects. (25) Furthermore plain X-ray imaging is used for postmortem coronary angiography in clinical autopsies. (26) Ultrasound based autopsies have been used in an experimental setting, but more advanced imaging methods like computed tomography (CT) and magnetic resonance imaging (MRI) for scanning larger parts of the body were initially used primarily in the forensic field. CT was the method of choice for a long period in the forensic setting, but since the nineties, when MRI became more advanced, quicker and more available, MRI has been used in postmortem forensic practice as well. (25, 27-37) Note that these imaging based autopsies were only used in combination with conventional autopsy and the purpose was not to replace autopsy, but only to complement its findings, and thus improve the overall process of post-mortem examination. (38)

The use of imaging in forensic autopsies provided an opening for clinical autopsy practice to start investigating postmortem radiology. Clinical and forensic postmortem radiology are two different specialties though: in forensic radiology the main objective is to find if and how a crime was committed, whereas clinical postmortem radiology focuses mainly on the pathologic processes that have led to the death of a patient. Furthermore, forensic cases vary widely in location where the body is found, postmortem time interval (i.e. the time between death and autopsy or other postmortem examination), and mechanism of death. In contrast most clinical autopsy cases died in the hospital, postmortem time interval is always relatively short, and the cause of death is nearly always natural.

Because of its ease of use, low cost and availability postmortem CT (Figure 1) has seen more use in postmortem radiology in adults than MRI. The strength of CT is its exceptional spatial resolution, which makes it an excellent diagnostic tool for skeletal pathologies and all pathologies where abnormal air is seen (e.g. pneumothorax). (39) As a quick

postmortem diagnostic test it suffices, but native (non-contrast-enhanced) CT lacks the soft-tissue contrast necessary to diagnose several common causes of death, most notably myocardial infarction. Therefore, the use of only native CT is generally not considered as a viable alternative to conventional autopsy. (38, 40-42)

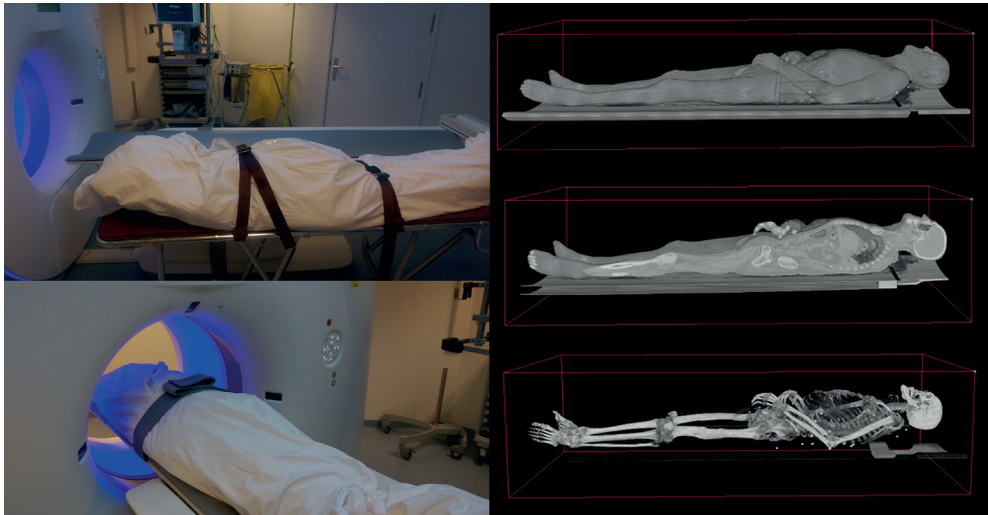


Figure 1: Postmortem computed tomography

An option to improve the performance of a CT-based autopsy method is to add CT-guided biopsies to the procedure. This provides the possibility to perform histological examination of lesions that are found on CT, which leads to a big improvement in diagnostic performance. Some studies have even investigated autopsy methods that used tissue biopsies, without any form of imaging and found an agreement for the cause of death with the conventional autopsy of 60%. (43)

Postmortem computed tomography angiography (CTA) has to deal with the limitation that upon death the heart stops pumping blood, and therefore contrast agent cannot be simply injected into the blood stream. Several techniques have been developed to distribute contrast agent after death: both total-body CTA, using a pump to replace the heart function to create a form of alternative circulation, and local CTA methods (figure 2), which utilize a standard contrast infusion pump (similar to those used in clinical radiology) to inject contrast into a specific region of interest, such as the coronaries. (44, 45) Postmortem CTA has the advantage that it can reliably diagnose pathology of the blood vessels and therefore performs much better than native CT in finding the correct cause of death. (46, 47)

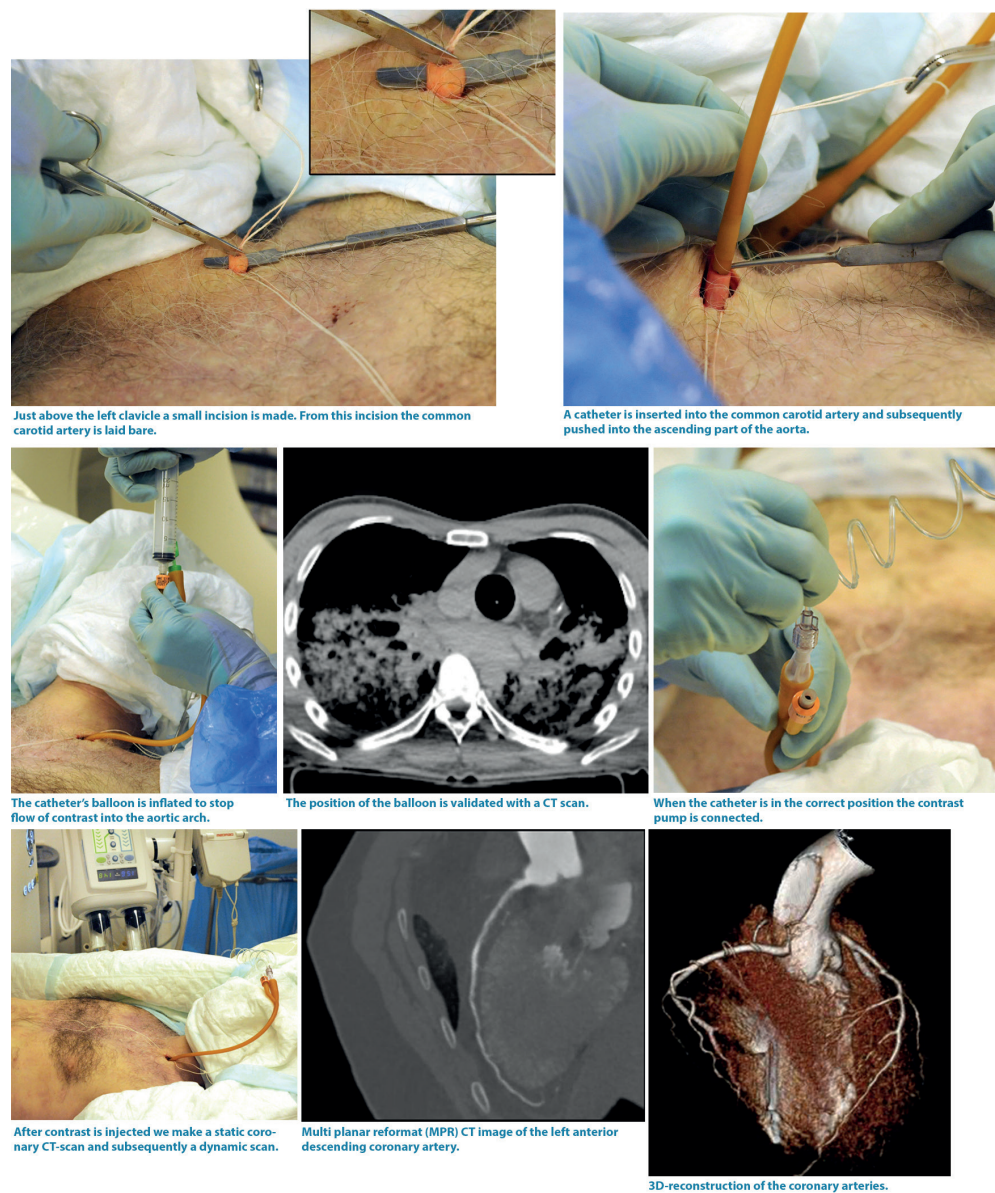


Figure 2: Coronary CTA with local administration of contrast agent

Postmortem MRI has the benefit that it has good soft-tissue contrast. In perinatal and pediatric deaths, postmortem MRI is already widely used. In fact, perinatal postmortem MRI was the first major use of postmortem radiology in the clinical setting and still constitutes the majority of all clinical postmortem scans. Its performance in fetuses, newborns and infants is on equal footing with conventional autopsy, but in older children conventional

autopsy outperforms MRI. (48-51) The performance of MRI for diagnosing causes of death and major diagnoses in adults is fairly good, but MRI is more expensive, and scanning takes much more time than CT. Furthermore, because the body temperature quickly drops after death, scan parameters need to be adjusted to account for different T1 and T2 relaxation times of tissues. (52-55)

The minimally invasive autopsy in Erasmus Medical Center Rotterdam

CT and MRI both have their strengths and limitations as diagnostic tools. Both methods have been used extensively in forensic medicine and to a lesser extent in clinical postmortem radiology. In the Erasmus Medical Center, we investigated a minimally invasive autopsy (MIA) method combining CT, MRI and CT-guided biopsies. (39, 56)

In this thesis I systematically review data from previously published studies on postmortem radiology in the hospital setting (chapter 2). In the next chapter I discuss the changes in the body that occur after death of which the clinical radiologist needs to be aware (chapter 3). In the next section we take a closer look at the diagnostic performance of MIA for establishing cause of death compared to the conventional autopsy (chapter 4), for diagnosing acute and chronic myocardial infarction (chapter 5), and at the performance of CT and MRI separately for finding major diagnoses and answering clinical questions (chapter 6). In chapter 7 we go back to the original hypothesis for our study: that minimally invasive autopsy will lead to an increase in autopsy rates and is more acceptable for next-of-kin, especially those of non-western ethnicity.

References

1. Burton J. A Bite Into the History of the Autopsy: From Ancient Roots to Modern Decay. *Forensic Science*. 2005;1.
2. Cambridge: Cambridge University Press. *Egyptian Mummies and Modern Science*. 2008.
3. Risse GB. The greatest benefit to mankind: a medical history of humanity from antiquity to the present. *Med Hist*. 1999;43(3):396-7.
4. von Staden H. The discovery of the body: human dissection and its cultural contexts in ancient Greece. *Yale J Biol Med*. 1992;65(3):223-41.
5. Bay NS-Y, Bay B-H. Greek anatomist herophilus: the father of anatomy. *Anat Cell Biol*. 2010;43(4):280-3.
6. Cecchetto G, Bajanowski T, Cecchi R, Favretto D, Grabherr S, Ishikawa T, et al. Back to the Future - Part 1. The medico-legal autopsy from ancient civilization to the post-genomic era. *International Journal of Legal Medicine*. 2017;131(4):1069-83.
7. King LS, Meehan MC. A history of the autopsy. A review. *Am J Pathol*. 1973;73(2):514-44.
8. Bliquez LJ, Kazhdan A. Four testimonia to human dissection in byzantine times. *Bulletin of the History of Medicine*. 1984;58(4):554-7.
9. Williams H. Remembering and Forgetting the Medieval Dead. In: Williams H, editor. *Archaeologies of Remembrance: Death and Memory in Past Societies*. Boston, MA: Springer US; 2003. p. 227-54.
10. Lees JT. Medieval Death: Ritual and Representation. *History: Reviews of New Books*. 1997;25(4):176-7.
11. Park K. The Life of the Corpse: Division and Dissection in Late Medieval Europe. *Journal of the History of Medicine and Allied Sciences*. 1995;50(1):111-32.
12. Dada MA, Ansari NA. Origins of the postmortem examination in diagnosis. *Journal of Clinical Pathology*. 1996;49(12):965.
13. Martin G. The death of Henry II of France: A sporting death and post-mortem. *ANZ Journal of Surgery*. 2001;71(5):318-20.
14. Kivelä T, Pelkonen R, Oja M, Heiskanen O. Diabetes Insipidus and Blindness Caused by a Suprasellar TumorPieter Pauw's Observations From the 16th Century. *JAMA*. 1998;279(1):48-50.
15. Morgagni on hospitals and autopsies. *Bull NY Acad Med*. 1975;51(10):1202-.
16. Shojania KG, Burton EC. The Vanishing Nonforensic Autopsy. *New England Journal of Medicine*. 2008;358(9):873-5.
17. Turnbull A, Osborn M, Nicholas N. Hospital autopsy: Endangered or extinct? *J Clin Pathol*. 2015;68(8):601-4.
18. Blokker BM, Weustink AC, Hunink MGM, Oosterhuis JW. Autopsy rates in the Netherlands: 35 years of decline. *PLOS ONE*. 2017;12(6):e0178200.
19. Shojania KG, Burton EC, McDonald KM, Goldman L. Changes in Rates of Autopsy-Detected Diagnostic Errors Over TimeA Systematic Review. *JAMA*. 2003;289(21):2849-56.

20. European Society of R. The future role of radiology in healthcare. *Insights Imaging*. 2010;1(1):2-11.
21. Al-Adnani M, Scheimberg I. How can we improve the rate of autopsies among Muslims? *BMJ*. 2006;332(7536):310.
22. Geller SA. Religious attitudes and the autopsy. *Arch Pathol Lab Med*. 1984;108(6):494-6.
23. Gatrad AR. Muslim customs surrounding death, bereavement, postmortem examinations, and organ transplants. *BMJ*. 1994;309(6953):521.
24. Allecijfers.nl. Informatie gemeente Rotterdam 2019, August 8 [Available from: <https://allecijfers.nl/gemeente/rotterdam/>].
25. Hughes N, Baker M. The use of radiography in forensic medicine. *Radiography*. 1997;3(4):311-20.
26. Smith M, Trummel DE, Dolz M, Cina SJ. A simplified method for postmortem coronary angiography using gastrograffin. *Arch Pathol Lab Med*. 1999;123(10):885-8.
27. Uchigasaki S, Oesterhelweg L, Gehl A, Sperhake JP, Puschel K, Oshida S, et al. Application of compact ultrasound imaging device to postmortem diagnosis. *Forensic Sci Int*. 2004;140(1):33-41.
28. Uchigasaki S, Oesterhelweg L, Sperhake JP, Puschel K, Oshida S. Application of ultrasonography to postmortem examination. Diagnosis of pericardial tamponade. *Forensic Sci Int*. 2006;162(1-3):167-9.
29. Charlier P, Chaillot P-F, Watier L, Ménétrier M, Carlier R, Cavard S, et al. Is post-mortem ultrasonography a useful tool for forensic purposes? *Medicine, Science and the Law*. 2013;53(4):227-34.
30. Thali MJ, Schwab CM, Tairi K, Dirnhofer R, Vock P. Forensic radiology with cross-section modalities: spiral CT evaluation of a knife wound to the aorta. *J Forensic Sci*. 2002;47(5):1041-5.
31. Bolliger SA, Thali MJ, Ross S, Buck U, Naether S, Vock P. Virtual autopsy using imaging: bridging radiologic and forensic sciences. A review of the Virtopsy and similar projects. *Eur Radiol*. 2008;18(2):273-82.
32. Flach PM, Schroth S, Schweitzer W, Ampanozi G, Slotboom J, Kiefer C, et al. Deep Into the Fibers! Postmortem Diffusion Tensor Imaging in Forensic Radiology. *Am J Forensic Med Pathol*. 2015;36(3):153-61.
33. Jackowski C, Wyss M, Persson A, Classens M, Thali MJ, Lussi A. Ultra-high-resolution dual-source CT for forensic dental visualization-discrimination of ceramic and composite fillings. *Int J Legal Med*. 2008;122(4):301-7.
34. Oliva A, Polacco M, D'Alessio P, Filograna L, Tartaglione T, Zobel B, et al. Will virtual autopsy technology replace the role of forensic pathologist in the future? *Am J Forensic Med Pathol*. 2011;32(4):e17-8.
35. Wilhelm M, Bolliger SA, Bartsch C, Fokstuen S, Grani C, Martos V, et al. Sudden cardiac death in forensic medicine - Swiss recommendations for a multidisciplinary approach. *Swiss Med Wkly*. 2015;145:w14129.

36. Yen K, Lovblad KO, Scheurer E, Ozdoba C, Thali MJ, Aghayev E, et al. Post-mortem forensic neuroimaging: correlation of MSCT and MRI findings with autopsy results. *Forensic Sci Int.* 2007;173(1):21-35.
37. Zech WD, Jackowski C, Schwendener N, Brencicova E, Schuster F, Lombardo P. Postmortem CT versus forensic autopsy: frequent discrepancies of tracheobronchial content findings. *Int J Legal Med.* 2015.
38. Blokker BM, Wagensveld IM, Weustink AC, Oosterhuis JW, Hunink MG. Non-invasive or minimally invasive autopsy compared to conventional autopsy of suspected natural deaths in adults: a systematic review. *Eur Radiol.* 2016;26(4):1159-79.
39. Weustink AC, Hunink MG, van Dijke CF, Renken NS, Krestin GP, Oosterhuis JW. Minimally invasive autopsy: an alternative to conventional autopsy? *Radiology.* 2009;250(3):897-904.
40. Westphal SE, Apitzsch J, Penzkofer T, Mahnken AH, Knuchel R. Virtual CT autopsy in clinical pathology: feasibility in clinical autopsies. *Virchows Arch.* 2012;461(2):211-9.
41. Takahashi N, Higuchi T, Shiotani M, Hirose Y, Shibuya H, Yamanouchi H, et al. The effectiveness of postmortem multidetector computed tomography in the detection of fatal findings related to cause of non-traumatic death in the emergency department. *Eur Radiol.* 2012;22(1):152-60.
42. Roberts IS, Benamore RE, Benbow EW, Lee SH, Harris JN, Jackson A, et al. Post-mortem imaging as an alternative to autopsy in the diagnosis of adult deaths: a validation study. *Lancet.* 2012;379(9811):136-42.
43. Huston BM, Malouf NN, Azar HA. Percutaneous needle autopsy sampling. *Modern pathology : an official journal of the United States and Canadian Academy of Pathology, Inc.* 1996;9(12):1101-7.
44. Roberts IS, Traill ZC. Minimally invasive autopsy employing post-mortem CT and targeted coronary angiography: evaluation of its application to a routine Coronal service. *Histopathology.* 2014;64(2):211-7.
45. Robinson C, Barber J, Amoroso J, Morgan B, Rutty G. Pump injector system applied to targeted post-mortem coronary artery angiography. *Int J Legal Med.* 2013;127(3):661-6.
46. Roberts IS, Benamore RE, Peebles C, Roobottom C, Traill ZC. Technical report: diagnosis of coronary artery disease using minimally invasive autopsy: evaluation of a novel method of post-mortem coronary CT angiography. *Clin Radiol.* 2011;66(7):645-50.
47. Ross SG, Bolliger SA, Ampanozi G, Oesterhelweg L, Thali MJ, Flach PM. Postmortem CT angiography: capabilities and limitations in traumatic and natural causes of death. *Radiographics.* 2014;34(3):830-46.
48. Breeze AC, Cross JJ, Hackett GA, Jessop FA, Joubert I, Lomas DJ, et al. Use of a confidence scale in reporting postmortem fetal magnetic resonance imaging. *Ultrasound Obstet Gynecol.* 2006;28(7):918-24.
49. Cohen MC, Paley MN, Griffiths PD, Whitby EH. Less invasive autopsy: benefits and limitations of the use of magnetic resonance imaging in the perinatal postmortem. *Pediatr Dev Pathol.* 2008;11(1):1-9.

50. Huisman TA. Magnetic resonance imaging: an alternative to autopsy in neonatal death? *Semin Neonatol*. 2004;9(4):347-53.
51. Thayyil S, Sebire NJ, Chitty LS, Wade A, Chong W, Olsen O, et al. Post-mortem MRI versus conventional autopsy in fetuses and children: a prospective validation study. *Lancet*. 2013;382(9888):223-33.
52. Michaud K, Grabherr S, Jackowski C, Bollmann MD, Doenz F, Mangin P. Postmortem imaging of sudden cardiac death. *Int J Legal Med*. 2014;128(1):127-37.
53. Ruder TD, Bauer-Kreutz R, Ampanozi G, Roskopf AB, Pilgrim TM, Weber OM, et al. Assessment of coronary artery disease by post-mortem cardiac MR. *Eur J Radiol*. 2012;81(9):2208-14.
54. Thayyil S, Chandrasekaran M, Chitty LS, Wade A, Skordis-Worrall J, Bennett-Britton I, et al. Diagnostic accuracy of post-mortem magnetic resonance imaging in fetuses, children and adults: a systematic review. *Eur J Radiol*. 2010;75(1):e142-8.
55. Kobayashi T, Isobe T, Shiotani S, Saito H, Saotome K, Kaga K, et al. Postmortem magnetic resonance imaging dealing with low temperature objects. *Magn Reson Med Sci*. 2010;9(3):101-8.
56. Blokker BM, Weustink AC, Wagensveld IM, von der Thüsen JH, Pezzato A, Dammers R, et al. Conventional Autopsy versus Minimally Invasive Autopsy with Postmortem MRI, CT, and CT-guided Biopsy: Comparison of Diagnostic Performance. *Radiology*. 2018;289(3):658-67.

CHAPTER 2



Non-invasive or minimally invasive autopsy compared to conventional autopsy of suspected natural deaths in adults: a systematic review

Britt M Blokker, Ivo M Wagenveld, Annick C Weustink, J Wolter Oosterhuis,
MG Myriam Hunink

Objectives

Autopsies are used for healthcare quality control and improving medical knowledge. Because autopsy rates are declining worldwide, various non-invasive or minimally invasive autopsy methods are now being developed. To investigate whether these might replace the invasive autopsies conventionally performed in naturally deceased adults, we systematically reviewed original prospective validation studies.

Materials and methods

We searched six databases. Two reviewers independently selected articles and extracted data. Methods and patient groups were too heterogeneous for meaningful meta-analysis of outcomes.

Results

Sixteen of 1538 articles met our inclusion criteria. Eight studies used a blinded comparison; ten included less than 30 appropriate cases. Thirteen studies used radiological imaging (seven dealt solely with non-invasive procedures), two thoracoscopy and laparoscopy, and one sampling without imaging. Combining CT and MR was the best non-invasive method (agreement for cause of death: 70%, 95%CI: 62.6; 76.4), but minimally invasive methods surpassed non-invasive methods. The highest sensitivity for cause of death (90.9%, 95%CI: 74.5; 97.6, suspected duplicates excluded) was achieved in recent studies combining CT, CT-angiography and biopsies.

Conclusion

Minimally invasive autopsies including biopsies performed best. To establish a feasible alternative to conventional autopsy and to increase consent to post-mortem investigations, further research in larger study groups is needed.

Introduction

Current problem and background

Autopsy is an age-old method for identifying the underlying pathology leading to death, and/ or for detecting unnatural deaths. It is an important tool for both criminal investigations and for health care quality control. In clinical practice, autopsy contributes to medical knowledge, medical training, accurate mortality statistics, epidemiologic databases, and therapeutic and diagnostic improvements (1-3).

Despite continuing development of innovative new diagnostic techniques, there are substantial discrepancies between ante-mortem and post-mortem diagnoses (4-11). Hence, autopsy continues to provide medical professionals with valuable feedback on provided care and possibly new insights for future decision-making. In some cases it also leads to counselling advice for family members.

Clinical autopsy rates are rapidly declining worldwide (12-14). To perform clinical autopsies, consent from next of kin is obligatory in most countries. Unfortunately, consent may not be requested or recommended by physicians (who are often junior staff members) and is often refused by bereaved families (15-25). Public resistance to autopsies has increased over the years, due to negative press attention (26), funeral delay, religious or cultural beliefs, and fear of mutilation of the deceased's body. For the latter reason, non-invasive or minimally invasive autopsy methods, which were already implemented in forensic medicine, are currently being developed to substitute clinical invasive autopsies (12; 13; 26).

Over the last decades, MR imaging has been introduced in clinical medicine for perinatal and neonatal autopsy (27; 28). Many other clinically established imaging techniques have emerged for broad post-mortem use in forensic medicine. Among these are image-guided tissue biopsies, and CT- or MR- angiography (29-34). Forensic specialists have optimized them for postmortem settings. However, despite high diagnostic performance in that field, hardly any of the new post-mortem techniques have been implemented in clinical medicine.

Purpose

In this systematic review we investigate whether non-invasive or minimally invasive autopsy methods could replace conventional autopsy in adults with a suspected natural cause of death. We calculate the sensitivity and agreement of non-invasive and minimally invasive autopsy methods using conventional autopsy as reference standard, and discuss if any method may be appropriate for a clinical setting.

Materials and methods

For this systematic review the methods of Cochrane and PRISMA were used to the extent possible (35; 36).

Database search

Together with a biomedical information specialist we searched the Embase, Medline, Web of Science and Cochrane databases. We defined search terms for Embase and, from those, we derived search terms for the other databases. The search terms included the following elements: autopsy, imaging, cause of death and validation (see appendix 1). Case reports, studies on children and animal studies were excluded. The search was performed on the 16th of July 2013 and, to see if any eligible articles had been published since the previous searches, repeated on the 1st of April 2014 and on the 27th of June 2014. The second and third time we also searched PubMed publisher and Google Scholar. EndNote software was used to collect all articles matching the search terms and to remove duplicate records of the same study.

Article selection

The following inclusion criteria were used for article selection: (1) original prospective studies comparing the diagnostic performance of non-invasive or minimally invasive autopsy methods to that of the reference standard (conventional autopsy, not necessarily including brain autopsy); (2) outcomes defined in agreement and/or sensitivity and/or specificity of cause of death and/or detected overall, major and/or minor diagnostic findings; (3) the alternative autopsy methods covered at least an investigation of the deceased's thorax and abdomen; (4) more than five adult cases (≥ 18 years of age) were studied; (5) more than five presumed natural deaths were studied.

Two reviewers excluded the articles outside the scope of this review, based on the article titles and abstracts. Subsequently, they retrieved and evaluated the available full texts of the remaining articles and selected the articles that fully met the five inclusion criteria. A third reviewer was consulted in case the two reviewers disagreed on study eligibility.

Data extraction and analysis

Four reviewers were involved in the analyses, of which two were already for decades involved in research and scientific publication. Two reviewers independently performed the data extraction. Their interpretation was different with respect to one or two minor data points per table and these differences could easily be resolved. A third reviewer was

consulted for advice on structuring the data extraction tables. Per article the reviewers extracted data on study population, number of cases eligible for this review, study design/methods, cost of the methods, and, if possible, data for outcomes in 2x2 tables. From these 2x2 tables on cause of death and/or (overall, major and/or minor) diagnostic findings both reviewers independently calculated the percentage of agreement, the sensitivity and if possible the specificity. If they were not able to extract any false positives and/or true negatives, the reviewers only calculated sensitivity. If the reviewers could not extract any data from the original article for a 2x2 table, the reported outcome measures were quoted. If necessary the reviewers contacted the authors, requesting additional information in order to exclude individual cases (based on age or suspected forensic cause of death) in the articles (37-42), or to identify multiple reports of the same cases (40; 41; 43; 44). Unfortunately, only one author responded (39).

The alternative autopsy methods applied and the case characteristics in the included studies were very heterogeneous, precluding meaningful meta-analysis of the study outcomes.

The outcomes of only two studies were pooled, since these studies seemed to be performed by the same research group, investigating the same alternative autopsy method, and even including some of the same cases (43; 44).

Results

All database searches together provided us with 1538 articles that matched the search criteria (see figure 1), of which 51 were considered potentially relevant (see appendix 2). One of these articles could not be obtained via our hospital library. Of the remaining 50 articles 34 were not eligible for this systematic review upon reading the full text.

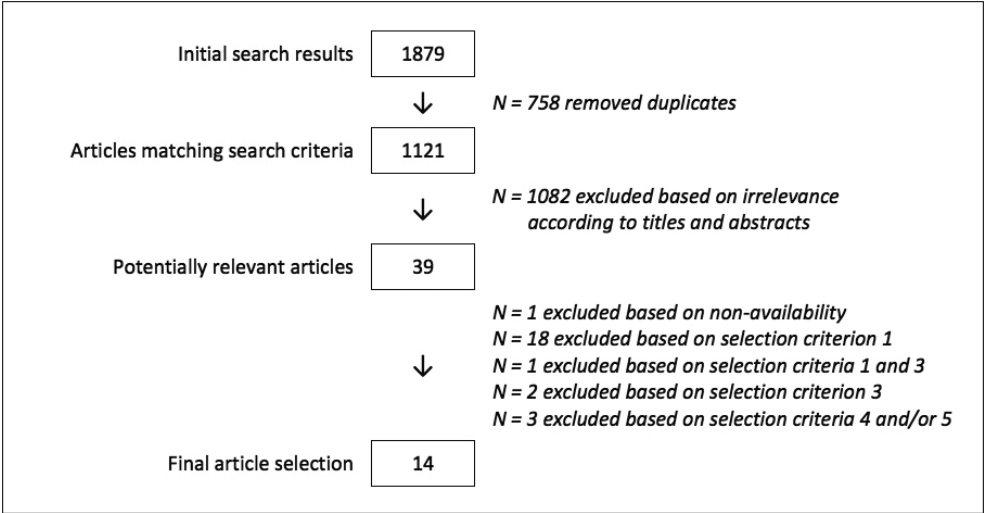


Figure 1a: Flowchart article selection: Initial literature search

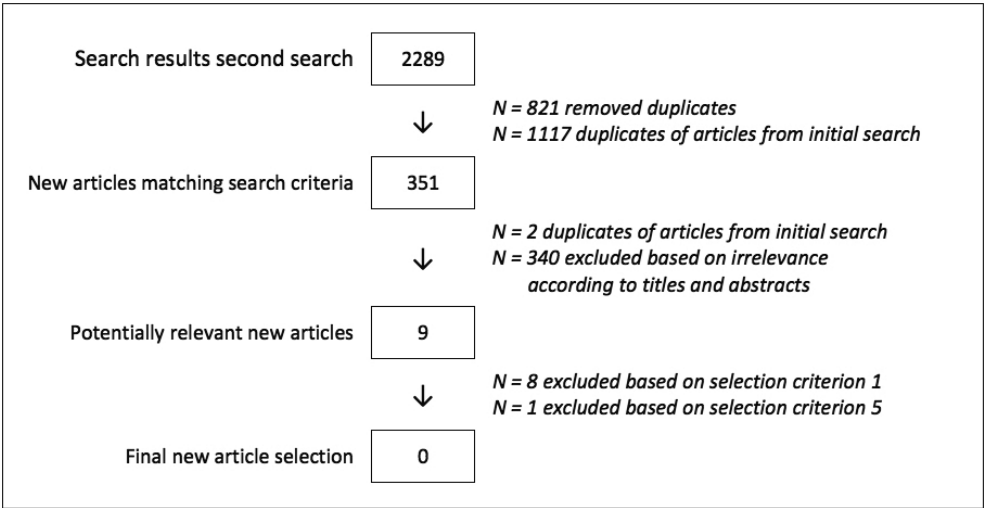


Figure 1b: Flowchart article selection: Second literature search

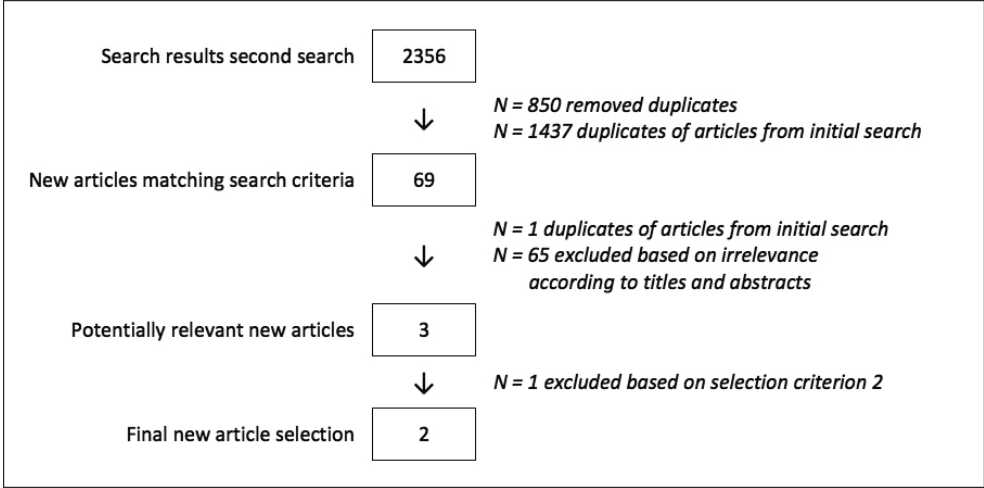


Figure 1c: Flowchart article selection: Third literature search

Study design and quality appraisal

Sixteen articles, published from 1996 to 2014, met the five inclusion criteria (see tables 1-3). Eight studies included just cases of adult deaths (37; 45-51), and in seven studies the cases were only included if the cause of death was suspected to be natural (39; 42 ; 44; 46-48; 52). Among the studies that registered a male-female ratio, the majority of cases was male. The available mean ages differed from 22.7 years to 74.0 years. Seven studies examined the accuracy of non-invasive autopsy methods, and nine studies the accuracy of various minimally invasive methods. In twelve studies a conventional autopsy (reference standard) was performed on all cases within the examined group (37; 40-44; 46-49; 51; 52). In only eight studies the description of the comparison between new method and reference standard could be interpreted as blind (40; 41; 45-48; 51; 52).

Table 1. Article details and study population

First author	Year of publ.	Journal	Country	Inclusion via	Overall N included/ of which with autopsy	Age mean, range (years)	Sex ratio, male:female (n)	Postmortem interval (hours/days/ minutes)
Puranik (1)	2014	J Cardiovasc Magn Reson	Australia	Department of Forensic Medicine	17/ 17	22.7, 1.5-35	13:4*	Mean time to autopsy: 56.1h
Roberts (2)	2012	Lancet	United Kingdom	Coroner	182/ 182	n/r	n/r	n/r
Takahashi (3)	2012	Eur Radiol	Japan	Emergency Department	494/ 20	Median: 74, 0-101 among autopsied: 46.5	306:188 among autopsied: 16:4	Mean PMI for imaging: 21.7m CA within 4-24h after CT
Westphal (4)	2012	Virchows Arch	Germany	Hospital, Department of Pathology	29/ 28	59, 0-91	19:10	Mean PMI for imaging: 50h Mean PMI for CA: 62h
Wichmann (5)	2012	Ann Intern Med	Germany	9 Intensive Care Units	162/ 47	among autopsied: 63	among autopsied: 26:21	n/r
Roberts (6)	2003	Histopathology	United Kingdom	Coroner	10/ 10	n/r	n/r	Median time from death to imaging: 2d
Patriquin (7)	2001	J Magn Reson Imaging	USA	n/r	8/ 8	64	4:4	Imaging within 12h of death. CA within 12h of imaging.

Non-invasive methods

Minimally invasive methods	With radiological imaging					Without	
	Wichmann (8)	2014	Ann Intern Med	Germany	Department of Intensive Care Medicine		Median interval between death and CT: 4d
	Ross (9)	2012	Radiology	Switzerland	Institute of Forensic Medicine		Median interval between death and autopsy: 6d
	Bolliger (10)	2010	Am J Roentgenol	Switzerland	Institute for Forensic Autopsy		Mean PMI for imaging: 19h
	Weustink (11)	2009	Radiology	The Netherlands	Hospital (wards)		n/r
	Fariña (12)	2002	Virchows Arch	Spain	n/r		Mean PMI for imaging: 9.6h
	Fariña (13)	1998	J Echogr Med Ultrasons	Spain	n/r		CA after additional mean of 15.1h
	Fan (14)	2010	Forensic Sci Int	China	Coroner		n/r
	Cacchione (15)	2001	Surg Endosc	USA	Hospital		n/r
	Huston (16)	1996	Mod Pathol	USA	n/r		n/r
All procedures completed within 24h after death							
Range: 3-72h							

Table 2a. Study methods and design

First author	Year of publ.	Inclusion criteria	Exclusion criteria	Post-mortem techniques			Reference Standard	Blinded study*
				Imaging	Biopsies	Other		
Puranik (1)	2014	Consecutive patients aged 1-35 years	Patients with trauma, suicide or known drug overdose	1st comparison – 1.5Tesla MRI: (3D) T1, T1 FFE, T2 DE STIR, FLAIR, FFE and IR of the brain; cardiac balanced FFE and T2 STIR short-axis; T2 STIR multiple lung axes 2nd comparison – 64-slice CT from head to pelvis	No	No	Conventional autopsy	Yes
		Referred to dept. of forensic medicine						
		Death was identified to be sudden						
		Available scanning time and autopsy delay <24 hours						
		Verbal and written consent						
Non-invasive methods								
Roberts (2)	2012	First case each study day and study days according to availability of staff	Failure to obtain consent Severe obesity (>100kg)	8 or 16-slice CT from vertex to symph. pubicus. MRI: T1, DE or FLAIR, and STIR of the brain; T1, STIR and T2 FSE from neck to pelvis; fT2 short-axis of the heart	No	No	Full autopsy	Unknown
Takahashi (3)	2012	Subjects for whom emergency physicians could not determine COD by an external examination Permission obtained	Undoubtedly traumatic deaths Cases that had undergone only head CT	6-slice (155 cases), 16-slice (303 cases) or 64-slice CT (36 cases) from the head to the iliac bone	No	No	16 conventional autopsies (6 excluding brain); 4 forensic autopsies	Radiologists were blinded to autopsy findings. Pathologist were not blinded

Westphal (4)	2012	Deceased persons delivered for conventional autopsy (randomly selected) Manner of death due to natural cause	n/r	64-slice, dual source CT from head to toe	No	No	Conventional autopsy (1 limited to cardiac autopsy)	Unknown
Funeral scheduled early CT scanner maintenance Medical autopsy performed before CT Eligible for organ donation Body weight too high for CT scanner								
Wichmann (5)	2012	Patients died at an Intensive Care Unit Informed consent		Multislice CT from head to abdomen	No	No	Conventional autopsy	Yes
1.5 Tesla MRI: T1, GE, FLAIR and T2 of the head; T1, FSE, FLAIR with SPIR fat suppression from neck to pelvis								
Roberts (6)	2003	Sudden unexpected adult deaths in the community	Suspicious, violent or potentially drug- related deaths		No	No	Full autopsy	Yes
1.5 Tesla MRI: turbo STIR from vertex to the knees using coronal body coil; T2 FFE or T2 SPIR from thorax to pelvis								
Patriquin (7)	2001	Consent for both MRI and (limited) surgical dissection	Medical examiner cases Pediatric cases		No	No	7 conventional autopsies (1 excluding head); 1 percutaneous biopsy technique	Yes

Non-invasive methods

Table 2b. Study methods and design

Wichmann (8)	2014	Hospitalized patients who died unexpectedly or within 48 hours of an even necessitating CPR	Maintenance work on the CT scanner Funerals scheduled before autopsy could be done	4-slice and 16-slice native CT from head to hip joint?	No	Multiphase CTA via femoral vein and artery, from head to hip joint, using heart-lung machine	Full autopsy	Yes
Ross (9)	2012	Sheduled forensic autopsy Antemortem reports of chest pain	n/r	6-slice unenhanced CT from head to pelvis	CT-guided 14G needle biopsies of heart, lungs and suspected areas	Arterial and venous CTA from head to pelvis, via femoral vein and artery, using heart-lung machine	Conven-tional autopsy	No
Bolliger (10)	2010	Consecutive cases of unclear COD No signs of mechanical trauma Case circumstances indicative of a natural death	n/r	6-slice CT Scanned body parts not mentioned	CT fluoroscopic controlled 14G needle biopsies of heart, lungs and suspicious regions	CTA via femoral vein and artery, using heart-lung machine	Full forensic autopsy	Unknown
Weustink (11)	2009	Age 18 years or older Weight less than 100kg	No informed consent Forensic COD Known or suspected "high-risk" infections Open abdominal wounds Cases referred from Friday to Sunday	16-slice CT from the calvarium to the pelvis 1.5 Tesla MRI: T1 SE, T2 TSE and T2 FLAIR of the head using head coil; T1 SE, T2 TSE, T2 spectral fat saturation IR of thorax and abdomen	12G needle biopsies: Unguided biopsies of heart and lungs. US-guided biopsies of liver, kidneys and spleen. If indicated additional.	No	Conven-tional Autopsy	Yes

Minimally invasive methods
With radiological imaging

Without radiological imaging								
Fariña (12)	2002	n/r	n/r	Ultrasound of the internal organs, GI and urogenital tracts; pleural and peritoneal cavities and superficial structures	Ultrasound guided 14G needle biopsies of the internal organs (incl. brain) and lesions	No	Conventional autopsy	Yes
Fariña (13)	1998	n/r	n/r	Ultrasound of all organs	14G needle biopsies/ liquids	No	Conventional autopsy	Yes
Cases reported to coroner								
Cases ordered for autopsy examinations								
Fan (14)	2010	n/r	n/r	No	If indicated biopsies of the abdominal organs	Laparoscopy and thoracoscopy in 18 cases; Endoscopic arterioscopy in 2 cases	Full autopsies 4 limited autopsies	Unknown
Cases were selected to maximize benefit of method								
Cacchione (15)	2001	Patients who died in their institution	n/r	No	Needle biopsies of the internal organs	Laparoscopy, thoracoscopy and review of patients' hospital records	Conventional autopsy	Unknown
Huston (16)	1996	Patients with permission for complete post mortem examination	Medical examiner cases Fetal cases	No	Percutaneous 15G needle biopsies of heart, liver, lungs and kidneys. If indicated additional.	Appropriate tissues and fluids for post mortem cultures	Full autopsy	Unknown

* Unknown if not explicitly mentioned

Table 3. Results

First author	Year of publ.	Cases for review	Cause of death		Major diagnoses		Minor diagnoses	
			Agreement (95%CI)	Sensitivity (95%CI)	Agreement (95%CI)	Sensitivity (95%CI)	Agreement (95%CI)	Sensitivity (95%CI)
Puranik (1)	2014	11	MRI: 11/11 = 100% (71.5; 100)	MRI: 10/10 = 100% (69.2; 100)	n/r	n/r	n/r	n/r
			CT: 3/11 = 27.3% (6.0; 61.0)	CT: 2/10 = 20% (2.5; 55.6)				
Puranik (1)	2012	182 (-6) ¹	"70%" (62.6; 76.4)	n/r	n/r	n/r	n/r	n/r
xTakahashi (3)	2012	16 (-2) ¹	10/16 = 62.5% (35.4; 84.8)	8/14 = 57.1% (28.9; 82.3)	n/r	n/r	n/r	n/r
Westphal (4)	2012	24	n/r	17/24 = 70.8% ² (48.9; 87.4)	death related diagnoses 23/44 = 52.3% (36.7; 67.5)	death related diagnoses 23/43 = 53.5% (37.7; 68.8)	21/69 = 30.4% (19.9; 42.7)	21/45 = 46.7% (31.7; 62.1)
Wichmann (5)	2012	47	n/r	n/r	n/r	new major diagnoses 10/14 = 71.4% (41.9; 91.6)	new minor diagnoses 26/88 = 29.5% (20.3; 40.2)	new minor diagnoses 26/61 = 42.6% (30.0; 56.0)
Roberts (6)	2003	10	n/r	6/10 = 60% ² (26.2; 87.8)	n/r	n/r	n/r	n/r
Patriquin (7)	2001	7	n/r	3/7 = 42,9% ² (9.9; 81.6)	13/34 = 38.2% (22.2; 56.4)	13/23 = 56.5% (34.5; 76.8)	8/39 = 20.5% (9.3; 36.5)	8/23 = 34.8% (16.4; 57.3)
					death related diagnoses 6/15 = 40% (16.3; 67.7)	death related diagnoses 6/11 = 54.5% (23.4; 83.3)		

Non-invasive methods

	Minimally invasive methods				With radiological imaging			
	Author (n)	Year	n/r	n/r	new major diagnoses 13/16 = 81.3% (54.4; 96.0)	new major diagnoses 13/14 = 92.9% (66.1; 99.8)	new minor diagnoses 140/238 = 58.8% (52.3; 65.1)	new minor diagnoses 140/190 = 73.7% (66.8; 79.8)
Minimally invasive methods	Wichmann (8)	2014	50	n/r	n/r	n/r	n/r	n/r
	Ross (9)	2012	19*	n/r	18/19 = 94.7% (74.0; 99.9)	n/r	n/r	n/r
	Bolliger (10)	2010	19*	n/r	17/19 = 89.5% (66.9; 98.7)	n/r	n/r	n/r
	Weustink (11)	2009	30	23/30 = 76.7% (57.7; 90.1)	n/r	129/140 = 92.1% (86.4; 96.0)	129/137 = 94.2% (88.8; 97.5)	n/r
	Fariña (12)	2002	81	64/81 = 79.0% (68.5; 87.3)	n/r	n/r	n/r	n/r
Without	Fariña (13)	1998	130 (-29) ¹	120/130 = 92.3% (86.3; 96.3)	n/r	n/r	n/r	n/r
	Fan (14)	2010	16	15/16 = 93.8% (69.8; 99.8)	based on 18 cases "90%" (65.3; 98.6)	n/r	n/r	n/r
	Cacchione (15)	2001	7	combined with review of patients' hospital records "100%" (59.0; 100)	n/r	n/r	n/r	n/r
	Huston (16)	1996	20(-1 or more) ¹	12/20 = 60% (36.1; 80.9)	11/19 = 57.9% (33.5; 79.8)	new major diagnoses 20/24 = 83.3% (62.6; 95.3)	new major diagnoses 12/16 = 75% (47.6; 92.7)	cultures 39/46 = 84.8% (71.1; 93.7)
								cultures 10/15 = 66.6% (38.4; 88.2)

¹ Some cases should still be excluded, for these deceased were younger than 18 years of age or died from an unnatural cause of death

² Originally reported as being agreement

* Some of the included cases seem to overlap

Table 4. Advantages and disadvantages of non-invasive and minimally invasive autopsy methods using radiological techniques

	Advantages	Disadvantages
Ultrasound (12; 13)	Logistics: High availability Operator friendly	Image quality and diagnose: Inferior to MRI and CT in image quality Inferior to MRI and CT in biopsy guidance Limited visualisation of the vascular system (no flow) Operator dependent
	Cost: Inexpensive	
CT (3; 17; 18)	Logistics: High availability Rapid whole body examination Repeated scanning possible Possibility of biopsy guidance	Logistics: Limited availability during regular working hours (interferes with scanning of the living)
	Cost: Relatively inexpensive (compared to MRI)	
	Image quality and diagnose: Good visualization of bone (e.g. fractures), lung parenchyma disease, calcifications (stones, atherosclerosis), acute haemorrhage, air/ gas (e.g. pneumothorax, pneumatosis intestinalis, free air) High in-plane resolution (e.g. small lung nodules) Isovolumetric multi-planar and 3D reconstructions	
MRI (3; 18; 19)	Logistics: Possibility of biopsy guidance	Logistics: Limited availability during regular working hours (interferes with scanning of the living) Relatively time consuming examination (depending on scan protocol) Requires dedicated postmortem scan protocols (e.g. adjusting scan parameters for the body temperature) Requires MRI compatible body bags (e.g. no metal)
	Image quality and diagnose: Good, detailed visualization of organ parenchyma (e.g. brain, heart and myocardial infarct age), soft tissue (e.g. muscle injury), fluids (e.g. pleural/ pericardial), nervous system (e.g. spinal canal disorders), bone marrow disorders, metabolic diseases (e.g. hemochromatosis), large vessels (e.g. aortic dissection) Good differentiation between postmortem changes and pathology	
		Cost: Relatively expensive Requires dedicated training of technicians
		Image quality and diagnose: Image artefacts (e.g. metal from dental filling)

CT Angiography (8; 17; 18; 20; 21)	Image quality and diagnose: Good detection (of the origin) of haemorrhages (e.g. aortic rupture) Good detection of cardiovascular conditions (e.g. coronary stenosis)	Logistics: Limited availability of dedicated equipment and contrast agents Time consuming and complicated examination (e.g. achieving optimal contrast timing and full enhancement is difficult) Cost: Expensive (longer procedure time, contrast agents, dedicated equipment) Requires dedicated training Image quality and diagnose: Differentiation between post-mortem clotting and embolus is difficult Lack of circulation and insufficient mixing of blood and contrast
Targeted CT (coronary) angiography (21-23)	Cost: Relatively inexpensive equipment (compared to whole body angiography) Cannulation and scanning can be performed with minimal training Image quality and diagnose: Less expensive than whole body angiography	Logistics: Time consuming examination (e.g. positioning catheter, turning the corpse) Image quality and diagnose: Images restricted to coronary arteries Limited visualisation of internal mammary grafts, due to balloon position in the ascending aorta

Complete 2x2 tables for cause of death were extracted from two articles (38; 42), for overall findings from another article (48), and for new major findings and cultures from yet another article (42). In addition, partial 2x2 tables could be extracted from eleven studies (39-41; 43-47; 49; 51; 52).

For each available agreement percentage and sensitivity for cause of death in table 3, we calculated the exact binomial confidence interval. We plotted these confidence intervals in forest plots (see figure 2). They were often very wide, due to small study groups. We plotted both agreement and sensitivity in a funnel plot (see figure 3) and could not detect any signs of publication bias.

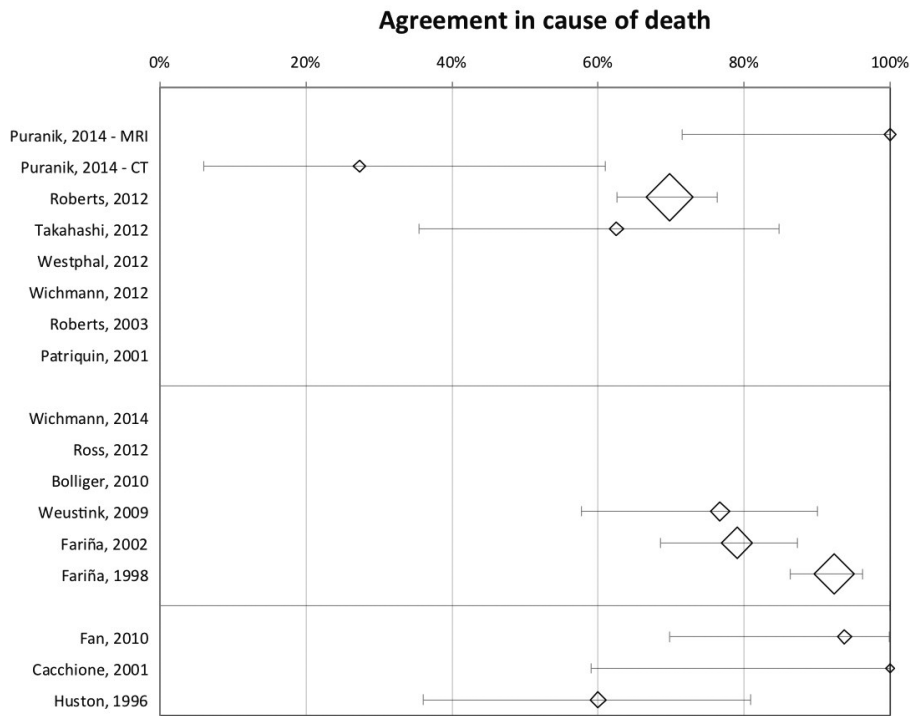


Figure 2a: Forest plot: Agreement in cause of death

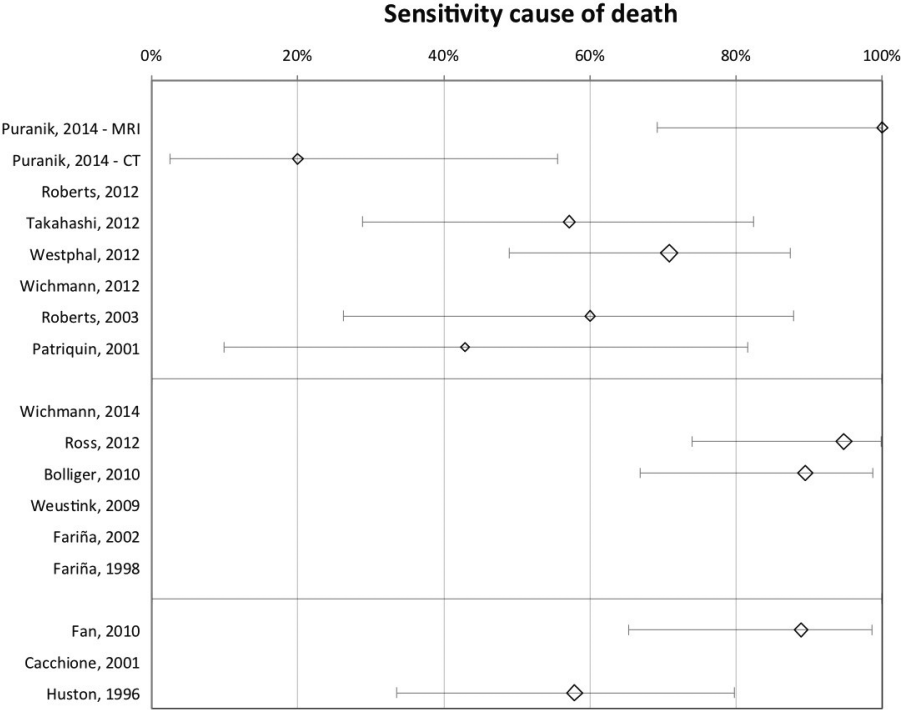


Figure 2b: Forest plot: Sensitivity cause of death

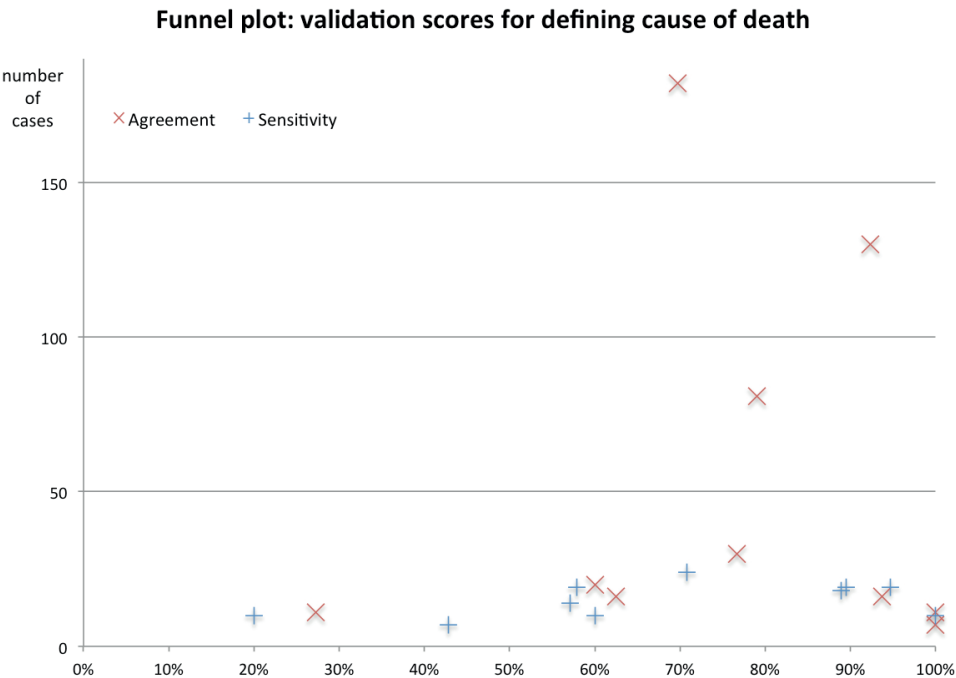


Figure 3: Funnel plot: Validation scores for defining cause of death

Agreement and accuracy of non-invasive autopsy methods

As a potential alternative to the conventional autopsy, the earliest two studies examined the use of magnetic resonance imaging (MRI) (46; 47). Three other studies used (multi detector) computed tomography, (MD)CT (38; 39; 45). The two most recent studies performed both MRI and CT (37; 52), but only one of them combined the results to define a cause of death (37). This latter study included more cases than all other non-invasive studies together.

The results of these studies, except Puranik et al. (52), suggest that the non-invasive autopsies using CT perform somewhat better than those using MRI. The highest sensitivity achieved with CT was 70.8% (39). The one study combining MRI and CT achieved an agreement of 70% in cause of death (37).

Other outcomes, such as sensitivity for major findings, could only be extracted from three studies. These outcomes could not be compared, due to the heterogeneity in study methods.

The criteria for case selection were various, and studies with similar patient groups investigated different imaging methods.

Agreement and accuracy of minimally invasive autopsy methods

The oldest minimally invasive autopsy study applied a combination of tissue biopsies and post-mortem cultures, without any kind of imaging and showed an agreement and sensitivity of (almost) 60% for the cause of death (42). They also showed a reasonably good agreement and sensitivity for new major findings.

Two studies performing a combination of post-mortem laparoscopy, thoracoscopy and (if indicated) tissue biopsies showed very high agreement percentages for the cause of death (49; 50). However, one of these studies included very few cases ($n=7$) and the other selected cases to maximize the benefit of the studied method.

There were two studies, by the same author, examining ultrasonography and (ultrasound-guided) biopsies in comparison to autopsy (40; 41). It is unknown if any of their cases were reported twice. The second study appeared to have worse outcomes than the first, but the agreement was still higher than in all non-invasive methods.

Weustink et al. (48) evaluated a combination of MRI and CT, and ultrasonography-guided tissue biopsies, and showed agreement for cause of death in 76.7%. They were the only investigators who calculated specificity for overall findings, which was 99%.

In their most recent study Wichmann et al. performed native CT and multiphase CT-angiography (no tissue biopsies) (51). With the addition of the CT-angiography the sensitivity of new major diagnoses had improved from 71.4% (MDCT only) to 92.9%.

Two studies combined CT, CT-angiography and (CT-guided) tissue biopsies as alternative to conventional autopsy (43; 44), resulting in high sensitivities for cause of death: 94.7% and 89.5%. Both studies included twenty cases of which six appeared to be duplicates, so together they actually included 34 cases, of which 33 were eligible for this review, leading to a pooled sensitivity of 90.9% (95%CI: 74.5; 97.6).

Further analyses or comparison between these studies was difficult, because of the heterogeneity in studied methods.

Cost of alternative autopsy methods

Although several studies mentioned costs, only one of them compared the actual cost of the two methods investigated. Weustink et al. (48) calculated a mean cost of $\$1497 \pm 148$ per minimally invasive autopsy, and $\$2274 \pm 104$ per conventional autopsy. Wichmann et al. (51) stated that the addition of angiography increased cost with \$300 per case. Roberts et al. mentioned that alternative autopsies using MRI are more expensive than conventional

autopsy (37; 46). Alternative autopsies using CT (37; 38; 45) or ultrasonography (40; 41), on the other hand, appear to be less expensive than conventional autopsy.

Discussion

This is one of few systematic reviews to analyse the accuracy of alternatives to the conventional methods of autopsy in natural deaths, and the first to focus on naturally deceased adults. Although none of the alternative methods performed as well as conventional autopsy, higher agreement and sensitivity percentages demonstrated that minimally invasive autopsy methods were more accurate than non-invasive autopsy methods, especially those including tissue biopsies.

Comparison with the literature

A similar systematic review has been performed by Thayyil et al (53), who found better overall pooled sensitivity and specificity of post-mortem MRI in fetuses (69% and 95%) than in children and adults. As an alternative to conventional autopsy, however, its diagnostic accuracy was insufficient in all patient groups.

Since then, more studies have been published, and the diagnostic performance of alternative methods has improved significantly, as our study shows. With the introduction of minimally invasive autopsy methods, including imaging and tissue biopsies, remarkable improvements in accuracy were achieved. The merit of histological examination of vital organ tissue, in particular obtained under image-guidance, is also addressed in forensic studies (54).

When comparing cost, minimally invasive autopsy may be less expensive than conventional autopsy. According to the reviewed studies, a minimally invasive autopsy including both biopsies and CT-angiography costs \$1649 to \$1945, whereas autopsy costs \$2170 to \$2378. In Switzerland each autopsy is preceded by at least CT, and Flach et al. (55) recently calculated a cost of \$820 to \$1150 per post-mortem examination including CT, CT-angiography, MRI, and forensic expert opinion.

Even though post-mortem endoscopic methods (thoracoscopy and laparoscopy) appear to be very accurate alternatives to conventional autopsy (49; 50), we hesitate to draw conclusions. Both studies included a fairly small number of cases and did not report whether the examiners were blinded to the conventional autopsy findings. One study states that it induced selection bias by selecting cases in order to maximize the benefit of the alternative autopsy (49). Avrahami et al. (56) support our doubts, and state that findings from an endoscopic autopsy are insufficient to establish a definite cause of death. They recommend performing endoscopic autopsy only in cases in which there are

objections to conventional autopsy and in order to rule out or identify major thoracic or abdominal pathology leading to death.

Several studies have shown that post-mortem whole-body CT-angiography visualizes pathological changes in blood vessels, such as stenosis, occlusion and injuries, and improves the accuracy of a minimally invasive autopsy method (30; 43; 44; 51; 57). As these whole-body angiographies tend to be expensive, for heart-lung machines and large volumes of special contrast agents are required, either out-dated and therefore inexpensive equipment, or newly developed low-cost “targeted” angiography methods are being used. For instance, a post-mortem coronary CT-angiography was designed to improve the accuracy of a minimally invasive autopsy method in sudden natural death cases (58; 59). For findings in the coronary arteries, Roberts et al. achieved a correlation of 80% between autopsy and CT-angiography. Moreover, Saunders et al. were able to reduce the time for whole body CT-scanning and a coronary CT-angiography to an average of 48 minutes.

Another interesting technique, which was not performed in any of the reviewed studies, is postmortem ventilation. In clinical practice, the detection of small lung lesions is improved by having patients hold their breath when the scan is made. To achieve a similar effect in postmortem imaging, forensic examiners simulated expiration and inspiration scans by ventilating the lungs (60-62).

When searching for validation studies of alternatives to autopsies, we also found articles about verbal autopsy. This is a World Health Organization-method used in populations lacking vital registration and medical certification, to determine the probable cause of death based on questionnaires and/ or narratives from next of kin or other reliable informants (such as caregivers). The method is not based on any post-mortem physical examination of the body, and not accurate for attributing cause of death at the individual level. Therefore, verbal autopsy was excluded from this review.

Limitations

We found very few validation studies on non-invasive and minimally invasive autopsy methods performed on adults with a non-suspicious and supposedly natural cause of death. We therefore chose not to exclude studies that did not provide sufficient data for composing complete 2x2 tables. As a result, the agreement on cause of death could not always be calculated, as it should be based on the combined true positives and true negatives whereas the latter was frequently missing. As we could neither extract true negatives nor false positives, we calculated only sensitivity percentages, even though the results had originally been reported as being agreement percentages.

Due to insufficient data, we were also unable to test whether the agreement percentages on cause of death were any better than chance, since, with incomplete 2x2 tables, the chance-corrected proportional agreement (κ -statistic) could not be correctly calculated.

Also, variability of the investigated study groups and study methods, and the information that was reported in the articles was too large to combine study outcomes in a meta-analysis.

For example, in studies using radiological imaging, one, two, four or six (specialized) radiologists reviewed the images. Previous experience in post-mortem imaging was mentioned in 6 studies: it varied from no experience to 5 years of experience, and was not comparable between studies. Though Roberts et al. (46) found that previous experience did not result in more correctly diagnosed causes of death. Moreover, only two studies calculated an inter-observer agreement (kappa): Weustink et al. (48) reported kappas of 0.85 for CT and 0.84 for MRI, and Ross et al. (43) reported a kappa of 0.94.

In addition, when comparing a new method to the reference standard in a validation study, the investigators performing one method should ideally be blind to outcomes of the other. This might not have been the case in eight of the studies reviewed, in which the agreement or sensitivity percentages may have been influenced, possibly biasing their value.

Controversially, blinding induces failure to detect false positive and false negative results. Christe et al. (63) reported that both gas and fractures were better detected at imaging than autopsy. To prevent these imaging findings from being registered as false positives, they had the findings confirmed after a second look at the autopsy. The same way, taking a second look at the radiologic images after autopsy could rectify false negative results. However, in both situations the findings were not originally reported, so they may be missed again in the future.

Another limitation, which is almost inevitable due to the kind of studies investigated, is knowledge of the medical histories prior to performing autopsy. None of the reviewed studies reported, that the investigators of conventional autopsy and its potential alternative were uninformed about the case circumstances. Therefore, this prior knowledge may have influenced the outcomes of agreement between the two methods, for known pathologies are more likely to be identified than unknown ones.

Advantages and disadvantages of the non-invasive and minimally invasive autopsy methods

When comparing radiological techniques for non-invasive and minimally invasive autopsy methods, CT and MRI are likely to be preferred over ultrasound. Both have their strengths and shortcomings, and may ideally complement each other. Table 4 gives an overview of the advantages and disadvantages of the radiologic techniques (32; 38; 40; 41; 51; 58; 59; 64-67).

Both radiologic techniques and scopic techniques are generally used in medical practice for the living. Hence, they are not available for autopsy cases during busy working hours. If a technique were to be purchased for post-mortem investigations only, the costs may not outweigh the benefits. The more advanced an alternative autopsy technique is, the higher is its price, but, in general, the better are its diagnostic capabilities (if the reviewed studies had used all available techniques, their results would inevitably have been better). Yet, those capabilities are not always required for each individual autopsy case. For example, MRI should preferably be used to examine congenital abnormalities or neurologic pathology in neonates, infants and children, whereas CT is required to examine lung pathology in adults.

Without reliable criteria for selecting those techniques or protocols required based on individual case characteristics, it is impossible to minimize cost and enable investigators to identify or rule out specific pathologies. In order to determine an adequate strategy, that is not unduly expensive, more studies should be performed on large study groups that represent patients with all causes of death.

According to the articles reviewed difficulties remain, even with the advanced minimally invasive autopsy techniques. The main difficulties are in detecting small metastases (51); in diagnosing cardiovascular disease, such as (localized or massive) acute myocardial infarction and endocarditis (43-45; 48); and in distinguishing post-mortem clotting from true thromboembolic material, especially in the pulmonary arteries (43; 45). On the other hand, in certain cases post-mortem imaging has a diagnostic advantage, since some death related findings are better depicted on imaging than with conventional autopsy. For example, a pneumothorax was diagnosed on imaging only and missed at autopsy (48; 68).

To achieve the highest diagnostic accuracy we think an alternative autopsy method should at least be minimally invasive. Even though the minimally invasive autopsy method is not yet as accurate as conventional autopsy, some of its other features favour this alternative method.

The first is that imaging data can easily be stored and subjected to second reading, and used for clinical feedback and teaching purposes, whereas macroscopic autopsy findings have to be photographed or organs have to be preserved in order to do so.

Another benefit of a minimally invasive autopsy is the possibility to take tissue biopsies under precise CT-guidance from very small lesions. It is known that in patients who died from metastatic disease, scarcely enlarged lymph nodes could be detected at conventional autopsy.

Just as in conventional autopsy, one could collect extra tissue biopsies that can be frozen and stored in a tissue bank. Such frozen samples could be used for further diagnostic analyses on a molecular level, and be used for medical research (69).

A logistic advantage of minimally invasive autopsy is that a specialised radiologist is able to read the images from another location and even plan the exact coordinates of the biopsy trajectories for a robot to precisely place the introducer needles (31; 70). If multiple biopsies are routinely obtained, certain advanced techniques will minimize procedure time and eventually help reducing cost. From a technological point of view, Lundström et al. (71) see no obstacles to introducing minimally invasive autopsies on a larger scale.

Fryer et al. (68) emphasize the benefit of using a minimally invasive method for screening prior to conventional autopsy in cases with high-risk infections. Among a group of suddenly deceased drug users with a known category 3 infection (such as Human Immunodeficiency Virus or hepatitis-C virus), they identified the cause of death through a minimally invasive examination in a considerable percentage of cases, thereby achieving a two-thirds reduction in the number of high-risk invasive autopsies.

Last but not least, clinicians would gain more information from an alternative autopsy than from no post-mortem investigation at all.

Conclusion

Non-invasive or minimally invasive autopsy methods could serve as an alternative to conventional autopsy. However, it should be remembered that these alternative methods are still less accurate than the reference standard, and that taking image-guided tissue biopsies for histologic examination (and therefore performing a minimally invasive autopsy) is essential for achieving the best possible diagnostic accuracy.

To improve the technical aspects of minimally invasive autopsy methods and to test their potential in larger study groups, including patients who died in hospital with a broad spectrum of diseases, there is a need for more extensive studies. Such studies should not

just examine the practical use and accuracy of the alternative autopsy method, but also take into account the cost of implementing the alternative method. If possible, an alternative to conventional autopsy should be developed that is suitable for implementation in academic and non-academic hospitals. Such alternatives to conventional autopsy should ultimately contribute to increasing autopsy rates, improving medical feedback to clinicians, and better overall health care quality control.

Acknowledgements

Wichor Bramer, biomedical information specialist in our medical library, who helped perform the literature searches.

Nikola Vitlarov, MD, who assisted with the data extraction.

References

- 1 Burton EC (2002) The autopsy: a professional responsibility in assuring quality of care. *Am J Med Qual*, 17:56-60.
- 2 Lundberg GD (1998) Low-tech autopsies in the era of high-tech medicine: continued value for quality assurance and patient safety. *JAMA*, 280:1273-1274.
- 3 Shojania KG, Burton EC, McDonald KM, Goldman L (2002) The autopsy as an outcome and performance measure. *Evid Rep Technol Assess (Summ)*:1-5.
- 4 Burton EC, Troxclair DA, Newman WP, 3rd (1998) Autopsy diagnoses of malignant neoplasms: how often are clinical diagnoses incorrect? *JAMA*, 280:1245-1248.
- 5 Murken DR, Ding M, Branstetter Bf, Nichols L (2012) Autopsy as a quality control measure for radiology, and vice versa. *AJR Am J Roentgenol*, 199:394-401.
- 6 Roulson J, Benbow EW, Hasleton PS (2005) Discrepancies between clinical and autopsy diagnosis and the value of post mortem histology; a meta-analysis and review. *Histopathology*, 47:551-559.
- 7 Scordi-Bello IA, Kalb TH, Lento PA (2010) Clinical setting and extent of premortem evaluation do not predict autopsy discrepancy rates. *Mod Pathol*, 23:1225-1230.
- 8 Shojania KG, Burton EC, McDonald KM, Goldman L (2003) Changes in rates of autopsy-detected diagnostic errors over time: a systematic review. *JAMA*, 289:2849-2856.
- 9 Veress B, Alafuzoff I (1994) A retrospective analysis of clinical diagnoses and autopsy findings in 3,042 cases during two different time periods. *Hum Pathol*, 25:140-145.
- 10 Winters B, Custer J, Galvagno SM, et al. (2012) Diagnostic errors in the intensive care unit: a systematic review of autopsy studies. *Bmj Qual Saf*, 21:894-902.
- 11 Wittschieber D, Klauschen F, Kimmritz AC, et al. (2012) Who is at risk for diagnostic discrepancies? Comparison of pre- and postmortal diagnoses in 1800 patients of 3 medical decades in East and West Berlin. *PLoS One*, 7:e37460.
- 12 Burton JL, Underwood J (2007) Clinical, educational, and epidemiological value of autopsy. *Lancet*, 369:1471-1480.
- 13 Gaensbacher S, Waldhoer T, Berzlanovich A (2012) The slow death of autopsies: A retrospective analysis of the autopsy prevalence rate in Austria from 1990 to 2009. *Eur J Epidemiol*, 27:577-580.
- 14 Shojania KG, Burton EC (2008) The vanishing nonforensic autopsy. *N Engl J Med*, 358:873-875.
- 15 Brown HG (1990) Perceptions of the autopsy: views from the lay public and program proposals. *Hum Pathol*, 21:154-158.
- 16 Burton JL, Underwood JC (2003) Necropsy practice after the "organ retention scandal": requests, performance, and tissue retention. *J Clin Pathol*, 56:537-541.
- 17 Burton EC, Phillips RS, Covinsky KE, et al. (2004) The relation of autopsy rate to physicians' beliefs and recommendations regarding autopsy. *Am J Med*, 117:255-261.
- 18 Charlton R (1994) Autopsy and medical education: a review. *J R Soc Med*, 87:232-236.

- 19 Gatrad AR (1994) Muslim customs surrounding death, bereavement, postmortem examinations, and organ transplants. *BMJ*, 309:521-523.
- 20 Hinchliffe SA, Godfrey HW, Hind CR (1994) Attitudes of junior medical staff to requesting permission for autopsy. *Postgrad Med J*, 70:292-294.
- 21 Hull MJ, Nazarian RM, Wheeler AE, Black-Schaffer WS, Mark EJ (2007) Resident physician opinions on autopsy importance and procurement. *Hum Pathol*, 38:342-350.
- 22 Loughrey MB, McCluggage WG, Toner PG (2000) The declining autopsy rate and clinicians' attitudes. *Ulster Med J*, 69:83-89.
- 23 Oluwasola OA, Fawole OI, Otegbayo AJ, Ogun GO, Adebamowo CA, Bamigboye AE (2009) The autopsy: knowledge, attitude, and perceptions of doctors and relatives of the deceased. *Arch Pathol Lab Med*, 133:78-82.
- 24 Tsitsikas DA, Brothwell M, Chin Aleong JA, Lister AT (2011) The attitudes of relatives to autopsy: a misconception. *J Clin Pathol*, 64:412-414.
- 25 Sanchez H, Collins, K.A. (2013) Autopsy Request Process. <http://emedicine.medscape.com/article/1730552-overview> - accessed November 19th, 2013.
- 26 Ayoub T, Chow J (2008) The conventional autopsy in modern medicine. *J R Soc Med*, 101:177-181.
- 27 Brookes JAS, HallCraggs MA, Sams VR, Lees WR (1996) Non-invasive perinatal necropsy by magnetic resonance imaging. *Lancet*, 348:1139-1141.
- 28 Griffiths PD, Paley MNJ, Whitby EH (2005) Post-mortern MRI as an adjunct to fetal or neonatal autopsy. *Lancet*, 365:1271-1273.
- 29 Leth PM (2007) The Use of CT Scanning in Forensic Autopsy. *Forensic Sci. Med. Pathol*, 3:65-69.
- 30 Dirnhofer R, Jackowski C, Vock P, Potter K, Thali MJ (2006) VIRTOPSY: minimally invasive, imaging-guided virtual autopsy. *Radiographics*, 26:1305-1333.
- 31 Ebert LC, Ptacek W, Naether S, et al. (2010) Virtobot--a multi-functional robotic system for 3D surface scanning and automatic post mortem biopsy. *Int J Med Robot*, 6:18-27.
- 32 Thali MJ, Yen K, Schweitzer W, et al. (2003) Virtopsy, a new imaging horizon in forensic pathology: virtual autopsy by postmortem multislice computed tomography (MSCT) and magnetic resonance imaging (MRI)--a feasibility study. *J Forensic Sci*, 48:386-403.
- 33 Le Blanc-Louvry I, Thureau S, Duval C, et al. (2013) Post-mortem computed tomography compared to forensic autopsy findings: a French experience. *European Radiology*, 23:1829-1835.
- 34 Ruder TD, Hatch GM, Ebert LC, et al. (2012) Whole Body Postmortem Magnetic Resonance Angiography. *Journal of Forensic Sciences*, 57:778-782.
- 35 <http://handbook.cochrane.org/> - accessed on the 17th of July, 2013.
- 36 Liberati A, Altman DG, Tetzlaff J, et al. (2009) The PRISMA Statement for Reporting Systematic Reviews and Meta-Analyses of Studies That Evaluate Health Care Interventions: Explanation and Elaboration. *Plos Medicine*, 6.

- 37 Roberts ISD, Benamore RE, Benbow EW, et al. (2012) Post-mortem imaging as an alternative to autopsy in the diagnosis of adult deaths: A validation study. *Lancet*, 379:136-142.
- 38 Takahashi N, Higuchi T, Shiotani M, et al. (2012) The effectiveness of postmortem multidetector computed tomography in the detection of fatal findings related to cause of non-traumatic death in the emergency department. *Eur Radiol*, 22:152-160.
- 39 Westphal SE, Apitzsch J, Penzkofer T, Mahnken AH, Knuchel R (2012) Virtual CT autopsy in clinical pathology: Feasibility in clinical autopsies. *Virchows Arch*, 461:211-219.
- 40 Farina J, Millana C, Fdez-Acenero JM, et al. (2002) Ultrasonographic autopsy (echopsy): A new autopsy technique. *Virchows Arch*, 440:635-639.
- 41 Farina J, Millana C (1998) Applications of ultrasonography on the post-mortem examination (ecopsy) in humans. *J Echogr Med Ultrasons*, 19:280-286.
- 42 Huston BM, Malouf NN, Azar HA (1996) Percutaneous needle autopsy sampling. *MOD PATHOL*, 9:1101-1107.
- 43 Ross SG, Thali MJ, Bolliger S, Germerott T, Ruder TD, Flach PM (2012) Sudden death after chest pain: Feasibility of virtual autopsy with postmortem CT angiography and biopsy. *Radiology*, 264:250-259.
- 44 Bolliger SA, Filograna L, Spendlove D, Thali MJ, Dirnhofner S, Ross S (2010) Postmortem imaging-guided biopsy as an adjuvant to minimally invasive autopsy with CT and postmortem angiography: A feasibility study. *Am J Roentgenol*, 195:1051-1056.
- 45 Wichmann D, Obbelode F, Vogel H, et al. (2012) Virtual autopsy as an alternative to traditional medical autopsy in the intensive care unit; A prospective cohort study. *Ann Intern Med*, 156:123-130.
- 46 Roberts ISD, Benbow EW, Bisset R, et al. (2003) Accuracy of magnetic resonance imaging in determining cause of sudden death in adults: Comparison with conventional autopsy. *Histopathology*, 42:424-430.
- 47 Patriquin L, Kassarian A, O'Brien M, Andry C, Eustace S (2001) Postmortem whole-body magnetic resonance imaging as an adjunct to autopsy: Preliminary clinical experience. *J Magn Reson Imaging*, 13:277-287.
- 48 Weustink AC, Hunink MGM, Van Dijke CF, Renken NS, Krestin GP, Oosterhuis JW (2009) Minimally invasive autopsy: An alternative to conventional autopsy? *Radiology*, 250:897-904.
- 49 Fan JKM, Tong DKH, Poon JTC, et al. (2010) Multimodality minimally invasive autopsy-A feasible and accurate approach to post-mortem examination. *Forensic Sci Int*, 195:93-98.
- 50 Cacchione RN, Sayad P, Pecoraro AM, Ferzli GS (2001) Laparoscopic autopsies. *Surg Endosc*, 15:619-622.
- 51 Wichmann D, Heinemann A, Weinberg C, et al. (2014) Virtual Autopsy With Multiphase Postmortem Computed Tomographic Angiography Versus Traditional Medical Autopsy to Investigate Unexpected Deaths of Hospitalized Patients. *Annals of Internal Medicine*, 160:534-+.

- 52 Puranik R GB, Lackey H, Yeates L, Parker G, Duflou J, Semsarian C (2014) Comparison of conventional autopsy and magnetic resonance imaging in determining the cause of sudden death in the young. *J Cardiovasc Magn Reson.*, 16:44.
- 53 Thayyil S, Chandrasekaran M, Chitty LS, et al. (2010) Diagnostic accuracy of post-mortem magnetic resonance imaging in fetuses, children and adults: a systematic review. *Eur J Radiol*, 75:e142-148.
- 54 Bolliger SA, Thali MJ, Ross S, Buck U, Naether S, Vock P (2008) Virtual autopsy using imaging: bridging radiologic and forensic sciences. A review of the Virtopsy and similar projects. *Eur Radiol*, 18:273-282.
- 55 Flach PM, Thali MJ, Germerott T (2014) Times have changed! Forensic radiology--a new challenge for radiology and forensic pathology. *AJR Am J Roentgenol*, 202:W325-334.
- 56 Avrahami R, Waternberg S, Daniels-Philips E, Kahana T, Hiss J (1995) Endoscopic autopsy. *Am J Forensic Med Pathol*, 16:147-150.
- 57 Saunders SL, Morgan B, Raj V, Rutty GN (2011) Post-mortem computed tomography angiography: Past, present and future. *Forensic Sci Med Pathol*, 7:271-277.
- 58 Roberts ISD, Benamore, R. E., Peebles, C., Roobottomd, C., Traill, Z. C. (2011) Diagnosis of coronary artery disease using minimally invasive autopsy: evaluation of a novel method of post-mortem coronary CT angiography. *Clinical Radiology*, 66:645-650.
- 59 Saunders SL, Morgan B, Raj V, Robinson CE, Rutty GN (2011) Targeted post-mortem computed tomography cardiac angiography: proof of concept. *Int J Legal Med*, 125:609-616.
- 60 Germerott T, Preiss US, Ebert LC, et al. (2010) A new approach in virtopsy: Postmortem ventilation in multislice computed tomography. *Leg Med (Tokyo)*, 12:276-279.
- 61 Robinson C, Biggs MJ, Amoroso J, Pakkal M, Morgan B, Rutty GN (2014) Post-mortem computed tomography ventilation; simulating breath holding. *International Journal of Legal Medicine*, 128:139-146.
- 62 Rutty GN, Biggs MJP, Brough A, et al. (2015) Ventilated post-mortem computed tomography through the use of a definitive airway. *International Journal of Legal Medicine*, 129:325-334.
- 63 Christe A, Ross S, Oesterhelweg L, et al. (2009) Abdominal Trauma-Sensitivity and Specificity of Postmortem Noncontrast Imaging Findings Compared With Autopsy Findings. *Journal of Trauma-Injury Infection and Critical Care*, 66:1302-1307.
- 64 Burton JL, Rutty GN *The Hospital Autopsy: A Manual of Fundamental Autopsy Practice* (Hodder Arnold Publication). CRC Press; 3 edition (25 Jun 2010).
- 65 Jackowski C, Schweitzer W, Thali M, et al. (2005) Virtopsy: Postmortem imaging of the human heart in situ using MSCT and MRI. *Forensic Sci Int*, 149:11-23.
- 66 Michaud K, Grabherr S, Jackowski C, Bollmann MD, Doenz F, Mangin P (2013) Postmortem imaging of sudden cardiac death. *Int J Legal Med*.

- 67 Bruguier C, Mosimann PJ, Vaucher P, et al. (2013) Multi-phase postmortem CT angiography: recognizing technique-related artefacts and pitfalls. *International Journal of Legal Medicine*, 127:639-652.
- 68 Fryer EP, Traill ZC, Benamore RE, Roberts IS (2013) High risk medicolegal autopsies: is a full postmortem examination necessary? *J Clin Pathol*, 66:1-7.
- 69 van der Linden A, Blokker BM, Kap M, Weustink AC, Riegman PH, Oosterhuis JW (2014) Post-Mortem Tissue Biopsies Obtained at Minimally Invasive Autopsy: An RNA-Quality Analysis. *PLoS One*, 9:e115675.
- 70 Ebert LC, Ptacek W, Furst M, Ross S, Thali MJ, Hatch G (2012) Minimally invasive postmortem telebiopsy. *J Forensic Sci*, 57:528-530.
- 71 Lundstrom C, Persson A, Ross S, et al. (2012) State-of-the-art of visualization in post-mortem imaging. *Apmis*, 120:316-326.

3

CHAPTER 3

Total-body CT and MR features of postmortem change in in-hospital deaths

Ivo M Wagenveld, Britt M Blokker, Piotr A Wielopolski, Nomdo S Renken, Gabriel P Krestin, Myriam G Hunink, J Wolter Oosterhuis, Annick C Weustink

Objectives

To evaluate the frequency of total-body CT and MR features of postmortem change in in-hospital deaths.

Materials and Methods

In this prospective blinded cross-sectional study, in-hospital deceased adult patients underwent total-body postmortem CT and MR followed by image-guided biopsies. The presence of PMCT and PMMR features related to postmortem change was scored retrospectively and correlated with postmortem time interval, post-resuscitation status and intensive care unit (ICU) admittance.

Results

Intravascular air, pleural effusion, periportal edema, and distended intestines occurred more frequently in patients who were resuscitated compared to those who were not. Postmortem clotting was seen less often in resuscitated patients ($p=0.002$). Distended intestines and loss of grey-white matter differentiation in the brain showed a significant correlation with postmortem time interval ($p=0.001$, $p<0.001$). Hyperdense cerebral vessels, intravenous clotting, subcutaneous edema, fluid in the abdomen and internal livores of the liver were seen more in ICU patients. Longer postmortem time interval led to a significant increase in decomposition related changes ($p=0.026$).

Conclusion

There is a wide variety of imaging features of postmortem change in in-hospital deaths. These imaging features vary among clinical conditions, increase with longer postmortem time interval and must be distinguished from pathologic changes.

Introduction

Hospital autopsy rates today are as low as 0-5%, having decreased from a rate of 30% or higher in the 1990s. (1-3) This low rate is alarming, since one in five autopsies show major discrepancies between antemortem and postmortem diagnoses despite improved diagnostic testing. (4) A possible cause for this decline may be the invasiveness of the conventional autopsy procedure. (5) To provide a less invasive alternative to conventional autopsy, imaging-based autopsy methods were developed, primarily in forensic medicine. These modern autopsies include total-body postmortem CT (PMCT) and MR (PMMR), sometimes combined with CT angiography (PMCTA) and image-guided biopsies. (6-8) More recently the imaging autopsy is steadily emerging in clinical radiology and there is a growing number of diagnostic studies analyzing the performance of the noninvasive (imaging only) and minimally invasive autopsy (imaging with angiography and / or biopsies). (9-11) Combined PMCT, PMCTA and image-guided biopsies appear most sensitive in diagnosing cause of death, however more clinical studies are needed to accurately determine the diagnostic value of the imaging autopsy. (10, 11) In forensic centers access to MR scanners is often limited, so PMCT is most commonly performed. In hospitals, MRI is more widely available, and its high performance to visualize organ parenchyma and soft tissues make PMMR a valuable addition to PMCT.

Postmortem imaging is not the same as imaging the living. Directly after death various chemical and physical processes affect the body in ways that can change PMCT and PMMR features of organs and soft-tissues. These processes can generally be divided into gravity dependent changes (including sedimentation of blood and livor mortis; also known as lividity or hypostasis), decomposition (including putrefaction), rigor mortis (muscle stiffness) and algor mortis (cooling of the body).

Livor mortis is caused by blood settling in the dependent parts of the body due to gravity. Livores can be observed both internally, on imaging and autopsy, and externally upon visual inspection. External livores manifest as dark bluish (or livid) areas of the skin within several hours after death. Internal livores are noted as increased attenuation or signal changes of the dependent areas of organs. The combination of postmortem leakage of cell membranes and subsequent increased osmolality of the interstitial fluid, together with the effect of gravity leads to accumulation of fluids in dependent areas, such as the subcutaneous fat, thoracic cavity and abdominal cavity. (12-14)

Decomposition consists of many processes that cause organic material to break down into simpler forms of matter. It includes putrefaction, autolysis and insect and animal predation. Putrefaction leads to gas formation, it is found intravascular in an early decomposition stage and in more advanced stages also in soft tissues and organ parenchyma.

Rigor mortis leads to muscle contraction after death that results in muscle stiffness. Rigor mortis is caused by cessation of synthesis of adenosine triphosphate (ATP). ATP is consumed in muscle fibers to separate actin and myosin filaments. Directly after death

ATP is still present in the muscle, but it is consumed in the first hours after death. When the ATP reserves are depleted, actin and myosin filaments cannot separate anymore. This state lasts until decomposition leads to the breakdown of actin and myosin filaments. The speed of this process depends on temperature: both the time until rigor mortis starts and reaches its maximum and the time until rigor mortis recedes are longer in colder bodies. (15-18)

Algor mortis can affect tissue contrast on PMMR images. There is a wide variability of T1 values due to higher sensitivity of T1 to temperature differences. (19) T2 values are less temperature dependent.

Radiologists need in-depth understanding of these processes for correct acquisition and interpretation of PMCT and PMMR scans. The aim of this study is to evaluate the frequency of total-body CT and MR features of postmortem change in in-hospital deaths.

Materials and methods

Study protocol

This study was undertaken as part of the *Minimally Invasive Autopsy* (MIA) study. This is a prospective single center cross-sectional study in a tertiary referral hospital comparing diagnostic performance of conventional autopsy and MIA. Approval of the Erasmus MC Institutional Review Board and Ethics Committee was obtained; the study was filed with the Netherlands National Trial Register. Patients aged 18 years and older who died in the Erasmus University Medical Center were eligible for inclusion, if written informed consent was obtained from next-of-kin for MIA and CA of at least the torso.

Exclusion criteria were (suspected) unnatural cause of death (COD), body size exceeding diameter of 16 inches in supine position (limitation for PMMR), known or suspected “high-risk” infected bodies (tuberculosis, hepatitis B and C, human immunodeficiency virus, methicillin-resistant *Staphylococcus aureus*, multi-drug resistant *Acinetobacter*), and open abdominal wounds that could not be completely closed or taped to prevent leakage of body fluids.

All cases underwent total-body PMCT and PMMR followed by biopsies under CT (torso) or stereotactic guidance (brain) according to standardized protocols (Table 1 and 2). Total scan time was approximately 60 minutes for PMMR and 10 minutes for PMCT. First PMMR was performed on a 1.5T scanner (Discovery MR450, GE Healthcare, Milwaukee, Wisconsin USA) and consisted of scans from the head to the pelvis (legs were omitted on because of MR scanner availability). Directly after PMMR, PMCT was performed on a dual-source CT scanner (SOMATOM Definition Flash, Siemens Healthcare Forchheim, Germany) and consisted of scans from head to feet. Standardized CT-guided biopsies (12 Gauge) were taken from heart, lungs, liver, kidneys, spleen, and additional biopsies were taken from radiologically suspected pathology. All biopsies were stained with hematoxylin and eosin (H&E) and when requested by the pathologist additional stains were performed.

Table 1. Postmortem imaging protocol

A. Postmortem magnetic resonance protocol											
Scan area	Coil	Sequence	TR/TE/TI (ms)	Slice width		FOV (cm)	Matrix	Coverage			
				(mm)	(mm)			No. of slices	per section (cm)	No. of sections	Time per section (s)
Head-Pelvis	Body	FLAIR FSE T1w	2320/9.5/963	4.0	48	48	384x320	50	20.0	5-8	174
Head-Pelvis	Body	STIR FSE T2w	12000/41/120	4.0	48	48	288x224	50	20.0	5-8	168
Thorax	8-channel	3D fs FSPGR T1w	3.3/1.2/14	1.6	40	40	256x256	212	33.9	1	153
Thorax	8-channel	2D STIR FSE T2w	11200/ 94/120	2.0	40	40	256x256	170	34.0	1	359
B. Postmortem computed tomography protocol											
Scan area	Rotation time (s)	Tube voltage (kV)	Tube current (eff. mAs)	Slice collimation		Pitch	Reconstruction				
				(mm)	(mm)		Scan time (s)				
Head-Neck	1.0	100	750	2 x 64 x 0.6		0.35	21	FBP			
Thorax-Abdomen	1.0	120	600	2 x 64 x 0.6		0.6	32	FBP			
Extremities	1.0	120	600	2 x 64 x 0.6		0.6	57	FBP			

Table 2. Image-guided biopsy protocol

Organ	Targets aimed at
Brain	Normal parenchyma and suspected pathology
Lungs	Both lungs, normal parenchyma and suspected pathology
Heart	Left ventricle: lateral wall, apex, normal myocardium and suspected pathology Right ventricle: on indication
Kidneys	Both kidneys, normal parenchyma and suspected pathology
Spleen	Sub-capsular parenchyma and suspected pathology
Liver	Normal parenchyma and suspected pathology
Other	Region of interest

Scoring

We composed a scoring list of PMCT and PMMR features of postmortem change (Table 3-5). The features that were included were based on our radiological expertise (9, 10) and were supplemented with features from published postmortem imaging studies. (5, 12, 20-51)

Table 3. Scoring list of PMCT and PMMR features of postmortem changes in the brain

Postmortem imaging feature	Category	Postmortem process
1. Hyperdense superior sagittal sinus	Gravity dependent changes	Blood sedimentation
2. Hyperdense veins	Gravity dependent changes	Blood sedimentation
3. Hyperdense arteries	Gravity dependent changes	Blood sedimentation
4. Thickened / irregular falx	Gravity dependent changes	Blood sedimentation
5. Liquid in paranasal sinus	Decomposition	Cell wall leakage
6. Intracranial air	Decomposition	Putrefaction
7. High T1 signal basal ganglia	Algor mortis	Temperature change
8. Low T2 signal basal ganglia	Algor mortis	Temperature change
9. Diffusion restriction	Algor mortis	Temperature change
10. Insufficient suppression of liquor on Flair	Algor mortis	Temperature change
11. Loss of grey-white matter differentiation	Miscellaneous	Cerebral hypoxia
12. Sulcal effacement	Miscellaneous	Cerebral hypoxia
13. Compression cisterns	Miscellaneous	Cerebral hypoxia
14. Cerebellar tonsillar herniation	Miscellaneous	Cerebral hypoxia

Table 4. Scoring list of PMCT and PMMR features of postmortem changes in the thorax

Postmortem imaging feature	Category	Postmortem process
1. Hyperdense aortic wall	Gravity dependent	Blood sedimentation
2. Sedimentation of blood aorta	Gravity dependent	Blood sedimentation
3. Sedimentation of blood large vessels	Gravity dependent	Blood sedimentation
4. Livores heart	Gravity dependent	Livor mortis
5. Sedimentation of blood heart	Gravity dependent	Blood sedimentation
6. Livores lung	Gravity dependent	Livor mortis
7. Groundglass opacification	Gravity dependent	Livor mortis
8. Increased density dependent areas skin and subcutis	Gravity dependent	Livor mortis
9. Edema dependent areas subcutis	Decomposition / Gravity dependent	Cell wall leakage / Livor mortis
10. Intravascular air	Decomposition	Putrefaction
11. Gas formation heart	Decomposition	Putrefaction
12. Gas formation myocardium	Decomposition	Putrefaction
13. Susceptibility artifacts heart (gas)	Decomposition	Putrefaction
14. Pericardial effusion	Decomposition	Cell wall leakage
15. Pleural effusion	Decomposition	Cell wall leakage
16. Gas formation lung parenchyma	Decomposition	Putrefaction
17. T2 signal decay from subepicardial to subendocardial	Rigor mortis	Rigor mortis
18. Dilated vena cava inferior	Miscellaneous	Loss of blood pressure
19. Postmortem clotting large vessels	Miscellaneous	Clotting
20. Collapse large vessels	Miscellaneous	Loss of blood pressure
21. Dilated heart	Miscellaneous	Loss of blood pressure
22. Dilated right atrium	Miscellaneous	Loss of blood pressure
23. Postmortem clotting heart	Miscellaneous	Clotting
24. Collapse of aorta	Miscellaneous	Loss of blood pressure
25. Postmortem clotting aorta	Miscellaneous	Clotting
26. Dilated vena cava superior	Miscellaneous	Loss of blood pressure
27. Gas formation subcutaneous areas	Decomposition	Putrefaction
28. Liquid trachea / bronchi	Decomposition	Cell wall leakage

Table 5. Scoring list of PMCT and PMMR features of postmortem changes in the abdomen

Postmortem imaging feature	Category	Postmortem process
Intestinal sedimentation	Gravity dependent	Sedimentation
Livores liver	Gravity dependent	Livor mortis
Sedimentation gall bladder	Gravity dependent	Sedimentation
Livores spleen	Gravity dependent	Livor mortis
Livores kidneys	Gravity dependent	Livor mortis
Free air	Decomposition	Putrefaction
Fluid in the abdomen	Decomposition	Cell wall leakage
Gas in the intestinal wall	Decomposition	Putrefaction
Distended intestines	Decomposition	Putrefaction
Gas liver parenchyma	Decomposition	Putrefaction
Air liver vessels	Decomposition	Putrefaction
Gas bile ducts	Decomposition	Putrefaction
Periportal edema	Decomposition	Cell wall leakage
Gas spleen parenchyma	Decomposition	Putrefaction
Gas kidney parenchyma	Decomposition	Putrefaction
Intravascular air	Decomposition	Putrefaction
Collapse aorta	Miscellaneous	Loss of blood pressure
Collapse vena cava	Miscellaneous	Loss of blood pressure
Dilated vena cava	Miscellaneous	Loss of blood pressure

All cases were retrospectively and independently scored by a radiologist (ACW; board-certified with 10 years of clinical expertise in postmortem imaging) and a researcher (IMW with 3 years of expertise). When available, clinical information and antemortem scans were reviewed. Specific clinical conditions were scored; including intensive care unit (ICU) admittance and post-resuscitation status (PRS).

PMCT and PMMR features were – if possible – categorized to a specific chemical and/or physical process; 1. gravity dependent changes; 2. decomposition; 3. rigor mortis; 4. algor mortis. Features that could not be classified to any of these four processes were labeled to a miscellaneous category.

Statistical analyses

We recorded percentage of male/female cases, mean age at death, and mean postmortem time interval (PTI) including standard deviations. PTI was defined as the time from death to the start of MR scanning. For each case, we calculated the frequency of PMCT and PMMR features. Fisher's exact test was used for the association between specific clinical conditions (ICU and PRS) and frequencies of PMCT and PMMR features. Linear discriminant analysis was used to evaluate the correlation of PTI and PMCT and PMMR features. ANOVA was used to test the correlation of PTI and a combination score for all decomposition and all gravity dependent changes. The inter-observer agreement was calculated using kappa statistics (agreement <0.2: poor, 0.2-0.4: fair, 0.4-0.6: moderate, 0.6-0.8: good, and 0.8-1.0: very good). Furthermore, we calculated inter-observer agreement for the group of pathological mimics (those postmortem changes that were most likely to be confused with real pathologic changes) and a group of postmortem changes that does not correspond to a pathologic process with similar radiological features.

Results

We scanned 100 cases from January 2012 to December 2014. The mean age was 62.7 (± 13.0), 62% were male (Table 6). Inter-observer agreement was very good, with a kappa of 0.84 for PMCT and 0.83 for PMMR. The kappa score for the group with pathological mimics was 0.79 for PMCT and 0.76 for PMMR, the kappa score for the non-pathologic mimics was 0.89 for PMCT and 0.88 for PMMR.

Table 6. Patient demographics

Patient demographics (n=100)				
Men/women (n)	62/38			
Mean age (SD, min-max)	62.7 (±13.0, 25-92)			
Mean PTI (SD, min-max)	22.6 (±15.4, 3.1-71.5)			
PRS (n)	43			
Mean image acquisition time	MRI: 59 minutes, CT: 3-4 minutes			
Hospital ward	n			
ICU	38			
ER	15			
Internal medicine / gastroenterology	11			
Oncology	8			
Neurology	6			
Thoracic surgery	5			
Hematology	5			
Pulmonology	5			
General surgery	4			
Gynecology/urology	3			
Antemortem imaging	Not available (n)	CT (n)	MR (n)	CT and MR (n)
Brain	65	26	5	4
Thorax	30	70	0	0
Abdomen	31	67	0	2

Legend to table 6: SD = standard deviation; PTI = postmortem time interval (hours); PRS = post-resuscitation status; ICU = intensive care unit; ER = emergency room; CT = computed tomography, MR = magnetic resonance

Total-body CT and MR features of postmortem change – general overview
PMCT and PMMR features of different organs and observed frequencies are presented in Table 7-9.

Table 7. Frequencies of postmortem PMCT and PMMR features of the brain

PMCT and PMMR features of brain (n=100)		
	PMCT	PMMR
Loss of grey-white matter differentiation	85%	85%
Hyperdensity superior sagittal sinus	96%	NA
Hyperdensity veins	54%	NA
Sulcal effacement	44%	41%
Hyperdensity Willis' circle and cerebral arteries	35%	NA
Liquid paranasal sinuses	32%	32%
High T1 signal basal ganglia and thalamus	NA	32%
Thickened / irregular aspect falx	20%	NA
Intracranial air cerebral vasculature	8%	1%

Legend to Table 7: PMCT = postmortem computed tomography; PMMR = postmortem magnetic resonance; NA = not assessable

Table 8. Frequencies of postmortem PMCT and PMMR features of thorax

PMCT and PMMR features of thorax (n=100)		
	PMCT	PMMR
Heart and large vessels		
Air heart	44%	22%
Sedimentation of blood heart	62%	84%
Dilatation right atrium and ventricle	25%	25%
Pericardial effusion	26%	27%
T2 signal decay epi- to endocardial	NA	12%
Postmortem clotting heart	4%	8%
Air pericardial space	4%	2%
Air coronaries	18%	12%
Hyperdense aortic wall	90%	NA
Sedimentation in blood vessels	71%	88%
Postmortem clotting vessels	25%	38%
Intravascular air	31%	8%
Collapse of thoracic aorta	30%	29%
Lungs		
Internal livores	86%	85%
Pleural effusion	31%	38%
Liquid trachea / main bronchi	78%	78%

Legend to Table 8: PMCT = postmortem computed tomography; PMMR = postmortem magnetic resonance; NA = not assessable

Table 9. Frequencies of postmortem PMCT and PMMR features of the abdomen

PMCT and PMMR features of abdomen (n=100)		
Liver, gallbladder, spleen and kidney	PMCT	PMMR
Gas liver vasculature	37%	26%
Internal livores liver	NA	74%
Sedimentation gallbladder	8%	14%
Periportal edema	11%	27%
Internal livores spleen	NA	31%
Gas spleen parenchyma or vessels	5%	1%
Internal livores kidneys	NA	6%
Gas kidney parenchyma or vessels	9%	1%
Stomach, intestines, abdominal cavity	PMCT	PMMR
Intestinal sedimentation	6%	15%
Gas in the intestinal wall	8%	1%
Distended intestines	14%	14%
Free air	7%	2%
Fluid in the abdomen	20%	35%
Abdominal vessels	PMCT	PMMR
Intravascular air	21%	5%
Collapse abdominal aorta	67%	67%
Collapse abdominal vena cava	53%	53%
Dilated abdominal vena cava	2%	2%
Air vertebral venous plexus	11%	2%

Legend to Table 9: PMCT = postmortem computed tomography; PMMR = postmortem magnetic resonance; NA = not assessable

Brain

Sedimentation led to increased attenuation of the posterior sagittal sinus (96%), cerebral veins (54%) and cerebral arteries (35%) in a symmetric distribution (Figure 1A-B). Putrefactive gas in the brain was seen in only a few cases (8%). Liquefaction of the brain was not observed.

PMMR showed high T1 signal of the basal ganglia in one third of cases (Figure 1C). Effacement of sulci (Figure 1D) and loss of grey-white matter differentiation was seen in the majority of cases (85%) (Figure 1E-1F).

Heart and large vessels

The right atrium and ventricle were dilated in 25% (Figure 2A). The thoracic aorta showed clotting in 38% of cases and was detected best on PMMR (Figure 2B). Air in the heart chambers was seen in 44% (Figure 2C-D). No air was observed within the myocardium. T2 signal decline in the myocardium from the epicardial to endocardial regions was seen in 12% (Figure 2A). We observed a collapse of the thoracic aorta in 30% (Figure 2E). Sedimentation of blood was often present in the heart (84%) (Figure 2A) and large thoracic vessels (Figure 2F). The thoracic aortic wall showed increased attenuation in a majority of cases (90%) (Figure 2G). The abdominal aorta was collapsed in 67% and the abdominal vena cava in 53% (Figure 2H). Air in the vertebral venous plexus was seen less frequently (11%), and usually in cases with extensive intravascular air.

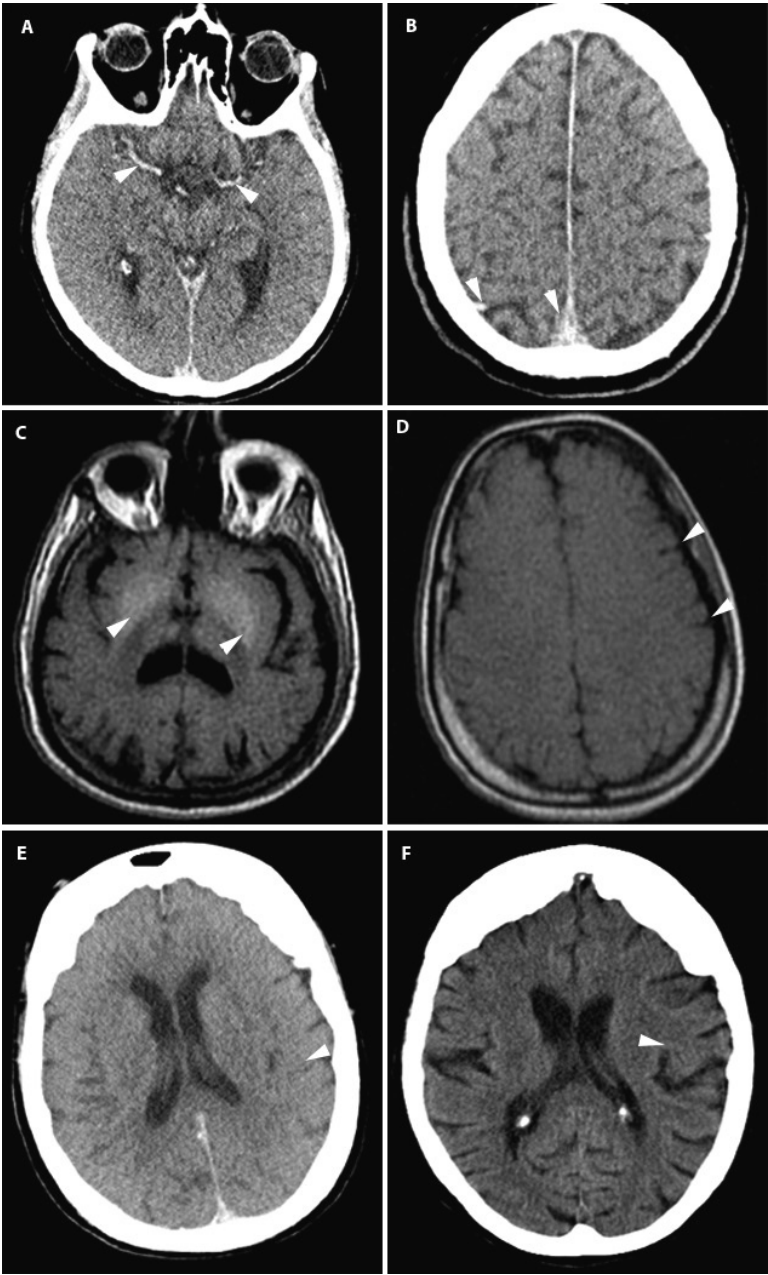


Figure 1: Postmortem imaging features of the brain. (A) PMCT: Symmetrical hyperdense cerebral arteries (arrowheads). (B) PMCT: Hyperdensity in the dependent cerebral veins and sagittal sinus (arrowheads). (C) T1w PMMR: High signal of the basal nuclei of the brain (arrowheads). (D) T1w PMMR: Sulcal effacement (arrowheads). (E/F) PMCT (E) and antemortem CT (F) of the same patient. The antemortem CT scan shows normal grey-white matter differentiation (arrowhead). PMCT shows complete loss of grey-white matter differentiation (arrowhead).

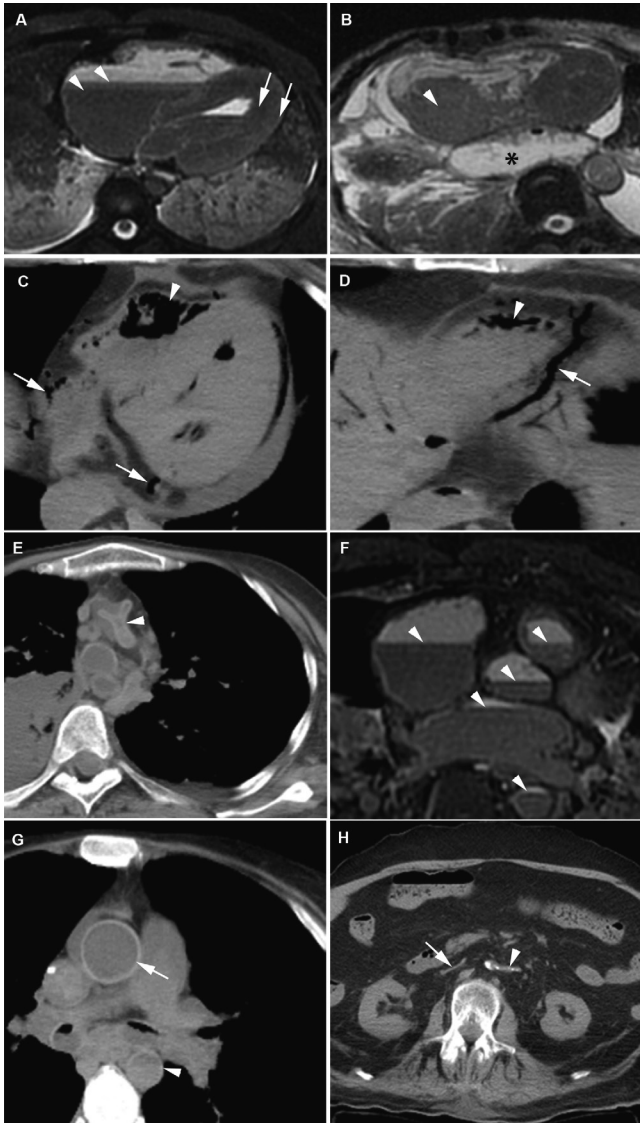


Figure 2: Postmortem imaging features of the heart and large vessels. (A) T2w PMMR: Sedimentation of blood in the heart chambers (arrowhead). T2 signal decay from subepicardial to subendocardial myocardium (arrows). (B) T2w PMMR: Postmortem clotting in the right atrium (arrowhead). Additional finding: a mediastinal herniation of the stomach (asterisk). (C/D) PMCT: Extensive air in the right and left ventricle (arrowheads) and coronary veins (arrows). (E) PMCT: Collapsed ascending aorta (arrowhead). (F) T2w PMMR: Sedimentation of the blood (arrowheads), the plasma layer becomes hyperintense and the dependent layer becomes hypointense. (G) PMCT: Relatively hyperdense aortic wall (arrow) as a result of sedimentation. This is best seen in the ascending aorta. The descending aorta shows a sedimentation level with a hyperdense aspect of the anterior vessel wall (arrowhead). (H) PMCT: Complete collapse of the abdominal aorta (arrowhead) and vena cava inferior (arrow).

Lungs

Livor mortis affected the lungs frequently (86%); it appeared as areas with increased density or high T2 signal in the dependent areas of the lungs. In these parts of the lung it is challenging to distinguish livores from pneumonia (Figure 3A-I) or other interstitial diseases. Liquid in the trachea and bronchi was very common (78%). Pleural effusion was seen in only 38% of cases.

Liver, spleen, kidneys, gallbladder, pancreas, adrenals

Internal livores of the spleen and kidney were noted by two layers of different T1 and T2 signal reflecting blood settling in the parenchyma. In the liver, three layers can be seen: an upper layer with small amounts of putrefactive gas, a middle layer with intermediate signal and a lower layer that together with the middle layer reflect settling of blood (Figure 4A-F). Gravity can cause sedimentation of the gallbladder content and this is best seen on PMMR as vertical signal gradients. Livor mortis in organ parenchyma (spleen 31%, kidneys 6% and liver 74%) was also best depicted on PMMR and presented as different layers of T1 and T2 signal. In general, livores of the organ parenchyma were not clearly detectable on PMCT. Periportal edema was found on PMMR in 27% (Figure 5A). Putrefaction gas in the liver vasculature was seen on PMCT in 37% (Figure 5B). The imaging features of the pancreas and adrenal glands were not notably affected by postmortem change.

Stomach, intestines, abdominal cavity

Sedimentation in the stomach and intestines was seen in only a few cases (15%). Fluid in the abdomen was present in 35%. Bowel distension (14%), gas in the intestinal wall (8%) and free abdominal air (7%) were less common features (Figure 5C-F).

Soft tissues

On PMCT superficial internal livor mortis was manifested as increased densities of the dependent subcutaneous areas (37%). (12) Putrefactive gas in subcutaneous tissue was not observed.

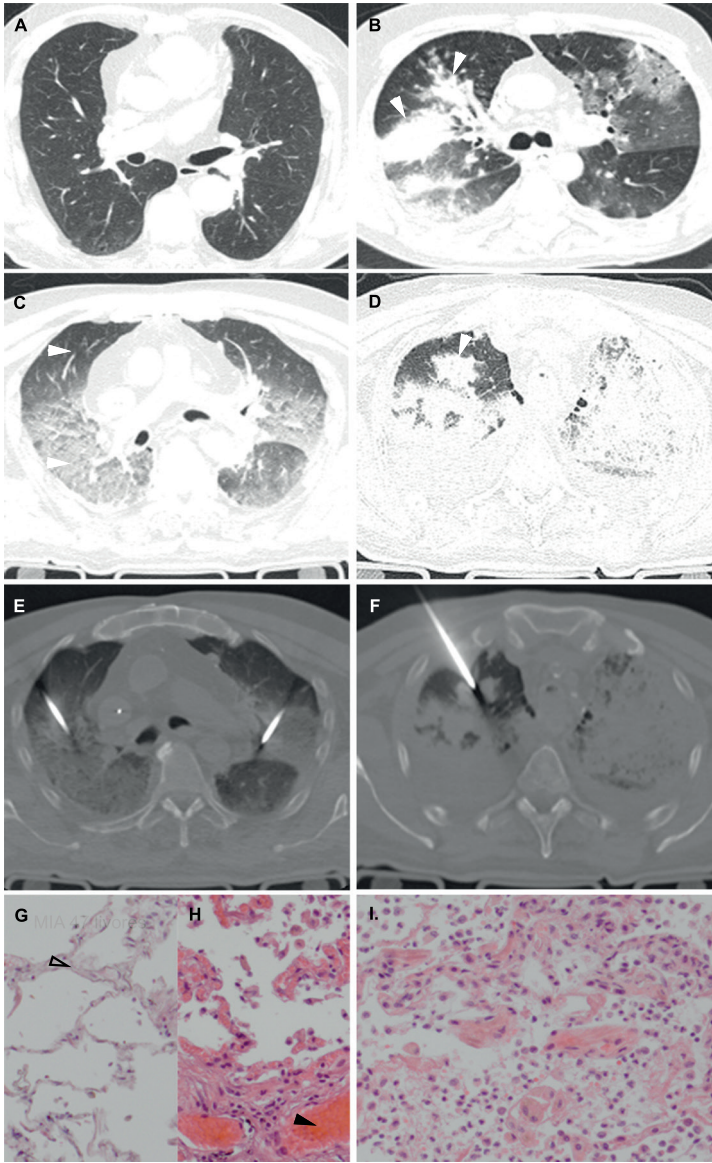


Figure 3: Internal livores of the lungs versus pneumonia. (A/C) antemortem CT (A) and PMCT (C). Normal (A) and internal livores (C) (arrowheads). (B/D) antemortem CT (B) and PMCT (D). Patient with a pneumonia (arrowheads). (E) CT-guided lung biopsies in the same patient as A/C. (F) CT-guided lung biopsy in the same patient as B/D. (G) HE, x100 original magnification. Lung parenchyma non-dependent: capillaries in alveolar walls practically devoid of blood (arrowhead). (H) HE, x100 original magnification. Same patient as G, lung parenchyma dependent, capillaries in alveolar walls congested with blood (arrowhead). (I) HE, x100 original magnification. Same patient as B/D/F, lung parenchyma, resolving pneumonia with thickened alveolar walls with mainly lymphocytic infiltrates, and hyaline membranes and extravasations of erythrocytes in the alveolar spaces.

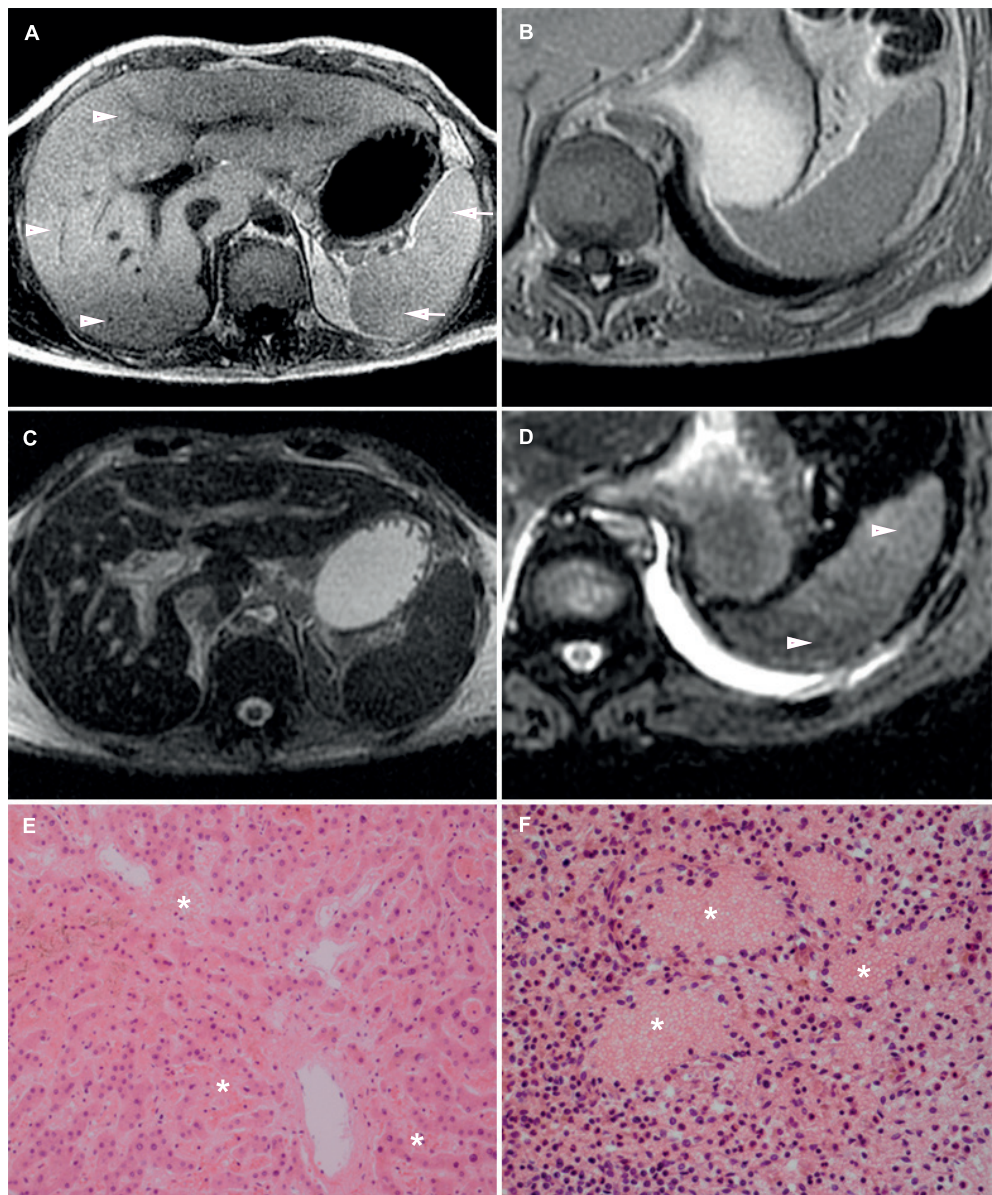


Figure 4: Internal livores of the liver and spleen. (A/C) T1w (A) and T2w fs (C) PMMR. Internal livores. In the liver 3 distinct layers (arrowheads) of different T1 signal can be seen and in the spleen 2 layers (arrows). A low T1 signal layer on top, relatively intermediate-to high signal layer in the middle and a low T1 signal layer in the dependent part of the liver. On T2w fs internal livores are not clearly seen. (B/D) T1w (B) and T2w fs (D) PMMR. The spleen shows 2 layers of different T2 signal (arrowheads). T1w show no clear livores in this patient. (E) HE, x100 original magnification. Centrilobular area of the liver with wide sinuses extended by blood (asterisks). (F) HE, x200 original magnification. Congested spleen with lakes of blood (asterisks).

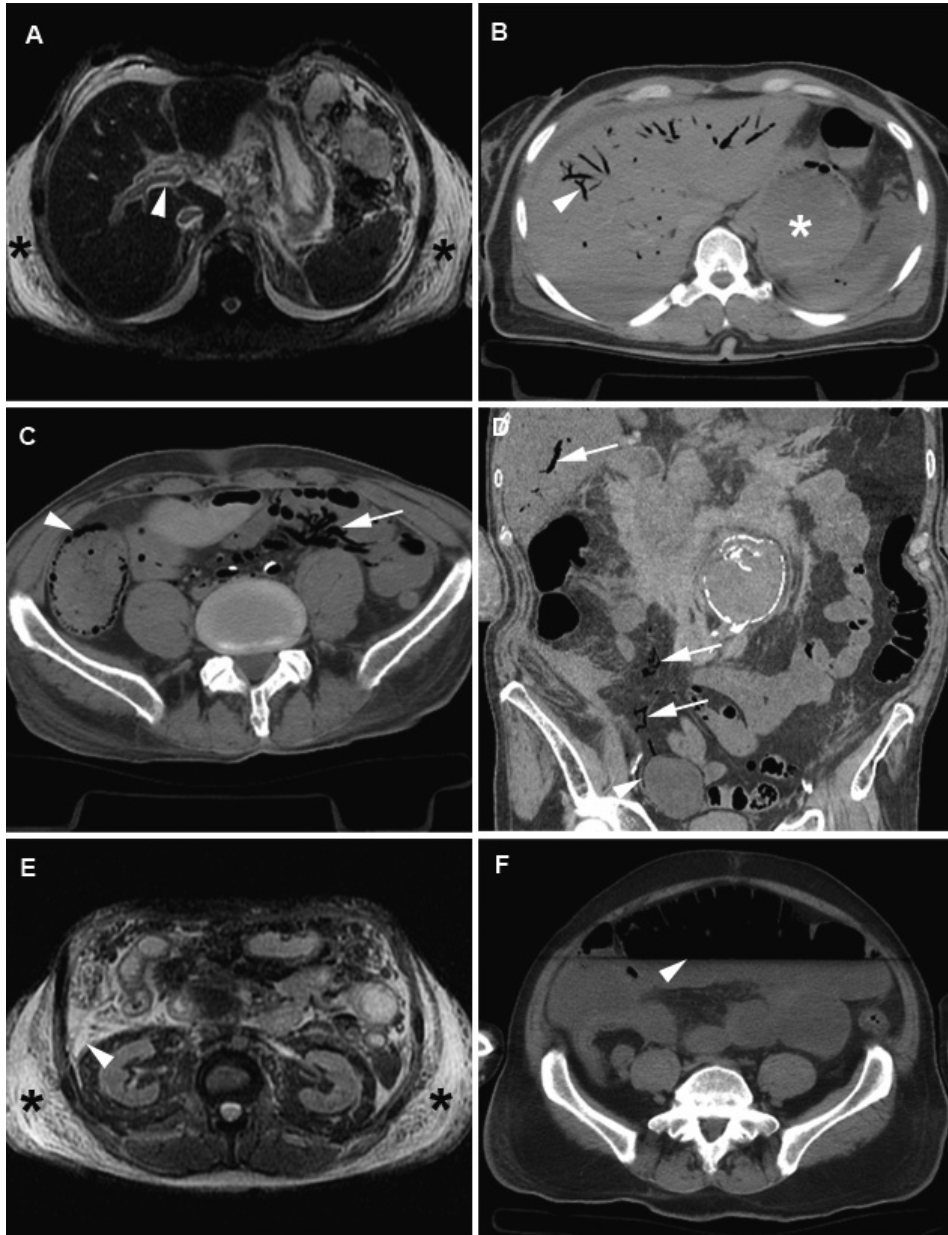


Figure 5: Postmortem imaging features of the abdomen. (A) T2w PMMR: Periportal edema (arrowhead) and subcutaneous edema (asterisks). (B) PMCT: Putrefactive gas in the liver vessels (arrowhead) and distended stomach (asterisk). (C/ D) PMCT: Gas in the intestinal wall (arrowhead) and air in the mesenteric and portal veins (arrows). (E) T2w PMMR: Subcutaneous edema (asterisks) and fluid in the abdomen (arrowhead). (F) PMCT: Distended intestines with a sharp fluid-air level (arrowhead).

Total-body CT and MR features of postmortem change – in relation to clinical conditions and postmortem time interval

Intensive care unit admittance

In our cohort 38/100 patients died in the ICU. Livores of the liver was seen significantly more often in ICU patients than in non-ICU patients (92% vs. 62%, $p=0.001$) (Table 10). High T1 signal of the basal ganglia was significantly less frequently observed in ICU patients (44% vs. 13 %, $p=0.001$).

Post-resuscitation status

Forty-three patients underwent unsuccessful resuscitation just prior to death. Pleural effusion ($p<0.001$) and periportal edema ($p=0.001$) were seen significantly more often in patients that had undergone resuscitation (Table 10). Postmortem clotting occurred significantly less frequently in patients that had underwent resuscitation ($p=0.002$). Intravascular air (both arterial and venous) was visible in 58% of patients and more frequently present in PRS patients than in non-PRS patients (72% vs. 47%, $p=0.013$).

Postmortem time interval

The mean PTI was 23.0 (± 15.6) hours. PTI showed a significant correlation with internal livores of the lungs ($p=0.038$), distended intestines ($p=0.001$) and loss of grey-white matter differentiation in the brain ($p<0.001$) (Table 11). PTI showed a significant correlation with postmortem changes related to decomposition ($p=0.026$).

Table 10. Postmortem CT and MR features in relation to clinical conditions

Clinical condition	Modality*	Yes	No	Total	P-value
Intensive care unit admittance		N=38	N=62	N=100	
Hyperdense cerebral arteries	PMCT	17 (45%)	18 (29%)	35 (35%)	0.133
High T1 signal basal ganglia	PMMR	5 (13%)	27 (44%)	32 (32%)	0.002
Postmortem clotting	PMMR	21 (55%)	23 (37%)	44 (44%)	0.098
Subcutaneous edema	PMMR	17 (45%)	20 (32%)	37 (37%)	0.286
Fluid in the abdomen	PMMR	17 (45%)	18 (29%)	35 (35%)	0.133
Livores liver	PMMR	35 (92%)	39 (63%)	74 (74%)	0.001
Livores spleen	PMMR	10 (26%)	21 (34%)	31 (31%)	0.507
PRS		N=43	N=57	N=100	
Pleural effusion	PMMR	25 (58%)	13 (23%)	38 (38%)	<0.001
Periportal edema	PMMR	19 (44%)	8 (14%)	27 (27%)	0.001
Distended intestines	PMCT/PMMR	9 (21%)	5 (9%)	14 (14%)	0.144
Postmortem clotting	PMMR	11 (26%)	33 (58%)	44 (44%)	0.002
Dilated right atrium / ventricle	PMCT/PMMR	15 (35%)	10 (18%)	25 (25%)	0.063
Intravascular air	PMCT	31 (72%)	27 (47%)	58 (58%)	0.015

*Specifies the modality that has the highest detection of the postmortem changes

Legend to Table 10: PMCT = postmortem computed tomography; PMMR = postmortem magnetic resonance; PRS = post-resuscitation status

Table 11. Postmortem CT and MR features in relation to postmortem time interval

Postmortem time interval	Modality*	<12 hours N=25	12-24 hours N=37	24-48 hours N=28	>48 hours N=10	Total N=100	P-value
Intravascular air	PMCT	14 (56%)	23 (62%)	16 (57%)	5 (50%)	58 (58%)	0.905
Sedimentation blood	PMMR	24 (96%)	35 (95%)	28 (100%)	10 (100%)	97 (97%)	0.416
Loss of grey-white matter differentiation	PMCT/PMMR	14 (56%)	33 (89%)	28 (100%)	10 (100%)	85 (85%)	<0.001
Distended intestines	PMCT/PMMR	0 (0%)	4 (11%)	7 (25%)	3 (30%)	14 (14%)	0.001
Postmortem clotting	PMMR	6 (24%)	20 (54%)	12 (43%)	6 (60%)	44 (44%)	0.197
Livores lungs	PMCT/PMMR	20 (80%)	30 (81%)	26 (93%)	10 (100%)	86 (86%)	0.038
Livores liver	PMMR	17 (68%)	27 (73%)	25 (89%)	5 (50%)	74 (74%)	0.805
Livores spleen	PMMR	5 (20%)	11 (30%)	10 (35%)	5 (50%)	31 (31%)	0.062
Gravity dependent changes	PMCT/PMMR	50%	47%	51%	56%	50%	0.094
Decomposition	PMCT/PMMR	23%	30%	29%	34%	28%	0.026

*Specifies the modality that has the highest detection of the postmortem change
Legend to Table 11: PMCT = postmortem computed tomography; PMMR = postmortem magnetic resonance

Discussion

This is the first study evaluating the frequency of PMCT and PMMR features of postmortem change in a large cohort of adult patients. Similar imaging studies on postmortem change in fetuses and neonates have been published. (13, 52). We observed a wide variety of PMCT and PMMR features of postmortem change. Particularly livor mortis and decomposition have great impact on the imaging features. Algor mortis and rigor mortis lead to only minor changes. Our results indicate that PMCT and PMMR appear to be complementary for correct interpretation of postmortem changes. Some changes are more clearly seen on PMMR such as livores of organ parenchyma or blood clotting, while others such as the presence and distribution of putrefaction air is better noted on PMCT.

Clinical conditions may influence imaging features of postmortem change. Importantly, postmortem changes may mimic or even mask real pathological changes related to the cause of death: e.g. gravity causes sedimentation of blood contents within the first hours after death. On PMCT the upper (plasma) and lower layer (blood cells) shows decreased and increased attenuation respectively. As a result the upper part of the aortic wall shows relatively high attenuation compared to the plasma content and may mimic aortic wall hematoma (Figure 2G).

Bacterial infections can speed decomposition processes and increase gas and fluid formation in the body. Hypovolemia causes the heart cavities and vessel lumen to decrease in size.

Medical treatments can also change imaging features; e.g. intravascular lines and surgical wounds can be accompanied by air in the surrounding soft tissues and bloodstream.

Resuscitation can cause rib fractures, pneumothorax, lung contusions, hemothorax, and intravascular air. We found that the majority of PRS patients showed significantly more intravascular air as opposed to non-PRS patients, suggesting that air was introduced during resuscitation. (12, 27, 53, 54) Intravascular air after resuscitation is caused by pneumatization of dissolved gas in the blood as a result of compression and expansion of vessels and direct mechanical force to the chest allowing air from the lungs to enter the bloodstream. (55, 56) Likewise resuscitation attempts may introduce free abdominal air that should not be confused with free air caused by intestinal perforation. (13) Pleural effusion, periportal edema, and distended intestines were also more frequently observed after resuscitation. Postmortem clotting occurred less often in PRS patients and we hypothesize this is caused by anti-coagulation given during resuscitation attempts. (12, 27, 53, 54)

Lack of oxygenation in the brain was noted by loss of grey- white matter differentiation, edema, swelling of the brain and effacement of sulci. (23, 57, 58) These features involve the entire brain and are symmetrical. (14, 23) Patients with elevated intracranial pressure prior to death may show similar features, and comparison to antemortem scans is recommended. In living patients a dense-artery-sign in the cerebral arteries is often

asymmetric and indicative for cerebral ischemia, a postmortem mimic of this sign is usually symmetrical and is non-pathological (Figure 1A). The cessation of cardiac output and fall in blood pressure causes the arterial wall to collapse directly after death. (30, 59) This change may obscure an aortic aneurysm or dissection. Within 2 hours after death blood clots form in the heart and large vessels.

Postmortem clots are best detected on PMMR; the clot shows low T2 signal relative to the high T2 signal of the serum. A postmortem clot can often be distinguished from a central pulmonary embolism that shows a more homogeneous high T1 signal (Figure 6A-J). Other distinctive features of postmortem clots are that they are seen in the dependent areas of the vessel, usually fill only part of the lumen and do not expand the lumen. With pulmonary embolism the thrombus follows the blood stream until it reaches a point where the lumen becomes too narrow or the vessel branches. The shape of a postmortem clot is often more irregular than a thrombus (Figure 6C-D). (60) If clinically relevant, a CT-guided biopsy may help differentiate between postmortem clotting and pulmonary embolism.

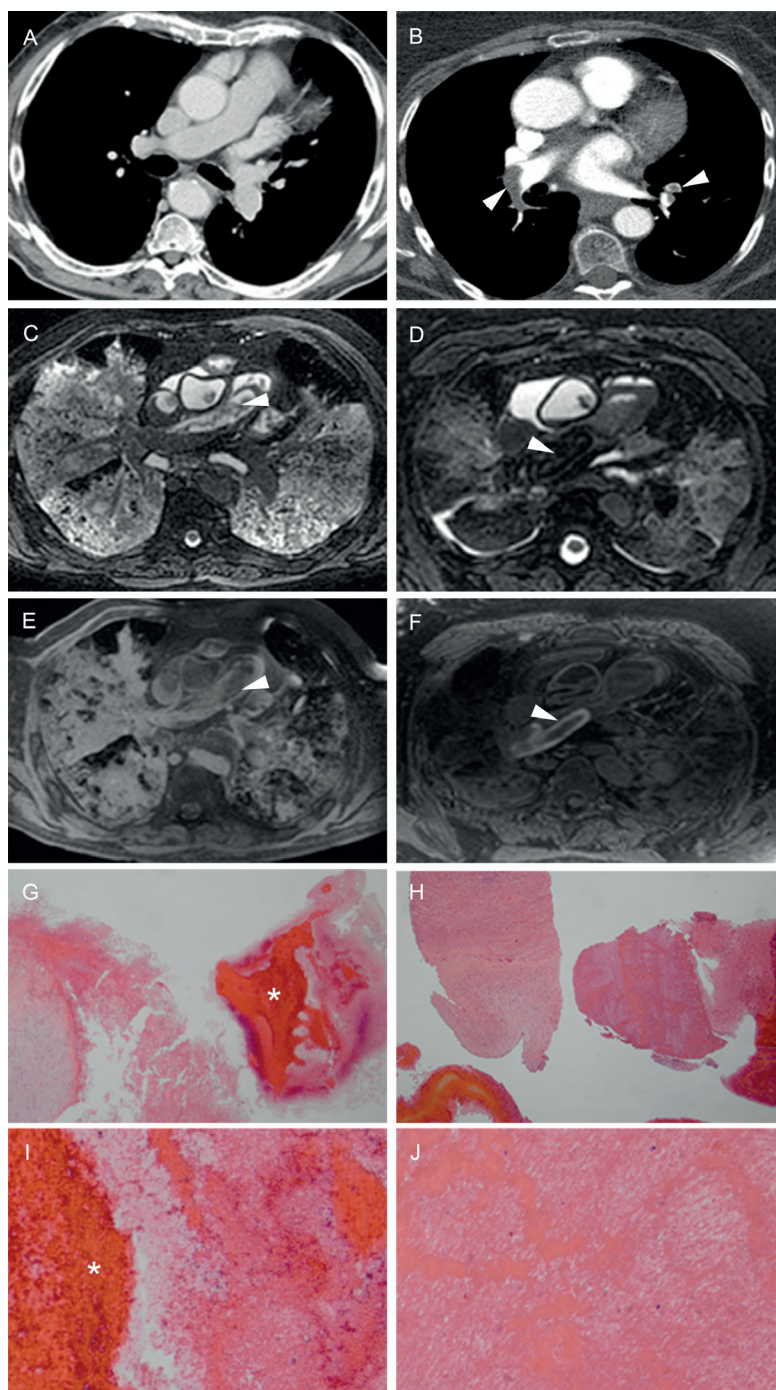


Figure 6: Pulmonary thrombo-embolism versus postmortem blood clot. (A/C/E) Antemortem CT (A) and T2w (C) and T1w (E) PMMR in the same patient. Antemortem CT (A) shows no abnormalities in the pulmonary arteries. PMMR (C/E) shows an irregularly shaped clot in the right pulmonary artery (C:

arrowhead), with low T1 signal (E: arrowhead). (B/D/F) Antemortem CTA (B) and T2w (D) and T1w (F) PMMR in a patient with a thrombo-embolus. Antemortem CTA (B) shows a thrombo-embolus in the right and left pulmonary artery (arrowheads). PMMR (D/F) shows a thrombo-embolus in the right pulmonary artery (arrowheads). (G) HE, x16 original magnification, corresponding to image A/C/E. Wall of right pulmonary artery with a postmortem blood clot (asterisk). (I) HE, x50 original magnification, corresponding to image A/C/E. Higher power of blood clot showing blood with loosely arranged depositions of fibrin. (H) HE, x16 original magnification, corresponding to image B/D/F. Wall of pulmonary artery and thrombus. (J) HE, x50 original magnification, corresponding to image B/D/F. Wall of pulmonary artery and thrombus with dense depositions of fibrin and platelets, alternating with degenerated erythrocytes and white blood cells, thus constituting so-called lines of Zahn.

In this study we investigated in-hospital deceased adult deaths. The mean PTI was relatively short and bodies were stored in a protected environment after death, PTI seem to have an impact on the occurrence and extent of specific changes.

Autolysis occurs early after death. It leads to significant changes that can be noted at microscopic examination of tissues obtained at biopsy, in particular of the pancreas and adrenal glands. (12, 61) However, in our cohort imaging features of these organs seem less affected by autolysis. Imaging features related to decomposition were seen more frequently. There was tendency to more extensive livores of the lungs with longer PTI and the livores can become so extensive as to completely consolidate the lung parenchyma. In such cases, accurate diagnosis of underlying parenchymal disease can be challenging. In such cases we highly recommend to biopsy both normal and suspected parts of parenchyma to reliably differ postmortem changes from infection (Figure 3A-I), hemorrhage, or tumor. (13, 14, 62, 63)

The distribution of putrefactive gas also differs with a different PTI, first occurring in the heart cavities and large vessels and with longer intervals in the smaller vessels, organ parenchyma and soft tissues. Putrefactive gas must be differentiated from pathological air collections, such as soft tissue emphysema, free air or gas in the intestinal wall. Putrefactive gas usually has an intestinal origin and travels through the mucosa to the portal veins in the early stage. It may mimic air embolism, however the latter will show a more equal distribution throughout the vascular system. (14) Intestinal bacteria continue to produce gas after death causing bowel distension. The amount of intestinal air significantly increases with longer PTI. This may look similar to a bowel obstruction or paralysis, and should be carefully evaluated. With longer PTI, putrefaction can also lead to formation of subcutaneous air.

Our study had several limitations. We composed a scoring list of postmortem imaging features that may not be complete and some features may be missing. We did not measure body temperature during scanning. Ideally, body temperature should be monitored to allow adaption of MR scan parameters to temperature variations to achieve optimal tissue

contrast. However all bodies were stored at the morgue at a constant temperature of 5 degrees Celsius prior to scanning and the transit time from the morgue to the MR scanner was equal for all cases.

We optimized MR sequences for scanning of cold corpses. Furthermore the scan time was maintained approximately the same for all scanning sessions while the temperature in the scanning room was kept constant.

Conclusion

There is a wide variety of imaging features of postmortem change in in-hospital deaths. These imaging features vary among clinical conditions, increase with longer PTI and must be distinguished from pathologic changes.

References

1. Burton JL, Underwood J. Clinical, educational, and epidemiological value of autopsy. *Lancet*. 2007;369(9571):1471-80.
2. Gaensbacher S, Waldhoer T, Berzlanovich A. The slow death of autopsies: a retrospective analysis of the autopsy prevalence rate in Austria from 1990 to 2009. *Eur J Epidemiol*. 2012;27(7):577-80.
3. Turnbull A, Martin J, Osborn M. The death of autopsy? *Lancet*. 2015;386(10009):2141.
4. Shojania KG, Burton EC, McDonald KM, Goldman L. Changes in rates of autopsy-detected diagnostic errors over time: a systematic review. *JAMA*. 2003;289(21):2849-56.
5. Roberts IS, Benamore RE, Benbow EW, Lee SH, Harris JN, Jackson A, et al. Post-mortem imaging as an alternative to autopsy in the diagnosis of adult deaths: a validation study. *Lancet*. 2012;379(9811):136-42.
6. Burke M, O'Donnell C. Postmortem Computed Tomography Findings in Ruptured Splenic Artery Aneurysm: Value of the Clinical "Sentinel Clot" Sign in Identification of Bleeding Location. *Am J Forensic Med Pathol*. 2015;36(3):224-6.
7. Thali MJ, Jackowski C, Oesterhelweg L, Ross SG, Dirnhofner R. VIRTopsy - the Swiss virtual autopsy approach. *Leg Med (Tokyo)*. 2007;9(2):100-4.
8. Thali MJ, Braun M, Buck U, Aghayev E, Jackowski C, Vock P, et al. VIRTopsy--scientific documentation, reconstruction and animation in forensic: individual and real 3D data based geo-metric approach including optical body/object surface and radiological CT/MRI scanning. *J Forensic Sci*. 2005;50(2):428-42.
9. Weustink AC, Hunink MG, van Dijke CF, Renken NS, Krestin GP, Oosterhuis JW. Minimally invasive autopsy: an alternative to conventional autopsy? *Radiology*. 2009;250(3):897-904.
10. Blokker BM, Wagenveld IM, Weustink AC, Oosterhuis JW, Hunink MG. Non-invasive or minimally invasive autopsy compared to conventional autopsy of suspected natural deaths in adults: a systematic review. *Eur Radiol*. 2016;26(4):1159-79.
11. Eriksson A, Gustafsson T, Höistad M, Hultcrantz M, Jacobson S, Mejare I, et al. Diagnostic accuracy of postmortem imaging vs autopsy - A systematic review. *European Journal of Radiology*. 2017;89:249-69.
12. Charlier P, Carlier R, Roffi F, Ezra J, Chaillot PF, Duchat F, et al. Postmortem abdominal CT: assessing normal cadaveric modifications and pathological processes. *Eur J Radiol*. 2012;81(4):639-47.
13. Klein WM, Bosboom DG, Koopmanschap DH, Nievelstein RA, Nikkels PG, van Rijn RR. Normal pediatric postmortem CT appearances. *Pediatr Radiol*. 2015;45(4):517-26.
14. Flach PM, Thali MJ, Germerott T. Times have changed! Forensic radiology--a new challenge for radiology and forensic pathology. *AJR Am J Roentgenol*. 2014;202(4):W325-34.
15. Kobayashi M, Takatori T, Iwade K, Nakajima M. Reconsideration of the sequence of rigor mortis through postmortem changes in adenosine nucleotides and lactic acid in different rat muscles. *Forensic Sci Int*. 1996;82(3):243-53.

16. Krompecher T. Experimental evaluation of rigor mortis. V. Effect of various temperatures on the evolution of rigor mortis. *Forensic Sci Int.* 1981;17(1):19-26.
17. Ampanozi G, Hatch GM, Flach PM, Thali MJ, Ruder TD. Postmortem magnetic resonance imaging: Reproducing typical autopsy heart measurements. *Leg Med (Tokyo).* 2015;17(6):493-8.
18. Shiotani S, Kohno M, Ohashi N, Yamazaki K, Nakayama H, Watanabe K, et al. Dilatation of the heart on postmortem computed tomography (PMCT): comparison with live CT. *Radiat Med.* 2003;21(1):29-35.
19. Zech WD, Schwendener N, Persson A, Warntjes MJ, Jackowski C. Temperature dependence of postmortem MR quantification for soft tissue discrimination. *Eur Radiol.* 2015;25(8):2381-9.
20. Roberts IS, Benbow EW, Bisset R, Jenkins JP, Lee SH, Reid H, et al. Accuracy of magnetic resonance imaging in determining cause of sudden death in adults: comparison with conventional autopsy. *Histopathology.* 2003;42(5):424-30.
21. Dirnhofer R, Jackowski C, Vock P, Potter K, Thali MJ. VIRTOPSY: minimally invasive, imaging-guided virtual autopsy. *Radiographics.* 2006;26(5):1305-33.
22. Yamazaki K, Shiotani S, Ohashi N, Doi M, Honda K. Hepatic portal venous gas and hyperdense aortic wall as postmortem computed tomography finding. *Leg Med (Tokyo).* 2003;5 Suppl 1:S338-41.
23. Christe A, Flach P, Ross S, Spendlove D, Bolliger S, Vock P, et al. Clinical radiology and postmortem imaging (Virtopsy) are not the same: Specific and unspecific postmortem signs. *Leg Med (Tokyo).* 2010;12(5):215-22.
24. Jackowski C, Hofmann K, Schwendener N, Schweitzer W, Keller-Sutter M. Coronary thrombus and peracute myocardial infarction visualized by unenhanced postmortem MRI prior to autopsy. *Forensic Sci Int.* 2012;214(1-3):e16-9.
25. Scholing M, Saltzherr TP, Fung Kon Jin PH, Ponsen KJ, Reitsma JB, Lameris JS, et al. The value of postmortem computed tomography as an alternative for autopsy in trauma victims: a systematic review. *Eur Radiol.* 2009;19(10):2333-41.
26. Egger C, Vaucher P, Doenz F, Palmiere C, Mangin P, Grabherr S. Development and validation of a postmortem radiological alteration index: the RA-Index. *Int J Legal Med.* 2012;126(4):559-66. d
27. Egger C, Bize P, Vaucher P, Mosimann P, Schneider B, Dominguez A, et al. Distribution of artifactual gas on post-mortem multidetector computed tomography (MDCT). *Int J Legal Med.* 2012;126(1):3-12.
28. Hyodoh H, Sato T, Onodera M, Washio H, Hasegawa T, Hatakenaka M. Vascular measurement changes observed using postmortem computed tomography. *Jpn J Radiol.* 2012;30(10):840-5.
29. Jackowski C, Grabherr S, Schwendener N. Pulmonary thrombembolism as cause of death on unenhanced postmortem 3T MRI. *Eur Radiol.* 2013;23(5):1266-70.

30. Jackowski C, Thali M, Aghayev E, Yen K, Sonnenschein M, Zwygart K, et al. Postmortem imaging of blood and its characteristics using MSCT and MRI. *Int J Legal Med.* 2006;120(4):233-40.
31. Kobayashi T, Shiotani S, Kaga K, Saito H, Saotome K, Miyamoto K, et al. Characteristic signal intensity changes on postmortem magnetic resonance imaging of the brain. *Jpn J Radiol.* 2010;28(1):8-14.
32. Levy AD, Harcke HT, Getz JM, Mallak CT, Caruso JL, Pearse L, et al. Virtual autopsy: two- and three-dimensional multidetector CT findings in drowning with autopsy comparison. *Radiology.* 2007;243(3):862-8.
33. Takahashi N, Satou C, Higuchi T, Shiotani M, Maeda H, Hirose Y. Quantitative analysis of intracranial hypostasis: comparison of early postmortem and antemortem CT findings. *AJR Am J Roentgenol.* 2010;195(6):W388-93.
34. Scheurer E, Lovblad KO, Kreis R, Maier SE, Boesch C, Dirnhofer R, et al. Forensic application of postmortem diffusion-weighted and diffusion tensor MR imaging of the human brain in situ. *AJNR Am J Neuroradiol.* 2011;32(8):1518-24.
35. Smith AB, Lattin GE, Jr., Berran P, Harcke HT. Common and expected postmortem CT observations involving the brain: mimics of antemortem pathology. *AJNR Am J Neuroradiol.* 2012;33(7):1387-91.
36. Jackowski C, Schweitzer W, Thali M, Yen K, Aghayev E, Sonnenschein M, et al. Virtopsy: postmortem imaging of the human heart in situ using MSCT and MRI. *Forensic Sci Int.* 2005;149(1):11-23.
37. Jackowski C, Christe A, Sonnenschein M, Aghayev E, Thali MJ. Postmortem unenhanced magnetic resonance imaging of myocardial infarction in correlation to histological infarction age characterization. *Eur Heart J.* 2006;27(20):2459-67.
38. Thali MJ, Yen K, Schweitzer W, Vock P, Ozdoba C, Dirnhofer R. Into the decomposed body-forensic digital autopsy using multislice-computed tomography. *Forensic Sci Int.* 2003;134(2-3):109-14.
39. Eggen MD, Swingen CM, Iuzzo PA. Ex vivo diffusion tensor MRI of human hearts: relative effects of specimen decomposition. *Magn Reson Med.* 2012;67(6):1703-9.
40. Jackowski C, Schwendener N, Grabherr S, Persson A. Post-mortem cardiac 3-T magnetic resonance imaging: visualization of sudden cardiac death? *J Am Coll Cardiol.* 2013;62(7):617-29.
41. Crooijmans HJ, Ruder TD, Zech WD, Somaini S, Scheffler K, Thali MJ, et al. Cardiovascular magnetization transfer ratio imaging compared with histology: a postmortem study. *J Magn Reson Imaging.* 2014;40(4):915-9.
42. Shiotani S, Kohno M, Ohashi N, Yamazaki K, Nakayama H, Watanabe K, et al. Non-traumatic postmortem computed tomographic (PMCT) findings of the lung. *Forensic Sci Int.* 2004;139(1):39-48.
43. O'Donnell C, Woodford N. Post-mortem radiology--a new sub-speciality? *Clin Radiol.* 2008;63(11):1189-94.

44. Burke M, Parsons S, Bassed R. Management of medicolegal natural deaths from hemopericardium or hemothorax using postmortem CT scanning. *Forensic Sci Med Pathol.* 2012;8(4):367-72.
45. Ross SG, Thali MJ, Bolliger S, Germerott T, Ruder TD, Flach PM. Sudden death after chest pain: feasibility of virtual autopsy with postmortem CT angiography and biopsy. *Radiology.* 2012;264(1):250-9.
46. Bruguier C, Mosimann PJ, Vaucher P, Uske A, Doenz F, Jackowski C, et al. Multi-phase postmortem CT angiography: recognizing technique-related artefacts and pitfalls. *Int J Legal Med.* 2013;127(3):639-52.
47. Ruder TD, Thali MJ, Hatch GM. Essentials of forensic post-mortem MR imaging in adults. *Br J Radiol.* 2014;87(1036):20130567.
48. Jackowski C, Sonnenschein M, Thali MJ, Aghayev E, Yen K, Dirnhofner R, et al. Intrahepatic gas at postmortem computed tomography: forensic experience as a potential guide for in vivo trauma imaging. *J Trauma.* 2007;62(4):979-88.
49. Germerott T, Preiss US, Ebert LC, Ruder TD, Ross S, Flach PM, et al. A new approach in virtopsy: Postmortem ventilation in multislice computed tomography. *Leg Med (Tokyo).* 2010;12(6):276-9.
50. Michiue T, Sakurai T, Ishikawa T, Oritani S, Maeda H. Quantitative analysis of pulmonary pathophysiology using postmortem computed tomography with regard to the cause of death. *Forensic Sci Int.* 2012;220(1-3):232-8.
51. Jackowski C, Thali MJ, Buck U, Aghayev E, Sonnenschein M, Yen K, et al. Noninvasive estimation of organ weights by postmortem magnetic resonance imaging and multislice computed tomography. *Invest Radiol.* 2006;41(7):572-8.
52. Arthurs OJ, Barber JL, Taylor AM, Sebire NJ. Normal perinatal and paediatric postmortem magnetic resonance imaging appearances. *Pediatr Radiol.* 2015;45(4):527-35.
53. Gebhart FT, Brogdon BG, Zech WD, Thali MJ, Germerott T. Gas at postmortem computed tomography--an evaluation of 73 non-putrefied trauma and non-trauma cases. *Forensic Sci Int.* 2012;222(1-3):162-9.
54. Fischer F, Grimm J, Kirchhoff C, Reiser MF, Graw M, Kirchhoff S. Postmortem 24-h interval computed tomography findings on intrahepatic gas development and changes of liver parenchyma radiopacity. *Forensic Sci Int.* 2012;214(1-3):118-23.
55. Okuda T, Shiotani S, Kobayashi T, Kohno M, Hayakawa H, Kikuchi K, et al. Immediate non-traumatic postmortem computed tomographic demonstration of myocardial intravascular gas of the left ventricle: effects from cardiopulmonary resuscitation. *Springerplus.* 2013;2(1):86.
56. Shiotani S, Ueno Y, Atake S, Kohno M, Suzuki M, Kikuchi K, et al. Nontraumatic postmortem computed tomographic demonstration of cerebral gas embolism following cardiopulmonary resuscitation. *Jpn J Radiol.* 2010;28(1):1-7.

57. Takahashi N, Satou C, Higuchi T, Shiotani M, Maeda H, Hirose Y. Quantitative analysis of brain edema and swelling on early postmortem computed tomography: comparison with antemortem computed tomography. *Jpn J Radiol.* 2010;28(5):349-54.
58. Kanazawa A, Hyodoh H, Watanabe S, Fukuda M, Baba M, Okazaki S, et al. New pitfalls of high-density postmortem computed tomography. *Leg Med (Tokyo).* 2014;16(5):297-9.
59. Takahashi N, Higuchi T, Hirose Y, Yamanouchi H, Takatsuka H, Funayama K. Changes in aortic shape and diameters after death: comparison of early postmortem computed tomography with antemortem computed tomography. *Forensic Sci Int.* 2013;225(1-3):27-31.
60. Schwendener N, Mund M, Jackowski C. Type II DeBakey dissection with complete aortic rupture visualized by unenhanced postmortem imaging. *Forensic Sci Int.* 2013;225(1-3):67-70.
61. Levy AD, Harcke HT, Mallak CT. Postmortem imaging: MDCT features of postmortem change and decomposition. *Am J Forensic Med Pathol.* 2010;31(1):12-7.
62. Arthurs OJ, Guy A, Kiho L, Sebire NJ. Ventilated postmortem computed tomography in children: feasibility and initial experience. *Int J Legal Med.* 2015;129(5):1113-20.
63. Shiotani S, Kobayashi T, Hayakawa H, Kikuchi K, Kohno M. Postmortem pulmonary edema: a comparison between immediate and delayed postmortem computed tomography. *Leg Med (Tokyo).* 2011;13(3):151-5.

CHAPTER 4



Conventional autopsy versus minimally invasive autopsy with postmortem MRI, CT, and CT-guided biopsy: comparison of diagnostic performance

Britt M Blokker, Annick C Weustink, Ivo M Wagensveld, Jan H von der Thüsen, Andrea Pezzato, Ruben Dammers, Jan Bakker, Nomdo S Renken, Michael A den Bakker, Folkert J van Kemenade, Gabriel P Krestin, MG Myriam Hunink, J Wolter Oosterhuis

Purpose

To compare the diagnostic performance of minimally invasive autopsy with that of conventional autopsy.

Materials and Methods

For this prospective, single-center, cross-sectional study in an academic hospital, 295 of 2197 adult cadavers (mean age: 65 years [range, 18–99 years]; age range of male cadavers: 18–99 years; age range of female cadavers: 18–98 years) who died from 2012 through 2014 underwent conventional autopsy. Family consent for minimally invasive autopsy was obtained for 139 of the 295 cadavers; 99 of those 139 cadavers were included in this study. Those involved in minimally invasive autopsy and conventional autopsy were blinded to each other's findings. The minimally invasive autopsy procedure combined postmortem MRI, CT, and CT-guided biopsy of main organs and pathologic lesions. The primary outcome measure was performance of minimally invasive autopsy and conventional autopsy in establishing immediate cause of death, as compared with consensus cause of death. The secondary outcome measures were diagnostic yield of minimally invasive autopsy and conventional autopsy for all, major, and grouped major diagnoses; frequency of clinically unsuspected findings; and percentage of answered clinical questions.

Results

Cause of death determined with minimally invasive autopsy and conventional autopsy agreed in 91 of the 99 cadavers (92%). Agreement with consensus cause of death occurred in 96 of 99 cadavers (97%) with minimally invasive autopsy and in 94 of 99 cadavers (95%) with conventional autopsy ($P = .73$). All 288 grouped major diagnoses were related to consensus cause of death. Minimally invasive autopsy enabled diagnosis of 259 of them (90%) and conventional autopsy 224 (78%); 200 (69%) were found with both methods. At clinical examination, the cause of death was not suspected in 17 of the 99 cadavers (17%), and 124 of 288 grouped major diagnoses (43%) were not established. There were 219 additional clinical questions; 189 (86%) were answered with minimally invasive autopsy and 182 (83%) were answered with conventional autopsy ($P = .35$).

Conclusion

The performance of minimally invasive autopsy in the detection of cause of death was similar to that of conventional autopsy; however, minimally invasive autopsy has a higher yield of diagnoses.

Introduction

Conventional autopsy is a valuable tool, particularly for quality control in health care (1-3). Nevertheless, autopsy rates have been rapidly decreasing for various reasons, such as lack of interest of clinicians and next of kin due to overconfidence in premortem diagnostics, reluctance of family members to provide consent to autopsy because of the invasiveness of the procedure, reluctance of pathologists to perform autopsies, budgetary issues, and ideological opposition to postmortem investigation (4-11). Hence, non-invasive or minimally invasive alternative autopsy methods are being developed (12).

The entire body can be visualized with postmortem CT and MRI (13-15), and imaging-guided biopsy can be performed to obtain tissue for histologic examination (16). In addition CT-angiography can be performed (17-23). Some of these methods are already used to support or even substitute the forensic autopsy (24-26). In the clinical setting, non-invasive or minimally invasive autopsies of fetuses, newborns and infants (27) have gained acceptance with parents and physicians, and political and public interest (28). However, they are still rarely applied in adult patients.

The main purpose of this study was to compare immediate cause of death established with conventional autopsy and minimally invasive autopsy in adults who died in a clinical setting, under the a priori hypothesis that the performance of minimally invasive autopsy and conventional autopsy would not be significantly different.

Materials and Methods

Study Design

The institutional review board approved this study before data collection. Written informed consent was obtained from the next of kin for all cadavers.

Our prospective, single-center, cross-sectional study in an academic hospital was performed to compare the diagnostic performance of minimally invasive autopsy with that of conventional autopsy. Minimally invasive autopsy was followed by conventional autopsy. Those involved in minimally invasive autopsy and conventional autopsy were blinded to each other's findings. The primary outcome measure was performance in establishing the immediate cause of death with findings from minimally invasive autopsy and conventional autopsy. The secondary outcome measures were diagnostic yield for all diagnoses, major diagnoses, and grouped major diagnoses, frequency of clinically unsuspected diagnoses and causes of death, and the percentage of answered clinical questions.

Cadavers

All 2197 patients aged 18 years and older who died at the Erasmus University Medical Center in 2012–2014 were eligible for this study if written informed consent was obtained from next of kin for minimally invasive autopsy and conventional autopsy.

Exclusion criteria were as follows: suspected unnatural cause of death, body size exceeding height of 16 inches in supine position (limitation for MRI), known or suspected high-risk transmittable disease (eg, human immunodeficiency virus, tuberculosis, hepatitis B, and hepatitis C), and open abdominal wounds. Pathologic examination of the brain was not compulsory for inclusion.

The size of the cohort was determined by the available 3 years for inclusion, with the goal of assembling a substantially larger cohort than in our earlier study (16).

Preparation for Autopsy Procedures

For each cadaver, the clinically assumed immediate cause of death, specific clinical questions (both entered on the autopsy request forms), and a comprehensive medical history of the deceased patient, including premortem imaging findings, were collected and made available to the teams performing minimally invasive autopsy and conventional autopsy.

Minimally Invasive Autopsy Procedure

MRI and CT scans were made according to standardized protocols (Tables 1, 2).

A board-certified radiologist (A.C.W., with 10 years of experience in postmortem imaging) performed the initial reading of the MR images and CT scans, according to protocol,

compared these images to available premortem images, and marked suspected pathologic lesions for biopsy.

The minimally invasive autopsy researchers (B.M.B., resident in pathology; I.M.W., who recently obtained Doctor of Medicine degree; and J.W.O., with 36 years of experience), who had a brief training in performing CT-guided biopsies, obtained samples for biopsy with a reusable biopsy gun (Bard Magnum; Bard Biopsy Systems, Tempe, Ariz) (12-gauge needle) according to protocol. Samples were obtained from the heart, lungs, liver, kidneys, and spleen in all cases, even if there were no suspicious imaging findings. If lesions were suspected in these organs or elsewhere in the body, they Stereotactic biopsy was performed in the brain with assistance from a board-certified neurosurgeon (R.D., with 9 years of experience in neurosurgery) or a resident in neurosurgery (up to 5 years of training). The pathologist (J.W.O.) and researcher (B.M.B.) from the minimally invasive autopsy team examined the microscopic slides from the biopsies; when in doubt, they consulted pathologists with specific expertise to reach a conclusion.

A board-certified general radiologist (N.S.R., with 10 years of experience in postmortem imaging) independently performed a second reading (within 4 weeks of the first reading) of the CT and MR images. A board-certified cardiovascular radiologist (A.P., with 10 years of experience in cardiovascular radiology) performed a second reading of the MR images of the heart. Both readers were blinded to the findings of the initial radiologic reading. In case of disagreement between the initial and second readings, consensus was reached in joint sessions.

Radiologic and histologic findings were combined in the minimally invasive autopsy report, which included clinical history, postmortem diagnoses, proposed cause of death, and answers to clinical questions.

Table 1. MRI Protocol

Scan Area	Coil	Sequence	TR/TE/TI (ms)	Slice Width (mm)	FOV (cm)	Matrix	No. of Slices	Section coverage (cm)	No. of Sections	Scan Time per Section (s)
Head-Pelvis	Body	FLAIR FSE T1w	2320/9.5/963	4.0	48	384x320	50	20.0	Max 8	174
Head-Pelvis	Body	STIR FSE T2w	12000/41/120	4.0	48	288x224	50	20.0	Max 8	168
Thorax	8-channel torso	3D Fatsat FSPGR T1w	3.3/1.2/14	1.6	40	256x256	212	33.9	1	153
Thorax	8-channel torso	2D STIR FSE T2w	11200/ 94/120	2.0	40	256x256	170	34.0	1	359

MRI was performed on a 1.5T scanner (Discovery MR450, GE Medical systems, Milwaukee, Wisconsin) and consisted of scans of the brain, neck and torso. ms: millisecond; mm: millimeter; cm: centimeter; s: second; FLAIR: Fluid-Attenuated Inversion Recovery; FSE: Fast Spin Echo; T1w: T1-weighted; STIR: Short Tau Inversion Recovery; T2w: T2-weighted; Fatsat: fat saturated; FSPGR: fast spoiled gradient echo.

Table 2. CT Protocol

Scan Area	Rotation Time (s)	Tube Voltage (kV)	Tube Current (eff. mAs)	Slice Collimation (mm)	Pitch	Scan Time (s)	Reconstruction
Head-Neck	1.0	100	750	2 x 64 x 0.6	0.35	21	Filtered back-projection
Thorax-Abdomen	1.0	120	600	2 x 64 x 0.6	0.6	32	Filtered back-projection
Lower extremities	1.0	120	600	2 x 64 x 0.6	0.6	57	Filtered back-projection

CT was performed on a dual-source CT scanner (SOMATOM Definition Flash, Siemens Forchheim, Germany) and included scans of brain, neck, torso and lower extremities. s: second; kV: kilovolt; eff. mAs: effective milliampere-second; mm: millimeter; s: second.

Conventional Autopsy Procedure

The day after minimally invasive autopsy, a resident in pathology (experience: varying from starting to five years of training), supervised by the attending pathologist (rotation among all certified staff pathologists with 5-35 years of experience), performed conventional autopsy according to the departmental protocol as published previously (16) (Appendix A).

The conventional autopsy report included clinical history, post-mortem diagnoses, the proposed cause of death, and answers to clinical questions, and was authorized by the attending pathologist.

Data Extraction and Comparison of Autopsy Procedures

Agreement on Cause of Death

Immediate cause of death determined by means of minimally invasive autopsy and conventional autopsy were compared in three successive reviews by independent experts, as described in Appendix B.

Diagnoses

A researcher from the minimally invasive autopsy team (B.M.B.) extracted and coded all different postmortem diagnoses from the final minimally invasive autopsy and conventional autopsy reports according to the International Classification of Diseases, 10th revision (29). Diagnoses were sorted by 20 organ and tissue categories and one category of general diagnoses.

Per case, a researcher on the minimally invasive autopsy team (I.M.W.) extracted and coded all premortem diagnoses known from the clinical evaluation, using the prepared

International Classification of Diseases, 10th revision, list. The minimally invasive autopsy pathologist and radiologist jointly scored all postmortem diagnoses per minimally invasive autopsy, and two independent pathologists together scored all postmortem diagnoses per conventional autopsy. Postmortem diagnoses were scored as certain according to established radiologic and/or pathologic criteria or as probable if there was any uncertainty. Furthermore, a postmortem diagnosis was classified as major if it was directly related to the proposed immediate cause of death determined with minimally invasive autopsy or conventional autopsy.

After the cause of death was established by consensus (“consensus cause of death”), related major diagnoses were retrospectively combined to grouped major diagnoses (eg, necrosis of the lungs, plus infection of the lungs, plus acute pneumonia).

The diagnostic errors at minimally invasive autopsy and conventional autopsy were retrospectively classified. A perceptual error was defined as an abnormality that, though present, was not reported or as an abnormality that, although absent, was reported (30–32). A cognitive error was defined as an abnormality that, although reported correctly, was not correctly interpreted. An error was defined as a sampling error when a biopsy of a suspected radiologic finding was negative but findings of conventional autopsy were positive.

Clinical Questions

All clinical questions asked by the treating physicians before the start of the minimally invasive autopsy and conventional autopsy were extracted from the autopsy request forms. When the autopsy reports had been finalized, we scored whether the questions had been answered.

Statistical Analysis

All data were sealed in an electronic database (OpenClinica Community, version 3.1.3.1). Agreement on immediate cause of death between minimally invasive autopsy and conventional autopsy, and the percentage in which immediate cause of death was classified as correct, were calculated for each method. The clinically assumed cause of death, extracted from the autopsy request forms, was compared with the consensus cause of death.

Diagnostic yield; the contribution of minimally invasive autopsy and conventional autopsy to all diagnoses, major diagnoses, and grouped major diagnoses; and the percentage of clinically unsuspected diagnoses were calculated by using software (SPSS Statistics, version 21.0 [IBM, Armonk, NY]; Excel, Microsoft Office 2011 [Microsoft, Redmond, Wash]). To test for differences in the detection of cause of death, we used the McNemar test. $P < .05$ was considered indicative of a statistically significant difference. For grouped major diagnoses, we also analyzed overlap between minimally invasive autopsy, conventional autopsy, and the premortem clinical evaluation.

The performance of CT and MRI in establishing grouped major diagnoses and immediate cause of death, and the added value of the imaging-guided biopsy, were retrospectively analyzed. Interobserver agreement for major postmortem diagnoses made with CT and MRI was calculated with the κ statistic.

We also calculated the percentage of clinical questions that were answered with the minimally invasive autopsy and conventional autopsy procedures. The χ^2 test was used to test for differences in these proportions. $P < .05$ was considered indicative of a statistically significant difference.

Previous Studies on the Same Cohort

From 24 cases tissues were collected for analysis of RNA quality (33). All 99 cases were investigated for PMCT and PMMR features of post-mortem change (34), and for accuracy of myocardial CT, MRI and biopsies in detecting acute and chronic ischemia (35). Only the latter study overlaps with the present one as far as myocardial ischemia is concerned.

Results

Inclusion and data acquisition

From January 2012 to December 2014, conventional autopsy was performed in 295 of 2197 deceased adults (13.4%). Of those 295 cadavers, consent for minimally invasive autopsy was obtained for 139 (47.1%). Both minimally invasive autopsy and conventional autopsy were performed in 99 of the 295 cadavers (33.6%); these cases were included in our study. Twenty of the 99 cadavers (20%) underwent both stereotactic brain biopsy and brain autopsy, four (4.0%) underwent brain biopsy alone, and 18 (18%) underwent brain autopsy only. A flowchart of the included cases, along with demographic data, is shown in Figure 1.

The mean time (\pm standard deviation) between death and minimally invasive autopsy was 23.2 hours \pm 15.6. The mean procedure time for the minimally invasive autopsy, including transportation, was 6.28 hours \pm 1.07. The mean time between minimally invasive autopsy and conventional autopsy was 9.47 hours \pm 1.06.

At minimally invasive autopsy, 1574 biopsy samples were obtained. Of those 1574 samples, 338 (21.5%) were targeted at a suspected abnormality seen at imaging. In 22 of the 99 cases (22%), pleural effusion, ascites, and/or cerebrospinal fluid were obtained for cytologic examination.

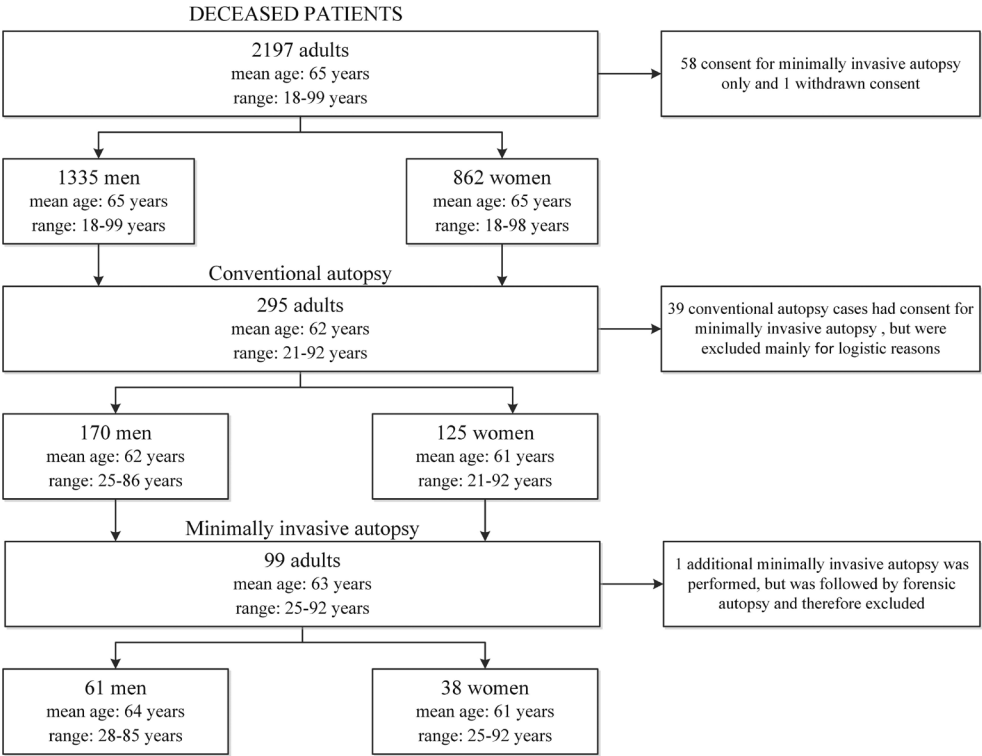


Figure 1: Flowchart case inclusion.

Agreement on Cause of Death

The immediate cause of death determined with minimally invasive autopsy agreed with that determined with conventional autopsy in 91 of the 99 cadavers (92%) (Table 3). Of the eight discordant cases, the consensus cause of death was determined with minimally invasive autopsy in five cases and with conventional autopsy in three (Table 4), resulting in a correct immediate cause of death in 96 (97%) minimally invasive autopsies and 94 (95%) conventional autopsies ($P = .73$).

The performance of imaging (CT and MRI) alone in establishing the immediate cause of death is shown in Table 5. In 11 minimally invasive autopsies, the immediate cause of death could have been established without the need for biopsy. Those causes included tension pneumothorax, massive air embolus (Figure 2), type A aortic dissection, esophagopleural fistula, ruptured aneurysm of abdominal aorta, repeat bleeding of cerebral arteriovenous malformation, and acute subdural and intracerebral hemorrhages with compression and cerebral ischemia.

Table 3. Immediate Cause of Death in Cases with Concordant Findings at Minimally Invasive Autopsy and Conventional Autopsy (n = 91)

Main Pathologic Condition n = 91	No. of Cases n (%)
Pulmonary Pathology	43 (47%)
Cardiac Pathology	30 (33%)
Sepsis/ MOF/ Shock	20 (22%)
Cerebral Pathology	10 (11%)
Intestinal Pathology	8 (9%)
Metastatic Disease	8 (9%)
Vascular Pathology	7 (8%)
Hemorrhage	6 (7%)
Thrombo-embolic Pathology	6 (7%)
Hematologic Disease	5 (5%)
Infectious Disease	4 (4%)
Liver Pathology	2 (2%)
Urological Pathology	2 (2%)
Intoxication	2 (2%)
Graft Versus Host Disease	1 (1%)
Organ Rejection	1 (1%)
Storage Disease (aceruloplasminemia)	1 (1%)

Legend to Table 3:

Numbers in parentheses are percentages. Percentages add to more than 100% because of cases in which more than one pathologic process was involved in cause of death. MOF = multiorgan failure.

Table 4. Immediate Cause of Death in Cases with Discordant Findings at Minimally Invasive Autopsy and Conventional Autopsy (n = 8)

Case No.	Sex	Age	Minimally invasive autopsy	Conventional autopsy	Correct
6	M	72	Sepsis, erythrophagocytosis, multiple organ failure, intestinal ischemia	diffuse alveolar damage, erythrophagocytosis, myocardial ischemia	Minimally invasive autopsy
16	F	63	tension pneumothorax	acute myocardial infarction	Minimally invasive autopsy
17	M	60	massive air embolus	myocardial infarction, thrombo-emboli	Minimally invasive autopsy
27	F	92	hemothorax with active bleeding	peripheral pulmonary emboli, old hematoma in pleural cavity	Minimally invasive autopsy
58	M	61	type-A dissection	focal (hypertensive) intracerebral bleeding	Minimally invasive autopsy
64	M	59	aspiration bronchitis	acute myocardial infarction	Conventional autopsy
79	F	80	Shock, acute aspiration pneumonia, paralytic ileus	shock , ischemic colitis	Conventional autopsy
81	F	67	(sub)acute cerebral ischemia, pneumosepsis	severe atherosclerosis, mesenterial ischemia, cerebral ischemia	Conventional autopsy

Table 5. Diagnostic Value of CT and MRI in Determining Immediate Cause of Death

Immediate Cause of Death	CT	MRI	CT and MRI
Not detected	26 (26)	9 (9)	7 (7)
Detected but uncertain diagnosis, biopsy needed	28 (28)	33 (33)	33 (33)
Detected and probable diagnosis, biopsy to confirm	34 (34)	47 (47)	48 (48)
Detected and certain diagnosis, no biopsy needed	11 (11)	10 (10)	11 (11)

Legend to table 5: Data are numbers of minimally invasive autopsies (n = 99), with percentages in parentheses.

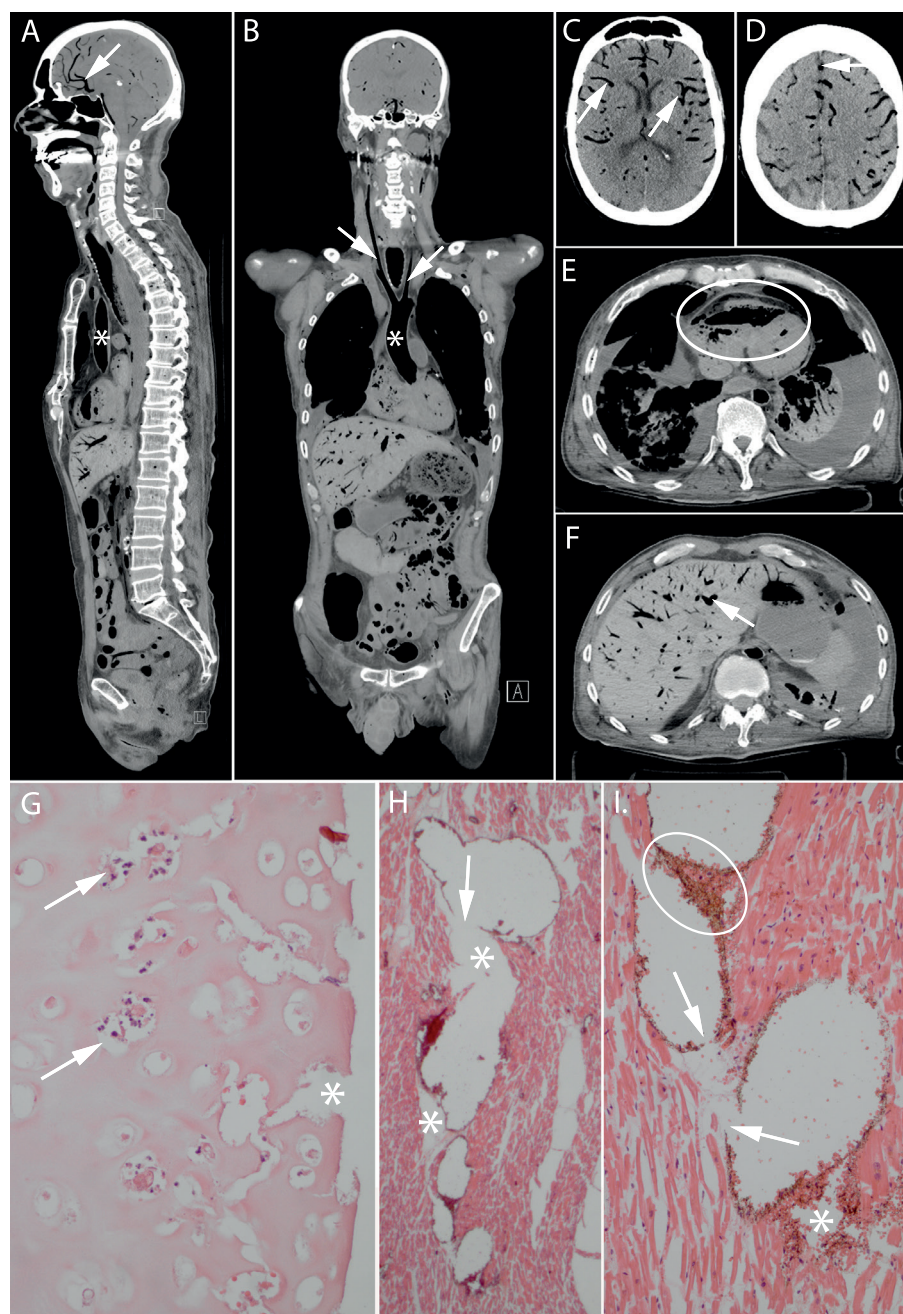


Figure 2: Images in 60-year-old man who underwent bilateral lung transplant 2 months before death. He developed postoperative delirium and was treated for pneumonia. Just prior to death he developed hypotension and agonal breathing. There were signs of elevated jugular venous pressure. Resuscitation during asystole was unsuccessful. Patient died under clinical suspicion of central pulmonary embolus or cardiac tamponade. Conventional autopsy identified a possible myocardial infarction and thrombo-

emboli as cause of death, whereas cause of death at minimally invasive autopsy was massive air embolus. The reference standard committee concluded that minimally invasive autopsy correctly identified the cause of death. A–F, Multiplanar, A, sagittal, B, coronal, and, C–F, transverse CT reconstructions show diffuse air in cardiovascular system. Images show aorta (* in A and B), carotid arteries (arrows in B), visceral blood vessels (cerebral blood vessels: arrows in A, C, D; liver blood vessel: arrow in F), and right ventricle (oval in E). G, Photomicrograph of luminal side of trachea (hematoxylin-eosin stain; original magnification, $\times 200$) shows disappearance of mucosa and submucosa; tracheal cartilage is necrotic with empty lacunae, nuclear debris (arrows), and clefts (*). H, I, Photomicrographs of myocardium (H: hematoxylin-eosin stain, original magnification, $\times 12.5$; I: hematoxylin-eosin stain, original magnification, $\times 100$) show blood vessels inflated by air that pushes erythrocytes to the walls and causes rupture of vessels (arrows), allowing air (*) and erythrocytes (oval in I) to escape into interstitial space, thereby tearing the tissue.

Correlation with Pre-Mortem Clinical evaluation

In 65 of the 99 cadavers (66%), the clinically presumed cause of death was the same as the consensus cause of death found with minimally invasive autopsy and/or conventional autopsy. In an additional 17 cadavers (17%), the consensus cause of death was mentioned in the clinical differential diagnosis. In the remaining 17 cases (17%), the cause of death was not suspected clinically. The latter causes were pneumonia ($n = 5$), myocardial infarction ($n = 2$), type A aortic dissection ($n = 2$), and tension pneumothorax, massive air embolus, multiple organ failure (due to disseminated bladder cancer), acute cellular (grade A2) lung rejection, mesenteric ischemia, sepsis (due to primary biliary cirrhosis with hepatocellular carcinoma), disseminated intravascular coagulation (on clinical grounds probably due to viral infection), and subdural hematoma ($n = 1$ each). Three of the 17 clinically unsuspected immediate causes of death were found only with minimally invasive autopsy (tension pneumothorax, massive air embolus, type A dissection), and two were found only with conventional autopsy (severe coronary atherosclerosis causing acute coronary syndrome, mesenteric ischemia).

Diagnoses

Within our study population, 347 different post-mortem ICD diagnoses were encountered; of these, 230 (66.3%) were classified as major in at least one case (Table 6). From the minimally invasive autopsy and conventional autopsy reports of the 99 included deceased, a total of 3097 post-mortem diagnoses were extracted (Appendix C); minimally invasive autopsy identified 2448/3097 (79.0%) of these and conventional autopsy 1421/3097 (45.9%). 1372/3097 (44.3%) of the diagnoses were classified as major; minimally invasive autopsy detected 992/1372 (72.3%) of them, and conventional autopsy 919/1372 (67.0%). After retrospective grouping, 85 different grouped major diagnoses remained. The postmortem techniques together scored 283 grouped major diagnoses. In addition,

there were five certain diagnoses at premortem clinical evaluation that were not scored as certain with either postmortem method but were nevertheless classified as a major diagnosis because they were related to immediate cause of death and therefore added to the list of grouped major diagnoses. Of the 288 grouped major diagnoses, 259 (89.9%) were found with minimally invasive autopsy and 224 (77.8%) with conventional autopsy; 200 of the 288 grouped major diagnoses (69.4%) were found with both minimally invasive autopsy and conventional autopsy.

Of the 288 grouped major diagnoses, 124 (43.1%) were clinically unsuspected, with 111 of the 124 (89.5%) found with minimally invasive autopsy and 92 (74.2%) found with conventional autopsy. Seventy-nine grouped major diagnoses were detected with both methods, 32 were detected only with minimally invasive autopsy, and 13 were detected only with conventional autopsy. Agreement between premortem clinical evaluation, minimally invasive autopsy, and conventional autopsy for all grouped major diagnoses and for grouped major diagnoses in lungs and for all neoplastic diseases is illustrated in Venn diagrams (Figure 3).

The performance of CT, MRI, biopsies, and conventional autopsy separately in the detection of grouped major diagnoses per category is shown in Appendix D. Interobserver agreement (κ value) for radiologic detection of grouped major diagnoses was excellent: 0.91 for CT and 0.80 for MRI.

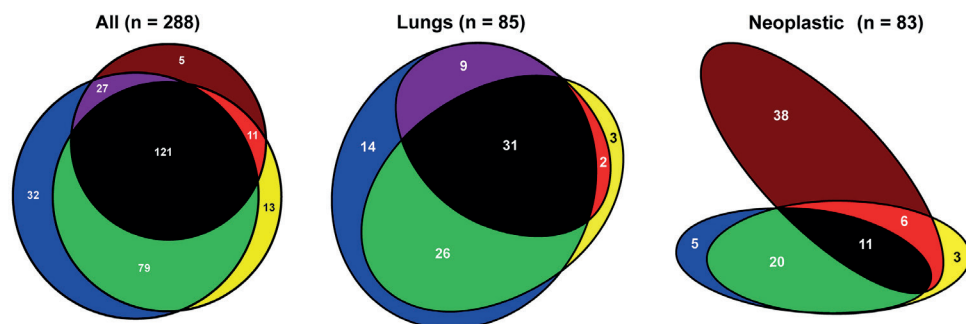


Figure 3: Venn diagrams show sum of grouped major diagnoses identified with the respective methods indicated by following colors: blue: minimally invasive autopsy; yellow: conventional autopsy; brown: clinical evaluation; green: overlap of minimally invasive autopsy and conventional autopsy; purple: overlap of minimally invasive autopsy and clinical examination; red: overlap of conventional autopsy and clinical examination; black: overlap of minimally invasive autopsy, conventional autopsy, and clinical examination. Venn diagrams include five certain premortem diagnoses that were not certain with either postmortem method but were nevertheless scored as major because of their direct relationship to cause of death. The neoplastic diseases retrieved from the clinical records were not necessarily present at the time of death, explaining the large number of neoplastic diseases not detected by either autopsy method. Numbers are numbers of grouped major diagnoses.

Clinical Questions

Apart from the cause of death, 219 additional clinical questions were asked by the referring physicians in 86 of the 99 autopsy request forms (87%). Of these 219 questions, 189 (86.3%) were answered with minimally invasive autopsy and 182 (83.1%) with conventional autopsy ($P = .35$).

Errors

There were 16 perceptual errors with minimally invasive autopsy: 12 at imaging and four at microscopic examination. There were seven cognitive errors, all at microscopy. Four diagnoses were missed due to sampling error. There were 26 perceptual errors with conventional autopsy: nine at gross examination and 17 at microscopic examination. There were six cognitive errors.

Table 6. Major Diagnoses: Total Numbers of Diagnoses and Unsuspected Diagnoses per Organ or Tissue Category

Organ or Tissue Category	No. of Different Postmortem Diagnoses	No. of Certain Postmortem Diagnoses in 99 Cases*	Clinically Unsuspected Post-mortem Diagnoses†	
			Minimally Invasive Autopsy	Conventional Autopsy
General	12	82 (6.0)	57 (69.5)	45 (54.9)
Adrenal Gland	2	2 (0.1)	0 (0.0)	2 (100.0)
Bladder	2	2 (0.1)	0 (0.0)	1 (50.0)
Bone Marrow	3	7 (0.5)	3 (42.9)	6 (85.7)
Brain/ Nervous System	20	89 (6.5)	29 (32.6)	51 (57.3)
Female Genital Tract	1	1 (0.1)	0 (0.0)	0 (0.0)
Gastrointestinal Tract	25	73 (5.3)	29 (39.7)	31 (42.5)
Head (ENT/ eye)	3	3 (0.2)	2 (66.7)	2 (66.7)
Heart	25	308 (22.4)	185 (60.1)	199 (64.6)
Kidney	18	74 (5.4)	49 (66.2)	37 (50)
Liver	19	73 (5.3)	44 (60.3)	37 (50.7)
Lung/ Airways	39	430 (31.3)	218 (50.7)	210 (48.8)
Lymph Nodes	3	7 (0.5)	3 (42.9)	3 (42.9)
Male Genital Tract	2	2 (0.1)	1 (50.0)	1 (50.0)
Mediastinum	4	4 (0.3)	3 (75.0)	1 (25.0)
Pancreas	9	12 (0.9)	4 (33.3)	5 (41.7)
Skeleton	1	1 (0.1)	1 (100.0)	1 (100.0)
Soft tissue/ Skin	13	19 (1.4)	7 (36.8)	7 (36.8)
Spleen	8	66 (4.8)	49 (74.2)	24 (36.4)
Thyroid/ Parathyroid	1	1 (0.1)	0 (0.0)	1 (100.0)
Vascular	20	116 (8.5)	60 (51.7)	62 (53.4)
TOTAL	230	1372	745 (54.3)	726 (52.9)

Legend to table 6: *Numbers in parentheses are percentages of all diagnoses. †Numbers in parentheses are percentages of diagnoses within that category.

Discussion

In our prospective study of a cohort of adult patients who died in-hospital, minimally invasive autopsy combining MRI, CT, and image-guided biopsies and conventional autopsy did not show a significant difference in identifying immediate cause of death and answering clinical questions. Minimally invasive autopsy had a higher yield than conventional autopsy for postmortem diagnoses, many of which were clinically unsuspected. The methods we used for minimally invasive autopsy appeared adequate and are technically feasible for most hospitals. Our technique of minimally invasive autopsy was improved compared with an earlier study, in which there were fewer biopsies and/or random biopsies guided with US (16).

Apart from our current study, to our knowledge the study by Weustink et al. is the only one reporting on the diagnostic performance of minimally invasive autopsy in patients who died in-hospital using the combination of CT, MRI, and postmortem biopsy. In a cohort of 182 coroner's cases, Roberts et al. (13) compared CT and MRI to conventional autopsy and found an agreement for cause of death of 70% (95% confidence interval: 62.6%, 76.4%). Most often missed were ischemic heart disease, pulmonary embolism, pneumonia, and intra-abdominal lesions. Westphal et al. (14), who investigated the feasibility of minimally invasive autopsy with CT in only 29 cases, reported accuracy for cause of death of 68% and a positive predictive value of 75%. In agreement with these studies, we found that CT and MRI alone could not with certainty help diagnose common causes of death such as pneumonia, myocardial infarction, peripheral pulmonary emboli, gastrointestinal ischemia, and sepsis without biopsy confirmation.

Recent studies investigated the additional value of CT angiography. The study by Westphal et al. (19) achieved an accuracy of 80% for cardiac causes of death. In a selected group of 50 cases, Wichmann et al. (20) compared diagnoses (not cause of death) identified with CT angiography or conventional autopsy. They found 16 new major diagnoses, comparable to grouped major diagnoses in our study; 93.8% of these were identified by CTA and 87.5% by conventional autopsy. These figures are comparable to the clinically unsuspected grouped major diagnoses in our study. Most recently Rutty et al. (17) established a correct cause of death in 86% of cases using CT angiography compared to a consensus cause of death. Bolliger et al. (23) and Ross et al. (21) combined CT, CT angiography and biopsies. In a systematic review the pooled sensitivity for cause of death was 90.9% (95% confidence interval: 74.5%, 97.6%) (12).

Post-mortem angiography, an important technical advancement of post-mortem imaging (17, 20, 21), appears not necessary for establishing immediate cause of death if cardiac MRI protocols are used in combination with targeted myocardial biopsies. For subclinical arterial stenoses and localizing the origin of bleeding angiography is indispensable. However, the logistics of post-mortem angiography requires expertise not yet available in general hospitals.

Minimally invasive autopsy provides a permanent auditable record of the entire body that can be referred to by pathologists, radiologists, clinicians, scientists, and next of kin (12, 13). For minimally invasive autopsy to become a routine procedure, cultural adaptation will be required, especially for pathologists. Minimally invasive autopsy requires dedicated radiologists and pathologists who know the strengths and limitations of both disciplines and are willing to jointly answer the questions asked by the clinicians. In view of the expensive imaging equipment, it seems sensible to centralize minimally invasive autopsy and/or postmortem imaging in regional autopsy facilities, where state-of-the-art imaging units and adequately trained specialists are available. These centers can take the lead in developing standardized consent forms, triaging cases, establishing efficient operating procedures, and managing quality. A centralized approach may maximize the use of the equipment, thereby reducing depreciation and running costs, and minimize interference with clinical radiology. Finally, adoption of these methods also requires awareness from both medical professionals and the lay public.

Our study had some limitations. The teams performing minimally invasive autopsy and conventional autopsy were blinded to each other; however, for the pathologist performing conventional autopsy, the biopsy sites could potentially lead to increased suspicion of a pathologic condition in the biopsied areas. We used consensus cause of death as a reference standard instead of conventional autopsy. However, errors are not uncommon with conventional autopsy alone (12, 16, 36). Errors in the interpretation of histologic findings obtained with conventional autopsy were corrected to compensate for this bias. Furthermore, when abnormal air collections were present, imaging appears more useful than conventional autopsy.

We did not calculate sensitivity and specificity of the two autopsy procedures for each diagnosis but scored their respective diagnostic yields. Specificity cannot be calculated in a meaningful way because it directly depends on the total number of diagnoses in the entire study population, since the number of true-negative diagnoses per case increases when more diagnoses are encountered in the population.

Only a small proportion of the 2197 patients who died during our study period underwent autopsy, and even fewer underwent minimally invasive autopsy. Furthermore, a number of minimally invasive autopsies for which we obtained consent could not be executed for logistical reasons. However, the immediate causes of death in our cohort were representative of the findings with routine autopsies in Western countries (37). Consent for histologic sampling from the brain was obtained in a small proportion of minimally invasive autopsies (24 of 99 cases) and conventional autopsies (38 of 99 cases). We also did not address costs and benefits of the minimally invasive autopsy and supplementary postmortem imaging.

In summary, there was excellent agreement between minimally invasive autopsy and conventional autopsy as to immediate cause of death. Importantly, minimally invasive autopsy resulted in a higher yield of diagnoses. Seventeen percent of immediate causes

of death and 43% of grouped major diagnoses were not suspected at clinical examination, which illustrates the lasting importance of postmortem examination for quality control in health care. Because minimally invasive autopsy and conventional autopsy have their own strengths and weaknesses, future postmortem examination in the clinic will probably use combinations of the two approaches.

Acknowledgments

The authors are grateful to the next of kin of included patients and to the professionals who made valuable contributions to this study: Jaap A.H. Bongers, Jaap Slooff, Clemens M.F. Dirven, MD, PhD, John S. Soria van Hoeve, MD, Rutger K. Balvers, MD, PhD, Jasson de Groot, Piotr A. Wielopolski, PhD, Ronald Booij, King H. Lam, MD, PhD, Vidija Soerdjbalie-Maikoe, MD, PhD, Marianne de Vries, MD, PhD, Arlette E. Odink, MD, PhD, and Mariska J.P. Rossius, MD.

References

1. Kircher T, Nelson J, Burdo H. The Autopsy as a Measure of Accuracy of the Death Certificate. *New Engl J Med*. 1985;313(20):1263-9.
2. Shojania KG, Burton EC, McDonald KM, Goldman L. Changes in rates of autopsy-detected diagnostic errors over time: a systematic review. *JAMA*. 2003;289(21):2849-56.
3. Winters B, Custer J, Galvagno SM, et al. Diagnostic errors in the intensive care unit: a systematic review of autopsy studies. *Bmj Qual Saf*. 2012;21(11):894-902.
4. Burton JL, Underwood J. Clinical, educational, and epidemiological value of autopsy. *Lancet*. 2007;369(9571):1471-80.
5. Shojania KG, Burton EC. The vanishing nonforensic autopsy. *N Engl J Med*. 2008;358(9):873-5.
6. Ayoub T, Chow J. The conventional autopsy in modern medicine. *J R Soc Med*. 2008;101(4):177-81.
7. Oluwasola OA, Fawole OI, Otegbayo AJ, Ogun GO, Adebamowo CA, Bamigboye AE. The autopsy: knowledge, attitude, and perceptions of doctors and relatives of the deceased. *Arch Pathol Lab Med*. 2009;133(1):78-82.
8. Blokker BM, Weustink AC, Hunink MGM, Oosterhuis JW. Autopsy of Adult Patients Deceased in an Academic Hospital: Considerations of Doctors and Next-of-Kin in the Consent Process. *PLoS One*. 2016;11(10):e0163811.
9. Blokker BM, Weustink AC, Hunink MGM, Oosterhuis JW. Autopsy rates in the Netherlands: 35 years of decline. *PLoS One*. 2017;12(6):e0178200.
10. Brown HG. Perceptions of the autopsy: views from the lay public and program proposals. *Hum Pathol*. 1990;21(2):154-8.
11. Council on Scientific Affairs. Autopsy. A comprehensive review of current issues. *JAMA*. 1987;258(3):364-9.
12. Blokker BM, Wagenveld IM, Weustink AC, Oosterhuis JW, Hunink MG. Non-invasive or minimally invasive autopsy compared to conventional autopsy of suspected natural deaths in adults: a systematic review. *Eur Radiol*. 2016;26(4):1159-79.
13. Roberts ISD, Benamore RE, Benbow EW, et al. Post-mortem imaging as an alternative to autopsy in the diagnosis of adult deaths: A validation study. *Lancet*. 2012;379(9811):136-42.
14. Westphal SE, Apitzsch J, Penzkofer T, Mahnken AH, Knuchel R. Virtual CT autopsy in clinical pathology: Feasibility in clinical autopsies. *Virchows Arch*. 2012;461(2):211-9.
15. Wichmann D, Obbelode F, Vogel H, et al. Virtual autopsy as an alternative to traditional medical autopsy in the intensive care unit; A prospective cohort study. *Ann Intern Med*. 2012;156(2):123-30.
16. Weustink AC, Hunink MGM, Van Dijke CF, Renken NS, Krestin GP, Oosterhuis JW. Minimally invasive autopsy: An alternative to conventional autopsy? *Radiology*. 2009;250(3):897-904.

17. Rutty GN, Morgan B, Robinson C, et al. Diagnostic accuracy of post-mortem CT with targeted coronary angiography versus autopsy for coroner-requested post-mortem investigations: a prospective, masked, comparison study. *Lancet*. 2017;390(10090):145-54.
18. Michaud K, Grabherr S, Jackowski C, Bollmann MD, Doenz F, Mangin P. Postmortem imaging of sudden cardiac death. *Int J Legal Med*. 2014;128:127-37.
19. Westphal SE, Apitzsch JC, Penzkofer T, Kuhl CK, Mahnken AH, Knuchel R. Contrast-enhanced postmortem computed tomography in clinical pathology: enhanced value of 20 clinical autopsies. *Hum Pathol*. 2014;45(9):1813-23.
20. Wichmann D, Heinemann A, Weinberg C, et al. Virtual Autopsy With Multiphase Postmortem Computed Tomographic Angiography Versus Traditional Medical Autopsy to Investigate Unexpected Deaths of Hospitalized Patients. *Ann Intern Med*. 2014;160(8):534-41.
21. Ross SG, Thali MJ, Bolliger S, Germerott T, Ruder TD, Flach PM. Sudden death after chest pain: Feasibility of virtual autopsy with postmortem CT angiography and biopsy. *Radiology*. 2012;264(1):250-9.
22. Grabherr S, Doenz F, Steger B, et al. Multi-phase post-mortem CT angiography: development of a standardized protocol. *International Journal of Legal Medicine*. 2011;125(6):791-802.
23. Bolliger SA, Filograna L, Spendlove D, Thali MJ, Dirnhofer S, Ross S. Postmortem imaging-guided biopsy as an adjuvant to minimally invasive autopsy with CT and postmortem angiography: A feasibility study. *Am J Roentgenol*. 2010;195(5):1051-6.
24. Dirnhofer R, Jackowski C, Vock P, Potter K, Thali MJ. VIRTOPSY: minimally invasive, imaging-guided virtual autopsy. *Radiographics*. 2006;26(5):1305-33.
25. Thali MJ, Yen K, Schweitzer W, et al. Virtopsy, a new imaging horizon in forensic pathology: virtual autopsy by postmortem multislice computed tomography (MSCT) and magnetic resonance imaging (MRI)--a feasibility study. *J Forensic Sci*. 2003;48(2):386-403.
26. Leth PM. Computed tomography in forensic medicine. *Dan Med J*. 2015;62(6).
27. Thayyil S, Sebire NJ, Chitty LS, et al. Post-mortem MRI versus conventional autopsy in fetuses and children: a prospective validation study. *Lancet*. 2013;382(9888):223-33.
28. Addison S, Arthurs OJ, Thayyil S. Post-mortem MRI as an alternative to non-forensic autopsy in fetuses and children: from research into clinical practice. *Br J Radiol*. 2014;87(1036):20130621.
29. <http://apps.who.int/classifications/icd10/browse/2016/en>.
30. Kundel HL. Perception errors in chest radiography. *Semin Respir Med* 1989;10:203–210. 1989.
31. Pescarini L, Inches I. Systematic approach to human error in radiology. *Radiol Med*. 2006;111(2):252-67.
32. Berlin L. Malpractice issues in radiology. Perceptual errors. *AJR Am J Roentgenol*. 1996;167(3):587-90.
33. van der Linden A, Blokker BM, Kap M, et al. Post-mortem tissue biopsies obtained at minimally invasive autopsy: an RNA-quality analysis. *PLoS One*. 2014;9(12):e115675.

34. Wagensveld IM, Blokker BM, Wielopolski PA, et al. Total-body CT and MR features of postmortem change in in-hospital deaths. *PLoS One*. 2017;12(9):e0185115.
35. Wagensveld IM, Blokker BM, Pezzato A, et al. Diagnostic accuracy of postmortem computed tomography, magnetic resonance imaging, and computed tomography-guided biopsies for the detection of ischaemic heart disease in a hospital setting. *Eur Heart J Cardiovasc Imaging*. 2018;19(7):739-48.
36. Roulson J, Benbow EW, Hasleton PS. Discrepancies between clinical and autopsy diagnosis and the value of post mortem histology; a meta-analysis and review. *Histopathology*. 2005;47(6):551-9.
37. <http://www.who.int/mediacentre/factsheets/fs310/en/index1.html>.

Appendices

Appendix A. Data Acquisition and Processing

- Minimally invasive autopsy
- Conventional autopsy

Appendix B. Cause of Death – Reference Standard Process

Appendix C. All Diagnoses – Total Number and Unsuspected Diagnoses per Organ/ Tissue Category

Appendix D. Grouped Major Diagnoses - Diagnostic Value of Post-mortem Imaging (CT and MRI) and Biopsy (Minimally Invasive Autopsy), and Conventional Autopsy

Appendix A. Data Acquisition and Processing

Minimally invasive autopsy

Upon radiological examination the following were systematically evaluated: brain, thyroid, heart, lungs including trachea, liver, spleen, kidneys, adrenal glands, pancreas, gastrointestinal tract including esophagus, uterus, ovaries, prostate, testes, bladder, thoracic and abdominal cavities, aorta, vena cava, greater arteries and veins, lymph nodes, soft tissues, and skeleton.

Biopsies were taken with the BARD MAGNUM® biopsy gun (BARD MAGNUM, Bard Biopsy Systems, Tempe, Arizona), fixed in buffered formalin, embedded in paraffin and processed for standard hematoxylin and eosin-stained slides. If necessary, special histological and immunohistochemical stainings were applied. Occasionally pathological fluid collections were sampled for cytological examination. Cytology specimens were routinely stained with Giemsa, Papanicolaou and hematoxylin and eosin.

If consented to by next-of-kin post-mortem stereotactic image-guided biopsies of the brain were taken from basal ganglia, white matter, grey matter, and suspected pathology, using fiducial markers and a neuro-navigation system (Brainlab, Munich, Germany, Vector Vision2 with Vector Vision Cranial 6.x software). If possible, cerebrospinal (CSF) fluid was aspirated from the ventricles, and processed for cytological examination.

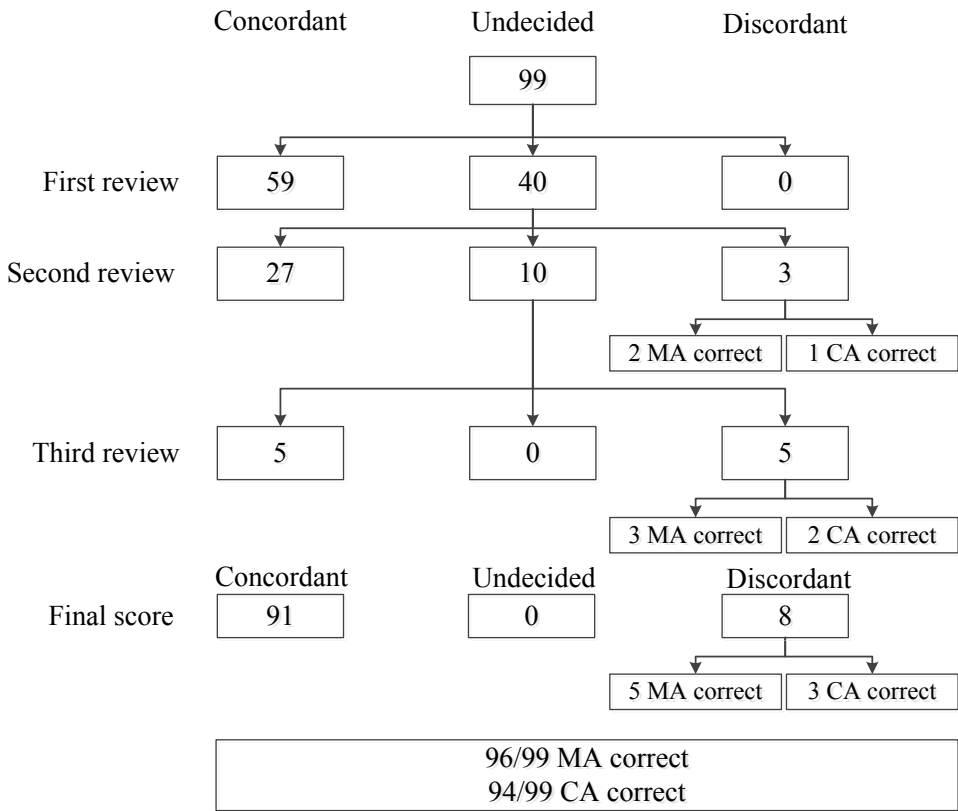
Conventional autopsy

The following were systematically evaluated: thyroid, heart, trachea, lungs, liver, spleen, kidneys, adrenal glands, pancreas, gastrointestinal tract including esophagus, uterus, ovaries, prostate, testes, bladder, thoracic and abdominal cavities, aorta, vena cava, greater arteries and veins, lymph nodes, and, if consented to, brain.

Sampling for histology included a protocolled set of tissue blocks from the main organs (heart, lungs, liver, kidney, spleen and bone marrow), and additional samples from any gross abnormality. On indication tissue and body fluids were sampled for microbiology cultures. After dissection of the organs the gross findings were discussed with the physicians requesting autopsy.

Body fluids were sampled for cytology if deemed necessary. To reduce costs the results of microbiology cultures of samples taken at conventional autopsy were made available to the minimally invasive autopsy team upon their request.

Appendix B. Cause of Death – Reference Standard Process



MA = Minimally Invasive Autopsy; CA = Conventional Autopsy.

Legend to Appendix B:

The reference standard process consisted of three successive reviews by independent experts, resulting in a consensus cause of death for all 99 cases (see methods section), in which the cause of death for both methods was defined as concordant or discordant.

Explanation of the Reference Standard Process

An intensivist (JB), professionally familiar with postmortem examination of patients who die of critical illnesses, and not himself involved in any of the cases, was asked to participate in the first review. The minimally invasive autopsy team and the intensivist independently reviewed the minimally invasive autopsy and conventional autopsy reports, with regards to the presumed cause of death and decided whether they found the results of the two methods concordant, discordant or undecided. Only the cases, of which both parties decided that the findings were concordant, were classified as such.

In the second review an independent pathologist (JT), together with the minimally invasive autopsy pathologist and radiologist, checked all discordant or undecided cases by reviewing the minimally invasive autopsy - and conventional autopsy reports, the radiological and macroscopic images and histological slides. Errors of histological interpretation with conventional autopsy were corrected to compensate for bias due to the different settings of minimally invasive autopsy (research) and conventional autopsy (daily routine). After this correction, cases were classified as concordant, discordant, or undecided. For the discordant cases the independent pathologist decided whether minimally invasive autopsy or conventional autopsy was correct, or that a case required further review.

In the third review the remaining undecided and discordant cases were independently reviewed by a reference standard committee, which included a pathologist (FJK), a radiologist (GPK) and the intensivist (JB). They classified the cases as concordant or discordant. If a case was classified as discordant, the reference standard committee decided which of the two methods was correct.

Appendix C. All Diagnoses – Total Number and Unsuspected Diagnoses per Organ/ Tissue Category

Organ/ Tissue Category	Number of Different Post-mortem Diagnoses	Number of Certain Post-mortem Diagnoses in 99 Cases (% all Diagnoses)	Clinically Unsuspected Post-mortem Diagnoses (% within Category)	
			MA	CA
General	13	155 (5.0)	77 (49.7)	53 (34.2)
Adrenal Gland	5	9 (0.3)	2 (22.2)	4 (44.4)
Bladder	7	21 (0.7)	6 (28.6)	12 (57.1)
Bone Marrow	7	19 (0.6)	9 (47.4)	12 (63.2)
Brain/ Nervous System	29	199 (6.4)	91 (45.7)	94 (47.2)
Female Genital Tract	7	19 (0.6)	13 (68.4)	8 (42.1)
Gastrointestinal Tract	30	178 (5.7)	105 (59.0)	51 (28.7)
Head (ENT/ eye)	10	20 (0.6)	16 (80.0)	3 (15.0)
Heart	28	527 (17.0)	349 (66.2)	285 (54.1)
Kidney	26	281 (9.1)	217 (77.2)	71 (25.3)
Liver	30	309 (10.0)	240 (77.7)	96 (31.1)
Lung/ Airways	43	630 (20.3)	346 (54.9)	274 (43.5)
Lymph Nodes	4	27 (0.9)	16 (59.3)	6 (22.2)
Male Genital Tract	11	44 (1.4)	28 (63.6)	21 (47.7)
Mediastinum	7	21 (0.7)	18 (85.7)	3 (14.3)
Pancreas	11	41 (1.4)	21 (51.2)	14 (34.1)
Skeleton	13	116 (3.7)	91 (78.4)	4 (3.4)
Soft tissue / Skin	25	114 (3.7)	81 (71.1)	12 (10.5)
Spleen	13	165 (5.3)	135 (81.8)	39 (23.6)
Thyroid / Parathyroid	4	16 (0.5)	2 (12.5)	16 (100.0)
Vascular	24	186 (6.0)	108 (58.1)	87 (46.8)
TOTAL	347	3097	1971 (63.6)	1165 (37.6)

MA = minimally invasive autopsy; CA = conventional autopsy

Appendix D. Grouped Major Diagnoses - Diagnostic Value of Post-Mortem Imaging (CT and MRI) and Biopsy (Minimally Invasive Autopsy), and Conventional Autopsy

Grouped Major Post-mortem ICD Diagnosis		N CT	Minimally Invasive Autopsy		Conventional Autopsy	
			MRI	Biopsy*		
General	Sepsis / shock / multiple organ failure	32	-	-	++	++
	Metastatic disease	11	+/-	+	++	++
Brain/ Nervous System	Compression of brain	6	+/-	+/-	+/-	+/-
	Recent ischemia of the brain	4	+/-	+	++	+/-
	Intracerebral hemorrhage	3	++	++	++	+/-
	Meningitis	2	-	+/-	+/-	++
Heart	Acute myocardial infarction	17	-	+/-	++	++
	Acute heart failure	10	-	+/-	++	+/-
	Tamponade - pericardium	3	+/-	++	++	++
Vascular	Type-A aortic dissection	5	+/-	+	+	+/-
	Rupture of artery	6	+/-	+	+/-	++
	Arterial embolism and thrombosis	3	-	+/-	++	++
Lung/ Airways	Acute pneumonia	32	+/-	+/-	++	++
	Aspiration	9	+/-	+/-	++	+/-
	Pulmonary embolism, periferal	5	-	+/-	++	+/-
	Pulmonary embolism, central	3	-	+	++	+/-
	Hemothorax	3	+/-	+/-	+/-	++
	Hemorrhage (lungs)	2	+	+	++	++
	Tension pneumothorax	1	++	++	++	-
Liver	Abscess of liver	2	+	+	++	+/-
Kidney	Pyelourethritis	2	+/-	+/-	++	-

Gastrointestinal Tract and Abdominal Cavity	Ischemia / necrosis of intestine	8	+/-	+/-	+/-	++
	Abdominal abscess	3	+/-	+/-	+/-	+/-
	Gastroenteritis and colitis	2	-	+/-	+/-	++
	Peritonitis	2	+/-	+/-	++	+/-
	Perforation of intestine (non-traumatic)	1	+	-	++	++
	Perforation of oesophagus	1	++	+	++	-
	Graft versus Host (intestine)	1	-	+/-	++	++
	New gastrointestinal hemorrhage	1	-	-	++	++
	Obstructive ileus, colon or small intestine	1	++	-	++	+
	Diverticulitis	1	+	+	++	++

* In contrast to CT and MRI, the value of biopsy is not an independent measure, for a substantial part of the biopsies was obtained based on the imaging findings.

Legend to Appendix D:

This table demonstrates how often findings of the different minimally invasive autopsy elements (CT, MRI and biopsy) and conventional autopsy were consistent with the grouped major diagnoses.

For CT and MRI: [-] < 20% of diagnoses scored 1 or 2 or 3; [+ / -] > 20% of diagnoses scored 1 or 2 or 3; [+] > 80% of diagnoses scored 2 or 3; [++] > 80% of diagnoses scored 3. Score 0, not detected; score 1, detected but uncertain diagnosis, biopsy needed; score 2, detected and probable diagnosis, biopsy to confirm; score 3, detected and certain diagnosis, no biopsy needed.

For minimally invasive autopsy and conventional autopsy: [-] < 20% of diagnoses scored 1 or 2; [+ / -] > 20% of diagnoses scored 1 or 2; [+] > 80% of diagnoses scored 1 or 2; [++] > 80% of diagnoses scored 2; score 0 = not detected; score 1 = detected but uncertain diagnosis; score 2 = detected and certain diagnosis

CHAPTER 5



Diagnostic accuracy of postmortem computed tomography, magnetic resonance imaging, and computed tomography-guided biopsies for the detection of ischaemic heart disease in a hospital setting

Ivo M Wagenveld, Britt M Blokker, Andrea Pezzato, Piotr A Wielopolski, Nomdo S Renken, Jan H von der Thüsen, Gabriel P Krestin, MG Myriam Hunink, J Wolter Oosterhuis, Annick C Weustink

Aims

The autopsy rate worldwide is alarmingly low (0-15%). Mortality statistics are important, and it is, therefore, essential to perform autopsies in a sufficient proportion of deaths. The imaging autopsy, non-invasive, or minimally invasive autopsy (MIA) can be used as an alternative to the conventional autopsy in an attempt to improve postmortem diagnostics by increasing the number of postmortem procedures. The aim of this study was to determine the diagnostic accuracy of postmortem magnetic resonance imaging (MRI), computed tomography (CT), and CT-guided biopsy for the detection of acute and chronic myocardial ischaemia.

Methods and results

We included 100 consecutive adult patients who died in hospital, and for whom next-of-kin gave permission to perform both conventional autopsy and MIA. The MIA consists of unenhanced total-body MRI and CT followed by CT-guided biopsies. Conventional autopsy was used as reference standard. We calculated sensitivity and specificity and receiver operating characteristics curves for CT and MRI as the stand-alone test or combined with biopsy for detection of acute and chronic myocardial infarction (MI). Sensitivity and specificity of MRI with biopsies for acute MI was 0.97 and 0.95, respectively and 0.90 and 0.75, respectively for chronic MI. MRI without biopsies showed a high specificity (acute: 0.92; chronic: 1.00), but low sensitivity (acute: 0.50; chronic: 0.35). CT (total Agatston calcium score) had a good diagnostic value for chronic MI [area under curve (AUC) 0.74, 95% confidence interval (CI) 0.64-0.84], but not for acute MI (AUC 0.60, 95% CI 0.48-0.72).

Conclusion

We found that the combination of MRI with biopsies had high sensitivity and specificity for the detection of acute and chronic myocardial ischaemia.

Introduction

According to the world health organization cardiovascular disease and stroke are the foremost contributors to worldwide mortality, with ischaemic heart disease globally causing almost 9 million deaths per year in 2015. (1) Accurate mortality statistics are important for both policy- and decision-making regarding healthcare funding. For reliable statistics it is essential to perform autopsies in a sufficient proportion of deaths, both in and out of hospital.

Despite available modern diagnostic tests, the conventional autopsy still reveals unexpected findings related to the cause of death in 8.4-24.4% and findings that would have affected patient outcome (class I errors) in 4.1-6.7% of cases. (2-4)

Unfortunately today's autopsy rate has dropped to alarmingly low percentages worldwide (0-15%), both for academic and nonacademic hospitals. (5) In the late nineties, the imaging autopsy was introduced as alternative to conventional autopsy as a stimulus to postmortem diagnostics. Since then, a growing number of studies have evaluated the diagnostic value of postmortem CT and MRI with or without image guided biopsies. Two review articles concluded that the imaging autopsy, using a non-invasive or minimally invasive approach, can potentially serve as an alternative to conventional autopsy, but more extensive research in different settings is needed to validate these new autopsy methods. (6, 7)

Imaging protocols designed for the living patient differ from postmortem imaging protocols, in particular for cardiac imaging. For example, wall movement abnormalities of the heart cannot be diagnosed. In living patients, contrast-enhanced imaging, either noninvasive or invasive, is the gold standard for diagnosing ischaemic heart disease. Postmortem angiographic studies are feasible and not new; since the discovery of X-rays, angiography of organs and tissues has been used as an adjunct to the autopsy procedure. (8) More recently, postmortem total-body angiography, using CT (CTA) or MRI (MRA), has become technically feasible and there is a growing number of studies investigating its diagnostic value. Preliminary results are promising, especially for establishing ischaemic heart disease as the cause of death. (9-11)

Interestingly postmortem MRI without the use of contrast agents also shows a sufficient accuracy for detecting both acute and chronic myocardial infarction (MI). The presence and age of MI can be diagnosed by evaluating the signal changes related to morphological alterations in the infarcted myocardium, such as the presence of myocardial edema, fibrosis or fat. (12-15). Nonenhanced cardiac CT is also useful for detecting coronary artery calcifications.

In this study, we evaluate the minimally invasive autopsy (MIA) approach using both nonenhanced CT and MRI followed by CT-guided biopsies. The aim of this study was to determine the diagnostic accuracy of MRI, CT and CT-guided biopsy for the detection of acute and chronic MI, with conventional autopsy as the reference standard.

Methods

Study design

This study was undertaken as part of the Minimally Invasive Autopsy (MIA) study; this is a prospective single center cross-sectional study in a tertiary referral hospital comparing diagnostic performance of conventional autopsy and MIA. Conventional autopsy followed MIA on the same case. Pathologists involved with conventional autopsy were blinded to MIA findings as much as possible; however, biopsy sites could potentially lead to increased suspicion of the biopsied organs and tissues by the autopsy pathologist. MIA personnel were blinded to autopsy findings.

Patients

From January 2012 through December 2014 all hospitalized patients aged 18 years and older who died at Erasmus University Medical Center were eligible, if written informed consent was obtained from next-of-kin for MIA and conventional autopsy of at least the torso.

Exclusion criteria were (suspected) unnatural cause of death, body size exceeding height of 16 inches in supine position (limitation for MRI), known or suspected “high-risk” infected bodies (tuberculosis, hepatitis B and C, human immunodeficiency virus, methicillin-resistant *Staphylococcus aureus*, multi-drug resistant *Acinetobacter*), and open abdominal wounds that could not be completely closed or taped to prevent leakage of body fluids.

Clinical information

All relevant clinical information including medical history and suspected cause of death was recorded and available for both the MIA and the conventional autopsy team. The treating physician decided the most likely cause of death and a differential diagnosis based on the clinical presentation. For the analysis the population was divided into a group with and a group without clinical suspicion for ischaemic heart disease.

Minimally Invasive Autopsy procedure

MRI and CT scans were made according to standardized protocols (Table 1a and 1b respectively). Total acquisition time was one hour for MRI and around 5 minutes for CT. One radiologist (ACW) with expertise in postmortem radiology, performed the initial read of the MRI and CT scans, compared these to the available premortem imaging, and marked suspected pathological lesions on CT and MRI key images that were used to plan the biopsies.

Table 1a. Postmortem magnetic resonance protocol

Scan area	Coil	Sequence	TR/TE/TI (ms)	Slice width (mm)	FOV (cm)	Matrix	No. of slices	Section coverage (cm)	No. of sections	Scan time per section (s)
Head - Pelvis	Body	FLAIR FSE T1w	2320/9.5/963	4.0/no gap	48x48	384x320	50	20.0	5-8	174
Head - Pelvis	Body	STIR FSE T2w	12000/41/120	4.0/no gap	48x48	288x224	50	20.0	5-8	168
Thorax	8-channel torso array	3D fs FSPGR T1w	3.3/1.2/14	1.6	40x40	256x256	212	33.9	1	153
Thorax	8-channel torso array	2D STIR FSE T2w	11200/ 94/120	2.0 / no gap	40x40	256x256	170	34.0	1	359

TR, repetition time; TE, echo time; TI, inversion time; FOV, field of view; FLAIR, fluid attenuated inversion recovery; FSE, fast spin echo; STIR, short tau inversion recovery; fs FSPGR, fat-saturated fast spoiled gradient echo. All scans were made in the axial orientation.

Table 1b. Postmortem computed tomography protocol

Scan area	Rotation time (s)	Tube voltage (kV)	Tube current (eff. mAs)	Slice collimation (mm)	Pitch	Scan time (s)	Reconstruction
Head - Neck	1.0	100	750	2 x 64 x 0.6	0.35	21	Filtered back-projection
Thorax - Pelvis	1.0	120	600	2 x 64 x 0.6	0.6	32	Filtered back-projection
Pelvis - Lower extremities	1.0	120	600	2 x 64 x 0.6	0.6	57	Filtered back-projection

MRI was performed on a 1.5T scanner (Discovery MR450, GE Medical systems, Milwaukee, Wisconsin USA) and consisted of scans of the brain, neck, thorax, abdomen and pelvis. The MRI total-body protocol consisted of axially-acquired STIR FSE T2w and FLAIR FSE T1w from the cranium to the pelvis. An additional 2D STIR FSE T2w scan and 3D Fatsat FSPGR T1w scan with higher resolution than the total-body scans were acquired of the thorax, using an 8-channel torso array coil. All MRI scans were made in the axial orientation.

After MRI was completed CT scans were acquired from head to feet (Somatom Definition, Siemens Healthcare, Forchheim, Germany). CT data sets of the head, thorax and abdomen were reconstructed with section thickness of 1.0 mm and 5.0 mm in the axial plane and 3.0 mm in the coronal and sagittal planes, by using medium-to-smooth (H31/B31) and very sharp (H70/B70) convolution kernels.

CT-guided biopsies (12 Gauge) were taken from heart, lungs, liver, kidneys, spleen, and radiologically suspected pathology as indicated. In the heart, standard biopsies (5-10 samples) were taken from the lateral wall (mid and basal parts) and apex of the left ventricle. Additional biopsies were taken from MRI signal abnormalities within the myocardium. In those cases where there was a clinical suspicion of myocardial infarction and the MRI showed no signal abnormalities additional biopsies were taken from the septum, anterior and posterior wall. The MIA pathologist (JWO) and researcher (BMB) examined the microscopic slides of the biopsies; when in doubt, they consulted pathologists with specific expertise, not involved in the matching conventional autopsy, to reach a conclusion.

Cardiac imaging evaluation

CT

For each case, CT calcium score was calculated by one observer (IMW) using dedicated software (Syngo.via 3.0 Calcium Scoring[®], Siemens Healthcare, Forchheim, Germany) and expressed as total Agatston scores.

MRI

MR images were reconstructed and evaluated in the short axis view. Two radiologists with expertise in cardiac radiology (ACW, APP) independently evaluated MR images and in case of disagreement, consensus was reached in joint sessions. Myocardial infarctions were classified according to a modified classification by Jackowski et al. (12, 16, 17)

Peracute infarction (within 6 hours after onset) is characterized by T2 hypointense signal in the necrotic center, caused by a state of hypoperfusion. In the acute phase (within 6 hours – 1 week after onset) the marginal areas become edematous and show T2 hyperintense signal, T1 signal in the center is isointense and the edematous marginal regions can show T1 hypointense signal. Subacute infarction (>1 week after onset) shows

T2 hyperintense signal in the infarcted area when the area becomes reperfused, while the marginal areas show normal T1 and T2 signal. Chronic infarction (>2 months after onset) shows wall thinning and scar tissue reflected by T1 and T2 hypointense signal and foci of T1 hyperintense signal can be seen due to fatty infiltration.

In our analysis peracute and acute infarctions were grouped into one category and defined as acute MI (<1 week old infarction). Subacute and chronic infarctions were grouped into one category and defined as chronic MI (>1 week old infarction). MRI criteria for determining infarction age are detailed in table 2.

Table 2. MRI criteria for determining infarction age*

		Necrotic center		Marginal regions	
		T1	T2	T1	T2
Acute	Peracute (<6 hours)	=	↓	=	=
	Acute (6 hours – 1 week)	= / ↑	↓	↓	↑
Chronic	Subacute (1 week – 2 months)	=	↑	=	=
	Chronic (>2 months)	↓ / ↑ (fat)	↓	=	=

* Criteria based on Jackowski et al. (12, 16, 17)

Conventional autopsy

The day after MIA, a resident in pathology, supervised by the attending pathologist, performed conventional autopsy according to the departmental protocol. The autopsy report included medical history, postmortem diagnoses, a presumed cause of death, and answers to specific clinical questions, and was authorized by the pathologist. Macroscopic evaluation consisted of sectioning of the heart in slices of 0.5 to 1 cm and visual inspection of the myocardium. Lactate dehydrogenase (LDH) staining was performed on a mid-ventricular slice. Hematoxylin and Eosin (HE) was used for histologic staining. (18) When there was a discrepancy between the histology of the MIA and conventional autopsy, a pathologist with expertise in cardiac pathology (JHT) reviewed the histology. The following criteria for myocardial infarction age were used (separately or in combination): Acute MI: hypereosinophilia and loss of cross striation within myocardial fibers, contraction band necrosis, coagulation necrosis with or without granulocyte infiltration or hemorrhage, and various degrees of nuclear pyknosis, karyolysis, granulocyte infiltration and myocardial edema. Chronic MI: fibroblasts with loose connective tissue formation, angiogenesis (subacute), paucicellular collagenous fibrosis (chronic). (12)

Statistical analysis

Analyses were performed on the patient level. Conventional autopsy was used as the reference standard. We calculated sensitivity and specificity and 95% confidence intervals for the detection of acute and chronic MI for MRI and for MIA (MRI, CT and biopsies). Confidence intervals for sensitivity and specificity are Clopper-Pearson confidence intervals. (19) Inter-observer agreement was calculated using kappa statistics. Calculations were performed using IBM® SPSS® Statistics version 21.

ROC curves

We calculated ROC curves to investigate diagnostic value of CT (Total Agatston calcium score), MRI and biopsies for diagnosing acute and chronic myocardial infarction. In the analysis the diagnostic value (sensitivity and specificity and ROC curves) of biopsies was combined with MRI, because biopsies were taken from radiologically suspect areas, identified at MRI.

Results

Case recruitment

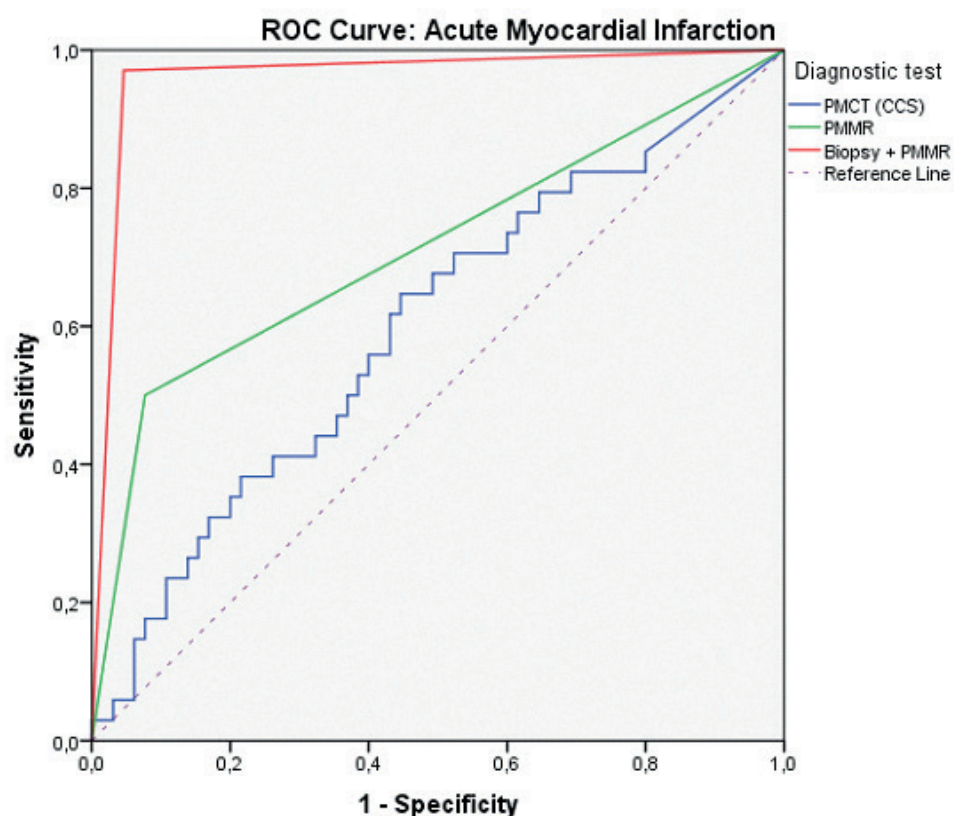
From January 2012 to December 2014, 100 consecutive cases (62 men, 38 women) were included in the study. One case was excluded because autopsy findings warranted a forensic autopsy. The mean interval between death and start of imaging was 23.2 ± 15.6 hours (range: 3.2-71.6). Mean age at the time of death was 62.5 years (range: 25-92). In the group with clinical suspicion of ischaemic heart disease 14/30 (46%) patients were admitted to the hospital with out-of-hospital cardiac arrest vs 3/69 (4%) in the group without clinical suspicion of cardiac death.

Agreement between clinical suspicion and autopsy findings

In the group with a clinical suspicion of ischaemic heart disease as the cause of death, acute MI was found in 16/30 (53.3%) of cases by conventional autopsy. In the group without clinical suspicion of ischaemic heart disease as the cause of death, acute MI was found in 18/69 (26.1%) cases. Twenty-two of the 34 cases with acute myocardial infarction found with conventional autopsy had no known ischaemic heart disease during life. Twenty cases had clinically known ischaemic heart disease during life (at least one ischaemic episode during life, determined by clinicians). Myocardial infarction, either chronic or acute, was confirmed by conventional autopsy and MIA in 16/20 of these cases (the same cases were identified with MIA and conventional autopsy).

Diagnostic performance

Acute MI was found in 34/99 cases on conventional autopsy and 36/99 cases on MIA. Chronic MI was found in 40/99 cases on conventional autopsy and 51/99 cases on MIA. The diagnostic accuracy of MRI, and biopsies for the detection of acute and chronic MI is shown in table 3 and for CT (Total Agatston calcium score) in table 4, and the ROC curves for acute and chronic MI are shown in Figure. 1 and 2 respectively.



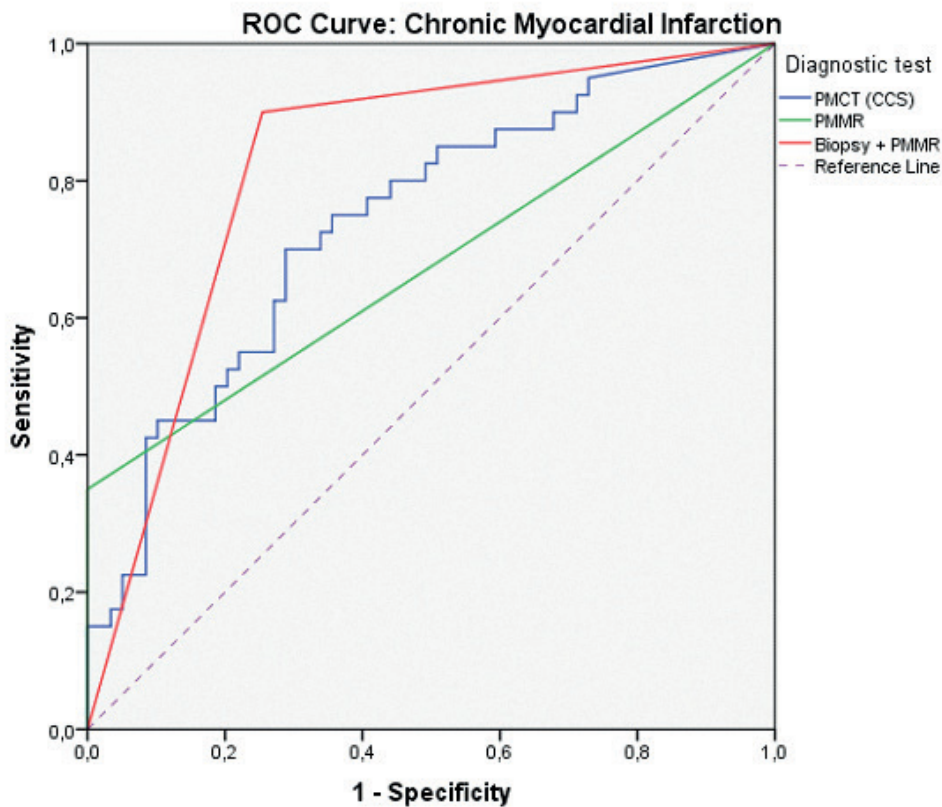
Area Under the Curve (AUC)

Diagnostic test(s)	AUC	95% CI
PMCT (Total Agatston calcium score)	0.60	0.48-0.72
PMMR	0.71	0.60-0.83
PMMR + biopsy	0.96	0.92-1.00

PMCT, postmortem computed tomography; PMMR, postmortem magnetic

resonance

Figure 1: Receiver operator characteristics curves (ROC) for CT, MRI and biopsy combined with MRI for the detection of acute myocardial infarction. The table details area under the curve for the different diagnostic tests and their corresponding 95% confidence intervals.



Area Under the Curve (AUC)

Diagnostic test(s)	AUC	95% CI
PMCT (Total Agatston calcium score)	0.74	0.64-0.84
PMMR	0.68	0.56-0.79
PMMR + biopsy	0.82	0.74-0.91

PMCT, postmortem computed tomography; PMMR, postmortem magnetic resonance

Figure 2: Receiver operator characteristics curve (ROC) for CT, MRI and biopsy combined with MRI for the detection of chronic myocardial infarction. The table details area under the curve for the different diagnostic tests and their corresponding 95% confidence intervals.

Acute myocardial infarction

Sensitivity of MRI for acute MI was 0.50 (95% CI: 0.32-0.68) and specificity was 0.92 (0.83-0.97). Sensitivity of MIA for acute MI was 0.97 (95% CI: 0.85-1.00) and specificity was 0.95 (0.87-0.99). Figure. 3 shows a case with acute MI.

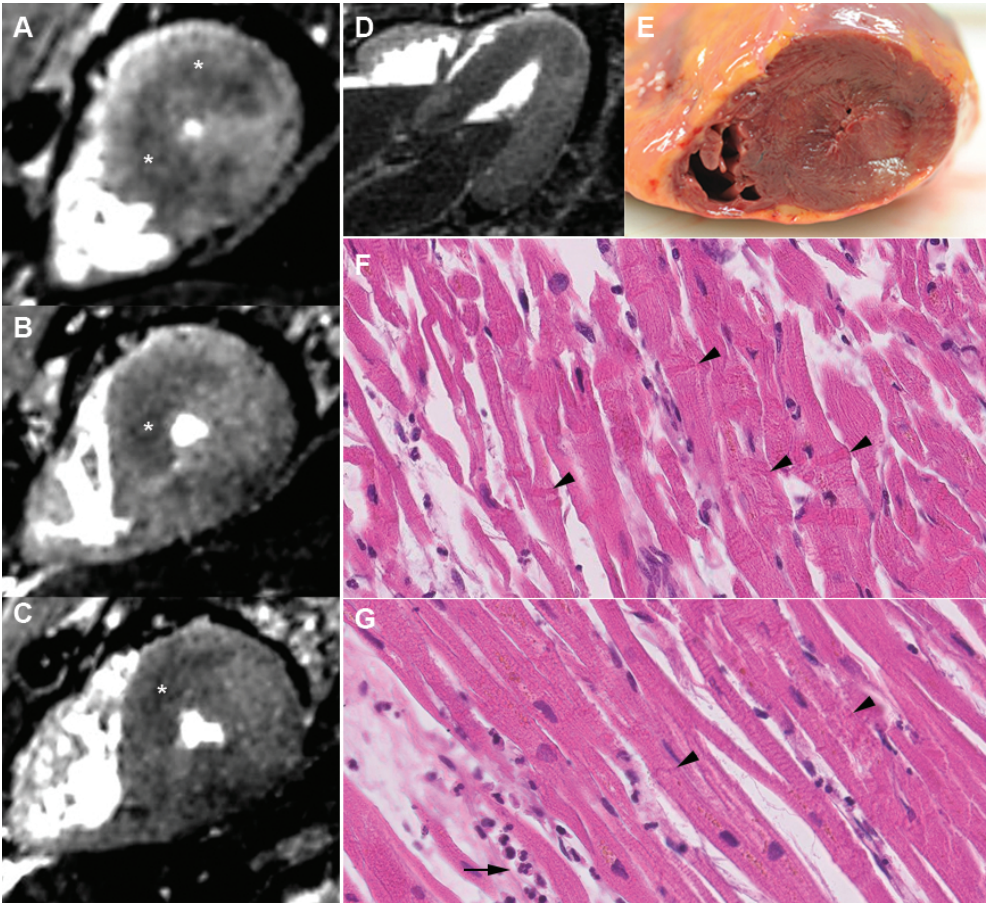


Figure 3: 45-year old man, who died shortly after requiring cardiopulmonary resuscitation following a period of acute chest pain during sports. T2w MRI short axis (A, B, C) and axial (D) views show diffuse hypointense signal (asterisks) on LAD territory (the entire septum, and anterior and posterior apical wall). T1w MRI did not show any abnormalities. Macroscopy (E) appeared normal. These areas were biopsied and microscopy (HE stain) shows contraction band necrosis (arrows) (F) and infiltration of granulocytes (arrow) (G) confirming acute myocardial infarction.

The area under the curve (AUC) for the detection of acute MI was 0.60 (95% CI: 0.48-0.72) for CT (Total Agatston calcium score), 0.71 (95% CI: 0.60-0.83) for MRI and 0.96 (95% CI: 0.92-1.00) for MRI with biopsy (MIA). Five cases were classified as peracute infarction on MRI, in 2 of these cases no evidence for an infarction was found on conventional autopsy.

Chronic myocardial infarction

Sensitivity of MRI for chronic MI was 0.35 (95% CI: 0.21-0.52) and specificity was 1.00 (95% CI: 0.94-1.00). Sensitivity of MIA for chronic MI was 0.90 (95% CI: 0.76-0.97) and specificity was 0.75 (95% CI: 0.62-0.85). Figure. 4 and 5 are examples of cases with chronic MI.

The area under the curve (AUC) for the detection of chronic MI was 0.74 (95% CI: 0.64-0.84) for CT (Total Agatston calcium score), 0.68 (95% CI: 0.56-0.79) for MRI and 0.82 (95% CI: 0.74-0.91) for MRI with biopsy (MIA).

Inter-observer agreement MRI

The two radiologists were in agreement in 82 of 99 cases, in the remaining 17 cases consensus was reached in joint sessions. The kappa score of inter-observer agreement was 0.85.

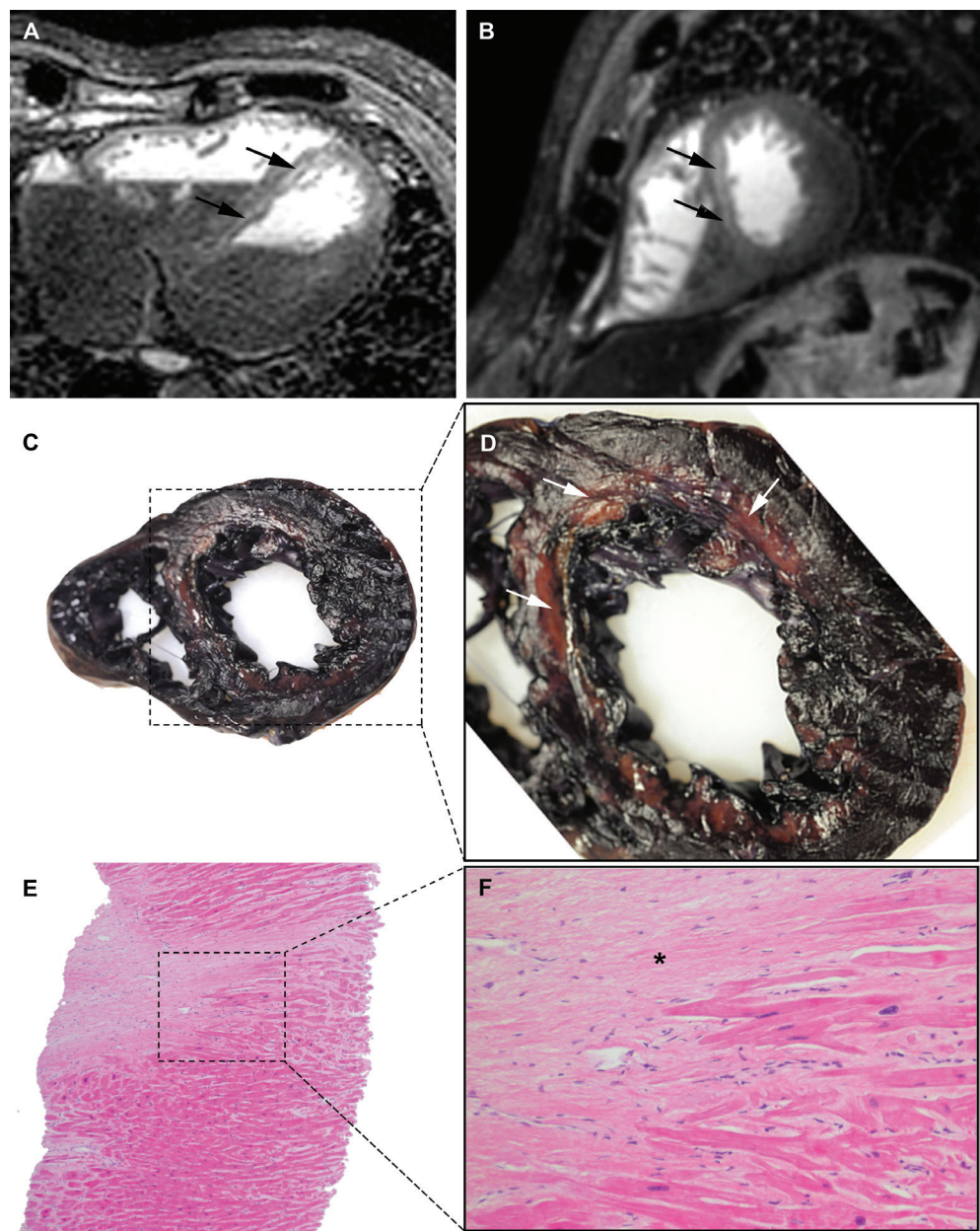


Figure 4: 66-year old man with a medical history of ischaemic heart disease, who died after a period of dyspnea and anemia. MRI STIR FSE T2w MRI (A) axial and (B) short axis showing septal mid and apical wall thinning of the left ventricle with hyperintense T2 signal (black arrows), indicative of a chronic infarction with subacute infarction overlying. (C) and (D) mid ventricular slice stained with LDH, showing discolouration of the corresponding areas of the myocardium (white arrows) indicative of acute infarction. (E) and (F) HE staining of CT-guided biopsy taken from the suspected area in the interventricular septum showing uninfamed replacement fibrosis with viable adjacent myocardium (asterisk).

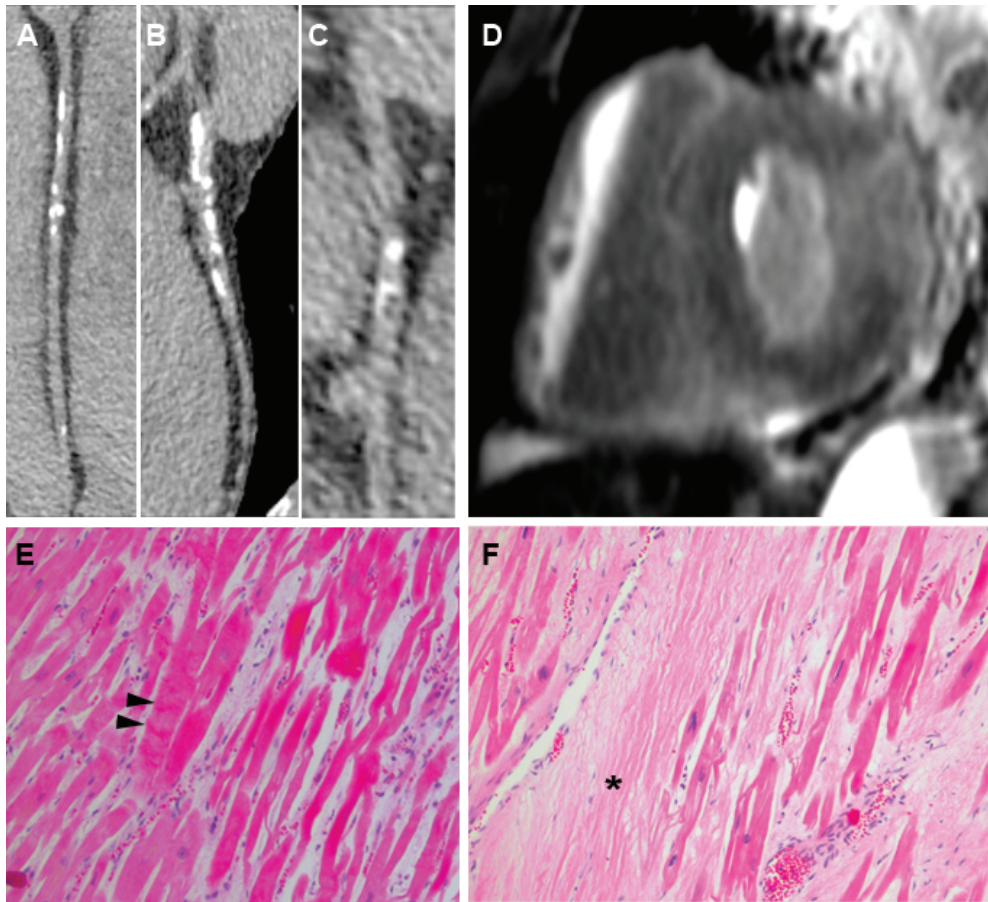


Figure 5: 54-year old man with no medical history of ischaemic heart disease. CT curved MPR of the RCA (A), LAD (B) and LCX (C), showing severely calcified coronary arteries (Total Agatston score: 409). T2w MRI (D): diffuse T2 hyperintense signal indicative of myocardial edema as a sign of acute myocardial infarction. These areas were biopsied and microscopy (HE) shows contraction band necrosis (E: arrow heads) and hypereosinophilia fitting with the diagnosis of acute myocardial infarction and connective tissue (F: asterisk) within a region of chronic myocardial infarction.

Table 3. Diagnostic accuracy of MRI and MIA

	Prevalence of disease (%)	N	TP	TN	FP	FN	K	Sensitivity (%)	Specificity (%)
MRI									
Acute MI	34	99	17	60	5	17	0.46	50 (32-68)	92 (83-97)
Chronic MI	40	99	14	59	0	26	0.39	35 (21-52)	100 (94-100)
MIA									
Acute MI	34	99	33	62	3	1	0.91	97 (85-100)	95 (87-99)
Chronic MI	40	99	36	44	15	4	0.62	90 (76-97)	75 (62-85)

N, number; TP, true positives; TN, true negatives; FP, false positives; FN, false negatives; K, kappa measure of agreement; MRI, magnetic resonance imaging; MI, myocardial infarction; MIA, minimally invasive autopsy. Values in parentheses represent upper and lower bound for 95% confidence interval.

Table 4. Diagnostic accuracy of CT (Total Agatston calcium score)

	Prevalence of disease (%)	N	TP	TN	FP	FN	K	Sensitivity (%)	Specificity (%)
Calcium score >0									
Acute MI	34	99	29	13	52	5	0.04	85 (68-95)	20 (11-32)
Chronic MI	40	99	38	16	43	2	0.19	95 (83-99)	27 (16-40)
Calcium score >100									
Acute MI	34	99	24	30	35	10	0.14	71 (53-85)	46 (34-59)
Chronic MI	40	99	32	32	27	8	0.32	80 (64-91)	54 (41-67)
Calcium score >400									
Acute MI	34	99	17	41	24	17	0.13	50 (32-68)	63 (50-75)
Chronic MI	40	99	25	43	16	15	0.35	63 (46-77)	73 (59-84)

N, number; TP, true positives; TN, true negatives; FP, false positives; FN, false negatives; K, kappa measure of agreement; MI, myocardial infarction. Values in parentheses represent upper and lower bound for 95% confidence interval.

Discussion

In this study we investigated the diagnostic accuracy of a minimally invasive autopsy (MIA) consisting of MRI, CT and CT-guided biopsy for detection of ischaemic heart disease in a hospital setting. We found that the combination of MRI and biopsies, had the highest accuracy for detecting acute and chronic MI with conventional autopsy as reference standard. MRI without biopsies showed a high specificity, but low sensitivity for acute and chronic MI. High CT Agatston calcium score (>400) was a good predictor for chronic MI, but not for acute MI.

We found a lower sensitivity of MRI as a standalone test for acute MI (0.50) compared to other studies investigating MRI. Ruder et al. reported that with MRI acute MI (within 3 hours after onset) could be detected in ex vivo porcine hearts in which they correctly detected acute infarctions in all twenty-one cases. (20) Forensic studies showed that with MRI acute and chronic MI (up to 100% sensitivity) could be accurately diagnosed in human subjects. Importantly, MRI could diagnose peracute MI (onset within 3 hours) in cases not yet showing histological changes, but with a matching coronary stenosis at conventional autopsy. (12, 13, 17)

The differences in sensitivity and specificity among studies can be explained by the differences in studied population and clinical setting; most are forensic studies that investigated subjects who died under the suspicion of an out-of-hospital-cardiac-arrest and as such had a high pre-test probability. Also, these studies often involve high-resolution cardiac imaging at 3T scanners using surface coils and relatively long scan time for imaging only the heart (approximately 1 hour). (16) Conversely, we scanned in a hospital setting and performed total-body imaging to diagnose both cardiac and non-cardiac cause of death. So as not to interfere with the patient workflow at the MR scanner, we were restricted to one-hour scan time for imaging the entire body.

The addition of biopsies to MRI increased the sensitivity substantially. This highlights the importance of extensive sampling, even when no changes are visible yet on MRI. The big difference between sensitivity of MRI and MRI combined with biopsies can be explained by the quantity of sampling. From each biopsy location, at least 5 samples were taken, e.g. from the lateral wall also the mid and posterior segments were biopsied. Furthermore, in those cases where there was a clinical suspicion of myocardial ischemia and the MRI showed no signal abnormalities, extra biopsies were taken from the septum, anterior and posterior wall (both mid and posterior segments).

The noninvasive approach (CT and/or MRI) is less expensive than the minimally invasive approach (imaging plus biopsy). CT is now widely used as a stand-alone modality because of its high accessibility, short examination time and robust performance. CT can provide better mortality statistics than the cause of death determined by the clinician and is useful for excluding certain diagnoses. However, for diagnosing acute myocardial infarction, our results show that the diagnostic accuracy of CT as stand-alone test is insufficient. (21, 22)

To improve CT performance, in particular for ischaemic heart disease, more recent studies report on the diagnostic value of CT angiography. Grabherr et al. extensively performed feasibility studies on CTA using different contrast agents and perfusion techniques. There are different CTA approaches; it can be targeted at the coronary arteries by selective placement of the catheter at the level of the coronary ostia, or total-body CTA can be performed including multiphase scanning. (9, 23-25)

Wichman et al. applied total-body CTA in 50 ICU patients who died unexpectedly or within 48 hours of an event requiring resuscitation and found that CTA confirmed 93% of the clinical diagnoses, and autopsy confirmed 80%. In addition, CTA and CA identified 16 new major and 238 new minor diagnoses. They concluded that in cases of unexpected death CTA was a valuable addition to autopsy.

Rutty et al. performed total-body CTA in 210 cases of natural and non-suspicious unnatural death and found that CTA established a cause of death in 92% of cases. The number of discrepancies with the final cause of death was not significantly different between autopsy and CTA, suggesting that total-body CTA is a feasible alternative to autopsy. (26, 27)

A drawback of CTA is that it requires specific training, technical equipment and contrast agents and is time-consuming due to extensive preparation of the body (e.g. intra-arterial and/or intravenous femoral access for catheter placement) prior to scanning.

At the time of the study, the equipment was not available and professional expertise and scanner availability to perform CTA was lacking.

Another noninvasive approach is the use of stand-alone MRI. Diffusion tensor imaging (DTI) is showing promising results in diagnosing myocardial ischemia in situ, correctly predicting MI (either acute or chronic) with an accuracy of 0.73, using fractional anisotropy and mean diffusivity. (28)

First studies show that quantitative MRI can detect and differentiate between early and following stages of myocardial ischemia based on T1, T2 and proton density values. (29-31) They concluded that temperature-corrected quantitative MRI can diagnose early acute, acute and chronic MI, but histological confirmation is required.

In the hospital setting an important part of every postmortem examination should be a thorough evaluation of the medical history and clinical circumstances prior to death. In our patients with known obstructive coronary artery disease, chronic and or acute MI was confirmed in 16 out of 20 cases by postmortem examination (both by MIA and conventional autopsy). Conventional autopsy found 22 new cases of acute MI, highlighting the lasting need for postmortem examinations.

Today the use of postmortem imaging, mostly CT, is widely accepted as adjunct to the medicolegal autopsy. (7, 26, 27, 32, 33) In the hospital setting, there is a growing interest in postmortem imaging, however, expertise and logistics (e.g. access to scanners) are still important limitations.

Conclusion

We evaluated the diagnostic accuracy of minimally invasive autopsy for the detection of ischaemic heart disease in a hospital setting. We found that the combination of MRI with biopsies had high sensitivity and specificity for the detection of acute and chronic MI.

References

1. World health organization, The top 10 causes of death (Updated January 2017), Retrieved from: <http://www.who.int/mediacentre/factsheets/fs310/en/>.
2. Shojania KG, Burton EC, McDonald KM, Goldman L. Changes in rates of autopsy-detected diagnostic errors over time: a systematic review. *JAMA*. 2003;289(21):2849-56.
3. van den Tweel JG, Wittekind C. The medical autopsy as quality assurance tool in clinical medicine: dreams and realities. *Virchows Arch*. 2016;468(1):75-81.
4. Burton JL, Underwood J. Clinical, educational, and epidemiological value of autopsy. *Lancet*. 2007;369(9571):1471-80.
5. Turnbull A, Osborn M, Nicholas N. Hospital autopsy: Endangered or extinct? *J Clin Pathol*. 2015;68(8):601-4.
6. Blokker BM, Wagenveld IM, Weustink AC, Oosterhuis JW, Hunink MG. Non-invasive or minimally invasive autopsy compared to conventional autopsy of suspected natural deaths in adults: a systematic review. *Eur Radiol*. 2016;26(4):1159-79.
7. Eriksson A, Gustafsson T, Höistad M, Hultcrantz M, Jacobson S, Mejare I, et al. Diagnostic accuracy of postmortem imaging vs autopsy - A systematic review. *European Journal of Radiology*. 2017;89:249-69.
8. Grabherr S, Djonov V, Yen K, Thali MJ, Dirnhofer R. Postmortem angiography: review of former and current methods. *AJR Am J Roentgenol*. 2007;188(3):832-8.
9. Turillazzi E, Frati P, Pascale N, Pomara C, Grilli G, Viola RV, et al. Multi-phase post-mortem CT-angiography: a pathologic correlation study on cardiovascular sudden death. *J Geriatr Cardiol*. 2016;13(10):855-65.
10. Grabherr S, Grimm J, Dominguez A, Vanhaebost J, Mangin P. Advances in post-mortem CT-angiography. *Br J Radiol*. 2014;87(1036):20130488.
11. Grabherr S, Grimm J, Baumann P, Mangin P. Application of contrast media in post-mortem imaging (CT and MRI). *Radiol Med*. 2015;120(9):824-34.
12. Jackowski C, Christe A, Sonnenschein M, Aghayev E, Thali MJ. Postmortem unenhanced magnetic resonance imaging of myocardial infarction in correlation to histological infarction age characterization. *Eur Heart J*. 2006;27(20):2459-67.
13. Jackowski C. Special issue on postmortem imaging 2013. *Forensic Sci Int*. 2013;225(1-3):1-2.
14. Jackowski C, Sonnenschein M, Thali MJ, Aghayev E, von Allmen G, Yen K, et al. Virtopsy: postmortem minimally invasive angiography using cross section techniques--implementation and preliminary results. *J Forensic Sci*. 2005;50(5):1175-86.
15. Michaud K, Grabherr S, Jackowski C, Bollmann MD, Doenz F, Mangin P. Postmortem imaging of sudden cardiac death. *Int J Legal Med*. 2014;128(1):127-37.
16. Jackowski C, Schwendener N, Grabherr S, Persson A. Post-mortem cardiac 3-T magnetic resonance imaging: visualization of sudden cardiac death? *J Am Coll Cardiol*. 2013;62(7):617-29.

17. Jackowski C, Warntjes MJ, Berge J, Bar W, Persson A. Magnetic resonance imaging goes postmortem: noninvasive detection and assessment of myocardial infarction by postmortem MRI. *Eur Radiol.* 2011;21(1):70-8.
18. Basso C, Aguilera B, Banner J, Cohle S, d'Amati G, de Gouveia RH, et al. Guidelines for autopsy investigation of sudden cardiac death: 2017 update from the Association for European Cardiovascular Pathology. *Virchows Archiv.* 2017;471(6):691-705.
19. Ross D. Accurate confidence intervals for binomial proportion and Poisson rate estimation. *Computers in Biology and Medicine.* 2003;33:509-31.
20. Ruder TD, Ebert LC, Khattab AA, Rieben R, Thali MJ, Kamat P. Edema is a sign of early acute myocardial infarction on post-mortem magnetic resonance imaging. *Forensic Sci Med Pathol.* 2013;9(4):501-5.
21. Oyake Y, Aoki T, Shiotani S, Kohno M, Ohashi N, Akutsu H, et al. Postmortem computed tomography for detecting causes of sudden death in infants and children: retrospective review of cases. *Radiat Med.* 2006;24(7):493-502.
22. Inai K, Noriki S, Kinoshita K, Sakai T, Kimura H, Nishijima A, et al. Postmortem CT is more accurate than clinical diagnosis for identifying the immediate cause of death in hospitalized patients: a prospective autopsy-based study. *Virchows Arch.* 2016;469(1):101-9.
23. Roberts IS, Benamore RE, Peebles C, Roobottom C, Traill ZC. Technical report: diagnosis of coronary artery disease using minimally invasive autopsy: evaluation of a novel method of post-mortem coronary CT angiography. *Clin Radiol.* 2011;66(7):645-50.
24. Saunders SL, Morgan B, Raj V, Robinson CE, Rutty GN. Targeted post-mortem computed tomography cardiac angiography: proof of concept. *Int J Legal Med.* 2011;125(4):609-16.
25. Rutty G, Saunders S, Morgan B, Raj V. Targeted cardiac post-mortem computed tomography angiography: a pictorial review. *Forensic Sci Med Pathol.* 2012;8(1):40-7.
26. Rutty GN, Morgan B, Robinson C, et al. Diagnostic accuracy of post-mortem CT with targeted coronary angiography versus autopsy for coroner-requested post-mortem investigations: a prospective, masked, comparison study. *Lancet.* 2017;390(10090):145-54.
27. Wichmann D, Heinemann A, Weinberg C, Vogel H, Hoepker WW, Grabherr S, et al. Virtual autopsy with multiphase postmortem computed tomographic angiography versus traditional medical autopsy to investigate unexpected deaths of hospitalized patients: a cohort study. *Ann Intern Med.* 2014;160(8):534-41.
28. Winklhofer S, Stoeck CT, Berger N, Thali M, Manka R, Kozerke S, et al. Post-mortem cardiac diffusion tensor imaging: detection of myocardial infarction and remodeling of myofiber architecture. *Eur Radiol.* 2014;24(11):2810-8.
29. Schwendener N, Jackowski C, Persson A, Warntjes MJ, Schuster F, Riva F, et al. Detection and differentiation of early acute and following age stages of myocardial infarction with quantitative post-mortem cardiac 1.5T MR. *Forensic Sci Int.* 2017;270:248-54.
30. Zech WD, Schwendener N, Persson A, Warntjes MJ, Jackowski C. Postmortem MR quantification of the heart for characterization and differentiation of ischaemic myocardial lesions. *Eur Radiol.* 2015;25(7):2067-73.

31. Persson A, Baeckmann J, Berge J, Jackowski C, Warntjes M, Zech WD. Temperature-corrected postmortem 3-T MR quantification of histopathological early acute and chronic myocardial infarction: a feasibility study. *Int J Legal Med.* 2017.
32. Dirnhofer R, Jackowski C, Vock P, Potter K, Thali MJ. VIRTOPSY: minimally invasive, imaging-guided virtual autopsy. *Radiographics.* 2006;26(5):1305-33.
33. Flach PM, Thali MJ, Germerott T. Times have changed! Forensic radiology--a new challenge for radiology and forensic pathology. *AJR Am J Roentgenol.* 2014;202(4):W325-34.

6

CHAPTER 6

Hospital implementation of minimally invasive autopsy: a prospective cohort study of clinical performance and costs

Ivo M. Wagenveld, M.G. Myriam Hunink, Piotr A. Wielopolski, Folkert J. van Kemenade, Gabriel P. Krestin, Britt M. Blokker, J. Wolter Oosterhuis, Annick C. Weustink

Objectives

Autopsy rates worldwide have dropped significantly over the last decades and imaging-based autopsies are increasingly used as an alternative to conventional autopsy. Our aim was to evaluate the clinical performance and cost of minimally invasive autopsy.

Methods

This study was part of a prospective cohort study evaluating a newly implemented minimally invasive autopsy consisting of MRI, CT, and biopsies. We calculated diagnostic yield and clinical utility - defined as the percentage successfully answered clinical questions - of minimally invasive autopsy. We performed minimally invasive autopsy in 46 deceased (30 men, 16 women; mean age 62.9 ± 17.5 , min-max: 18-91).

Results

Ninety-six major diagnoses were found with the minimally invasive autopsy of which 47/96 (49.0%) were new diagnoses. CT found 65/96 (67.7%) major diagnoses and MRI found 82/96 (85.4%) major diagnoses. Eighty-four clinical questions were asked in all cases. Seventy-one (84.5%) of these questions could be answered with minimally invasive autopsy. CT successfully answered 34/84 (40.5%) clinical questions; in 23/84 (27.4%) without the need for biopsies, and in 11/84 (13.0%) a biopsy was required. MRI successfully answered 60/84 (71.4%) clinical questions, in 27/84 (32.1%) without the need for biopsies, and in 33/84 (39.8%) a biopsy was required. The mean cost of a minimally invasive autopsy was €1296 including brain biopsies and €1087 without brain biopsies. Mean cost of CT was €187 and of MRI €284.

Conclusion

A minimally invasive autopsy, consisting of CT, MRI and CT-guided biopsies, performs well in answering clinical questions and detecting major diagnoses. However, the diagnostic yield and clinical utility were quite low for postmortem CT and MRI as standalone modalities.

Introduction

Autopsy rates worldwide have dropped significantly, from rates of up to 50% in 1960s to 0-10% today. (1-3) Both in forensic and clinical medicine, the imaging autopsy is increasingly used as adjunct or alternative to the conventional autopsy. Noninvasive autopsies use CT, MRI, or ultrasound as stand-alone test or combinations of diagnostic tests. (4, 5) A minimally invasive autopsy may include laparoscopy, CT-angiography (CTA) and/or image-guided tissue biopsies. (6-19) The value of the modern imaging autopsy in the hospital setting is now under investigation and first studies show that postmortem MRI and CTA have good performance for establishing the cause of death and related or unrelated diagnoses. (6, 20)

In this study, we share our results of the implementation of minimally invasive autopsy procedure in our hospital over a 1-year-period. Because not much is reported yet about the clinical performance and costs of such procedures, our aim was to evaluate diagnostic yield and clinical utility - defined as the percentage of successfully answered clinical questions - and to calculate the cost of minimally invasive autopsy - consisting of MRI, CT, and CT-guided biopsies.

Methods

Study design and patients

This prospective cohort study was performed at the Erasmus University Medical Center in Rotterdam, the Netherlands, from September 2016 to December 2017. This study was approved by the Erasmus MC Medical Ethical Committee (file number MEC-2011-055). Written informed consent from relatives was acquired in all included cases. During this period both minimally invasive, and conventional autopsy were available to the next-of-kin of all deceased adult patients. Consent for both autopsy methods was asked by the treating physician. In difficult cases we offered the option to perform both minimally invasive autopsy and conventional autopsy, or minimally invasive autopsy combined with a partial conventional autopsy of a specified organ or organ system (e.g. minimally invasive autopsy combined with a partial conventional autopsy of the heart and lungs). In these cases, the minimally invasive autopsy was performed first, and if imaging alone did not answer all clinical questions and give a definite cause of death, minimally invasive autopsy was followed by conventional autopsy, or partial autopsy on the same day. The size of the cohort was determined by the 1-year inclusion period.

Minimally invasive autopsy

Preparation and transportation

The bodies were stored in a refrigerated environment during the period between arrival in the mortuary and the start of imaging. Prior to minimally invasive autopsy the body received general postmortem care in the mortuary. This consisted of cleaning, photographing and removing metal and implanted medical materials in and around the body (only if there was no clinical suspicion about their correct positioning). Next, the body was placed in an MRI compatible body bag.

Imaging

MRI was performed on a 1.5T scanner (Discovery MR450, GE Healthcare, Milwaukee, Wisconsin USA), prior to CT scanning. The body was scanned in supine position and was not moved after initial positioning was completed. MRI acquisition contained T1-weighted and T2-weighted scans from head and torso, scanned in 5 segments of 20 cm (Table 1), supplemented with additional acquisitions that depended on the clinical questions (S1 protocols). MRI scanning time was limited to 1 hour, excluding transportation and positioning.

Table 1. Postmortem MRI protocol.

	T1	T2
Repetition time (ms)	3285	9400
Echo time (ms)	10	42
Inversion time (ms)	892	120
Echo-train-length	6	10
NSA	0.5	1.0
Flip angle (°)	160	160
Coil	Body coil	Body coil
Slice width (mm)	5.0	5.0
FOV (mm)	480x288	480x288
Matrix	384x224	288x160

Table 1 legend: MRI was performed with a 1.5-T scanner (Discovery MR450; GE Medical Systems, Milwaukee, Wis). NSA = number of signals averaged, FOV = field of view.

CT scans were acquired from head to feet (SOMATOM Definition Edge, Siemens Healthcare, Forchheim, Germany), according to a standardized protocol (Table 2).

Table 2. Postmortem CT protocol.

	Total body protocol	Head – Neck protocol
Rotation time (s)	1.0	1.0
Tube voltage (kV)	120	100
Tube current (eff. mAs)	400	750
Slice collimation (mm)	2 x 64 x 0.6	2 x 64 x 0.6
Pitch	0.65	0.35
Scan time (s)	69.9	24.1
Reconstruction	Iterative	Iterative

Table 2 legend: CT was performed with a dual-source CT scanner (SOMATOM Definition Edge; Siemens, Forchheim, Germany) and included scans of brain, neck, torso, and lower extremities.

A board-certified radiologist interpreted the CT and MRI scans directly after acquisition was completed, compared the postmortem scans with available premortem imaging, and identified suspected pathological lesions to plan CT-guided biopsies. The radiologist was familiar with the medical history and had access to the electronic patient record.

Biopsies

A board-certified pathologist and the treating clinician were consulted to discuss imaging findings and plan biopsy targets. CT-guided biopsies were performed with a reusable biopsy instrument (Bard Biopsy Systems, Tempe, USA) directly after the CT scan was completed. Biopsies (12 Gauge) were routinely taken from heart, lungs, liver, kidneys, and spleen. Additional biopsies were taken from suspected pathology at imaging. From every biopsy location 4-6 different needle biopsies were sampled to reduce the risk of sampling error. Microbiology cultures and fluid for cytology were sampled upon indication. Histologic staining (H&E) was performed according to department protocol and upon examination of the pathologist additional pathological stains were performed on indication.

If consented to, stereoscopic brain biopsies were planned and executed using a stereoscopic navigation system (Brainlab Kolibri, Brainlab, Munich, Germany). The radiologist performed the brain biopsies in the mortuary directly after the CT-guided biopsies of the torso were completed.

Reporting

The radiologist made a standardized radiology report that included both imaging findings and biopsy targets. Postmortem imaging was compared to antemortem imaging when available. Radiologists or pathologists in different subspecialties were consulted when organ-specific expertise was required. The pathologist evaluated the biopsies and discussed the imaging and microscopic findings with the radiologist during interdisciplinary meetings. The pathologist integrated the radiological report in the autopsy report and both pathologist and radiologist authorized the final minimally invasive autopsy report. Both the radiologist and pathologist had knowledge of the patient history and clinical questions and these were always addressed in the final report. The whole process of preparation, imaging, biopsies and reporting is schematically shown in Figure 1.

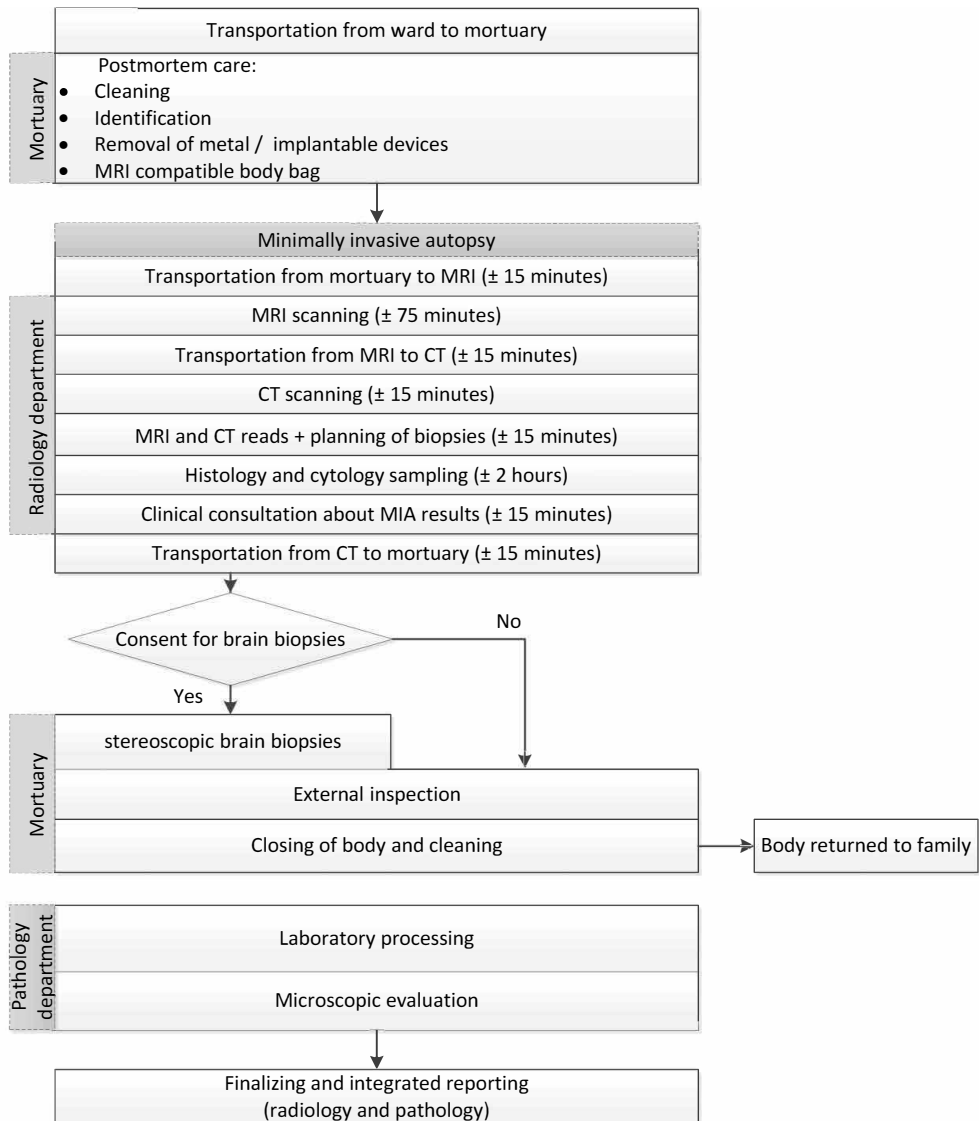


Figure 1: Logistical flow-chart of minimally invasive autopsy.

Data Analysis

Clinical performance

Diagnostic yield

All major diagnoses found with minimally invasive autopsy (CT, MRI, biopsies, or partial autopsy) were registered in a clinical data file (Microsoft Excel). Major diagnoses were defined as diagnoses related to the cause of death. For all diagnoses we registered if the diagnosis was found with CT and/or MRI, and if a biopsy was needed. For analysis purposes imaging confidence scores were attributed on the diagnosis level for CT and MRI separately. A diagnosis was scored as 0 if it was found on neither CT nor MRI, a diagnosis was scored as 1 if it was detected on CT or MRI but no likely diagnosis could be made on imaging alone and a biopsy was needed for further elucidation, a diagnosis was scored as 2 if it was detected on imaging with high likelihood of being the suspected diagnosis, but a biopsy is needed for confirmation, and a score of 3 was given if a definitive diagnosis could be made based on CT or MRI and no biopsy was required for confirmation. A Chi-squared test was used to test if there was statistically significant difference in diagnostic yield between CT and MRI.

Clinical Utility

We calculated the percentage of clinical questions that could be answered by minimally invasive autopsy. To evaluate this, we registered all clinical questions from the minimally invasive autopsy request forms provided by the treating physicians. We calculated the percentage of successfully answered clinical questions. All analyses were performed on the individual question level. We retrospectively evaluated if the radiologist was able to provide an answer to the clinical question with CT or MRI, or the combination of CT and MRI, and in how many cases a biopsy was needed to answer the question. A Chi-squared test was used to test if there was a statistically significant difference between clinical utility of CT and MRI.

Cost calculation

We evaluated the mean cost per procedure (in Euros) of the minimally invasive autopsy from the perspective of the hospital. We recorded all direct costs of the minimally invasive autopsy including materials used, personnel involved, energy usage, maintenance and depreciation of scanning equipment. Overhead costs were also included in the cost calculation and included the cost of scanning rooms used and planning costs for the imaging procedures. Other costs were use of the hospital's Picture Archiving and Communication System (PACS), as well as reporting fees. Costs of the pathology department mainly comprised personnel and overhead costs and fees for the histological processing of biopsies. Personnel cost was estimated based on the average wage multiplied

by the average amount of time required for the specified parts of the procedure. Cost of cytology and toxicology were not factored in the cost calculation, because both were only performed in a small number of cases. For comparison purposes we also calculated the costs of conventional autopsy as performed in our hospital.

Results

Recruitment

We evaluated 46 cases that underwent minimally invasive autopsy. In 16 of these cases permission was given for brain biopsies. Within the group with permission for minimally invasive autopsy, there were 6 cases with additional permission for a partial autopsy (in 5 cases partial autopsy of heart and lungs, in 1 case partial autopsy of an adrenal lesion that was seen prior to death). In an additional 4 cases there was permission for a full conventional autopsy after the minimally invasive autopsy, and in 2 of these cases there was also permission for brain autopsy. A case inclusion diagram is shown in Fig 2.

The cohort consisted of 30/46 (65.2%) men and 16/46 (34.8%) women, mean age was 62.9 years old (SD: 17.5, min-max: 18-91). MRI acquisition time was approximately 60 minutes, CT acquisition took 20 minutes including the multiplanar reconstructions. Torso biopsies took between 1.5 and 2.5 hours and brain biopsies approximately 1 hour. The full procedure time including preparation and transportation was 4 to 5 hours on average, depending on the number and location of biopsies necessary. Per minimally invasive autopsy case, 17 different targets were biopsied on average. Cytology samples were taken in 11 cases.

Clinical performance

Diagnostic yield

Ninety-six major diagnoses were found with the minimally invasive autopsy: 47/96 (49.0%) were new diagnoses and in another 15/96 (15.6%) the minimally invasive autopsy revealed an unexpected but clinically relevant diagnosis that was not known prior to death (e.g. new information on the size or etiology of a known malignancy).

MRI had a significantly higher diagnostic yield than CT: 82 were (85.4%) found with MRI and 65 with CT (67.7%) ($p=0.008$).

The imaging confidence scores for CT and MRI are shown in Figure 3 and case examples are shown in Figures 4 – 6. The specific diagnoses per case and corresponding imaging confidence scores are detailed in Table 3.

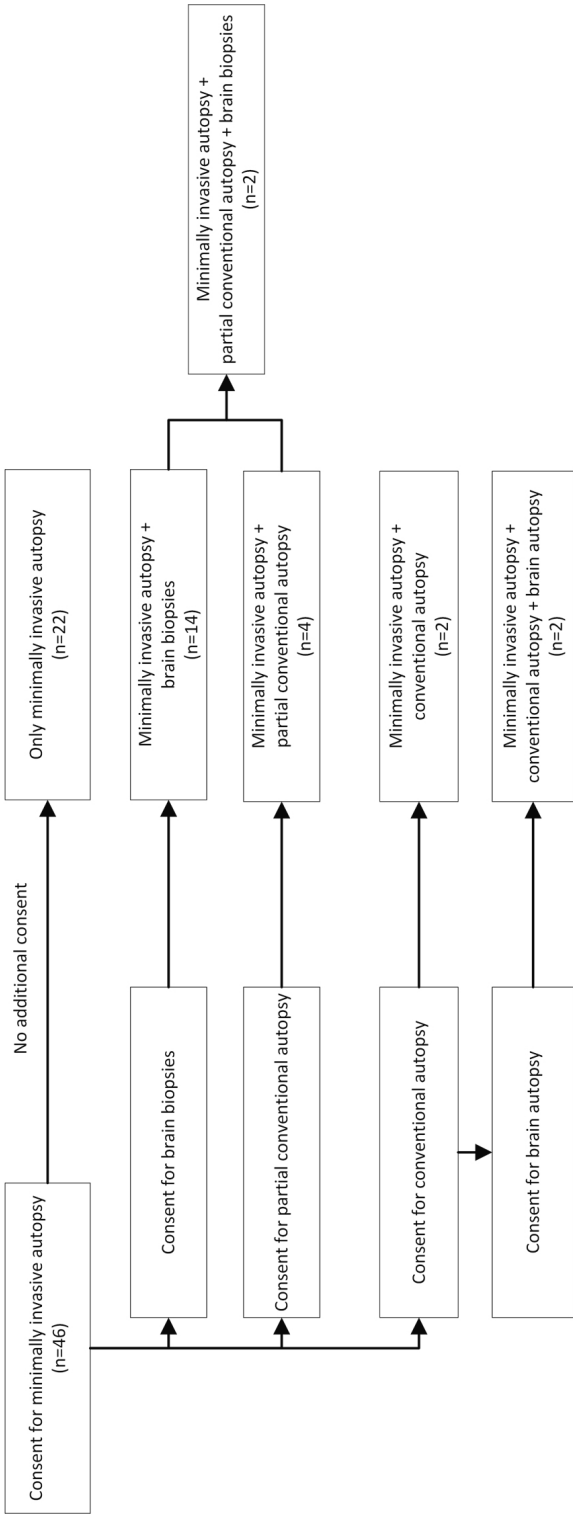
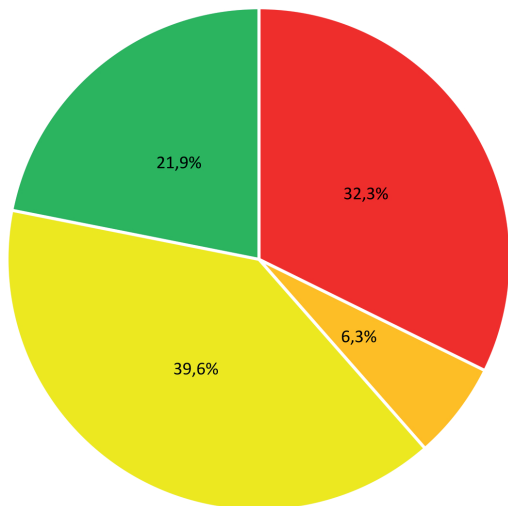


Figure 2: Case inclusion flow-chart.

Diagnostic confidence level CT (n=96)



Diagnostic confidence level MRI (n=96)

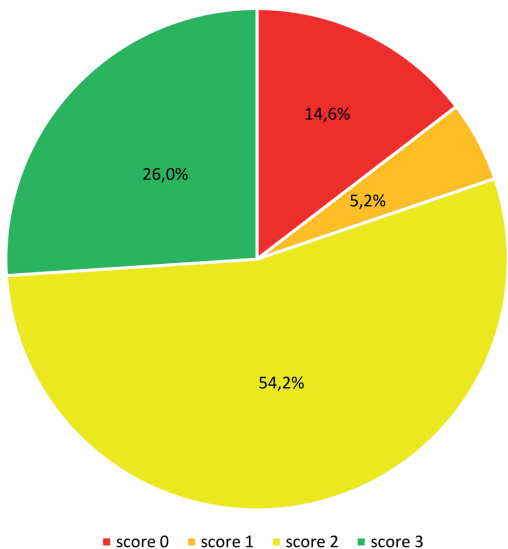


Figure 3: Diagnostic yield of postmortem CT and MRI. Red – Imaging confidence score 0: diagnosis not detected; Orange – score 1: diagnosis detected on imaging, but unclear; biopsy required; Yellow – score 2: diagnosis seen on imaging and likely, biopsy required for confirmation; Green - score 3: diagnosis certain, no biopsy required.

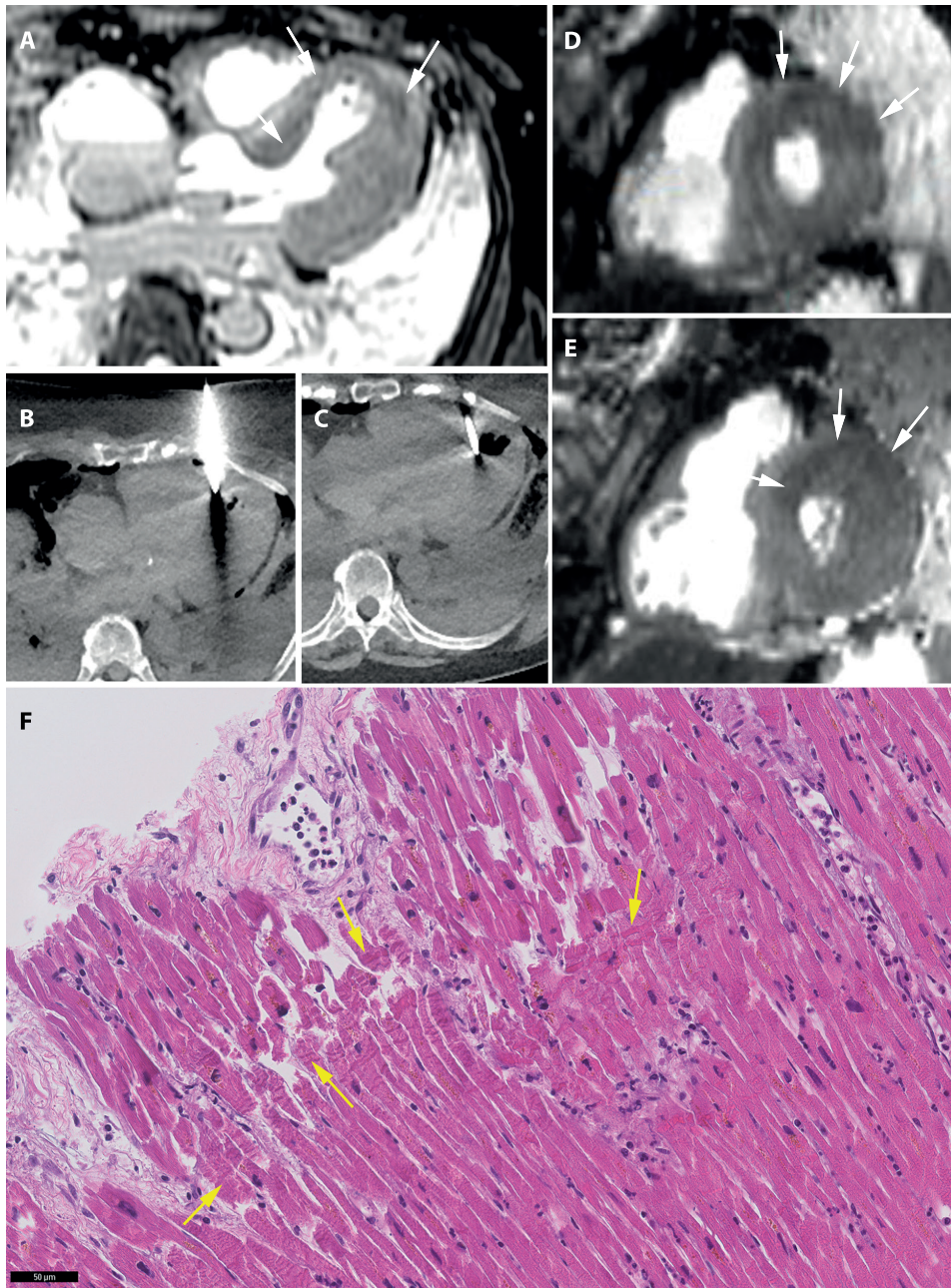


Figure 4: Acute myocardial infarction. 77-year-old woman with a history of hypertension and cerebral ischemia. She was resuscitated unsuccessfully after she was found gasping and unresponsive in bed. Postmortem MRI found T2 hypointensity in the septal, anterior and lateral myocardium (A, D, E: arrows) indicative of acute myocardial infarction in the area supplied by the left anterior descending (LAD) artery. CT-guided biopsies (B and C) from the myocardium were taken and histology showed contraction band necrosis (arrows) confirming acute myocardial infarction (F).

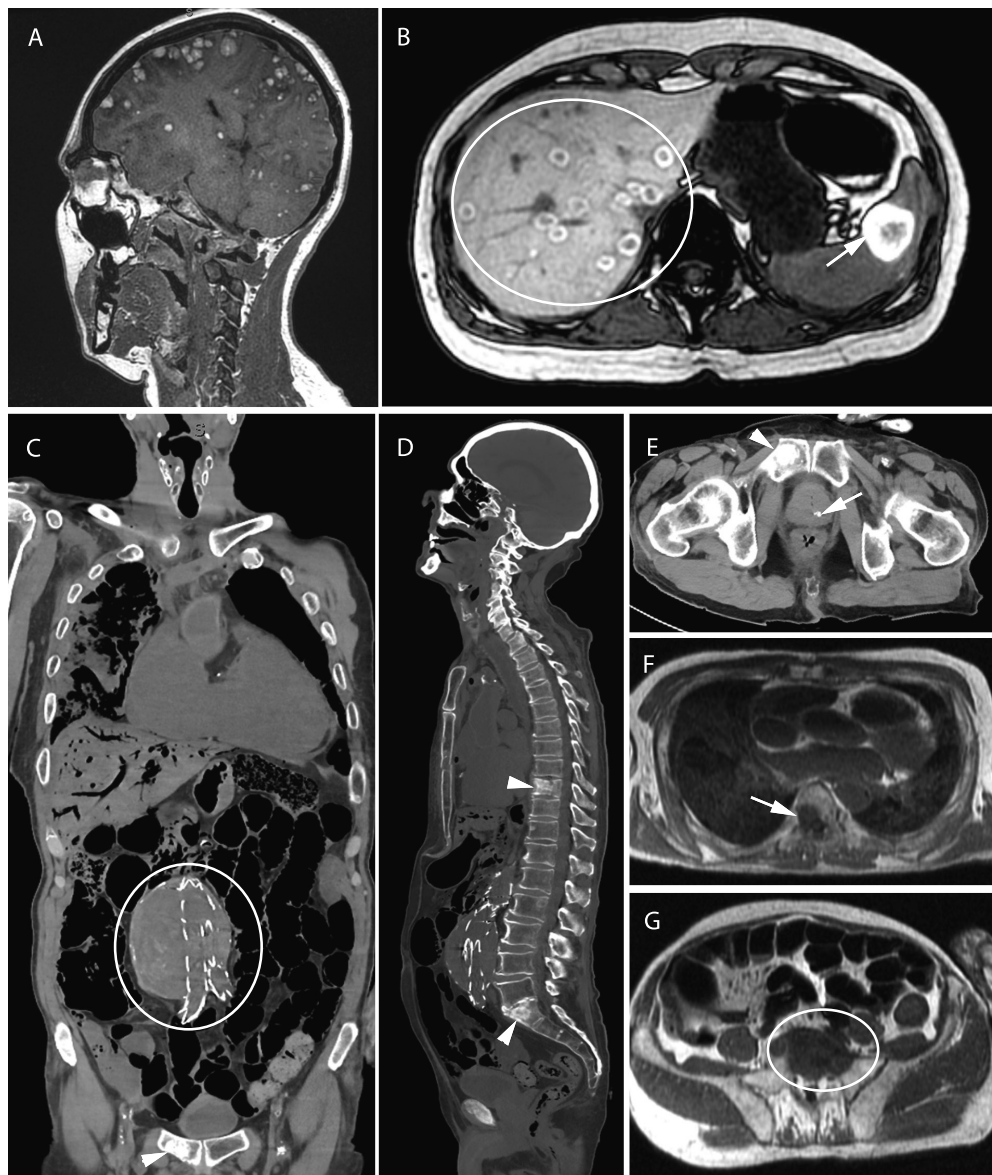


Figure 5: Oncologic cases. A and B: 45-year-old woman with metastasized melanoma. Postmortem T1w MRI shows extensive metastases in brain (A), liver (circle) and spleen (arrows) (B). Tissue was sampled for histologic examination and genetic testing. C through G: 87-year-old man with a known aneurysm of the abdominal aorta, for which he underwent endovascular aortic repair (C: circle). The clinician wanted to exclude aortic rupture or acute myocardial infarction. Minimally invasive autopsy found prostate cancer (E: arrow) with multiple osseous metastases (D and E: arrowheads, F: arrow, G: circle) as unexpected findings. Focal signal abnormalities in the myocardium and histology confirmed acute myocardial infarction as the cause of death (not shown in this image).

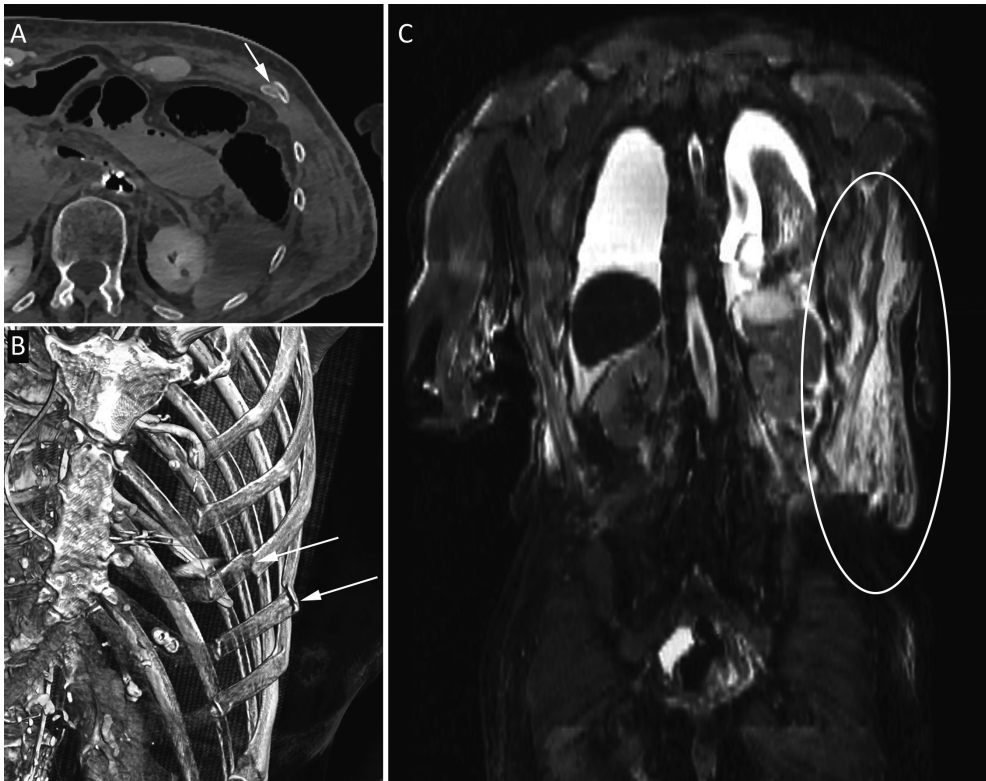


Figure 6: Rib fractures with soft-tissue hematoma. 89-year-old woman who underwent an elective coronary angiography for mitral valve insufficiency and complaints of angina. During the procedure she developed cardiac arrest and required cardiopulmonary resuscitation. She was transported to the intensive care, where she showed symptoms of hypovolemic shock and she died shortly afterwards. Postmortem CT showed multiple rib fractures (A and B: arrows) and on postmortem MRI a large soft-tissue hematoma was seen in the left flank (C: ellipse).

Table 3. Case table.

Case no.	Diagn. No.	Diagnosis	Organ	CT confidence	MRI confidence
1	1	Brain herniation	Brain	3	3
	2	Acute myocardial infarction	Heart	0	2
2	1	Chronic myocardial infarction	Heart	0	2
	2	Acute myocardial infarction	Heart	0	2
3	3	Pulmonary sequester	Lung	2	2
	1	Acute myocardial infarction	Heart	0	2
4	2	Aspiration	Lung	2	2
	1	Brain hemorrhage	Brain	3	3
5	2	Adrenal hemorrhage	Adrenal gland	2	2
	1	Lymphoma	Lung	3	3
6	2	Aspiration	Lung	1	1
	3	Cellular rejection heart transplant	Heart	0	0
7	1	Chronic myocardial infarction	Heart	0	0
	2	Acute myocardial infarction	Heart	0	0
8	3	Brain microbleeds	Brain	0	3
	4	Brain hemorrhage	Brain	2	2
9	5	Systemic infection	Brain	0	0
	1	Encephalitis	Brain	0	0
10	2	Systemic metastases	Lung	2	2
	3	Lung tumor	Lung	0	0
11	1	Gastrointestinal tract leakage	Intestines	2	2
	2	Pneumonia	Lung	2	2
12	1	Myocardial hypertrophy	Heart	2	2
	2	Pulmonary edema	Lung	1	1
13	3	Encephalitis	Brain	0	0
	1	Pulmonary embolism	Lung	1	3
14	1	Pneumonia	Lung	2	2
	2	Kidney abscess	Kidney	2	2
15	1	No major diagnosis found	-	-	-
	1	Chronic myocardial infarction	Heart	2	3
16	2	Pulmonary edema	Lung	2	2
	1	Pneumonia	Lung	2	2
17	2	Myocardial hypertrophy	Heart	2	2
	3	Pneumothorax with hemothorax	Lung	3	3
18	1	Acute myocardial infarction	Heart	0	2
	2	Pulmonary edema	Lung	2	2
19	1	Systemic metastases	Bone	2	2
	2	Acute myocardial infarction	Heart	0	2
20	3	Prostate cancer	Prostate	2	2
	1	Systemic metastases	Systemic	3	3
21	1	Brain hemorrhage	Brain	3	3
	2	Pneumothorax	Lung	3	3
22	3	Pneumonia	Lung	2	2

	4	Muscle dystrophy	Muscle	3	3
19	1	Rupture of abdominal aneurysm	Vascular	3	3
20	1	Acute myocardial infarction	Heart	0	2
21	1	Gastrointestinal tract bleeding	Intestines	2	2
22	1	Cardiomyopathy	Heart	2	2
	2	Pneumonia	Lung	2	2
	3	Acute myocardial infarction	Heart	0	2
23	1	Systemic iron overload	Systemic	0	3
	2	Gastrointestinal tract infection	Intestines	0	2
24	1	Acute myocardial infarction	Heart	0	2
25	1	Ischemia	Intestines	2	2
	2	Cardiomyopathy	Heart	2	2
26	1	Heart failure	Heart	2	2
	2	Focal liver steatosis	Liver	2	2
27	1	Aspergillus infection	Lung	2	2
	2	Graft-versus-host-disease	Systemic	0	0
28	1	Lung tumor	Lung	3	3
	2	Systemic metastases	Liver	2	2
	3	Aspiration	Lung	1	1
29	1	Acute myocardial infarction	Heart	0	2
30	1	Systemic metastases	Systemic	3	3
31	1	Pneumonia	Lung	2	2
	2	Lymphoma	Systemic	3	3
32	1	Aspiration	Lung	2	2
	2	Acute pancreatitis	Pancreas	2	2
33	1	Hemothorax	Lung	3	3
	2	Pneumothorax	Lung	3	3
	3	Rib fractures	Skeleton	3	2
	4	Pulmonary hypertension	Lung	2	2
	5	Spondylodiscitis	Skeleton	2	2
34	1	Liver cirrhosis	Liver	3	3
	2	Acute tubular necrosis	Kidney	0	0
35	1	Acute myocardial infarction	Heart	0	0
	2	Pancreatic carcinoma	Pancreas	2	2
36	1	Acute myocardial infarction	Heart	0	2
37	1	Pulmonary embolism	Lung	1	3
	2	Chronic myocardial infarction	Heart	0	1
38	1	Intestinal wall thickening (inflammation)	Intestines	1	1
39	1	Rupture of abdominal aneurysm	Vascular	3	3
	2	Breast cancer	Breast	2	2
40	1	Acute myeloid lymphoma	Systemic	0	2
	2	Leukostasis	Lung	2	2
	3	Systemic infection	Systemic	0	0
41	1	Pulmonary fibrosis	Lung	0	0
	2	Hemothorax	Lung	3	3

	3	Acute pneumonia	Lung	0	0
42	1	Hemothorax	Lung	3	3
43	1	Chronic myocardial infarction	Heart	0	2
44	1	Retroperitoneal hematoma	Soft tissue	3	3
	2	Thoracic wall hematoma	Soft tissue	3	3
45	1	Aspiration	Lung	2	2
46	1	Ileus	Intestines	2	2
	2	Intestinal ischemia	Intestines	2	2
	3	Acute tubular necrosis	Kidney	0	0

Clinical utility

A total of 84 clinical questions were asked in 46 minimally invasive autopsy procedures. Seventy-one (84.5%) of these questions could be answered with minimally invasive autopsy.

CT could answer 34/84 (40.5%) of clinical questions; in 23/84 (27.4%) without the need for biopsies, and in 11/84 (13.0%) a biopsy was required. MRI could answer 60/84 (71.4%) of clinical questions, in 27/84 (32.1%) without the need for biopsies, and in 33/84 (39.8%) a biopsy was required. MRI had significantly higher clinical utility than CT ($p<0.001$).

The combination of CT and MRI could answer 65/84 (77.4%) of clinical questions, in 30/84 (35.7%) without the need for biopsies, and in 35/84 (41.7%) a biopsy was required. Six additional questions of the 84 (7.1%) were answered based on histological findings that were not seen on imaging (i.e. biopsies taken with random sampling of organs). Table 4 shows the performance of CT and MRI for clinical questions in our cohort and gives an estimate of the hypothetical performance, based on expert opinion, of conventional autopsy for these questions.

Table 4. Clinical utility of postmortem CT and postmortem MRI for specific clinical questions.

Clinical question	n	CT performance	MRI performance	Biopsy required	Hypothetical performance of conventional autopsy
Brain hemorrhage	3	Good	Good	No	Good
Brain ischemia	4	Fair	Good	Yes	Good
Meningitis	1	Poor	Poor	Yes	Good
Myocardial infarction	13	Poor	Good	Yes	Good
Cardiomyopathies	2	Poor	Fair	Yes	Good
Coronary artery disease	1	Fair	Poor	No	Good
Cardiac arrhythmia	2	Poor	Poor	No	Fair
Pulmonary embolism	6	Poor	Fair	Yes	Good
Pneumonia	3	Fair	Fair	Yes	Good
Pulmonary hemorrhage / Hemothorax	3	Fair	Fair	No	Good
Rupture of abdominal aortic aneurysm	2	Good	Good	No	Good
Intestinal perforation	1	Fair	Fair	No	Good
Intestinal ischemia	2	Fair	Fair	Yes	Good
Liver cirrhosis	2	Fair	Good	Yes	Good
Implanted organ rejection / graft-versus-host disease	2	Poor	Poor	Yes	Good
Status of (oncological) disease	4	Good	Good	No	Fair
Position of implanted devices	3	Good	Good	No	Fair
Infection focus	4	Fair	Fair	Yes	Fair

Table 4 legend: CT and MRI performance were based on expert opinion of the postmortem radiologist (ACW). Hypothetical performance of conventional autopsy was based on expert opinion of the pathologist (JWO).

Costs

The mean cost of a minimally invasive autopsy was €1296 including brain biopsies and €1087 without brain biopsies. Mean cost of CT was €117 and of MRI €215. Mean cost of CT-guided biopsies was €685. The different components of minimally invasive autopsy and their respective cost are detailed in Table 5.

The mean cost of a full conventional autopsy was €991 including brain autopsy and €740 without brain autopsy. Costs of the different components of conventional autopsy are found in table 6.

Table 5. Costs of minimally invasive autopsy.

	Postmortem care & external inspection	MRI	CT	CT-guided biopsies	Brain biopsies
Personnel	Mortuary personnel	Students	Students	Students	Radiologist
	Pathology resident	Radiographer	Radiographer	Radiographer	Mortuary personnel
	Pathologist	Radiologist	Radiologist	Radiologist	
				Pathologist	
Mean cost (€)	15	109	67	240	115
Materials	MRI compatible body bag	Cleaning materials	Cleaning materials	Protective clothing	Cleaning materials
	Protective clothing	Protective clothing	Protective clothing	Cleaning materials	Protective clothing
	Other materials			Biopsy gun + needle	Drill
				Other materials	
Mean cost (€)	55	3	3	40	3
Equipment	-	Scanner depreciation	Scanner depreciation	Scanner depreciation	Brainlab navigation
		Power usage	Power usage	Power usage	Maintenance
		Maintenance	Maintenance	Maintenance	Neurosurgical skull clamp
Mean cost (€)		40	16	23	15
Other costs	-	Overhead	Overhead	Overhead	Overhead
		Reporting	Reporting	Reporting	Reporting
		PACS	PACS	PACS	Histology processing
				Histology processing	
Mean cost (€)		63	31	382	76
Total mean cost (€)	70	215	117	685	209

Table 5 legend: PACS = picture archiving and communication system.

Table 6. Costs of conventional autopsy

	Postmortem care	External inspection	Dissection	Microscopy	Brain autopsy	Reporting
Personnel	Mortuary personnel	Pathology resident	Mortuary personnel	Pathology resident	Laboratory assistant	Pathology resident
		Pathologist	Pathology resident	Pathologist	Mortuary personnel	Pathologist
		Mortuary personnel	Pathologist	Mortuary personnel		
Materials	Protective clothing	Protective clothing	Protective clothing	Protective clothing	Protective clothing	-
	Other materials		Cleaning materials	Other materials	Cleaning materials	
			Other materials		Other materials	
Equipment	-	-	Autopsy table	Autopsy table	Autopsy table	-
Other costs	Overhead	Overhead	Overhead	Overhead	Overhead	Overhead
				Histology processing	Histology processing	
Cost (€)	50	15	142	419	251	114

Discussion

This study on a minimally invasive autopsy, using MRI, CT and CT-guided biopsies, provides insight into the diagnostic yield, clinical utility and costs of commonly used postmortem imaging methods. The percentage of clinical questions answered with the complete minimally invasive autopsy method (MRI, CT and biopsies combined) was very high (84.5%), but CT and MRI as standalone modalities left many questions unanswered. Diagnostic yield of MRI was higher than CT: 85% of diagnoses were found with MRI versus 68% with CT. Most diagnoses required biopsies for confirmation; diagnostic yield of CT and MRI without biopsies was low. The mean cost of a full minimally invasive autopsy was €1296, and by far the most expensive part of the procedure were the CT-guided biopsies. For comparison, a full conventional autopsy (including brain autopsy) in our hospital had a mean cost of €991. In terms of time; a minimally invasive autopsy took approximately 4 to 5 hours, depending on the complexity of the case and the required biopsies. A conventional autopsy on average takes between 2.5 and 4 hours.

In a previously published study, we compared the performance for finding the immediate cause of death and related major diagnoses of minimally invasive autopsy - consisting of CT, MRI and CT-guided needle biopsies – versus a conventional autopsy. Minimally invasive autopsy and conventional autopsy performed equally well in finding the cause of death, whereas minimally invasive autopsy found a greater number of major diagnoses than conventional autopsy. Furthermore, both minimally invasive autopsy and conventional autopsy found unexpected postmortem findings that were considered relevant new information for the treating physicians: 124/288 (43.1%) of the major diagnoses and 17/99 (17%) of the causes of death were not clinically suspected before death. (21)

Earlier studies on the diagnostic performance of non-invasive and minimally invasive autopsies found that the performance of contrast enhanced imaging methods was better than that of non-contrast enhanced imaging. Furthermore, methods combining radiology with tissue-biopsies had a higher diagnostic performance than imaging alone. (11, 17)

In this study we evaluated the clinical utility of minimally invasive autopsy, defined as the percentage of successfully answered clinical questions by this new autopsy method. In our experience this outcome measure is highly valued by clinicians when they request an autopsy, and often this is considered equally as important as finding the cause of death. Our results show that the diagnostic yield and clinical utility of CT and MRI without biopsy is low. This finding is in line with diagnostic studies on imaging-based autopsies: methods combining imaging with biopsy showed highest sensitivity and specificity. (11, 21) Nevertheless CT and MRI both have strengths and weaknesses. CT is noninvasive, relatively cheap, and widely available. Additionally, CT performs well at visualizing (abnormal) air collections and skeletal abnormalities, such as fractures and bone lesions. A clinical study found that postmortem CT is more accurate in establishing the cause of death than the clinician. (22) However, our results indicate a low performance of CT as

standalone test, because unenhanced CT lacks the high soft-tissue contrast necessary to diagnose some common causes of death, such as acute myocardial infarction. (23) Studies on postmortem CTA show that it has a higher sensitivity, but CTA is logistically challenging to perform in a clinical setting and is not purely non-invasive. (24) MRI has excellent soft-tissue contrast, but it is more expensive and generally has longer scanning times and lower availability than unenhanced CT.

Because of its good soft-tissue discrimination, MRI was able to detect more major diagnoses in our study cohort. Cardiac diagnoses in particular were better diagnosed with MRI; acute myocardial infarctions were not seen at all with unenhanced CT-imaging, but MRI detected 10 out of 12 myocardial infarctions. Chronic myocardial infarction can sometimes be detected with CT in a late stage where wall thinning is present, in our cohort this was seen in 1 case. MRI also performed much better than CT in detecting chronic myocardial infarctions: chronic infarctions were detected with MRI in 4 out of 5 cases, and with CT in only 1 out of 5 cases. (25) Pneumonia, another common cause of death, was detected both with MRI and CT, but postmortem artefacts in the lungs such as internal livores can mask or mimic pathologic processes and therefore biopsies of lung abnormalities are always recommended. (26)

A closer look at the performance for answering clinical questions of CT and MRI (table 4) shows that CT and MRI can answer most questions, but biopsies are still necessary in the majority of questions. Intestinal ischemia and perforation, as well as organ transplant rejection and graft-versus-host disease are difficult to diagnose on imaging. Also, finding the etiology of cardiac arrhythmia's is almost impossible with CT and MRI. For these diagnoses it is recommended to perform a conventional autopsy when consent can be obtained. Minimally invasive autopsy outperforms the conventional autopsy in cases where a full-body assessment is required, e.g. the status or growth of systemic diseases or oncological processes. All clinical questions regarding skeletal lesions or pathology involving air can be answered with postmortem imaging (sometimes combined with biopsies) and in these cases we recommend either a minimally invasive autopsy, or otherwise combining a conventional autopsy with postmortem CT. Furthermore, the location of implanted devices is more reliably assessed on imaging, because the position can be seen in-situ, whereas with conventional autopsy artificial movement can occur during the opening of the body or removal of organs.

For our minimally invasive autopsy method we opted for a combination of CT, MRI and CT-guided biopsies, because it combines the soft-tissue contrast of MRI, to screen the brain and torso for soft-tissue abnormalities that can then be targeted with CT-guided biopsies. We designed multiple different MRI protocols for different clinical scenarios. This allowed us to scan with a higher resolution in the region of interest and use specific MRI-sequences when a particular question demanded it, without increasing MRI scanning time to more than 1 hour: e.g. when cerebral microhemorrhages were suspected a susceptibility-weighted MRI sequence would be made of the brain, and when a young

adult died suddenly and sudden-cardiac death was suspected a high-resolution cardio-thoracic MRI would be performed.

Other studies have suggested that using postmortem MRI as a screening tool prior to conventional autopsy in selected cases may lead to a cost reduction; in this case postmortem MRI is performed first and is only followed by conventional autopsy if the MRI does not give a definitive cause of death. (27) In a similar fashion we could perform a slimmed down version of the minimally invasive autopsy on a case-per-case basis depending on the clinical questions. For specific questions it may be possible to omit either CT or MRI and take only biopsies of organs or tissues of clinical importance. The risk of missing important diagnoses needs to be considered though; in our cohort 14/96 (14.6%) of diagnoses were not seen on imaging, and would have been missed if no random sampling of all organs was performed. The sampling success rate in our validation study was very high (>95%), because we sampled at least 4 needle biopsies per target location. Future research should focus on different imaging strategies for various clinical circumstances in which patients die. The cost that a hospital is willing to pay and the measure of invasiveness the next-of-kin are willing to accept are important factors when deciding how to design a postmortem imaging service. These considerations can be different depending on the setting. For example, an intensive care doctor might be more interested in knowing the cause of death and may be less interested in diagnoses already known or unrelated to death. In contrast, a clinical oncologist is more eager to know the exact tumor type in patients who were unresponsive to treatment, warranting a more invasive technique.

Our study has several limitations. Our study includes a minimally invasive autopsy that combines CT, MRI and biopsies. Alternative procedures, such as postmortem CTA, MRA, and ultrasound were not part of our imaging protocol. The addition of CTA could greatly increase the clinical performance of minimally invasive autopsy for coronary heart disease. Our cohort was relatively small, therefore we made no attempt to aggregate diagnoses per organ system. The costs of minimally invasive autopsy were calculated based on direct material, personnel and overhead cost. We did not take into account that the overall cost per individual procedure tends to increase when fewer procedures in total are performed, as overhead costs and wages for personnel are shared between the total amount of procedures. (20) Finally, the population that we scanned is dependent on country and setting; we investigated the performance and costs in an academic hospital in the Netherlands. More studies are necessary to evaluate performance and costs in different settings and countries.

Conclusion

A minimally invasive autopsy, consisting of CT, MRI and CT-guided biopsies, performs well in answering clinical questions and detecting major diagnoses. However, the diagnostic yield and clinical utility were quite low for postmortem CT and MRI as standalone modalities.

References

1. Turnbull A, Osborn M, Nicholas N. Hospital autopsy: Endangered or extinct? *J Clin Pathol*. 2015;68(8):601-4.
2. Reichert CM, Kelly VL. Prognosis for the autopsy. *Health Aff (Millwood)*. 1985;4(2):82-92.
3. Roberts WC. The autopsy: its decline and a suggestion for its revival. *N Engl J Med*. 1978;299(7):332-8.
4. Benbow EW, Roberts IS. The autopsy: complete or not complete? *Histopathology*. 2003;42(5):417-23.
5. Cohen MC, Whitby E, Fink MA, Collett JM, Offiah AC. Running a postmortem service--a business case and clinical experience. *Pediatr Radiol*. 2015;45(4):501-8.
6. Wichmann D, Heinemann A, Weinberg C, Vogel H, Hoepker WW, Grabherr S, et al. Virtual autopsy with multiphase postmortem computed tomographic angiography versus traditional medical autopsy to investigate unexpected deaths of hospitalized patients: a cohort study. *Ann Intern Med*. 2014;160(8):534-41.
7. Grabherr S, Grimm J, Dominguez A, Vanhaebost J, Mangin P. Advances in post-mortem CT-angiography. *Br J Radiol*. 2014;87(1036):20130488.
8. Roberts IS, Traill ZC. Minimally invasive autopsy employing post-mortem CT and targeted coronary angiography: evaluation of its application to a routine Coronal service. *Histopathology*. 2014;64(2):211-7.
9. Jalalzadeh H, Giannakopoulos GF, Berger FH, Fronczek J, van de Goot FR, Reijnders UJ, et al. Post-mortem imaging compared with autopsy in trauma victims - A systematic review. *Forensic Sci Int*. 2015;257:29-48.
10. Thali MJ, Jackowski C, Oesterhelweg L, Ross SG, Dirnhofer R. VIRTopsy - the Swiss virtual autopsy approach. *Leg Med (Tokyo)*. 2007;9(2):100-4.
11. Blokker BM, Wagenveld IM, Weustink AC, Oosterhuis JW, Hunink MG. Non-invasive or minimally invasive autopsy compared to conventional autopsy of suspected natural deaths in adults: a systematic review. *Eur Radiol*. 2016;26(4):1159-79.
12. Puranik R, Gray B, Lackey H, Yeates L, Parker G, Duflou J, et al. Comparison of conventional autopsy and magnetic resonance imaging in determining the cause of sudden death in the young. *J Cardiovasc Magn Reson*. 2014;16:44.
13. Flach PM, Thali MJ, Germerott T. Times have changed! Forensic radiology--a new challenge for radiology and forensic pathology. *AJR Am J Roentgenol*. 2014;202(4):W325-34.
14. Wichmann D, Obbelode F, Vogel H, Hoepker WW, Nierhaus A, Braune S, et al. Virtual autopsy as an alternative to traditional medical autopsy in the intensive care unit: a prospective cohort study. *Ann Intern Med*. 2012;156(2):123-30.
15. Westphal SE, Aпитзsch J, Penzkofer T, Mahnken AH, Knuchel R. Virtual CT autopsy in clinical pathology: feasibility in clinical autopsies. *Virchows Arch*. 2012;461(2):211-9.
16. Takahashi N, Higuchi T, Shiotani M, Hirose Y, Shibuya H, Yamanouchi H, et al. The effectiveness of postmortem multidetector computed tomography in the detection of

- fatal findings related to cause of non-traumatic death in the emergency department. *Eur Radiol.* 2012;22(1):152-60.
17. Weustink AC, Hunink MG, van Dijke CF, Renken NS, Krestin GP, Oosterhuis JW. Minimally invasive autopsy: an alternative to conventional autopsy? *Radiology.* 2009;250(3):897-904.
18. Roberts IS, Benbow EW, Bisset R, Jenkins JP, Lee SH, Reid H, et al. Accuracy of magnetic resonance imaging in determining cause of sudden death in adults: comparison with conventional autopsy. *Histopathology.* 2003;42(5):424-30.
19. Ros PR, Li KC, Vo P, Baer H, Staab EV. Preautopsy magnetic resonance imaging: initial experience. *Magn Reson Imaging.* 1990;8(3):303-8.
20. Rutty GN, Morgan B, Robinson C, Raj V, Pakkal M, Amoroso J, et al. Diagnostic accuracy of post-mortem CT with targeted coronary angiography versus autopsy for coroner-requested post-mortem investigations: a prospective, masked, comparison study. *The Lancet.* 2017;390(10090):145-54.
21. Blokker BM, Weustink AC, Wagensveld IM, von der Thüsen JH, Pezzato A, Dammers R, et al. Conventional Autopsy versus Minimally Invasive Autopsy with Postmortem MRI, CT, and CT-guided Biopsy: Comparison of Diagnostic Performance. *Radiology.* 2018;289(3):658-67.
22. Inai K, Noriki S, Kinoshita K, Sakai T, Kimura H, Nishijima A, et al. Postmortem CT is more accurate than clinical diagnosis for identifying the immediate cause of death in hospitalized patients: a prospective autopsy-based study. *Virchows Arch.* 2016;469(1):101-9.
23. Wagensveld IM, Blokker BM, Pezzato A, et al. Diagnostic accuracy of postmortem computed tomography, magnetic resonance imaging, and computed tomography-guided biopsies for the detection of ischaemic heart disease in a hospital setting. *Eur Heart J Cardiovasc Imaging.* 2018;19(7):739-48.
24. Ross SG, Thali MJ, Bolliger S, Germerott T, Ruder TD, Flach PM. Sudden death after chest pain: feasibility of virtual autopsy with postmortem CT angiography and biopsy. *Radiology.* 2012;264(1):250-9.
25. Wagensveld IM, Blokker BM, Pezzato A, Wielopolski PA, Renken NS, von der Thüsen JH, et al. Diagnostic accuracy of postmortem computed tomography, magnetic resonance imaging, and computed tomography-guided biopsies for the detection of ischaemic heart disease in a hospital setting. *European Heart Journal - Cardiovascular Imaging.* 2018;19(7):739-48.
26. Wagensveld IM, Blokker BM, Wielopolski PA, Renken NS, Krestin GP, Hunink MG, et al. Total-body CT and MR features of postmortem change in in-hospital deaths. *PLOS ONE.* 2017;12(9):e0185115.
27. Ahmad MU, Sharif KA, Qayyum H, Ehsanullah B, Balyasnikova S, Wale A, et al. Assessing the use of magnetic resonance imaging virtopsy as an alternative to autopsy: a systematic review and meta-analysis. *Postgraduate Medical Journal.* 2017;93(1105):671-8.

7

CHAPTER 7

Effect of minimally invasive autopsy and ethnic background on consent rate for postmortem investigation in adult deceased patients: a prospective single center before-after study

Ivo M Wagenveld, Annick C Weustink, Jan A Kors, Britt M Blokker, MG Myriam Hunink, J Wolter Oosterhuis

Objectives

Autopsy rates worldwide have dropped significantly over the last five decades. Imaging based autopsies are increasingly used as alternatives to conventional autopsy (CA). The aim of this study was to investigate the effect of the introduction of minimally invasive autopsy, consisting of CT, MRI and tissue biopsies on the total consent rate for postmortem diagnostics.

Methods

We performed a prospective single center before-after study. The intervention was the introduction of minimally invasive autopsy as an alternative to conventional autopsy. Minimally invasive autopsy consisted of MRI, CT, and CT-guided tissue biopsies. Consent rates over time and the effect of introducing minimally invasive autopsy were analyzed with a linear regression model. We performed a subgroup analysis comparing the consent rates of two groups: a group of western-European ethnicity versus a group of other ethnicities.

Results

Autopsy rates declined from 14.0% in 2010 to 8.3% in 2019. The linear regression model showed a significant effect of both time and availability of minimally invasive autopsy on the consent rate. The predicted acceptance rate in the model started at 15.1% in 2010 and dropped approximately 0.1% per month ($\beta = -0.001$, $p < 0.001$). Availability of minimally invasive autopsy increased the acceptance rate by 2.4% ($\beta = 0.024$, $p < 0.001$). The overall post-mortem consent rate of people with an ethnic background other than western-European was significantly higher in years when minimally invasive autopsy was available compared to when it was not available (22/176=12.5% vs. 81/1014 (8.0%), $p=0.049$).

Conclusion

The introduction of minimally invasive autopsy had a small, but significant effect on the overall consent rates for postmortem investigations. Furthermore, the minimally invasive autopsy appears to be more acceptable than conventional autopsy among people with an ethnicity other than western-European.

Introduction

Clinical autopsy acceptance rates have dropped considerably over the previous decades. (1-6) Improvements in imaging techniques in living patients may have led to the belief that autopsies hardly add to the information acquired prior to death. (7) However, despite improved diagnostic studies, autopsies still provide valuable feedback on diagnoses and treatment, and accurate statistics on causes of death. (8) Moreover, they are useful for healthcare policymaking, education and research purposes. (3, 9-11)

The low consent rate of next-of-kin for the autopsy is one of the reasons for the decline in clinical autopsy rates. Therefore, strategies to improve the consent rates are under investigation: improved availability of modern imaging techniques has led to the development of imaging-based autopsy techniques. Such methods can be non-invasive or minimally invasive (12); in our hospital we introduced and validated a minimally invasive autopsy, consisting of postmortem CT, MRI and CT-guided biopsies. (8)

The aim of our study was to determine the acceptance rates of postmortem investigations (both minimally invasive and conventional autopsy combined) on adult deceased patients in our hospital over the years 2010-2019 and to investigate if the introduction of the minimally invasive autopsy led to an increase in acceptance of postmortem investigations. A subgroup analysis was performed comparing a group of western-European ethnicity with a group of other ethnicities. Furthermore, we used a questionnaire to investigate the considerations and motivations of doctors and next-of-kin in the consent process for postmortem investigations.

Materials and Methods

Setting and design

This study was performed at the Erasmus University Medical Center in Rotterdam, the largest academic hospital in the Netherlands. The design was a prospective before-after study whereby additional data was collected retrospectively. The intervention was the introduction of minimally invasive autopsy as an alternative to conventional autopsy. The study was approved by the Erasmus University Medical Center Medical Ethical Committee (file number MEC-2011-055). The institutional review board approved the study prior to data collection. All adult patients who had died in-hospital were included.

Autopsy procedures

Conventional autopsy and minimally invasive autopsy were both available from Monday to Friday. Only 1 minimally invasive autopsy per day was possible, due to limited scanner availability. When multiple minimally invasive autopsy procedures were requested on the same day, requests would be processed in the order they were received: if next-of-kin agreed, a procedure would be postponed until the next available day.

Minimally invasive autopsy procedure

A minimally invasive autopsy consisted of MRI of the head and torso, full-body CT scan and CT-guided biopsies of organs (heart, lungs, liver, kidneys and spleen) and additional biopsies of abnormal / pathological lesions detected on imaging. The CT and MRI protocols are described in previous articles. (8, 13-15)

Conventional autopsy procedure

The conventional autopsy was performed according to standard department protocol: the body was opened with a Y-incision and the thoracic cavity opened with a rib-cutter. Organs were eviscerated by the mortuary assistant and dissected by a resident in pathology, supervised by a certified pathologist. (8)

Acceptance

The primary outcome measure was the effect of minimally invasive autopsy on the consent rate for postmortem diagnostics.

Consent for both autopsy procedures was requested by the treating physicians. Before the actual introduction of the minimally invasive autopsy, all clinical wards were educated about the new autopsy method.

Questionnaires

As a secondary outcome we investigated the motivations of next-of-kin for consenting to or refusing an autopsy, and the motivations of doctors to not ask for permission. We

distributed the questionnaires to the doctors who were involved in the consent process, since they would be informed about the motivations of next-of-kin when discussing the possibility of autopsy after a patient had passed away. Questionnaires were distributed from September 2016 - December 2017.

Data analysis

Because we expected that the autopsy rates were declining during the study period we performed a linear regression analysis to calculate the effect of time and availability of minimally invasive autopsy on consent rate. The independent variables were time in months since the start of the study and the availability of minimally invasive autopsy as a standalone postmortem investigation.

We performed a subgroup analysis among people of western-European ethnicity versus people of other ethnical backgrounds. We calculated the acceptance rates of both groups and performed an independent T-test in order to test for significance.

To determine the ethnicity, we used a two-stage classification process. In the first stage, the predicted probabilities of a supervised machine-learning algorithm were used to distinguish between classifications with high and low certainty. For this stage, we used a random forest classifier (method ranger in the R package caret). To train and test the classifier, we used data from a questionnaire in which the next-of-kin were asked to provide the ethnic background of the deceased. (7, 8) The total set consisted of 2,083 cases, which were split in a training set (80%) and a test set (20%). As features we used character n-grams (with $n = 2, 3$, and 4) of the last names and, if available, of the first names. Each case was labelled as having either a western-European or other ethnic background. Henceforth we will refer to this latter group as 'other' ethnicities. The training set was used to develop the classifier; the test set was only used for performance evaluation. Performance measures were the area under the receiver operating characteristic curve (AUROC), negative predictive value (proportion of correctly predicted Western-European cases), and positive predictive value (proportion of correctly predicted cases of 'other' ethnicity). (16-18) In the second stage, the classifications with low certainty were manually validated, in cases of doubt the Dutch surname database was consulted (<https://www.cbgfamilienamen.nl/nfb/>). For the manual classification, the group allocation (intervention vs. non-intervention) was unknown to the observer (IMW).

Results

Consent rates

Autopsy rates declined from 14.0% in 2010 to 8.3% in 2019. The annual autopsy rates of the years 2010-2019 are shown in Figure 1.

In the 'intervention' period (when minimally invasive autopsy was available) from October 2016 through December 2017, 1056 adult patients died and permission for postmortem diagnostics was given in 133 cases (12.6%): 87 underwent conventional autopsy (8.2%) and 46 minimally invasive autopsy (4.4%).

The linear regression model showed a significant effect on the consent rate of both time and availability of minimally invasive autopsy. The predicted acceptance rate in the model started at 15.1% in September 2010 and dropped approximately 0.1% per month ($\beta = -0.001$, $p < 0.001$) and minimally invasive autopsy availability increased the acceptance rate by 2.4% ($\beta = 0.024$, $p < 0.001$).

Prediction of ethnicity

We used 5-fold cross-validation to train the random forest classifier on the training set. On the test set, this classifier obtained an area under the receiver operating characteristic curve of 0.91, showing good performance. We empirically set probability thresholds to distinguish between high and low confidence classifications. Names with a predicted probability lower than 0.50 were labeled as 'other' ethnicity (this threshold yielded a positive predictive value of 1 on the test set), and names with a predicted probability greater than 0.82 were labeled as Western-European (yielding a negative predictive value of 0.95 on the test set). Cases with a probability between 0.50 and 0.82 were manually validated, using the Dutch surnames database. Of the cases from 2010-2019 which were not part of the learning dataset ($n=4764$), 1548 cases had a probability between 0.5 and 0.82; 733 (47.4%) of these were manually scored as western-European. In the total cohort, 82.8% (5736/6928) were classified as western-European.

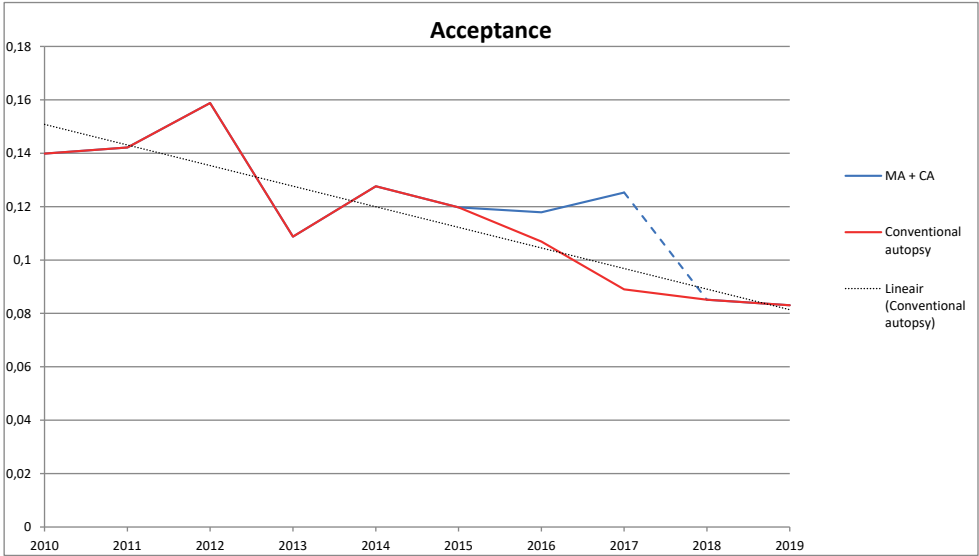


Figure 1: Postmortem consent rates 2010-2019. Combined consent rate are the combined consent rates of minimally invasive autopsy and conventional autopsy

Effect of ethnic background on consent rate

The consent rates of western-Europeans and 'other' ethnicities in the different cohorts is detailed in table 1. In the years when minimally invasive autopsy was not available, western-Europeans had a significantly higher consent rate for conventional autopsy than 'other' ethnicities (629/4858=12.9% vs. 82/1014=8.0%, $p<0.001$). When minimally invasive autopsy was available the total consent rate for postmortem investigations was nearly the same for western-Europeans and 'other' ethnicities (111/880=12.6% vs. 22/176=12.5%, $p=0.97$). The post-mortem consent rate among 'other' ethnicities was significantly higher in the years when minimally invasive autopsy was available compared to the years when it was not available (22/176=12.5% vs. 81/1014=8.0%, $p=0.049$).

Questionnaires

Questionnaires were distributed from September 2016 to December 2017. 505 out of 1123 (45.9%) questionnaires were returned. In the group that refused conventional autopsy or minimally invasive autopsy 413/988 (41.8%) questionnaires were returned, and in the group that gave permission 92/135 (68.1%) questionnaires were returned. In the group that gave permission for minimally invasive autopsy 40/46 (87.0%) of questionnaires were returned and in the group that gave permission for conventional autopsy 55/92 (59.8%) questionnaires were returned.

In 436/505 (86.3%) cases the doctors involved in the consent process declared that they had requested permission for autopsy. Doctors' reasons not to ask for permission are listed in table 2, the most frequently heard reason was "the cause of death is already known" 32/69 (46.4%).

The reasons for consenting to an autopsy procedure mostly overlapped for both conventional autopsy and minimally invasive autopsy. One exception was that people consenting to minimally invasive autopsy did so more often "to contribute to research and/or contribute to medical knowledge" than those consenting to conventional autopsy (5/46=10.9% vs. 2/99=2.0%, $p=0.02$).

Table 1. Consent rates of western-European vs ‘other’ ethnicities.

Time period	Available procedures	n	western-European	‘other’ ethnicities	Overall consent rate	Western-European vs ‘other’ ethnicities
Pre-intervention (Jan. 2010 - Sept. 2016)	CA only	4679	CA consent rate 538/3875 (13.9%)	71/804 (8.8%)	609/4679 (13.0%)	p>0.001
Post-intervention (Jan. 2018- Mar. 2019)	CA only	1193	CA consent rate 90/982 (9.2%)	11/211 (5.2%)	101/1193 (8.5%)	p=0.061
Total non-intervention (2010-2019, excluding intervention period)	CA only	5872	CA consent rate 629/4858 (12.9%)	81/1014 (8.0%)	710/5872 (12.1%)	p>0.001
Intervention (Oct. 2016 - Dec. 2017)	MIA + CA	1056	MIA consent rate 37/880 (4.2%)	9/176 (5.1%)	46/1056 (4.4%)	p=0.59
	MIA + CA	1056	CA consent rate 74/880 (8.4%)	13/176 (7.4%)	87/1056 (8.2%)	p=0.45
	MIA + CA	1056	Total consent rate 111/880 (12.6%)	22/176 (12.5%)	133/1056 (12.6%)	p=0.97
			(MIA + CA)			
Comparison of total consent rate: intervention vs. non intervention			p=0.79	p=0.049	p=0.65	

Table 2. Reasons why doctors did not ask for permission

Motivation	Frequency
The cause of death is already known	32/69 (46.4%)
The next-of-kin had already consented to an organ donation procedure	9/69 (13%)
Perceived uncomfortable situation	7/69 (10%)
No family present to ask permission	6/69 (9%)
Doctor thought an autopsy would be too much to ask	6/69 (9%)

Reasons of next-of-kin for giving or denying consent for postmortem diagnostics are listed in table 3 and 4.

Table 3. Reasons of next-of-kin for giving consent

Motivation	Frequency
To find out the cause of death	65/92 (70.7%)
Wanting to know the severity of disease	17/92 (18.5%)
Cater to treating doctor’s request	16/92 (17.4%)
Testing for hereditary disorders	13/92 (14.1%)
Testing for presence of diseases, not related to the cause of death	10/92 (10.7%)
Contribute to scientific research and/or medical knowledge	7/92 (7.6%)
Other reasons	4/92 (4.3%)

Table 4. Reasons of next-of-kin for denying consent*

Motivation	Frequency
The cause of death is already known	166/339 (49.0%)
Long illness, “the deceased has suffered enough”	77/339 (22.7%)
Religious motivation	35/339 (10.3%)
Autopsy is considered too invasive, scary or macabre	35/339 (10.3%)
Autopsy would take too long	8/339 (2.4%)
Already consented to donation procedure	7/339 (2.1%)
No reason given	24/339 (7.1%)

* this category also contains answers from next-of-kin who gave consent for one of the autopsy methods, but nevertheless gave objections against postmortem diagnostics.

Discussion

In this study we investigated if the introduction of a minimally invasive autopsy, consisting of CT, MRI and tissue biopsies, would increase the total consent rate for postmortem diagnostics. We found that the introduction of minimally invasive autopsy had a small, but significant effect on the combined consent rates (conventional autopsy and minimally invasive autopsy) for postmortem investigations. This is important information in light of the decline in autopsy consent rates, which is observed all over the world since approximately 1950. In our hospital we saw a further decrease in consent rates of approximately 0.1% per month since the start of our study. (19)

The measured effect (2.4%) that minimally invasive autopsy had on consent rates was smaller than we had expected. The reason for this is unclear: perhaps the invasiveness of the procedure isn't as important a motivation to deny consent for the next-of-kin. Alternatively, minimally invasive autopsy, using biopsies, might still be considered too invasive; or maybe any additional procedures performed on the deceased's body are considered macabre or scary. Another reason might be that low autopsy rates are attributable to a low request rate (20). In our hospital request rates are reported to be very high, but these rates are self-reported by doctors and the real request rate might be lower than what is reported.

An important reason we introduced the minimally invasive autopsy in our hospital is that the population of Rotterdam, where this study was carried out, consists for a large part of non-western immigrants (around 38% in 2018). Although most religions do not outrightly prohibit autopsy, in many religious groups some inhibitions against postmortem investigations are present. (21-23) In the years when minimally invasive autopsy was not available as a stand-alone postmortem investigation we observed that the consent rate in people of ethnicities other than western-European was significantly lower than in people with a western-European ethnicity. When minimally invasive autopsy was available, the combined consent rates of minimally invasive autopsy and conventional autopsy were the same for non- western-Europeans and 'other' ethnicities (12.6% and 12.5% respectively), and the consent rate among 'other' ethnicities was significantly higher than in the years without minimally invasive autopsy (12.5% vs 8.0%, $p=0.049$). This strongly suggests that minimally invasive autopsy is indeed more acceptable to people with an ethnicity other than western-European.

The main motivation for next-of-kin to withhold consent for autopsy was the assumption that the cause of death was already known, and no important questions remained to be answered. This is in line with our earlier questionnaire study. (7) It should be noted here that autopsy results differ from the presumed cause of death before autopsy in a substantial percentage of cases. Interestingly the invasiveness of the procedure was not often mentioned as motivation against postmortem diagnostics. This might suggest that the invasiveness is not a big factor in the declining autopsy rates, contrary to what is often

believed. This could be part of the reason why the postmortem consent rate of western-Europeans was not higher when minimally invasive autopsy was available.

In a study by Cox et al. the authors achieved a substantial increase in autopsy rates (from 5% to 38%). They attributed this increase in autopsy rates mainly to the study setting, which resulted in improved logistics of the consent process and a big increase in the request rate of doctors. Both factors did not play a big role in our study. We did not make major changes to the logistics of the consent process and the logistics of conventional autopsy stayed the same. The autopsy request rate in our hospital was already reported to be high before the introduction of minimally invasive autopsy. Furthermore, in some cases of the study by Cox et al. a member of the research team asked for consent. (24) It has also been suggested that pathologists should personally ask next-of-kin for permission, because they are most informed about the different procedures and can most adequately answer any questions the next-of-kin might have. (25) In our study, however, the treating physician always requested consent. We educated the doctors about the method, prior to introducing the minimally invasive autopsy hospital wide. For further questions during the study period, a researcher would be available by phone at any time. Apart from that, there was limited direct involvement of the research team in the day-to-day consent process. We think that success like that of Cox et al. and a similar increase in consent rates requires a dedicated team in each hospital with in-depth knowledge of all available postmortem diagnostic methods and all involved logistics. Members of this team could assist doctors in the consent process, or even request consent from next-of-kin in person, preferably with the treating physician present.

In studies performed in Sweden attitudes towards autopsy, organ donation and dissection (donation of the body for scientific purposes) were evaluated. Interestingly the authors found that at the time of the interview Swedes were much more positive about autopsy than they were about organ donation. (26, 27) This is in stark contrast with the current situation in the Netherlands and other western countries, where the autopsy rates are often below 10%, while registered organ donation is much more common (42% in 2018 in the Netherlands). (28) In new legislation, which will be implemented in 2020, all adults in the Netherlands are registered as an organ donor unless consent is specifically denied. Another factor that can influence autopsy rates is the quality of the autopsy perceived by the doctors who request autopsy. It is necessary to facilitate close collaboration between clinicians and the autopsy team. This includes ensuring good communication beforehand about what can be expected of the autopsy and clear and timely information about the autopsy results afterwards. Furthermore, there must be clarity about the financial aspects of autopsies: clinicians should not have to fear that a high autopsy rate will lead to a high fee for their department. In general, an increase in autopsy rates will only be achieved if there is a positive attitude towards the autopsy in clinicians, pathologists and other involved parties. (29-31)

Limitations

A limitation of our study was a relatively low response rate to the questionnaires. In our experience making the questionnaires obligatory for doctors to fill in after death makes the quality of the responses worse. By making it optional the doctors and families with a more positive attitude towards autopsy are more inclined to respond to the questionnaire which may lead to a bias in the answers. Another limitation was that we asked the treating physician about the motivation of the next-of-kin, because we considered it unethical to ask the bereaved family directly after their loss. This way the motivation of the next-of-kin was investigated indirectly, through the treating clinician.

In this study all ethnicities which were not classified as western European are classified in the category “other” ethnicities. The distinction between western-European ethnicity and all ‘other’ ethnicities is very broad and possibly semantically confusing. The western-European group does not include people from southern-, northern- and eastern-Europe and the USA, which are also considered as “western” in the common use of the word. Unfortunately, the group of other ethnicities was relatively small (less than 20% of the total cohort), therefore further subdividing that group resulted in low receiver operating characteristic curves for the supervised machine-learning algorithm. The Dutch surname database, used for the manual validation, contains the frequency of occurrence of surnames in 1947 and 2007. Most cases with an ‘other’ ethnicity were migrant workers who moved to the Netherlands after the second world war. This corresponds with the data from the Personal Records Database from the municipality of Rotterdam: over 50% of the population has a migration background, and within this group roughly 75% has a non-western background.

Information about the minimally invasive autopsy was distributed at the start of the cohort. Doctors in our hospital were already familiar with the procedure, because it had already been validated in the years prior to this cohort. Nevertheless, in a hospital environment with constant changes in personnel, the familiarity with minimally invasive autopsy and the ins-and-outs of this new procedure were suboptimal. We feel that, for a reliable measurement of the effect of minimally invasive autopsy on the total autopsy rates, a longer period of inclusion is necessary, so that doctors and the public become more familiar with the procedure. In this light, the results from our current cohort should be seen as a baseline measurement for our hospital and comparable hospitals.

Conclusion

In this study we investigated if the introduction of a minimally invasive autopsy consisting of CT, MRI and biopsies would lead to an increase in total combined consent rates for post-mortem investigations (conventional autopsy and minimally invasive autopsy). We found that the introduction of minimally invasive autopsy had a small, but significant


effect on the combined consent rates for postmortem investigations. Furthermore, the minimally invasive autopsy appears to be more acceptable than conventional autopsy among people with an ethnicity other than western-European.

References

1. Shojania KG, Burton EC. The Vanishing Nonforensic Autopsy. *New England Journal of Medicine*. 2008;358(9):873-5.
2. Turnbull A, Osborn M, Nicholas N. Hospital autopsy: Endangered or extinct? *J Clin Pathol*. 2015;68(8):601-4.
3. Burton JL, Underwood J. Clinical, educational, and epidemiological value of autopsy. *Lancet*. 2007;369(9571):1471-80.
4. Blokker BM, Weustink AC, Hunink MGM, Oosterhuis JW. Autopsy rates in the Netherlands: 35 years of decline. *PLOS ONE*. 2017;12(6):e0178200.
5. Roberts WC. The autopsy: its decline and a suggestion for its revival. *N Engl J Med*. 1978;299(7):332-8.
6. Ayoub T, Chow J. The conventional autopsy in modern medicine. *J R Soc Med*. 2008;101(4):177-81.
7. Blokker BM, Weustink AC, Hunink MGM, Oosterhuis JW. Autopsy of Adult Patients Deceased in an Academic Hospital: Considerations of Doctors and Next-of-Kin in the Consent Process. *PLOS ONE*. 2016;11(10):e0163811.
8. Blokker BM, Weustink AC, Wagensveld IM, von der Thüsen JH, Pezzato A, Dammers R, et al. Conventional Autopsy versus Minimally Invasive Autopsy with Postmortem MRI, CT, and CT-guided Biopsy: Comparison of Diagnostic Performance. *Radiology*. 2018;289(3):658-67.
9. Shojania KG, Burton EC, McDonald KM, Goldman L. Changes in rates of autopsy-detected diagnostic errors over time: a systematic review. *JAMA*. 2003;289(21):2849-56.
10. Reichert CM, Kelly VL. Prognosis for the autopsy. *Health Aff (Millwood)*. 1985;4(2):82-92.
11. Turnbull A, Martin J, Osborn M. The death of autopsy? *Lancet*. 2015;386(10009):2141.
12. Blokker BM, Wagensveld IM, Weustink AC, Oosterhuis JW, Hunink MG. Non-invasive or minimally invasive autopsy compared to conventional autopsy of suspected natural deaths in adults: a systematic review. *Eur Radiol*. 2016;26(4):1159-79.
13. Wagensveld IM, Blokker BM, Wielopolski PA, Renken NS, Krestin GP, Hunink MG, et al. Total-body CT and MR features of postmortem change in in-hospital deaths. *PLOS ONE*. 2017;12(9):e0185115.
14. Wagensveld IM, Blokker BM, Pezzato A, Wielopolski PA, Renken NS, von der Thüsen JH, et al. Diagnostic accuracy of postmortem computed tomography, magnetic resonance imaging, and computed tomography-guided biopsies for the detection of ischaemic heart disease in a hospital setting. *European Heart Journal - Cardiovascular Imaging*. 2018;19(7):739-48.
15. Wagensveld IM, Hunink MGM, Wielopolski PA, van Kemenade FJ, Krestin GP, Blokker BM, et al. Hospital implementation of minimally invasive autopsy: A prospective cohort study of clinical performance and costs. *PLOS ONE*. 2019;14(7):e0219291.
16. Mateos P. A review of name-based ethnicity classification methods and their potential in population studies. *Population, Space and Place*. 2007;13(4):243-63.

17. Ambekar A, Ward C, Mohammed J, Male S, Skiena S. Name-ethnicity classification from open sources. Proceedings of the 15th ACM SIGKDD international conference on Knowledge discovery and data mining; Paris, France. 1557032: ACM; 2009. p. 49-58.
18. Treeratpituk P, Giles CL. Name-ethnicity classification and ethnicity-sensitive name matching. Proceedings of the Twenty-Sixth AAAI Conference on Artificial Intelligence; Toronto, Ontario, Canada. 2900890: AAAI Press; 2012. p. 1141-7.
19. Crowley PF, McKelvie PA. The decline in hospital autopsy rates. *Med J Aust.* 1996;164(3):188-9.
20. Sherwood SJ, Start RD. Asking relatives for permission for a post mortem examination. *Postgraduate medical journal.* 1995;71(835):269-72.
21. Gatrad AR. Muslim customs surrounding death, bereavement, postmortem examinations, and organ transplants. *BMJ.* 1994;309(6953):521.
22. Lewis C, Latif Z, Hill M, Riddington M, Lakhanpaul M, Arthurs OJ, et al. "We might get a lot more families who will agree": Muslim and Jewish perspectives on less invasive perinatal and paediatric autopsy. *PLOS ONE.* 2018;13(8):e0202023.
23. Lewis C, Hill M, Arthurs OJ, Hutchinson JC, Chitty LS, Sebire N. Health professionals' and coroners' views on less invasive perinatal and paediatric autopsy: a qualitative study. *Archives of Disease in Childhood.* 2018;103(6):572.
24. Cox JA, Lukande RL, Kateregga A, Mayanja-Kizza H, Manabe YC, Colebunders R. Autopsy acceptance rate and reasons for decline in Mulago Hospital, Kampala, Uganda. *Trop Med Int Health.* 2011;16(8):1015-8.
25. McDermott MB. Obtaining consent for autopsy. *BMJ (Clinical research ed).* 2003;327(7418):804-6.
26. Mjornheim B, Rosendahl A, Eriksson LC, Takman C. Attitudes of Nurses and Physicians About Clinical Autopsy in Neonatal and Adult Hospital Care: A Survey in Sweden. *Nurs Res.* 2015;64(4):264-71.
27. Sanner M. A Comparison of Public Attitudes Toward Autopsy, Organ Donation, and Anatomic Dissection: A Swedish Survey. *JAMA.* 1994;271(4):284-8.
28. <https://www.cbs.nl/en-gb/news/2018/32/donor-register-includes-6-3-million-persons>.
29. Haque AK, Patterson RC, Grafe MR. High autopsy rates at a university medical center. What has gone right? *Arch Pathol Lab Med.* 1996;120(8):727-32.
30. Haque AK. The autopsy and the public need. *Arch Pathol Lab Med.* 1995;119(12):1092-4.
31. Langer R, Tröhler A, Schnüriger B, Trippel M, Blank A, Banz Y, et al. Implementation of modern tools in autopsy practice—the way towards contemporary postmortal diagnostics 2018.

CHAPTER 8



General discussion



Summary and general discussion

In this thesis we present our findings and share our experience with the implementation of minimally invasive autopsy in our hospital. The form of minimally invasive autopsy which we conducted consisted of total-body CT, MRI of the head and torso, and CT-guided biopsies of the main organs and of any additional pathological lesions.

The rationale behind our study is to find a solution for the decrease in autopsy rates that is seen worldwide. Since the second half of the twentieth century clinical autopsy rates have dropped from over 50% of all hospital deaths to less than 10% in academic centers and as low as 5% in non-academic hospitals. (1, 2)

The current low rate of autopsies is a challenge to modern healthcare. If autopsy rates continue to decline the clinical autopsy faces extinction, which would be harmful to medical research, education, quality assurance, and accurate mortality statistics. If the medical world wishes to change the tide, interventions to improve autopsy rates are necessary. (3, 4)

Reasons for the decline in autopsy rates

Although it is difficult to pinpoint the exact reason for the decline in autopsy rates, there are some factors which likely contribute. Dominating social, cultural and religious attitudes play an important role in the way autopsy is perceived and considered acceptable. These include religious inhibitions and cultural norms from next-of-kin, but also expectations and values of clinicians. For example, to a doctor it might feel that an autopsy can only lead to two outcomes. It can either confirm what he already knows or reveal unexpected findings and identify potential errors. The former outcome could be considered a waste of resources, and the latter outcome a reprimand for the requesting doctor possibly leading to a fear of lawsuits and insurance claims.

For the next-of-kin, the invasive nature of conventional autopsy may be an important reason why next-of-kin withhold consent, although this does not fully explain the decline in autopsy rates. The invasiveness of conventional autopsy has not increased in the period when the autopsy rate was decreasing. However, patients (and society in general) have become more assertive over the last century. For example, a grieving family may have overlooked the invasiveness of autopsy to abide by the wish of the doctor 50 years ago, but nowadays a bereaved family is much more likely to pursue their own interests first.

In Rotterdam, where our study was performed, a large proportion of the population is of non-western ethnicity. This may also be a factor which contributes to a decline in autopsy rates. In the 1960's and early 1970's mass immigration of migrant workers led to a situation where more than one third of the population is of non-western ethnicity. This group consists for a large part of immigrants from Turkey and Morocco with a predominantly

Muslim religion. The Quran does not specifically prohibit autopsy, but Islam does state that it is forbidden to mutilate or desecrate the body of a deceased person and many Muslims interpret this as a prohibition against organ donation and autopsy. Furthermore, in Islam the body of a deceased person needs to be buried as soon as possible, preferably always within 24 hours after death. (5, 6)

Financial aspects could also be a reason why doctors are less inclined to request autopsy. In the Netherlands, reimbursement for autopsy is not directly charged to the hospital ward that requested the autopsy, but costs are borne by all departments. This should minimize the financial restraint that doctors might feel when requesting autopsy, but in times when healthcare costs are rapidly increasing there is always pressure to decrease costs. (7)

Innovations in diagnostic methods has led to the belief that autopsies have lost their value. For example, the increased availability and quality of modern imaging methods may have contributed to declining autopsy rates. The prevailing overall perception is that diagnoses are already found before death, and postmortem investigations cannot really add anything new to the clinical picture. (3) A systematic review published in JAMA found that the possibility that an autopsy found an error has indeed decreased over time, but the review also stressed that the rate of errors found by autopsy was still high enough to stimulate the use of autopsy in clinical practice. (4, 8, 9) Quality assurance - e.g. detecting clinical errors or missed diagnoses - is one of the purposes of autopsy, but aside from quality assurance, autopsy is also used in research and for educating new doctors.

Performance of non- and minimally invasive autopsy procedures

We introduced minimally invasive autopsy as a strategy to increase autopsy rates in our hospital. The assumption was that next-of-kin would be more willing to consent to autopsy methods that are less invasive than conventional autopsy. As clinical postmortem radiology is a relatively new field, the first step in our research was to validate the method of the minimally invasive autopsy procedure.

In chapter 2 we reviewed the available literature about the performance of non-invasive or minimally invasive autopsies, comparing a wide variety of methods, including CT, MRI and ultrasound, sometimes in combination with biopsies or laparoscopic procedures. We found that minimally invasive autopsies that combined imaging and histology performed best. In all articles the conventional autopsy was used as the reference standard. It is common practice to use the best available diagnostic test as the reference standard, and therefore it is understandable that most studies chose the conventional autopsy as reference standard. However, multiple studies and our own experience from a pilot study demonstrated that conventional autopsy is not a perfect diagnostic test, with its own flaws and strengths. (10-25) In general, conventional autopsy is worse in diagnosing pathology

involving air: in our validation study conventional autopsy missed an air embolism that is distinctly seen on postmortem CT, but is practically undetectable with conventional autopsy. (22)

Postmortem alterations

Since postmortem imaging is still a relatively new field, it is important to realize that postmortem imaging differs from clinical imaging in living patients. After death there are several processes that occur in the body that have an effect on imaging appearance, such as sedimentation and clotting of blood, and decomposition (including putrefaction). Several clinical conditions have an effect on the degree to which postmortem processes change the body. For example, infections can cause more gas formation than what is normally seen in deceased patients without infections. Resuscitation can often cause rib fractures, pneumothorax, lung contusions, hemothorax, and intravascular air. For a correct interpretation of these features the radiologist has to be aware of common postmortem alterations and needs to integrate this with in-depth knowledge of the patient's clinical history.

Minimally invasive autopsy versus conventional autopsy

In our own validation study (chapter 4) we compared the performance of minimally invasive autopsy and conventional autopsy. We included 100 cases and performed both minimally invasive autopsy and conventional autopsy in all those cases. One case was excluded from analysis because the findings at conventional autopsy warranted a forensic autopsy. We used a reference standard process to decide if the minimally invasive autopsy and conventional autopsy were concordant or discordant, and if so, which of the two procedures best represented the true cause of death. Minimally invasive autopsy and conventional autopsy performed equally well in establishing the cause of death. Minimally invasive autopsy and conventional autopsy were in agreement with regards to the cause of death in 91 of 99 cases. In the remaining 8 cases, the MIA was correct in 5 cases and the conventional autopsy in 3 cases.

Minimally invasive autopsy had a higher yield for post-mortem diagnoses than conventional autopsy. Many of these diagnoses were not clinically known, indicating the lasting importance of postmortem investigations. We did not calculate sensitivity and specificity, since these would require a reliable determination of true negative findings, which are very hard to define when looking at all possible diagnoses.

In short, minimally invasive autopsy and conventional autopsy perform well in finding the cause of death and finding diagnoses, but both procedures have strengths and

weaknesses. Therefore, it is worthwhile to take a closer look at the diagnostic performance of minimally invasive autopsy and conventional autopsy for specific organ systems.

Performance of minimally invasive autopsy for cardiac pathology

Chapter 5 specifically investigates the performance of minimally invasive autopsy for finding acute and chronic myocardial infarction. The revised conventional autopsy results from the validation cohort were used as the reference standard for this analysis.

Several studies on forensic postmortem MRI reported a very high sensitivity for acute and chronic MI in human subjects. Temperature-corrected quantitative MRI was shown to detect myocardial infarctions reliably and could even differentiate between early acute, acute and chronic infarctions, based on quantitative T1, T2 and proton density values. In addition to its high accuracy, MRI could diagnose peracute myocardial infarction with an onset within 3 hours before death. These peracute infarctions are notoriously difficult to diagnose with conventional autopsy, because often histological changes have not yet occurred. (26-29) In our validation study we found a much lower sensitivity of MRI as a stand-alone test for acute myocardial infarction (sensitivity of 0.50) compared to other studies investigating postmortem MRI. The difference in sensitivity between those studies and ours is most likely caused by a difference in population and setting. The forensic studies were performed on a subgroup of cases with a high suspicion of a cardiac cause of death. Furthermore, the forensic studies were performed in a forensic setting and therefore had access to dedicated postmortem MRI scanners and could use relatively long acquisition times for scanning only the heart. (26) In contrast we were restricted to 1-hour acquisition time, and there was no selection of cases in our cohort so pathology could be encountered in all organs. Consequently, we had to scan the entire body in 1 hour.

Nevertheless, the combination of all the modalities in our procedure (CT, MRI and biopsies combined) resulted in high sensitivity and specificity for acute and chronic myocardial infarction. Especially MRI combined with biopsies had a very high diagnostic accuracy: there was a large increase in accuracy due to the addition of biopsies. Roughly half of the acute myocardial infarctions were not detected on postmortem MRI. This stresses the importance of extensive random sampling from the myocardium in addition to biopsies from targets that are detected with MRI.

The use of CT without contrast (native CT) in the heart is mostly limited to coronary calcium scoring (either qualitative or quantitative) and detecting abnormalities in heart shape (e.g. thinning of the wall as a result of chronic myocardial infarction). We calculated the Agatston calcium score and found that a high calcium score was a good predictor for chronic myocardial infarction, but not for acute myocardial infarction.

CT is sometimes used as a standalone postmortem investigation due to its high accessibility, short examination time, robust performance, and relatively low cost. This use of CT may lead to an improvement of mortality statistics compared to statistics derived from the cause of death determined by the clinician. (30) Native CT has some considerable shortcomings though: it has poor performance in diagnosing parenchymal disease and coronary stenoses and is therefore not sufficient in cases with sudden cardiac death. (31, 32) CT angiography (CTA) might help in this regard by providing a reliable way of detecting coronary stenoses and other vascular pathologies. Although angiography cannot diagnose acute infarction directly, a significant coronary stenosis detected in a person with sudden death (when no other findings are detected) justifies a cardiac cause of death. The same approach is used in conventional autopsy for peracute infarctions when a coronary occlusion is seen but no histological changes are seen yet. (26-28)

Weaknesses of minimally invasive autopsy

CT and MRI can answer most clinical questions, but biopsies were required to give a definite answer in the majority of cases we examined. There are a couple of areas where conventional autopsy is indicated over a minimally invasive autopsy. For these cases it is recommended to perform a conventional autopsy when consent can be obtained.

Conventional autopsy has a better performance than minimally invasive autopsy in most gastrointestinal pathologies. Conventional autopsy has the advantage that the entire gastro-intestinal tract can be viewed directly with the naked eye. This is especially beneficial for finding perforations or other abnormalities in or on the intestinal wall. Discoloration of the intestinal wall is not seen directly on imaging but depending on the underlying pathologic process this can manifest in different ways on imaging. For example, intestinal ischemia can result in gas accumulation in the intestinal wall, which can be seen on CT (so called pneumatosis intestinalis). Organ transplant rejection and graft-versus-host disease are also difficult to diagnose with imaging.

In cases where a direct view of a surgically implanted device or organ is beneficial, we also recommend performing a conventional autopsy. For example, when a patient dies shortly after organ transplantation it can be difficult to see the anatomical relations on imaging, and direct inspection of the transplant is often necessary.

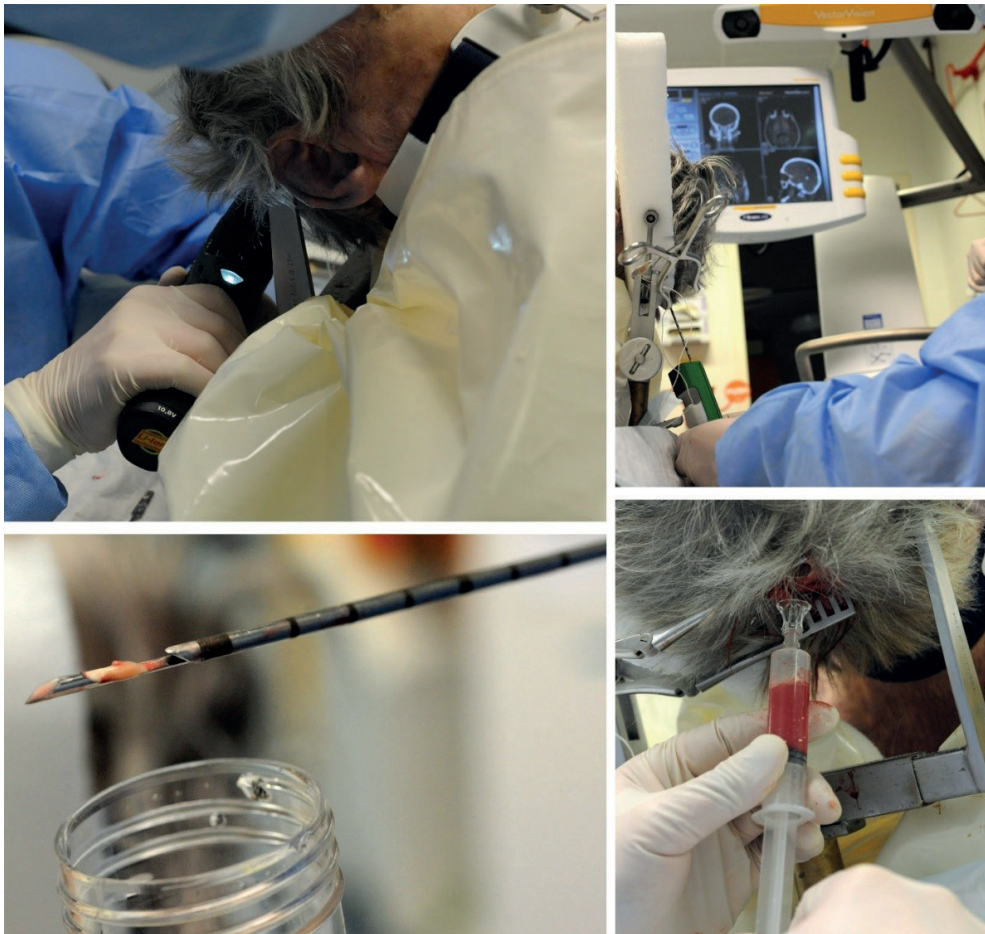Finally, sudden cardiac death in relatively young patients (under 40 years of age) often requires dissection of the heart. These young patients often suffered from cardiac arrhythmia and for an accurate diagnosis of the cause of the arrhythmia, it is necessary to take out the heart and dissect the entire conductive system of the heart.

Advantages of minimally invasive autopsy

Aside from the obvious advantage that minimally invasive autopsy leaves the body almost in its original state, it has several other important advantages over the conventional autopsy. Minimally invasive autopsy provides a permanent auditable record of the entire body including the brain that can be consulted objectively, whenever necessary, and at any location by pathologists, radiologists, clinicians, scientists, and next-of-kin. (25, 33)

Minimally invasive autopsy usually outperforms conventional autopsy when a full-body assessment is required, e.g. the status or growth of systemic diseases or oncological processes. Skeletal pathology or pathology involving air can be imaged exceptionally well, and in cases where these pathologies are suspected we recommend either a minimally invasive autopsy, or the combination of conventional autopsy with postmortem CT. Furthermore, the location of implanted devices is more reliably assessed on imaging, because the position can be seen in-situ.

Because the brain can only be investigated histologically after a long period of fixation, it is not possible to return the brain back into the skull after a conventional brain autopsy. Therefore, in the Erasmus University Medical Center and most other hospitals conventional autopsy is only combined with brain autopsy when additional specific consent is given to open the skull and investigate and retain the brain. Similarly, additional consent is required for brain biopsies, the equivalent of brain autopsy in a minimally invasive autopsy procedure (figure 1). An advantage that minimally invasive autopsy has over conventional autopsy is that it scans the brain by default. This means that even when no consent is given for histological examination of the brain, a basic postmortem brain examination is always possible. Postmortem CT and MRI can detect most major pathologies in the brain, like large hemorrhages and infarctions, but more subtle changes on postmortem scans of the brain often need histological confirmation for certain diagnosis.



Top-left: The head is first placed in a device that keeps it stable during the procedure. A small hole is made into the back of the skull. Top right: after calibration of the position of the head, the stereotactic camera can track the position of the needle. Bottom left: 11 gauge needle biopsy of brain tissue. Bottom right: liquor is usually taken without navigation.

Figure 1: Brain biopsies: a minimally invasive alternative to brain autopsy

Performance of CT and MRI

In chapter 6 we discussed the individual performance of CT and MRI for diagnosing major diagnoses and answering clinical questions. Overall MRI found more major diagnoses than CT in our study cohort. CT and MRI were both able to answer most clinical questions, but biopsies are required in most cases for a definitive answer.

CT has excellent performance for visualizing air collections and bone abnormalities, however myocardial infarctions are almost never seen with native CT, whereas MRI has

a reasonable performance for acute and chronic myocardial infarction. Nevertheless, we highly recommend the combination MRI with biopsies of the heart, especially if CTA is not performed. (34) Lung diagnoses, especially pneumonia, are among the most common causes of death, so a good diagnostic performance is necessary. CT and MRI both had a good diagnostic performance for pulmonary pathology, but postmortem alterations in the lungs can be quite extensive in a relatively short period of time after death and can mimic or mask diagnoses in dependent areas of the lungs. Therefore, random sampling from lung tissue (especially in the lower parts) is necessary to reduce the risk of missing diagnoses. (35)

Postmortem Computed Tomography Angiography (CTA)

There are several possible approaches when it comes to postmortem CTA: the contrast can either be targeted at a region of interest like the coronary system, or alternatively a total-body CTA can be performed. The latter approach requires a machine that can pump a liquid infusion with contrast material through the blood vessels. (19, 36-38)

A total-body CTA approach was tested by Rutty et al. in 210 natural, non-suspicious cases, and they found that postmortem CTA could identify the cause of death in 92% of cases. Postmortem CTA was better at diagnosing trauma and hemorrhage, and autopsy was better at diagnosing pulmonary thromboembolism. (39)

Full-body CTA was not included in our protocol, mainly because of logistical reasons: our mortuary does not have a dedicated postmortem CT scanner and we did not have the equipment and experience necessary to perform full-body CTA. Nevertheless, because of the ability of CTA to accurately diagnose vascular pathology it deserves a place in postmortem scanning protocols.

Effect of minimally invasive autopsy and ethnicity on acceptance

The most striking finding from our acceptance study was that the conventional autopsy rate was still decreasing during our measurement period (2010-2019) by about 0.1% per month. The autopsy rate was 14% in 2010 and dropped to approximately 8% in 2019. The introduction of minimally invasive autopsy had a small but significant effect (2.4%) on the total consent rate of postmortem investigations.

The effect of minimally invasive autopsy on total consent rate was smaller than what we had expected to see. This may be because the invasiveness of conventional autopsy is not an important enough factor in the decline of autopsy rates. Alternatively, the minimally invasive autopsy might still be considered too invasive, or maybe next-of-kin do not want

any kind of investigation on the body of their deceased family member, regardless of the extent of its invasiveness. The intervention period, when minimally invasive autopsy was available, was only 1 year. A longer period is necessary to be able to see if increased familiarity with the procedure would further increase consent rate. Therefore, the observed effect should be interpreted as a baseline measurement.

In the time period when minimally invasive autopsy was not available as a standalone postmortem investigation the consent rate of western-Europeans was significantly higher than in the group of other ethnicities. Interestingly the effect of minimally invasive autopsy on the total consent rate was only observed in the group of other ethnicities and not in western-Europeans. In the study period, when minimally invasive autopsy was available, the total consent rate was almost the same for both ethnic groups. This indicates that minimally invasive autopsy is indeed more acceptable to people of a non-western ethnicity. Because budget for research and healthcare interventions is often allotted based on mortality statistics it is crucial that postmortem diagnostics are performed in an adequate proportion of the population in all ethnic groups. Minimally invasive autopsy appears to be able to equalize the autopsy rates in the two ethnic groups that we differentiated in our analysis.

Attitudes of next-of-kin and doctors towards autopsy

The most frequently reported reason (given in roughly half of cases) to not give permission for an autopsy was the assumption that the cause of death was already known. Blokker et al. found a similar result in a questionnaire study in 2016, and this motivation is one of the most frequently assumed reasons for the decline in autopsy rate. (40) The reason that next-of-kin assume the cause of death is already known is often because of more advanced diagnostic tests available today. It should be noted however that the major error rate found at autopsy is still high enough to encourage the use of postmortem diagnostics. In our validation study the cause of death (found with minimally invasive autopsy or conventional autopsy) was not clinically suspected in 17% of cases, and 43% of the postmortem major diagnoses was clinically unsuspected. If clinicians become more aware of the value of autopsy, they are more likely to request consent and make a better case for autopsy, leading to an increased consent rate. (41)

Other reasons to deny permission for autopsy in order of the frequency they were reported were a long illness prior to death (23%), followed by religious objections against autopsy (10%) and the invasiveness of autopsy (10%). Especially the latter two motivations are interesting, because the minimally invasive autopsy can help alleviate these specific objections that next-of-kin have against autopsy. When people object to autopsy because of a long illness prior to death they often feel that the deceased 'has suffered enough' and they don't want to submit their loved one to more medical tests. It is plausible people who

denied consent for autopsy because of this objection are more amenable to consent to minimally invasive autopsy.

Cost of minimally invasive and conventional autopsy

The cost of a full minimally invasive autopsy was roughly €1.300. This includes all parts of the procedure (CT, MRI, biopsies, and brain biopsies). For reference a full conventional autopsy, including brain autopsy costs approximately €1.000. In our hospital conventional autopsy is a free service for next-of-kin. The overall costs of the autopsies are borne by the entire hospital, so little or no financial restraints should be felt by doctors or next-of-kin. Historically, the autopsy has always been viewed by the medical world as valuable enough to warrant its cost and the value of autopsy (accurate postmortem statistics, education of medical students and doctors, research, and quality control) has not diminished significantly. Nevertheless, an increase in postmortem tests (both minimally invasive autopsy and conventional autopsy) will lead to an increase in costs, and these costs are ultimately paid for by society.

Tailored approach

Instead of always going for the most extensive postmortem investigation, it could be a viable strategy to choose for a tailored approach on a case-per-case basis. In such a tailored approach a limited minimally invasive autopsy approach would be performed based on the clinical information. For example, if there is a high suspicion of myocardial infarction, instead of a full minimally invasive autopsy a detailed heart MRI scan would be performed, combined with histology sampling of the myocardium. This strategy is less expensive than performing a complete minimally invasive autopsy in, however there is a risk of tunnel visioning where only the clinically suspected pathologies are investigated, and unexpected findings are missed.

For next-of-kin a step-by-step approach may also be more acceptable, whereby more invasive techniques are only performed if the less invasive techniques are not conclusive. These considerations can be changed depending on the setting: for intensive care doctors it is important to know the correct cause of death and get feedback on the treatment, but for clinical oncologists it is important to know the exact tumor type and sample tissue for research in patients who were unresponsive to treatment.

Other strategies to increase autopsy rates

The primary reason we introduced minimally invasive autopsy in our hospital was to increase clinical autopsy rates by providing a more acceptable alternative to conventional autopsy. The advantages for clinical autopsy are generally accepted in medical literature and by most medical societies, but there is no formal recommendation for a minimal hospital autopsy rate. Consequently, it is difficult to formulate precise goals when it comes to autopsy rates, but there is no denying that the current rate is too low, even after the introduction of minimally invasive autopsy. Therefore, to reach an adequate level of autopsy rates more interventions may be necessary.

A prerequisite to achieve higher autopsy rates is to increase the perceived value of autopsy amongst clinicians. Clinicians are the ones who ask for permission and their conversation with the next-of-kin directly influences the chances of getting permission; if the doctor does not see value in autopsy, the next-of-kin are unlikely to be convinced of its value too. A first step could be to put more emphasis on the value of postmortem diagnostics in the medical curriculum and in the training of new residents. Unfortunately, a downward spiral is currently disrupting this: the low rate of autopsies results in new doctors hardly ever seeing an autopsy during medical school, therefore not realizing the value of autopsies and not being convincing when asking for permission for autopsy.

A different approach would be to have a dedicated team who leads the conversation after death, either counseling the family, or even asking for permission for postmortem diagnostics (preferably always with the doctor who is familiar with the case and the family present). The advantage of this approach is that a dedicated team would have in-depth knowledge of all postmortem diagnostics and can explain the ins-and-outs of the procedures. It is also easier to adequately train one dedicated team, than to train all clinicians, especially as there is a quick turnover in residents (who currently do the bulk of the consent conversations), making it difficult to maintain a high level of expertise. (42)

Limitations of our study and future perspectives

A limitation of our study was the lack of a good reference standard. Although conventional autopsy is often considered as the reference standard in many studies, our own experience and other authors have found that the technique is not perfect. Therefore, both minimally invasive autopsy and conventional autopsy were combined in the final reference standard result. This allowed us to compare both techniques with the best possible reference standard, but because both index tests were part of the reference test this is a source of incorporation bias. Another limitation in the validation of minimally invasive autopsy was that we could not reliably calculate specificity. For calculating specificity, it is necessary to know the number of true negative results. However, the number of true negatives was

impossible to define since we did not investigate diagnostic performance for a clearly defined set of diagnoses and locations. When we take all diagnoses into account that were found in the entire cohort and use this list to define true negatives, this leads to a very large number of true negatives and therefore an artificially inflated specificity. Future research should focus on clearly defined sets of diagnoses to give accurate diagnostic performance for new autopsy methods, similar to how we calculated performance of minimally invasive autopsy for acute and chronic myocardial infarctions.

Another limitation was the lack of a good effectiveness measure for autopsy procedures to perform a cost-effectiveness analysis. In chapter 6 we calculated both costs and a measure of diagnostic and clinical performance, but we did not have an effectiveness measure to perform a cost-effectiveness analysis. Whereas quality-adjusted life years gained is widely accepted as effectiveness measure in cost-effectiveness analysis, in the context of autopsy of a deceased patient this is meaningless. Future cost-effectiveness calculations could potentially use virtual health benefits gained in future patients as result of quality control as effectiveness measure.

There were issues with the logistics when we performed minimally invasive autopsy. The procedure time was a major limitation of the minimally invasive autopsy as we performed it: a minimally invasive autopsy consisting of CT, MRI and biopsies from the torso took approximately 4 to 5 hours to perform, and even longer when brain biopsies were performed. We did not have access to dedicated postmortem scanning facilities, therefore only 1 minimally invasive autopsy per day was possible, and we were limited to strict timeslots outside of regular working hours. A mortuary with scanning facilities -preferably both CT and MRI - that can be used for postmortem imaging would greatly alleviate many of the difficulties that we experienced. Not only would it greatly increase the available time in which bodies can be scanned, it would also remove the necessity of transporting bodies through the hospital to and from the scanners. To make this possible and cost-effective it seems logical to go for a centralized approach. For example, by establishing a regional autopsy and postmortem imaging center in Rotterdam to service the south-west region of the Netherlands. This would ensure that enough expertise is present to guarantee high quality of the involved personnel and would also increase the workload of the scanners and make the cost per procedure more affordable. Finally, successful implementation of a minimally invasive autopsy requires good cooperation and appreciation of the value of postmortem diagnostics from all involved parties.

References

1. Blokker BM, Weustink AC, Hunink MGM, Oosterhuis JW. Autopsy rates in the Netherlands: 35 years of decline. *PLOS ONE*. 2017;12(6):e0178200.
2. Ayoub T, Chow J. The conventional autopsy in modern medicine. *Journal of the Royal Society of Medicine*. 2008;101(4):177-81.
3. Nemetz PN, Tanglos E, Sands LP, Fisher WP, Jr., Newman WP, 3rd, Burton EC. Attitudes toward the autopsy—an 8-state survey. *MedGenMed*. 2006;8(3):80-.
4. Nichols L, Aronica P, Babe C. Are autopsies obsolete? *Am J Clin Pathol*. 1998;110(2):210-8.
5. Al-Adnani M, Scheimberg I. How can we improve the rate of autopsies among Muslims? *BMJ*. 2006;332(7536):310.
6. Gatrad AR. Muslim customs surrounding death, bereavement, postmortem examinations, and organ transplants. *BMJ*. 1994;309(6953):521.
7. Norbeck TB. Drivers of health care costs. A Physicians Foundation white paper - second of a three-part series. *Mo Med*. 2013;110(2):113-8.
8. Shojania KG, Burton EC, McDonald KM, Goldman L. Changes in rates of autopsy-detected diagnostic errors over time: a systematic review. *JAMA*. 2003;289(21):2849-56.
9. Brodlie M, Laing IA, Keeling JW, McKenzie KJ. Ten years of neonatal autopsies in tertiary referral centre: retrospective study. *BMJ*. 2002;324(7340):761.
10. Puranik R, Gray B, Lackey H, Yeates L, Parker G, Duflou J, et al. Comparison of conventional autopsy and magnetic resonance imaging in determining the cause of sudden death in the young. *J Cardiovasc Magn Reson*. 2014;16:44.
11. Roberts IS, Benamore RE, Benbow EW, Lee SH, Harris JN, Jackson A, et al. Post-mortem imaging as an alternative to autopsy in the diagnosis of adult deaths: a validation study. *Lancet*. 2012;379(9811):136-42.
12. Takahashi N, Higuchi T, Shiotani M, Hirose Y, Shibuya H, Yamanouchi H, et al. The effectiveness of postmortem multidetector computed tomography in the detection of fatal findings related to cause of non-traumatic death in the emergency department. *Eur Radiol*. 2012;22(1):152-60.
13. Westphal SE, Apitzsch J, Penzkofer T, Mahnken AH, Knuchel R. Virtual CT autopsy in clinical pathology: feasibility in clinical autopsies. *Virchows Arch*. 2012;461(2):211-9.
14. Westphal SE, Apitzsch JC, Penzkofer T, Kuhl CK, Mahnken AH, Knuchel R. Contrast-enhanced postmortem computed tomography in clinical pathology: enhanced value of 20 clinical autopsies. *Hum Pathol*. 2014;45(9):1813-23.
15. Wichmann D, Heinemann A, Weinberg C, Vogel H, Hoepker WW, Grabherr S, et al. Virtual autopsy with multiphase postmortem computed tomographic angiography versus traditional medical autopsy to investigate unexpected deaths of hospitalized patients: a cohort study. *Ann Intern Med*. 2014;160(8):534-41.

16. Roberts IS, Benbow EW, Bisset R, Jenkins JP, Lee SH, Reid H, et al. Accuracy of magnetic resonance imaging in determining cause of sudden death in adults: comparison with conventional autopsy. *Histopathology*. 2003;42(5):424-30.
17. Patriquin L, Kassarijian A, Barish M, Casserley L, O'Brien M, Andry C, et al. Postmortem whole-body magnetic resonance imaging as an adjunct to autopsy: preliminary clinical experience. *J Magn Reson Imaging*. 2001;13(2):277-87.
18. Wichmann D, Obbelode F, Vogel H, Hoepker WW, Nierhaus A, Braune S, et al. Virtual autopsy as an alternative to traditional medical autopsy in the intensive care unit: a prospective cohort study. *Ann Intern Med*. 2012;156(2):123-30.
19. Ross SG, Bolliger SA, Ampanozi G, Oesterhelweg L, Thali MJ, Flach PM. Postmortem CT angiography: capabilities and limitations in traumatic and natural causes of death. *Radiographics*. 2014;34(3):830-46.
20. Ross SG, Thali MJ, Bolliger S, Germerott T, Ruder TD, Flach PM. Sudden death after chest pain: feasibility of virtual autopsy with postmortem CT angiography and biopsy. *Radiology*. 2012;264(1):250-9.
21. Bolliger SA, Filograna L, Spendlove D, Thali MJ, Dirnhofer S, Ross S. Postmortem imaging-guided biopsy as an adjuvant to minimally invasive autopsy with CT and postmortem angiography: a feasibility study. *AJR Am J Roentgenol*. 2010;195(5):1051-6.
22. Weustink AC, Hunink MG, van Dijke CF, Renken NS, Krestin GP, Oosterhuis JW. Minimally invasive autopsy: an alternative to conventional autopsy? *Radiology*. 2009;250(3):897-904.
23. Fan JK, Tong DK, Poon JT, Lo OS, Beh PS, Patil NG, et al. Multimodality minimally invasive autopsy--a feasible and accurate approach to post-mortem examination. *Forensic Sci Int*. 2010;195(1-3):93-8.
24. Fariña J, Millana C, Fdez-Aceñero JM, Furió V, Aragoncillo P, Martín VG, et al. Ultrasonographic autopsy (echopsy): a new autopsy technique. *Virchows Archiv*. 2002;440(6):635-9.
25. Blokker BM, Wagenveld IM, Weustink AC, Oosterhuis JW, Hunink MGM. Non-invasive or minimally invasive autopsy compared to conventional autopsy of suspected natural deaths in adults: a systematic review. *European Radiology*. 2016;26(4):1159-79.
26. Jackowski C, Schwendener N, Grabherr S, Persson A. Post-mortem cardiac 3-T magnetic resonance imaging: visualization of sudden cardiac death? *J Am Coll Cardiol*. 2013;62(7):617-29.
27. Jackowski C, Warntjes MJ, Berge J, Bar W, Persson A. Magnetic resonance imaging goes postmortem: noninvasive detection and assessment of myocardial infarction by postmortem MRI. *Eur Radiol*. 2011;21(1):70-8.
28. Jackowski C, Christe A, Sonnenschein M, Aghayev E, Thali MJ. Postmortem unenhanced magnetic resonance imaging of myocardial infarction in correlation to histological infarction age characterization. *Eur Heart J*. 2006;27(20):2459-67.
29. Zech WD, Schwendener N, Persson A, Warntjes MJ, Jackowski C. Postmortem MR quantification of the heart for characterization and differentiation of ischaemic myocardial lesions. *Eur Radiol*. 2015;25(7):2067-73.

30. Sonnemans LJP, Kubat B, Prokop M, Klein WM. Can virtual autopsy with postmortem CT improve clinical diagnosis of cause of death? A retrospective observational cohort study in a Dutch tertiary referral centre. *BMJ Open*. 2018;8(3):e018834-e.
31. Oyake Y, Aoki T, Shiotani S, Kohno M, Ohashi N, Akutsu H, et al. Postmortem computed tomography for detecting causes of sudden death in infants and children: retrospective review of cases. *Radiat Med*. 2006;24(7):493-502.
32. Inai K, Noriki S, Kinoshita K, Sakai T, Kimura H, Nishijima A, et al. Postmortem CT is more accurate than clinical diagnosis for identifying the immediate cause of death in hospitalized patients: a prospective autopsy-based study. *Virchows Arch*. 2016;469(1):101-9.
33. Roberts ISD, Benamore RE, Benbow EW, Lee SH, Harris JN, Jackson A, et al. Post-mortem imaging as an alternative to autopsy in the diagnosis of adult deaths: A validation study. *Lancet*. 2012;379(9811):136-42.
34. Wagensveld IM, Blokker BM, Pezzato A, Wielopolski PA, Renken NS, von der Thüsen JH, et al. Diagnostic accuracy of postmortem computed tomography, magnetic resonance imaging, and computed tomography-guided biopsies for the detection of ischaemic heart disease in a hospital setting. *European Heart Journal - Cardiovascular Imaging*. 2018;19(7):739-48.
35. Wagensveld IM, Blokker BM, Wielopolski PA, Renken NS, Krestin GP, Hunink MG, et al. Total-body CT and MR features of postmortem change in in-hospital deaths. *PLOS ONE*. 2017;12(9):e0185115.
36. Roberts IS, Traill ZC. Minimally invasive autopsy employing post-mortem CT and targeted coronary angiography: evaluation of its application to a routine Coronial service. *Histopathology*. 2014;64(2):211-7.
37. Robinson C, Barber J, Amoroso J, Morgan B, Rutty G. Pump injector system applied to targeted post-mortem coronary artery angiography. *Int J Legal Med*. 2013;127(3):661-6.
38. Roberts IS, Benamore RE, Peebles C, Roobottom C, Traill ZC. Technical report: diagnosis of coronary artery disease using minimally invasive autopsy: evaluation of a novel method of post-mortem coronary CT angiography. *Clin Radiol*. 2011;66(7):645-50.
39. Rutty GN, Morgan B, Robinson C, Raj V, Pakkal M, Amoroso J, et al. Diagnostic accuracy of post-mortem CT with targeted coronary angiography versus autopsy for coroner-requested post-mortem investigations: a prospective, masked, comparison study. *Lancet*. 2017;390(10090):145-54.
40. Blokker BM, Weustink AC, Hunink MGM, Oosterhuis JW. Autopsy of Adult Patients Deceased in an Academic Hospital: Considerations of Doctors and Next-of-Kin in the Consent Process. *PLOS ONE*. 2016;11(10):e0163811.
41. Burton EC, Phillips RS, Covinsky KE, Sands LP, Goldman L, Dawson NV, et al. The relation of autopsy rate to physicians' beliefs and recommendations regarding autopsy. *The American Journal of Medicine*. 2004;117(4):255-61.
42. Limacher E, Carr U, Bowker L, Ball RY. Reversing the slow death of the clinical necropsy: developing the post of the Pathology Liaison Nurse. *J Clin Pathol*. 2007;60(10):1129-34.

English summary

Autopsies serve to establish cause of death and allow searching for diagnoses that were missed during life. In this regard, the autopsy can be seen as a quality assurance tool in healthcare. In addition, it is used in the education of doctors, and for scientific purposes. Despite its many benefits, autopsy rates worldwide have steadily declined, notable since the middle of the 20th century. Nowadays in the Netherlands a clinical autopsy is performed in only 5-10% of all patients who die in hospital. One of the reasons for the decline is the reluctance among next-of-kin and doctors to consent to an autopsy because of the invasiveness of the procedure.

To boost the rate of postmortem investigation, we introduced a minimally invasive autopsy (MIA) procedure at the Erasmus University Medical Center in Rotterdam, the Netherlands. It consists of an MRI- and a CT-scan, combined with CT-guided biopsies. The two main goals of the investigations described in this thesis were the validation of the MIA and the study of its implementation and acceptance in our hospital.

In **chapter 2** we compared 16 published studies that investigated the diagnostic performance of non- or minimally invasive autopsy procedures in a clinical setting. In these studies, various non-invasive imaging modalities were applied such as CT, MRI and ultrasound, and in some studies (minimally) invasive techniques such as laparoscopy, CT with intravascular contrast, and tissue biopsies as well. In every study the alternative autopsy procedure was compared to the conventional autopsy. The methodologies applied in these 16 studies appeared too diverse to allow a meta-analysis. However, it can be concluded that, compared to the conventional autopsy, the non-invasive methods performed relatively poorly and that the best results were achieved with procedures that combined radiology with tissue biopsies.

After death, various changes occur in the body due to normal postmortem processes. Briefly, the body stiffens (rigor mortis) and cools down (algor mortis). The absence of circulation causes sedimentation of blood in the vessels and gravity pulls all bodily fluids to the dependent (lower) parts of the body. Additionally, there is postmortem clotting of the blood. Decomposition and putrefaction result in the formation of gas in the body and degradation of tissues. Jointly these processes affect postmortem radiological images. In **chapter 3** we describe the frequency of common postmortem effects that can be depicted on imaging and investigate the effect of the postmortem time interval (the time between death and CT or MRI imaging) and certain clinical conditions, like intensive care admittance, and reanimation just before death. We found that a longer postmortem time interval mainly increases the changes that are due to decomposition and putrefaction. Patients who were resuscitated more often show air in the vessels, pleural effusion, distended intestines, and periportal edema on postmortem imaging. In contrast, the frequency of postmortem clotting is lower in patients who underwent resuscitation. Many postmortem changes can mimic pathologic changes on CT and MRI. Therefore,

radiologists need in-depth knowledge of postmortem processes and the effects they can have on radiological images.

The next part of this thesis focusses on the validation of our MIA procedure. In **chapter 4** we discuss the general validation of the MIA procedure that we applied at the Erasmus University Medical Center. Our validation cohort consisted of 99 deceased patients, for whom the next-of-kin gave permission to perform both MIA and conventional autopsy. In the cases where MIA and conventional autopsy found a different immediate cause of death, an independent reference standard committee consisting of a clinician, a radiologist and a pathologist, decided which one was correct. This committee had access to the findings of both the MIA and the conventional autopsy. In 91 of 99 cases the MIA and conventional autopsy found the same immediate cause of death. In the remaining eight cases the reference standard committee decided that the MIA was correct in five cases and the conventional autopsy in three. Aside from the immediate cause of death we also investigated the performance of MIA and conventional autopsy in finding other diagnoses. MIA found more diagnoses than the conventional autopsy: MIA found 259 (89.9%) and the conventional autopsy 224 of the 288 (77.8%) diagnoses that were related to the cause death of a patient. Minor diagnoses, unrelated to the cause of death, were also found more often with MIA. Unanswered or partly answered clinical questions are often a motivation for doctors to request an autopsy. MIA and conventional autopsy performed equally well in answering such questions. MIA answered 86% and conventional autopsy 83% of the 219 questions asked.

Acute cardiac death, often caused by myocardial ischemia, is a common cause of death in the Netherlands. Therefore, it is imperative that any new autopsy method has a good diagnostic performance for myocardial ischemia. In **chapter 5** we performed a sub-analysis on chronic and acute myocardial ischemia in the validation cohort. We separately analyzed the diagnostic performance of CT and MRI and the combination of CT, MRI and biopsies. CT without contrast can be used to calculate a coronary calcium score. Our results indicate that a high coronary calcium score in a deceased patient is strongly associated with chronic ischemia. However, CT could not reliably detect acute ischemia. On the other hand, MRI had some capability to diagnose both acute and chronic ischemia. However, the combination of MRI with biopsies specifically aimed at signal abnormalities achieved a very high diagnostic performance. This combination had a sensitivity of 97% and specificity of 95% for acute ischemia.

Chapter 6 focuses on the costs and performance of MIA in the acceptance cohort. In this cohort, MIA was performed in a routine clinical setting in 46 deceased. The main difference with the scientific setting of the validation cohort of chapter 4 being that MIA was now available as a stand-alone procedure, not followed by a conventional autopsy to validate the results. We investigated the costs, diagnostic yield and the percentage of clinical questions that could be answered by the full MIA and by CT and MRI separately. In this cohort we found 96 major diagnoses that were related to cause death. CT found

65/96 (67.7%) of these major diagnoses, and MRI found 82/96 (85.4%). However, in the majority of diagnoses that were detected on CT and MRI a biopsy was required to confirm or clarify the radiological findings. Eighty-four clinical questions were asked in the acceptance cohort and 71 (84.5%) of these could be answered by a full MIA. CT without biopsies could answer 23/84 (27.4%) clinical questions, and in combination with biopsies 34/84 (40.5%). MRI without biopsies answered 27/84 (32.1%) clinical questions, and in combination with biopsies 60/84 (71.4%). The average cost of a MIA procedure was €1296 and of conventional autopsy €991, both including investigation of the brain.

In the final part of this thesis I go back to the main goal as to why MIA was introduced at Erasmus University Medical Center, i.e. to increase the autopsy rate. In **Chapter 7** we investigated the effect of the availability of MIA as a standalone procedure on the total consent rate for postmortem investigation (i.e. the combined consent rates of MIA and conventional autopsy). Additionally, we investigated the effect of the introduction of MIA on the acceptance of postmortem investigation among people with a non-Western background. A striking finding was that the overall autopsy rate showed a significant decline throughout the investigated time period. In 2010 next-of-kin consented to autopsy in 14.0% of the deceased patients. In 2019 the autopsy rate had dropped to 8.3%. A linear regression model showed a significant effect of both time and the availability of MIA. Since the start of the study period, the autopsy rate dropped on average 0.1% per month. The possibility to consent to a MIA as a standalone procedure had a small but significant effect: an increase of 2.4% for the total postmortem consent rate. People with an ethnicity other than Western-European consented more often to postmortem investigation in the period that MIA was available. In fact, when MIA was available, next-of-kin of non-Western background consented to postmortem investigation just as often as next-of-kin with a Western background (12.5% non-Western vs. 12.6% Western).

Thus, the two main conclusions of this study are that MIA is a valid alternative to conventional autopsy, and that the availability of MIA appears to lead to an increase of the rate of postmortem investigation in people with a non-Western background.

Nederlandse samenvatting

Obducties worden gedaan om bij overledenen de doodsoorzaak vast te stellen en eventuele andere diagnoses op te sporen die bij het leven niet ontdekt waren. Hierdoor is de obductie een vorm van kwaliteitscontrole, maar tegelijkertijd speelt de obductie een rol bij onderwijs van artsen en wordt de obductie gebruikt voor wetenschappelijke doeleinden. Ondanks dit nut van de obductie daalt het obductiepercentage over de hele wereld gestaag sinds halverwege de vorige eeuw. Tegenwoordig wordt bij slechts 5-10 procent van de patiënten die in het ziekenhuis overlijden een obductie gedaan. Een van de redenen voor deze teruggang is de weerstand die de obductie oproept bij nabestaanden en artsen vanwege het invasieve karakter van de procedure.

Om de frequentie van postmortaal onderzoek te stimuleren hebben we een minimaal invasieve autopsie (MIA) procedure ontwikkeld in het Erasmus Medisch Centrum. De MIA bestaat uit een MRI- en CT-scan en CT-geleide bipten. In dit proefschrift beschrijf ik de validatie en het onderzoek naar implementatie en acceptatie van deze MIA-procedure.

In **hoofdstuk 2** vergeleken we 16 studies uit de literatuur over de prestaties van niet-invasieve of minimaal invasieve obducties in ziekenhuizen. Deze studies maken gebruik van verschillende niet-invasieve technieken zoals CT, MRI en echo. Naast deze niet-invasieve radiologie worden soms ook invasieve methodes gebruikt, zoals een kijkoperatie van de buik, een CT met intravasculair contrast, of weefselbipten. Alle alternatieve obductiemethoden werden vergeleken met een conventionele obductie. Helaas waren de 16 studies te uiteenlopend om een overkoepelende meta-analyse uit te kunnen voeren. Opvallend was dat de niet-invasieve methoden in vergelijking met de conventionele obductie matig presteerden en dat de beste resultaten werden behaald door de combinatie van beeldvorming en bipten.

Na het overlijden treden in het lichaam veranderingen op als gevolg van normale postmortale processen. Het lichaam verstijft (rigor mortis) en koelt af (algor mortis). De afwezigheid van bloedsomloop zorgt ervoor dat het bloed in de bloedvaten bezinkt, en de zwaartekracht maakt dat lichaamsvloeistoffen naar de lageregelegen delen van het lichaam worden verplaatst. Daarnaast ontstaan er postmortale stolsels in het bloed. Door ontbinding en rottingsprocessen ontstaat gas in het lichaam en vergaat het weefsel. Al deze processen kunnen een effect hebben op postmortale radiologische beelden. In **hoofdstuk 3** beschrijven we de frequentie van veelvoorkomende postmortale effecten op de CT en MRI-scans en onderzoeken we de invloed van het postmortale tijdsinterval (de tijd tussen het overlijden en de scans) en bepaalde klinische omstandigheden zoals intensive care opname en reanimatie voor het overlijden. Bij een langer postmortaal tijdsinterval nemen vooral de veranderingen toe die gerelateerd zijn aan ontbinding en rotting. Bij patiënten die gereanimeerd zijn wordt vaker lucht in de vaten, pleuravocht, uitgezette darmlussen en periportaal oedeem gezien, maar juist minder postmortale stolsels. Veel van deze postmortale effecten kunnen lijken op pathologische veranderingen. Daarom

hebben radiologen specifieke kennis nodig over de postmortale processen en welk effect ze kunnen hebben op radiologische beelden.

In het volgende onderdeel van dit proefschrift richten we ons op de validatie van onze methode. In **hoofdstuk 4** behandelen we de algemene validatie van de MIA zoals we die in het Erasmus Medisch Centrum hebben uitgevoerd. Ons validatiecohort bestond uit 99 overledenen voor wie de nabestaanden toestemming gaven voor het uitvoeren van zowel een MIA als een conventionele obductie. In gevallen waar de MIA en conventionele obductie een verschillende directe doodsoorzaak vonden besliste een 'gouden standaardcommissie' wat de juiste directe doodsoorzaak was. Deze commissie, die bestond uit een clinicus, een radioloog en een patholoog, had de beschikking over de resultaten van zowel de MIA als de conventionele obductie. In 91 van de 99 gevallen werd bij de MIA en de conventionele obductie dezelfde directe doodsoorzaak vastgesteld. In de resterende acht gevallen oordeelde de gouden standaardcommissie dat de MIA in vijf gevallen de juiste directe doodsoorzaak had vastgesteld en de conventionele obductie in drie gevallen. Naast de directe doodsoorzaak hebben we ook onderzocht hoe goed de MIA en conventionele obductie presteerden wat betreft het stellen van andere diagnoses. De MIA vond meer diagnoses dan de conventionele obductie: van de 288 diagnoses die een belangrijke rol hebben gespeeld bij het overlijden vond de MIA er 259 (89.9%) en de conventionele obductie 224 (77.8%). Ook minder belangrijke diagnoses werden door de MIA vaker gevonden. Klinische vragen die op het moment van het overlijden nog onbeantwoord zijn, vormen vaak een belangrijke motivatie om postmortaal onderzoek aan te vragen. MIA en conventionele obductie waren even goed in het beantwoorden van klinische vragen, met het antwoord op respectievelijk 86% en 83% van de 219 gestelde vragen.

In **hoofdstuk 5** hebben we een sub-analyse uitgevoerd op chronische en acute cardiale ischemie in het validatiecohort. Acute hartdood, vaak veroorzaakt door myocardiale ischemie, is een veelvoorkomende doodsoorzaak in Nederland. Daarom is het belangrijk dat een nieuwe obductiemethode een goede diagnostische zekerheid heeft op gebied van myocardiale ischemie. We hebben gekeken naar de diagnostische prestaties van CT en MRI en naar de combinatie van CT, MRI en biopten. CT (zonder contrast) kan gebruikt worden om de coronaire calcium-score te berekenen. Uit onze resultaten blijkt dat een hogere calcium-score bij een overleden patiënt een verhoogde kans op chronische (oude doorgemaakte) ischemie voorspelt. CT was echter niet geschikt om acute ischemie op te sporen. MRI had wel een redelijke diagnostische waarde voor zowel acute en chronische ischemie en zeker als MRI wordt gebruikt om gericht biopten van afwijkende gebieden te nemen, kan een hoge diagnostische zekerheid worden bereikt. De combinatie van MRI en biopten haalde een sensitiviteit van 97% en een specificiteit van 95% voor acute ischemie.

Hoofdstuk 6 richt zich op de kosten en resultaten in het acceptatiecohort, waarin de MIA in een routinematig geïmplementeerde setting werd uitgevoerd bij 46 overleden patiënten. Het belangrijkste verschil tussen deze setting en de wetenschappelijke setting

van de validatiestudie uit hoofdstuk 4 was dat MIA nu beschikbaar was als zelfstandige procedure (niet gevolgd door een conventionele obductie). We onderzochten de kosten, diagnostische zekerheid en het percentage klinische vragen dat kon worden beantwoord door de MIA als geheel en door CT en MRI als losse onderdelen. In dit cohort vonden we 96 belangrijke diagnoses die direct hadden bijgedragen aan het overlijden. De CT vond 65/96 (67.7%) van de diagnoses, en de MRI 82/96 (85.4%). Voor zowel CT als MRI gold echter dat bij de meerderheid van de diagnoses een biopsie nodig was voor de bevestiging of duiding van de radiologische bevindingen. In het acceptatiecohort kon de MIA (de combinatie van CT, MRI en biopsie) 71/84 (84.5%) klinische vragen beantwoorden. CT kon zonder biopsie 23/84 (27.4%) klinische vragen beantwoorden en in combinatie met biopsie 34/84 (40.5%). MRI kon zonder biopsie 27/84 (32.1%) klinische vragen beantwoorden en in combinatie met biopsie 60/84 (71.4%). De gemiddelde prijs van een MIA was €1296 en van conventionele obductie €991, beide inclusief histologisch onderzoek van de hersenen.

In het laatste deel van dit proefschrift keren we terug naar de reden waarom de MIA werd geïntroduceerd in het Erasmus Medisch Centrum: om het obductiepercentage te vergroten. In **hoofdstuk 7** onderzochten we het effect van de beschikbaarheid van de MIA op de totale frequentie van postmortale diagnostiek (MIA en conventionele obductie samen). Ook onderzochten we het effect van de introductie van de MIA op de acceptatie van postmortaal onderzoek bij mensen met een niet-Westerse achtergrond. Kenmerkend was dat gedurende de onderzochte periode nog steeds een duidelijke daling van het obductiepercentage te zien was. In 2010 stond nog 14.0% van de nabestaanden toe om een obductie uit te voeren. In 2019 werd dit nog maar bij 8.3% van de overleden patiënten toegestaan. Met een lineair regressiemodel hebben we het effect van de tijd en de beschikbaarheid van de MIA onderzocht. Sinds het begin van de studieperiode nam het obductiepercentage gemiddeld met 0.1% per maand af. De mogelijkheid voor nabestaanden om een MIA te laten uitvoeren als alternatief voor een obductie bleek een klein maar significant effect van 2.4% te hebben op de totale acceptatie. Mensen van een andere etniciteit dan Westers-Europees stonden in de periode dat MIA beschikbaar was vaker toe dat postmortaal onderzoek werd uitgevoerd. In de periode dat de MIA beschikbaar was, werd door nabestaanden met een Westerse en een niet-Westerse achtergrond nagenoeg even vaak postmortaal onderzoek toegestaan, namelijk in 12.6% (Westers) en 12.5% (Niet-westers).

De twee belangrijkste conclusies uit ons onderzoek zijn dat de MIA een valide alternatief is voor de conventionele obductie, en dat de beschikbaarheid van MIA lijkt te leiden tot een toename van postmortaal onderzoek onder mensen met een niet-Westerse achtergrond.

Curriculum Vitae

Ivo Wagenveld was born on October 23rd, 1989 in Vlissingen, the Netherlands. He graduated cum laude from gymnasium Nehalennia in Middelburg in 2007, after which he started medical school at Leiden University. His interest in research was sparked during his MSc studies, when he did scientific radiological research focusing on neuroimaging in migraine patients at the Leiden University Medical Center. His enthusiasm for radiology was further confirmed during a 4-month internship at the Haaglanden Medical Centre in the Hague. After completing medical school in 2013, he started his PhD project on the subject minimally invasive autopsy at the Erasmus University Medical Center in Rotterdam. This project, under supervision of professor M.G.M. Hunink, professor J.W. Oosterhuis and Dr. A.C Weustink, resulted in this thesis. In the final year of his PhD project, he also worked at NICTIZ in the Hague, where he contributed to a project on the Dutch translation of the SNOMED CT terminology database. In 2019 he started his radiology residency in the Erasmus University Medical Center.

PhD Portfolio

Courses and workshops	Year	Workload (ECTS)
Stralingsbeschermings-deskundigheidsniveau 5A	2013	1.0
MRI veiligheidstraining, niveau 2	2013	0.3
Intermediate course medical decision making	2014	0.3
Erasmus MC winter course: Diagnostic research (EWP05)	2014	0.9
Erasmus MC winter course: Advanced Topics In Decision-Making In Medicine (Ewp02)	2014	1.9
NIHES Biostatistical Methods I: Basic Principles Part a (CC02a)	2014	2.0
Courses for the Quantatative researcher	2014	1.4
Course scientific integrity	2015	0.3
Repeated measurements	2015	1.4
English writing course	2015	2.0
Acute hartdood in de klinische pathologie	2015	1.0
Moslims en orgaandonatie	2015	0.3
Workshop on photoshop and illustrator	2016	0.3
Workshop on Microsoft Excel 2010: Basic	2016	0.3
Workshop on Microsoft Excel 2010: Advanced	2016	0.4
Total		12.1

Conferences, symposia, presentations	Year	Workload (ECTS)
Clin-epi meeting 1 hour weekly, 3 years	2013-2016	2.0
presentation: MIA study: update and next cohort (Clin-epi meeting research group)	2016	0.1
European Congress of Radiology	2016	1.4
EPOS: Overview of physiological post-mortem alterations in total-body imaging of 100 in-hospital deceased patients	2016	1.0
EPOS: How to implement a Minimally Invasive Autopsy (MIA) procedure in a hospital setting; a practical guideline for radiologists	2016	1.0
Voice of EPOS: Postmortem stereotactic-guided biopsies in minimally invasive autopsy	2018	1.0
Erasmus MC PhD Day 2016: 'Balance your PhD!'	2016	0.3
RSNA Annual meeting	2017	1.4
Imaging research on the move	2017,2018	0.2
RSNA: Oral presentation: Diagnostic Performance of Minimally Invasive Autopsy for Detection of Ischemic Heart Disease	2017	1.0
Radiologendagen	2018	0.6
Radiologendagen scientific talk: Postmortem stereotactic-guided biopsies in minimally invasive autopsy	2018	0.5
Radiologendagen plenaire presentatie missers: forensisch	2018	0.5
Total		11.0

Teaching activities	Year	Workload (ECTS)
VO: 'keuze bij diagnostische testen'	2014,2015	1.4
Supervising Master student Nikola Vitlarov	2013-2014	4.0
VO: 'Clinical trials'	2016	0.7
Teaching assistant: Advanced Topics In Decision-Making In Medicine (EWP02)	2015,2016	1.8
Teaching session for CT & MRI technicians	2016,2017	0.6
Teaching session for radiology residents	2018	0.3
Total		8.8

Dankwoord

Promoveren doe je niet alleen en dit proefschrift is dan ook tot stand gekomen met de hulp en steun van ontzettend veel mensen. In het bijzonder wil ik een aantal personen bedanken, die de afgelopen jaren een grote rol hebben gespeeld bij mijn PhD traject of daarbuiten.

Allereerst mijn promotor, professor Myriam Hunink. Beste Myriam, ik heb ontzettend geluk gehad dat ik onder jouw begeleiding mocht promoveren. Bedankt voor de fijne overleggen, de overzichtelijke aantekeningen en de steun die je me over de jaren hebt gegeven. Jouw kalme instelling en aanpak in het leven zijn een grote inspiratie voor mij. Promoveren is niet altijd leuk, maar mede dankzij jou heb ik het willen en kunnen afmaken, bedankt!

Mijn copromotors, professor Wolter Oosterhuis en dr. Annick Weustink, bedankt voor jullie begeleiding.

Beste Wolter, bedankt voor de vele uren die we samen hebben doorgebracht achter de microscoop en de tijdsinvestering die u in dit onderzoek heeft gestopt. Ik heb meer geleerd van u dan ik hier kan noemen, en veel meer dan alleen op medisch gebied. Ik kijk op tegen de respectvolle, vriendelijke en professionele wijze waarop u met mensen omgaat. Ik heb ontzettend veel respect voor de manier waarop u met veel plezier en passie uw werk voortzet in de pathologie, in het bijzonder op wetenschappelijk gebied.

Beste Annick, bedankt voor je directe supervisie tijdens mijn promotie. Je praktische aanpak voor de vele problemen waar ik tegenaan liep tijdens mijn promotie zijn een belangrijke stimulans geweest voor het MIA-onderzoek. Ik zal je ongetwijfeld nog veel zien tijdens mijn opleiding tot radioloog, ik ga er van uit dat we onze plezierige samenwerking kunnen voortzetten.

Professor Gabriel Krestin, bedankt voor de ondersteuning en het vertrouwen vanuit de afdeling radiologie voor dit onderzoek, en voor uw bereidheid om in de grote commissie deel te nemen.

Professor Folkert Kemenade, bedankt voor de plezierige samenwerking en het gemak waarop ik vaak met je kon overleggen. Ik hoop dat we nog vaak kunnen samenwerken in de toekomst. Bedankt dat je deel wilt uitmaken van mijn kleine commissie.

Professor Vincent Smit wil ik graag bedanken voor de bereidheid om deel uit te maken van de kleine commissie en voor het lezen en beoordelen van dit proefschrift.

Hartelijk dank aan de leden van de grote commissie voor hun bereidheid om naar Rotterdam af te reizen om hun expertise in te zetten en met mij van gedachten te wisselen over dit proefschrift.

Beste Britt, bedankt voor de samenwerking met name in het begin van mijn promotietraject. Je nauwkeurigheid en grondigheid zijn een groot talent, wat ongetwijfeld van grote waarde zal zijn in je toekomstige carrière als patholoog.

Veel dank aan alle klinici van het Erasmus MC die patiënten hebben aangemeld voor een MIA-studie. Zonder jullie had het onderzoek niet kunnen plaatsvinden. Ook veel dank aan de nabestaanden die toestemming hebben gegeven voor het uitvoeren van post-mortaal onderzoek.

Er zijn veel mensen van de afdelingen radiologie en pathologie die een rol hebben gespeeld bij het MIA-onderzoek. Vooral alle laboranten en analisten die hebben geholpen met MIA's, jullie zijn van onschatbare waarde voor beide afdelingen en ik dank jullie hartelijk voor al het harde werk.

Van de afdeling radiologie wil ik nog een paar mensen specifiek benoemen:

Piotr Wielopolski, ik ben je veel dank verschuldigd. Weinig anderen zouden om 5 uur 's ochtends op de MRI-kamer aanwezig zijn voor het onderzoek van iemand anders. Ronald Booij, bedankt voor je hulp voor alle CT gerelateerde zaken. Succes met de laatste loodjes van je eigen promotie!

Alle MIA-radiologen: Mariska Rossius, Arlette Odink, Marianne de Vries, Jan-Jaap Visser, en Nomdo Renken, bedankt voor jullie inzet en enthousiasme tijdens de MIA's. Ik zie uit naar onze verdere samenwerking in de kliniek.

Andrea Pezzato, thank you for your help with the cardiac manuscript!

Van de afdeling pathologie is er ook een groep mensen zonder wie de MIA nooit van de grond zou zijn gekomen.

Ik wil graag de medewerkers van het mortuarium bedanken: de Japen en Mortalitas, bedankt voor de hulp en samenwerking tijdens de MIA-studie. Ik weet dat een MIA vaak extra werk voor jullie betekende, heel veel dank voor de inzet. Jaap Slooff, geniet van je welverdiende pensioen. Jaap Bongers, wie weet zullen we weer samenwerken als de MIA-studie een vervolg krijgt.

Bedankt aan alle pathologen die MIA-slides hebben bekeken als we er zelf niet uitkwamen.

Jan von der Thüsen, Vidijia Soerdjbalie, Max Kros, King Lam, bedankt voor jullie hulp!

Ingrid, Roos, Marjolein, Brenda, Annelise, bedankt voor jullie ondersteuning en hulp!

Alle MIA studenten: bedankt voor de hulp tijdens het uitvoeren van de MIA's en de gezellige momenten.

Iedereen met wie ik met plezier heb samengewerkt tijdens en rondom mijn promotie:

Mensen van Clin-epi: Loes, Rinske, John, Ewoud, Nikola, Erica, bedankt voor de nuttige overleggen en de gezelligheid.

Ca-207: Marisa, Laurens, Sara, Nikki, Fay, Wiebe, Adriaan, Raluca, Juste, Admir, Ali, Murat: de tijd in Ca-207 was zonder twijfel een van de leukste periodes van mijn onderzoek. Bedankt dat ik als niet-cardiologie PhD-student mocht aansluiten bij deze gezellige groep!

Alle mensen van Nictiz: Sander, Annemarieke, Elze, Natasha, Inge, Todor, Marly, Femi, Saswika, Gracia, Maikel, Nidal, Thomas 2x, Wing, Shacara, Maud, Omar, Malou, Eveline. Bedankt voor de gezellige en ontspannen tijd bij Nictiz en niet te vergeten de 2 T's: taart en tosti.

Ik wil ook Koekela graag bedanken voor alle cheesecake die me de energie heeft gegeven om door te gaan.

Beste Dave, ontzettend veel dank voor het ontwerpen van het originele en mooie cover design!

Koen, Jaap, Saskia, Sean bedankt voor de sportieve afleiding tijdens onze gezamenlijke bouldersessies.

Jongens van Hephaistos, ik kan me geen betere groep vrienden wensen dan jullie. Bedankt voor inmiddels al meer dan 12 jaar van ploeggetens, slechte grappen, hoogte- en dieptepunten die we samen hebben meegemaakt.

Willem, Bas, bedankt dat jullie mijn paranimfen wilden zijn. Bedankt voor de steun ter voorbereiding en tijdens de grote dag!

Lieve familie, bedankt voor jullie onvoorwaardelijke liefde en steun. Papa en mama jullie staan altijd voor mij klaar, bedankt voor alles. Coen, Joost, Merel, Jip en Daan. Reinder, Alice, Roeland en Lianne. Bedankt voor de leuke tijden in Zeeland en Polen. Een lieve familie is geen vanzelfsprekendheid en ik besef goed dat ik met jullie allemaal geboft heb. Lieve Laura, bedankt voor je steun, geduld en liefde. Ik weet zeker dat we een ongelooflijk fijne tijd gaan hebben in Rotterdam.

