

Case Report 

# Management of Septal Branch Perforation and Septal Hematoma During Retrograde Treatment of Coronary Chronic Total Occlusion Using Fat Embolization

Paola Scarparo, MD, Jeroen Wilschut, MD, Nicolas M. Van Mieghem, MD, PhD, and Roberto Diletti, MD, PhD

*Department of Cardiology, Thoraxcenter, Erasmus Medical Center, Rotterdam, the Netherlands*

**ABSTRACT**

Septal vessel perforation followed by septal hematoma is a rare complication of retrograde approach for treatment of coronary chronic total occlusions, possibly leading to septal rupture. We report 2 cases of patients with septal vessel perforation and subsequent hematoma successfully treated with autologous fat embolization. Such technique is inexpensive, omnipresent, and relatively easy to perform.

**RÉSUMÉ**

L'hématome septal qui suit la perforation septale est une complication rare de l'approche par voie rétrograde dans le traitement des occlusions totales chroniques d'une artère coronaire qui peut mener à la rupture septale. Nous rapportons deux cas de patients ayant subi une perforation septale et un hématome subséquent qui ont été traités efficacement par embolisation par graisse autologue. Cette technique est peu coûteuse, omniprésente et relativement facile à réaliser.

Recent advancements in techniques and material for percutaneous treatment of coronary chronic total occlusions (CTOs) led to increased adoption of a retrograde approach for treatment of complex CTO lesions. The most commonly used collaterals for retrograde procedures are the septal vessels compared with epicardial collaterals, given their intramuscular course that possibly contains blood extravasations.

However, although the navigation of septal collaterals is generally regarded as a relatively safe manoeuvre when performed by experienced operators, septal-vessel perforation is not devoid of risks.<sup>1,2</sup> Management of septal vessel perforation could be challenging, given the bilateral blood supply of those vessels, potentially requiring treatments at both sides.

We report the use of autologous fat embolization as a feasible, inexpensive, relatively easy, and omnipresent technique to treat septal hematomas and prevent occurrence of septal rupture.


**Case 1**

A 77-year-old man with previous history of coronary artery bypass grafting (LIMA-MO1/MO2, Ao-RCA) presented with

stable angina. Coronary angiography confirmed total saphenous vein graft occlusion to a chronically occluded right coronary artery (RCA). After demonstration of inferior wall viability, there was heart-team consensus for percutaneous recanalization attempt of the RCA.

The lesion had a J-CTO score of 3 (blunt stump, calcification, occlusion length  $\geq 20$  mm), a diffusely diseased distal vessel, and presence of septal collaterals. Successful recanalization was achieved with a retrograde approach through septal collaterals.

However, final angiograms revealed a septal vessel rupture and a growing septal hematoma

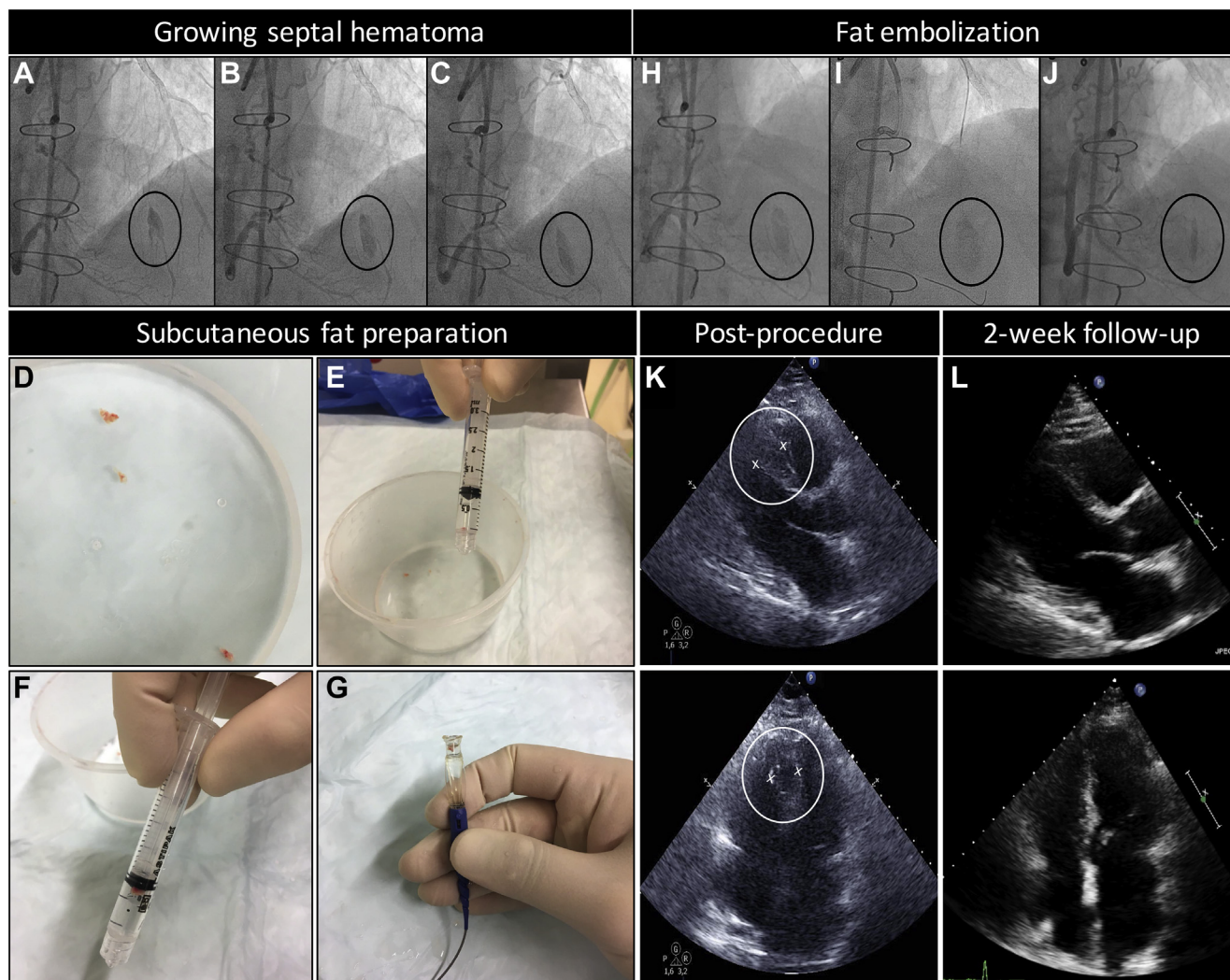
(Fig. 1, A-C; Video 1  view video online). Balloon occlusion of the posterior descending artery (PDA) was performed, blocking blood flow from the RCA. Subsequently a Corsair microcatheter (Asahi Intecc Co, Ltd, Aichi, Japan) was readvanced in the septal branch, also blocking the blood flow from the left anterior descending (LAD) artery. Small pieces of autologous subcutaneous fatty tissue ( $\leq 3$  mm in diameter) were obtained from the groin of the patient at the site of puncture of the femoral artery. The sample was cut into small particles with a diameter of 0.5 to 1.0 mm (Fig. 1, D-G), and the septal vessel was embolized with autologous fat particles via the microcatheter (Fig. 1 H and I). Then the balloon in the PDA was deflated, and a second embolization was performed after advancing a microcatheter in the distal segment of the septal branch via the distal RCA. A total of 8 fat microemboli—5 in the proximal and 3 in the distal septal branch—were delivered.

Received for publication November 8, 2019. Accepted December 9, 2019.

Corresponding author: Dr Roberto Diletti, Interventional Cardiology, Thoraxcenter, Erasmus MC, Dr.Molewaterplein 40, 3015 GD Rotterdam, the Netherlands. Tel.: +0031-10-703-52-60; fax: +0031-10-703-52-54.

E-mail: [r.diletti@erasmusmc.nl](mailto:r.diletti@erasmusmc.nl)

See page 1.e3 for disclosure information.



**Figure 1.** (A-C) Septal branch perforation and growing septal hematoma. (D) Fat material collection. (E) Aspiration of fat particles in a small syringe with saline. (F) The fat floats to the surface because of the low density. (G) Positioning in the microcatheter. (H) Septal hematoma before fat embolization. (I) Subcutaneous fat is injected into the septal branch through the microcatheter. (J) Angiographic result after fat embolization. (K) Postprocedure echocardiography reveals an echo-free space in the interventricular septum. (L) Hematoma reabsorption.

The septal hematoma was successfully confined, and the overall contrast staining in the septum shrunk (Fig. 1J). The echocardiogram revealed a circular septal hematoma (Fig. 1K). The patient remained asymptomatic, and serial echocardiograms were performed. Two weeks later, the septal hematoma appeared completely resorbed (Fig. 1L).

## Case 2

A 64-year-old woman presented with angina Canadian Cardiovascular Society (CCS) grade II and CTO of the RCA with a collateral retrograde filling via the LAD. There was heart-team consensus for percutaneous attempt of RCA recanalization.

During the septal crossing, a septal vessel perforation occurred, resulting into a growing septal hematoma. Fat particles were obtained from the subcutaneous tissue at the femoral puncture site, the microcatheter (Corsair; Asahi Intecc Co) was advanced in the septal proximally to the perforation,

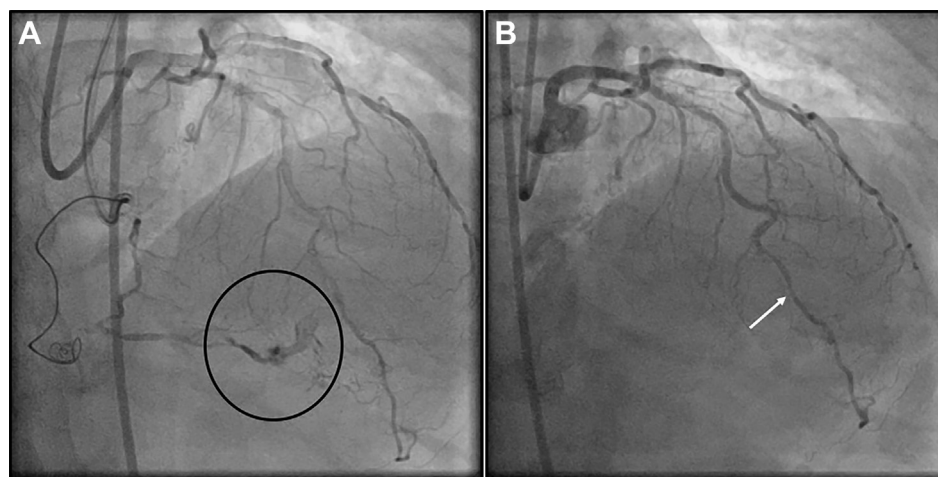
and multiple fat emboli were delivered. Subsequent angiogram demonstrated the complete sealing of the perforation, without any angiographic evidence of residual septal hematoma (Fig. 2 A and B).

## Discussion

Septal-vessel perforation followed by hematoma is rare during retrograde CTO percutaneous coronary intervention (PCI) but could be a potentially life threatening event if followed by septal rupture.<sup>1</sup>

Fat embolization is a fast, simple, and omnipresent technique to seal small-vessel (including collaterals) perforations. The fat embolization physically blocks blood flow and simultaneously triggers both platelet aggregation and coagulation.

Usually, multiple fat particles are required to reach a satisfactory result, and the embolization should be performed repeatedly until a complete hemostasis is achieved. For



**Figure 2.** (A) Septal hematoma. (B) After fat embolization, the septal vessel is occluded (arrow), and the septal hematoma is no longer visible.

detailed methodological information see [Supplementary Material](#).

The decision-making process for an optimal septal perforation/hematoma management should be guided by the evolution of the hematoma. Despite muscle containment in the majority of cases,<sup>3</sup> fast-growing intramural hematomas require swift medical attention and active treatment such as balloon inflations, delivery of microcoils, or fat embolization.

In our cases, prolonged balloon inflations were unsuccessful as a frontline approach to stop the bleedings, and rapid development of large septal hematoma prompted the adoption of fat embolization.

In similar situations, microcoils could be also used; however, those devices are not always readily available, and as with fat embolization, the need for multiple microcoils might increase costs. Of note, current 0.018-inch microcoils cannot be delivered through the standard microcatheters (for example, Corsair and Finecross [Shibuya, Tokyo, Japan]), and only smaller microcoils (0.014-inch) (Axiom, Medtronic, Dublin, Ireland) can be delivered directly via currently used CTO microcatheters.

Finally, an additional advantage of gaining experience and expertise in the fat-embolization technique is represented by the possible use of it also in non-CTO procedures. In particular, distal wire exits and perforation of small vessels could be also treated delivering fat particles.

## Conclusion

Septal collateral perforations and septal hematoma formation during CTO PCI procedures are rare but potentially life-threatening events. This case series reported autologous fat

embolization as feasible nonexpensive and omnipresent source to achieve rapid hemostasis.

## Funding Sources

The authors have no funding to disclose.

## Disclosure

The authors have no conflicts of interest to disclose.

## References

1. Fairley SL, Donnelly PM, Hanratty CG, Walsh SJ. Images in cardiovascular medicine. Interventricular septal hematoma and ventricular septal defect after retrograde intervention for a chronic total occlusion of a left anterior descending coronary artery. *Circulation* 2010;122:e518-21.
2. Frisoli TM, Afana M, Mawri S, et al. Respect the septal perforator: septal artery perforation during CTO PCI resulting in massive interventricular septal hematoma and biventricular cardiac obstructive shock. *JACC Cardiovasc Interv* 2017;10:e91-2.
3. Jackson MWP, Lee D, Egred M. Septal hematoma: a rare but potentially serious complication of retrograde CTO-PCI. *J Invasive Cardiol* 2019;31:e47-8.

## Supplementary Material

To access the supplementary material accompanying this article, visit the online version of the *Canadian Journal of Cardiology* at [www.onlinecjc.ca](http://www.onlinecjc.ca) and at <https://doi.org/10.1016/j.cjca.2019.12.012>.