

ORIGINAL ARTICLE

Surgical management and pathological assessment of pancreatoduodenectomy with venous resection: an international survey among surgeons and pathologists

Jesse V. Groen¹, Martijn W.J. Stommel², Arantza F. Sarasqueta³, Marc G. Besselink⁴, Lodewijk A.A. Brosens^{5,6}, Casper H.J. van Eijck⁷, Isaac Q. Molenaar⁸, Joanne Verheij³, Judith de Vos-Geelen⁹, Martin N. Wasser¹⁰, Bert A. Bonsing¹, J. Sven D. Mieog¹ for the Dutch Pancreatic Cancer Group

¹Department of Surgery, Leiden University Medical Center, Leiden, ²Department of Surgery, Radboud University Medical Center, Nijmegen, ³Department of Pathology, ⁴Department of Surgery, Cancer Center Amsterdam, Amsterdam UMC, University of Amsterdam, ⁵Department of Pathology, University Medical Center Utrecht, Utrecht, ⁶Department of Pathology, Radboud University Medical Center, Nijmegen, ⁷Department of Surgery, Erasmus Medical Center, Rotterdam Department of Surgery, ⁸Department of Surgery, University Medical Centre Utrecht, Utrecht, ⁹Department of Internal Medicine, Division of Medical Oncology, GROW - School for Oncology and Developmental Biology, Maastricht UMC+, Maastricht, and ¹⁰Department of Radiology, Leiden University Medical Center, Leiden, the Netherlands

Abstract

Background: The aim of this survey was to gain insights in the current surgical management and pathological assessment of pancreatoduodenectomy with portal–superior mesenteric vein resection (VR).

Methods: A systematic literature search was performed to identify international expert surgeons (N = 150) and pathologists (N = 40) who published relevant studies between 2009 and 2019. These experts and Dutch surgeons (N = 17) and pathologists (N = 20) were approached to complete an online survey.

Results: Overall, 76 (46%) surgeons and 37 (62%) pathologists completed the survey. Most surgeons (71%) estimated that preoperative imaging corresponded correctly with intraoperative findings of venous involvement in 50–75% of patients. An increased complication risk following VR was expected by 55% of surgeons, mainly after Type 4 (segmental resection-venous conduit anastomosis). Most surgeons (61%) preferred Type 3 (segmental resection-primary anastomosis). Most surgeons (75%) always perform the VR themselves. Standard postoperative imaging for patency control was performed by 54% of surgeons and 39% adjusted thromboprophylaxis following VR. Most pathologists (76%) always assessed tumor infiltration in the resected vein and only 54% of pathologists always assess the resection margins of the vein itself. Variation in assessment of tumor infiltration depth was observed.

Conclusion: This international survey showed variation in the surgical management and pathological assessment of pancreatoduodenectomy with venous involvement. This highlights the lack of evidence and emphasizes the need for research on imaging modalities to improve patient selection for VR, surgical techniques, postoperative management and standardization of the pathological assessment.

Received 6 December 2019; accepted 23 April 2020

Correspondence

J. S. D. Mieog, Department of Surgery, Leiden University Medical Center, Albinusdreef 2, 2300 RC Leiden, the Netherlands. E-mail: J.S.D.Mieog@lumc.nl

Introduction

Pancreatic cancer infiltration in the portal or superior mesenteric vein (PV-SMV) is not considered a contra-indication for a resection as stated by the International Study Group of Pancreatic Surgery (ISGPS) in 2014.¹ The assessment of venous involvement is important in surgical decision making since the resection margin on the level of the PV-SMV is among the most frequently affected.^{2,3} In selected patients, it is possible to perform a venous resection (VR) to acquire a tumor-free resection margin on the level of the PV-SMV.¹ There is considerable variation in contemporary literature on the clinical management of pancreatoduodenectomy with venous involvement.

The reported correspondence between preoperative imaging, findings during surgery and pathological assessment shows much variation and it remains challenging to select the right patients eligible for VR.^{4–6} Despite criteria for assessment of vascular involvement on computed tomography exist,⁷ absence of tumor infiltration in the resected vein in the final pathology is reported in 39% (range 17–78) of VR.⁸ The surgeon has to rely on preoperative imaging, visual inspection, palpation and intraoperative frozen sections in order to distinguish tumor from normal tissue, peritumoral inflammation and fibrosis. This is especially challenging after neoadjuvant chemo- and radiotherapy.^{9–11} Routine VR and a “no-touch” technique, without breaching the “capsule” of the tumor at the venous margin, have been described earlier.^{12,13} Some studies reported promising results of intraoperative ultrasound.^{14–17} The direct contact with the operative field and real-time imaging provides feedback about the tumor and vascular involvement. Still, it is unknown how often intraoperative ultrasound is used in daily practice and what the added value is in terms of clinically relevant outcome.

The preferred technique for VR is still under debate, illustrated by the variations in applied techniques for VR (e.g. wedge or segmental resection) and reconstruction (e.g. direct closure, end-to-end anastomosis or interposition graft).^{18–21} A meta-analysis of 27 studies on pancreatectomy with or without VR showed increased postoperative morbidity, mortality and worse survival after VR, although there was considerable heterogeneity between the included studies.⁸ Early PV-SMV thrombosis is a notorious complication which occurs in approximately 6% of patients after VR. Currently, guidelines regarding thromboprophylaxis are lacking.²²

The relevance of tumor infiltration in the resected vein and depth of tumor infiltration remain unclear. Some studies report an association with decreased survival^{4,23} whereas other studies report no association with survival at all.^{5,21,24} There are differences between the currently used techniques for macroscopic assessment of the pancreatoduodenectomy specimen by pathologists.²⁵ It should be noted that none of the regular used grossing protocols have a detailed description on how to assess and to approach the resected vein. Some studies

described the assessment of the resected vein, including the insertion of a plastic probe into the vein in the fresh specimen.^{26,27} Nevertheless, variations in assessment of tumor infiltration, depth of tumor infiltration and resection margins of the resected vein likely exist and hamper generalization of study results.^{28,29}

The aim of this survey was to gain insights in the current surgical management and pathological assessment of pancreatoduodenectomy with suspected venous involvement by international and Dutch surgeons and pathologists. Furthermore, it aims to identify areas in need for further research to improve the multidisciplinary management of pancreatic cancer with suspected venous involvement.

Methods

Study design and population

This study was performed and reported according to the Checklist for Reporting Results of Internet E-Surveys (CHERRIES).³⁰ An online surgeon-specific and pathologist-specific survey was designed by the authors. The survey was tested multiple times to guarantee that questions were clearly formulated and unambiguous.

A systematic search was performed to identify international expert surgeons who published relevant studies between January 2009 and June 2019 ([Supplementary Material](#)). The email addresses of corresponding authors (surgeons) were identified. These international expert surgeons were approached to complete the online surgeon-specific survey. Furthermore, the corresponding authors were requested to suggest an expert pathologist in their institution. These international expert pancreatic pathologists were approached to complete the online pathologist-specific survey. From every Dutch hospital performing pancreatic surgery (Dutch Pancreatic Cancer Group (DPCG)) at least one representing surgeon and pathologists was approached to complete the survey.

The open and voluntary surveys were sent out via Google Forms (<https://docs.google.com/forms>). Non-respondents were contacted by e-mail or telephone up to three times. Institutional Review Board approval was not requested since no patients were involved. Informed consent of respondents was implied when the survey was completed.

Survey

The content of the survey is provided in the [Supplementary Material](#). Survey questions included multiple-choice, checkbox and open questions and were not randomized, altered, or adaptive. Some questions were mandatory. Respondents were able to review and change their answers at the end of the survey. Cookies or IP addresses were not used to prevent multiple entries from the same individual. The request for single entry was stated in the welcome message. Data was collected anonymously and no incentives were offered.

The surgeon-specific survey consisted of 33 questions divided over 12 pages. The survey consisted of questions regarding: surgeon characteristics, volume of VR, correspondence between imaging, surgery and pathology, technical aspects, complications and postoperative care.

The pathologist-specific survey consisted 18 questions divided over seven pages. The survey consisted of questions regarding: volume of VR, assessment of (depth of) tumor infiltration in the resected vein and resection margins of the resected vein.

Definitions

Throughout the manuscript, 'VR' refers to a resection of the PV-SMV, 'venous involvement' refers to (suspected) involvement of the PV-SMV and 'resected vein' refers to the resected PV-SMV itself. Correspondence between preoperative imaging, intraoperative findings and pathological assessment was considered in cases such as: suspected venous involvement on preoperative imaging was also observed during surgery and VR was performed or; VR was performed with tumor infiltration in the resected vein in final pathology. Type of VR was classified according to the ISGPS guidelines: Type 1 = partial venous excision with direct closure (venorrhaphy) by suture closure; Type 2 = partial venous excision using a patch; Type 3 = segmental resection with primary venovenous anastomosis; Type 4 = segmental resection with interposed venous conduit and at least two anastomoses.¹ Extent of sampling of the resected vein for pathological assessment was categorized as 'none' (no assessment), 'most suspected' (assessment of one slice of the resected vein most suspect of tumor infiltration or irradical

margin) and 'complete' (assessment of multiple slices of the resected vein).

Statistical analysis

For statistical analysis Statistical Package for the Social Sciences for Windows (version 23.0, SPSS, Inc) was used. All completed surveys were analyzed. No formal sample size calculation was performed. The results are reported for the total cohort and compared by international experts *versus* DPCG surgeons and pathologists. Categorical data were reported as numbers (percentages) and compared by chi-square or Fisher's exact tests. P-values <0.05 were considered significant.

Results

Respondents

Rate of response and estimated percentage of venous resections

In total, 76 of 167 (46%) surgeons and 37 of 60 (62%) pathologists completed the survey (Fig. 1). Thirty-seven (49%) surgeons estimated that a VR was performed in 11–20% of patients (Table 1). Fifteen (41%) pathologists estimated that a VR was performed in 5–10% of patients (Table 2).

Surgeon-specific survey

Correspondence between preoperative imaging, surgery and pathology

Correspondence on venous involvement between preoperative imaging and intraoperative findings in 50–75% of patients was

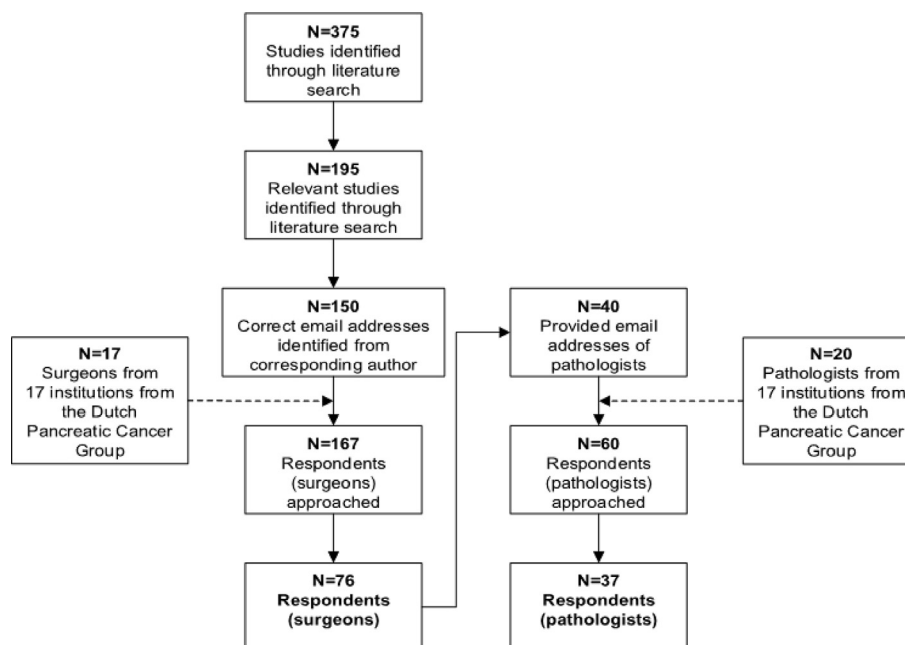


Figure 1 Flow chart of approached surgeons and pathologists

Table 1 Clinical management of pancreatoduodenectomy with venous involvement by surgeons

	Total cohort of surgeons	
	N	%
Total	76	
Continent		
Europe	51	67
America	13	17
Asia/Oceania	12	16
Estimated percentage of venous resection?		
≥10%	19	25
11–20%	37	49
21–40%	17	22
>40%	3	4
Do you use per-operative imaging (ultrasound)?		
Never	43	57
Selected cases	25	33
Always	8	11
Increased risk of complications?		
Venous resection		
No	34	45
Yes	42	55
Confluens/SMV versus the PV?		
No	21	28
Yes	55	72
Estimated incidence of:		
Post-operative PV-SMV thrombosis? ^a		
<5%	32	42
5–10%	32	42
>10%	12	16
Post-operative portal hypertension at long-term?		
<5%	42	55
5–10%	20	26
>10%	14	18
Post-operative bleeding of vascular reconstruction? ^a		
<5%	72	95
5–10%	3	4
>10%	1	1
Post-operative complications due to congestion? ^a		
<5%	56	74
5–10%	13	17
>10%	7	9

^a <90 days after surgery.

estimated by 54 (71%) surgeons. More variation in the estimated correspondence between preoperative imaging or intraoperative findings and pathological assessment was observed (Fig. 2).

Intraoperative ultrasound was used by 33 (43%) surgeons (Table 1).

Complications

An increased risk of complications after VR was estimated by 42 (55%) surgeons (Table 1). An increased risk of complications after a resection of the SMV/confluens compared with PV was estimated by 55 (72%) surgeons. Type 3 reconstruction (in the scenario of multiple options) was preferred by 46 (61%) surgeons, followed by 22 (26%) surgeons who preferred Type 1 reconstruction (Fig. 3). Type 4 reconstruction was presumed to carry the highest risk of complications by 45 (59%) surgeons, followed Type 1 reconstruction by 15 (20%) surgeons (Fig. 2B).

The most expected postoperative complication was PV-SMV thrombosis within 90 days after surgery, followed by development of portal hypertension at long-term (Table 1). Some variation in the expected complications due to congestion of the VR within 90 days after surgery existed. Bleeding from the VR within 90 days was the least expected complication.

Technical aspects

A VR was always performed by 57 (75%) surgeons themselves, 22% of surgeons prefer to consult a vascular or transplant surgeon (if available) and 2% of surgeons never perform the VR themselves (Table 3). Clamping for proximal and distal venous control before VR was preferred over vessel loops by 72 (95%) surgeons. The use of a donor vein was preferred over an autologous vein by 14 (18%) surgeons. Heparinization during VR was used by 23 (30%) surgeons. Intraoperative flow measurement in the venous reconstruction was performed by nine (12%) surgeons (accepted flow range: 150–900 mL/min). Clamping of the superior mesenteric artery (SMA) to prevent bowel wall edema during VR was used by 14 (18%) surgeons.

Postoperative care

Standard postoperative imaging (ultrasound or computed tomography) for patency control was performed by 41 (54%) surgeons. More than 10 standard thromboprophylaxis regimens were identified when considering type of medication, dosage and duration of prophylaxis. An adjusted thromboprophylaxis regimen following VR (compared to standard) was used by 30 (39%) surgeons.

International expert surgeons versus DPCG surgeons

A comparison between international expert and Dutch surgeons is provided in the Supplementary Material. Among international expert surgeons, the estimated percentage of VR was higher, Type 3 VR was more often preferred over Type 1, an increase of the risk of complications after VR was less often expected (namely less PV-SMV thrombosis within 90 days after surgery) and Type 4 VR was presumed to carry a higher risk of complication over Type 1. Furthermore, international expert surgeons performed

Table 2 Assessment of pancreatoduodenectomy specimen with venous involvement by pathologists

	Total cohort of pathologists	
	N	%
Total	37	100
Continent		
Europe	29	78
America	2	5
Asia/Oceania	5	14
Unknown	1	3
Estimated percentage of venous resection?		
<5%	10	27
5–10%	15	41
11–20%	3	8
>20%	9	24
Do you assess tumor infiltration in the resected vein?		
Never	3	8
Rarely	1	3
Most often	5	14
Always	28	76
Extent of assessment of tumor infiltration in the resected vein		
None	3	8
Most suspected (part of resected vein)	18	49
Complete (entire resected vein)	15	41
Not standardized	1	3
Do you assess depth of tumor infiltration in the resected vein?		
Never	10	27
Rarely	6	16
Most often	9	24
Always	12	32
Extent of assessment of depth of tumor infiltration in the resected vein?		
None	10	27
Most suspected (part of resected vein)	13	35
Complete (entire resected vein)	14	38
Do you assess the resection margins of the resected vein?		
Never	6	16
Rarely	4	11
Most often	7	19
Always	20	54
Extent of assessment of the resection margins of the resected vein?		
None	6	16
Most suspected (resection margins of the resected vein)	12	32
Complete (all resection margins of the resected vein)	19	51
Do you use additional stainings for assessment of the resected vein?		
No	19	51
Yes	18	49
Differences between institutions and pathologists in assessment of venous involvement?		
No	4	11
Yes	33	89

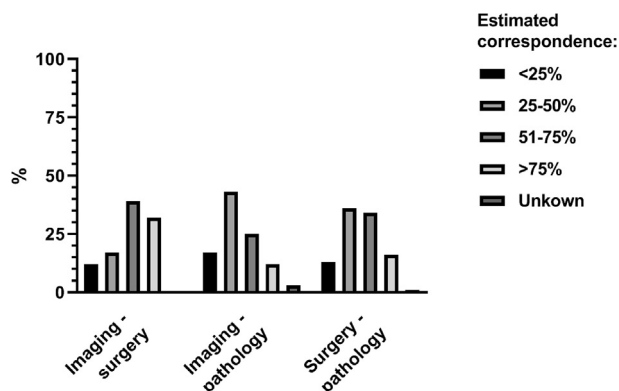


Figure 2 Estimated correspondence between preoperative imaging, findings during surgery and pathological assessment regarding venous involvement

the VR more often themselves and performed heparinization more often.

Pathologist-specific survey

Pathological assessment

Tumor infiltration in the wall of the resected vein was always assessed by 28 (78%) pathologists (Table 2). The resection margins of the resected vein were always assessed by 19 (53%) pathologists. The depth of tumor infiltration in the wall of the resected vein was always assessed by 12 (32%) pathologists. Some variation was observed in the extent of sampling to assess tumor infiltration.

Additional stainings for the assessment of the wall of the resected PV-SMV were used by 18 (49%) pathologists. The Elastica von Gieson staining was preferred by 16 (45%) pathologists. Among the reasons not to determine (depth of) tumor infiltration or resection margins of the resected vein: 'not in hospital protocol', 'not relevant for prognosis', 'resected vein not recognized' were mentioned. Variation in daily practice of

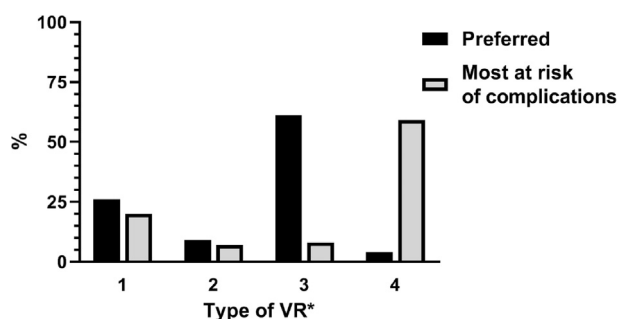


Figure 3 Preferred type of venous resection and presumed most at risk of complications. Type 1= partial venous excision with direct closure; Type 2= partial venous excision with patch reconstruction; Type 3= segmental resection with primary anastomosis; Type 4=segmental resection with interposed venous conduit and at least two anastomoses

pathological assessment of the resected vein was expected by 33 pathologists (89%).

International expert pathologists versus DPCG pathologists

A comparison between international expert and Dutch pathologists is provided in the [Supplementary Material](#). Among international expert pathologists, the estimated percentage of VR was higher, assessment of depth of tumor infiltration in the wall of the resected PV-SMV was more often always performed and additional stainings (namely Elastica von Gieson staining) for assessment of the wall of the resected PV-SMV were used less frequently.

Discussion

This international survey gives insights into the current surgical management and pathological assessment of pancreatoduodenectomy with venous involvement of international surgeons and pathologists. Different perceptions exist between surgeons and pathologists regarding the estimated percentage of pancreatoduodenectomies with VR. Correspondence between preoperative imaging, intraoperative findings and pathology regarding venous involvement was considered to be suboptimal. Half of the surgeons use intraoperative ultrasound to assess venous involvement. Type 3 reconstruction (segmental resection with primary anastomosis) is most popular, followed by Type 1 reconstruction (partial venous excision with direct closure). Half of surgeons expected a higher risk of complications after VR (especially PV-SMV thrombosis). Some surgeons prefer a donor vein over an autologous vein and some surgeons use clamping of the SMA. Heparinization during VR, postoperative imaging and thromboprophylaxis regimens differed substantially. Most pathologists determine whether there is tumor infiltration in the wall of the resected vein. However, only half of the responding pathologists assess the resection margins of the resected vein. Assessment of depth of tumor infiltration differed between pathologists. Only small differences were observed between international expert and Dutch surgeons and pathologists.

Differences in estimated percentage of VR by participating surgeons reflect what is already known in the literature: a VR rate ranging from 6–65%.⁸ Regarding venous involvement, the surgeons estimated less correspondence between preoperative imaging-pathology and surgery-pathology than preoperative imaging-surgery. Surgeons find it hard to determine if there is tumor infiltration in the resected vein during surgery and to select the right candidates for VR. The estimated correspondence between preoperative imaging and intraoperative findings might deteriorate in the near future, because of more frequent neoadjuvant treatment.³¹ Neoadjuvant chemo- and radiotherapy downstages the tumor, but also induces inflammation and fibrosis, which makes assessment of vessel involvement on preoperative imaging and during surgery less reliable.^{9–11} It should

Table 3 Technical management of pancreatoduodenectomy with venous involvement by surgeons

	Total cohort of surgeons	
	N	%
Total	76	
Do you perform the venous resection and reconstruction yourself?		
No	2	3
If possible, with vasc/tx surgeon	17	22
Yes	57	75
Preference for vascular control before venous resection?		
Vessel loops	3	4
Clamping	72	95
Not specified	1	1
Preference as venous graft?		
Autologous vein	62	82
Donor vein	14	18
Preference as synthetic graft?		
PTFE	15	20
Goretex	10	13
Dacron	2	3
Not specified	49	64
Do you perform heparinization?		
No	53	70
Yes	23	30
Do you perform flow measurement?		
No	67	88
Yes	9	12
Do you perform SMA occlusion to prevent portal congestion		
No	62	82
Yes	14	18
Do you perform standard post-operative imaging?		
No	35	46
Yes	41	54
Do you adjust thromboprophylaxis?		
No	46	61
Yes	30	39

Vasc/tx: vascular/transplant; PTFE: polytetrafluoroethylene; SMA: superior mesenteric artery.

be noted that this survey did not include questions regarding types, quality and timing of preoperative imaging or neoadjuvant treatment.

A survey study found that intraoperative ultrasound is underexposed in the training of active Americas Hepato-Pancreato-Biliary Association members and recent graduates.³² This may explain why 57% of international expert surgeons never use intraoperative ultrasound (DPCG surgeons: 47%). The

promising results of intraoperative ultrasound,^{14–17} have led to the initiation of the ULTRAPANC study within the DPCG (<https://www.trialregister.nl/trial/7621>) investigating the added value of intraoperative ultrasound in vascular involvement assessment in pancreatic cancer. To distinguish pancreatic tumor infiltration from inflammatory or fibrotic tissue, other techniques like fluorescence image-guided surgery and intraoperative cytology of the touch smear of the exposed PV-SMV are being investigated.^{33–35} These additional tools may decrease the number of patients put at increased risk of complications due to unnecessary VR (i.e. no tumor infiltration in the resected vein and sufficient resection margin). On the other hand, previous studies have suggested improved survival after routine VR which warrants further investigation.¹³

Type 3 reconstruction was most popular in the scenario of multiple options, followed by Type 1 (namely among DPCG surgeons). A donor vein was preferred over an autologous vein for reconstruction by 18% of surgeons. This probably reflects a variety of personal preferences and experience, though might also be influenced by ethical or legislation issues. Several studies have shown an increase of VR over the time, indicating that there should be sufficient exposure in the training program of pancreatoduodenectomy surgeons.^{36–38} Most surgeons thought that Type 4 reconstruction carried the highest risk of complications. Several studies about association between type of VR and complications exist.^{19,21,39,40} A meta-analysis and a cohort study showed that a prosthetic graft was associated with early PV-SMV thrombosis.^{18,22} This is relevant since early PV-SMV thrombosis (the most expected complication in the survey) is one of the main causes of postoperative mortality and immediate treatment is warranted.^{22,41,42} Some studies describe the use of intraoperative techniques like clamping of the SMA, heparinization²² and flow measurement in the venous reconstruction,⁴³ although its role has yet to be determined as the use varied between surgeons. Thromboprophylaxis might decrease the risk of PV-SMV thrombosis following VR, but a meta-analysis of non-randomized studies showed no association between thromboprophylaxis and incidence of thrombosis.²² Thromboprophylaxis remains a difficult subject as the balance between thrombosis and postoperative hemorrhage is delicate.⁴⁴ In this regard, the large variation in postoperative imaging and thromboprophylaxis regimens among surgeons is remarkable in view of the fact that PV-SMV thrombosis is the most expected complication after VR. Future research is needed to identify the optimal technique for VR, postoperative management (including imaging for patency control and thromboprophylaxis) after pancreatoduodenectomy with VR.

The low estimated percentages of VR by pathologists compared to surgeons may for a large part be explained by unrecognized resected vein due to absence or loss of marking of the specimen and insufficient information in the pathology order. Within the DPCG there is increasing awareness of this problem and several proposals have been discussed to standardize

pathology orders and reports. The majority of pathologists in the survey determine tumor infiltration in the wall of the resected vein, whereas only half assesses the resection margins of the resected venous wedge or segment. As stated by the ISGPS, a VR is indicated if a radical resection is possible and thus the resection margins of the VR should be assessed to confirm this. However, the significance of a positive or minimal margin at the resected vein is unclear, let alone the relevance of tumor reaching the tunica intima which suggests possible shedding of tumor into the bloodstream. Assessment of depth of tumor infiltration (27% never, 16% rarely, 24% most often, 32% always) varied between pathologists. This is not surprising, since contemporary literature on the clinical relevance of depth of infiltration is contradicting.^{4,5,21,23,24} According to the ISGPS, depth of vessel infiltration should be classified as tunica adventitia, media and further, or tumor in the intima.¹ It is unclear whether pathologists were involved in the ISGPS statement. The proposed classification is challenging for pathologists as the limits of the tunica adventitia are not easily identified due to peritumoral inflammation.

There are two commonly used grossing techniques (axial slicing and bivalving) for pathological assessment of the pancreatoduodenectomy specimen. There is no evidence in favor of one or the other and the choice is often based on personal preferences and training history.²⁵ The main advantage of the bivalving technique is the ability to adequately assess the origin of periampullary tumors and assess cystic tumors and their relationship to the ducts, which is less relevant in pancreatic cancer specimens. The bivalving dissection method⁴⁵ and the Royal College of Pathologists dataset⁴⁶ describe sampling of the resected vein, although without precise sampling directions. The axial dissection method necessitates more samples, with a higher probability of finding an R1 margin, and a more extensive nodal assessment. However, it does not describe sampling of the resected vein.^{47,48} Almost all pathologists expected variation in daily practice regarding the approach of a resected vein. The principal reason for this is the lack of information in pathology orders and communication between the surgeon and pathologist. This emphasizes the need for standardization and completeness of pathology orders. Once the resected vein is always recognized and assessment is standardized, it may become possible to study the clinical and prognostic implications of tumor infiltration in the wall of the resected vein, its resection margins and relationship between tumor infiltration and circulating tumor DNA.

This results of this study should be interpreted in light of some limitations. First, the relatively small sample size. The systematic review of the last decade ensures representation of expert pancreatic surgeons and pathologists and provides insight in the multidisciplinary management on an international level. Due to the small sample size, however, no subgroup analyses were performed per continent. Second, responses are preferences and

perceptions of individuals and were not confirmed by patient data. Lastly, when interpreting the comparison between international experts and Dutch surgeons and pathologists, one must realize that the international experts are mostly from high (er) volume institution and have been involved in research on this topic as a result of the selection of these experts from the literature.

Nowadays, pancreatoduodenectomy with venous involvement is a small but growing part of clinical practice and therefore collaboration is pivotal to gain evidence and improve outcomes. To provide more insight in the clinical impact of pancreatoduodenectomy with venous involvement, the authors initiated the MULTI-VERS PROJECT (<https://www.trialregister.nl/trial/6775>).

In conclusion, this international survey shows variations in the surgical management and pathological assessment of pancreatoduodenectomy with venous involvement. This highlights the lack of high-level evidence and emphasizes the need for further research on imaging modalities to improve patient selection for VR, surgical techniques, postoperative management, the prognostic relevance and standardized pathology assessment of tumor infiltration, depth of tumor infiltration and resection margins of the resected vein.

Acknowledgements

The authors would like to thank all participating surgeons and pathologists who completed the survey.

Ethics approval and consent to participate

Institutional Review Board approval was not sought since no patients were involved. Informed consent of respondents was implied when they completed the survey.

Consent for publication

Not applicable.

Data availability

The datasets used during this study are available on reasonable request from the corresponding author.

Funding

This work was supported by the Bas Mulder Award (grant UL2015-7665) from the Alpe d'HuZes foundation/Dutch Cancer Society.

Authors' contributions

Study conception and design: JVG, MS, AFS, MGB, CHJvE, IQM, JdV, MNW, BAB, JSDM.

Data acquisition, analyses and interpretation: JVG, MS, AFS, MGB, LAAB, JV, BAB, JSDM.

Manuscript drafting and revising: JVG, MS, AFS, LAAB, MGB, CHJvE, IQM, JV, JdV, MNW, BAB, JSDM.

Final approval of manuscript: JVG, MS, AFS, MGB, LAAB, CHJvE, IQM, JV, JdV, MNW, BAB, JSDM.

Conflict of interest

None declared.

References

- Bockhorn M, Uzunoglu FG, Adham M, Imrie C, Milicevic M, Sandberg AA *et al.* (2014) Borderline resectable pancreatic cancer: a consensus statement by the International Study Group of Pancreatic Surgery (ISGPS). *Surgery* 155:977–988.
- van Roessel S, Kasumova GG, Tabatabaie O, Ng SC, van Rijssen LB, Verheij J *et al.* (2018 Jun) Pathological margin clearance and survival after pancreaticoduodenectomy in a US and European pancreatic center. *Ann Surg Oncol* 25:1760–1767. <https://doi.org/10.1245/s10434-018-6467-9>. Epub 2018 Apr 12.
- Tummers WS, Groen JV, Sibinga Mulder BG, Farina-Sarasqueta A, Morreau J, Putter H *et al.* (2019 Jul) Impact of resection margin status on recurrence and survival in pancreatic cancer surgery. *Br J Surg* 106: 1055–1065. <https://doi.org/10.1002/bjs.11115>. Epub 2019 Mar 18.
- Han SS, Park SJ, Kim SH, Cho SY, Kim YK, Kim TH *et al.* (2012) Clinical significance of portal-superior mesenteric vein resection in pancreatoduodenectomy for pancreatic head cancer. *Pancreas* 41: 102–106.
- Nakao A, Kanzaki A, Fujii T, Kodera Y, Yamada S, Sugimoto H *et al.* (2012) Correlation between radiographic classification and pathological grade of portal vein wall invasion in pancreatic head cancer. *Ann Surg* 255:103–108.
- Porembka MR, Hawkins WG, Linehan DC, Gao F, Ma C, Brunt EM *et al.* (2011) Radiologic and intraoperative detection of need for mesenteric vein resection in patients with adenocarcinoma of the head of the pancreas. *HPB* 13:633–642.
- Shen YN, Bai XL, Li GG, Liang TB. (2017) Review of radiological classifications of pancreatic cancer with peripancreatic vessel invasion: are new grading criteria required? *Canc Imag* 17:14.
- Giovinazzo F, Turri G, Katz MH, Heaton N, Ahmed I. (2016) Meta-analysis of benefits of portal-superior mesenteric vein resection in pancreatic resection for ductal adenocarcinoma. *Br J Surg* 103: 179–191.
- Buchs NC, Chilcott M, Poletti PA, Buhler LH, Morel P. (2010) Vascular invasion in pancreatic cancer: imaging modalities, preoperative diagnosis and surgical management. *World J Gastroenterol* 16:818–831.
- Ferrone CR, Marchegiani G, Hong TS, Ryan DP, Deshpande V, McDonnell EI *et al.* (2015) Radiological and surgical implications of neoadjuvant treatment with FOLFIRINOX for locally advanced and borderline resectable pancreatic cancer. *Ann Surg* 261:12–17.
- White RR, Paulson EK, Freed KS, Keogan MT, Hurwitz HI, Lee C *et al.* (2001) Staging of pancreatic cancer before and after neoadjuvant chemoradiation. *J Gastrointest Surg* 5:626–633.
- Hirota M, Kanemitsu K, Takamori H, Chikamoto A, Tanaka H, Sugita H *et al.* (2010) Pancreatoduodenectomy using a no-touch isolation technique. *Am J Surg* 199:e65–e68.
- Turrini O, Ewald J, Barbier L, Mokart D, Blache JL, Delpero JR. (2013) Should the portal vein be routinely resected during pancreaticoduodenectomy for adenocarcinoma? *Ann Surg* 257:726–730.
- Morelli L, Berchiolli R, Guadagni S, Palmeri M, Furbetta N, Gianardi D *et al.* (2018) Pancreatoduodenectomy without vascular resection in patients with primary resectable Adenocarcinoma and unilateral venous contact: a matched case study. *Gastroenterol Res Pract* 2018:1081494.
- Vogel JA, Rombouts SJ, de Rooij T, van Delden OM, Dijkgraaf MG, van Gulik TM *et al.* (2017) Induction chemotherapy followed by resection or irreversible electroporation in locally advanced pancreatic cancer (IMPALA): a prospective cohort study. *Ann Surg Oncol* 24:2734–2743.
- van Veldhuisen E, Walma MS, van Rijssen LB, Busch OR, Bruijnen RCG, van Delden OM *et al.* (2019 Oct) Added value of intra-operative ultrasound to determine the resectability of locally advanced pancreatic cancer following FOLFIRINOX chemotherapy (IMAGE): a prospective multicenter study. *HPB* 21:1385–1392. <https://doi.org/10.1016/j.hpb.2019.02.017>. Epub 2019 Apr 19.
- Sibinga Mulder BG, Feshtali S, Farina Sarasqueta A, Vahrmeijer AL, Swijnenburg RJ, Bonsing BA *et al.* (2019) A prospective clinical trial to determine the effect of intraoperative ultrasound on surgical strategy and resection outcome in patients with pancreatic cancer. *Ultrasound Med Biol* 45:2019–2026.
- Dua MM, Tran TB, Klausner J, Hwa KJ, Poultsides GA, Norton JA *et al.* (2015) Pancreatectomy with vein reconstruction: technique matters. *HPB* 17:824–831.
- Kleive D, Berstad AE, Sahakyan MA, Verbeke CS, Naper C, Haugvik SP *et al.* (2018) Portal vein reconstruction using primary anastomosis or venous interposition allograft in pancreatic surgery. *J Vasc Surg Venous Lymphat Disord* 6:66–74.
- Kleive D, Berstad AE, Verbeke CS, Haugvik SP, Gladhaug IP, Line PD *et al.* (2016) Cold-stored cadaveric venous allograft for superior mesenteric/portal vein reconstruction during pancreatic surgery. *HPB* 18:615–622.
- Ravikumar R, Sabin C, Abu Hilal M, Al-Hilli A, Aroori S, Bond-Smith G *et al.* (2017) Impact of portal vein infiltration and type of venous reconstruction in surgery for borderline resectable pancreatic cancer. *Br J Surg* 104:1539–1548.
- Chandrasegaram MD, Eslick GD, Lee W, Brooke-Smith ME, Padbury R, Worthley CS *et al.* (2014) Anticoagulation policy after venous resection with a pancreatectomy: a systematic review. *HPB* 16:691–698.
- Fukuda S, Oussoultzoglou E, Bachellier P, Rosso E, Nakano H, Audet M *et al.* (2007) Significance of the depth of portal vein wall invasion after curative resection for pancreatic adenocarcinoma. *Arch Surg* 142: 172–179. discussion 80.
- Roch AM, House MG, Cioffi J, Ceppa EP, Zyromski NJ, Nakeeb A *et al.* (2016) Significance of portal vein invasion and extent of invasion in patients undergoing pancreatoduodenectomy for pancreatic adenocarcinoma. *J Gastrointest Surg* 20:479–487. discussion 87.
- Soer E, Brosens L, van de Vijver M, Dijk F, van Velthuysen ML, Farina-Sarasqueta A *et al.* (2018) Dilemmas for the pathologist in the oncologic assessment of pancreatoduodenectomy specimens: an overview of different grossing approaches and the relevance of the histopathological characteristics in the oncologic assessment of pancreatoduodenectomy specimens. *Virchows Arch – Int J Pathol* 472:533–543.
- Boggi U, Del Chiaro M, Croce C, Vistoli F, Signori S, Moretto C *et al.* (2009) Prognostic implications of tumor invasion or adhesion to peripancreatic vessels in resected pancreatic cancer. *Surgery* 146: 869–881.
- Kauffmann EF, Napoli N, Menonna F, Vistoli F, Amorese G, Campani D *et al.* (2016) Robotic pancreatoduodenectomy with vascular resection. *Langenbeck's Arch Surg* 401:1111–1122.
- Kleive D, Labori KJ, Line PD, Gladhaug IP, Verbeke CS. (2020 Jan) Pancreatoduodenectomy with venous resection for ductal

- adenocarcinoma rarely achieves complete (R0) resection. *HPB* 22: 50–57. <https://doi.org/10.1016/j.hpb.2019.05.005>. Epub 2019 Jun 8.
29. Chandrasegaram MD, Goldstein D, Simes J, GebSKI V, Kench JG, Gill AJ *et al.* (2015) Meta-analysis of radical resection rates and margin assessment in pancreatic cancer. *Br J Surg* 102:1459–1472.
 30. Eysenbach G. (2004) Improving the quality of web surveys: the checklist for reporting results of Internet E-surveys (CHERRIES). *J Med Internet Res* 6:e34.
 31. Versteijne E, Vogel JA, Besselink MG, Busch ORC, Wilmink JW, Daams JG *et al.* (2018 Jul) Meta-analysis comparing upfront surgery with neoadjuvant treatment in patients with resectable or borderline resectable pancreatic cancer. *Br J Surg* 105(8):946–958. <https://doi.org/10.1002/bjs.10870>. Epub 2018 Apr 30, Review.
 32. Warner SG, Alseidi AA, Hong J, Pawlik TM, Minter RM. (2015) What to expect when you're expecting a hepatopancreatobiliary surgeon: self-reported experiences of HPB surgeons from different training pathways. *HPB* 17:785–790.
 33. Hoogstins CES, Boogerd LSF, Sibinga Mulder BG, Mieog JSD, Swijnenburg RJ, van de Velde CJH *et al.* (2018) Image-guided surgery in patients with pancreatic cancer: first results of a clinical trial using SGM-101, a novel carcinoembryonic antigen-targeting, near-infrared fluorescent agent. *Ann Surg Oncol* 25:3350–3357.
 34. Ishikawa O, Ohigashi H, Sasaki Y, Nakano H, Furukawa H, Imaoka S *et al.* (1998) Intraoperative cytodiagnosis for detecting a minute invasion of the portal vein during pancreatoduodenectomy for adenocarcinoma of the pancreatic head. *Am J Surg* 175:477–481.
 35. Tummers WS, Miller SE, Teraphongphom NT, Gomez A, Steinberg I, Huland DM *et al.* (2018) Intraoperative pancreatic cancer detection using tumor-specific multimodality molecular imaging. *Ann Surg Oncol* 25:1880–1888.
 36. Kleive D, Sahakyan MA, Berstad AE, Verbeke CS, Gladhaug IP, Edwin B *et al.* (2017) Trends in indications, complications and outcomes for venous resection during pancreatoduodenectomy. *Br J Surg* 104: 1558–1567.
 37. van Roessel S, Mackay TM, Tol J, van Delden OM, van Lienden KP, Nio CY *et al.* (2019) Impact of expanding indications on surgical and oncological outcome in 1434 consecutive pancreatoduodenectomies. *HPB* 21:865–875.
 38. Womi M, Castleberry AW, Clary BM, Gloor B, Carvalho E, Jacobs DO *et al.* (2013) Concomitant vascular reconstruction during pancreatotomy for malignant disease: a propensity score-adjusted, population-based trend analysis involving 10,206 patients. *JAMA Surg* 148: 331–338.
 39. Stauffer JA, Dougherty MK, Kim GP, Nguyen JH. (2009) Interposition graft with polytetrafluoroethylene for mesenteric and portal vein reconstruction after pancreatoduodenectomy. *Br J Surg* 96:247–252.
 40. Kantor O, Talamonti MS, Wang CH, Roggin KK, Bentrem DJ, Winchester DJ *et al.* (2018) The extent of vascular resection is associated with perioperative outcome in patients undergoing pancreatoduodenectomy. *HPB* 20:140–146.
 41. Clark W, Silva M, Donn N, Luberic K, Humphries LA, Paul H *et al.* (2012) Targeting early deaths following pancreatoduodenectomy to improve survival. *J Gastrointest Surg* 16:1869–1874.
 42. Zyromski NJ, Howard TJ. (2008) Acute superior mesenteric-portal vein thrombosis after pancreatoduodenectomy: treatment by operative thrombectomy. *Surgery* 143:566–567.
 43. Alemi F, Rocha FG, Helton WS, Biehl T, Alseidi A. (2016) Classification and techniques of en bloc venous reconstruction for pancreatoduodenectomy. *HPB* 18:827–834.
 44. Hanna-Sawires RG, Groen JV, Klok FA, Tollenaar R, Mesker WE, Swijnenburg RJ *et al.* (2019) Outcomes following pancreatic surgery using three different thromboprophylaxis regimens. *Br J Surg* 106: 765–773.
 45. Adsay NV, Basturk O, Saka B, Bagci P, Ozdemir D, Balci S *et al.* (2014) Whipple made simple for surgical pathologists: orientation, dissection, and sampling of pancreatoduodenectomy specimens for a more practical and accurate evaluation of pancreatic, distal common bile duct, and ampullary tumors. *Am J Surg Pathol* 38:480–493.
 46. Campbell F, Cairns A, Duthie F, Feakins R. Dataset for the histopathological reporting of carcinomas of the pancreas, ampulla of Vater and common bile duct. Available at: www.rcpath.org. [Accessed 3 October 2019].
 47. Gebauer F, Tachezy M, Vashist YK, Marx AH, Yekebas E, Izbicki JR *et al.* (2015) Resection margin clearance in pancreatic cancer after implementation of the Leeds Pathology Protocol (LEPP): clinically relevant or just academic? *World J Surg* 39:493–499.
 48. Verbeke CS, Leitch D, Menon KV, McMahon MJ, Guillou PJ, Anthony A. (2006) Redefining the R1 resection in pancreatic cancer. *Br J Surg* 93:1232–1237.

Appendix A. Supplementary data

Supplementary data to this article can be found online at <https://doi.org/10.1016/j.hpb.2020.04.015>.