

Circulation

JOURNAL OF THE AMERICAN HEART ASSOCIATION



Clinical, Angiographic, and Procedural Predictors of Angiographic Restenosis After Sirolimus-Eluting Stent Implantation in Complex Patients: An Evaluation From the Rapamycin-Eluting Stent Evaluated At Rotterdam Cardiology Hospital (RESEARCH) Study

Pedro A. Lemos, Angela Hoye, Dick Goedhart, Chourmouziou A. Arampatzis, Francesco Saia, Willem J. van der Giessen, Eugene McFadden, Georgios Sianos, Pieter C. Smits, Sjoerd H. Hofma, Pim J. de Feyter, Ron T. van Domburg and Patrick W. Serruys

Circulation 2004;109:1366-1370; originally published online Mar 1, 2004;
DOI: 10.1161/01.CIR.0000121358.26097.06

Circulation is published by the American Heart Association, 7272 Greenville Avenue, Dallas, TX 75214

Copyright © 2004 American Heart Association. All rights reserved. Print ISSN: 0009-7322. Online ISSN: 1524-4539

The online version of this article, along with updated information and services, is located on the World Wide Web at:

<http://circ.ahajournals.org/cgi/content/full/109/11/1366>

Subscriptions: Information about subscribing to *Circulation* is online at
<http://circ.ahajournals.org/subscriptions/>

Permissions: Permissions & Rights Desk, Lippincott Williams & Wilkins, 351 West Camden Street, Baltimore, MD 21202-2436. Phone 410-5280-4050. Fax: 410-528-8550. Email:
journalpermissions@lww.com

Reprints: Information about reprints can be found online at
<http://www.lww.com/static/html/reprints.html>

Clinical, Angiographic, and Procedural Predictors of Angiographic Restenosis After Sirolimus-Eluting Stent Implantation in Complex Patients

An Evaluation From the Rapamycin-Eluting Stent Evaluated At Rotterdam Cardiology Hospital (RESEARCH) Study

Pedro A. Lemos, MD; Angela Hoye, MB ChB, MRCP; Dick Goedhart; Chourmouzos A. Arampatzis, MD; Francesco Saia, MD; Willem J. van der Giessen, MD, PhD; Eugene McFadden, MB ChB, FRCPI; Georgios Sianos, MD; Pieter C. Smits, MD; Sjoerd H. Hofma, MD; Pim J. de Feyter, MD, PhD; Ron T. van Domburg, PhD; Patrick W. Serruys, MD, PhD

Background—The factors associated with the occurrence of restenosis after sirolimus-eluting stent (SES) implantation in complex cases are currently unknown.

Methods and Results—A cohort of consecutive complex patients treated with SES implantation was selected according to the following criteria: (1) treatment of acute myocardial infarction, (2) treatment of in-stent restenosis, (3) 2.25-mm diameter SES, (4) left main coronary stenting, (5) chronic total occlusion, (6) stented segment >36 mm, and (7) bifurcation stenting. The present study population was composed of 238 patients (441 lesions) for whom 6-month angiographic follow-up data were obtained (70% of eligible patients). Significant clinical, angiographic, and procedural predictors of post-SES restenosis were evaluated. Binary in-segment restenosis was diagnosed in 7.9% of lesions (6.3% in-stent, 0.9% at the proximal edge, 0.7% at the distal edge). The following characteristics were identified as independent multivariate predictors: treatment of in-stent restenosis (OR 4.16, 95% CI 1.63 to 11.01; $P<0.01$), ostial location (OR 4.84, 95% CI 1.81 to 12.07; $P<0.01$), diabetes (OR 2.63, 95% CI 1.14 to 6.31; $P=0.02$), total stented length (per 10-mm increase; OR 1.42, 95% CI 1.21 to 1.68; $P<0.01$), reference diameter (per 1.0-mm increase; OR 0.46, 95% CI 0.24 to 0.87; $P=0.03$), and left anterior descending artery (OR 0.30, 95% CI 0.10 to 0.69; $P<0.01$).

Conclusions—Angiographic restenosis after SES implantation in complex patients is an infrequent event, occurring mainly in association with lesion-based characteristics and diabetes mellitus. (*Circulation*. 2004;109:1366-1370.)

Key Words: stents ■ angioplasty ■ revascularization ■ restenosis

In-stent restenosis is the major limitation hampering the medium-term efficacy of coronary stenting. Several reports have evaluated the impact of baseline and procedural characteristics on the risk of subsequent restenosis after bare metal stent implantation, with a number of high-risk parameters, such as diabetes, lesion length, and vessel size, being consistently identified in most studies.¹⁻⁷ Unfortunately, these characteristics are commonly found in the daily practice, where treatment of complex patients frequently appears as a challenging therapeutic dilemma.

Sirolimus-eluting stents (SESs) have been proven to strikingly decrease neointimal growth, leading to a marked reduction in restenosis rates.⁸⁻¹⁰ In the RAndomized study with the sirolimus-eluting Bx VELOCITY balloon-expandable stent in the treatment of patients with de novo native coronary

artery Lesions (RAVEL),⁸ no cases of binary angiographic restenosis were seen after SES implantation. Moreover, restenosis was significantly reduced from 36.3% with conventional stents to 8.9% with SESs in the randomized SIRoImUS-eluting Bx velocity balloon expandable stent trial (SIRIUS)⁹ and from 42.3% to 5.9% in the E-SIRIUS trial,¹⁰ with diabetes, small vessel size, and long lesions being identified as predictors of post-SES restenosis in the SIRIUS trial.⁹ Nevertheless, these randomized studies have been largely restricted to selected patients treated with single-lesion elective stenting. The factors related to angiographic restenosis after SES implantation in highly complex subsets are currently unknown.

SES implantation was recently shown to effectively improve the 1-year clinical outcomes in “real world” practice in

Received October 14, 2003; revision received December 17, 2003; accepted December 30, 2003.

From Erasmus Medical Center (P.A.L., A.H., C.A.A., F.S., W.J.v.d.G., E.M., G.S., P.C.S., S.H.H., P.J.d.F., R.T.v.D., P.W.S.), Thoraxcenter, and Cardialysis BV (D.G.), Statistical Department, Rotterdam, The Netherlands.

Correspondence to Patrick W. Serruys, MD, PhD, Department of Cardiology, Thoraxcenter, Room Bd 408, Erasmus Medical Center Rotterdam, Dr Molewaterplein 40, 3015 GD Rotterdam, The Netherlands. E-mail p.w.j.c.serruys@erasmusmc.nl

© 2004 American Heart Association, Inc.

Circulation is available at <http://www.circulationaha.org>

DOI: 10.1161/01.CIR.0000121358.26097.06

patients enrolled in the Rapamycin-Eluting Stent Evaluated At Rotterdam Cardiology Hospital (RESEARCH) study.¹¹ In the RESEARCH study, a parallel angiographic substudy was conducted to evaluate the late angiographic findings of complex patients treated with SESs. The present report aimed to evaluate the value of clinical, angiographic, and procedural factors in predicting the risk of binary restenosis in highly complex patients treated with SES implantation in the RESEARCH study.

Methods

Study Design and Patient Population

The design of the RESEARCH study has been reported previously.¹¹ In brief, SES implantation (Cypher; Johnson & Johnson-Cordis unit, Cordis Europa NV) was introduced as the default strategy for all patients undergoing percutaneous coronary interventions in our institution after April 2002. All procedures were performed according to standard techniques, and the final interventional strategy was left to the discretion of the operator, with the aim of achieving a final residual stenosis <50% by online quantitative coronary angiography in the presence of TIMI (Thrombolysis In Myocardial Infarction) 3 grade flow. The use of periprocedural glycoprotein IIb/IIIa inhibitors and antithrombotic medications was left entirely to the discretion of the attending team.

Patients receiving SESs were considered candidates for angiographic reevaluation if they had at least 1 of the following characteristics: (1) treatment of acute myocardial infarction, (2) treatment of in-stent restenosis, (3) use of a very small SES (2.25-mm nominal diameter), (4) treatment of left main coronary, (5) treatment of chronic total occlusion (>3 months), (6) total adjacent stented segment longer than 36 mm, and (7) bifurcation stenting (SES implanted in both the main vessel and the side branch). Patients with the aforementioned characteristics who had not undergone repeat intervention in the first month and had not presented any formal medical contraindication for angiographic restudy were considered eligible for angiographic follow-up at 6 to 8 months. Coronary angiograms performed prematurely because of clinical indications were used as the follow-up angiography if performed after 4 months or if restenosis was detected. In other cases, a second angiogram was obtained between 6 and 8 months. Importantly, although all patients were approached for angiographic follow-up, patient refusal was not considered as an exclusion criterion to be enrolled in the RESEARCH study. Angiographic restudy was not requested for non-residents of the Netherlands.

During the first 6 months of enrollment, a total of 362 consecutive patients had at least 1 of the high-risk criteria listed above (57% of all patients treated with SESs in the period). Of these, 2 patients moved to another country, 10 had died within the first 6 months of follow-up, 6 had repeat intervention before 30 days (surgical or percutaneous), and 3 were considered to have a medical contraindication to the angiographic follow-up (1 patient with previous stroke and disabling dementia, 1 with severe allergic contrast reaction at the index procedure, and 1 with end-stage hepatic failure due to autoimmune hepatitis). Of the remaining 341 patients, angiographic reevaluation at 204±34 days was obtained for 238 patients (70% of eligible patients), who compose the present study population.

Quantitative Coronary Angiography

Quantitative coronary angiographic analysis was performed as described previously with a validated computer-based edge-detection system (CASS II, Pie Medical).¹² Interpolated reference diameter, minimal luminal diameter, and diameter stenosis were obtained at baseline, after stenting, and at follow-up. In-stent restenosis was defined by diameter stenosis >50% and was classified as in-stent if inside the stent or in-segment if located within the stented segment plus the 5-mm segments distal or proximal to the stent margins.⁹ Restenosis at an ostial location (within 3 mm of the vessel origin)

TABLE 1. Clinical Characteristics of 238 Patients Treated With SES Implantation

Characteristic	No.
Male gender	73
Age, y	60±12
Height, cm	172±9
Weight, kg	82±14
Hypercholesterolemia*	58
Hypertension	56
Diabetes mellitus	22
Insulin-dependent diabetes	6
Non-insulin-dependent diabetes	16
Previous myocardial infarction	32
Previous bypass surgery	11
Previous percutaneous intervention	28
Vessel disease	
1-vessel disease	40
2-vessel disease	35
3-vessel disease	25
Clinical presentation	
Stable angina	54
Unstable angina	21
Acute myocardial infarction	26
Periprocedural IIb/IIIa inhibitor	27

Values are percentages or mean±SD.

*Total cholesterol >200 mg/dL or receiving lipid-lowering treatment.

was classified as in-stent unless clearly located outside the limits of the SES.¹³

Statistical Analysis

Continuous variables are presented as mean±SD and were compared with Student's unpaired *t* test. Categorical variables are presented as counts and percentages and compared with the Fisher exact test. Demographic, clinical, procedural, and angiographic variables were tested in univariate and multivariate logistic analyses for their value in predicting binary restenosis. All variables shown in Tables 1 and 2 were considered in multivariate logistic regression analyses regardless of their univariate findings. The final model was built iteratively and evaluated for lack of fit with the Hosmer-Lemeshow test. Global predictive accuracy was assessed by means of the C-index (area under the receiver operating characteristic curve). Finally, an internal validation was performed with a bootstrap technique.¹⁴ The model was repeatedly applied to 1000 replicated bootstrap samples, and the C-index for each individual sample was calculated. The C-index obtained from each bootstrap sample was then subtracted from the initial C-index value of the original population. The average of the differences was considered as a measure of optimism in the model fit. Finally, a corrected C-index was calculated by subtracting the average of the optimism estimates from the original C-index. The bootstrap correction has been described as a nearly unbiased internal validation, which penalizes for any model overfitting.¹⁴ Presented 95% CIs of all multivariate estimates were derived from the bootstrap analysis.

Results

Among the 238 patients (441 lesions) included in this analysis, 13 (6%) had left main coronary stenting, 35 (15%) had at least 1 chronic total occlusion, 45 (19%) received sirolimus stents to treat at least 1 restenotic lesion, 50 (21%)

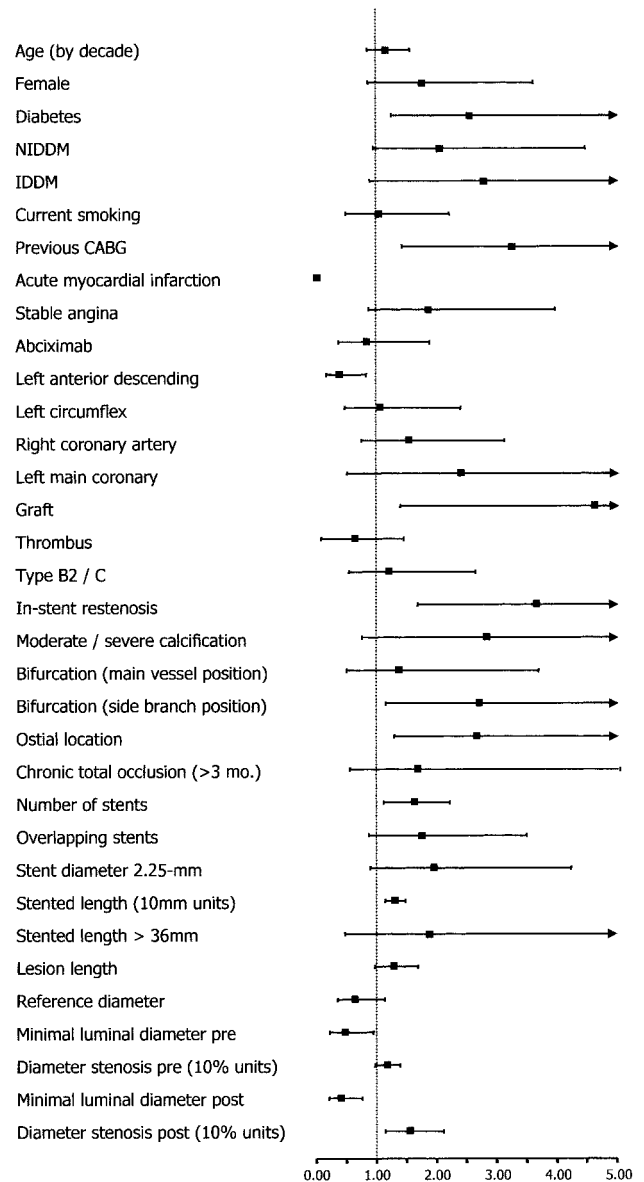
TABLE 2. Procedural and Angiographic Characteristics of 441 Lesions Treated With SES Implantation

Characteristic	No.
Treated vessel	
Left main coronary	3
Left anterior descending	43
Left circumflex artery	22
Right coronary artery	30
Bypass graft	3
Lesion type	
A	6
B1	23
B2	43
C	28
Chronic total occlusion >3 months	8
Moderate/severe angiographic calcification	7
Ostial location	22
Bifurcation treatment*	22
Treatment of in-stent restenosis	13
No. of stents implanted	1.41±0.81
Overlapping stents	39
Total stented length, mm	26.0±20.3
Stented length >36 mm	17
Use of 2.25-mm SES	18
Reference diameter, mm	2.50±0.61
Preprocedure minimal luminal diameter, mm	0.69±0.54
Preprocedure diameter stenosis, %	72.2±20.0
Lesion length, mm	16.1±11.8
Postprocedure minimal luminal diameter, mm	2.13±0.58
Postprocedure diameter stenosis, %	17.2±11.1
Follow-up minimal luminal diameter, mm	2.10±0.69
Follow-up diameter stenosis, %	22.8±19.9
Late loss, mm	0.04±0.49
Binary restenosis	7.9
In-stent	6.3
Proximal edge	0.9
Distal edge	0.7

Values are percentages or mean±SD.

*SES implantation in both the main vessel and the side branch.

had bifurcation stenting, 62 (26%) were in the acute phase of a myocardial infarction, 68 (28%) had at least one 2.25-mm SES implanted, and 83 (35%) had very long stenting (>36 mm) in at least 1 vessel (Tables 1 and 2). On average, 1.41±0.81 stents were implanted per lesion, and 39% of lesions had at least 2 stents that overlapped. Most lesions were classified as American College of Cardiology/American Heart Association type B2 or C (71%); 22% received bifurcation stenting (stent implanted in both the main vessel and the side branch); 8% were chronic total occlusions (duration >3 months); and 3% were located in the left main coronary. Mean vessel size was 2.50±0.61 mm (range 1.00 to 4.59 mm), and the average stented length was 26.0±20.3 mm (range 8 to 117 mm).



Univariate OR of binary angiographic in-segment restenosis after SES restenosis according to demographic, clinical, procedural, and angiographic characteristics. NIDDM indicates non-insulin-dependent diabetes mellitus; IDDM, insulin-dependent diabetes mellitus; pre, preprocedure; and post, postprocedure.

At the follow-up angiogram, 7.9% of lesions had binary in-segment restenosis. Of these, 6.3% were located inside the stent (in-stent), 0.9% were located in the proximal edge, and the remaining 0.7% occurred at the distal edge. Because of the limited number of lesions with edge restenosis (7 observations), additional analyses were performed for all lesions grouped as in-segment restenosis.

The Figure shows the univariate relationship between demographic, angiographic, and procedural characteristics and the incidence of post-SES restenosis, and significant univariate parameters are shown in Table 3. In the multivariate analysis, the following variables were identified as independent predictors of restenosis: treatment of in-stent restenosis, ostial location, presence of diabetes mellitus, total

TABLE 3. Clinical, Procedural, and Angiographic Univariate Predictors of In-Segment Restenosis After SES Restenosis

	OR	95% CI	P
Bypass graft	4.61	1.39–15.33	0.01
Treatment of in-stent restenosis	3.66	1.68–7.96	<0.01
Previous bypass surgery	3.24	1.42–7.41	<0.01
Bifurcation stenting (side branch position)	2.77	1.15–6.33	0.02
Ostial location	2.66	1.30–5.46	<0.01
Diabetes mellitus	2.54	1.24–5.21	0.01
No. of stents implanted	1.62	1.19–2.22	<0.01
Postprocedure diameter stenosis (per 10% increase)	1.55	1.14–2.10	<0.01
Total stented length (per 10-mm increase)	1.30	1.14–1.48	<0.01
Preprocedure minimal luminal diameter	0.46	0.22–0.95	0.04
Postprocedure minimal luminal diameter	0.39	0.20–0.76	<0.01
Left anterior descending artery	0.37	0.16–0.82	0.02
Acute myocardial infarction	0	...	<0.01

stented length, reference diameter, and left anterior descending artery location (Table 4). The final multivariate model fit the data well (Hosmer-Lemeshow test $P=0.94$; $\chi^2=2.93$; $df=8$) and had a good predictive accuracy (C-index 0.83), which was virtually unchanged after the bootstrap correction (corrected C-index 0.82). Actual restenosis rates for patients with “high-risk” characteristics (derived from the multivariate model) are shown in Table 5.

Discussion

The present study reported on the predictors of angiographic restenosis after SES implantation in complex patients. Overall, our series included patients with smaller vessels and longer lesions than in other trials conducted to date.^{8–10} Moreover, a considerable proportion of patients had previous in-stent restenosis, bifurcation stenting, chronic total occlusions, thrombus-containing lesions, and calcified vessels, conditions that were formally excluded from previous trials. Nevertheless, binary restenosis after SES implantation in such a complex patient population was detected in only a minority of cases (7.9% of lesions). The expected restenosis rate for de novo lesions included in the present report would range from 40.1% to 43.0% if treated with bare metal stents, as calculated from prediction equations derived from previous meta-analysis with conventional stents.^{3,6}

TABLE 4. Clinical, Procedural, and Angiographic Multivariate Predictors of In-Segment Restenosis After SES Restenosis*

	OR	95% CI	P
Treatment of in-stent restenosis	4.16	1.63–11.01	<0.01
Ostial location	4.84	1.81–12.07	<0.01
Diabetes mellitus	2.63	1.14–6.31	0.02
Total stented length (per 10-mm increase)	1.42	1.21–1.68	<0.01
Reference diameter (per 1.0-mm increase)	0.46	0.24–0.87	0.03
Left anterior descending artery	0.30	0.10–0.69	<0.01

*Intercept coefficient, -2.34 .

TABLE 5. Actual Rates of Post-SES In-Segment Restenosis According to the Presence of High-Risk Characteristics*

	In-Segment Restenosis Rate, %
Treatment of in-stent restenosis	19.6
Ostial location	14.7
Diabetes mellitus	14.3
Stented length >26 mm†	13.9
Reference diameter <2.17 mm‡	10.3
Non-LAD location	10.8

LAD indicates left anterior descending artery.

*Presence of multivariate independent predictors.

†Higher tercile for stented length.

‡Lower tercile for reference diameter.

In the SIRIUS trial, small vessel size, long lesion length, and diabetes were shown to significantly increase the incidence of restenosis after SES.⁹ These characteristics were confirmed as predictors of post-SES restenosis in the present study, which additionally extended the list of independent parameters to include ostial location and treatment of in-stent restenosis (as negative factors) and left anterior descending artery location (as a protective factor). Interestingly, most characteristics identified as predictors of post-SES restenosis have long been recognized as major predictors of restenosis after balloon angioplasty or conventional bare stent implantation.^{1–7,15–17} It seems intuitive to assume that the increased incidence of restenosis after SES implantation in patients with these risk factors may reflect an extreme background tendency to tissue reaction and neointimal growth, which was not sufficiently inhibited by the antiproliferative action of the drug.

Restenosis after SES has been shown to be associated with incomplete lesion coverage in some cases, as detected by intravascular ultrasound.¹³ In the present study, lesions involving ostial sites had a higher risk of restenosis, which may be related, at least in part, to technical difficulties in stent positioning and vessel scaffolding at the ostium. We may speculate that the presence of “traditional” risk factors for restenosis may potentially act as a predisposing factor that will lead to restenosis in case a subtle device-related or procedure-related local failure is eventually superimposed. Unfortunately, small gaps between stents and minor ruptures in the metallic stent mesh or in the polymer integrity are not detectable by conventional coronary angiography¹³ and could not be evaluated in the present report.

The treatment of in-stent restenosis with SES was associated with a more than 4-fold increase in the risk of restenosis after adjustment for other independent variables. Although SES implantation has been associated with low rates of repeat restenosis after treatment of noncomplex in-stent restenosis,^{18,19} the efficacy of this device for more complicated cases remains to be established.^{20,21} Redilation of restenotic lesions (ie, exposure to “double injury”) has been shown to trigger a peculiar local vascular response, distinct from that observed after the first dilation.²² Modifications in the reparative mechanisms, especially after endovascular brachytherapy,²⁰ may decrease the responsiveness of restenotic lesions to the antiproliferative drug.

Curiously, lesions located in the left anterior descending artery had a decreased restenosis rate in the present series. Whether this factor represents a true protective characteristic has to be further investigated in future studies. Although post-SES restenosis was not detected in any patient admitted with acute myocardial infarction, this characteristic was not included in our final multivariate model, which suggests that perhaps acute myocardial infarction at admission per se was not an important factor affecting restenosis in the present study population. Post-SES restenosis in the present study was almost entirely restricted to the segment inside the stent ($\approx 80\%$ of restenoses). This finding represents a major difference from previous trials with SES, in which restenosis more frequently occurred at the stent edges.^{9,10} In the RESEARCH study, all operators were strongly advised to actively cover the entire injured vessel area and to avoid both residual dissection at stent borders and gaps between stents. In addition, the stent placement strategy aimed to cover the treated segment "from healthy tissue to healthy tissue," to avoid having the free borders of the stents terminate in grossly diseased segments. However, it remains speculative whether these procedural strategies might have had any impact in reducing the incidence of restenosis at the stent edges.

Study Limitations

The present report may suffer from its relatively limited study population, which was restricted to complex patients who fulfilled predefined criteria to be included in this angiographic substudy. Therefore, our results cannot be directly extrapolated to the entire cohort of consecutive patients treated in the RESEARCH study, and further analyses are needed to fully assess the angiographic outcomes of subsets not included in the present study. Ten patients with early death could not be restudied at 6 months, and a higher rate of angiographic follow-up ($\approx 70\%$ in this study) would be desirable for a comprehensive evaluation. However, the present study was designed to enroll all unselected patients treated in our institution, and patient refusal for angiographic follow-up did not preclude enrollment in the RESEARCH study. Obviously, this real-life scenario differs substantially from that of randomized trials and limits the compliance to angiographic restudy.

Conclusions

Angiographic restenosis after SES implantation in complex patients is an infrequent event (7.9% of lesions), occurring mainly in association with local, lesion-based characteristics and diabetes mellitus.

Acknowledgments

This study was supported with healthcare funds allotted by the Erasmus Medical Center, University Medical Center Rotterdam, Rotterdam, the Netherlands, and with an institutional grant from Cordis, a Johnson & Johnson Company, Miami Lakes, Fla.

References

- Kastrati A, Schomig A, Elezi S, et al. Predictive factors of restenosis after coronary stent placement. *J Am Coll Cardiol*. 1997;30:1428–1436.
- Bauters C, Hubert E, Prat A, et al. Predictors of restenosis after coronary stent implantation. *J Am Coll Cardiol*. 1998;31:1291–1298.
- Ho KKL, Senerchia C, Rodriguez O, et al. Predictors of angiographic restenosis after stenting: pooled analysis of 1197 patient with protocol-mandated angiographic follow-up from 5 randomized stent trials. *Circulation*. 1998;98(suppl I):I-362. Abstract.
- Serruys PW, Kay IP, Disco C, et al. Periprocedural quantitative coronary angiography after Palmaz-Schatz stent implantation predicts the restenosis rate at six months: results of a meta-analysis of the BELgian Netherlands Stent study (BENESTENT) I, BENESTENT II Pilot, BENESTENT II and MUSIC trials: Multicenter Ultrasound Stent In Coronaries. *J Am Coll Cardiol*. 1999;34:1067–1074.
- de Feyter PJ, Kay P, Disco C, et al. Reference chart derived from post-stent-implantation intravascular ultrasound predictors of 6-month expected restenosis on quantitative coronary angiography. *Circulation*. 1999;100:1777–1783.
- Mercado N, Boersma E, Wijns W, et al. Clinical and quantitative coronary angiographic predictors of coronary restenosis: a comparative analysis from the balloon-to-stent era. *J Am Coll Cardiol*. 2001;38:645–652.
- Hausleiter J, Kastrati A, Mehili J, et al. Predictive factors for early cardiac events and angiographic restenosis after coronary stent placement in small coronary arteries. *J Am Coll Cardiol*. 2002;40:882–889.
- Morice MC, Serruys PW, Sousa JE, et al. A randomized comparison of a sirolimus-eluting stent with a standard stent for coronary revascularization. *N Engl J Med*. 2002;346:1773–1780.
- Moses JW, Leon MB, Popma JJ, et al. Sirolimus-eluting stents versus standard stents in patients with stenosis in a native coronary artery. *N Engl J Med*. 2003;349:1315–1323.
- Schofer J, Schluter M, Gershlick AH, et al. Sirolimus-eluting stents for treatment of patients with long atherosclerotic lesions in small coronary arteries: double-blind, randomised controlled trial (E-SIRIUS). *Lancet*. 2003;362:1093–1099.
- Lemos PA, Serruys PW, van Domburg RT, et al. Unrestricted utilization of sirolimus-eluting stents compared with conventional bare stent implantation in the "real world": the Rapamycin-Eluting Stent Evaluated At Rotterdam Cardiology Hospital (RESEARCH) registry. *Circulation*. 2004;109:190–195.
- Reiber JH, Serruys PW, Kooijman CJ, et al. Assessment of short-, medium-, and long-term variations in arterial dimensions from computer-assisted quantitation of coronary cineangiograms. *Circulation*. 1985;71:280–288.
- Lemos PA, Saia F, Ligthart JM, et al. Coronary restenosis after sirolimus-eluting stent implantation: morphological description and mechanistic analysis from a consecutive series of cases. *Circulation*. 2003;108:257–260.
- Harrell FE Jr, Lee KL, Mark DB. Multivariable prognostic models: issues in developing models, evaluating assumptions and adequacy, and measuring and reducing errors. *Stat Med*. 1996;15:361–387.
- Elezi S, Kastrati A, Neumann FJ, et al. Vessel size and long-term outcome after coronary stent placement. *Circulation*. 1998;98:1875–1880.
- Elezi S, Kastrati A, Pache J, et al. Diabetes mellitus and the clinical and angiographic outcome after coronary stent placement. *J Am Coll Cardiol*. 1998;32:1866–1873.
- Briguori C, Sarais C, Pagnotta P, et al. In-stent restenosis in small coronary arteries: impact of strut thickness. *J Am Coll Cardiol*. 2002;40:403–409.
- Sousa JE, Costa MA, Abizaid A, et al. Sirolimus-eluting stent for the treatment of in-stent restenosis: a quantitative coronary angiography and three-dimensional intravascular ultrasound study. *Circulation*. 2003;107:24–27.
- Degertekin M, Lemos PA, Lee CH, et al. Intravascular ultrasound evaluation after sirolimus eluting stent implantation for de novo and in-stent restenosis lesions. *Eur Heart J*. 2004;25:32–38.
- Saia F, Lemos PA, Sianos G, et al. Effectiveness of sirolimus-eluting stent implantation for recurrent in-stent restenosis after brachytherapy. *Am J Cardiol*. 2003;92:200–203.
- Degertekin M, Regar E, Tanabe K, et al. Sirolimus-eluting stent for treatment of complex in-stent restenosis: the first clinical experience. *J Am Coll Cardiol*. 2003;41:184–189.
- Koyama H, Reidy MA. Reinjury of arterial lesions induces intimal smooth muscle cell replication that is not controlled by fibroblast growth factor 2. *Circ Res*. 1997;80:408–417.