



Review

Cardiovascular disease in non-classic Pompe disease: A systematic review

H.A. van Kooten^a, C.H.A. Roelen^a, E. Brusse^a, N.A.M.E. van der Beek^a, M. Michels^b, A.T. van der Ploeg^c, M.A.E.M. Wagenmakers^d, P.A. van Doorn^{a,*}^aDepartment of Neurology, Center for Lysosomal and Metabolic Diseases, Erasmus MC, University Medical Center Rotterdam, Doctor Molewaterplein 40, 3015 GD Rotterdam, the Netherlands^bDepartment of Cardiology, Erasmus MC, University Medical Center Rotterdam, the Netherlands^cDepartment of Pediatrics, Center for Lysosomal and Metabolic Diseases, Erasmus MC – Sophia Children's Hospital, University Medical Center Rotterdam, the Netherlands^dDepartment of Internal Medicine, Center for Lysosomal and Metabolic Diseases, Erasmus MC, University Medical Center Rotterdam, the Netherlands

Received 14 May 2020; received in revised form 22 October 2020; accepted 23 October 2020

Abstract

Pompe disease is a rare inherited metabolic and neuromuscular disorder, presenting as a spectrum, with the classic infantile form on one end and the more slowly progressive non-classic form on the other end. While being a hallmark in classic infantile Pompe disease, cardiac involvement in non-classic Pompe disease seems rare. Vascular abnormalities, such as aneurysms and arterial dolichoectasia, likely caused by glycogen accumulation in arterial walls, have been reported in non-classic Pompe patients. With this first systematic review on cardiovascular disease in non-classic Pompe disease, we aim to gain insight in the prevalence and etiology of cardiovascular disease in these patients. Forty-eight studies (eight case-control studies, 15 cohort studies and 25 case reports/series) were included. Fourteen studies reported cardiac findings, 25 studies described vascular findings, and nine studies reported both cardiac and vascular findings. Severe cardiac involvement in non-classic Pompe disease patients has rarely been reported, particularly in adult-onset patients carrying the common IVS1 mutation. There are indications that intracranial dolichoectasia and aneurysms are more prevalent in non-classic Pompe patients compared to the general population. To further investigate the prevalence of cardiovascular disease in non-classic Pompe patients, larger case-control studies that also study established cardiovascular risk factors should be conducted.

© 2020 The Authors. Published by Elsevier B.V.

This is an open access article under the CC BY license (<http://creativecommons.org/licenses/by/4.0/>)**Keywords:** Pompe disease; Cardiac involvement; Vascular abnormalities; Cardiovascular risk factors.**1. Introduction**

Pompe disease is an inherited metabolic and neuromuscular disorder. Mutations in the GAA gene lead to deficiency of the enzyme acid α -glucosidase, causing lysosomal glycogen accumulation. This ultimately leads to cell destruction, mainly causing progressive impairment of muscle function [1]. Patients with the classic infantile form of Pompe disease have (virtually) no acid α -glucosidase activity, causing generalized hypotonia, severe hypertrophic cardiomyopathy and respiratory failure. Without treatment, these infants die within the first year of life [2]. In non-

classic or late onset Pompe disease, residual activity of acid α -glucosidase causes a more slowly progressive phenotype, with limb-girdle myopathy and respiratory muscle weakness as the main symptoms [3]. While severe cardiomyopathy is a hallmark of classic infantile Pompe disease, cardiac involvement in non-classic Pompe disease seems rare [4,5]. Vascular abnormalities such as aneurysms, (vertebrobasilar) dolichoectasia and arterial dissections have been reported in several cases of non-classic Pompe patients [4–8]. Pathology studies have shown that glycogen may accumulate in endothelial cells and smooth muscle cells within the media of arterial walls of Pompe patients, and it is hypothesized that these changes cause weakness of the arterial wall [9–13]. Moreover, we have previously found increased aortic stiffness in adults with Pompe disease. This is an independent risk

* Corresponding author.

E-mail address: p.a.vandoorn@erasmusmc.nl (P.A. van Doorn).

factor for cardiovascular disease and stresses the importance of appropriate cardiovascular care in these patients [14,15]. However, cardiovascular disease is also very prevalent among the general population, and literature on cardiovascular disease in non-classic Pompe disease is very diverse, mainly consisting of case reports and relatively small case series [16]. Therefore at present, it is not clear if patients with non-classic Pompe have a higher cardiovascular risk than the general aging population and, if this is the case, if this is caused by Pompe disease itself or a higher prevalence of established cardiovascular risk factors such as physical inactivity or obesity. To our knowledge, this is the first systematic review on cardiovascular disease in non-classic Pompe disease patients. By analyzing the current literature, we aim to gain insight in the prevalence and etiology of cardiovascular disease in non-classic Pompe disease. This potentially could help to formulate diagnostic and monitoring strategies, and improve cardiovascular care to prevent serious morbidity and even mortality in patients with non-classic Pompe disease.

2. Methods

2.1. Search strategy

A systematic search in Embase, Medline Epub (Ovid), Cochrane Central, Web of Science and Google Scholar was performed on February 14, 2018 and updated in November 2019. Keywords of ‘Pompe disease’ (glycogen storage disease type 2, acid maltase deficiency, glycogenosis) and different types of ‘cardiovascular disease’ (cardiac disease, cerebrovascular disease, aneurysm, arrhythmia, stroke) were combined. Studies in animals, conference abstracts and editorials were excluded. The full search strategy is summarized in Appendix 1.

2.2. Selection strategy

All retrieved publications were reviewed by two independent reviewers (HvK and CR). There were two stages in this process. First, the title and abstract of all retrieved publications were screened by both reviewers. Publications primarily reporting on cardiovascular disease were selected, studies on classic or atypical infantile Pompe disease (these patients were not the focus of our study) were excluded. In the second stage, full-text articles of the included publications were assessed for eligibility. Studies with no full-text available or full-text only in languages other than or English were excluded. Review articles were excluded as well. At both stages, discrepancies in selection of publications between the two reviewers were discussed, to reach consensus on in/exclusion. Remaining uncertainties regarding inclusion were discussed with a third reviewer (PD). The remaining publications included after this stage were reviewed in detail. In addition, the reference lists of excluded review articles and all included publications were searched for additional studies not found by our search strategy.

2.3. Data extraction

For the included studies, data was extracted using a data extraction table. Extraction was conducted by both reviewers and again compared, to ensure reliability and accuracy of the extracted information. Based on the clinic(s) where the study was conducted, the possibility that different studies reported on the same cohort of patients was evaluated. We assessed the certainty of the Pompe disease diagnosis based on the techniques mentioned in the article: 1. definite Pompe disease (genetically confirmed), 2. probable Pompe disease (acid α -glucosidase deficiency, combined with muscle biopsy abnormalities, or specific Pompe disease symptoms in combination with treatment with ERT) or 3. possible Pompe disease (no diagnostics mentioned or only results of a muscle biopsy typical for Pompe disease reported).

2.4. Synthesis of results

Due to heterogeneity of the included studies, a meta-analysis could not be performed. Aiming to overcome the variability and extensiveness of the information retrieved, study outcomes were grouped into two key themes: cardiac findings and vascular findings. Cardiac findings were further grouped into electrocardiogram (ECG) findings and findings on transthoracic echocardiogram (TTE) or other imaging. Findings and events related to vascular abnormalities/disease were further divided into six main categories: 1. ectasia/dilatation, 2. aneurysms, 3. stroke, 4. white matter lesions (WML) and microhemorrhages (MH), 5. pathology findings (PA) and 6. other. Vascular ectasias/dilatations and aneurysms were further grouped based on their location: anterior cerebral circulation (anterior or middle cerebral artery), vertebrobasilar circulation (vertebral or basilar artery), carotid arteries (common or internal carotid artery), aorta, iliac artery, renal artery.

3. Results

3.1. Study selection

Our literature search retrieved 1482 studies. Through reference lists of included studies, three additional studies were included. Forty-one studies fulfilled our criteria and were included in the review (Fig. 1). Seven additional studies were included from the updated search in November 2019.

3.2. Characteristics of included studies

The characteristics of the included studies ($n=48$) are summarized in Table 1. Most studies were case reports or case series ($n=25$), eight case control studies and 15 cohort studies were included. Multiple case-control and cohort studies reported on patients from the same cohorts. We considered the diagnosis of Pompe disease definite (genetically confirmed) in 32 studies. Twelve studies were classified as probable Pompe disease (no DNA data

Table 1
Study characteristics.

Author (year)	Patients (N)	Pompe diagnosis*	Diagnostic modality/modalities	Outcome‡
Case-control studies				
Nemes (2007) ^a [20]	17	1	BP, TTE	C, V
Wens (2014) ^a [14]	84	1	BP, cervical US, PWV	V
Fayssol (2014) [19]	10	3	ECG, TTE	C
Hensel (2015) ^b [34]	10	1	brain MRI/MRA, TCD	V
Morris (2015) [18]	12	3	cardiac MRI, ECG, holter ECG, TTE	C
Boentert (2016) [21]	17	1	CMR	C
Hensel (2018) ^b [35]	20	1	brain CT/CTA/MRI/MRA	V
Schneider (2019) ^b [36]	19	1	brain MRI	V
Cohort studies				
Müller-Felber (2007) ^c [26]	38	1	ECG, holter ECG, TTE	C, V
Soliman (2008) ^a [22]	46	1	ECG, TTE	C
Van der Beek (2008) ^a [23]	68	1	ECG, TTE	C
Sacconi (2010) ^d [37]	6	2	brain MRA	V
El-Gharbawy (2011) [83]	40	1	chest CTA/MRA, CXR, TTE	V
Forsha (2011) ^{a,e} [24]	87	1	ECG, TTE	C
Sacconi (2014) [84]	4	1	ECG, holter ECG, TTE	C
Schüller (2012) ^c [27]	44	1	ECG, TTE	C, V
Montagnese (2016) ^f [39]	21	1	brain CT/CTA	V
Van Capelle (2016) ^a [25]	31	1	ECG, TTE	C
Garibaldi (2017) ^d [38]	5	2	brain MRA	V
Pichiecchio (2017) [63]	18	1	brain CT/CTA/MRI/MRA	V
Herbert (2018) ^e [29]	83	1	CXR, ECG, TTE	C
Musumeci (2019) ^f [40]	21	1	brain MRI/MRA, NPP	V
Alandy-Dy (2019) [31]	18	1	NM	C, V
Case reports/case series				
Francesconi (1982) [85]	1	2	ECG, TTE	C
Miyamoto (1985) [86]	2	2	brain CT, PA	V
Braunsdorf (1987) [87]	1	3	brain CT/MRI	V
Makos (1987) [10]	3	2	brain CTA, PA	V
Matsuoka (1988) [88]	1	2	PA	V
Kretzschmar (1990) [9]	1	2	brain CT/MRI, ECG, PA	C, V
Anneser (2005) [89]	1	1	brain CTA/MRI/MRA	V
Brettschneider (2008) [90]	1	1	brain MRI/MRA	V
Laforêt (2008) [91]	3	1	brain CT/CTA/MRI/MRA, cervical US	V
Refai (2008) [55]	1	2	brain CT/MRI, DSA	V
Renard (2010) [92]	1	1	brain MRI/MRA	V
Fernández (2012) [93]	1	1	ECG, TTE	C
Goeber (2013) [94]	1	3	aorta CTA, brain CTA, PA	C, V
Céron-Rodríguez (2014) [95]	1	1	ECG, TTE	C
Peric (2014) [96]	1	1	abdominal US, brain CT/CTA, ECG, TTE	V
Quenardelle (2014) [97]	1	1	brain MRI/MRA, ECG, PA, TTE	V
Sandhu (2014) [98]	1	2	brain CT/MRI/MRA	V
Huded (2016) [99]	2	2	brain CT/MRI, DSA	V
Zhang (2016) [100]	1	1	brain CTA, ECG, TTE	C, V
Kim (2017) [32]	1	1	ECG, TTE	C
Malhotra (2017) [101]	1	2	brain CTA/MRI	V
Mori (2017) [33]	1	2	cardiac MRI, PA, TTE	C, V
Walczak-Galezewska (2017) [102]	1	2	brain MRI, CMR, ECG, TTE	C
Hossain (2018) [103]	1	1	brain CT/MRI, TTE	C, V
Pappa (2018) [104]	1	1	abdominal CT, brain CT/CTA/MRA, renal arteriography	V

* 1: definite Pompe disease (genetically confirmed); 2: probable Pompe disease (enzyme activity combined with muscle biopsy abnormalities or enzyme activity only or specific Pompe symptoms and treatment with ERT); 3: possible Pompe disease (only muscle biopsy abnormalities or no diagnostics mentioned).

‡ C: cardiac; V: vascular.^{a,b,c,d,e,f} studies that (likely) included patients from the same cohort; BP: blood pressure measurement; CMR: cardiovascular magnetic resonance; CT: computed tomography; CTA: computed tomography angiography; CXR: chest X-ray; ECG: electrocardiogram; MRA: magnetic resonance angiography; MRI: magnetic resonance imaging; NM: not mentioned; NPP: neuropsychological profile; PA: pathology; PWV: pulse wave velocity measurement; TCD: transcranial Doppler; TTE: transthoracic echocardiography; US: ultrasound.

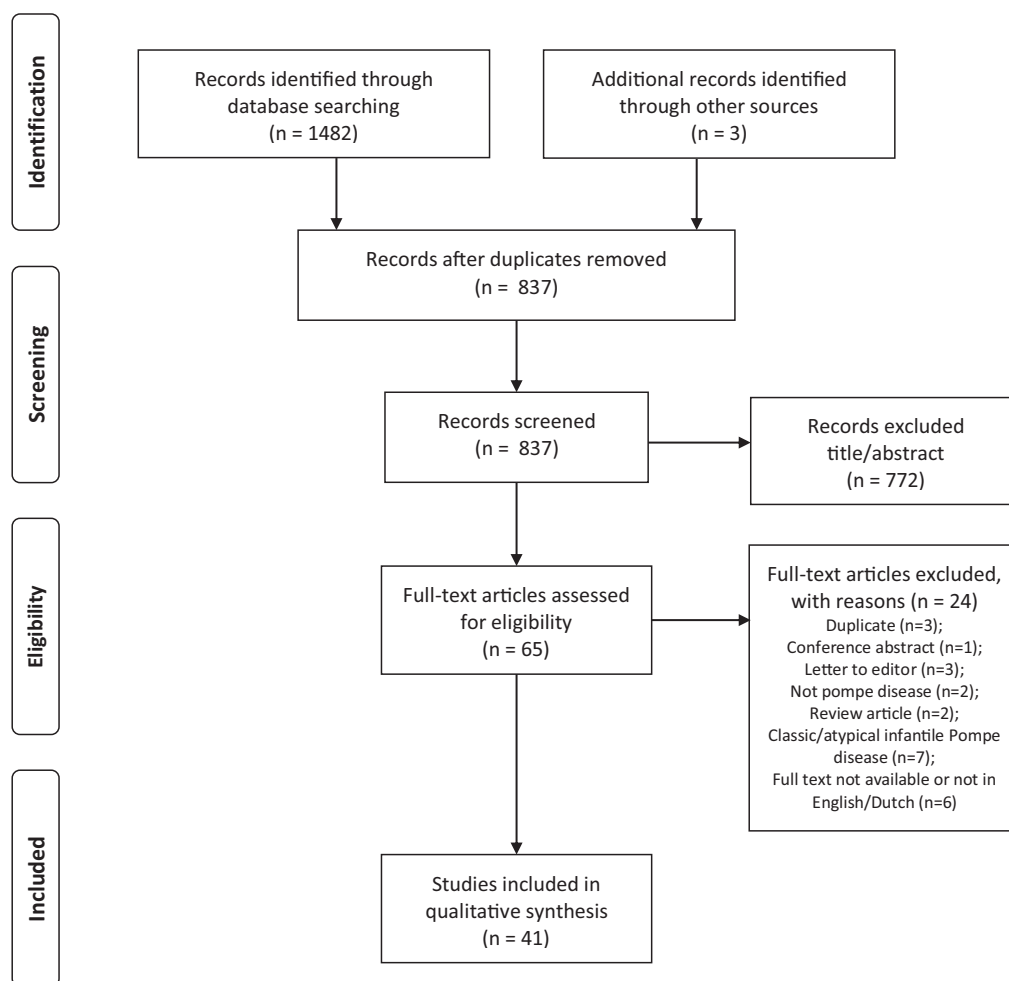


Fig. 1. Study selection flow diagram (adapted from the Preferred Reporting Items for Systematic Reviews and Meta-analyses (PRISMA) template [17]). Seven additional studies were included from the updated search in November 2019.

mentioned) and in four studies no specific diagnostics or only muscle biopsy abnormalities were mentioned (based on the level of certainty, these studies were classified as possible Pompe disease), all patients were included in our review. Most commonly used diagnostic modalities to investigate cardiovascular disease were: ECG, TTE, magnetic resonance imaging (MRI), magnetic resonance angiography (MRA), computed tomography (CT), computed tomography angiography (CTA) and PA. Fourteen studies reported on cardiac outcomes, 25 studies described vascular outcomes, and nine studies reported on both cardiac and vascular outcomes.

3.3. Cardiac findings

The findings of 23 studies reporting on cardiac findings are summarized in Table 2.

3.3.1. Cardiac findings in case-control studies

In Table 2A, outcomes of four small case control studies on cardiac outcomes are summarized [18–21]. Two studies performed ECGs, one of these studies reported no

abnormalities in 12 Pompe patients [18]. The other study reported one patient with a short PR-interval (sPR) and one patient with a right bundle branch block (RBBB), among 10 Pompe disease patients, but ECG findings in controls were not reported [19]. In two other studies ECGs were not reported [20,21]. In all four studies echocardiography and/or cardiac MRI was performed. Two studies, with in total 22 patients and 194 controls, did not find significant differences in structural or functional cardiac features between patients and controls [18,19]. One study reported a larger mean diastolic aortic diameter (measured with TTE) in 17 Pompe patients compared to 17 controls [20]. One study reported significant differences in left ventricular global radial strain (LV-GRS) and left ventricular global circumferential strain (LV-GCS) (both measures of cardiac deformation), measured with MRI between 17 patients and 18 controls, but findings were within the normal range in both groups [21].

3.3.2. Cardiac findings in cohort studies

Nine cohort studies reporting on cardiac findings are summarized in Table 2B. Eight cohort studies (describing 528 cases in total) performed ECGs. Multiple studies

Table 2
Findings of studies focusing on cardiac outcomes.

A. Case-control studies							
Reference (year)	Patients/controls (N)	Pompe disease onset (N)		Age (years)*	Outcomes significantly different between patients and controls		
		Childhood	Adult				
Faysoil (2014) [19]	10/7	NR	NR	56.7 (10.2)	–		
Morris (2015) [18]	12/187	0	12	37.9 (13.4)	–		
Boentert (2016) [21]	17/18	4	13	50 (18)	HC, LV-GCS, LV-GRS		
B. Cohort studies							
Reference (year)	Pts with abnormality (N)	Pompe disease onset (N)		Age (years)	Findings (N)		
		Childhood	Adult		ECG	TTE/imaging	CV RF
Müller-Felber (2007) ^b [26]	8	6	32	NR	VPC (5), WPWs (3)	–	NR
Soliman (2008) ^a [22]	13	0	46	48 (12)*	AF (1), LAHB (1), LBBB (1), RBBB (1), sPR (1)	BVH (1), DDF (9), dEF (1), LVD (1)	HT (11), DM (2)
Van der Beek (2008) ^a [23]	6	23	45	38 (19)*	AF (1), LBBB (1), LAHB (2), RBBB (1), sPR (1), WPWp (1)	BVH (1), dEF (1), LVED (1), VA (1)	S (2), DM (2), HT (1)
Forsha (2011) ^{a,c} [24]	40	NR	NR	44 (39–52) [‡]	IBBB (2), LAE (3), LBBB (1), LVH (10), pQRS (1), pQT (3), RAE (1), RBBB (1), sPR (8), ST (5), WPWs (2)	dEF (6), LVMI (4)	NR
Schüller (2012) ^b [27]	19	NR	NR	18–62 [†]	RBBB (2), SA (7), SSS (1), WPWs (3)	LVH (6)	–
Sacconi (2014) [84]	4	0	131	35–55 [†]	AVB (4), pQT (1), ST (1)	–	–
Van Capelle (2016) ^a [25]	6	31	0	0.1–17.1 [†]	sPR (3)	HCM (2), VA (3)	NR
Herbert (2018) ^c [29]	29	NR	NR	0.5 - 78 [†]	AVB (1), MA (8), RBBB (1), SVT (2)	LAE (4), LVH (14), VD (18)	HT, DM, HL (N?)
Alandy-dy (2019) [31]	2	5	13	53.7 (14)*	NP	CM (3)	NR
C. Case reports/case series							
Reference (year)	Pompe disease onset (N)		Age (years)	Findings			
	Childhood	Adult		ECG	TTE/imaging	PA	CV RF
Francesconi (1982) [85]		1	30	AVB, PES	–		NR
Kretzschmar (1990) [9]	1		40	RBBB	NP	MA	NR
Fernández (2012) [93]	1		12	sPR	–		NR
Goeber (2013) [94]	1		48	–	LVH, LVD		NR
Céron-Rodríguez (2014) [95]	1		9	VRD	BVH, PH, RAE		NR
Zhang (2016) [100]	1		28	–	VA		NR
Kim (2017) [32]	1		5	WPWs	HCM, LVOT		NR
Mori (2017) [33]		1	33	NP	DCM, dEF	GS	NR
Walczak-Galezewska (2017) [102]		1	54	–	dEF, HMI		HC
Hossain (2018) [103]		1	59	NP	LAE, LVH		HT

* mean (SD).

[‡] median (interquartile range).

[†] range. N: number of patients. ^{a,b,c} studies that (likely) included patients from the same cohort; –=no abnormalities; NP: not performed; NR: not reported. AF: atrial fibrillation; AVB: atrioventricular block; BVH: biventricular hypertrophy; CM: cardiomyopathy; DCM: dilated cardiomyopathy; DDF: diastolic dysfunction; dEF: decreased ejection fraction; DM: diabetes mellitus; ECG: electrocardiogram; GS: lysosomal glycogen storage and myocyte vacuolization; HC: hypercholesterolemia; HCM: hypertrophic cardiomyopathy; HL: hyperlipidemia; HMI: heart muscle infiltration; HT: hypertension; IBBB: incomplete bundle branch block; LAE: left atrium enlargement; LAHB: left anterior hemi block; LBBB: left bundle branch block; LVD: increased left ventricular diameter; LVED: increased left ventricular end-diastolic dimension; LV-GCS: left ventricular global circumferential strain; LV-GRS: left ventricular global radial strain; LVH: left ventricular hypertrophy; LVMI: elevated left ventricular mass; LVOT: left ventricular outflow tract obstruction; MA: minor abnormalities (unspecified); PA: pathology; PES: pre-excitation syndrome; PH: pulmonary hypertension; pQRS: prolonged QRS-interval; pQT: prolonged QT-interval; RAE: right atrium enlargement; RBBB: right bundle branch block; S: smoking; SA: sinusarrhythmia; sPR: short PR-interval; SSS: sick sinus syndrome; ST: sinustachycardia; SVT: supraventricular tachycardia; TTE: transthoracic echocardiography; VA: various valve abnormalities; VD: valvular dysfunction; VPC: ventricular premature complexes; VRD: ventricular repolarization disorder; WPWp: Wolff-Parkinson-White pattern; WPWs: Wolff-Parkinson-White syndrome.

reported on the same cohorts of patients [22–30]. Sixteen different ECG findings were described. Most commonly reported findings were sPR, RBBB and Wolf-Parkinson-White syndrome (WPWs). The prevalence of these findings varied between different studies: sPR was reported in 1.5–9.7% of patients, RBBB in 1.2–6.3% of patients and WPWs in 2.3–7.9% of patients. Signs of left ventricular hypertrophy (LVH) on ECG were reported in 10/87 (11.5%) of patients in one study, only one of these patients showed elevated left ventricular mass (LVMI) on echocardiography [28].

Eight cohort studies performed cardiac imaging and/or function tests using TTE, one study did not report what type of diagnostic modality was used [31]. Most commonly reported findings were various valvular abnormalities/dysfunction (VA/VD), LVH and decreased ejection fraction (dEF). The prevalence of these conditions in different studies was: 1.5–21.7% for VA/VD, 13.6–16.7% for LVH and 1.5–6.9% for dEF. One study reported two children with a hypertrophic cardiomyopathy (HCM), both patients did not carry the common IVS1 mutation and had a very early onset of Pompe disease symptoms (before the age of 1) [25]. One study reported three adults (aged 22, 40 and 42 years) with cardiomyopathy (unspecified) which improved with ERT, of whom one had a childhood onset of Pompe disease and did not carry the common IVS1 mutation [31].

3.3.3. Cardiac findings in case reports and case series

As summarized in Table 2C, 10 case reports described cardiac findings. Six different ECG findings were described in five individual patients (age 5–40 years). One study reported WPWs and HCM with left ventricular outflow tract obstruction (LVOT) in a five-year-old girl, which improved after start of ERT at age 15 [32].

Abnormalities on TTE or other imaging were described in seven patients, with LVH and dEF being the most common. Hypertrophic cardiomyopathy was described only in the above mentioned five-year old girl. One 33-year-old woman with a dilated cardiomyopathy (DCM) and myocardial glycogen accumulation (GA) with vacuolization was reported, ERT was not started because of severe and irreversible cardiac muscle damage [33]. One other study describing pathology findings reported that the heart was “minimally affected”, without further specification of these abnormalities [9].

3.4. Vascular findings

In Table 3, 34 studies reporting on vascular findings are summarized.

3.4.1. Vascular findings in case-control studies

As shown in Table 3A, five case control studies focused on vascular outcomes. Two studies, reporting on the same cohort of patients, reported increased aortic stiffness in Pompe patients, using aortic stiffness index (ASI) and carotid-femoral pulse wave velocity measurement (cfPWV) as non-invasive methods to measure aortic stiffness [14,20]. These studies also reported higher mean arterial pressure (MAP) and

smaller carotid artery diameter in Pompe patients compared to controls.

One study reported a larger diameter of the carotid, cerebral anterior circulation and vertebrobasilar circulation arteries in 10 Pompe patients compared to controls [34]. Also carotid and vertebral artery mean flow velocity (MFV) and carotid and vertebrobasilar cerebral blood flow (CBF) were higher in Pompe patients compared to controls in this study. These 10 patients plus 10 new patients were described in another study, reporting abnormal length, volume and height of the bifurcation of the basilar artery in patients compared to 40 controls [35]. During five year follow up, one patient experienced an intracerebral hemorrhage (ICH). White matter lesions were also reported in this study, but the prevalence of WML did not differ between patients and controls. This cohort of patients was studied again using cerebral MRI, this study showed no significant difference in Fazekas score and WML volume between Pompe patients and controls matched for age, sex and number of cerebrovascular risk factors [36].

3.4.2. Vascular findings in cohort studies

Eight cohort studies reported on vascular findings, as shown in Table 3B. All studies performed (vascular) imaging and reported on a total of 193 cases. However, the number of individual patients is probably lower, since several studies reported on the same cohorts of patients [27,30,37–40]. Most commonly reported findings or events were (dolicho)ectasias, aneurysms, strokes and WML. Six studies reported (dolicho)ectasias of the vertebrobasilar circulation (VBD), the carotid arteries (CAE) and the anterior circulation (ACD). The prevalence of these findings varied between different studies: VBD was reported in 2–72% of patients, CAE in 39–50% of patients and ACD in 28% of patients. One study reported no significant changes in MRA findings and no major vascular events during 10-year follow up of five patients with VBD and CAE [38]. Four studies reported aneurysms; anterior circulation aneurysms (ACA) were reported in 2–14% of patients, aortic aneurysms (AA) were reported in 2–10% of patients and vertebrobasilar aneurysms (VBA) were reported in 3–6% of patients. Strokes were reported in five studies, with ischemic stroke (IS) occurring in 3–10% of patients. White matter lesions were commonly reported, with a prevalence ranging from 62% to 100% of patients.

3.4.3. Vascular findings in case reports and case series

In Table 3C, 20 case reports/series reporting on vascular findings are summarized. Vascular abnormalities or events in 25 individual patients were reported. In total, 19 cases of (dolicho)ectasia at various locations (vertebrobasilar ($n=8$), diffuse cerebral ($n=5$), carotid arteries ($n=3$), anterior circulation ($n=1$), renal artery ($n=1$) and iliac artery ($n=1$)) were reported. Ages of the reported patients ranged from 16 to 68 years. Ten aneurysms (located at the vertebrobasilar circulation ($n=7$), anterior circulation ($n=2$) and aorta ($n=1$)) were described in patients aged 16–59 years. In five patients rupture of an intracerebral aneurysm caused

Table 3
Findings of studies focusing on vascular outcomes.

A. Case-control studies										
Reference (year)	Patients/ controls (N)	Pompe disease onset (N)		Age (years)	Outcomes significantly different between patients and controls					
		Childhood	Adult		ASI, BMI, DAD	ART, CA-D, cfPWV, HR, HT, MAP	BA-CBF, BA-D, CA-CBF, CA-D, CA-MFV, MCA-D, VA-CBF, VA-D, VA-MFV	BA-D, BA-H, BA-L, BA-V, SUCA-OA	-	
Nemes (2007) ^a [20]	17/17		17	44 (8)*						
Wens (2014) ^a [14]	84/179	NR	NR	54 (42-63)‡						
Hensel (2015) ^b [34]	10/20	1	9	44-71†						
Hensel (2018) ^b [35]	20/40	3	17	53.7 (14.6)*						
Schneider (2019) ^b [36]	19/38	3	17	54.4 (19-82)×						
B. Cohort studies										
Reference (year)	Pts with abnormality (N)	Pompe disease onset (N)		Age (years)	Findings/events related to vascular abnormalities (N)					
		Childhood	Adult		Ectasia/dilatation	Aneurysm	Stroke	WML/MH	CV RF	Other
Müller-Felber (2007) ^c [26]	1		1	28			IS		NR	
Sacconi (2010) [37]	4		4	38-69†	CAE (3), VBD (4)		TIA (1)		-	
El-Gharbawy (2011) [83]	5	1	4	33-64†		AA (4), VBA (1)			HT (1), HL (1), HC (1)	AD (1)
Schüller (2012) ^c [27]	3	NR	NR	30-53†	VBD (1)	AA (1), ACA (1)	IS (2)		-	
Montagnese (2016) [39]	18	1	17	50 (14.97)*	VBD (10)	ACA (2)	IS (2)	WML (13)	HT (5), S (4), OB (3), HC (4)	BA-F (1)
Garibaldi (2017) ^d [38]	3		3	62-78†	CAE (2), VBD (3)				NR	
Pichiecchio (2017) [63]	1	2	13	52.3 (28-76)×	ACD (5), CAE (7), VBD (13)			WML (6)	S (5), OB (2), DM (2), HC (4), HT (4)	PSG (4)
Musumeci (2019) ^e [40]	21	4	17	49 (1.4)*	VBD (11)	ACA (3)		WML (21)	S (7), HT (7), HC (5)	
Alandy-Dy (2019) [31]	1	5	13	53.7 (14)*		VBA (1)			NR	
C. Case reports/case series										
Reference (year)	Pompe disease onset (N)		Age (years)	Findings/events related to vascular abnormalities (N)						
	Childhood	Adult		Ectasia/dilatation	Aneurysm	Stroke	WML/MH	PA	CV RF	Other
Miyamoto (1985) [86]		1	25		VBA	SAH		VAC	NR	
Braunsdorf (1987) [87]	NR	NR	34	CAE	VBA		WML		NR	
Makos (1987) [10]	2	1	16-27†	CAE (1), VBD (2)	VBA (2)	IS (1), SAH (2)		GA, VAC	NR	
Matsuoka (1988) [88]		1	20		VBA	IS, SAH		VAC	NR	
Kretzschmar (1990) [9]	1		40				MH	GA, VAC	NR	
Anneser (2005) [89]		1	30	DCD			MH		-	
Brettscheider (2008) [90]		1	68			ICH	MH		-	
Laforêt (2008) [91]	2	1	30-44†	DCD (1), VBD (1)	VBA (1)				NR	DCP (1), ICD (1)
Refai (2008) [55]	1		19	VBD		IS			NR	
Renard (2010) [92]		1	68	ACD, VBD			MH		-	
Goeber (2013) [94]	1		48	VBD	AA			GA	NR	ENV
Peric (2014) [96]		1	50		ACA	SAH			-	
Quenardelle (2014) [97]		1	52	CAE, IAD, RAD, VBD		IS			-	KI
Sandhu (2014) [98]	NR	NR	25	DCD		ICH	MH		HT	
Huded (2016) [99]		2	40, 43	DCD (2)		IS (2)	MH (1)		NR	
Zhang (2016) [100]	1		28		VBA				NR	
Malhotra (2017) [101]		1	40	VBD		IS			NR	BA-S
Mori (2017) [33]		1	33			IS			NR	
Hossain (2018) [103]		1	57		ACA	IS, SAH	WML		HT	
Pappa (2018) [104]		1	38			ICH			-	KI, RAD

N: number of patients ^{a,b,c}, studies that (likely) included patients from the same cohort, ^d follow up of 5/6 patients of Sacconi (2010), ^e findings of 17/21 patients were previously reported by Montagnese (2016); * mean (SD); ‡ median (interquartile range); × median (range); † range; NR: not reported; - no abnormalities; AA: aortic aneurysm; ACA: anterior circulation aneurysm; ACD: anterior circulation (dolicho)ectasia/dilatation; AD: aortic dissection; ART: aortic reflexion time; ASI: aortic stiffness index; BA-CBF: basilar artery cerebral blood flow; BA-D: basilar artery diameter; BA-F: basilar artery fenestration; BA-H: height of basilar artery bifurcation; BA-L: basilar artery length; BA-S: basilar artery stenosis; BA-V: basilar artery volume; BMI: body mass index; DM: diabetes mellitus; CA-CBF: carotid artery cerebral blood flow; CA-D: carotid artery diameter; CAE: carotid artery ectasia/dilatation; CA-MFV: carotid artery mean flow velocity; cfPWV: carotid-femoral pulse wave velocity; CV RF: cardiovascular risk factors; DAD: diastolic aortic diameter; DCD: diffuse cerebral (dolicho)ectasia/dilatation; DCP: diffuse cerebral pseudo-aneurysm; ENV: elongated neck vessels; GA: glycogen accumulation in vascular smooth muscle cells; HC: hypercholesterolemia; HT: hypertension; HR: heart rate; IAD: iliac artery dilatation; ICD: internal carotid artery dissection; ICH: intracranial hemorrhage; IS: ischemic stroke; KI: kidney infarct; MAP: mean arterial pressure; MCA-D: mid cerebral artery diameter; MH: microhemorrhages; OB: obesity; PA: pathology; PSG: punctate subcortical gliosis; RAD: renal artery dilatation; SAH: subarachnoid hemorrhage; SUCA-OA: superior cerebellar artery outlet angle; TIA: transient ischemic attack; VAC: vacuolar changes in vascular smooth muscle cells; VA-CBF: vertebral artery cerebral blood flow; VA-D: vertebral artery diameter; VA-MFV: vertebral artery mean flow velocity; VBA: vertebrobasilar circulation aneurysm; VBD: vertebrobasilar (dolicho)ectasia/dilatation; WML: white matter lesions.

a subarachnoid hemorrhage (SAH). Ischemic strokes were reported in nine patients (aged 19–59 years), ICH in three patients (aged 25–68 years). Six patients with MH and two patients with WML were reported. Pathology findings were described in six studies; five of these studies reported vacuolar changes and/or glycogen accumulation within smooth muscle cells in the media of the arterial walls, one study reported no abnormalities. Two patients with a kidney infarct (KI) and one patient with a dissection of the internal carotid artery (ICD) were reported.

3.5. Cardiovascular risk factors

Reported cardiovascular risk factors for all studies are summarized in [Tables 2](#) and [3](#). For case control studies, only risk factors between patients and controls being significantly different are reported in the tables. Non-significantly different cardiovascular risk factors reported in these case-control studies were: hypertension (30–70%), hypercholesterolemia/hyperlipidemia (10–70%), diabetes mellitus (6–20%), obesity (18–40%), and smoking (5–30%). In the cohort studies, hypertension was reported in 22–33%, diabetes in 4–11%, smoking in 19–33%, hypercholesterolemia/hyperlipidemia in 19–24% and obesity in 11–14% of patients.

4. Discussion

To our knowledge, this is the first systematic review on cardiovascular disease in non-classic Pompe disease. It gives a comprehensive overview of the present literature. A large number of studies were included ($n=48$), reporting on 750 cases in total. However, the exact number of individual patients is difficult to estimate, since several studies reported on the same cohorts of patients. Moreover, we could not determine the level of diagnostic certainty of all patients in the included papers, as in some cases or papers the diagnosis was not genetically confirmed, or the DNA results were not reported. Also, the level of evidence of the studies was variable, a large proportion of the included studies are case reports or case series ($n=25$) and outcomes and used methodologies vary greatly. It was not possible to perform meta-analysis, but a thorough qualitative analysis was performed.

In case-control studies, no significant differences between patients and controls were reported for ECG findings [\[18,19\]](#). However, patient numbers were small. In cohort studies, various ECG/conduction abnormalities were described, with sPR, RBBB and WPW pattern/syndrome being the most common. The cause of conduction abnormalities in non-classic Pompe patients may be glycogen accumulation in the myocardium and/or conduction system [\[11,41\]](#). However, minor ECG findings and conduction abnormalities, like RBBB, have a high prevalence in the general, healthy population as well [\[42\]](#). Wolff–Parkinson–White syndrome or pattern was reported in 2.3–7.9% of patients in different cohorts, whereas the prevalence of WPW pattern in the general population is estimated to be around 0.25%

[\[42–47\]](#). Since different types of (severe) arrhythmias and even sudden cardiac death can occur in patients with WPW pattern, it seems important that an ECG is conducted at least once in all newly diagnosed non-classic Pompe disease patients [\[48,49\]](#). In patients with a normal ECG at baseline, repeated ECG could be considered, since WPW pattern may be intermittent and Pompe disease is, despite ERT, a progressive disease [\[50,51\]](#). It can therefore not be ruled out that glycogen accumulation in cardiac tissue causes conduction abnormalities as the disease progresses.

In case-control studies, severe structural cardiac abnormalities or cardiac dysfunction on TTE or other imaging were not described. In cohort studies, LVH was the most commonly reported TTE/imaging abnormality. Left ventricular hypertrophy or elevated LVMI, was described in 4.6–16.7% of patients, which is comparable to the prevalence in the general population [\[24,27,29,52\]](#). Left ventricular hypertrophy is mainly caused by long-term pressure and/or volume overload, consequently the prevalence of LVH is higher in a population with high blood pressure [\[53\]](#). One study reported that all patients with LVH also had other cardiovascular risk factors, including hypertension [\[29\]](#). The other studies did not report whether patients with LVH also had hypertension, but since mean blood pressure is reported to be increased in non-classic Pompe patients, it is likely that hypertension was prevalent in these cohorts as well [\[14\]](#). Hypertrophic cardiomyopathy, a hallmark in classic infantile Pompe disease, was described in only three patients in the retrieved studies [\[25,32\]](#). However, these patients did not carry the common IVS1 mutation and had a (very) early onset of disease, and therefore might be classified as atypical infantile onset patients, rather than non-classic Pompe patients. Only one adult patient, with one mutation with unknown pathogenicity, was reported to have severe dilated cardiomyopathy [\[33\]](#).

The most commonly reported vascular abnormalities in non-classic Pompe patients were (dolicho)ectasias, with a predisposition for the vertebral and/or basilar arteries. One case-control study showed an increased diameter of extra- and intracranial arteries in patients compared to controls matched for age and sex [\[34\]](#). Importantly, the presence of other cardiovascular risk factors was distributed evenly among patients and controls in this study. In cohort studies, the prevalence of VBD varied between 2% and 72%. Reported estimates of prevalence of VBD in the general population vary from 0.8% to 6.5%, indicating that VBD is more prevalent in Pompe patients [\[54\]](#). Moreover, (dolicho)ectasias were also described in (very) young Pompe disease patients, with the youngest patient being only 19 years old [\[55\]](#). Other important vascular abnormalities commonly reported in the included studies were intracranial (anterior and vertebrobasilar circulation) and aortic aneurysms. Intracranial aneurysms were reported in up to 14% of Pompe patients in different cohort studies, whereas the prevalence of intracranial aneurysms is estimated to be 3.2% in a population without comorbidity [\[56\]](#). The pathophysiology of these vascular abnormalities is most

likely multifactorial, as both degeneration of smooth muscle cells of arterial walls caused by glycogen accumulation and established cardiovascular risk factors (i.e. hypertension, cigarette smoking, aging) are associated with (dolicho)ectasia and aneurysm formation [54,57–59]. Although asymptomatic in a proportion of patients, the consequences of intracranial (dolicho)ectasia and aneurysms can be serious, with brain infarction, ICH and SAH, and compression of the brainstem being most common [54,60]. Interestingly, ICH and/or SAH as a consequence of intracranial dolichoectasia or aneurysms were only reported in case reports/series and not in any of the cohort studies. Previous studies have shown that ERT can decrease glycogen in arteries and veins, but not completely and not in all patients [6,61,62]. However, as established vascular risk factors also contribute to the pathophysiological mechanisms of arterial widening, monitoring and treatment of these risk factors is particularly important in patients with non-classic Pompe disease.

White matter lesions in a lacunar pattern, characteristic for small vessel disease, were reported in a large proportion of patients in different cohort studies [39,40,63]. However, most of these patients also had other (established) vascular risk factors. Moreover, in a case-control study, Fazekas score and WML volume did not significantly differ between Pompe patients and controls matched for gender, age and number of cerebrovascular risk factors [36]. This suggests that WML in Pompe patients mainly result from other (established) cerebrovascular risk factors. The lacunar pattern of WML reported in non-classic Pompe patients is clearly distinct from the white-matter involvement, which slowly evolves from periventricular to subcortical, described in classic infantile Pompe disease [64]. Severe cognitive decline, as reported in some classic infantile Pompe disease patients, was not reported in non-classic Pompe patients, although one study reported mild cognitive impairment in 52% of patients [40,64,65]. The severity of WML did not correlate with neuropsychological variables in this study, indicating that other factors may play a role in the cognitive impairment in these patients.

As stated previously, arterial stiffness, LVH and WML in Pompe disease patients may also be caused by established cardiovascular risk factors, such as obesity, hypertension, diabetes mellitus and dyslipidemia [53,66–68]. No large study systematically investigated if established cardiovascular risk factors are more prevalent in Pompe disease than in the general population. Studies in Pompe patients reported a large prevalence range for various cardiovascular risk factors, such as for hypertension (22–70%), diabetes (4–20%), and obesity (11–40%). Whether this is different compared to the prevalence of these risk factors in the general population remains to be established. The prevalence of hypertension in adults is estimated to be around 30–45% and increases to over 60% in individuals over the age of 60 years [69]. The global prevalence of diabetes in the general population is estimated to be around 9%, with great variation due to age, regional, income and ethnic differences [70]. Global prevalence of obesity is estimated to be around 13%, increasing up to

26% in high income countries [71]. These large ranges imply that larger case-control studies in Pompe patients are needed before reliable conclusions about these risk factors in comparison to the general population can be drawn. As Pompe disease affects skeletal muscle function, resulting in decreased overall activity level and ability to exercise and decreased resting energy, we hypothesize that these cardiovascular risk factors may be more prevalent in non-classic Pompe patients compared to the general population. This should be objectified in future studies.

It is important to realize that there are large differences between muscle glycogen storage diseases (GSD) in respect to the presence of cardiac abnormalities. In muscle glycogen synthase deficiency (GSD 0b) hypertrophic cardiomyopathy is a key clinical finding [72,73]. In muscle phosphofructokinase (PFKM) deficiency or Tarui disease (GSD VII) cardiomyopathy is rare, but has been described [74]. In phosphoglucomutase 1 deficiency in muscle (GSD XIV) dilated cardiomyopathy and tachycardia have been described in some patients [75–77]. Arrhythmias and cardiomyopathy due to abnormal glycogen storage in the heart are characteristic for glycogenin 1 deficiency (GSD XV) [77–79]. Mutations in the PRKAG2 gene cause glycogen storage cardiomyopathy and conduction system abnormalities [80]. However, not all muscle glycogenoses are associated with cardiac involvement (e.g. muscle phosphorylase deficiency or McArdle disease (GSD V), phosphoglycerate kinase deficiency, lactate dehydrogenase A and B deficiency (GSD XI), aldolase A deficiency (GSD XII), beta-enolase deficiency in muscle (GSD XIII)) [81,82]. Interestingly, arterial ectasia, dilation and aneurysms as reported in Pompe disease, are not characteristic for other muscle glycogenoses [81].

This is the first systemic review that provides an overview of different types of cardiovascular disease described in non-classic Pompe disease. Besides some indications that (intracranial) arterial dolichoectasia and aneurysms may be more common in Pompe disease than in the general population, we found no literature evidence for other clinically significant cardiovascular abnormalities in non-classic Pompe disease patients, in particular in those patients carrying the common IVS1 mutation. Different types of ECG/conduction abnormalities were reported in cohort studies, but a relationship with Pompe disease remains uncertain, and argues for additional (larger) case-control studies. Currently, it seems recommendable to perform an ECG at least once in every newly diagnosed Pompe patient, to investigate for possible arrhythmias or conduction abnormalities. To further investigate the prevalence of cardiovascular disease in non-classic Pompe patients, especially larger case-control studies, that also investigate more established risk factors for cardiovascular disease are indicated. Ideally, patients and controls should be matched not only for age and sex, but also for a variety of established cardiovascular risk factors, in order to draw more robust conclusions about the prevalence of cardiovascular disease in non-classic Pompe disease. Due to the prevalence of the disease, this may require international collaboration.

Declaration of Competing Interest

The authors declare that they have no known competing financial interests or personal relationships that could have appeared to influence the work reported in this paper.

Acknowledgments

We would like to acknowledge G.B. de Jonge, S. Gunput and M.F.M. Engel of the Medical Library of Erasmus MC for assisting with the literature search.

Supplementary materials

Supplementary material associated with this article can be found, in the online version, at doi:10.1016/j.nmd.2020.10.009.

References

- [1] van der Ploeg AT, Reuser AJ. Pompe's disease. *Lancet* 2008;372(9646):1342–53.
- [2] Van den Hout HMP, Hop W, Van Diggelen OP, Smeitink JAM, Smit GPA, Poll-The BTT, et al. The natural course of infantile Pompe's disease: 20 Original cases compared with 133 cases from the literature. *Pediatrics* 2003;112(2 I):332–40.
- [3] Van der Beek NAME, Hagemans MLC, Van der Ploeg AT, Reuser AJJ, Van Doorn PA. Pompe disease (glycogen storage disease type II): clinical features and enzyme replacement therapy. *Acta Neurol Belg* 2006;106(2):82–6.
- [4] Chan J, Desai AK, Kazi ZB, Corey K, Austin S, Hobson-Webb LD, et al. The emerging phenotype of late-onset Pompe disease: a systematic literature review. *Mol Genet Metab* 2017;120(3):163–172.
- [5] Toscano A, Rodolico C, Musumeci O. Multisystem late onset Pompe disease (LOPD): an update on clinical aspects. *Ann Transl Med* 2019;7(13):284.
- [6] McCall AL, Salemi J, Bhanap P, Strickland LM, Elmallah MK. The impact of Pompe disease on smooth muscle: a review. *J Smooth Muscle Res* 2018;54(0):100–18.
- [7] Finsterer J. Dilative arteriopathy in metabolic myopathies, particularly Pompe's disease. *Acta Neurol Belg* 2012;112(1):15–18.
- [8] Filosto M, Todeschini A, Cotelli MS, Vielmi V, Rinaldi F, Rota S, et al. Non-muscle involvement in late-onset glycogenosis II. *Acta Myol* 2013;32(2):91–4.
- [9] Kretzschmar HA, Wagner H, Hubner G, Danek A, Witt TN, Mehraein P. Aneurysms and vacuolar degeneration of cerebral arteries in late-onset acid maltase deficiency. *J Neurol Sci* 1990;98(2–3):169–83.
- [10] Makos MM, McComb RD, Hart MN, Bennett DR. Alpha-glucosidase deficiency and basilar artery aneurysm: report of a sibship. *Ann Neurol* 1987;22(5):629–33.
- [11] Hobson-Webb LD, Proia AD, Thurberg BL, Banugaria S, Prater SN, Kishnani PS. Autopsy findings in late-onset Pompe disease: a case report and systematic review of the literature. *Mol Genet Metab* 2012;106(4):462–9.
- [12] Bijvoet AG, Van Hirtum H, Vermey M, Van Leenen D, Van Der Ploeg AT, Mooi WJ, et al. Pathological features of glycogen storage disease type II highlighted in the knockout mouse model. *J Pathol* 1999;189(3):416–24.
- [13] Winkel LP, Kamphoven JH, van den Hout HJ, Severijnen LA, van Doorn PA, Reuser AJ, et al. Morphological changes in muscle tissue of patients with infantile Pompe's disease receiving enzyme replacement therapy. *Muscle Nerve* 2003;27(6):743–51.
- [14] Wens SCA, Kuperus E, Mattace-Raso FUS, Kruijshaar ME, Brusse E, Van Montfort KCAGM, et al. Increased aortic stiffness and blood pressure in non-classic Pompe disease. *J Inherit Metab Dis* 2014;37(3):391–7.
- [15] Mattace-Raso FU, van der Cammen TJ, Hofman A, van Popele NM, Bos ML, Schalekamp MA, et al. Arterial stiffness and risk of coronary heart disease and stroke: the Rotterdam study. *Circulation* 2006;113(5):657–63.
- [16] van der Ende MY, Hartman MH, Hagemeyer Y, Meems LM, de Vries HS, Stolk RP, et al. The lifelines cohort study: prevalence and treatment of cardiovascular disease and risk factors. *Int J Cardiol* 2017;228:495–500.
- [17] Moher D, Liberati A, Tetzlaff J, Altman DG, Group P. Preferred reporting items for systematic reviews and meta-analyses: the PRISMA statement. *BMJ* 2009;339:b2535.
- [18] Morris DA, Blaschke D, Krebs A, Canaan-Kühl S, Plöckinger U, Knobloch G, et al. Structural and functional cardiac analyses using modern and sensitive myocardial techniques in adult Pompe disease. *Int J Card Imaging* 2015;31(5):947–56.
- [19] Faysoil A, Nardi O, Annane D, Orlikowski D. Right ventricular function in late-onset Pompe disease. *J Clin Monit Comput* 2014;28(4):419–21.
- [20] Nemes A, Soliman OII, Geleijnse ML, Anwar AM, van der Beek NAME, van Doorn PA, et al. Increased aortic stiffness in glycogenosis type 2 (Pompe's disease). *Int J Cardiol* 2007;120(1):138–41.
- [21] Boentert M, Florian A, Dräger B, Young P, Yilmaz A. Pattern and prognostic value of cardiac involvement in patients with late-onset pompe disease: a comprehensive cardiovascular magnetic resonance approach. *J Cardiovasc Magn Reson* 2016;18(1):91.
- [22] Soliman OII, Van Der Beek NAME, Van Doorn PA, Vletter WB, Nemes A, Van Dalen BM, et al. Cardiac involvement in adults with Pompe disease. *J Intern Med (GBR)* 2008;264(4):333–9.
- [23] van der Beek NAME, Soliman OII, van Capelle CI, Geleijnse ML, Vletter WB, Kroos MA, et al. Cardiac evaluation in children and adults with Pompe disease sharing the common c.-32-13T>G genotype rarely reveals abnormalities. *J Neurol Sci* 2008;275(1–2):46–50.
- [24] Forsha D., Li J.S., Smith P.B. Cardiovascular abnormalities in late onset Pompe disease and response to enzyme replacement therapy: ncbi.nlm.nih.gov; 2011.
- [25] Van Capelle CI, Van Der Meijden JC, Van Den Hout JMP, Jaeken J, Baethmann M, Voit T, et al. Childhood Pompe disease: clinical spectrum and genotype in 31 patients. *Orphanet J Rare Dis* 2016;11(1):65.
- [26] Müller-Felber W, Horvath R, Gempel K. Late onset Pompe disease: clinical and neurophysiological spectrum of 38 patients including long-term follow-up in 18 patients. Elsevier; 2007.
- [27] Schüller A, Wenninger S, Strigl-Pill N, Schoser B. Toward deconstructing the phenotype of late-onset Pompe disease. *Am J Med Genet Part C Semin Med Genet* 2012;160(C(1)):80–8.
- [28] Forsha D, Li JS, Smith PB, Van Der Ploeg AT, Kishnani P, Pasquali SK. Cardiovascular abnormalities in late-onset Pompe disease and response to enzyme replacement therapy. *Gen Med* 2011;13(7):625–31.
- [29] Herbert M, Cope H, Li JS, Kishnani PS. Severe cardiac involvement is rare in patients with late-onset pompe disease and the common c.-32-13T>G variant: implications for newborn screening. *J Pediatr* 2018;198:308–12.
- [30] Müller-Felber W, Horvath R, Gempel K, Podskarbi T, Shin Y, Pongratz D, et al. Late onset Pompe disease: clinical and neurophysiological spectrum of 38 patients including long-term follow-up in 18 patients. *Neuromuscular Disord* 2007;17(9–10):698–706.
- [31] Alandy-Dy J, Wencel M, Hall K, Simon J, Chen Y, Valenti E, et al. Variable clinical features and genotype-phenotype correlations in 18 patients with late-onset Pompe disease. *Ann Transl Med* 2019;7(13):276.

- [32] Kim J, Kim H, Eun LY. Enzyme therapy for hypertrophic cardiomyopathy in non-classical Pompe disease: effectiveness of treatment. *Pediatr Int* 2017;59(1):107–8.
- [33] Mori M, Bailey LA, Estrada J, Rehder CW, Li JS, Rogers JG, et al. Severe cardiomyopathy as the isolated presenting feature in an adult with late-onset Pompe disease: a case report. *JIMD Rep* 2017;31:79–83.
- [34] Hensel O, Hanisch F, Stock K, Stoevesandt D, Deschauer M, Muller T. Morphology and function of cerebral arteries in adults with pompe disease. *JIMD Rep* 2015;20:27–33.
- [35] Hensel O, Schneider I, Wieprecht M, Kraya T, Zierz S. Decreased outlet angle of the superior cerebellar artery as indicator for dolichoectasia in late onset Pompe disease. *Orphanet J Rare Dis* 2018;13(1):57.
- [36] Schneider I, Hensel O, Zierz S. White matter lesions in treated late onset Pompe disease are not different to matched controls. *Mol Genet Metab* 2019;127(2):128–31.
- [37] Sacconi S, Bocquet JD, Chanalet S, Tanant V, Salvati L, Desnuelle C. Abnormalities of cerebral arteries are frequent in patients with late-onset Pompe disease. *J Neurol* 2010;257(10):1730–3.
- [38] Garibaldi M, Sacconi S, Antonini G, Desnuelle C. Long term follow-up of cerebrovascular abnormalities in late onset Pompe disease (LOPD). *J Neurol* 2017;264(3):589–90.
- [39] Montagnese F, Granata F, Musumeci O, Rodolico C, Mondello S, Barca E, et al. Intracranial arterial abnormalities in patients with late onset Pompe disease (LOPD). *J Inherit Metab Dis* 2016;39(3):391–398.
- [40] Musumeci O, Marino S, Granata F, Morabito R, Bonanno L, Brizzi T, et al. Central nervous system involvement in late-onset Pompe disease: clues from neuroimaging and neuropsychological analysis. *Eur J Neurol* 2019;26(3):442–e35.
- [41] van der Walt JD, Swash M, Leake J, Cox EL. The pattern of involvement of adult-onset acid maltase deficiency at autopsy. *Muscle Nerve* 1987;10(3):272–81.
- [42] De Bacquer D, De Backer G, Kornitzer M. Prevalences of ECG findings in large population based samples of men and women. *Heart* 2000;84(6):625–33.
- [43] Klein GJ, Gula LJ, Krahn AD, Skanes AC, Yee R. WPW pattern in the asymptomatic individual: has anything changed? *Circ Arrhythm Electrophysiol* 2009;2(2):97–9.
- [44] McDowell R, Li JS, Benjamin DK Jr, Morgan C, Becker A, Kishnani PS, et al. Arrhythmias in patients receiving enzyme replacement therapy for infantile Pompe disease. *Genet Med* 2008;10(10):758–62.
- [45] van Capelle CI, Poelman E, Frohn-Mulder IM, Koopman LP, van den Hout JMP, Regal L, et al. Cardiac outcome in classic infantile Pompe disease after 13years of treatment with recombinant human acid alpha-glucosidase. *Int J Cardiol* 2018;269:104–10.
- [46] Davenport ED, Rupp KA, Palileo E, Haynes J. Asymptomatic Wolff-Parkinson-White Pattern ECG in USAF Aviators. *Aerosp Med Hum Perform* 2017;88(1):56–60.
- [47] Fitzsimmons PJ, McWhirter PD, Peterson DW, Kruyer WB. The natural history of Wolff-Parkinson-White syndrome in 228 military aviators: a long-term follow-up of 22 years. *Am Heart J* 2001;142(3):530–6.
- [48] Obeyesekere MN, Leong-Sit P, Massel D, Manlucu J, Modi S, Krahn AD, et al. Risk of arrhythmia and sudden death in patients with asymptomatic preexcitation: a meta-analysis. *Circulation* 2012;125(19):2308–15.
- [49] Obeyesekere MN, Klein GJ. Preventing Sudden Death in Asymptomatic Wolf-Parkinson-White Patients. *JACC Clin Electrophysiol* 2018;4(4):445–7.
- [50] Benson DW, Cohen MI. Wolff-Parkinson-White syndrome: lessons learnt and lessons remaining. *Cardiol Young* 2017;27(S1):S62–SS7.
- [51] Kiger ME, McCanta AC, Tong S, Schaffer M, Runciman M, Collins KK. Intermittent versus persistent Wolff-Parkinson-White syndrome in children: electrophysiologic properties and clinical outcomes. *Pacing Clin Electrophysiol* 2016;39(1):14–20.
- [52] Schirmer H, Lunde P, Rasmussen K. Prevalence of left ventricular hypertrophy in a general population; the Tromso study. *Eur Heart J* 1999;20(6):429–38.
- [53] Cuspidi C, Sala C, Negri F, Mancia G, Morganti A. Italian Society of H. Prevalence of left-ventricular hypertrophy in hypertension: an updated review of echocardiographic studies. *J Hum Hypertens* 2012;26(6):343–9.
- [54] Del Brutto VJ, Ortiz JG, Biller J. Intracranial Arterial dolichoectasia. *Front Neurol* 2017;8:344.
- [55] Refai D, Lev R, Cross DT, Shimony JS, Leonard JR. Thrombotic complications of a basilar artery aneurysm in a young adult with Pompe disease. *Surg Neurol* 2008;70(5):518–20.
- [56] Vlak MH, Algra A, Brandenburg R, Rinkel GJ. Prevalence of unruptured intracranial aneurysms, with emphasis on sex, age, comorbidity, country, and time period: a systematic review and meta-analysis. *Lancet Neurol* 2011;10(7):626–36.
- [57] Pico F, Labreuche J, Amarenco P. Pathophysiology, presentation, prognosis, and management of intracranial arterial dolichoectasia. *Lancet Neurol* 2015;14(8):833–45.
- [58] Vlak MH, Rinkel GJ, Greebe P, Algra A. Independent risk factors for intracranial aneurysms and their joint effect: a case-control study. *Stroke* 2013;44(4):984–7.
- [59] Taylor CL, Yuan Z, Selman WR, Ratcheson RA, Rimm AA. Cerebral arterial aneurysm formation and rupture in 20,767 elderly patients: hypertension and other risk factors. *J Neurosurg* 1995;83(5):812–819.
- [60] Wolters FJ, Rinkel GJ, Vergouwen MD. Clinical course and treatment of vertebrobasilar dolichoectasia: a systematic review of the literature. *Neurol Res* 2013;35(2):131–7.
- [61] Van den Hout JM, Kamphoven JH, Winkel LP, Arts WF, De Klerk JB, Loonen MC, et al. Long-term intravenous treatment of Pompe disease with recombinant human alpha-glucosidase from milk. *Pediatrics* 2004;113(5):e448–57.
- [62] Bijvoet AG, Van Hirtum H, Kroos MA, Van de Kamp EH, Schoneveld O, Visser P, et al. Human acid alpha-glucosidase from rabbit milk has therapeutic effect in mice with glycogen storage disease type II. *Hum Mol Genet* 1999;8(12):2145–53.
- [63] Pichiecchio A, Sacco S, De Filippi P, Caverzasi E, Ravaglia S, Bastianello S, et al. Late-onset Pompe disease: a genetic-radiological correlation on cerebral vascular anomalies. *J Neurol* 2017;264(10):2110–18.
- [64] Ebbink BJ, Poelman E, Aarsen FK, Plug I, Regal L, Muentjes C, et al. Classic infantile Pompe patients approaching adulthood: a cohort study on consequences for the brain. *Dev Med Child Neurol* 2018;60(6):579–86.
- [65] Ebbink BJ, Poelman E, Plug I, Lequin MH, van Doorn PA, Aarsen FK, et al. Cognitive decline in classic infantile Pompe disease: an underacknowledged challenge. *Neurology* 2016;86(13):1260–1.
- [66] Dumor K, Shoemaker-Moyle M, Nistala R, Whaley-Connell A. Arterial stiffness in hypertension: an update. *Curr Hypertens Rep* 2018;20(8):72.
- [67] Cuspidi C, Rescaldani M, Sala C, Grassi G. Left-ventricular hypertrophy and obesity: a systematic review and meta-analysis of echocardiographic studies. *J Hypertens* 2014;32(1):16–25.
- [68] Habes M, Erus G, Toledo JB, Zhang T, Bryan N, Launer LJ, et al. White matter hyperintensities and imaging patterns of brain ageing in the general population. *Brain* 2016;139(Pt 4):1164–79.
- [69] Williams B, Mancia G, Spiering W, Agabiti Rosei E, Azizi M, Burnier M, et al. 2018 ESC/ESH guidelines for the management of arterial hypertension. *Eur Heart J* 2018;39(33):3021–104.
- [70] Saeedi P, Petersohn I, Salpea P, Malanda B, Karuranga S, Unwin N, et al. Global and regional diabetes prevalence estimates for 2019 and projections for 2030 and 2045: results from the International Diabetes Federation Diabetes Atlas, 9(th) edition. *Diabetes Res Clin Pract* 2019;157:107843.

- [71] Prevalence of obesity among adults: World Health Organisation (WHO); 2020 [Available from: [https://www.who.int/data/gho/data/indicators/indicator-details/GHO/prevalence-of-obesity-among-adults-bmi-30-\(crude-estimate\)-\(-\)](https://www.who.int/data/gho/data/indicators/indicator-details/GHO/prevalence-of-obesity-among-adults-bmi-30-(crude-estimate)-(-))].
- [72] Kollberg G, Tulinius M, Gilljam T, Ostman-Smith I, Forsander G, Jotorp P, et al. Cardiomyopathy and exercise intolerance in muscle glycogen storage disease 0. *N Engl J Med* 2007;357(15):1507–1514.
- [73] Pederson BA, Chen H, Schroeder JM, Shou W, DePaoli-Roach AA, Roach PJ. Abnormal cardiac development in the absence of heart glycogen. *Mol Cell Biol* 2004;24(16):7179–87.
- [74] Musumeci O, Bruno C, Mongini T, Rodolico C, Aguenouz M, Barca E, et al. Clinical features and new molecular findings in muscle phosphofructokinase deficiency (GSD type VII). *Neuromuscul Disord* 2012;22(4):325–30.
- [75] Tegtmeier LC, Rust S, van Scherpenzeel M, Ng BG, Losfeld ME, Timal S, et al. Multiple phenotypes in phosphoglucomutase 1 deficiency. *N Engl J Med* 2014;370(6):533–42.
- [76] Timal S, Hoischen A, Lehle L, Adamowicz M, Huijben K, Sykut-Cegielska J, et al. Gene identification in the congenital disorders of glycosylation type I by whole-exome sequencing. *Hum Mol Genet* 2012;21(19):4151–61.
- [77] Laforêt P, Malfatti E, Vissing J. Update on new muscle glycogenosis. *Curr Opin Neurol* 2017;30(5):449–56.
- [78] Moslemi AR, Lindberg C, Nilsson J, Tajsharghi H, Andersson B, Oldfors A. Glycogenin-1 deficiency and inactivated priming of glycogen synthesis. *N Engl J Med* 2010;362(13):1203–10.
- [79] Hedberg-Oldfors C, Glamuzina E, Ruygrok P, Anderson LJ, Elliott P, Watkinson O, et al. Cardiomyopathy as presenting sign of glycogenin-1 deficiency-report of three cases and review of the literature. *J Inher Metab Dis* 2017;40(1):139–49.
- [80] Laforêt P, Richard P, Said MA, Romero NB, Lacene E, Leroy JP, et al. A new mutation in PRKAG2 gene causing hypertrophic cardiomyopathy with conduction system disease and muscular glycogenosis. *Neuromuscul Disord* 2006;16(3):178–82.
- [81] Kanungo S, Wells K, Tribett T, El-Gharbawy A. Glycogen metabolism and glycogen storage disorders. *Ann Transl Med* 2018;6(24):474.
- [82] Tarnopolsky MA. Myopathies related to glycogen metabolism disorders. *Neurotherapeutics* 2018;15(4):915–27.
- [83] El-Gharbawy AH, Bhat G, Murillo JE, Thurberg BL, Kampmann C, Mengel KE, et al. Expanding the clinical spectrum of late-onset Pompe disease: dilated arteriopathy involving the thoracic aorta, a novel vascular phenotype uncovered. *Mol Genet Metab* 2011;103(4):362–6.
- [84] Sacconi S, Wahbi K, Theodore G, Garcia J, Salviati L, Bouhour F, et al. Atrio-ventricular block requiring pacemaker in patients with late onset Pompe disease. *Neuromuscular Disord* 2014;24(7):648–50.
- [85] Francesconi M, Auff E. Cardiac arrhythmias and the adult form of type II glycogenosis. *N Engl J Med* 1982;306(15):937–8.
- [86] Miyamoto Y, Etoh Y, Joh R. Adult-onset acid maltase deficiency in siblings. *Acta Pathol Jpn* 1985;35(6):1533–42.
- [87] Braunsdorf WE. Fusiform aneurysm of basilar artery and ectatic internal carotid arteries associated with glycogenosis Type 2 (Pompe's disease). *Neurosurgery* 1987;21(5):748–9.
- [88] Matsuoka Y, Senda Y, Hirayama M, Matsui T, Takahashi A. Late-onset acid maltase deficiency associated with intracranial aneurysm. *J Neurol* 1988;235(6):371–3.
- [89] Anneser JMH, Pongratz DE, Podskarbi T, Shin YS, Schoser BGH. Mutations in the acid α -glucosidase gene (M. Pompe) in a patient with an unusual phenotype. *Neurology* 2005;64(2):368–70.
- [90] Brettschneider J, Sperfeld AD, Ludolph AC, Kassubek J. Intracerebral hemorrhage in a patient with glycogenosis type II (Pompe disease): is there a pathophysiological relationship? *Muscle Nerve* 2008;38(3):1211–12.
- [91] Laforêt P, Petiot P, Nicolino M, Orlikowski D, Caillaud C, Pellegrini N, et al. Dilative arteriopathy and basilar artery dolichoectasia complicating late-onset Pompe disease. *Neurology* 2008;70(22):2063–6.
- [92] Renard D, Labauge P. Cerebral microbleeds in Pompe disease. *J Neurol Neurosurg Psychiatry* 2010;81(11):1217.
- [93] Fernández C, Legido A, Jethva R, Marks HG. Correction of a short cardiac PR interval in a 12-year-old girl with late-onset Pompe disease following enzyme replacement therapy. *Gen Med* 2012;14(8):757–8.
- [94] Goeber V, Banz Y, Kaerberich A, Carrel T. Huge aneurysm of the ascending aorta in a patient with adult-type Pompe's disease: histological findings mimicking fibrillinopathy. *Eur J Cardiothorac Surg* 2013;43(1):193–5.
- [95] Cerón-Rodríguez M, Zamora A, Erdmenger J, Ureña R, Sánchez AC. First case of a patient with late-onset Pompe disease: cardiomyopathy remission with enzyme replacement therapy. *Bol Med Hosp Infant Mex* 2014;71(1):41–6.
- [96] Peric S, Fumic K, Bilic K, Reuser A, Rakocevic Stojanovic V. Rupture of the middle cerebral artery aneurysm as a presenting symptom of late-onset Pompe disease in an adult with a novel GAA gene mutation. *Acta Neurol Belg* 2014;114(2):165–6.
- [97] Quenardelle V, Bataillard M, Bazin D, Lannes B, Wolff V, Echaniz-Laguna A. Pompe disease presenting as an isolated generalized dilative arteriopathy with repeated brain and kidney infarcts. *J Neurol* 2014;262(2):473–5.
- [98] Sandhu D, Rizvi A, Kim J, Reshi R. Diffuse cerebral microhemorrhages in a patient with adult-onset Pompe's disease: a case report. *J Vasc Interv Radiol Neurol* 2014;7(5):82–5.
- [99] Huded V, Bohra V, Prajapati J, Desouza R, Ramankutty R. Stroke in young – dilative arteriopathy: a clue to late-onset Pompe's disease? *J Stroke Cerebrovasc Dis*. 2016;25(4):e50–ee2.
- [100] Zhang B, Zhao Y, Liu J, Li L, Shan J, Zhao D, et al. Late-onset Pompe disease with complicated intracranial aneurysm: a Chinese case report. *Neuropsychiatr Dis Treat* 2016;12:713–17.
- [101] Malhotra K, Carrington DC, Liebeskind DS. Restrictive arteriopathy in late-onset Pompe disease: case report and review of the literature. *J Stroke Cerebrovasc Dis* 2017;26(8):e172–e1e5.
- [102] Walczak-Galezewska M, Skrypnik D, Szulinska M, Musialik K, Skrypnik K, Bogdanski P. Late-onset Pompe disease in a 54 year-old sportsman with an episode of syncope: a case report. *Eur Rev Med Pharmacol Sci* 2017;21(16):3665–7.
- [103] Hossain MA, Miyajima T, Akiyama K, Eto Y. A case of adult-onset Pompe disease with cerebral stroke and left ventricular hypertrophy. *J Stroke Cerebrovasc Dis* 2018;27(11):3046–52.
- [104] Pappa E, Papadopoulos C, Grimbert P, Laforêt P, Bassez G. Renal artery fibromuscular dysplasia in Pompe disease: a case report. *Mol Genet Metab Rep* 2018;16:64–5.