

E.U. paediatric MOG consortium consensus: Part 1 – Classification of clinical phenotypes of paediatric myelin oligodendrocyte glycoprotein antibody-associated disorders



Arlette L. Bruijstens^{a, *}, Christian Lechner^b, Lorraine Flet-Berliac^c, Kumaran Deiva^{c, d}, Rinze F. Neuteboom^a, Cheryl Hemingway^{e, 1}, Evangeline Wassmer^{f, 1}, on behalf of the E.U. paediatric MOG consortium²

^a Department of Neurology, Erasmus Medical Center, Rotterdam, the Netherlands

^b Department of Paediatrics, Division of Paediatric Neurology, Medical University of Innsbruck, Austria

^c Department of Paediatric Neurology, Assistance Publique-Hôpitaux de Paris, University Hospitals Paris-Saclay, Bicêtre Hospital and Faculty of Medicine, Paris-Saclay University, Le Kremlin Bicêtre, France

^d French Reference Network of Rare Inflammatory Brain and Spinal Diseases, Le Kremlin Bicêtre, European Reference Network-RITA, France

^e Department of Paediatric Neurology, Great Ormond Street Hospital for Children, London, UK

^f Department of Paediatric Neurology, Birmingham Children's Hospital, Birmingham, UK

ARTICLE INFO

Article history:

Received 30 July 2020

Received in revised form

13 October 2020

Accepted 14 October 2020

Keywords:

Myelin-oligodendrocyte glycoprotein

Children

Acute disseminated encephalomyelitis

Optic neuritis

Transverse myelitis

Encephalitis

ABSTRACT

Over the past few years, increasing interest in the role of autoantibodies against myelin oligodendrocyte glycoprotein (MOG-abs) as a new candidate biomarker in demyelinating central nervous system diseases has arisen. MOG-abs have now consistently been identified in a variety of demyelinating syndromes, with a predominance in paediatric patients. The clinical spectrum of these MOG-ab-associated disorders (MOGAD) is still expanding and differs between paediatric and adult patients. This first part of the Paediatric European Collaborative Consensus emphasises the diversity in clinical phenotypes associated with MOG-abs in paediatric patients and discusses these associated clinical phenotypes in detail. Typical MOGAD presentations consist of demyelinating syndromes, including acute disseminated encephalomyelitis (ADEM) in younger, and optic neuritis (ON) and/or transverse myelitis (TM) in older children. A proportion of patients experience a relapsing disease course, presenting as ADEM followed by one or multiple episode(s) of ON (ADEM-ON), multiphasic disseminated encephalomyelitis (MDEM), relapsing ON (RON) or relapsing neuromyelitis optica spectrum disorders (NMOSD)-like syndromes. More recently, the disease spectrum has been expanded with clinical and radiological phenotypes including encephalitis-like, leukodystrophy-like, and other non-classifiable presentations. This review concludes with recommendations following expert consensus on serologic testing for MOG-abs in paediatric patients, the presence of which has consequences for long-term monitoring, relapse risk, treatments, and for counselling of patient and families. Furthermore, we propose a clinical classification of paediatric MOGAD with clinical definitions and key features. These are operational and need to be tested, however essential for future paediatric MOGAD studies.

© 2020 The Authors. Published by Elsevier Ltd on behalf of European Paediatric Neurology Society. This is an open access article under the CC BY license (<http://creativecommons.org/licenses/by/4.0/>).

* Corresponding author. Erasmus Medical Center, Department Medical Faculty, Room Number EE-2230, P.O. 2040, 3000, CA, Rotterdam, the Netherlands.

E-mail address: a.bruijstens@erasmusmc.nl (A.L. Bruijstens).

¹ Shared last senior author.

² E.U. paediatric MOG consortium: Eva-Maria Wendel, Frederik Bartels, Carsten Finke, Markus Breu, Aliénor de Chalus, Catherine Adamsbaum, Marco Capobianco, Giorgi Laetitia, Yael Hacohen, Ming Lim, Matthias Baumann, Ronny Wickström, Thais Armangue, Kevin Rostasy.

Contents

1. Introduction	3
2. Frequency and general characteristics of paediatric MOGAD	3
2.1. Incidence and prevalence of MOG-abs in paediatric ADS and frequency of MOGAD presentations	3
2.2. General characteristics of paediatric MOGAD and age dependency	4
3. Typical clinical phenotypes of paediatric MOGAD	4
3.1. Acute disseminated encephalomyelitis (ADEM)	4
3.2. Optic neuritis (ON)	5
3.3. (Longitudinally extensive) transverse myelitis ((LE)TM)	5
3.4. Neuromyelitis optica spectrum disorders (NMOSD)-like phenotype	6
4. Relapsing phenotypes	6
4.1. Multiphasic disseminated encephalomyelitis (MDEM)	7
4.2. ADEM-ON	7
4.3. Relapsing ON (RON)	7
4.4. Relapsing NMOSD-like phenotype	7
5. Emerging and atypical clinical phenotypes	7
5.1. Encephalitis, overlapping syndromes and seizures	7
5.2. Leukodystrophy-like phenotype	8
5.3. Combined central and peripheral demyelination in MOGAD	8
5.4. Non-classifiable clinical phenotypes	9
6. Conclusion	9
7. Expert consensus recommendations	9
Funding sources	10
Declaration of competing interest	10
References	11

Abbreviations

ADS	acquired demyelinating syndrome
ADEM	acute disseminated encephalomyelitis
ADEM-ON	ADEM followed by monophasic or recurrent ON
AE	autoimmune encephalitis
AQP4-ab	aquaporin-4 antibody
CNS	central nervous system
CRION	chronic relapsing inflammatory optic neuropathy
(LE)TM	(longitudinally extensive) transverse myelitis
MOG-ab	myelin oligodendrocyte glycoprotein antibody
MOGAD	MOG-antibody-associated disorders
MOG-ON	MOG-ab-associated ON
MOG-TM	MOG-ab-associated TM
MDEM	multiphasic disseminated encephalomyelitis
NMOSD	neuromyelitis optica spectrum disorders
OCT	optical coherence tomography
ON	optic neuritis
RNFL	retinal nerve fibre layer
RON	relapsing ON

1. Introduction

Paediatric acquired demyelinating syndromes (ADS) consist of a broad spectrum of immune-mediated demyelinating diseases of the central nervous system (CNS), including acute disseminated encephalomyelitis (ADEM), optic neuritis (ON), transverse myelitis (TM), neuromyelitis optica spectrum disorders (NMOSD) and multiple sclerosis (MS). Diagnosis of the specific phenotype at initial presentation can be challenging, as the situation frequently evolves over time [1–4]. The discovery of pathogenic serum autoantibodies targeted against aquaporin-4 (AQP4-abs) in 2004

enables their use as a diagnostic marker for AQP4-ab-positive NMOSD [5]. Over the past few years, there has been increasing interest in the role of autoantibodies against myelin oligodendrocyte glycoprotein (MOG-abs) as a candidate biomarker in demyelinating CNS diseases [6,7]. These antibodies target MOG, which is expressed exclusively on the outer surface of the myelin sheath and plasma membrane of oligodendrocytes [8,9]. Although MOG represents only a minor component of myelin (0.5%), it is a likely target for autoantibodies in a demyelinating disease due to its CNS specificity and highly immunogenic location [6,9]. While initially MOG-abs were thought to be a possible biomarker for MS, following improvements in assay design [10], multiple studies have established that MOG-abs are present only in a small proportion of MS patients [11–13]. Indeed, nowadays it is widely accepted that the presence of MOG-abs indicates a different disease and argues against an MS diagnosis [12,14].

MOG-abs have consistently been identified in an expanding spectrum of demyelinating syndromes, with predominance and increased heterogeneity in paediatric patients [15–17]. Therefore, this first part of the Paediatric European Collaborative Consensus will focus on the classification of the different paediatric clinical phenotypes within MOG-ab-associated disorders (MOGAD). Furthermore, consensus recommendations on serologic testing for MOG-abs in the paediatric population are included as guidance for clinicians in daily practice, as early diagnosis is relevant for accurate disease monitoring and treatment strategies.

2. Frequency and general characteristics of paediatric MOGAD

2.1. Incidence and prevalence of MOG-abs in paediatric ADS and frequency of MOGAD presentations

MOGAD are rare, with a higher incidence in paediatric compared to adult patients. A recent Dutch study reported a mean

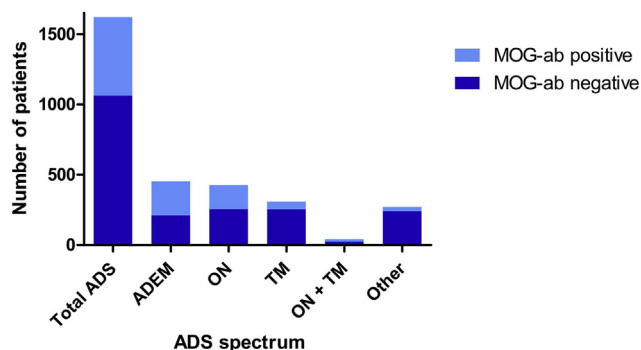


Fig. 1. ADS presenting phenotype, divided for MOG-ab-positive and negative patients [11–14,17–23].

ADEM = acute disseminated encephalomyelitis, ADS = acquired demyelinating syndrome, MOG-ab = myelin oligodendrocyte glycoprotein antibody, ON = optic neuritis, TM = transverse myelitis.

incidence of 0.31 per 100.000 children (95% CI 0.17–0.51), compared to 0.13 per 100.000 adults per year (95% CI 0.08–0.19) [17]. A recent review of 61 studies also described a higher prevalence of MOG-abs in paediatric (40%) compared to mixed (29%) and adult (22%) cohorts [16].

Various studies have determined the prevalence of MOG-abs within paediatric ADS [11–14,17–24], using the reliable live cell-based assay (CBA) [10]. According to pooled data of these 11 studies, MOG-abs are present in one third of all paediatric patients with ADS (34%; Fig. 1). Focusing on the different presenting phenotypes, these studies have shown that MOG-abs are predominantly found in patients presenting with ADEM (53%, range 33–65%), ON (40%, range 10–67%), and TM (18%, range 0–35%). An NMOSD-like phenotype with combination of ON and TM as presenting symptom is only reported in a limited number of ADS patients, with MOG-abs detected in 40% of these patients, however varying from 25 to 100% between studies [11,13,14,21,23].

The different clinical presentations of paediatric MOGAD at disease onset are shown in Fig. 2 [11–14,17,20–27]. Summarising data of these 13 studies, the most common include ADEM (46%), ON (30%), TM (11%) and NMOSD-like phenotype with simultaneous ON and TM (4%). Together these clinical presentations comprise already more than 90% of all phenotypes encompassed by paediatric MOGAD and will be discussed in detail below.

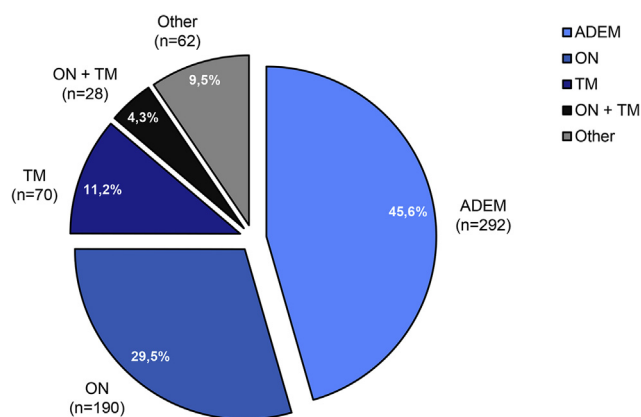


Fig. 2. Presenting clinical phenotypes within the paediatric MOGAD [11–13,17,20–27]. ADEM = acute disseminated encephalomyelitis, MOGAD = MOG-antibody-associated disorders, ON = optic neuritis, TM = transverse myelitis.

2.2. General characteristics of paediatric MOGAD and age dependency

The majority of patients in studies with MOGAD are of Caucasian descent [12,17,28,29], which most likely represents population rather than a true ethnicity bias as seen in AQP4-ab-positive disease [30]. Boys and girls are almost equally distributed, with only a slight preponderance of females in older children [11–14,17,20,23,26,28,29,31], in contrast to the female preponderance in both MS [32] and AQP4-ab-positive NMOSD [30,33]. Comparing paediatric ADS patients with and without MOG-abs, paediatric MOGAD patients are younger [11,13,14,20,28]. This difference may be due to the high number of ADEM patients within the MOGAD, who are generally the youngest among all ADS patients, and therefore could skew the age distribution. The fact that paediatric ADEM, ON and NMOSD patients with and without MOG-abs do not differ in age, supports this [31,33–37].

The presenting clinical phenotype of MOG-ab-positive patients appears to be strongly dependent on age at onset, with brain involvement seen more commonly in younger children (including ADEM and ADEM-like phenotypes), and an optospinal phenotype (including ON and/or TM or brainstem involvement) more often in older children [13,25,28], and adult patients [17,38–41]. The transition of this bimodal distribution seems to be around the age of nine [16]. As MOG is only expressed during late stages of myelination, it is thought to play a role in maturation of the CNS [42]. This age dependency of presenting clinical phenotype may represent a changing MOG expression during different stages of brain development and CNS maturation in childhood [7,25,28].

3. Typical clinical phenotypes of paediatric MOGAD

3.1. Acute disseminated encephalomyelitis (ADEM)

The heterogeneous clinical syndrome ADEM predominantly occurs in early childhood and is characterised by encephalopathy, polyfocal neurological deficits and typical magnetic resonance imaging (MRI) abnormalities, which can fluctuate during the acute phase (up to three months after disease onset) [2,43,44]. The presence of encephalopathy, defined by the International Paediatric Multiple Sclerosis Society Group (IPMSSG) as an altered consciousness or behavioural changes, both not explained by fever, is required for a diagnosis of ADEM [2]. This requirement is essential, because it distinguishes ADEM from other ADS.

ADEM is the most frequent type of paediatric MOGAD, but there is only one study comparing paediatric ADEM patients with and without MOG-abs. This study included 19 MOG-ab-positive and 14 negative patients [31]. Almost all these ADEM patients presented with altered consciousness due to encephalopathy, which was not different between MOG-ab-positive and negative patients. However, ADEM patients with MOG-abs presented less frequently with emotional or behavioural problems as representation of encephalopathy, compared to patients without MOG-abs (5% vs. 43%). Interestingly, besides a higher number of white blood cells in cerebrospinal fluid (CSF) in MOG-ab-positive patients, the remaining demographic and clinical characteristics at onset of disease, including age, sex ratio and other clinical symptoms, could not discriminate ADEM patients with MOG-abs from those without. Based on the MRI comparison however, the MOG-ab-positive patients more often had spinal cord involvement compared to MOG-ab-negative patients (93% vs. 33%). Remarkably, only 62% of the MOG-ab-positive patients with spinal involvement suffered from spinal symptoms, compared to 100% of the MOG-ab-negative patients with spinal involvement [32].

Although ADEM patients generally have a favourable long-term

prognosis, mainly based on recovery of motor function, there is a risk of long-term cognitive impairment [45,46,123], and a higher risk of post-ADEM epilepsy in MOG-ab-positive compared to MOG-ab-negative patients [47]. While ADEM patients typically have a monophasic disease course, relapses can occur in the MOG-ab-positive ADEM patients [31]. These relapsing clinical phenotypes after ADEM are discussed later.

In conclusion, up to 50% of paediatric ADEM patients are MOG-ab positive and ADEM is the most common presenting clinical phenotype of paediatric MOGAD. Although there are a few clinical and radiological differences between ADEM patients with and without MOG-abs, it still is not possible to distinguish these patients at onset of disease based on these features alone.

3.2. Optic neuritis (ON)

The inflammation of the optic nerve(s) in ON causes unilateral or bilateral visual problems, typically including visual loss, central scotoma or reduced visual fields and impaired colour vision, and is often accompanied with painful eye movements [32]. Paediatric MOG-ab-positive patients presenting with ON predominantly are adolescents between 13 and 18 years of age [13,25,28,47]. In patients with ON as clinically isolated syndrome, paediatric ON has different clinical features than ON in adults (most likely representing MS patients), regarding severity, bilateral vs. unilateral, and presence of disc oedema [48]. Studies exclusively analysing paediatric patients with MOG-ab-associated ON (MOG-ON) are limited.

The only three paediatric studies available, one European and two large Asian cohorts, showed that the majority of the paediatric MOG-ON patients had severe visual loss at onset, with a visual acuity (VA) of ≤ 0.1 at nadir, which is comparable to the vision loss at nadir of paediatric AQP4-ab-positive, double seronegative (i.e. MOG-ab and AQP4-ab-negative) and MS patients with ON [35,37,49]. However, after six months follow-up the MOG-ab-positive patients made a good recovery with a functional VA of ≥ 0.5 in 98% of patients [36], and ≥ 0.8 in 89% of patients [35], which is significantly better than AQP4-ab-positive, but comparable with double seronegative and MS patients with ON [35,37,49].

Simultaneous bilateral optic nerve involvement has been reported in most studies in more than 50% of paediatric MOG-ab-positive patients [20,35–37,49], although lower numbers have also been reported (29–38%) [17,23,33], and mixed paediatric and adult cohorts showed that bilateral involvement is more often seen in adult MOG-ab-positive patients [17,40,41]. Such bilateral involvement is atypical for MS [50]. In addition, a recent study showed that 73% of paediatric patients presenting with bilateral ON had MOG-abs [51]. Furthermore, a substantial proportion of paediatric MOG-ON patients presented with prominent optic disc oedema (60–90%), due to anterior involvement of the optic nerve in these patients [35,37,41]. Unlike in adults, disc oedema did not distinguish MOG-ab-positive from AQP4-ab-positive and double seronegative paediatric ON patients [35,37]. Additionally, besides the anterior optic nerve inflammation, MRI images of MOG-ON showed high rates of longitudinal involvement of the optic nerve in mixed paediatric and adults cohorts (90%), with relative sparing of the chiasm and optic tracts [41,48,50–53,124]. The latter being important since this is different from ON associated with AQP4-abs, where patients more often have chiasmal and optic tract involvement [50]. Additionally, perineural enhancement and inflammation of soft orbital tissues on MRI has been described in up to 50% of (mainly) adult patients presenting with MOG-ON [54–58], distinguishing MOG-ab-positive from AQP4-ab-positive and MS patients with ON [56,58]. This phenotype can be referred to as “ON plus phenotype”.

A proportion of these ON patients will experience further

relapses. The relapsing clinical phenotypes following ON are discussed later in more detail. Importantly, although in general the functional VA of MOG-ON patients recovers well, optical coherence tomography (OCT) scans showed signs of severe axonal damage, which was as severe as observed in AQP4-ab-positive patients [35,49,59], and was not or only partly correlated to the number of ON episodes [35,49,123].

In conclusion, paediatric MOG-ON patients are mainly adolescents who have severe visual loss at onset of disease, often with optic disc oedema and in about half of them simultaneous bilateral ON. These patients usually have a good functional visual recovery, although OCT scans reveal indication of permanent axonal damage.

3.3. (Longitudinally extensive) transverse myelitis ((LE)TM)

Patients with (LE)TM can present with motor and sensory deficits, which are often bilateral and include a sensory level, and/or bladder and bowel dysfunction, progressing within hours to days [32]. Due to the rarity of MOG-ab-associated TM (MOG-TM) in childhood, literature on this specific MOGAD phenotype in paediatric patients is sparse, without any studies comparing paediatric TM patients with and without MOG-abs.

However, one retrospective study included 54 patients with MOG-TM patients, among them 16 paediatric patients (30%), with isolated TM (54%) or TM as part of a multifocal disease presentation with ADEM (17%) or ON (6%) [60]. Similar to the ON patients, almost all TM patients had a severe disease at onset including prominent motor and sensory deficits, with one third of patients being wheelchair bound. Furthermore, 85% of these patients presented with neurological bowel and bladder dysfunction, and additionally 54% of male patients with erectile dysfunction, probably attributable to the often longitudinally extensive lesion with frequent conus involvement observed on MRI in these patients (41%). This conus involvement has also been demonstrated in 37% of all paediatric MOG-ab-positive patients presenting with spinal cord lesions [24]. While LETM is also characteristic for AQP4-ab-associated TM, conus involvement is more typical for MOG-TM [33,60–62]. Interestingly, 19% of patients of the above described retrospective study presented with a flaccid areflexia, which can be explained by the predilection for the central grey matter in MOG-TM, also typical for AQP4-ab-associated TM, but atypical for MS-associated TM [60].

Regardless of the disease severity at onset, most of these MOG-TM patients showed a good motor recovery [60], which may be better than the recovery in TM patients without MOG-abs, as previous paediatric TM cohorts with unknown MOG-ab serostatus reported worse outcomes [63,64]. However, bowel, bladder and/or erectile residual symptoms are common [60,123]. A proportion of MOG-TM patients have recurrent episodes during follow-up, described in around 17% of adult [27,39], and 0–14% of paediatric MOG-TM patients [14,22,33]. Furthermore, patients presenting with MOG-TM may have other relapses during follow-up, e.g. ON, extending the MOGAD phenotype to an NMOSD-like phenotype, also reported in around 14% of paediatric patients [33].

In conclusion, isolated TM only covers a small part of the paediatric MOGAD. MOG-TM often causes severe deficits at onset, including motor, sensory, and bowel, bladder and/or erectile impairment. Patients often have a LETM, in contrast to MS patients. Moreover, conus involvement can distinguish them from AQP4-ab-positive patients. Although patients make a good motor recovery, bowel, bladder and/or erectile residual symptoms are common and important features to discuss with the patient and to monitor during follow-up, besides the long-term monitoring for potential relapses.

3.4. Neuromyelitis optica spectrum disorders (NMOSD)-like phenotype

Neuromyelitis optica (NMO) initially was characterised by recurrent uni- or bilateral ON and (LE)TM. In 2015, the spectrum was broadened by inclusion of brainstem syndromes and limited forms of NMO, altogether referred to as NMO spectrum disorders (NMOSD) [4,65]. Although the presence of AQP4-abs was added as a supportive diagnostic criterion, these antibodies are rare in childhood, only found in 3–6% of ADS [13,22] and 11% of NMOSD patients [33]. In contrast, MOG-abs are found in one third of paediatric ADS and in 56% of paediatric patients with an NMOSD-like phenotype [33].

As described above, ON and (LE)TM can occur either as isolated clinical MOGAD phenotypes, or simultaneously, representing an NMOSD-like phenotype at onset of disease. Interestingly, in a study analysing paediatric NMOSD(-like) patients, none of the AQP4-ab-positive patients had concomitant ON and (LE)TM, in contrast to 85.7% of MOG-ab-positive patients [33]. This simultaneous phenotype has been observed in adult MOG-ab-positive patients in lower percentages (around 40%) [62,66,67], but still was a discriminative feature from AQP4-ab-positive NMOSD [66].

Since broadening NMO to NMOSD, brainstem involvement with inflammation of the area postrema is included as feature of AQP4-ab-positive NMOSD [65]. Area postrema syndrome (APS) causes intractable nausea, vomiting and/or unexplained hiccups, and is thought to be highly specific for AQP4-abs [68]. However, adult studies with MOG-ab-positive patients also reported brainstem involvement in 10–30% [18,70], e.g. with cranial nerve deficits, ataxia, respiratory insufficiency, and also nausea and vomiting as clinical symptoms [70]. In contrast, in paediatric MOG-ab-positive patients, isolated brainstem syndromes or brainstem involvement ever during disease course were only rarely observed (0–3% and 0–4%, respectively) [17,33], and evidently more often seen in the paediatric AQP4-ab-positive patients (20% and 60%, respectively) [33]. Lastly, as described above, both AQP4-ab and MOG-ab-positive patients can experience symptoms of APS (nausea, vomiting and/or hiccups), but in MOG-ab-positive patients these symptoms rarely seem to be attributed to inflammation of the area postrema, as seen in AQP4-ab-positive NMOSD, but may be due to disruption of anatomical connections to the vomiting centre [70]. Therefore, pure APS with inflammation of the area postrema remains a typical feature for AQP4-ab-positive NMOSD.

Despite clinical overlap between AQP4-ab-positive NMOSD and MOG-ab-associated NMOSD-like phenotypes, differences exist as summarised in Table 1. Importantly, the underlying immunological disease mechanisms of both antibody-associated diseases is different, with AQP4-abs targeting astrocytes and MOG-abs targeting oligodendrocytes, resulting in astrocytopathy and oligodendrocytopathy, respectively [71–73]. Additionally, differences in human leukocyte antigen association are found, suggestive of a distinctive underlying immunogenetic background [74]. There is an ongoing debate about the nosology of these disorders [75,76], although many argue for a separation of MOGAD from AQP4-ab-positive NMOSD [15,33,34,77–80].

In conclusion, AQP4-ab-positive NMOSD is rare in paediatric patients, and NMOSD-like phenotypes with MOG-abs are more common [81]. Typical for MOGAD is simultaneous ON and TM. While adult patients may have brainstem involvement, this is rare for paediatric patients. An area postrema syndrome attributable to inflammation in the area postrema is rare and remains a typical feature of AQP4-ab-positive NMOSD.

4. Relapsing phenotypes

The frequency of relapses among all paediatric MOG-ab-positive patients ranges widely between studies, because of e.g. differences in follow-up time, study design (retro- vs. prospective) and patient selection (nationwide coverage vs. secondary academic centres). Recent studies, with longer follow-up duration, have revealed increasing evidence for a multiphasic disease course in a subset of MOG-ab-positive patients [13,14,82]. Patients who remain seropositive during follow-up appear at higher risk for relapse compared to the patients who convert to a seronegative status (38% vs. 13%, respectively) [14]. Additionally, older age has been found to be strongly associated with a relapsing disease course [14,123].

In 2018, the European Paediatric Demyelinating Disease Consortium studied 102 MOG-ab-positive patients with a relapsing disease course [83]. Median follow-up was five years. This cohort included multiphasic disseminated encephalomyelitis (MDEM; 20%), ADEM followed by one or more ON episode(s) (ADEM-ON; 20%), relapsing ON (RON; 18%) and relapsing NMOSD (43%). Interestingly, the same age dependency of clinical phenotype was observed for the relapses, with MDEM and ADEM-ON in the younger, and RON and NMOSD in the older patients, again with the division between these phenotypes around the age of nine.

Table 1
Differences between paediatric AQP4-ab-positive NMOSD and MOG-ab-associated NMOSD-like phenotypes.

	NMOSD-like phenotypes	AQP4-ab+
	MOG-ab+	
Demographics	More often in paediatric patients Equal distribution boys/girls No association with other AID	Rare in paediatric patients Predominance in girls Association with other AID
Clinical phenotypes		
*ON	* Bilateral, longitudinally extensive with anterior involvement (disc oedema ^a)	* Longitudinally extensive with chiasma/optic tract involvement
*TM	* LETM with conus involvement	* LETM with cervico-thoracic spinal cord involvement
*NMOSD(-like)	* Often simultaneous ON and TM, area postrema syndrome is rare	* Area postrema syndrome, isolated brainstem syndrome
Severity at onset	Severe	Severe
Recovery	Promptly after steroids and often completely, except for axonal damage on OCT (ON) and bowel/bladder problems (TM)	High risk for poor recovery
Disease course	More often monophasic, but relapses are possible	Relapsing

AID = autoimmune disease, AQP4-ab = aquaporin-4 antibody, LETM = longitudinally extensive transverse myelitis, MOG-ab = myelin oligodendrocyte glycoprotein antibody, NMOSD = neuromyelitis optica spectrum disorders, OCT = optical coherence tomography, ON = optic neuritis, TM = transverse myelitis, + = positive, - = negative.

^a Discriminative feature for MOG-abs and AQP4-abs in mixed paediatric and adult studies, but not in paediatric studies exclusively.

4.1. Multiphasic disseminated encephalomyelitis (MDEM)

ADEM, whilst usually monophasic, can present as a relapsing form, known as MDEM [2]. Almost all MDEM patients are MOG-ab positive [11,13,14,21,31]. Importantly, clinical symptoms and radiologic features can fluctuate during the acute phase of ADEM (up to three months) [2], mainly during weaning off immunomodulatory treatment. Therefore, during this acute ADEM period it is important to be aware of the possibility of a “flare-up”, which does not reflect a true relapse [125]. A relapse was defined by the consensus group as a new clinical episode accompanied by radiological evidence depending on the subtype of MOGAD, appearing at least one month subsequently to the last acute attack. On the contrary, a “flare-up” was defined by the consensus group as re-occurrence of symptoms within one month (and up to three months in ADEM patients) after start of acute treatment and not meeting definition of a relapse.

The first study describing multiple MDEM patients was published in 2016 [84]. In total, only eight MDEM patients were identified from 295 paediatric ADS patients including 59 ADEM patients, and all eight were MOG-ab-positive. These numbers are comparable to the reported number of MDEM patients in other paediatric ADS cohorts, in whom almost all had positive MOG-abs [11,13,14,22,30]. Remarkable is the heterogeneity between MDEM patients, observed in the initial eight patients [84], but also in the 20 MOG-ab-positive MDEM patients identified from the European Paediatric Demyelinating Disease Consortium [83]. Although IPSSG criteria for MDEM are limited to only two ADEM episodes [2], studies with MOG-ab-positive MDEM patients have shown that these patients may have only one relapse, but can also have multiple, with more than ten documented in certain cases [83,84]. Most patients had a new attack within two years after onset, but new attacks also occurred years later. In these cohorts with MDEM patients, 25–50% of patients had a good recovery, but the remaining patients had mild to moderate impairment, including cognitive deficits, motor deficits or seizures [83,84]. Every new relapse with new brain demyelination might increase the risk of secondary neuroaxonal injury, and consequently, risk of poor outcome might depend on number of relapses [42]. However, this hypothesis has not been investigated systematically in paediatric patients yet.

4.2. ADEM-ON

A subgroup of children with initial ADEM presentation continue to have demyelinating episode(s) limited to the optic nerve (ADEM-ON) [83]. As for MDEM, during the acute phase of ADEM (up to three months) the possibility of a “flare-up”, instead of a true relapse, should be considered [125], as optic nerve involvement can also occur during the acute phase of ADEM [2,31].

The majority of these ADEM-ON patients are MOG-ab positive [11,13,22,31,85,86]. Like MDEM, this ADEM-ON phenotype is rare and characteristics of these patients have only been described previously in detail in seven patients from Germany [84] and more recently in 20 patients from the European Paediatric Demyelinating Disease Consortium [86]. The heterogeneity among ADEM-ON patients is comparable to MDEM patients; the number of relapses ranged from one to nine per patient, and the interval between relapses ranged from three months to even 20 years in one patient [85,86]. Furthermore, relapses occurred in patients after a long steady period without treatment, but also in patients on treatment [86]. In a high proportion of patients (60–70%), visual residual deficits were reported [85,85], which were not related to the number of relapses, at least not in this small sample size [87]. Importantly, in the ADEM patients with further relapses, a shorter time to first relapse [86] as well as a persistent MOG-ab positivity

during follow-up [34] were found to both increase the risk of (further) relapses, the latter arguing for longitudinal MOG-ab testing for prediction of relapse risk [10,123].

4.3. Relapsing ON (RON)

As the majority of adult patients already present with ON, RON is the most frequent relapsing phenotype in adulthood [34,41], while in childhood, an ON relapse can result in ADEM-ON, relapsing NMOSD-like phenotype, or RON as final diagnosis [13,41,42].

In 2012, a study reported that a proportion of MOG-ab-positive children with ON will experience further relapse(s), and suggested that these patients represent a separate subgroup distinct from MS or NMOSD [19]. Subsequently, several studies confirmed that paediatric MOG-ON patients show higher rates of recurrence compared to paediatric MOG-ab-negative [36,38] and MS patients with ON [48]. These relapses have been shown to be highly steroid-responsive, or even steroid-dependent. Therefore, relapsing MOG-ab-positive patients often meet criteria for chronic relapsing inflammatory optic neuropathy (CRION) [41,53,86,87].

Compared to other paediatric relapsing MOGAD, RON patients had a similar number of relapses, but a slightly longer time to their first relapse, and more often a good outcome, defined as expanded disability status scale (EDSS) score of 0 [82,123].

4.4. Relapsing NMOSD-like phenotype

Patients who present with an NMOSD-like phenotype at onset of disease can experience further relapses during disease course, mainly ON or simultaneous ON and (LE)TM [82]. Furthermore, also patients initially presenting with isolated ON or (LE)TM may have subsequent relapse(s), converting to a relapsing NMOSD-like phenotype during follow-up [32]. Finally, some patients presenting with ADEM also convert to this phenotype due to further relapses with for example simultaneous ON and (LE)TM, or sequential relapses with ON as well as (LE)TM [12,21,33,82].

From all paediatric patients with NMOSD (fulfilling Wingerchuk diagnostic criteria [64]) or limited forms of NMOSD (including LETM, bilateral ON, brainstem syndromes or RON), only half of the MOG-ab-positive patients relapsed, compared to 100% of AQP4-ab-positive patients [32]. While adult studies have shown better outcome in MOG-ab-positive than AQP4-ab-positive patients [38], no differences in outcome between these groups in paediatric patients were observed regarding VA and EDSS, possibly due to limited number of AQP4-ab-positive patients included in this study (n = 5), related to the rarity in childhood [32].

5. Emerging and atypical clinical phenotypes

Due to the continuing research in this field, MOG-abs are consistently identified within new disease presentations, thus expanding the spectrum of MOGAD. These disease presentations are overall rare and include less common or atypical demyelinating phenotypes, and phenotypes beyond the demyelinating syndromes.

5.1. Encephalitis, overlapping syndromes and seizures

A number of case series [88–95] and retrospective studies [97–99] have reported an association between MOG-abs and encephalitis, mainly in adult, but also more recently in paediatric patients [99]. ADEM and encephalitis are both characterised by encephalopathy. However, ADEM typically includes demyelinating features with clinically ON and/or TM, and on neuroimaging poorly demarcated widespread lesions of predominantly white matter and

deep grey matter, while in typical encephalitis brain MRI shows cortical lesions or no abnormalities at all [2,102,102]. The reported (mainly adult) patients with encephalitis and MOG-abs presented with seizures, headache and/or fever, with uni- or bilateral cortical lesions on brain MRI, also referred to as “cortical encephalitis” [89–99].

Recently, this association between MOG-abs and encephalitis has been explored further in two paediatric studies [24,103], including one large prospective, multicentre, observational paediatric cohort study from Spain [23]. In this study, among the 296 patients with definite or possible encephalitis (according to international criteria [103]), 7% had MOG-abs [23]. Even more interesting, among the 64 patients with autoimmune encephalitis (AE, excluding encephalitis patients with an infectious or unknown cause), 34% of patients had MOG-abs, which was more common than all neuronal antibodies combined (33%; 22% had N-methyl-D-aspartate-receptor (NMDAR)-abs). MOG-ab-positive patients with encephalitis clinically showed impaired consciousness (100%), seizures (64%; 45% with status epilepticus), fever (59%), and abnormal behaviour (50%) and movements (36%). Brain MRI showed cortical involvement in 73% of patients, which was extensive and bilateral in most of these patients (75%), and additional or isolated basal ganglia or thalamic involvement in 41% of patients. Only 9% of these patients had no radiological abnormalities, which is clearly lower than reported for other forms of AE, e.g. in anti-NMDAR encephalitis, 55% of patients had a normal MRI [103]. Within a median follow-up of 42 months, 23% of MOG-ab-positive patients with encephalitis had further relapses, including a demyelinating syndrome (ON or TM) in 80% of these relapsing patients [22]. This is in line with above-mentioned case reports and retrospective studies reporting MOG-ab-positive patients with encephalitis, in which patients frequently, but not always, experienced prior, accompanying or subsequent clinical and/or radiological demyelinating events beside the cortical encephalitis event(s) [88,89,91–93,95–98,101].

Whether MOG-abs are the causative agent of the encephalitis and cortical lesions remains to be determined. Only a few studies reported additional pathological findings in these patients, which are inconsistent. The brain autopsy of one deceased patient showed multiple predominantly cortical demyelinating lesions [90], while evidence for demyelination was absent in the brain biopsies of two other cases [89,92]. This absence of demyelination could be due to the biopsy taken in the very early stage of disease, before fulminant demyelination [92]. However, it could also suggest that another autoantibody is responsible for the encephalitis and may coexist with MOG-abs [90,97], which in its turn is responsible for the additional demyelinating features in the majority of these patients. Such overlapping syndromes with MOG-abs and other autoantibodies have been described, mainly in patients with anti-NMDAR encephalitis, both in adult [105–110] and paediatric patients [102,105,107,111–113]. These patients had either concurrent or separate episodes compatible with anti-NMDAR encephalitis (mainly clinically) or MOGAD (mainly radiologically) [113], and had more relapses compared to anti-NMDAR encephalitis patients without MOG-abs [111,112]. Additionally, an overlapping syndrome with MOG-abs and Glycine receptor antibodies has also been described in a limited number of paediatric patients [23].

Although seizures most often occur during an encephalitis episode (including ADEM, cortical encephalitis or overlap syndrome with anti-NMDAR encephalitis), isolated seizures have been described in both adult and paediatric MOG-ab-positive patients [41,114,115]. These patients had an unremarkable brain MRI at onset, but all developed typical demyelinating events with MRI abnormalities during follow-up, with persisting MOG-abs.

Although the interval between the isolated seizures and a new demyelinating event ranged from months to years, these subsequent demyelinating events are suggestive of an underlying immunological pathogenesis that was potentially already present at onset of the isolated seizures [114]. Although no inflammatory involvement of the cortex was observed in any of these patients during onset, such cortical lesions could have been missed with regular brain MRI. If indeed an immunological pathogenesis underlies these seizures, this may have important treatment implications. Importantly, isolated seizures after an encephalitis episode will not always represent new inflammatory activity but can also be the result of cortical damage from the initial episode.

Altogether, although the underlying pathophysiology has not been fully elucidated yet, MOG-abs are found in a significant subset of paediatric patients presenting with AE other than ADEM, expanding the spectrum of MOGAD. These patients often have seizures and primarily cortical involvement on MRI in the presenting event. Most of these patients also have clinical and/or radiological features of demyelination, either simultaneously or subsequently, which is relevant for clinical management.

5.2. Leukodystrophy-like phenotype

Most MOG-ab-positive patients presenting with ADEM have large, diffuse, poorly demarcated, bilateral, but asymmetrical white matter changes on MRI, which often dramatically resolve during follow-up, concurrently with an overall good recovery [30]. However, some MOG-ab-positive patients presenting with ADEM exhibit a more symmetrical extensive confluent pattern on MRI that progresses over time, which resembles a genetic or metabolic leukodystrophy, but with no indication for such underlying diseases in extensive additional testing [23,82,116]. A retrospective study further analysed this subgroup of patients and found seven patients who developed a leukodystrophy-like pattern on MRI within a cohort of 31 paediatric MOG-ab-positive patients [118]. This leukodystrophy-like phenotype was only seen in patients younger than seven years old, and more frequently observed in the youngest patients (mean age 3.7 years), compared to the middle-age group (mean age 5.2 years) who more often had ADEM-like lesions. All patients with a leukodystrophy-like MRI pattern were diagnosed with ADEM at onset of disease and presented either at onset or at relapse with encephalopathy (100%), ataxia (100%), ON (71%), and/or seizures (43%). While all these patients did show clinical improvement after acute treatment with steroids, their overall outcome was poor, and, importantly, worse compared to the patients without this leukodystrophy-like pattern on MRI (EDSS 3 vs. 0). In addition, persistent cognitive and behavioural problems were observed in 57%, and ongoing seizures in 43% of patients. In total, 40% of patients continued to have relapses despite treatment with disease-modifying drugs, or only showed a partial response to second-line immunotherapy. Yet, the total number of relapses did not differ from the other MOG-ab-positive patients in their cohort. Additionally, this leukodystrophy-like MRI pattern has also been associated with a poor outcome in the above mentioned large prospective study from Spain [23].

This overall very rare phenotype fits in the age-dependency of MOGAD, with more ADEM-like presentations in the younger paediatric patients, and even more extensive brain involvement with such leukodystrophy-like phenotypes in the youngest MOG-ab-positive population.

5.3. Combined central and peripheral demyelination in MOGAD

A few MOG-ab-positive cases are reported with central as well

as peripheral nervous system demyelination [118,119]. These patients reported had peripheral cranial nerve involvement together with accompanying brain lesions with or without encephalopathy [118], or a polyradiculoneuropathy simultaneously with TM [119]. These phenotypes can be referred to as “brain plus phenotype” or “TM plus phenotype”, respectively. Although MOG is thought to be CNS specific, peripheral MOG has been identified in rats and primates as well [120]. Nevertheless, further investigation in humans is needed to determine whether MOG-abs are the causative agent in these reported “plus” phenotypes.

5.4. Non-classifiable clinical phenotypes

Previous studies have also reported several MOG-ab-associated atypical monophasic or recurrent syndromes, which did not fulfil any of the current criteria within the ADS or encephalitis spectrum [23,41]. These comprised for example patients with the above-mentioned combination of encephalitis and following demyelinating features, or patients with other syndromes without encephalopathy and ADEM-like lesions on MRI or MRI lesions not resembling ADEM of MS. These non-classifiable clinical phenotypes underline the need for an updated MOGAD terminology.

6. Conclusion

This review emphasises the diversity in clinical phenotypes associated with MOG-abs in paediatric patients. The majority of MOGAD presentations consist of demyelinating syndromes, including typical phenotypes as ADEM in younger, and ON and/or TM in older children. A proportion of patients experience a

relapsing disease course, presenting as ADEM-ON, MDEM, RON or relapsing NMOSD-like syndromes. More recently, the disease spectrum has been expanded to include (recurrent) encephalitis-like, overlapping syndromes, leukodystrophy-like, and non-classifiable phenotypes.

7. Expert consensus recommendations

Presence of MOG-abs has consequences due to the relapse risk and possible treatment interventions [125], and for accurate counselling of patient and families. Based on the wide diversity of paediatric MOGAD, and the fact that MOG-abs are common in childhood, we recommend to test all paediatric patients presenting with a demyelinating or encephalitic event with abnormalities on brain and/or spinal MRI (Fig. 3). This MOG-ab testing should be combined with AQP4-ab testing in the blood, and with CSF analysis for oligoclonal bands (OCB). Previous suggested protocols of MOG-ab testing advised to only test for MOG-abs in atypical MS presentations [81,120]. However, in our opinion, the interpretation of typical MS can differ between clinicians. MOG-ab positivity should result in patient referral to a centre of expertise for further management. Additionally, previously suggested protocols advised to only test NMOSD patients for MOG-abs if they were tested negative for AQP4-abs [82,120]. As in childhood MOG-abs are found five times more often than AQP4-abs, especially in patients presenting with simultaneous ON and (LE)TM, patients with an NMOSD-like phenotype need to be tested at onset for both MOG-abs and AQP4-abs. Finally, in patients with encephalitic syndromes with abnormalities on brain and/or spinal MRI, MOG-ab testing should be included in the initial work-up, as in these patients MOG-abs are

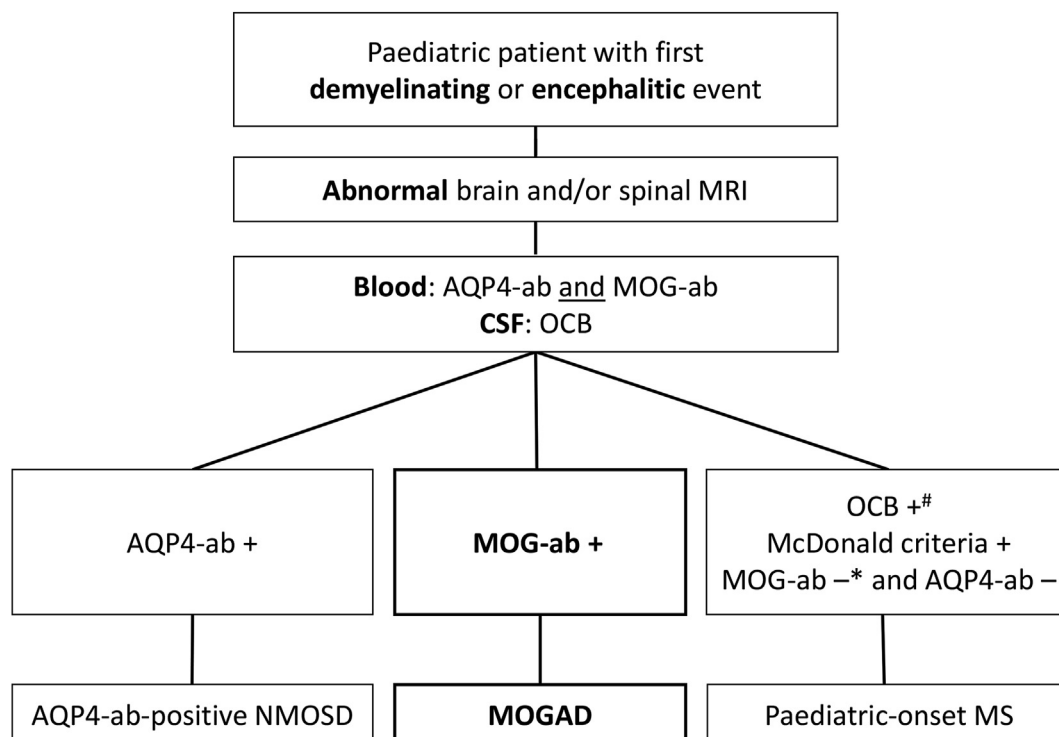


Fig. 3. Paediatric European Collaborative Consensus recommendation on MOG-ab testing (in an accredited laboratory) in paediatric patients.

Up to 90% of paediatric-onset MS patients have OCB specific to the CSF [122].

* A minor proportion of paediatric-onset MS patients have MOG-abs (mostly low titre/weak positive CBA test result which rapidly declines during follow-up). However, presence of MOG-abs should result in patient referral to a centre of expertise for further management.

AQP4-ab = aquaporin-4 antibody, CBA = cell-based assay, CSF = cerebrospinal fluid, NMOSD = neuromyelitis optica spectrum disorders, MOG-ab = myelin oligodendrocyte glycoprotein antibody, MOGAD = MOG-ab-associated disorders, MRI = magnetic resonance imaging, MS = multiple sclerosis, OCB = oligoclonal bands, + = positive, - = negative.

Table 2
Clinical classification of paediatric MOGAD with corresponding key features.

Disease course	Classification	Key features
Monophasic MOGAD with	ADEM phenotype	Younger patients Characterised by encephalopathy Often longitudinal spinal cord involvement, which can be asymptomatic
	ON phenotype	Adolescents Severe vision loss at onset, anterior and bilateral optic nerve involvement, with disc oedema Overall good and often rapid functional recovery, but indication of permanent axonal damage (OCT)
	ON plus phenotype TM phenotype	Adolescents ON and optic perineuritis (perineural enhancement and inflammation of orbital tissues)
	NMOSD-like phenotype	Adolescents Severe motor and sensory deficits at onset; subset with conus involvement and following bladder problems Overall good and often rapid motor recovery, but bowel/bladder residual symptoms are common
Relapsing* MOGAD with	encephalitis-like phenotype	Adolescents Simultaneous ON and TM
	ADEM-ON phenotype	Seizures and cortical lesions, with adjacent subcortical involvement in a subset of patients Younger patients Recurrent episode(s) of ON more than 3 months after start of previous ADEM episode
	MDEM phenotype	Younger patients Characterised by encephalopathy Recurrent episode(s) of ADEM more than 3 months after start of previous ADEM episode
	RON phenotype	Adolescents Relapsing ON episodes, often steroid responsive, sometimes steroid-dependent
	NMOSD-like phenotype	Adolescents ON followed by subsequent TM or reversed; or simultaneous ON and TM followed by new ON and/or TM episode(s)
	encephalitis-like phenotype	Seizures and cortical lesions, with adjacent subcortical involvement in a subset of patients Subsequently with demyelinating event(s)/lesion(s)
	leukodystrophy-like phenotype	Youngest patients Encephalopathy, ataxia, ON and/or seizures Extensive brain involvement

* A relapse is defined by the consensus group as a new clinical episode accompanied by radiological evidence depending on the subtype of MOGAD, appearing at least one month subsequently to the last acute attack, while a 'flare-up' is defined as re-occurrence of symptoms within one month (and up to three months in ADEM patients) after start of acute treatment and not meeting definition of a relapse [125].

ADEM = acute disseminated encephalomyelitis, ADEM-ON = ADEM episode followed by one of more optic neuritis episode(s), MDEM = multiphasic disseminated encephalomyelitis, MOGAD = MOG-ab-associated disorders, OCT = optical coherence tomography, ON = optic neuritis, TM = transverse myelitis, RON = relapsing optic neuritis.

found more often than all other neuronal autoantibodies combined. Due to challenges in MOG-ab laboratory testing, it is of utmost importance that MOG-abs are tested only in an accredited laboratory, in order to avoid false positive or false negative test results [10].

MOGAD phenotypes can change during follow-up, depending on age at onset and possible relapses during follow-up. Therefore, MOGAD presents a fluid disease spectrum compared to the more defined AQP4-ab-positive NMOSD. Accordingly, and besides the already mentioned additional clinical and immunological differences, we believe MOGAD and AQP4-ab-positive NMOSD are distinctive demyelinating disorders of the CNS and should be classified as two different disease entities. We here suggest using an antibody-directed classification, with use of the term MOGAD for all MOG-ab-positive patients, with subsequent addition of the disease course (monophasic vs. relapsing) and their clinical phenotype: e.g. monophasic or relapsing MOGAD with ADEM phenotype; with NMOSD-like phenotype; with encephalitis-like phenotype; or with non-classifiable phenotype. This proposed clinical classification of paediatric MOGAD with corresponding key features is shown in Table 2. This classification is operational and needs to be tested, but importantly, the potentially changing MOGAD phenotype during disease course can also be appointed with this classification, which is essential to incorporate in future paediatric MOGAD studies.

Funding sources

This study was supported in part by the Dutch MS Research Foundation (16-927MS to ALB and RFN).

Declaration of competing interest

Arlette L. Bruijstens and Lorraine Flet-Berliac have no conflict of interest to declare.

Christian Lechner has served as a consultant for Roche, but has no conflict of interest with this manuscript.

Kumaran Deiva has received speaker/consultant honoraria from Novartis and Biogen, but has no conflict of interest with this manuscript.

Rinze F. Neuteboom participates in trials by Sanofi and Novartis and has received honoraria from Novartis and Zogenix.

Cheryl Hemingway serves as consultant for MS treatment for Biogen, Novartis and AQP4 treatment for Roche. She is an investigator in trials with Biogen, Roche and Novartis, but has no conflict of interest with this manuscript.

Evangeline Wassmer has served as a consultant for Novartis and Biogen, PTC therapeutics, GMP-Orphan and Alexion. She is an investigator in trials with Alexion, Biogen Idec, Sanofi and Novartis. Her MS research projects have been funded by the UK MS Society, Action Medical Research and Birmingham Children's Hospital Research Foundation.

References

- [1] B. Banwell, J. Kennedy, D. Sadovnick, D.L. Arnold, S. Magalhaes, K. Wambara, et al., Incidence of acquired demyelination of the CNS in Canadian children, *Neurology* 72 (3) (2009) 232–239.
- [2] L.B. Krupp, M. Tardieu, M.P. Amato, B. Banwell, T. Chitnis, R.C. Dale, et al., International Pediatric Multiple Sclerosis Study Group criteria for pediatric multiple sclerosis and immune-mediated central nervous system demyelinating disorders: revisions to the 2007 definitions, *Mult. Scler.* 19 (10) (2013) 1261–1267.
- [3] I.A. Ketelslegers, C.E. Catsman-Berrevoets, R.F. Neuteboom, M. Boon, K.G. van Dijk, M.J. Eikelenboom, et al., Incidence of acquired demyelinating syndromes of the CNS in Dutch children: a nationwide study, *J. Neurol.* 259 (9) (2012) 1929–1935.
- [4] R. Neuteboom, C. Wilbur, D. Van Pelt, M. Rodriguez, A. Yeh, The spectrum of inflammatory acquired demyelinating syndromes in children, *Semin. Pediatr. Neurol.* 24 (3) (2017) 189–200.
- [5] V.A. Lennon, D.M. Wingerchuk, T.J. Kryzer, S.J. Pittock, C.F. Lucchinetti, K. Fujihara, et al., A serum autoantibody marker of neuromyelitis optica: distinction from multiple sclerosis, *Lancet* 364 (9451) (2004) 2106–2112.
- [6] M. Reindl, F. Di Pauli, K. Rostasy, T. Berger, The spectrum of MOG autoantibody-associated demyelinating diseases, *Nat. Rev. Neurol.* 9 (8) (2013) 455–461.
- [7] E.M. Hennes, M. Baumann, C. Lechner, K. Rostasy, MOG spectrum disorders and role of MOG-antibodies in clinical practice, *Neuropediatrics* 49 (1) (2018) 3–11.
- [8] C. Brunner, H. Lassmann, T.V. Waehneltd, J.M. Matthieu, C. Linington, Differential ultrastructural localization of myelin basic protein, myelin/oligodendroglial glycoprotein, and 2',3'-cyclic nucleotide 3'-phosphodiesterase in the CNS of adult rats, *J. Neurochem.* 52 (1) (1989) 296–304.
- [9] B. Hemmer, J.J. Archelos, H.P. Hartung, New concepts in the immunopathogenesis of multiple sclerosis, *Nat. Rev. Neurosci.* 3 (4) (2002) 291–301.
- [10] Thaïs. Armangue, Marco Capobianco, et al., E.U. paediatric MOG consortium consensus: Part 3 - Biomarkers of paediatric myelin oligodendrocyte glycoprotein antibody-associated disorders, *Eur. J. Paediatr. Neurol.* 21 (2020) 22–31.
- [11] I.A. Ketelslegers, D.E. Van Pelt, S. Bryde, R.F. Neuteboom, C.E. Catsman-Berrevoets, D. Hamann, et al., Anti-MOG antibodies plead against MS diagnosis in an Acquired Demyelinating Syndromes cohort, *Mult. Scler.* 21 (12) (2015) 1513–1520.
- [12] Y. Hacohen, M. Absoud, K. Deiva, C. Hemingway, P. Nytrova, M. Woodhall, et al., Myelin oligodendrocyte glycoprotein antibodies are associated with a non-MS course in children, *Neurol Neuroimmunol Neuroinflamm* 2 (2) (2015) e81.
- [13] E.M. Hennes, M. Baumann, K. Schanda, B. Anlar, B. Bajer-Kornek, A. Blaschek, et al., Prognostic relevance of MOG antibodies in children with an acquired demyelinating syndrome, *Neurology* 89 (9) (2017) 900–908.
- [14] P. Waters, G. Fadda, M. Woodhall, J. O'Mahony, R.A. Brown, D.A. Castro, et al., Serial anti-myelin oligodendrocyte glycoprotein antibody analyses and outcomes in children with demyelinating syndromes, *JAMA Neurol* (2019).
- [15] S. Ramanathan, R.C. Dale, F. Brilot, Anti-MOG antibody: the history, clinical phenotype, and pathogenicity of a serum biomarker for demyelination, *Autoimmun. Rev.* 15 (4) (2016) 307–324.
- [16] M. Reindl, P. Waters, Myelin oligodendrocyte glycoprotein antibodies in neurological disease, *Nat. Rev. Neurol.* 15 (2) (2019) 89–102.
- [17] C.L. de Mol, Y. Wong, E.D. van Pelt, B. Wokke, T. Siepman, R.F. Neuteboom, et al., The clinical spectrum and incidence of anti-MOG-associated acquired demyelinating syndromes in children and adults, *Mult. Scler.* (2019), 1352458519845112.
- [18] A.K. Probstel, K. Dornmair, R. Bittner, P. Sperl, D. Jenne, S. Magalhaes, et al., Antibodies to MOG are transient in childhood acute disseminated encephalomyelitis, *Neurology* 77 (6) (2011) 580–588.
- [19] K. Rostasy, S. Mader, K. Schanda, P. Huppke, J. Gartner, V. Kraus, et al., Anti-myelin oligodendrocyte glycoprotein antibodies in pediatric patients with optic neuritis, *Arch. Neurol.* 69 (6) (2012) 752–756.
- [20] R.C. Dale, E.M. Tantsis, V. Merheb, R.Y. Kumaran, N. Sinmaz, K. Pathmanandavel, et al., Antibodies to MOG have a demyelination phenotype and affect oligodendrocyte cytoskeleton, *Neurol Neuroimmunol Neuroinflamm* 1 (1) (2014) e12.
- [21] G. Fadda, R.A. Brown, G. Longoni, D.A. Castro, J. O'Mahony, L.H. Verhey, et al., MRI and laboratory features and the performance of international criteria in the diagnosis of multiple sclerosis in children and adolescents: a prospective cohort study, *Lancet Child Adolesc Health* 2 (3) (2018) 191–204.
- [22] S. Duignan, S. Wright, T. Rossor, J. Cazabon, K. Gilmour, O. Ciccarelli, et al., Myelin oligodendrocyte glycoprotein and aquaporin-4 antibodies are highly specific in children with acquired demyelinating syndromes, *Dev. Med. Child Neurol.* 60 (9) (2018) 958–962.
- [23] T. Armangue, G. Olive-Cirera, E. Martinez-Hernandez, M. Sepulveda, R. Ruiz-Garcia, M. Munoz-Batista, et al., Associations of paediatric demyelinating and encephalitic syndromes with myelin oligodendrocyte glycoprotein antibodies: a multicentre observational study, *Lancet Neurol.* 19 (3) (2020) 234–246.
- [24] S. Salama, S. Pardo, M. Levy, Clinical characteristics of myelin oligodendrocyte glycoprotein antibody neuromyelitis optica spectrum disorder, *Mult Scler Relat Disord* 30 (2019) 231–235.
- [25] M. Baumann, A. Grams, T. Djurdjevic, E.M. Wendel, C. Lechner, B. Behring, et al., MRI of the first event in pediatric acquired demyelinating syndromes with antibodies to myelin oligodendrocyte glycoprotein, *J. Neurol.* 265 (4) (2018) 845–855.
- [26] B. Konuskan, M. Yildirim, R. Gocmen, T.D. Okur, I. Polat, H. Kilic, et al., Retrospective analysis of children with myelin oligodendrocyte glycoprotein antibody-related disorders, *Mult Scler Relat Disord* 26 (2018) 1–7.
- [27] A. Cobo-Calvo, A. Ruiz, H. D'Indy, A.L. Poulat, M. Carneiro, N. Philippe, et al., MOG antibody-related disorders: common features and uncommon presentations, *J. Neurol.* 264 (9) (2017) 1945–1955.
- [28] C. Fernandez-Carbonell, D. Vargas-Lowy, A. Musallam, B. Healy, K. McLaughlin, K.W. Wucherpfennig, et al., Clinical and MRI phenotype of children with MOG antibodies, *Mult. Scler.* 22 (2) (2016) 174–184.
- [29] Y. Hacohen, B. Banwell, Treatment approaches for MOG-ab-associated demyelination in children, *Curr. Treat. Options Neurol.* 21 (1) (2019) 2.
- [30] A. McKeon, V.A. Lennon, T. Lotze, S. Tenenbaum, J.M. Ness, M. Rensel, et al., CNS aquaporin-4 autoimmunity in children, *Neurology* 71 (2) (2008) 93–100.
- [31] M. Baumann, K. Sahin, C. Lechner, E.M. Hennes, K. Schanda, S. Mader, et al., Clinical and neuroradiological differences of paediatric acute disseminated encephalomyelitis with and without antibodies to the myelin oligodendrocyte glycoprotein, *J. Neurol. Neurosurg. Psychiatry* 86 (3) (2015) 265–272.
- [32] R.Q. Hintzen, R.C. Dale, R.F. Neuteboom, S. Mar, B. Banwell, Pediatric acquired CNS demyelinating syndromes: features associated with multiple sclerosis, *Neurology* 87 (9 Suppl 2) (2016) S67–S73.
- [33] C. Lechner, M. Baumann, E.M. Hennes, K. Schanda, K. Marquard, M. Karenfort, et al., Antibodies to MOG and AQP4 in children with neuromyelitis optica and limited forms of the disease, *J. Neurol. Neurosurg. Psychiatry* 87 (8) (2016) 897–905.
- [34] A.S. Lopez-Chiriboga, M. Majed, J. Fryer, D. Dubey, A. McKeon, E.P. Flanagan, et al., Association of MOG-IgG serostatus with relapse after acute disseminated encephalomyelitis and proposed diagnostic criteria for MOG-IgG-associated disorders, *JAMA Neurol* 75 (11) (2018) 1355–1363.
- [35] Q. Chen, G. Zhao, Y. Huang, Z. Li, X. Sun, P. Lu, et al., Clinical characteristics of pediatric optic neuritis with myelin oligodendrocyte glycoprotein seropositive: a cohort study, *Pediatr. Neurol.* 83 (2018) 42–49.
- [36] R.N. Narayan, M. McCreary, D. Conger, C. Wang, B.M. Greenberg, Unique characteristics of optical coherence tomography (OCT) results and visual acuity testing in myelin oligodendrocyte glycoprotein (MOG) antibody positive pediatric patients, *Mult Scler Relat Disord* 28 (2019) 86–90.
- [37] H. Song, H. Zhou, M. Yang, S. Tan, J. Wang, Q. Xu, et al., Clinical characteristics and prognosis of myelin oligodendrocyte glycoprotein antibody-seropositive paediatric optic neuritis in China, *Br. J. Ophthalmol.* 103 (6) (2019) 831–836.
- [38] M. Jurynczyk, S. Messina, M.R. Woodhall, N. Raza, R. Everett, A. Roca-Fernandez, et al., Clinical presentation and prognosis in MOG-antibody disease: a UK study, *Brain* 140 (12) (2017) 3128–3138.
- [39] A. Cobo-Calvo, A. Ruiz, E. Maillart, B. Audoin, H. Zephir, B. Bourre, et al., Clinical spectrum and prognostic value of CNS MOG autoimmunity in adults: the MOGADOR study, *Neurology* 90 (21) (2018) e1858–e1869.
- [40] L. Chen, C. Chen, X. Zhong, X. Sun, H. Zhu, X. Li, et al., Different features between pediatric-onset and adult-onset patients who are seropositive for MOG-IgG: a multicenter study in South China, *J. Neuroimmunol.* 321 (2018) 83–91.
- [41] S. Ramanathan, S. Mohammad, E. Tantsis, T.K. Nguyen, V. Merheb, V.S.C. Fung, et al., Clinical course, therapeutic responses and outcomes in relapsing MOG antibody-associated demyelination, *J. Neurol. Neurosurg. Psychiatry* 89 (2) (2018) 127–137.
- [42] D. Pham-Dinh, M.G. Mattei, J.L. Nussbaum, G. Roussel, P. Pontarotti, N. Roeckel, et al., Myelin/oligodendrocyte glycoprotein is a member of a subset of the immunoglobulin superfamily encoded within the major histocompatibility complex, *Proc. Natl. Acad. Sci. U. S. A.* 90 (17) (1993) 7990–7994.
- [43] I.A. Ketelslegers, I.E. Visser, R.F. Neuteboom, M. Boon, C.E. Catsman-Berrevoets, R.Q. Hintzen, Disease course and outcome of acute disseminated encephalomyelitis is more severe in adults than in children, *Mult. Scler.* 17 (4) (2011) 441–448.
- [44] Y.Y.M. Wong, E.D. van Pelt, I.A. Ketelslegers, C.E. Catsman-Berrevoets, R.Q. Hintzen, R.F. Neuteboom, et al., Evolution of MRI abnormalities in paediatric acute disseminated encephalomyelitis, *Eur. J. Paediatr. Neurol.* 21 (2) (2017) 300–304.
- [45] D. Pohl, G. Alper, K. Van Haren, A.J. Kornberg, C.F. Lucchinetti, S. Tenenbaum, et al., Acute disseminated encephalomyelitis: updates on an inflammatory CNS syndrome, *Neurology* 87 (9 Suppl 2) (2016) S38–S45.
- [46] K. Deiva, A. Cobo-Calvo, H. Maurey, A. De Chalus, E. Yazbeck, B. Husson, et al., Risk factors for academic difficulties in children with myelin oligodendrocyte glycoprotein antibody-associated acute demyelinating syndromes, *Dev. Med. Child Neurol.* (2020).
- [47] T. Rossor, C. Benetou, S. Wright, S. Duignan, K. Lascelles, R. Robinson, et al., Early predictors of epilepsy and subsequent relapse in children with acute disseminated encephalomyelitis, *Mult. Scler.* 26 (3) (2020) 333–342.
- [48] J.H. Lock, N.J. Newman, V. Biousse, J.H. Peragallo, Update on pediatric optic neuritis, *Curr. Opin. Ophthalmol.* 30 (6) (2019) 418–425.
- [49] M. Eyre, A. Hameed, S. Wright, W. Brownlee, O. Ciccarelli, R. Bowman, et al., Retinal nerve fibre layer thinning is associated with worse visual outcome

- after optic neuritis in children with a relapsing demyelinating syndrome, *Dev. Med. Child Neurol.* 60 (12) (2018) 1244–1250.
- [50] S. Ramanathan, K. Prelog, E.H. Barnes, E.M. Tantsis, S.W. Reddel, A.P. Henderson, et al., Radiological differentiation of optic neuritis with myelin oligodendrocyte glycoprotein antibodies, aquaporin-4 antibodies, and multiple sclerosis, *Mult. Scler.* 22 (4) (2016) 470–482.
- [51] E.M. Wendel, M. Baumann, N. Barisic, A. Blaschek, E. Coelho de Oliveira Koch, A. Della Marina, et al., High association of MOG-IgG antibodies in children with bilateral optic neuritis, *Eur. J. Paediatr. Neurol.* (2020).
- [52] J.J. Chen, M.T. Bhatti, Clinical phenotype, radiological features, and treatment of myelin oligodendrocyte glycoprotein-immunoglobulin G (MOG-IgG) optic neuritis, *Curr. Opin. Neurol.* 33 (1) (2020) 47–54.
- [53] H. Song, H. Zhou, M. Yang, Q. Xu, M. Sun, S. Wei, Clinical characteristics and outcomes of myelin oligodendrocyte glycoprotein antibody-seropositive optic neuritis in varying age groups: a cohort study in China, *J. Neurol. Sci.* 400 (2019) 83–89.
- [54] H.J. Lee, B. Kim, P. Waters, M. Woodhall, S. Irani, S. Ahn, et al., Chronic relapsing inflammatory optic neuropathy (CRION): a manifestation of myelin oligodendrocyte glycoprotein antibodies, *J. Neuroinflammation* 15 (1) (2018) 302.
- [55] J.J. Chen, E.P. Flanagan, J. Jitrapaikulsan, A.S.S. Lopez-Chiriboga, J.P. Fryer, J.A. Leavitt, et al., Myelin oligodendrocyte glycoprotein antibody-positive optic neuritis: clinical characteristics, radiologic clues, and outcome, *Am. J. Ophthalmol.* 195 (2018) 8–15.
- [56] T. Akaishi, D.K. Sato, I. Nakashima, T. Takeshita, T. Takahashi, H. Doi, et al., MRI and retinal abnormalities in isolated optic neuritis with myelin oligodendrocyte glycoprotein and aquaporin-4 antibodies: a comparative study, *J. Neurol. Neurosurg. Psychiatry* 87 (4) (2016) 446–448.
- [57] T. Akaishi, D.K. Sato, T. Takahashi, I. Nakashima, Clinical spectrum of inflammatory central nervous system demyelinating disorders associated with antibodies against myelin oligodendrocyte glycoprotein, *Neurochem. Int.* 130 (2019) 104319.
- [58] S.M. Kim, M.R. Woodhall, J.S. Kim, S.J. Kim, K.S. Park, A. Vincent, et al., Antibodies to MOG in adults with inflammatory demyelinating disease of the CNS, *Neurol Neuroimmunol Neuroinflamm* 2 (6) (2015) e163.
- [59] A. Peng, M. Kinoshita, W. Lai, A. Tan, X. Qiu, L. Zhang, et al., Retinal nerve fiber layer thickness in optic neuritis with MOG antibodies: a systematic review and meta-analysis, *J. Neuroimmunol.* 325 (2018) 69–73.
- [60] D. Dubey, S.J. Pittock, K.N. Krecke, P.P. Morris, E. Sechi, N.L. Zaleski, et al., Clinical, radiologic, and prognostic features of myelitis associated with myelin oligodendrocyte glycoprotein autoantibody, *JAMA Neurol* 76 (3) (2019) 301–309.
- [61] D.K. Sato, D. Callegaro, M.A. Lana-Peixoto, P.J. Waters, F.M. de Haidar Jorge, T. Takahashi, et al., Distinction between MOG antibody-positive and AQP4 antibody-positive NMO spectrum disorders, *Neurology* 82 (6) (2014) 474–481.
- [62] J. Kitley, P. Waters, M. Woodhall, M.I. Leite, A. Murchison, J. George, et al., Neuromyelitis optica spectrum disorders with aquaporin-4 and myelin oligodendrocyte glycoprotein antibodies: a comparative study, *JAMA Neurol* 71 (3) (2014) 276–283.
- [63] K. Deiva, M. Absoud, C. Hemingway, Y. Hernandez, B. Husson, H. Maurey, et al., Acute idiopathic transverse myelitis in children: early predictors of relapse and disability, *Neurology* 84 (4) (2015) 341–349.
- [64] C.G. De Goede, E.M. Holmes, M.G. Pike, Acquired transverse myelopathy in children in the United Kingdom—a 2 year prospective study, *Eur. J. Paediatr. Neurol.* 14 (6) (2010) 479–487.
- [65] D.M. Wingerchuk, B. Banwell, J.L. Bennett, P. Cabre, W. Carroll, T. Chitnis, et al., International consensus diagnostic criteria for neuromyelitis optica spectrum disorders, *Neurology* 85 (2) (2015) 177–189.
- [66] E.D. van Pelt, Y.Y. Wong, I.A. Ketelslegers, D. Hamann, R.Q. Hintzen, Neuromyelitis optica spectrum disorders: comparison of clinical and magnetic resonance imaging characteristics of AQP4-IgG versus MOG-IgG seropositive cases in The Netherlands, *Eur. J. Neurol.* 23 (3) (2016) 580–587.
- [67] S. Jarius, K. Ruprecht, I. Kleiter, N. Borisow, N. Asgari, K. Pitarokoiili, et al., MOG-IgG in NMO and related disorders: a multicenter study of 50 patients. Part 2: epidemiology, clinical presentation, radiological and laboratory features, treatment responses, and long-term outcome, *J. Neuroinflammation* 13 (1) (2016) 280.
- [68] E. Shosha, D. Dubey, J. Palace, I. Nakashima, A. Jacob, K. Fujihara, et al., Area postrema syndrome: frequency, criteria, and severity in AQP4-IgG-positive NMOSD, *Neurology* 91 (17) (2018) e1642–e1651.
- [69] S. Jarius, I. Kleiter, K. Ruprecht, N. Asgari, K. Pitarokoiili, N. Borisow, et al., MOG-IgG in NMO and related disorders: a multicenter study of 50 patients. Part 3: brainstem involvement - frequency, presentation and outcome, *J. Neuroinflammation* 13 (1) (2016) 281.
- [70] A. Kunchok, K.N. Krecke, E.P. Flanagan, J. Jitrapaikulsan, A.S. Lopez-Chiriboga, J.J. Chen, et al., Does area postrema syndrome occur in myelin oligodendrocyte glycoprotein-IgG-associated disorders (MOGAD)? *Neurology* 94 (2) (2020) 85–88.
- [71] J.D. Parratt, J.W. Prineas, Neuromyelitis optica: a demyelinating disease characterized by acute destruction and regeneration of perivascular astrocytes, *Mult. Scler.* 16 (10) (2010) 1156–1172.
- [72] L. Fang, X. Kang, Z. Wang, S. Wang, J. Wang, Y. Zhou, et al., Myelin oligodendrocyte glycoprotein-IgG contributes to oligodendrocytopathy in the presence of complement, distinct from astrocytopathy induced by AQP4-IgG, *Neurosci Bull* 35 (5) (2019) 853–866.
- [73] S.J. Pittock, C.F. Lucchinetti, Neuromyelitis optica and the evolving spectrum of autoimmune aquaporin-4 channelopathies: a decade later, *Ann. N. Y. Acad. Sci.* 1366 (1) (2016) 20–39.
- [74] A.L. Buijstens, Y.Y.M. Wong, D.E. van Pelt, P.J.E. van der Linden, G.W. Haasnoot, R.Q. Hintzen, et al., HLA association in MOG-IgG- and AQP4-IgG-related disorders of the CNS in the Dutch population, *Neurol Neuroimmunol Neuroinflamm* 7 (3) (2020).
- [75] M.I. Leite, D.K. Sato, MOG-antibody-associated disease is different from MS and NMOSD and should be considered as a distinct disease entity - Yes, *Mult. Scler.* (2019), 1352458519868796.
- [76] K. Fujihara, MOG-antibody-associated disease is different from MS and NMOSD and should be classified as a distinct disease entity - Commentary, *Mult. Scler.* (2019), 1352458519895236.
- [77] A. Cobo-Calvo, S. Vukusic, R. Marignier, Clinical spectrum of central nervous system myelin oligodendrocyte glycoprotein autoimmunity in adults, *Curr. Opin. Neurol.* 32 (3) (2019) 459–466.
- [78] S.S. Zamvil, A.J. Slavin, Does MOG Ig-positive AQP4-seronegative opticospinal inflammatory disease justify a diagnosis of NMO spectrum disorder? *Neurol Neuroimmunol Neuroinflamm* 2 (1) (2015) e62.
- [79] S.J. Pittock, Demyelinating disease: NMO spectrum disorders: clinical or molecular classification? *Nat. Rev. Neurol.* 12 (3) (2016) 129–130.
- [80] Y. Hachohen, J. Palace, Time to separate MOG-Ab-associated disease from AQP4-Ab-positive neuromyelitis optica spectrum disorder, *Neurology* 90 (21) (2018) 947–948.
- [81] C. Lechner, M. Breu, E.-M. Wendel, B. Kornek, K. Schanda, M. Baumann, et al., Epidemiology of pediatric NMOSD in Germany and Austria, *Front. Neurol.* 11 (415) (2020).
- [82] Y. Hachohen, K. Mankad, W.K. Chong, F. Barkhof, A. Vincent, M. Lim, et al., Diagnostic algorithm for relapsing acquired demyelinating syndromes in children, *Neurology* 89 (3) (2017) 269–278.
- [83] Y. Hachohen, Y.Y. Wong, C. Lechner, M. Jurynczyk, S. Wright, B. Konusku, et al., Disease course and treatment responses in children with relapsing myelin oligodendrocyte glycoprotein antibody-associated disease, *JAMA Neurol* 75 (4) (2018) 478–487.
- [84] M. Baumann, E.M. Hennes, K. Schanda, M. Karenfort, B. Kornek, R. Seidl, et al., Children with multiphasic disseminated encephalomyelitis and antibodies to the myelin oligodendrocyte glycoprotein (MOG): extending the spectrum of MOG antibody positive diseases, *Mult. Scler.* 22 (14) (2016) 1821–1829.
- [85] P. Huppke, K. Rostasy, M. Karenfort, B. Huppke, R. Seidl, S. Leiz, et al., Acute disseminated encephalomyelitis followed by recurrent or monophasic optic neuritis in pediatric patients, *Mult. Scler.* 19 (7) (2013) 941–946.
- [86] Y.Y.M. Wong, Y. Hachohen, T. Armangue, E. Wassmer, H. Verhelst, C. Hemingway, et al., Paediatric acute disseminated encephalomyelitis followed by optic neuritis: disease course, treatment response and outcome, *Eur. J. Neurol.* 25 (5) (2018) 782–786.
- [87] K. Chalmoukou, H. Alexopoulos, S. Akrivou, P. Stathopoulos, M. Reindl, M.C. Dalakas, Anti-MOG antibodies are frequently associated with steroid-sensitive recurrent optic neuritis, *Neurol Neuroimmunol Neuroinflamm* 2 (4) (2015) e131.
- [88] S. Ramanathan, S.W. Reddel, A. Henderson, J.D. Parratt, M. Barnett, P.N. Gatt, et al., Antibodies to myelin oligodendrocyte glycoprotein in bilateral and recurrent optic neuritis, *Neurol Neuroimmunol Neuroinflamm* 1 (4) (2014) e40.
- [89] J. Fujimori, Y. Takai, I. Nakashima, D.K. Sato, T. Takahashi, K. Kaneko, et al., Bilateral frontal cortex encephalitis and paraparesis in a patient with anti-MOG antibodies, *J. Neurol. Neurosurg. Psychiatry* 88 (6) (2017) 534–536.
- [90] A. Budhram, A. Mirian, C. Le, S.M. Hosseini-Moghaddam, M. Sharma, M.W. Nicolle, Unilateral cortical FLAIR-hyperintense lesions in Anti-MOG-associated Encephalitis with Seizures (FLAMES): characterization of a distinct clinico-radiographic syndrome, *J. Neurol.* 266 (10) (2019) 2481–2487.
- [91] S. Hochmeister, T. Gattringer, M. Asslaber, V. Stangl, M.T. Haindl, C. Enzinger, et al., A fulminant case of demyelinating encephalitis with extensive cortical involvement associated with anti-MOG antibodies, *Front. Neurol.* 11 (2020) 31.
- [92] T. Ikeda, K. Yamada, R. Ogawa, Y. Takai, K. Kaneko, T. Misu, et al., The pathological features of MOG antibody-positive cerebral cortical encephalitis as a new spectrum associated with MOG antibodies: a case report, *J. Neurol. Sci.* 392 (2018) 113–115.
- [93] S. Mariotto, S. Monaco, P. Peschl, I. Coledan, R. Mazzi, R. Hoftberger, et al., MOG antibody seropositivity in a patient with encephalitis: beyond the classical syndrome, *BMC Neurol.* 17 (1) (2017) 190.
- [94] T. Sugimoto, H. Ishibashi, M. Hayashi, K. Tachiyaama, H. Fujii, K. Kaneko, et al., A case of anti-MOG antibody-positive unilaterally dominant meningoencephalitis followed by longitudinally extensive transverse myelitis, *Mult Scler Relat Disord* 25 (2018) 128–130.
- [95] T. Otani, T. Irioka, S. Igarashi, K. Kaneko, T. Takahashi, T. Yokota, Self-remitting cerebral cortical encephalitis associated with myelin oligodendrocyte glycoprotein antibody mimicking acute viral encephalitis: a case report, *Mult Scler Relat Disord* 41 (2020) 102033.
- [96] R. Tao, C. Qin, M. Chen, H.H. Yu, L.J. Wu, B.T. Bu, et al., Unilateral cerebral cortical encephalitis with epilepsy: a possible special phenotype of MOG antibody-associated disorders, *Int. J. Neurosci.* (2020) 1–5.
- [97] R. Ogawa, I. Nakashima, T. Takahashi, K. Kaneko, T. Akaishi, Y. Takai, et al.,

- MOG antibody-positive, benign, unilateral, cerebral cortical encephalitis with epilepsy, *Neurol Neuroimmunol Neuroinflamm* 4 (2) (2017) e322.
- [98] L. Wang, J. Zhang, L. Zhou, Y. Zhang, H. Li, Y. Li, et al., Encephalitis is an important clinical component of myelin oligodendrocyte glycoprotein antibody associated demyelination: a single-center cohort study in Shanghai, China, *Eur. J. Neurol.* 26 (1) (2019) 168–174.
- [99] S.H.M. Hamid, D. Whittam, M. Saviour, A. Alorainy, K. Mutch, S. Linaker, et al., Seizures and encephalitis in myelin oligodendrocyte glycoprotein IgG disease vs aquaporin 4 IgG disease, *JAMA Neurol* 75 (1) (2018) 65–71.
- [100] F. Graus, M.J. Titulaer, R. Balu, S. Benseler, C.G. Bien, T. Cellucci, et al., A clinical approach to diagnosis of autoimmune encephalitis, *Lancet Neurol.* 15 (4) (2016) 391–404.
- [101] S. Salama, M. Khan, S. Pardo, I. Izbudak, M. Levy, MOG antibody-associated encephalomyelitis/encephalitis, *Mult. Scler.* 25 (11) (2019) 1427–1433.
- [102] A. Wegener-Panzer, R. Cleaveland, E.M. Wendel, M. Baumann, A. Bertolini, M. Hausler, et al., Clinical and imaging features of children with autoimmune encephalitis and MOG antibodies, *Neurol Neuroimmunol Neuroinflamm* 7 (4) (2020).
- [103] A. Venkatesan, A.R. Tunkel, K.C. Bloch, A.S. Luring, J. Sejvar, A. Bitnun, et al., Case definitions, diagnostic algorithms, and priorities in encephalitis: consensus statement of the international encephalitis consortium, *Clin. Infect. Dis.* 57 (8) (2013) 1114–1128.
- [104] T. Armangue, M.J. Titulaer, I. Malaga, L. Bataller, I. Gabilondo, F. Graus, et al., Pediatric anti-N-methyl-D-aspartate receptor encephalitis-clinical analysis and novel findings in a series of 20 patients, *J. Pediatr.* 162 (4) (2013) 850–856 e2.
- [105] M.J. Titulaer, R. Hoftberger, T. Iizuka, F. Leypoldt, L. McCracken, T. Cellucci, et al., Overlapping demyelinating syndromes and anti-N-methyl-D-aspartate receptor encephalitis, *Ann. Neurol.* 75 (3) (2014) 411–428.
- [106] C.A. Perez, P. Agyei, B. Gogia, R. Harrison, R. Samudralwar, Overlapping autoimmune syndrome: a case of concomitant anti-NMDAR encephalitis and myelin oligodendrocyte glycoprotein (MOG) antibody disease, *J. Neuroimmunol.* 339 (2020), 577124.
- [107] S. Fan, Y. Xu, H. Ren, H. Guan, F. Feng, X. Gao, et al., Comparison of myelin oligodendrocyte glycoprotein (MOG)-antibody disease and AQP4-IgG-positive neuromyelitis optica spectrum disorder (NMOSD) when they co-exist with anti-NMDA (N-methyl-D-aspartate) receptor encephalitis, *Mult Scler Relat Disord* 20 (2018) 144–152.
- [108] J. Zhou, W. Tan, S.E. Tan, J. Hu, Z. Chen, K. Wang, An unusual case of anti-MOG CNS demyelination with concomitant mild anti-NMDAR encephalitis, *J. Neuroimmunol.* 320 (2018) 107–110.
- [109] B. Rojc, B. Podnar, F. Graus, A case of recurrent MOG antibody positive bilateral optic neuritis and anti-NMDAR encephalitis: different biological evolution of the two associated antibodies, *J. Neuroimmunol.* 328 (2019) 86–88.
- [110] S. Aoe, Y. Kokudo, T. Takata, H. Kobara, M. Yamamoto, T. Touge, et al., Repeated anti-N-methyl-D-aspartate receptor encephalitis coexisting with anti-myelin oligodendrocyte glycoprotein antibody-associated diseases: a case report, *Mult Scler Relat Disord* 35 (2019) 182–184.
- [111] E. Sarigecili, M.D. Cobanogullari, M. Komur, C. Okuyaz, A rare concurrence: antibodies against Myelin Oligodendrocyte Glycoprotein and N-methyl-D-aspartate receptor in a child, *Mult Scler Relat Disord* 28 (2019) 101–103.
- [112] J. Zhang, T. Ji, Q. Chen, Y. Jiang, H. Cheng, P. Zheng, et al., Pediatric autoimmune encephalitis: case series from two Chinese tertiary pediatric neurology centers, *Front. Neurol.* 10 (2019) 906.
- [113] C. Hou, W. Wu, Y. Tian, Y. Zhang, H. Zhu, Y. Zeng, et al., Clinical analysis of anti-NMDAR encephalitis combined with MOG antibody in children, *Mult Scler Relat Disord* 42 (2020), 102018.
- [114] T. Foadelli, M. Gastaldi, S. Scaranzin, D. Franciotta, S. Savasta, Seizures and myelin oligodendrocyte glycoprotein (MOG) antibodies: two paradigmatic cases and a review of the literature, *Mult Scler Relat Disord* 41 (2020) 102011.
- [115] S. Ramanathan, G.L. O'Grady, S. Malone, C.G. Spooner, D.A. Brown, D. Gill, et al., Isolated seizures during the first episode of relapsing myelin oligodendrocyte glycoprotein antibody-associated demyelination in children, *Dev. Med. Child Neurol.* 61 (5) (2019) 610–614.
- [116] J. Zhou, X. Lu, Y. Zhang, T. Ji, Y. Jin, M. Xu, et al., Follow-up study on Chinese children with relapsing MOG-IgG-associated central nervous system demyelination, *Mult Scler Relat Disord* 28 (2019) 4–10.
- [117] Y. Hachohen, T. Rossor, K. Mankad, W. Chong, A. Lux, E. Wassmer, et al., 'Leukodystrophy-like' phenotype in children with myelin oligodendrocyte glycoprotein antibody-associated disease, *Dev. Med. Child Neurol.* 60 (4) (2018) 417–423.
- [118] A. Cobo-Calvo, X. Aygnac, P. Kerschen, P. Horellou, F. Cotton, P. Labauge, et al., Cranial nerve involvement in patients with MOG antibody-associated disease, *Neurol Neuroimmunol Neuroinflamm* 6 (2) (2019) e543.
- [119] R. Vazquez Do Campo, A. Stephens, I.V. Marin Collazo, D.I. Rubin, MOG antibodies in combined central and peripheral demyelination syndromes, *Neurol Neuroimmunol Neuroinflamm* 5 (6) (2018) e503.
- [120] M. Pagany, M. Jagodic, A. Schubart, D. Pham-Dinh, C. Bachelin, A.B. van Evercooren, et al., Myelin oligodendrocyte glycoprotein is expressed in the peripheral nervous system of rodents and primates, *Neurosci. Lett.* 350 (3) (2003) 165–168.
- [121] F. Di Pauli, M. Reindl, T. Berger, New clinical implications of anti-myelin oligodendrocyte glycoprotein antibodies in children with CNS demyelinating diseases, *Mult Scler Relat Disord* 22 (2018) 35–37.
- [122] D. Pohl, K. Rostasy, H. Reiber, F. Hanefeld, CSF characteristics in early-onset multiple sclerosis, *Neurology* 63 (10) (2004) 1966–1967.
- [123] Arlette L. Buijstems, Markus Breu, et al., E.U. paediatric MOG consortium consensus: Part 4 e Outcome of paediatric myelin oligodendrocyte glycoprotein antibody-associated disorders, *J. Paediatr. Neurol.* 29 (2020) 32–40.
- [124] Matthias Baumann, Frederik Bartels, et al., E.U. paediatric MOG consortium consensus: Part 2 - Neuroimaging features of paediatric myelin oligodendrocyte glycoprotein antibody-associated disorders, *Eur. J. Paediatr. Neurol.* 29 (2020) 14–21.
- [125] Arlette L. Buijstems, Eva-Maria Wendel, et al., E.U. paediatric MOG consortium consensus: Part 5 - Treatment of paediatric myelin oligodendrocyte glycoprotein antibody-associated disorders, *Eur. J. Paediatr. Neurol.* 29 (2020) 41–53.