

CLINICAL ASPECTS OF HEPATOCELLULAR CARCINOMA

C. Verhoef

The production of this thesis was financially supported by Bayer Health Care and Astra-Zeneca, Sanofi Synthelabo, Johnston & Johnston Medical, Codman, Covedien, Novartis Oncology, Roche Nederland B.V., Braun Medical B.V., Glaxo SmithKline Oncology

Printed by Optima Grafische Communicatie, Rotterdam

CLINICAL ASPECTS OF HEPATOCELLULAR CARCINOMA

Proefschrift

ter verkrijging van de graad van doctor aan de
Erasmus Universiteit Rotterdam
op gezag van de Rector Magnificus

Prof.dr. S.W.J. Lamberts

en volgens besluit van het College voor Promoties.

De openbare verdediging zal plaatsvinden op
Woensdag 13 februari 2008 om 15.45 uur

door

Cornelis Verhoef

Geboren te Dordrecht

Promotiecommissie

Promotor:

Prof. dr. J.N.M. IJzermans

Overige leden:

Prof. dr. R.A. Tollenaar

Prof. dr. E.J. Kuipers

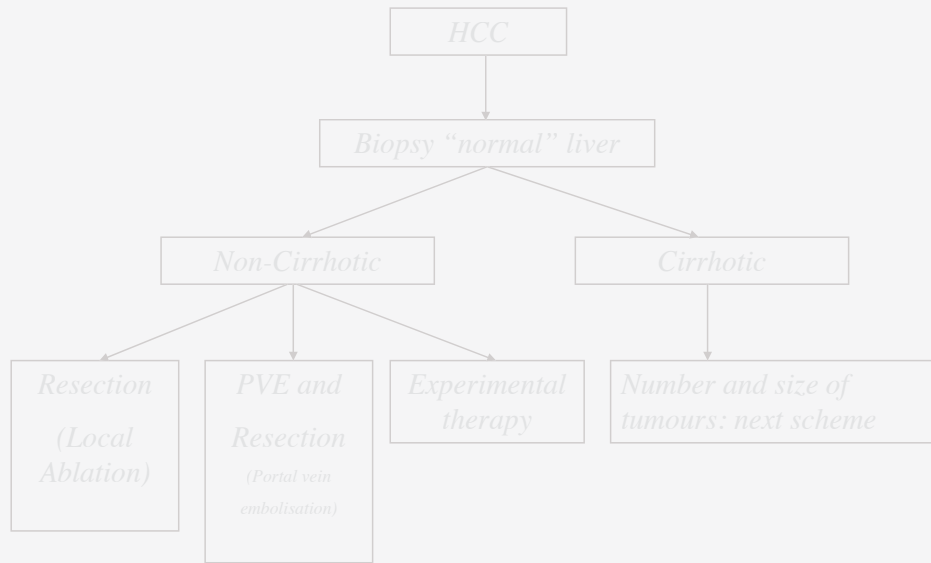
Prof. dr. A.M.M. Eggermont

Copromotor:

Dr. R.A. de Man

CONTENTS

Chapter I	Introduction and aim of the thesis	7
Chapter II	Hepatocellular carcinoma in the Netherlands: incidence, treatment and survival Patterns <i>Eur J Cancer</i> 2004;40:1530-1538	13
Chapter III	Detection of identical <i>Helicobacter</i> species in the non-cirrhotic liver and stomach of patients with hepatocellular carcinoma <i>Eur J Gastroenterol Hepatol</i> 2003;15:1171-1174	27
Chapter IV	Fluorine-18 FDG imaging in hepatocellular carcinoma using positron coincidence detection and single photon emission computed tomography <i>Liver</i> 2002;22:51-56	35
Chapter V	Cell biological evaluation of liver cell carcinoma, dysplasia and adenoma by tissue micro-array analysis. <i>Acta Histochem</i> 2005;107(3):161-71	45
Chapter VI	Good outcomes after resection of large hepatocellular carcinomas in the non-cirrhotic liver <i>Dig Surg</i> 2004;21:380-386	61
Chapter VII	Interstitial laser coagulation with temporary hepatic artery occlusion for patients with cirrhosis and irresectable unresectable hepatocellular carcinoma <i>Br J Surg</i> 2003;90:950-955	73
Chapter VIII	Radiofrequency ablation in patients with primary and secondary hepatic malignancies. <i>J Gastrointest Surg</i> 2006;10(7):960-73	85
Chapter IX	Resection of extrahepatic hepatocellular carcinoma metastases can result in long term survival <i>Acta Chir Belg</i> 2005;105(5):533-6	105
Chapter X	Identification of somatostatin receptors subtypes in human hepatocellular carcinomas: a clinical study. <i>Dig Surg</i> 2008: in press	113
Chapter XI	Summary and conclusions	123
Chapter XII	Samenvatting en conclusies	134
	Nawoord	145
	List of publications	151
	Curriculum Vitae	157



HCC non-cirrhotic liver

Chapter I

Introduction and aim of the thesis

GENERAL INTRODUCTION

Hepatocellular carcinoma (HCC) is the fifth most common cancer in the world and the third most common cause of cancer mortality¹. Despite the high numbers of patients diagnosed worldwide (the estimated number of people is 0.5 million cases per year), HCC continue to pose challenging clinical problems. The assessment of the tumor and treatment options needs a multi-disciplinary approach in which the surgeon plays a central role. The aim of this thesis is to update on the incidence, etiology, diagnostic and treatment modalities in patients with HCC.

Incidence

It is a disease with a highly uneven geographical distribution. In North America and several European countries, HCC is uncommon and the estimated death rate is less than 5/100.000 inhabitants/year^{2,3}. This in contrast to countries in the east and Africa where the incidence rates exceeds 30/100.000/year. An article of McGlynn⁴ about international trends and patterns of primary liver cancer suggested that developed countries (low endemic areas) have experienced an increase in primary liver cancer incidence whereas developing countries (high endemic areas) have experienced a decline. For example, the incidence increases in the United Kingdom⁵, France⁶ and the United States⁷. Publications describing epidemiological, treatment and survival figures are mostly derived from a selected group of patients⁸⁻¹¹. This may be of limited relevance. Therefore, a population-based study was performed to determine whether the reported changes in incidence were also observed in the Netherlands including all patients with HCC between 1989 and 2000. Treatment and survival patterns were also investigated between 1989 and 1998 in the Netherlands (**Chapter II**).

Etiology

Although solid experimental evidence for a single causative agent of HCC is lacking, there is a clear association of HCC with viral infections, including hepatitis B (HBV) and hepatitis C virus (HCV), alcoholic liver disease, haemochromatosis, tyrosinaemia, and long term use of aflatoxin, oral contraceptives or anabolic steroids. This epidemiological evidence has lead to the hypothesis that cirrhosis resulting from any cause is the seedbed for HCC¹². There are likely to be co-factors that modify the risk of known risk factors. In addition, in the western world, a significant proportion of patients with HCC arise in a non-cirrhotic liver. In case of a non-cirrhotic liver, a significant proportion of these patients lack a recognized risk factor. It is known that *Helicobacter* species can be carcinogenic. The possible relationship between the presence of *Helicobacter* species in the non-cirrhotic liver and stomach of patients with hepatocellular carcinoma and the detection of *Helicobacter* species was explored (**Chapter III**).

Diagnosis

Liver cirrhosis is present in the majority of patients with HCC ^{13,14}. Cirrhosis is a process of liver fibrosis that is characterized by architectural distortion and the development of nodules ranging from regenerative nodules to hepatocellular carcinoma ¹⁵. The complexity of the different parenchymal changes makes it difficult to detect and characterize liver lesions suspected for HCC with imaging procedures as ultrasonography, CT and MRI ¹⁶. There is a growing interest in the development of in vivo methods of assessing functional and metabolic parameters in normal and diseased tissues ^{17,18}. Positron emission tomography with fluorine-18-deoxyglucose (¹⁸FDG-PET) is one example of such a technique. PET is currently not widely available, mainly because of its high costs. Recently, alternative techniques for ¹⁸FDG imaging have become available: SPECT (Single Photon Emission Tomography) using special high-energy collimators and coincidence detection using adapted multi-head gamma cameras (3, 4). These techniques are less costly than PET. To which extent gamma camera coincidence imaging can be used for clinical purpose is currently being investigated for various applications, including oncological diagnostics (5). We performed a prospective clinical pilot study to investigate the additive value of ¹⁸FDG imaging by SPECT using special high-energy collimators and coincidence detection using adapted multi-head gamma cameras in patients with HCC. (**Chapter IV**). In patients with a focal liver lesion in whom the diagnosis is uncertain, a biopsy can be considered. The incidence of needle tract seeding among those with confirmed HCC is around 2% ²². Moreover, it may be difficult for a pathologist to distinguish liver cell adenomas from primary liver cell carcinomas. The false negative rate in a centre of excellence is about 10%. ²² We developed a liver tissue micro-array, and investigated various cellular biomarkers in order enhance the possibility to discriminate liver cell adenomas from carcinomas. This study is described in **Chapter V**.

Treatment

The prognosis of untreated patients with HCC is discouraging. However, early treatment may alter survival and to date surgical resection seems to be the gold standard. Series describe 5-year survival rates between 20 and 80%, depending on the inclusion criteria for treatment. Most of these series are coming from the eastern part of the world and southern Europe. Patients with HCC in these parts of the world have liver cirrhosis as underlying disease in 90 to 100%. So far, the prognosis of HCC in non-cirrhotic livers has not been studied extensively. We performed a study of patients with HCC in a non-cirrhotic liver and evaluated the effect of surgical treatment on survival (**Chapter VI**).

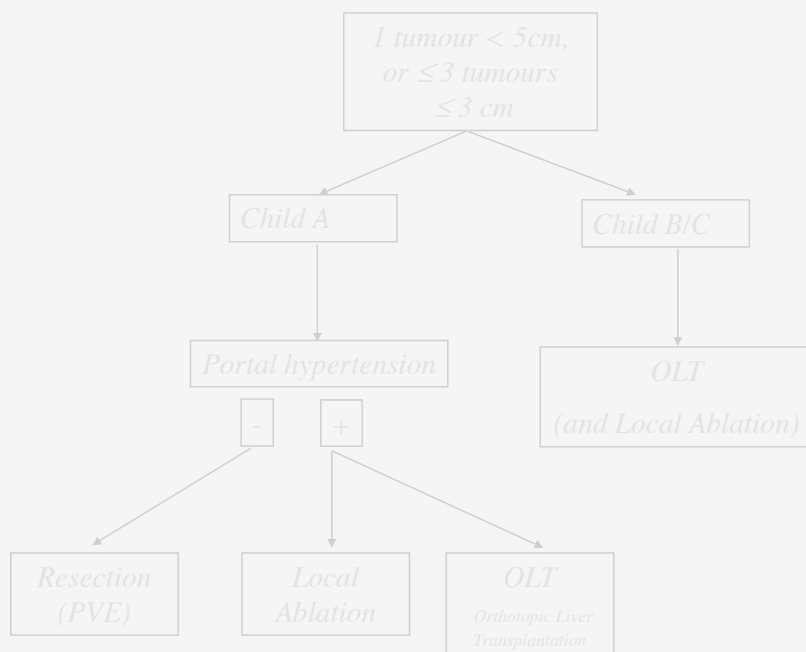
Due to the loss of functional reserve in the cirrhotic liver only 20% of patients with HCC and cirrhosis can tolerate partial liver resection. If the liver function is decompensated due to cirrhosis, orthotopic liver transplantation is the preferred treatment for HCC offering a 5-year survival comparable to other indications for transplanta-

tion in well-selected patients. However, the paucity of donor organs necessitates the development of alternative treatment modalities. Local thermal ablation methods (Radiofrequency, Cryoablation, Interstitial Laser Coagulation (ILC) are well-known and upcoming alternative treatment modalities with promising results. One of the major drawbacks of thermal ablation methods is the size of the tumor. To increase the effect of thermal ablation we performed a prospective clinical trial of ILC with temporary arterial occlusion in patients with HCC (**Chapter VII**). Because of the practical drawbacks of ILC and the success of RFA described by others we adapted our technique of thermal ablation and subsequently performed a prospective study using RFA as a local ablation method (**Chapter VIII**). Even when local tumor control can be achieved (as in complete resection), recurrence rates are as high as 80%. Since HCC is a chemo- and radiation insensitive tumor, resection or local thermal ablation are the only modalities offering chance for cure. For intra-hepatic recurrences, resection and ablation are accepted. Little is known about resection of extra-hepatic disease. Our experience in this field is described in **Chapter IX** and compared with findings from an extensive review of the literature.

HCC is relatively insensitive for chemotherapy and radiotherapy. Other systemic treatment modalities are being studied. In pre-clinical studies Somatostatin (SS) analogues have been demonstrated to inhibit the growth of a wide variety of tumours *in vivo* and *in vitro*. To date the results published on the efficacy of SS on survival of patients with HCC are conflicting. Some studies do not display a beneficial effect on the survival of patients with unresectable HCC's²³⁻²⁵, while others report a significant survival benefit²⁶⁻²⁸. Placebo controlled randomized trials do not show a significant benefit of SS on patient survival^{23,29}. In none of these studies it was investigated whether HCC tumours expressing SS-Rs may form a subgroup at the genetic level changing the sensitivity for SS treatment. To investigate the *ssr* in HCC and to test whether specific genetic alterations are associated with *ssr*-positive or *ssr*-negative HCC's, we examined protein (over) expression of tumour suppressor genes (p16, p53 and Rb1) by immunohistochemistry. In addition, the proliferative capacity was examined by immunostaining of Ki67 and the DNA ploidy status (aneuploidy) by using fluorescent in situ hybridization (FISH) with a chromosome 1-specific repetitive DNA probe. These results indicate the existence of *ssr* in human HCC and may help to clarify a correlation between *ssr* expression and patient characteristics, tumour size, underlying liver disease or alterations of investigated proto-oncogenes. (**Chapter X**)

References:

1. Parkin DM, Bray F, Ferlay J, Pisani P. Estimating the world cancer burden:GLOBOCAN 2000. *Int J Cancer* 2001;94:153-156.
2. Ramsey WH, Wu GY. Hepatocellular carcinoma: Update on diagnosis and treatment. *Dig Dis* 1995;13:81-91.
3. Bosch FX, Ribes J. Epidemiology of liver cancer in Europe. *Can J Gastroenterol* 2000;14(7):621-630.
4. McGlynn KA, Tsao L, Hsing AW, Devesa SS, Fraumeni Jr JF. International trends and patterns of primary liver cancer. *Int J Cancer* 2001;94:290-296.
5. Taylor-Robinson SD, Foster GR, Arora S, Hargreaves S, Thomas HC. Increase in primary liver cancer in the UK, 1979-94. *Lancet* 1997;350:1142-43.
6. Deuffic S, Poynard T, Buffat L, Valleron AJ. Trends in primary liver cancer. *Lancet* 1998;351:214-15.
7. El-Serag HB, Mason AC. Rising incidence of hepatocellular carcinoma in the United States. *N Engl J Med* 1999;340(10):745-50.
8. Stuart KE, Anand AJ, Jenkins RL. Hepatocellular carcinoma in the United States. Prognostic features, treatment outcome and Survival. *Cancer* 1996;77:2217-2222.
9. Fong Y, Sun RL, Jarnagin W, Blumgart LH. An analysis of 412 cases of hepatocellular carcinoma at a Western center. *Ann Surg* 1999;229:790-800.
10. Zhou XD, Tang ZY. Management of hepatocellular carcinoma: long-term outcome in 2639 cases. *Gan To Kagaku Ryoho* 1997;24(suppl1):9-16.
11. Cance WG, Stewart AK, Menck HR. The national cancer database report on treatment patterns for hepatocellular carcinomas. *Cancer* 2000;88:912-920.
12. Schafer DF, Sorrell MF. Hepatocellular carcinoma. *Lancet* 1999; 353:1253-1257.
13. Di Bisceglie AM. Hepatitis C and hepatocellular carcinoma. *Hepatology* 1997;26(suppl 1):34-8.
14. Haydon GH, Hayes PC. Screening for hepatocellular carcinoma. *Eur J Gastroenterol Hepatol* 1996;8:856-60.
15. Brown JJ, Naylor MJ, Yagan N. Imaging of hepatic cirrhosis. *Radiology* 1997;202:1-16.
16. Fernandez MDP, Redvanly RD. Primary hepatic malignant neoplasms. *Radiol Clin North Am* 1998;36:333-48.
17. Wagner HN Jr, Conti PS. Advances in medical imaging for cancer diagnosis and treatment. *Cancer* 1991;67:1121-28.
18. Srauss LG, Conti PS. The applications of PET in clinical oncology. *J Nucl Med* 1991;32:623-48.
19. Van Lingen A, Huijgens PC, Visser FC, et al. Performance characteristics of a 511-keV collimator for imaging positron emitters with a standard gamma-camera. *Eur J Nucl Med* 1992; 19: 315-21.
20. Patton JA. Instrumentation for coincidence imaging with multihead scintillation cameras. *Semin Nucl Med* 2000; 30: 239-54.
21. Ak I, Blokland JAK, Pauwels EKJ et al. The clinical value of ¹⁸F-FDG detection with a dual-head coincidence camera: a review. *Eur J Nucl Med* 2001 28:763-778.
22. Hertz G, Reddy VB, Green L, et al. Fine-needle aspiration biopsy of the liver: a multicenter study of 602 radiologically guided FNA. *Diagn Cytopathol* 2000;23:326-328.
23. Yuen MF, Poon RT, Lai CL, et al. A randomized placebo-controlled study of long-acting octreotide for the treatment of advanced hepatocellular carcinoma. *Hepatology* 2003;36:687-91.
24. Rabe C, Pilz T, Allgaier, et al. Clinical outcome of a cohort of 63 patients with hepatocellular carcinoma treated with octreotide. *Z Gastroenterol* 2002;40:395-400.
25. Raderer M, Hejna MH, Muller C, et al. Treatment of hepatocellular cancer with the long acting somatostatin analoglanreotide in vitro and in vivo. *Int J Oncol* 2000;16:1197-201.
26. Dimitroulopoulos D, Xinopoulos D, Tsimakidis K, et al. The role of sandostatin LAR in treating patients with advanced hepatocellular cancer. *Hepatogastroenterology* 2002;49:1245-50.
27. Samonakis DN, Moschandreas J, Arnaoutis T, et al. Treatment of hepatocellular carcinoma with long acting somatostatin analogues. *Oncol Rep* 2002;9:903-7.
28. Kouroumalis E, Skordilis P, Thermos K, Vasilaki A, Moschandrea J, Manousos ON. Treatment of hepatocellular carcinoma with octreotide: a randomised controlled study. *Gut* 1998;42:442-447.
29. Allgaier HP, Becker G, Olschewski M, et al. Octreotide treatment in patients with advanced hepatocellular carcinoma: first results of the randomized placebo-controlled double blind Hector trial. *Hepatology* 2003;38:760A.



HCC cirrhotic liver

Chapter II

Hepatocellular carcinoma in the Netherlands. Incidence, Treatment and Survival Patterns

Eur J Cancer 2004;40:1530-1538

ABSTRACT

To examine recent trends of hepatocellular carcinoma (HCC) in an unselected patient population in the Western world, cancer registration data of HCC in the Netherlands were analysed. Trends in incidence, mortality, treatment and survival, according to gender, age, stage of disease and period of diagnosis were studied.

We found no rising age-standardised incidence of HCC in the Netherlands during 1989 and 2000. In men older than 75 years, there was a significant increase. Mortality due to primary liver cancer increased in 1989-2000. There was no change in treatment pattern (1989-1998), whereas 73% of patients with HCC received no cancer-related therapy during this period of analysis. Twelve percent of the patients underwent either partial liver resection or orthotopic liver transplantation. This low percentage suggests that patients with HCC must be analysed and discussed in specialised centres to minimise the number of patients not receiving possible curative therapy.

INTRODUCTION

Hepatocellular carcinoma (HCC) is the fifth most common cancer in the world and the third most common cause of cancer mortality. The estimated number of people who develop HCC is 564,000 cases/year worldwide [1]. In North America and several European countries, HCC is uncommon and the estimated death rate is less than 5/100,000 inhabitants/year [2,3]. However, the incidence has been increasing in low-endemic areas, as has been reported for the United Kingdom [4], France [5] and the United States [6]. Most of the publications regarding incidence, treatment and prognosis of patients with HCC are derived from selected groups of patients [7-10]; because these may be of limited relevance, we performed a population-based study in the Netherlands including all patients with HCC diagnosed between 1989 and 2000. Trends in incidence, mortality, treatment and survival, according to gender, age, stage of disease and period of diagnosis were studied.

PATIENTS AND METHODS

Incidence, treatment and mortality.

Incidence (1989-2000) and treatment (1989-1998) data regarding liver tumours were provided by the population-based Netherlands Cancer Registry, for which 9 regional cancer registries collect data. All liver malignancies diagnosed and treated from 1989 onward in people living in the Netherlands, have been registered nation-wide [11]. Upon notification by the pathological laboratories or the hospital medical records departments, the registration clerks actively collect data (diagnosis, staging and treatment) on all new patients. Data are collected from the medical records of the various hospitals, usually within 6 months of diagnosis. Primary liver cancer was classified as HCC, cholangiocarcinoma, angiosarcoma, other sarcomas or tumours not otherwise specified. Due to privacy regulations, death certificates cannot be used as an additional source of notification of cancer cases in the Netherlands. Despite the lack of this notification source, the infrastructure of the Netherlands health care system and the notification procedures used have made it possible to establish a cancer registry with high completeness (96.2%) [12,13]. In the case of multiple tumours, the same rules were applied as those recommended by the International Association of Cancer Registries [14].

We calculated age-specific and age-standardised incidence rates. For the age-standardised rates the European population was used as a standard (European Standardised Rates, ESR). Treatment was scored as follows: surgery included partial liver resection or liver transplantation, chemotherapy was systemic or regional, other therapies included local ablation, systemic or local therapy (other than chemotherapy) and radiation. Statistics Netherlands provided mortality data. Trends in

incidence and mortality were estimated by calculating the Estimated Annual Percentage Change (EAPC) [15]. Mortality data are based on all primary liver cancers. Due to different coding during the study period, it was impossible to examine the mortality trends for the histological subgroups. For calculating age-standardized incidence rates in European cancer registries between 1978 and 1997 we used data of the EUROCIM (European cancer incidence and mortality) database. Only registries with data since 1978 were included. Age-adjustment was performed by direct standardization according to the European Standard Population (ESR: European Standardized Rate)[16].

Survival

Follow-up of cancer patients was completed in two regional cancer registries: the Amsterdam Cancer Registry, Comprehensive Cancer Centre Amsterdam (CCCA) and the Eindhoven Cancer Registry, Comprehensive Cancer Centre South (CCCS). Therefore, survival analyses were restricted to these registries. Together these covered an area of about 3.5 million inhabitants (+/- 25% of the total population in the Netherlands at that time). In addition to passive follow-up in the hospitals, active follow-up was done, using regional municipal databases and the national bureau for genealogy. The database of the bureau for genealogy contains data of all people deceased in the Netherlands. Follow-up was complete at least until 1 January 1999. Survival was analysed according to gender, age, tumour stage and treatment. Patients were staged according to the UICC staging system [17]. We calculated Kaplan-Meier curves: to analyse differences between subgroups the log-rank test was used. To calculate variation in survival within Europe, data of the EUROCARE database (a concerted action among European cancer registries) were used [18]. Patients diagnosed with primary liver cancer between 1990 and 1994 in European population-based cancer registries were included. For international comparison and for comparison with clinical studies, cases incidentally discovered at autopsy were excluded, as were those known to registries from the death-certificate-only (DCO). In case of multiple metachronous tumours, only the first-

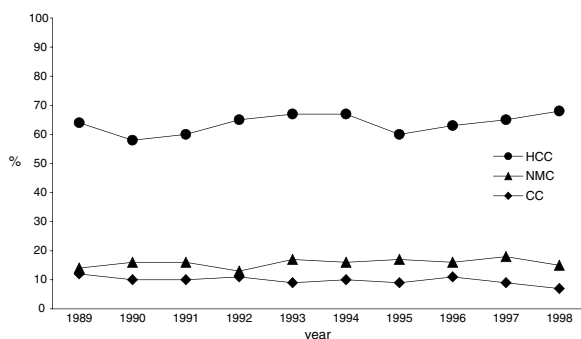


Fig. 1. Proportional distribution of the histological subtypes of primary liver cancer in the Netherlands (1989–1998). NMC: not microscopically confirmed; HCC: hepatocellular carcinoma; CC: cholangiocarcinoma.

diagnosed tumour was included for survival analysis. In EUROCARE, relative survival rates are computed. Relative survival is an estimation of disease-specific survival. It is calculated as the ratio of the observed to the expected survival rates. Expected survival rates were calculated from life tables for regional male and female populations with the same 5-year age distribution. Since the age distribution of patients differs between countries, the survival rates were adjusted to a common age structure.

RESULTS

Incidence

Between 1989 and 2000, 3048 primary liver cancers were recorded in the Netherlands. Liver cancer was about twice as common in males as in females. HCC was the predominant histology (64%) followed by cholangiocarcinoma (10%). In 16% of the cases the disease was not microscopically confirmed. The remaining 10% were angiosarcomas,

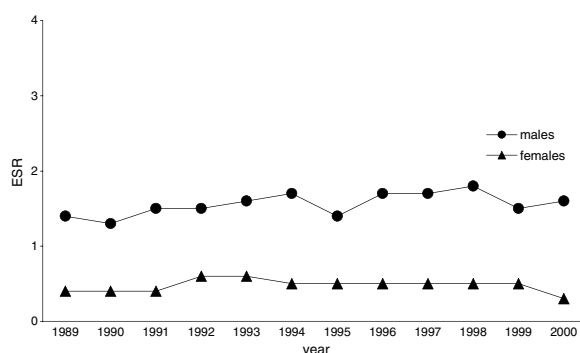


Fig. 2. The age-standardised incidence rate (patients/100 000/year) for HCC in the Netherlands (1989–2000). ESR: European standardised rates.

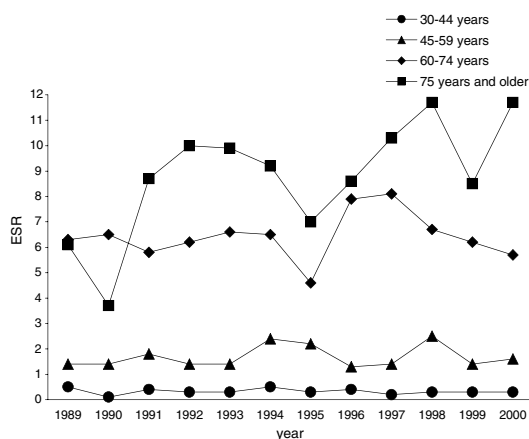


Fig. 3. HCC age-specific trends for males in the Netherlands (1989–2000). ESR: European standardised rates.

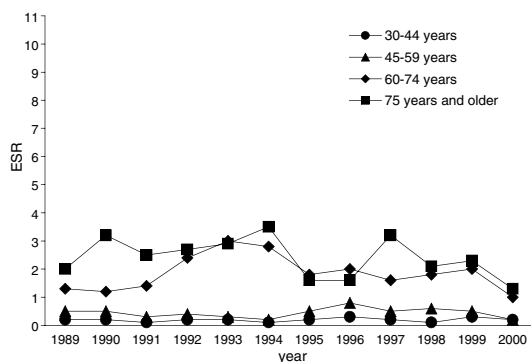


Fig. 4. HCC age-specific trends for females in the Netherlands (1989–2000). ESR: European standardised rates.

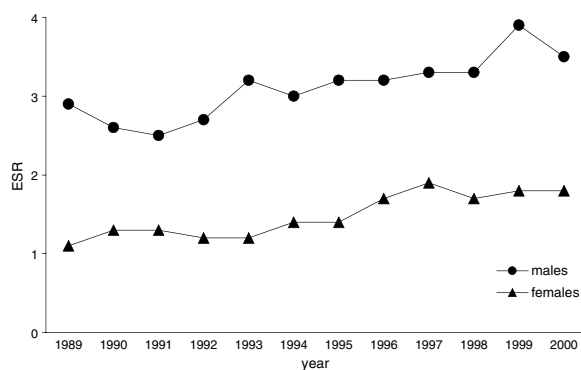


Fig. 5. Age-standardised mortality rates due to primary liver cancer in the Netherlands (1989–2000). ESR: European standardised rates.

Table 1 Incidence rates of HCC in Europe (patients/100 000/year); source: EUROCIM

	MALE		FEMALE	
	1988-1992	1993-1997	1988-1992	1993-1997
Estonia	1.72	2.34	0.65	0.84
England	1.30	1.65	0.38	0.51
Finland	3.35	3.28	1.29	1.01
France-North	9.31	9.94	0.97	0.88
Germany-Saarland	1.86	3.30	0.50	0.84
Iceland	3.29	3.34	0.64	1.27
Italy-Varese	10.40	14.10	2.23	2.26
Norway	1.46	1.36	0.58	0.56
Slovenia	2.87	3.34	0.55	0.85
Spain-Navarra	4.82	7.66	0.66	1.42
Sweden	3.67	3.40	1.49	1.33
Switzerland-Geneva	11.32	8.89	1.16	1.61
Scotland	2.27	3.02	0.55	0.72
The Netherlands	1.54	1.70	0.50	0.52

HCC, hepatocellular carcinoma.

other sarcomas, or tumours not otherwise specified. The percentages of the three largest groups, i.e. HCC, cholangiocarcinoma and tumours not microscopically confirmed, remained stable over time (1989-1998) (Figure 1). Between 1989 and 2000, 1964 new patients with HCC were registered in the Netherlands. The male/female ratio was 2.4:1. The age-standardised incidence rate (ESR) did not show a significant trend in these 12 years (Figure 2). In 2000 the ESR for males was 1.6/100,000 and for females 0.3/100,000. Figures 3 and 4 show the age-specific trends of HCC incidence. Besides in males older than 75 years, there was no significant increase of incidence.

Table 2 Treatment patterns of patients with HCC in the Netherlands according to age and time of diagnosis

Age (years)	Treatment	1989-1993 n %	1994-1998 n %	1989-1998 n %
< 45	Surgery	26 (37%)	17 (28%)	43 (33%)
	Chemotherapy	12 (17%)	11 (18%)	23 (17%)
	Other therapy	6 (8%)	7 (11%)	13 (10%)
	No therapy	27 (38%)	26 (43%)	53 (40%)
		71 (100%)	61 (100%)	132 (100%)
45-59	Surgery	20 (17%)	40 (23%)	60 (20%)
	Chemotherapy	9 (7%)	18 (10%)	27 (9%)
	Other therapy	16 (13%)	15 (8%)	31 (10%)
	No therapy	77 (63%)	103 (59%)	180 (60%)
		122 (100%)	176 (100%)	298 (100%)
60-74	Surgery	28 (8%)	46 (11%)	74 (10%)
	Chemotherapy	19 (5%)	15 (4%)	34 (4%)
	Other therapy	28 (8%)	46 (11%)	74 (10%)
	No therapy	278 (79%)	309 (74%)	587 (76%)
		353 (100%)	416 (100%)	769 (100%)
>75	Surgery	8 (4%)	12 (5%)	20 (5%)
	Chemotherapy	2 (1%)	3 (1%)	5 (1%)
	Other therapy	12 (6%)	19 (9%)	31 (7%)
	No therapy	172 (89%)	188 (85%)	360 (87%)
		194 (100%)	222 (100%)	416 (100%)
Total	Surgery	82 (11%)	115 (13%)	197 (12%)
	Chemotherapy	42 (6%)	47 (5%)	89 (6%)
	Other therapy	62 (8%)	87 (10%)	149 (9%)
	No therapy	554 (75%)	626 (72%)	1180 (73%)
		740 (100%)	875 (100%)	1615 (100%)

Mortality due to primary liver cancer increased (Figure 5). This trend was present both in males and in females (males EAPC = 3.1%, females EAPC = 4.6%) [19]. This was mainly caused by an increase in mortality in patients aged 60 or older. The age distribution has remained relatively stable throughout the study period. Two percent of all HCCs were diagnosed under the age of 29 years, about 3 patients yearly. The incidence was highest for men older than 75 years (12/100,000/year). Despite the low incidence rate there was a large variation in incidence within the Netherlands, especially among males. Among males the age standardised incidence rates were 2.5/100,000 in highly urbanised areas and only 0.7 in rural areas. These differences were only found for HCC and not for the other primary liver cancers. The incidence of HCC in several countries in Europe is given in Table 1. The incidence of HCC was relatively low in England, Norway and the Netherlands, and relatively high in France (North), Italy (Varese), Spain (Navarra) and Switzerland (Geneva).

Table 3 Survival patterns according to age and treatment in CCCS (comprehensive cancer centre south) and CCCA (comprehensive cancer centre amsterdam) of patients diagnosed with HCC between 1989-1998.

Treatment	5-year survival age < 60 years	5-year survival age > 60 years	5-year survival total population
Surgery	31%	25%	29%
Chemotherapy	5%	6%	6%
Other therapy	0%	0%	0%
No therapy	2%	2%	2%
Overall	5%	5%	5%

Treatment

Between 1989 and 1998, twelve percent (n=198) of the total HCC population underwent a partial liver resection or orthotopic liver transplantation (OLT) (Table 2). There was no difference in resection rate between males and females. During the 10-year study period, the resection rate remained stable. Patients younger than 45 years of age (n=132) had the highest resection rate (33%). Patients older than 75 years (n=416) had the lowest resection rate (5%). Seventy three percent did not get any form of cancer-related treatment; this did not change during the study period.

Survival

Table 3 gives the estimated 5-year survival rates according to Kaplan Meier, stratified according to age and treatment. Survival was best for patients with a resected tumour. Survival of patients diagnosed during 1989-1993 was the same as the survival of patients diagnosed during 1994-1998 (results not shown). Nor in the untreated group nor in the surgically-treated group a difference was found in survival between these two time intervals.

There was no difference in 5-year survival rate between males and females or between patients younger than 60 years and those older than 60 years. Five-year survival of

Table 4 Survival rates in Europe (1990-1994);Source:EUROCARE

	COV.	MALE		FEMALE		OVERALL	
	(%)	No of cases	surv	No of cases	surv	No of cases	surv
Estonia	100	138	3%	107	1%	245	2%
England	59	2222	6%	1370	8%	3592	7%
Finland	100	613	4%	597	4%	1210	4%
France-North	4	628	7%	145	9%	773	7%
Germany	2	133	5%	77	6%	210	5%
Italy	14	4004	7%	1825	8%	5829	7%
Norway	100	247	3%	190	4%	437	3%
Slovenia	100	162	6%	78	4%	240	5%
Spain	6	881	10%	349	10%	1230	10%
Sweden	100	1215	3%	967	3%	2182	3%
Switzerland	13	137	6%	43	0%	180	5%
Scotland	100	515	4%	321	5%	836	4%
The Netherlands	23	268	6%	91	3%	359	5%

COV: Coverage of the country

surv: 5-year relative survival rate

patients with tumour stage I/II or III (13%) was significantly better than for those with tumour stage IV (1%). In the surgically-treated group, there was also a difference in 5-year survival between tumour stage I/II and tumour stage III (48% and 24%, respectively, $p=0.06$). In the group of patients who did not receive surgery or chemotherapy, patients with tumour stage I/II and III had a 2-year survival rate of 14% and 18%, respectively and both had a 5-year survival rate of only 2%. Patients with tumour stage IV had the poorest survival (2-year survival-rate of 3 % and no 5-year survivors). Relative 5-year survival of patients with HCC in the Netherlands was average compared to other European countries (Table 4).

DISCUSSION

The results of this study show that the incidence of HCC in the Netherlands was stable during 1989 - 2000. This is in contrast with recent publications that described an increased incidence in other low-endemic areas [4-6,20]. An article of McGlynn and colleagues about international trends and patterns of primary liver cancer, suggested that developed countries have experienced an increase in primary liver cancer incidence whereas developing countries have experienced a decline [21]. The apparent changes in liver cancer rates as described world-wide are not fully understood. Possible explanations for the rise in low-endemic areas may be the rise of hepatitis C

viral (HCV) infections, improved survival of cirrhotic patients, and a better diagnostic work-up [21-25]. Another possible explanation for the rise is the increased proportion of immigrants from high-endemic areas. The relatively high proportion of immigrants from high-risk areas in the world could explain the high rates in urbanised areas in our study. However, during our 12-year study period, the incidence of HCC in urbanised areas also remained stable (results not shown).

The geographic variation in different incidence rates within Europe strongly correlates with the prevalence of hepatitis infection and the prevalence of liver cirrhosis by any cause [3]. Therefore, the incidence rates in France, Italy, Switzerland and Spain are markedly higher than in the other European countries (Table 1).

Diagnostic work-up has changed over time. Computed tomography and high-resolution MRI of the liver have facilitated the diagnosis of liver malignancies. One may consider that if there is an increase for all primary liver cancers this reflects a better diagnostic work-up of liver malignancies. This could be an explanation for the increasing incidence for both intrahepatic cholangiocarcinoma and HCC in the United States and the United Kingdom [4,6,26,27]. We did not find an increasing trend for HCC, cholangiocarcinoma or any other primary liver malignancies (Fig.1). These data support the concept that a better diagnostic work-up for patients or accuracy of registration probably did not influence the incidence rate in our study.

The terms HCC and primary liver cancer are often used interchangeably. In Japan, 94% of all primary liver cancers were HCC [25], compared with 64% in our study and 74% in the USA [6]. Therefore it is more accurate to describe the primary liver cancers separately if the population is based on Western-world standards. Differences in study design might explain the difference between our results and studies reporting an increase of HCC [4-6,20,22,28].

The study of El-Serag and colleagues [6] used the data on incidence from the Surveillance, Epidemiology and End Results (SEER) Program of the National Cancer Institute and found a rising incidence. Since this database accounts for 14% of the American population, it may not reflect the U.S.A. as a whole (SEER regions are more urban and have a higher proportion of foreign-born persons than the general U.S. population) [6,29]. El-Serag and colleagues [6] analysed mortality and data on hospitalisation. The results of these two measures were similar to the observed increasing incidence rate of HCC. This strengthens the internal validity of the observed increasing incidence trend. However, it has been stated that analyses on mortality data are not very reliable if one analyses a subgroup of cancer [22] and the data on hospitalisation were of a specific subgroup of the population; i.e. U.S. veterans, mainly men. We found a significant rise of mortality due to primary liver cancer. This is in contrast to the stable incidence rate of the primary liver cancers during the same period (Figure 1). An increasing incidence in the period before this study with long-time survivors, is a very unlikely explanation in this usually rapid fatal disease. In a recent update of the study of El-Serag and colleagues [29], the incidence of HCC continues to increase in the United States, with

rates increasing the fastest in white men 45 to 54 years of age. If age-adjusted rates are analysed, age-specific trends can be diverse. Therefore, we analysed our data according to specific age groups in both sexes (figures 3 and 4). In males older than 75 years, there was a significant increase. We have not a conclusive explanation for this phenomenon. An aging population is an unlikely explanation for this increase in HCC since it did not affect females. The most likely explanation is that the increase of HCC incidence in males older than 75 years is confound by the small numbers of patients (323 patients in 12 years). It may also reflect an influx of male immigrants in the last decades. An increase of HCV infection during the seventies is another suggestion however this does not explain the sex difference. After HCV infection it takes about 25 years to develop liver cirrhosis. Afterwards there is an incidence of 1 or 2 percent annually to develop HCC.

In our study, a high proportion of patients with HCC (73%) did not receive cancer-related treatment. In the USA, e.g., 51% of the HCC patients received no treatment [10]. To our knowledge, there are no other western data on the percentage of patients who received treatment without any referral bias. In view of the promising local ablation methods [30] and the successful living related liver transplantation program [31], the percentage of patients receiving no treatment may decline in the near future. In our series, however, there was no trend towards this phenomenon. Of all patients, 12% were treated by partial liver resection or OLT. This is interesting because this percentage is in the absence of any referral bias. In experienced centres, the reported resection rates (**not** including OLT) are, e.g., 37% [8], 49% [32] and even 67% [33]. Resection rates of patients with HCC without referral bias are scarce in the literature. Cance and colleagues [10] (data representing approximately 14% of the estimated cases of carcinomas of the liver and biliary tract diagnosed in the USA) found a resection rate of 17%, excluding the patients who underwent OLT. We have the impression that our percentage (12%) with either partial liver resection or OLT is low. Reasons for this low percentage need to be explored. The underlying liver disease (60-95%) [34-36], the older age of patients (75% older than 60 years in this study) and the usually large tumour diameter of patients without underlying liver cirrhosis (mean 9 and 10 cm) [37,38] are known drawbacks for resection. However, liver cirrhosis is nowadays not an absolute contra-indication for even major liver resections in specialised centres [39]. Liver resection in the elderly patients with HCC has short- and long-term results comparable to those of younger patients, if well selected and if they receive specialised postoperative care [40,41]. Despite the usually large tumour diameter in the non-cirrhotic liver, 5-year survival rates of 40% after partial liver resection have been reported [37,38]. To minimize the number of patients not receiving possible curative therapy, we suggest that all patients with HCC must at least be discussed in specialised centres, offering consultation service.

The 5-year survival rate of 29% after resection/OLT is rather low compared to the 5-year survival rates found in the literature. It is difficult to explain this difference since

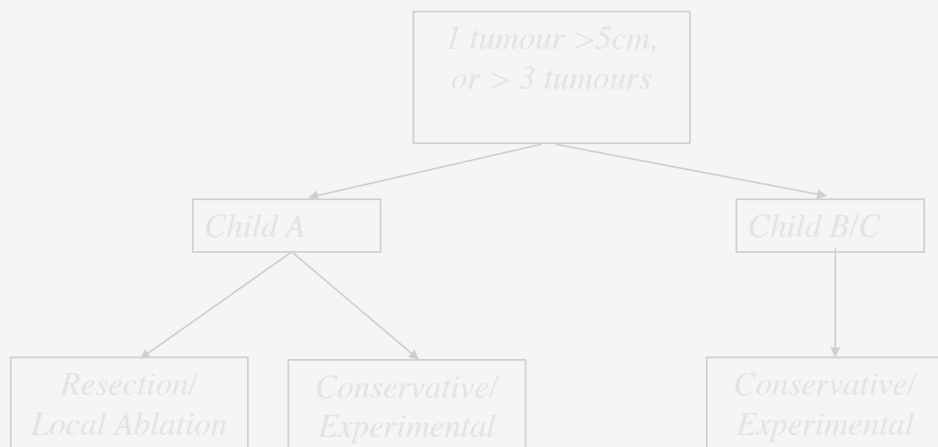
the survival after resection or OLT is highly influenced by underlying liver disease, vascular invasion, size and number of the tumour nodules. This is exactly the reason why the TNM classification [17] does not have prognostic power in patients with HCC [42]. However, the survival rate in our study is interesting because, in contrast to previous studies, it is without any referral bias. Previous reports have demonstrated that women appear to have better survival outcomes from HCC than men [10,43]. In the current report, enhanced survival among women was not observed; this was seen in all treatment modalities and the untreated group. Cance and colleagues [10] suggested that especially women with tumour stage II and III had a better survival than men, however, even in this subgroup we did not find better survival rates for females. Table 4 gives the relative survival rates at 5 years among several European countries between 1990 and 1994 (EUROCARE III). There are small intercountry differences in survival. Survival rates were slightly higher in England, Italy and France than in the other countries. It is unclear if the intercountry differences are a result of differences in stage at diagnosis and/or more aggressive therapeutic approaches, or a methodological difference (completeness) [44].

In conclusion: This is (to our knowledge) the first study that reports on incidence data and treatment patterns of a whole country. In contrast to previous reports of sub populations in non-endemic areas, we found no age-standardised rising incidence of HCC in the Netherlands between 1989 and 2000. There was no change in treatment pattern. Seventy-three percent of patients with HCC received no therapy and only 12% of the patients underwent either partial liver resection or OLT. This low percentage suggests that patients with HCC must be analysed and discussed in specialised centres to minimise the number of patients not receiving possible curative therapy.

References

1. Parkin DM, Bray F, Ferlay J, Pisani P. Estimating the world cancer burden: GLOBOCAN 2000. *Int J Cancer* 2001;94:153-156.
2. Ramsey WH, Wu GY. Hepatocellular carcinoma: Update on diagnosis and treatment. *Dig Dis* 1995;13:81-91.
3. Bosch FX, Ribes J. Epidemiology of liver cancer in Europe. *Can J Gastroenterol* 2000;14(7):621-630.
4. Taylor-Robinson SD, Foster GR, Arora S, Hargreaves S, Thomas HC. Increase in primary liver cancer in the UK, 1979-94. *Lancet* 1997;350:1142-43.
5. Deuffic S, Poynard T, Buffat L, Valleron AJ. Trends in primary liver cancer. *Lancet* 1998;351:214-15.
6. El-Serag HB, Mason AC. Rising incidence of hepatocellular carcinoma in the United States. *N Engl J Med* 1999;340(10):745-50.
7. Stuart KE, Anand AJ, Jenkins RL. Hepatocellular carcinoma in the United States. Prognostic features, treatment outcome and Survival. *Cancer* 1996;77:2217-2222.
8. Fong Y, Sun RL, Jarnagin W, Blumgart LH. An analysis of 412 cases of hepatocellular carcinoma at a Western center. *Ann Surg* 1999;229:790-800.
9. Zhou XD, Tang ZY. Management of hepatocellular carcinoma: long-term outcome in 2639 cases. *Gan To Kagaku Ryoho* 1997;24(suppl1):9-16.
10. Cance WG, Stewart AK, Menck HR. The national cancer database report on treatment patterns for hepatocellular carcinomas. *Cancer* 2000;88:912-920.
11. Sanden van der GAC, Coebergh JWW, Schouten LJ, Visser O, van Leeuwen FE. Cancer incidence in the Netherlands in 1989 and 1990: first results of the nation-wide Netherlands Cancer Registry. *Eur J Cancer* 1995;31A:1822-1829.
12. Schouten LJ, Hoppener P, van den Brandt PA, Knottnerus JA, Jager JJ. Completeness of cancer registration in Limburg, the Netherlands. *Int J Epidemiol* 1993;22:369-376.
13. Berkel J. General practitioners and completeness of cancer registry. *J Epidemiol Community Health* 1990;44:121-124.
14. IARC/IACR. Multiple primaries. IARC Internal Report No. 94/003. Lyon, France: International Agency for Research on Cancer 1994.
15. Kleinbaum DG, Kupper LL, Muller KE. Applied regression analysis and other multivariable methods. Boston: PWS-Kent Publishing Company. 1988.
16. Ferlay J, Bray F, Sankila R, et al. European Network of Cancer Registries. EUROCIM User Manual, 3rd edn. Lambda-Plus Software.
17. Hermanek P, Sobin LH. TNM classification of malignant tumors. Berlin: Springer, 1992:104-12.
18. Eurocare Working Group. Eurocare-3: the survival of cancer patients diagnosed in Europe during 1990-1994. *Ann Oncol* 2003 (in press).
19. Visser O, Siesling S, van Dijck JAAM. Incidence of cancer in the Netherlands 1999/2000. Utrecht: Vereniging van Integrale Kankercentra, 2003.
20. Irvine HDV, Goldberg D, Hole DJ, McMenamin J. Trends in primary liver cancer. *Lancet* 1998;351:215-216.
21. McGlynn KA, Tsao L, Hsing AW, Devesa SS, Fraumeni Jr JF. International trends and patterns of primary liver cancer. *Int J Cancer* 2001;94:290-296.
22. Sharp GB, Cologne JB, Fukuhara T, Itakura H, Yamamoto M, Tokuoka S. Temporal changes in liver cancer incidence rates in Japan: Accounting for death certificate inaccuracies and improving diagnostic techniques. *Int J Cancer* 2001;93:751-758.
23. La Vecchia C, Lucchini F, Franceschi S, Negri E, Levi F. Trends in mortality from primary liver cancer in Europe. *Eur J Cancer* 2000;36:909-15.
24. Howe HL, Wingo PA, Thun MJ, et al. Annual report to the nation on the status of cancer (1973 through 1998), featuring cancers with recent increasing trends. *J Natl Cancer Inst* 2001;93:824-842.
25. Parkin DM, Whelan S, Ferlay J, et al. (eds). Cancer incidence in five continents, 143rd ed, volume VII. Lyon, France: IARC Scientific Publications 1997.
26. Patel T. Increasing incidence and mortality of primary intrahepatic cholangiocarcinoma in the United States. *Hepatology* 2001;33:1353-1357.

27. Taylor-Robinson SD, Toledano MB, Arora S, et al. Increase in mortality rates from intrahepatic cholangiocarcinoma in England and Wales 1968-1998. *GUT* 2001;48:816-820.
28. Benhamiche AM, Faivre C, Minello A, et al. Time trends and age-period-cohort effect on the incidence of primary liver cancer in a well-defined French population:1976-1995. *J Hepatol* 1998;29:802-806.
29. El-Serag H, Davilla JA, Petersen NJ, McGlynn KA. The continuing increase in the incidence of hepatocellular carcinoma in the United States: an update. *Ann Intern Med* 2003;139:817-823.
30. Poon RT, Fan ST, Tsang FHF, Wong J. Locoregional therapies for hepatocellular carcinoma: a critical review from the surgeon's perspective. *Ann Surg* 2002;235:466-486.
31. Gondolesi G, Munoz L, Matsumoto C, et al. Hepatocellular carcinoma: A prime indication for living donor liver transplantation. *J Gastrointest Surg* 2002;6:102-107.
32. Lise M, Bacchetti S, Da Pian P, Nitti D, Pilati PL, Pigato P. Prognostic factors affecting long term outcome after liver resection for hepatocellular carcinoma: results in a series of 100 Italian patients. *Cancer* 1998;82:1028-1036.
33. Zhou XD, Tang ZY, Yang BH, et al. Experience of 1000 patients who underwent hepatectomy for small hepatocellular carcinoma. *Cancer* 2001;91:1479-86.
34. Nzeako UC, Goodman ZD, Ishak KG. Hepatocellular carcinoma in cirrhotic and non cirrhotic livers. A clinico-histopathologic study of 804 North American patients. *Am J Clin Path* 1996;105:65-75.
35. Nakshima T, Okuda K, Kojiro M, et al. Pathology of hepatocellular carcinoma in Japan: 232 consecutive cases autopsied in ten years. *Cancer* 1983;51:863-77.
36. Liver Cancer Study Group of Japan: Clinicopathologic features and results of surgical treatment. *Ann Surg* 1990;211:277-87.
37. Bismuth H, Chiche L, Castaing D. Surgical treatment of hepatocellular carcinomas in noncirrhotic liver: experience with 68 liver resections. *World J Surg* 1995;19:35-41.
38. Fong Y, Sun RL, Jarnagin W, Blumgart LH. An analysis of 412 cases of hepatocellular carcinoma at a western center. *Ann Surg* 1999;229:790-800.
39. Poon RT, Fan ST, Lo CM, et al. Extended hepatic resection for hepatocellular carcinoma in patients with cirrhosis: Is it justified? *Ann Surg* 2002;236:602-611.
40. Wu CC, Chen JT, Ho WL, et al. Liver resection for hepatocellular carcinoma in octogenarians. *Surgery* 1999;125:332-8.
41. Nagasue N, Chang YC, Takemoto Y, Taniura H, Kohno H, Nakamura T. Liver resection in the aged (seventy years or older) with hepatocellular carcinoma. *Surgery* 1993;113:148-54.
42. Llovet JM, Bruix J, Fuster J, et al. Liver transplantation for small hepatocellular carcinoma: The tumor-node-metastasis classification does not have prognostic power. *Hepatology* 1998;27:1572-7.
43. Ng IO, Ng MM, Lai EC, Fan ST. Better survival in female patients with hepatocellular carcinoma. Possible causes from a pathologic approach. *Cancer* 1995;75:18-22.
44. Faivre J, Forman D, Esteve J, Obradovic M, Sant M and the EURO CARE working group. Survival of patients with primary liver cancer, pancreatic cancer and biliary tract cancer in Europe. *Eur J Cancer* 1998;34:2184-2190.



HCC cirrhotic liver

Chapter III

Detection of identical *Helicobacter* DNA in the stomach and in the non-cirrhotic liver of patients with hepatocellular carcinoma

Eur J Gastroenterol Hepatol 2003; 15:1171–1174

ABSTRACT

Objectives: Studies have implied the presence of *Helicobacter* species in the human liver. The possible relationship between the presence of *Helicobacter* species in the non-cirrhotic liver of patients with hepatocellular carcinoma (HCC) and the detection of *Helicobacter* species in their stomach was explored.

Patients and methods: A 16S rDNA-based polymerase chain reaction (PCR) followed by DNA sequence analysis of the obtained PCR fragments was performed on 51 surgically obtained non-cirrhotic liver specimens and 14 gastric samples.

Results: Analysis indicated a significant difference in the presence of *Helicobacter*-species-specific DNA in the liver of patients with HCC compared with controls. Sequence analysis of these PCR products obtained from HCC patients indicated that they were related most closely to the 16S rDNA sequence of *Helicobacter pylori* but that they always differed at the same two positions. This same aberrant *Helicobacter*-species-specific 16S rDNA could be isolated in gastric samples of patients with HCC.

Conclusion: These data suggest that gastric colonization with a specific subset of *Helicobacter* strains is associated with the induction of HCC, either directly via colonization of the liver or indirectly, e.g. via secretion of specific toxins by *Helicobacter* residing in the stomach.

INTRODUCTION

Hepatocellular carcinoma (HCC) is one of the most common cancers in men and its incidence is increasing in low-endemic areas, such as the UK [1], France [2] and the USA [3]. Depending on the geographical location, the prevalence of HCC arising from non-cirrhotic liver varies between 9 and 54% [4]. A significant proportion of patients with non-cirrhotic liver lack a recognized risk factor.

In 1994 it was reported that hepatic colonization with a spiral-shaped, Gram-negative bacterium was associated with chronic active hepatitis and high incidence of hepatocellular tumours in A/JCr mice [5,6]. Since then, several investigators have reported on a putative hepatic *Helicobacter* colonization in patients with various liver diseases [7–16]. In most of these studies, a causative relationship between the presence of *Helicobacter* in the liver and the occurrence of HCC is suggested, but others doubt such a relation and attribute it to selection bias, small sample numbers, and secondary infection of the diseased liver with gastric *Helicobacter* [17].

To our knowledge, there are no published data that correlate the presence of the hepatic *Helicobacter* isolates with the presence/absence of gastric *Helicobacter* in HCC patients. This demands further studies to explore the possibility of a relationship between *Helicobacter* species that colonize the liver and HCC in humans, and to relate these findings with that of a possible *Helicobacter* species in their stomach.

PATIENTS AND METHODS

Patients

All consecutive patients with colorectal metastases or HCC in non-cirrhotic liver were included in our study. At the time when patients underwent liver resection, sterile, non-tumourous liver tissue was sampled. Twenty patients with HCC in non-cirrhotic liver (seven (35%) female, 13 (65%) male; median age 61 years) and 31 patients with colorectal liver metastases as a control group (11 (35%) female, 20 (65%) male; median age 62 years) were studied. Histological examination of the resected liver specimen confirmed the presence of HCC or colorectal metastases and the absence of liver cirrhosis. Nine patients who underwent liver resection because of HCC gave informed consent to obtain gastric samples. Liver samples and gastric samples were stored in liquid nitrogen until further use.

DNA extraction

DNA was extracted from the frozen liver and stomach tissue using the commercially available Wizard Genomic DNA Purification System (Promega, Madison, WI, USA) and stored at –80°C until required for polymerase chain reaction (PCR) amplification. Polymerase chain reaction amplification, cloning and sequencing of 16S rDNA, and 16S

rDNA data analysis. The extracted DNA was used in a nested PCR. To increase sensitivity, samples were first subjected to PCR amplifying eubacterial 16S rDNA sequences using primer 16SEubacF and 16SEubacR (Table 1). The amplification products were subsequently used in *Helicobacter*-specific PCR using primers *HelicospeciesF* and *HelicospeciesR* (Table 1), which are located within the fragment amplified in the first reaction. Primers *HelicospeciesF* and *HelicospeciesR* gave positive reaction with all ten gastric and five enterohepatic *Helicobacter* species tested. The presence of *cagA* and *cagE* as a marker for the *cag* pathogenicity island was assessed by PCR with primers listed in Table 1.

Table I

Oligonucleotide primers used to amplify the 16s rRNA gene and beta-globulin

Primer	Primer sequence (5'-3')	Amplicon size	Cycle
16sEubacF	CTTACGCCCATTTAATCCG	500 bp	95 °C(30"), 60 °C(30")*, 72 °C(1'), 20 cycles
16sEubacR	AGAGTTTGATCCTGGTTCAG		95 °C(30"), 50 °C(30"), 72 °C(1'), 20 cycles
<i>HelicospeciesF</i>	aacgatgaagcttctagcttgtag	400 bp	95 °C(30"), 50 °C(30"), 72 °C(1'), 40 cycles
<i>HelicospeciesR</i>	gtgcttattcgtagataccgcat		
Beta-GlobulinF	ACACAACTGTGTCTACTAGC	329 bp	95 °C(30"), 50 °C(30"), 72 °C(1'), 40 cycles
Beta-GlobulinR326	CATCAGGAGTGGACAGATCC	436 BP	95 °C(30"), 52 °C(30"), 72 °C(1'), 40 cycles
Cag A-F	GCCACTACTACCACCGACAT		
Cag A-R	CGTTGTGAGCCTGTGAGTTG	756 BP	95 °C(30"), 52 °C(30"), 72 °C(1'), 40 cycles
Cag E-F	TGTTGGTTTCCCTGAACT		
Cag E-R	AGCTTGGCTCTAATAATCCT		

All PCR programs end with a 10 min extension step at 72°C

* After every cycle the annealing temperature was decreased with 0.5 °C.

PCR was performed, essentially as described in previous studies [18], using the PCR Core System (Promega), using 1 unit Tag DNA polymerase, 1.5 mM MgCl₂, 0.2 mM of each nucleotide and 10 pmol of each primer. Amplification was performed in a total volume of 50 l following the PCR programme as described in Table 1. The nucleotide sequence of the PCR fragments was determined by direct DNA sequencing and checked against the GenBank databases using the Blast program at the National Center for Biotechnology Institute (NCBI, www.ncbi.nlm.nih.gov/blast) for the presence of homologous sequences. Water processed together with the liver samples was always included in order to exclude contamination. As controls, five gastric biopsy samples from patients with *Helicobacter pylori*-related gastric complaints but without HCC, and the purified DNA from the *H. pylori* reference strain 26695 [19] were used. PCR on the beta-globulin gene (Table 1) was performed on all samples to exclude false-negative PCR due to inhibition.

RESULTS

Nested PCR showed that nine (45%) of the 20 HCC patient liver samples were positive, whereas only three (9.6%) of the 31 samples from the control group were positive. This difference was highly significant (Pearson chi-squared test, $P < 0.004$). The sequences obtained from the positive PCR samples gave identical sea quences; the sequence obtained was related most closely to that of *H. pylori* but always differed at two base pair positions from the sequence of the *H. pylori* a reference strain (Table 2). We were also able to obtain a gastric biopsy sample from nine of the 20 HCC patients, of which three (33%) samples tested positive for *H. pylori* in routine diagnostic culture procedures. This was in agreement with the three (33%) of nine gastric samples that tested positive in nested PCR. One patient was infected with a *cag*-positive strain and two patients were infected with a *cag*-negative strain. None of the nine HCC patients who underwent gastroscopy had complaints of peptic ulcer disease or gastroscopic view of peptic ulcer disease. Sequence analysis revealed that the same two specific base pair differences were also present in the 16S rDNA fragments from these gastric *Helicobacter* (Table 2). The *Helicobacter* status of the gastric samples correlated with the liver samples, i.e. all patients with positive gastric samples also had positive liver samples while all patients with negative gastric samples also had negative liver samples. All 51 samples were positive in the beta-globulin PCR, indicating that there were no false-negative PCRs due to inhibition of the samples. The five control gastric biopsy samples (i.e. from patients with *H. pylori*-related gastric complaints and without HCC) were all positive for *H. pylori* in routine diagnostic culture. These five gastric samples all tested positive in nested PCR. Sequence analysis from these samples gave identical sequences of the *H. pylori* reference strain (Table 2).

Table II

16S rDNA sequence differences of the detected *Helicobacter* spp. compared to the reference strain

	Reference	92#	130#
<i>Helicobacter pylori</i> reference strain 26695	[19]	A	C
Liver samples HCC	Present series	G	T
Liver samples colorectal metastases	Present series	G	T
Ponzetto et al.	[12]	G	T
Avenauid et al.	[11]	G	T
Cultured <i>Helicobacter</i> from liver	[14]	G	T
Gastric samples from control group	Present series	A	C
Gastric samples from HCC patients	Present series	G	T

numbering according to 16S rRNA of *H. pylori* strain 26695 [19]

G:Guanine, T:Thymine, A:Adenine, C:Cytosine

DISCUSSION

Although solid experimental evidence for a single causative agent of HCC is lacking, there is a clear association of HCC with infections with hepatitis B virus (HBV) and hepatitis C virus (HCV), alcoholic liver disease, haemochromatosis, tyrosinaemia, and long-term use of oral contraceptives and anabolic steroids. This epidemiological evidence has led to the hypothesis that cirrhosis resulting from any cause is the seedbed for HCC [20]. However, in a significant proportion of patients with HCC in non-cirrhotic liver, no risk factor can be identified.

In 1994 it was demonstrated that infection with *Helicobacter hepaticus* resulted in hepatitis and hepatic tumour induction in mice [5,6]. In 1997 a significantly higher prevalence of immunoglobulin G (IgG) antibody against *H. pylori* in patients with liver cirrhosis than in controls ($P < 0.0005$) was reported [15]. Subsequent studies report an increased prevalence of *Helicobacter* DNA in the liver of patients with HCC, further supporting the notion that *Helicobacter* plays a role in the occurrence of HCC in humans [11–16]. As these studies are based mostly on the analysis of biopsy materials from cirrhotic livers, it is unclear whether the presence of *Helicobacter* species is the cause or merely the result of the cirrhosis. To address this issue, the presence of *Helicobacter* DNA in liver samples of patients with HCC in non-cirrhotic livers was examined. Matched controls were obtained from a group with virtual absence of any liver abnormalities, except for the presence of a tumour in a distinct location. The observed higher incidence of *Helicobacter* DNA in the HCC group supports the hypothesis of *Helicobacter* being a risk factor rather than an innocent bystander for HCC.

In our study, two HCC patients were HCV-positive. Of these two patients, one was positive for *Helicobacter* DNA. The higher frequency of *Helicobacter* species in the liver of patients with HCC than in the liver of patients with colorectal metastasis is therefore unlikely to be the result of HCV infection or any other known risk factor.

Recently, Coppola and colleagues [17] reported that they were unable to detect *Helicobacter* DNA in the liver of 28 patients. From this they concluded that *Helicobacter* species are not associated with specific hepatobiliary disease and that the increased prevalence might have been due to the tumour process, which favours cholestasis, and not to a specific role of *Helicobacter* in the carcinogenic process. In our study group, all patients in the control group (colorectal liver metastases) had a liver tumour. Despite this, there was a significantly higher frequency of *Helicobacter* species DNA in the non-cirrhotic liver of patients with HCC. The discrepancy between the data reported by Coppola and colleagues [17] and in our study may be explained by the less sensitive (non-nested) PCR approach used by them. If so, this indicates that only small amounts of bacterial DNA are present in the liver. This then poses the question: is there a true colonization of the liver or does it represent bacterial DNA from phagocytosed gastric *Helicobacter* that enter the liver via the macrophages of the portal blood flux?

The gastric samples we have obtained in patients with HCC correlated with the liver samples of these patients. Patients with positive gastric samples (with the same two mutations specific for the *Helicobacter*-specific PCR fragments found in the liver) also had positive liver samples, while patients with negative gastric samples had negative liver samples. Gastric *Helicobacter* may survive intestinal and bile acids and descend into the liver through the duodenum and common bile duct. The DNA sequences obtained from the liver and stomach specimens in our study were related most closely to that of *H. pylori* but always differed at two base pair positions from the sequence of the *H. pylori* reference strain (Table 2). Interestingly, our sequence data are identical to the sequences of liver *Helicobacter* found in the studies by Avenaud and colleagues [11] and Ponzetto and colleagues [12] (Table 2). It is possible that a specific subspecies of *Helicobacter*, marked by the two typical mutations of the 16S rDNA, produces a specific factor that leads to the occurrence of HCC and thus may represent another extraintestinal manifestation of *H. pylori* infection [21,22].

To answer the question whether there is a true colonization of the liver or only detectable bacterial DNA, culture is the ultimate test, as it proves the viability of the *Helicobacter* species in the liver samples. The inability to culture *Helicobacter* from the liver biopsy of HCC patients [11,13] suggests that the bacterial load in the liver of HCC patients is so low that it is insufficient for positive culturing. Alternatively, the positive hepatic PCR signals might represent *Helicobacter* DNA rather than true colonization of the liver. However, recently the first successful culture of a *Helicobacter* species from a cirrhotic liver from a patient with Wilson's disease has been reported [14]. This *Helicobacter* species presented the same two sequence differences in the 16S rDNA as found in our study and others (Table 2). This result strongly supports the hypothesis of colonization. The fact that all patients in our series had received antibiotics before partial liver resection might be another explanation for the inability to culture *Helicobacter* species.

In conclusion, *Helicobacter* DNA was observed at a higher frequency in the non-cirrhotic liver of patients with HCC ($P < 0.004$). The same *H. pylori* subspecies was present in the stomach of patients with HCC. This suggests that gastric *Helicobacter* colonization may play a role in the induction of HCC, either directly via colonization of the liver or indirectly, e.g. via secretion of specific toxins by *Helicobacter* residing in the stomach.

Acknowledgements

We thank Dr B. van der Hoven and Dr P. Siersema for performing gastroscopy with biopsy in the patients with HCC.

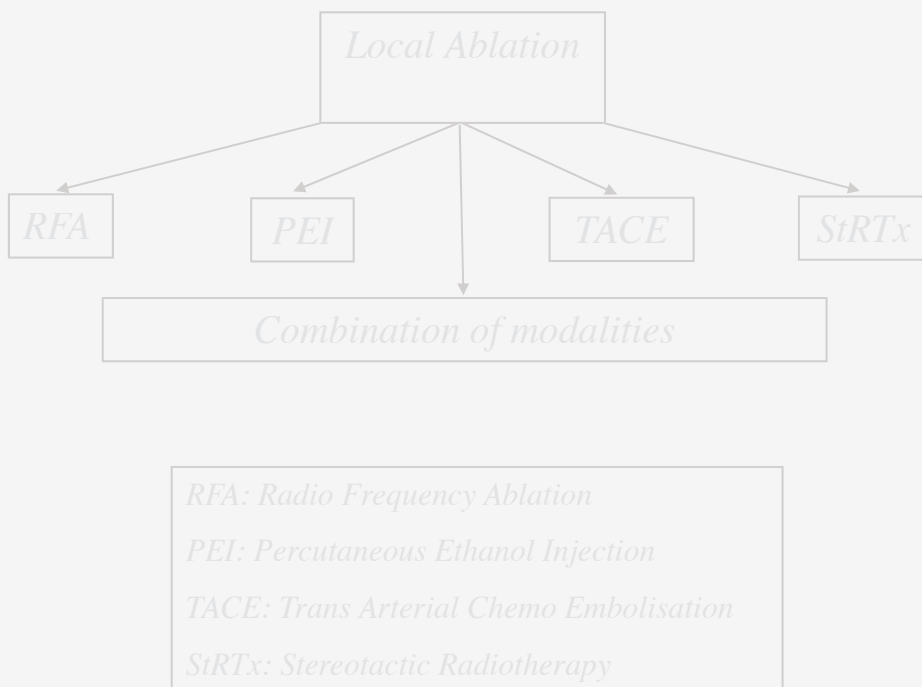
Conflict of interest None declared.

Authors' contributions

C Verhoef and RA de Man conceived the idea for this study. C Verhoef, RA de Man, JNM IJzermans, JG Kusters and EJ Kuipers developed the study. RGJ Pot performed the experimental analyses under supervision of JG Kusters. PE Zondervan provided and reviewed the samples. All authors contributed to the preparation of the manuscript.

References

1. Taylor-Robinson SD, Foster GR, Arora S, Hargreaves S, Thomas HC. Increase in primary liver cancer in the UK, 1979–94. *Lancet* 1997; 350:1142–1143.
2. Deuffic S, Poynard T, Buffat L, Valleron AJ. Trends in primary liver cancer. *Lancet* 1998; 351:214–215.
3. El-Serag HB, Mason AC. Rising incidence of hepatocellular carcinoma in the United States. *N Engl J Med* 1999; 340:745–750.
4. Nzeako UC, Goodman ZD, Ishak KG. Hepatocellular carcinoma in cirrhotic and non cirrhotic livers. A clinico-histopathologic study of 804 North American patients. *Am J Clin Pathol* 1996; 105:65–75.
5. Fox JG, Dewhirst FE, Tully JG, Paster BJ, Yan L, Taylor NS, et al. *Helicobacter hepaticus* sp. nov., a microaerophilic bacterium isolated from livers and intestinal mucosal scrapings from mice. *J Clin Microbiol* 1994; 32:1238–1245.
6. Ward JM, Fox JG, Anver MR, Haines DC, George CV, Collins MJ, Jr, et al. Chronic active hepatitis and associated liver tumours in mice caused by a persistent bacterial infection with a novel *Helicobacter* species. *J Natl Cancer Inst* 1994; 86:1222–1227.
7. Nilsson HO, Castedal M, Olsson R, Wadstrom T. Detection of *Helicobacter* in the liver of patients with chronic cholestatic liver diseases. *J Physiol Pharmacol* 1999; 50:875–882.
8. Nilsson HO, Taneera J, Castedal M, Glatz E, Olsson R, Wadstrom T. Identification of *Helicobacter pylori* and other *Helicobacter* species by PCR hybridization, and partial DNA sequencing in human liver samples from patients with primary sclerosing cholangitis or primary biliary cirrhosis. *J Clin Microbiol* 2000; 38:1072–1076.
9. Fox JG, Dewhirst FE, Shen Z, Feng Y, Taylor NS, Paster BJ, et al. Hepatobiliary *Helicobacter* spp. identified from patients with primary sclerosing cholangitis. *Gastroenterology* 1998; 114:A978.
10. Fox JG. The non-*H. pylori* helicobacters: their expanding role in gastrointestinal and systemic diseases. *Gut* 2002; 50:273–283.
11. Avenaud P, Marais A, Monteiro L, LeBail B, Bioulac Sage P, et al. Detection of *Helicobacter* species in the liver of patients with and without primary liver carcinoma. *Cancer* 2000; 89:1431–1439.
12. Ponzetto A, Pellicano R, Leone N, Cutufo MA, Turrini F, Grigionio WF, et al. *Helicobacter* infection and cirrhosis in hepatitis C virus carriage: is it an innocent bystander or a troublemaker? *Med Hypotheses* 2000; 54:275–277.
13. Nilsson HO, Mulchandani R, Tranberg KG, Wadstrom T. *Helicobacter* species identified in liver from patients with cholangiocarcinoma and hepatocellular carcinoma. *Gastroenterology* 2001; 120:323–324.
14. Magalhães Queiroz de DM, Santos A. Isolation of a *Helicobacter* strain from the human liver. *Gastroenterology* 2001; 121:1023–1024.
15. Siringo S, Vaira D, Menegatti M, Piscaglia F, Sofia S, Gaetani M, Miglioli M. High prevalence of *Helicobacter pylori* in liver cirrhosis. Relationship with clinical and endoscopic features and the risk of peptic ulcer. *Dig Dis Sci* 1997; 42:2024–2030.
16. Dore MP, Realdi G, Mura D, Graham DY, Sepulveda AR. *Helicobacter* infection in patients with HCV-related chronic hepatitis, cirrhosis and hepatocellular carcinoma. *Dig Dis Sci* 2002; 47:1638–1643.
17. Coppola N, de Stefano G, Marrocco C, Scarano F, Scolastico C, Tarantino L, et al. Absence of *Helicobacter* species in the liver of patients with primary or metastatic liver cancer. *Hepatology* 2002; 36: 1300–1301.
18. Roosendaal R, Kuipers EJ, Vandenbroucke-Grauls CMJE, Kusters JG. *Helicobacter* species are not detectable by 16S rDNA PCR in bile from Dutch patients with common bile duct stones. *Digestion* 2002; 66: 89–91.
19. Tomb JF, White O, Kerlavage AR, Clayton RA, Sutton GG, Fleischmann RD, et al. The complete genome sequence of the gastric pathogen *Helicobacter pylori*. *Nature* 1997; 388:539–547.
20. Schafer DF, Sorrell MF. Hepatocellular carcinoma. *Lancet* 1999; 353:1253–1257.
21. Realdi G, Dore MP, Fastame L. Extradigestive manifestations of *H. pylori* infection: fact or fiction? *Dig Dis Sci* 1999; 44:229–236.
22. Nedrud JG, Czinn SJ. *Helicobacter pylori*. *Curr Opin Gastroenterol* 1997; 13:71–78.



Chapter IV

Fluorine-18 FDG imaging in hepatocellular carcinoma using positron coincidence detection and single photon emission computed tomography.

Liver 2002;22:51-56

ABSTRACT

Aim: We prospectively evaluated whether fluorine-18 deoxyglucose (^{18}F FDG) positron coincidence detection (PCD) or ^{18}F FDG single-photon emission computed tomography (SPECT) provide additional benefits to our conventional preoperative evaluation of lesion detection in patients suspected for hepatocellular carcinoma (HCC).

Methods: Thirteen consecutive patients with a suspected HCC underwent conventional preoperative evaluation with ultrasonography (US), triple-phase helical computed tomography (CT), superparamagnetic iron oxides (SPIO) enhanced magnetic resonance imaging (MRI) and serum α -fetoprotein (AFP) level. All thirteen patients had an ^{18}F FDG-PCD and SPECT. These results were evaluated to assess the value of ^{18}F FDG-PCD and SPECT in addition to US, SPIO enhanced MRI and triple-phase helical CT.

Results: Ten of the thirteen (77%) patients had at least one histological confirmed HCC without extrahepatic abdominal spread. The tumours ranged in size from 1 to 8 cm and the serum AFP ranged from 3 to 30000 ug/L. Of these ten patients, two patients had an increased tumour ^{18}F -FDG uptake, (sensitivity of 20%); one patient with an AFP of 5ug/L and a tumour size of maximum 4.5 cm and one patient with an AFP of 249 ug/L and a tumour size of maximum 2 cm. In three patients with a benign liver mass, ^{18}F FDG imaging with either PCD or SPECT was negative. There was no false positive finding.

Conclusions: We found a poor sensitivity of ^{18}F FDG-PCD and ^{18}F FDG-SPECT for the detection of HCC. There were no clear relations between AFP or tumour size and FDG uptake. Therefore, we conclude that FDG imaging with PCD or SPECT has no value in the preoperative work-up for HCC in patients with cirrhosis.

INTRODUCTION

There is a growing interest in the development of in vivo methods of assessing functional parameters and metabolism in normal and diseased tissues (1,2). Positron emission tomography with fluorine-18-deoxyglucose (¹⁸FDG-PET) is one example of such a technique. PET is currently not widely available, mainly because of its high costs. Recently, alternative techniques for ¹⁸FDG imaging have become available: SPECT using special high-energy collimators (3) and coincidence detection using adapted multi-head gamma cameras (4). These techniques are less costly than PET. However, their sensitivity is lower. To which extent gamma camera coincidence imaging can be used in clinical circumstances is being investigated for many oncological and cardiological applications (5).

Hepatocellular carcinoma (HCC) is one of the most common cancers in men. Its world-wide annual incidence has been estimated to be 250.000 to 1 million (6) and more than 1 million death per year world-wide.(7) A number of imaging modalities are used to detect HCC, but radionuclide scanning techniques currently play only a minor role in the diagnosis of HCC (8,9,10,11).

In a pilot study we prospectively evaluated if ¹⁸FDG Positron Coincidence Detection (PCD) and single photon emission computed tomography (SPECT) provide additional benefit to our conventional preoperative evaluation of patients with a suspected HCC.

PATIENTS AND METHODS

We prospectively studied thirteen consecutive patients with a suspected HCC (11 men and 2 women). The patients ranged in age from 39 to 65 years (mean and median 54 year). All thirteen patients were seen in the outpatient clinic and had a

Table 1. Summary of the results

Pt.	Hist./size	Cirrhosis	AFP	FDG-PCD	SPECT	CT	MRI	US	Therapy
1	HCC/2 cm	HCV	47	2	—	3	3	3	OLT
2	HCC/4.5 cm	HCV	5	3	3	3	3	1	Laser/ethanol
3	HCC/2.5 cm	AT def	10	1	0	0	3	0	OLT
4	HCC/8 cm	HBV	3	1	1	2	3	2	Right hemihepatectomy
5	HCC/1 cm	HBV	400	0	0	0	3	0	Excision biopsy channel
6	Hemangioma/3 cm	HCV	18	1	1	2	2	2	Observation
7	HCC/1.8 cm	HBV	2060	0	0	3	3	2	OLT
8	HCC/5 cm	HCV	69	1	1	3	2	2	Ethanol
9	Focal lesion/1 cm	HBV	16	1	1	0	1	1	Observation
10	HCC/2 cm	HBV	30000	1	1	2	2	2	Segment resection
11	Hemangioma/5 cm	HCV	41	1	1	2	2	2	Observation
12	HCC/2 cm	HBV	249	3	3	3	3	3	Palliative
13	HCC/8 cm	No cirr.	609	0	0	3	3	3	Palliative

OLT: Orthotopic liver transplantation, AT def: α -¹ antitrypsin deficiency, HBV: hepatitis B virus, HCV: hepatitis C virus, No cirr: no cirrhosis, cm: centimeter, AFP: serum α -fetoprotein. Imaging modalities scored as follows: Grade 0 — no lesion, Grade 1 — equivocal, Grade 2 — lesion, but uncertain diagnosis, Grade 3 — HCC (almost) certain.

Table 2. Publications which formulated the value of static ^{18}F FDG imaging in patients with HCC concerning detection

Ref	Author and year of publication	No. of patients	Sensitivity	Aspect of study
30	Delbeke et al. 1998	23	70%	Prospective
33	Rose et al. 1998	23	57%	Retrospective
32	Trojan et al. 1999	14	50%	Prospective
31	Khan et al. 2000	20	55%	Retrospective
	Present series	10	20%	Prospective

REF: reference.

conventional preoperative evaluation with ultrasonography (US), triple phase helical CT, SPIO enhanced MRI and serum α -fetoprotein (AFP). Finally, in all patients we had histology of the suspected lesion to confirm the diagnosis. Twelve patients had liver cirrhosis. The aetiology of the underlying liver disease was chronic hepatitis B virus (HBV) infection in six patients, chronic hepatitis C virus (HCV) infection in five patients and α -1 antitrypsine deficiency in one patient (Table 1).

After the patients had their conventional preoperative evaluation, all patients had an ^{18}F FDG-PCD directly followed by SPECT. A single observer (RV) reviewed the images, being unaware of the results of the conventional investigations. The reading was based on visual interpretation. After the reading of the ^{18}F FDG-PCD and SPECT studies, the results were compared with the conventional preoperative evaluation and the histology of the resected specimen or ultrasound-guided needle liver biopsy. FDG, CT, MRI and US were scored as follows: Grade 0 – no lesion, Grade 1 – equivocal, Grade 2 – lesion, but uncertain diagnosis, Grade 3 – HCC (almost) certain. The whole work-up was done within 3 months. Surgery, if necessary and possible, was done within 4 weeks for partial liver resection and not more than 4 months for orthotopic liver transplantation (OLT).

^{18}F FDG PCD

The patients fasted overnight, for at least 12 hours. Coincidence imaging of the abdominal region only was started 45 min. after i.v. injection of 185 MBq (5mCi) ^{18}F -FDG (Prism 2000 XP, Marconi, Cleveland, OH). Before injection a normal blood glucose level was found in all patients. The acquisition was performed using axial filters, in list mode, with 60 steps over 360° , nominal 30 sec. per step. Decay correction was employed, yielding longer acquisition times for later steps; the total acquisition time was 37 min. The raw acquisition data were rebinned to 180 views, in 128×128 matrices, using only photo peak pairs. An initial iterative reconstruction with an ordered subset estimation maximization (OSEM) algorithm defined the outer contours of the patient. These were used for calculating the attenuation correction during the final reconstruction, assuming homogeneous attenuation by tissues inside the body. The final reconstruction was done by a maximum likelihood estimation maximization algorithm (ML-EM) with 20 iterations, followed by filtering using a 3D-Wiener filter and reorientation in transverse, coronal and sagittal slices.

DUAL-ISOTOPE SPECT

After completion of PCD imaging, the patients received an injection of 80 MBq ^{99m}Tc-colloid. Ten min. later dual-isotope SPECT was performed with a triple-head camera fitted with ultra-high energy collimators (Prism 3000 XP, Marconi, Cleveland, OH). Acquisition was done in separate 511 keV (¹⁸F) and 140 keV (^{99m}Tc) channels in 120 views over 360 degrees using 64x64 matrices. The iterative reconstruction was done by an ML-EM algorithm with 20 iterations, followed by attenuation correction and filtering with a low-pass filter.

Reorientation in transverse, coronal and sagittal slices was done simultaneously for the ¹⁸F-FDG images and corresponding ^{99m}Tc-colloid images to enable exact comparison.

RESULTS

The results are summarised in table 1. Of the thirteen patients enrolled in this study, ten patients had a HCC, two patients had a hemangioma and one patient had a

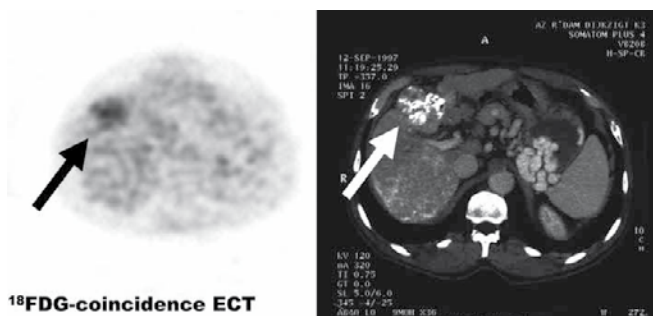


Fig. 1. FDG coincidence ECT image (transverse) of a patient with HCC (Left), with corresponding contrast-enhanced CT image (Right). The tumor is indicated by arrows.

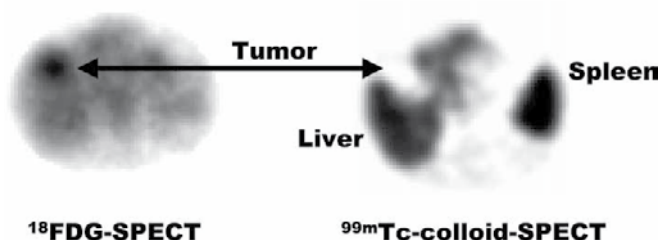


Fig. 2. FDG and ^{99m}Tc-colloid dual-isotope SPECT images of the same patient as depicted in Fig. 1. The simultaneous acquisition and processing allows exact comparison. Note the cold defect in the liver with ^{99m}Tc-colloid corresponding to the hot tumor with ¹⁸FDG. The SPECT image has inferior sharpness and contrast compared with the coincidence ECT image (Fig. 1).

regenerating nodule. In two of the ten patients with HCC, FDG with either PCD or SPECT was positive (20%); Patient 2 with an AFP of 5ug/l and a tumour size of maximum 4.5 cm (see Figure 1 and 2) and Patient 13 with an AFP of 249 ug/l and a tumour size of maximum 2 cm. In three patients without a HCC, FDG with either PCD or SPECT was negative. This results in a sensitivity of 20%. Histological examination in all ten patients, six surgical resection specimen and four core biopsies, confirmed the diagnosis of HCC. The tumours ranged in size from 1 to 8 cm with a mean diameter of 3.6 cm (median 2 cm). Of the resected specimen, grading of HCC was performed; five were moderately differentiated and one was well differentiated. The serum AFP levels of the patients with a HCC ranged from 3 to 30.000 ug/L. with a mean serum value of 3345 ug/l (median of 159 ug/L.). Of the three patients without a HCC, two patients had hemangiomas, histologically confirmed after ultrasound-guided needle liver biopsy. In all three patients without a HCC, we performed an ultrasound and SPIO enhanced MRI of the liver after one year follow-up. Again no tumour was detected, thus confirming the benign diagnosis.

DISCUSSION

Hepatocellular carcinoma is the most common primary hepatic malignancy and one of the most common tumours world-wide with an incidence of 1 to 5 cases per 100.000 citizens per year in Western Europe and North America (8). In Western Europe, liver cirrhosis is present up to 90% of the patients with HCC (12,13). Cirrhosis is a process of liver fibrosis that is characterised by architectural distortion and the development of nodules ranging from regenerative nodules to hepatocellular carcinoma (14). That makes it difficult for ultrasonography and a variety of other imaging procedures as CT and MRI, to detect HCC in a cirrhotic liver (15).

Warburg and Conti (16) and many others (17,18,19) demonstrated that aerobic glycolysis was increased in malignant tumours. Experimental studies demonstrate that glycogenesis decreases and glycolysis increases during carcinogenesis in the liver. (20,21) FDG, an analogue of glucose, enters the cell and is phosphorylated by hexokinase. Because of the relatively low level of glucose-6-phosphatase in most malignant cells, FDG-6-phosphate is trapped in the tumour tissue and leading to intracellular accumulation. The liver, and also muscle, intestine and kidneys, are known to have increased activity of glucose-6-phosphatase.(22,23) This may result in increased accumulations of FDG in HCC compared to normal liver tissue, as confirmed by others. (2,24-37) PET using ^{18}F FDG is the most sensitive technique for imaging and quantification of glucose metabolism. Established and reimbursed oncological applications for ^{18}F FDG-PET are well known.(38) Due to the high costs of PET it is not widely available, and alternative less expensive techniques for ^{18}F FDG imaging were developed. An alternative to dedicated PET is coincidence imaging using an adapted hybrid

gamma camera, where the opposite camera heads and special electronics are used to detect coincident photon pairs. The price of such cameras is typically less than one million dollar, while a dedicated PET camera may cost more than two million dollars. Gamma camera based coincidence detection has the same spatial resolution as PET, but the sensitivity is lower.(4) Therefore, small lesions < 1.5cm in diameter cannot be reliably detected with these systems, while lesions smaller than 1cm may be detected by PET. Nevertheless, due to the lower costs hybrid coincidence gamma cameras are becoming widespread.(5)

A relatively simple approach is SPECT using a normal gamma camera fitted with special high-energy collimators.(3) An unique advantage of SPECT is the ability to image in separate energy windows simultaneously, thus enabling the dual-isotope imaging of ¹⁸F FDG and ^{99m}Tc-colloid. A cold spot on the ^{99m}Tc-colloid image should coincide with a hot spot on the corresponding ¹⁸F FDG image, thus theoretically enhancing the diagnostic accuracy.

¹⁸F FDG-PCD imaging is an established oncological application in head and neck tumours (5) and SPECT is of additional value in the detection of cervical lymph node metastases of nasopharyngeal carcinomas (39), mediastinal lymph node metastases of non-small cell lung cancer (40) and oesophageal carcinoma (41). We evaluated the additional benefit of ¹⁸F FDG-PCD and dual-isotope SPECT imaging in patients suspected for HCC. To our knowledge, this has never been done before. Therefore we compare our results with studies using dedicated PET. We have used static imaging. Torizuka et al. (24) and Okazumi et al (25) proved the advantage of dynamic imaging in characterisation of tumour and assessment of effect of treatment. However, this dynamic imaging is not feasible with our PCD system in a routine clinical setting. In an other study of Torizuka et al. (29), all patients with a HCC have had intervention therapy and after this 19 of the 30 patients had an increased FDG uptake, sensitivity of 63%, using static FDG imaging.

Only one prospective study is performed, Trojan et al (32), to evaluate the value of static FDG imaging in patients with a histologically confirmed HCC for detection of the lesion. Trojan et al used static ¹⁸F FDG-PET in 14 consecutive patients with HCC. The results were compared with US, CT, histological grading, p53 protein expression and AFP. Fifty percent of the patients had an increased tumour ¹⁸F FDG uptake. In three patients extrahepatic spread was demonstrated by ¹⁸F FDG PET. This study also demonstrated that ¹⁸F FDG imaging was high sensitive for moderately or poorly differentiated HCC (7 of 8) and tumours > 5cm (5 of 5). Also patients with a markedly elevated AFP levels had a higher sensitivity. These results differ clearly with ours. We had a sensitivity of 20% (versus 50%) and there was no clear relation between AFP, tumour size or histologic grading. We had two patients (pts.4 and 13) with a size of 8 cm HCC (one of them moderately differentiated), but there was no increased tumour ¹⁸F FDG uptake. Neither had one of the patients (pts.5,7,10,13) with a markedly raised serum AFP (≥ 400 ug/l.). One of the differences between both studies

was that we had HCC positive and negative patients. Another explanation might be the difference in imaging technique, the use of PCD and SPECT in our study versus PET in other studies. It is known that coincidence detection with an adapted gamma camera has a lower sensitivity than PET. However, lesions that are larger than 1.5 cm in diameter should be visible with PCD, provided that they have significantly higher ^{18}F FDG accumulation than the surrounding tissue. Therefore, another explanation of the low sensitivity in our study could be the high percentage of inhomogeneous background activity in cirrhotic livers, in our group 90% (9/10) of the patients with a HCC had a cirrhotic liver. When we compared the sensitivity with retrospective study results, we found two retrospective studies who also used static ^{18}F FDG-PET in detecting HCC where the sensitivity was 57% (Rose et al.(33)) and 55%.(Khan et al.31)). In the study of Rose et al, ^{18}F FDG-PET was used selectively to determine the presence of extrahepatic disease in patients being considered for surgery, transplantation or hepatic regional therapy. One prospective study from Delbeke et al. (30) showed the value of PET scan using static imaging on benign versus malignant hepatic lesions. They concluded that PET technique using FDG imaging was useful to differentiate malignant from benign lesions in the liver. In their study there were 23 patients with HCC, 16 patients had increased uptake values, a sensitivity of 70%. In this publication they described a sensitivity of 100% for livermetastases from adenocarcinoma and sarcoma primaries in 66 patients and cholangiocarcinomas in 8 patients. All benign hepatic lesions (n=23) had poor FDG uptake, except for 1 of 3 abscesses that had definite uptake. All three patients with no malignancy in our study had a negative FDG imaging but there were eight false negative ^{18}F FDG-PCD scans. The results of the 4 studies concerning static FDG imaging and HCC is summarised in table 2. Table 1 shows us that MRI was the most sensitive imaging method to detect HCC or a benign lesion in our study. CT scanning missed two HCC (2.5cm and 1cm) and one regenerating nodule compared to the SPIO-enhanced MRI. This is in conformity with the literature where contrast-enhanced MR imaging is superior to CT for detecting and differentiating focal lesions in a cirrhotic liver.(42,43,44,45) Promising is the use of contrast enhanced ultrasonography (46) but the data in the literature are too scarce to draw any definite conclusions.

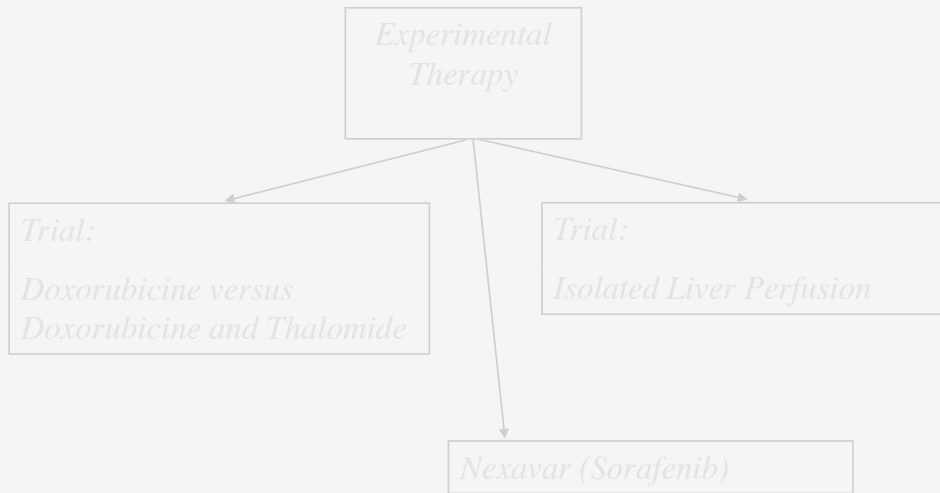
Conclusions

In this prospective study of 13 patients with or without a HCC, we evaluated if ^{18}F -FDG-PCD or SPECT provides an additional benefit in a preoperative evaluation. We found a poor sensitivity of FDG PCD and SPECT for the detection of HCC. There were no clear relations between AFP or tumour size and FDG uptake. We must conclude that FDG imaging with PCD has no value in the pre-operative work-up of patients suspected of hepatocellular carcinoma

References

1. Wagner HN Jr, Conti PS. Advances in medical imaging for cancer diagnosis and treatment. *Cancer* 1991;67:1121-28.
2. Srauss LG, Conti PS. The applications of PET in clinical oncology. *J Nucl Med* 1991;32:623-48.
3. Van Lingen A, Huijgens PC, Visser FC, et al. Performance characteristics of a 511-keV collimator for imaging positron emitters with a standard gamma-camera. *Eur J Nucl Med* 1992; 19: 315-21.
4. Patton JA. Instrumentation for coincidence imaging with multihead scintillation cameras. *Semin Nucl Med* 2000; 30: 239-54.
5. Ak I, Blokland JAK, Pauwels EKJ et al. The clinical value of ^{18}F -FDG detection with a dual-head coincidence camera: a review. *Eur J Nucl Med* 2001 28:763-778.
6. Simonetti RG, Camma C, Fiorello F et al. Hepatocellular carcinoma. A worldwide problem and the major risk factors. *Dig Dis Sci* 1991;36:962-72.
7. Rutsgi VK. Epidemiology of hepatocellular carcinoma. *Ann Int Med* 1988;108:390-1.
8. Ramsey WH, Wu GY. Hepatocellular carcinoma: Update on diagnosis and treatment. *Dig Dis* 1995;13:81-91.
9. Bennet WE, Bova JG. Review of hepatic imaging and a problem-oriented approach to liver masses. *Hepatology* 1990;12:761-75.
10. Savci G. The changing role of radiology in imaging liver tumors:an overview. *Eur J Rad* 1999;32:36-51.
11. Ijzermans JN, Bac DJ. Recent developments in screening, diagnosis and surgical treatment of hepatocellular carcinoma. *Scand J Gastroenterol Suppl* 1997;223:50-4.
12. Di Bisceglie AM. Hepatitis C and hepatocellular carcinoma. *Hepatology* 1997;26(suppl 1):34-8.
13. Haydon GH, Hayes PC. Screening for hepatocellular carcinoma. *Eur J Gastroenterol Hepatol* 1996;8:856-60.
14. Brown JJ, Naylor MJ, Yagan N. Imaging of hepatic cirrhosis. *Radiology* 1997;202:1-16.
15. Fernandez MDP, Redvanly RD. Primary hepatic malignant neoplasms. *Radiol Clin North Am* 1998;36:333-48.
16. Warburg O, Wind F, Negelein E. On the metabolism of tumors in the body. In: Warbutg O, ed. *The metabolism of tumors*. London:Constable;1930:254-70.
17. Flier JS, Mueckler MM, Usher P, et al. Elevated levels of glucose transport and transporter messenger RNA are induced by ras or src oncogenes. *Science* 1987;235:1492-5.
18. Monakhov NK, Neistadt EL, Shavlovski MM, et al. Physiochemical properties and isoenzyme composition of hexokinase from normal and malignant human tissues. *J Natl Cancer Inst* 1978;61:27-34.
19. Knox WE, Jamdar SC, Davis PA, et al. Hexokinase, differentiation, and growth rates of transplanted tumors. *Cancer Res* 1970;30:2240-4.
20. Weber G, Cantero A. Glucose-6-phosphatase activity in normal, precancerous, and neoplastic tissues. *Cancer Res* 1955;15:105-8.
21. Weber G, Morris HP. Comparative biochemistry of hepatomas. *Carbohydrate enzymes in liver tumors of different growth rates*. *Cancer Res* 1963;23:987-94.
22. Gallagher BM, Fowler JS, Gutterson NI, et al. Metabolic trapping as a principle of radiopharmaceutical design:some factors responsible for biodistribution of ^{18}F 2-deoxy-2-fluoro-D-glucose. *J Nucl Med* 1978;19:1154-61.
23. Knox WE. Enzyme patterns in fetal, adult, and neoplastic rat tissues. *Basel:S.Karger*;1976:269-309.
24. Torizuka T, Tamaki N, Inokuma T et al. In vivo assessment of glucose metabolism in hepatocellular carcinoma with FDG-PET. *J Nucl Med* 1995;36:1811-7.
25. Okazumi S, Isono K, Enomoto K et al. Evaluation of liver tumors using fluorine-18-fluorodeoxyglucose PET: Characterization of tumor and assessment of effect of treatment. *J Nucl Med* 1992;33:333-9.
26. Fukuda H, Yoshioka S, Takahashi J et al. A case of hepatocellular carcinoma with lumbar bone metastasis with high uptake of ^{18}F -fluorodeoxy galactose in PET. *Kaku Igaku* 1994;31:1351-5.
27. Goldberg MA, Lee MJ, Fischman AJ et al. Fluorodeoxyglucose PET of abdominal and pelvic neoplasms: potential role in oncologic imaging. *Radiographics* 1993;13:1047-62.
28. Smith FW, Heys SD, Evans NT et al. Pattern of 2-deoxy- ^{18}F -fluoro-D-glucose accumulation in liver tumours: primary, metastatic and after chemotherapy. *Nucl Med Commun* 1992;13:193-5.

29. Torizuka T, Tamaki N, Inokuma T et al. Value of Fluorine-18-FDG-PET to monitor hepatocellular carcinoma after interventional therapy. *J Nucl Med* 1994;35:1965-9.
30. Delbeke D, Martin WH, Sandler MP et al. Evaluation of benign vs malignant hepatic lesions with positron emission tomography. *Arch Surg* 1998;133:510-16.
31. Khan MA, Combs CS, Brunt EM et al. Positron emission tomography scanning in the evaluation of hepatocellular carcinoma. *J Hepatol* 2000;32:792-7.
32. Trojan J, Schroeder O, Raedle J, et al. Fluorine-18 FDG positron emission tomography for imaging of hepatocellular carcinoma. *Am J Gastroenterol* 1999;94:3314-9.
33. Rose AT, Rose DM, Pinson CW et al. Hepatocellular carcinoma outcomes based on indicated treatment strategy. *Am Surg* 1998;64:1128-34.
34. Schroder O, Trojan J, Zeuzem S, et al. Limited value of fluorine-18-fluorodeoxyglucose PET for the differential diagnosis of focal liver lesions in patients with chronic hepatitis C virus infection. *Nuklearmedizin*. 1998;37:279-85.
35. Shiomi S, Sasaki N, Kawashima D et al. Combined hepatocellular carcinoma and cholangiocarcinoma with high F-18 fluorodeoxyglucose positron emission tomographic uptake. *Clin Nucl Med* 1999 May;24(5):370-1.
36. Rigo P, Paulus P, Kaschten BJ, et al. Oncological applications of positron emission tomography with fluorine-18-fluorodeoxyglucose. *Eur J Nucl Med* 1996;23:1641-74.
37. Iwata Y, Shiomi S, Sasaki N, et al. Clinical usefulness of positron emission tomography with fluorine-18-fluorodeoxyglucose in the diagnosis of liver tumors. *Ann Nucl Med* 2000;14(2):121-26.
38. Health Care Financing Administration. Medicare Coverages Issues Manual, Transmittal 136. 2001: Section 50-36.
39. Shiau YC, Tsai SC, Wang JJ et al. Detection of cervical lymph node metastases of nasopharyngeal carcinomas with technetium-99m tetrofosmin single photon emission computed tomography and comparison with computed tomography. *Anticancer Res* 2001;21:723-26.
40. Shiau YC, Hsieh JF, Tsai SC et al. Technetium-99m methoxy-isobutyl-isonitrile chest single photon emission computed tomography to detect mediastinal lymph node metastases in patients with non-small cell lung cancer: comparison with computed tomography. *Anticancer Res* 2000;20:3751-54.
41. Sun SS, Hsieh JF, Tsai SC et al. Detection of esophageal carcinoma using single photon emission computed tomography with technetium-99m tetrofosmin. *Anticancer Res* 2000;29:3641-45.
42. Sharma R, Saini S. Role and limitations of magnetic resonance imaging in the diagnostic work-up of patients with liver cancer. *J Comput Assist Tomogr* 1999;23(Suppl1):S39-S44.
43. Hahn PF, Saini S. Liver-specific MR imaging contrast agents. *Radiol Clin North Am* 1998;36:287-98.
44. Mergo PJ, Ros PR. Imaging of diffuse liverdisease. *Radiol Clin North Am* 1998;36(2):365-75.
45. Rode A, Bancel B, Douek P et al. Small nodule detection in cirrhotic livers: evaluation with US, spiral CT, and MRI and correlation with pathologic examination of explanted liver. *J Comput Assist Tomogr* 2001;25(3):327-336.
46. Choi D, Lim HK, Kim SH et al. Hepatocellular carcinoma treated with percutaneous radio-frequency ablation: usefulness of power Doppler US with a microbubble contrast agent in evaluating therapeutic response-preliminary results. *Radiology* 2000;217(2):558-563.



Chapter V

Cell biological evaluation of liver cell carcinoma, dysplasia and adenoma by tissue micro-array analysis.

Acta Histochem 2005;107(3):161-71

ABSTRACT

The clinical and morphological definition of hepatocellular carcinoma (HCC), dysplasia and adenoma suffers from a lack of biological understanding. This is especially important in the histomorphological diagnosis of nodular liver lesions in needle biopsies. Therefore, we constructed a liver tissue micro-array (TMA) and evaluated 48 HCC's, 46 dysplasias, 8 adenomas, 20 cirrhotic specimens and 28 normal liver samples derived from 68 patients. Protein (over)expression of tumor suppressor genes p16, p53 and Rb1 was assessed by immunohistochemistry, the proliferative capacity was examined by immunostaining of Ki67. Further, DNA ploidy status (hyperdiploidy) was measured by fluorescent in situ hybridization (FISH) with a chromosome 1-specific repetitive DNA probe. An abnormal chromosome 1 number, i.e. the percentage of hyperdiploid cells, was 11.0, 13.7, 16.1, 23.7 and 31.3 for normal liver samples, adenomas, cirrhosis, dysplasias and HCC's, respectively. A significant difference was found for HCC versus cirrhosis ($P=0.024$) or adenoma ($P=0.033$), a trend was seen for dysplasia versus cirrhosis ($P=0.094$). Immunohistochemical protein expression of p53 and Rb1, as well as Ki67 defined proliferation, was clearly higher in HCC than in cirrhosis or dysplasia (all $P<0.001$). Proliferation was also higher in HCC than in adenoma ($P=0.025$), whereas a trend was observed for Rb1 overexpression ($P=0.063$). These data suggest that in the liver cell dysplasia-carcinoma pathway changes in ploidy are followed by increased proliferation and cell biological perturbations involving p53 and Rb1. Adenomas can be distinguished from carcinomas, but not from dysplasias, based on ploidy and proliferation characteristics.

INTRODUCTION

The global distribution of hepatocellular carcinoma (HCC) shows a high incidence in China, south-east Asia and Africa south of the Sahara, an intermediate incidence in southern Mediterranean countries, and a low incidence in north-western Europe, Australia and the USA (Bruix et al., 2004). Chronic (viral) liver disease ending in cirrhosis is an important contributing factor (Bruix et al., 2004; Feitelson et al., 2002). Over the past decade it became clear, that precursors of HCC can be found in the liver (Borzio et al., 1994; Mion et al., 1996; Riegler JL, 1996). Confusion is still existing about the exact definition of these lesions. We will use the definitions of the Working Party on Nodular Lesions in the Liver (1995). These aberrations can be found in non-cirrhotic and cirrhotic livers, both with and without HCC. The diagnosis of nodular liver lesions is generally made by histopathology of needle biopsies. However, a correct classification of adenoma, liver cell dysplasia and (well differentiated) HCC is often difficult (Scheuer and Lefkowitz, 2000). Immunohistochemical methods might help in defining parameters that aid in the histomorphological diagnosis of nodular liver lesions.

The genetics of liver cancer have been the subject of many studies (reviewed in: Feitelson et al., 2002; Van Dekken et al., 2003). However, little is known of genetic aberrations in preneoplastic liver lesions. Wong et al. (1999) used comparative genomic hybridization (CGH) to analyse 3 HBV-related "adenomatous hyperplasias" (cirrhotic/dysplastic nodules), and detected gains of 1q and chromosome 20 in one. Wilkens et al. (2001) distinguished liver cell adenomas from HCC by CGH: all HCCs showed multiple alterations, whereas only 2 (out of 10) adenomas displayed few genomic changes. Likewise, no loss of heterozygosity (LOH) was detected in 6 adenomas (Ding et al., 1993). In a CGH study by Zondervan et al. (2000) dysplasias adjacent to HCC showed frequent losses on 4q, 16q and 17p, frequent gain was discriminated on 17q. Polysomies of chromosomes 1, 7, 17 and 18 were found by in situ hybridization technology in large and small cell dysplasias (Terris et al., 1997).

Likewise, there is ample data concerning genes involved in HCC, but the literature is sparse with respect to such investigations in liver cell dysplasia or cirrhosis. Loss of chromosome 17p, including the p53 gene locus, had already been described by classical karyotyping (Parada et al., 1998). Allelotyping investigations have revealed frequent LOH of 9p, 13q, and 17p implicating the involvement of p16, Rb1 and p53 genes, respectively (Biden et al., 1997; Nagai et al., 1997; Okabe et al., 2000). Recurrent loss of these chromosomal regions on 9p, 13q and 17p was also discriminated by CGH (Marchio et al., 1997; Kusano et al., 1999; Zimonjic et al., 1999; Zondervan et al., 2000). A diffuse and strong immunolabeling with Ki67 of HCC was reported by Wu et al. (1999). In this study p53 protein overexpression was seen in approx. 50% of carcinoma cells. In another report p53-positive HCC's showed a significantly higher Ki67 score, although the p53 labeling index was relatively low (D'Errico et al.,

1994). P53 staining patterns were found to be negative in liver cell dysplasia of large type, but positive in a small proportion of small cell dysplasia (Zhao et al., 1994). Cohen and DeRose (1994) discerned p53 positivity in half of the liver cancers, but in only one of thirty dysplasias in HBV patients. Mutant p53 protein expression was described absent in adenoma, focal nodular hyperplasia and cirrhosis, but it increased in the successive pathological grades of HCC (Ojanguren et al., 1995). Likewise, Ki67 was found to be low or absent in normal and cirrhotic tissues, but high in carcinomas (Grigioni et al., 1989). Immunohistochemistry data of p16 and Rb1 are essentially missing in the literature, although p16 alterations, including hypermethylation and deletion, were detected in 60% of HCC's (Jin et al., 2000). Further, a significant correlation between loss of Rb1 expression and Rb1 methylation was recently reported (Edamoto et al., 2003).

We created a liver tissue micro-array comprising a large series of nodular liver lesions. Cell biological markers, i.e. Ki67, p16, p53, Rb1 and ploidy were investigated by means of immunohistochemistry and in situ hybridization in order to address the following questions: 1] Is it possible to refine the morphological criteria of nodular liver cell lesions during malignant progression from cirrhosis to carcinoma?, and 2] Is it possible to better discriminate liver cell adenomas from other nodular aberrations, i.e. carcinomas and liver cell dysplasias?

MATERIALS AND METHODS

Patient materials

We collected representative paraffin blocks from neoplastic and non-neoplastic liver cell specimens. These tissues were selected based on the criteria of the International Working Party on the "Terminology of nodular hepatocellular lesions" (1995):

1] Hepatocellular adenoma; a benign neoplasm composed of hepatocytes occurring in a liver that is otherwise histologically normal or nearly normal. 2] Dysplastic focus or nodule; a cluster or nodule of hepatocytes with dysplasia but without histologic criteria of malignancy. 3] Hepatocellular carcinoma (HCC); a malignant neoplasm composed of cells with hepatocellular differentiation. HCC's were graded using a standard grading system (Edmondson and Steiner, 1954). Staging was not included in our analysis, since different surgical procedures were applied.

The tissue micro-array (TMA) was constructed as described by Kononen et al. (1998). Samples from surgical resections of 68 patients (26 complete resections, 42 hemihepatectomies) were selected for the TMA including 58 HCC's, 2 dysplastic nodules (in cirrhosis without HCC) and 8 adenomas, plus adjacent dysplastic, cirrhotic and normal liver specimens. Of each patient 6 cylindric tissue cores were included in the TMA, e.g. 2 carcinoma, 2 dysplasia and 2 cirrhosis tissue cores, or, 3 carcinoma and 3 normal cores. A total of 150 liver tissue samples were available for analysis,

i.e. 48 HCC's, 8 adenomas, 46 dysplasias, 20 cirrhotic specimens and 28 normal liver tissues cores. In addition, 4 tissue cores each of liver parenchyma derived from 10 hemihepatectomies with metastases of colon carcinoma were included as normal liver controls.

Fluorescent in situ hybridization

FISH was performed on a 4- μ m-thick tissue section of the TMA that was adhered to a aminoacetylsilane (AAS) coated slide (Starfrost, Berlin, Germany). The (peri) centromeric DNA probe for chromosome 1 was labeled with Spectrum Green using a Nick Translation Reagent Kit (Vysis, Downers Grove IL, USA) according to the manufacturer's directions. The FISH procedure was carried out basically as described before by us (Alers and Van Dekken; Van Dekken et al., 2003). Briefly, after appropriate pepsin digestion, the section was heat-denatured for 2 min in 70% formamide in 2x SSC, and hybridized overnight at 37°C with the denatured probe in a hybridization mixture containing 2 ng/ μ l DNA probe, 500 ng/ μ l herring sperm DNA (Sigma, St. Louis MO, USA), 0.1% Tween-20, 10% dextran sulphate, and 60% formamide in 2x SSC at pH 7.0. Then, a series of stringent washes followed to remove unbound probe, and the cells were counterstained with DAPI in antifade solution (Vectashield; Vector, Burlingame CA, USA). Two investigators scored a minimum of 50 interphase liver cell nuclei per tissue core for the centromere 1 probe on a computer screen. Images of each of the 2 fluorochromes were collected using an epifluorescence microscope (Leica DM, Rijswijk, The Netherlands) equipped with appropriate excitation and emission filter sets (Leica), and a cooled CCD camera (Photometrics, Tucson AZ, USA). The green and blue images were collected sequentially by changing the excitation filter using Smartcapture software (Vysis). The number of green fluorescent centromere 1 spots per nucleus was scored (0, 1, 2, 3, 4, >4 spots/nuclear slice), and the percentage of hyperdiploid cell nuclei was determined for further comparisons between tissue groups.

Immunohistochemistry

4 μ m thick consecutive tissue sections of the TMA were mounted on aminoacetylsilane (AAS) coated slides (Starfrost, Berlin, Germany), and immunostaining was performed using the UltraVision Large Volume Detection System Anti-Polyvalent, HRP (Labvision, Fremont, CA). After deparaffinization microwave (700 W) pretreatment was performed for 15 minutes using citrate buffer (10mM citric acid monohydrate, pH 6.0). The following antibodies, diluted in phosphate-buffered saline/5% BSA, were used: p16 gene product, E6H4 (DAKO, Glostrup, Denmark; diluted 1/25); p53 protein, DO-7 (DAKO; diluted 1/100); retinoblastoma gene product, Rb1 (DAKO; diluted 1/25); Ki67 antigen, Mib-1 (Immunotech, Marseille, France; diluted 1/100). As a positive control a cytokeratin 8/18 antibody was used, as a negative control the primary antibody was omitted. Moderate or intense brown nuclear staining was

considered positive for p53, Rb1 or Ki67, whereas nuclear and/or cytoplasmic staining was evaluated for p16. Ten liver resection specimens from patients with colon cancer metastases, present on the TMA, served as normal liver controls. No positively stained hepatocytes were observed for p16, p53 and Rb1 in these normal control cells (600-800 cells counted, i.e. 3-4 tissue cores), Ki67 revealed an occasional positive hepatocyte nucleus (mean 0.001, range 0-0.005). Subsequently, a cut-off value of 1% was chosen. For practical reasons this cut-off value was used for all immunostains. At least 50 cells were scored per tissue core by two independent investigators. Ki67: A percentage >1% positive cell nuclei was regarded as increased proliferation; 2-10% moderately (+), and >10% strongly (++) increased. For p16, p53 and Rb1 an identical scoring system was used: A percentage exceeding 1% of positive cells was regarded as protein overexpression of these tumor suppressor genes; 2-20% moderate (+), and >20% strong (++) overexpression. The + and ++ categories were arbitrarily determined after a pre-screen of the TMA.

Table 1. Clinical and experimental data

Patient	Tumor	Sex	Age ¹	Virus	Grade ²	FISH (C#1) ³	Ki67 ⁴	p16 ⁵	p53 ⁵	Rb1 ⁵
1	Adenoma	m	37				-	-	+	-
2	Adenoma	f	21			6	++	-	-	+
3	Adenoma	f	30			8	-	-	-	-
3	Normal					8	-	-	-	-
4	Adenoma	f	31			26	-	-	-	-
4	Normal						-	-	-	-
5	Adenoma	f	32			2	-	-	-	-
5	Normal					6	-	-	-	-
6	Adenoma	f	15			28	-	-	+	-
6	Normal						-	-	-	-
7	Adenoma	f	21				-	-	-	-
7	Normal						-	-	-	-
8	Adenoma	f	32			12	-	-	-	-
8	Normal					11	-	-	-	-
9	Carcinoma	m	59	HBV/HCV	1	22	+	-	-	+
9	Dysplasia						-	-	-	-
9	Cirrhosis					18	-	-	-	-
10	Carcinoma	m	66	non-viral	3	40	+	-	+	-
10	Dysplasia					14	-	-	-	-
10	Cirrhosis					8	-	-	-	-
11	Carcinoma	m	64	non-viral	2	50	+	-	++	-
11	Dysplasia						-	+	-	-
11	Cirrhosis						-	+	-	-

Patient	Tumor	Sex	Age ¹	Virus	Grade ²	FISH (C#1) ³	Ki67 ⁴	p16 ⁵	p53 ⁵	Rb1 ⁵
12	Carcinoma	m	74	non-viral	3		++	-	+	-
12	Dysplasia						-	-	+	-
12	Normal						-	-	+	-
13	Carcinoma	m	59	HBV	2	8	-	-	-	-
13	Dysplasia						-	-	-	-
13	Cirrhosis						-	-	-	-
14	Carcinoma	m	68	HCV	3		-	-	-	-
14	Dysplasia					11	+	-	-	-
15	Carcinoma	m	45	HCV	2	40	+	-	-	+
15	Dysplasia						-	-	-	-
15	Normal						-	-	-	-
16	Carcinoma	f	70	HCV	2	64		-	-	+
16	Cirrhosis					8		-	-	+
17	Carcinoma	f	52	HBV	2	24	+	-	-	+
17	Dysplasia					18	+	+	-	-
17	Normal					18	+	+	-	-
18	Carcinoma	m	63	non-viral	4	42	+	-	+	-
18	Dysplasia					12	-	+	-	-
18	Cirrhosis					12	-	-	-	-
19	Carcinoma	f	61	non-viral	2	56	+	-	-	+
19	Dysplasia						-	-	-	-
19	Normal					8	-	-	-	-
20	Carcinoma	f	30	non-viral	1	2	-	-	-	-
21	Carcinoma	m	65	HBV	3	24	+	-	-	-
21	Dysplasia						-	-	-	-
21	Cirrhosis							-	-	-
22	Carcinoma	m	46	non-viral	3	50	+	-	++	+
22	Dysplasia					64	-	-	-	-
22	Normal					14	-	-	-	-
23	Carcinoma	m	65	non-viral	2	14	-	-	+	+
23	Dysplasia						-	-	+	-
23	Cirrhosis						-	-	-	-
24	Carcinoma	m	69	non-viral	1		-	-	-	-
24	Dysplasia						-	-	-	-
24	Cirrhosis						-	-	-	-
25	Carcinoma	f	53	non-viral	1	12	-	-	+	-
26	Carcinoma	m	59	HBV	2		+	-	++	-
26	Dysplasia					6	-	+	-	-
27	Carcinoma	f	43	non-viral	3	22	-	-	+	-
27	Dysplasia						-	-	-	-
27	Normal					9	-	-	-	-
28	Carcinoma	m	72	non-viral	3	56	+	-	+	+
29	Carcinoma	m	48	HBV	2	24	-	+	+	-
29	Dysplasia						-	-	-	-
29	Cirrhosis					28	-	+	-	-

Patient	Tumor	Sex	Age ¹	Virus	Grade ²	FISH (C#1) ³	Ki67 ⁴	p16 ⁵	p53 ⁵	Rb1 ⁵
30	Carcinoma	m	63	HCV	2	66	+	-	-	+
30	Dysplasia					20	-	-	-	-
31	Carcinoma	m	73	non-viral	3	40	++	-	+	+
32	Carcinoma	m	62	HBV	2	22	-	-	-	-
32	Dysplasia						-	+	-	-
33	Carcinoma	f	41	non-viral	4	16	++	++	++	+
33	Normal					12	-	-	-	-
34	Carcinoma	f	43	non-viral	1		-	+	-	-
34	Normal						-	-	-	-
35	Carcinoma	m	66	HCV	2	12	-	-	-	-
35	Dysplasia						-	-	+	-
35	Normal						-	-	-	-
36	Carcinoma	f	45	non-viral	4		+	+	+	+
36	Dysplasia					22	-	-	-	-
36	Normal					8	-	-	-	-
37	Carcinoma	m	59	non-viral	2	26	-	-	-	+
37	Dysplasia						-	-	-	-
37	Cirrhosis						-	-	-	-
38	Carcinoma	f	22	HBV	2		+	-	+	-
38	Dysplasia						-	-	-	-
38	Normal						-	-	-	-
39	Carcinoma	f	56	HBV	2		-	-	-	-
39	Dysplasia						-	-	-	-
40	Carcinoma	f	56	non-viral	2	10	+	-	-	+
40	Dysplasia						-	-	-	-
40	Normal						-	-	-	-
41	Carcinoma	f	38	HBV	3		++	++	+	+
41	Normal						-	-	-	-
42	Carcinoma	f	70	non-viral	3		++	+	+	-
42	Normal						-	-	-	-
43	Carcinoma	f	46	HBV	3	16	-	-	-	-
43	Normal					18	-	-	-	-
44	Carcinoma	f	65	HCV	2	10	-	-	+	-
44	Dysplasia						-	-	-	-
44	Normal						-	-	-	-
45	Carcinoma	m	43	HBV/HCV	3	12	-	-	-	-
45	Dysplasia						-	-	-	-
45	Cirrhosis						-	-	-	-
46	Carcinoma	m	53	HBV	2	16	-	-	-	-
46	Dysplasia						-	-	+	-
47	Carcinoma	m	72	HBV	2		++	+	+	+
47	Dysplasia						+	-	-	+
47	Cirrhosis					21	-	-	-	-
48	Carcinoma	m	49	HCV	2	46	-	-	+	-
48	Dysplasia					30	-	+	-	-

Patient	Tumor	Sex	Age ¹	Virus	Grade ²	FISH (C#1) ³	Ki67 ⁴	p16 ⁵	p53 ⁵	Rb1 ⁵
49	Carcinoma	m	43	HBV	2	38	+	+	-	+
49	Dysplasia						-	+	-	-
50	Carcinoma	m	55	HBV	3	28	+	++	-	+
50	Dysplasia					33	-	-	-	-
50	Cirrhosis						-	-	-	-
51	Carcinoma	m	66	HCV	2	64	+	-	+	+
51	Normal					6	-	-	-	-
52	Carcinoma	m	59	non-viral	2	70	++	-	++	++
52	Dysplasia						-	-	-	-
52	Cirrhosis					12	-	-	+	-
53	Carcinoma	f	42	non-viral	4		-	-	-	+
53	Normal						-	-	-	-
54	Carcinoma	m	57	non-viral	2		-	-	+	+
54	Dysplasia					25	-	-	-	-
55	Carcinoma	m	63	non-viral	4		++	-	+	+
55	Dysplasia					17	-	-	-	-
55	Normal						-	-	-	-
56	Carcinoma	m	45	HCV	2	22	+	-	+	+
56	Dysplasia						-	-	-	-
57	Dysplasia ⁶	m	67	non-viral		25	-	-	-	-
58	Dysplasia ⁶	m	68	HCV			-	-	-	-
59	Dysplasia ⁶	m	48	non-viral			-	-	-	-
60	Dysplasia ⁶	m	64	non-viral		18	-	-	-	-
60	Normal						-	-	-	-
61	Dysplasia ⁶	f	23	HBV		28	-	-	-	-
61	Normal					14	-	-	-	-
62	Dysplasia ⁷	m	42	HBV		22	-	-	-	-
63	Dysplasia ⁶	m	48	HCV			-	+	-	-
63	Cirrhosis						-	-	-	-
64	Dysplasia ⁶	m	55	non-viral			-	-	-	-
64	Normal						-	-	-	-
65	Dysplasia ⁶	m	51	non-viral			-	-	-	-
65	Cirrhosis					25	-	-	-	-
66	Dysplasia ⁷	f	49	non-viral		38	-	-	-	-
66	Cirrhosis					17	-	-	-	-
67	cirrhosis ⁶	m	50	HBV		12	-	-	-	-
68	cirrhosis ⁶	m	66	HCV			-	-	-	-

1 Age at operation.

2 Histopathological grade according to Edmondson and Steiner (1954).

3 Percentage of hyperdiploid cells, i.e. with abnormal chromosome 1 numbers.

4 Ki67 protein expression: +, ++, and +++ represent p1%, 2–10% and 410% positive cells, respectively.

5 p16, p53 and Rb1 protein expression: +, ++, and +++ refer to p1%, 2–20% and 420% positive cells.

6 HCC not available for evaluation.

7 Dysplasia only in surgical specimen, no HCC.

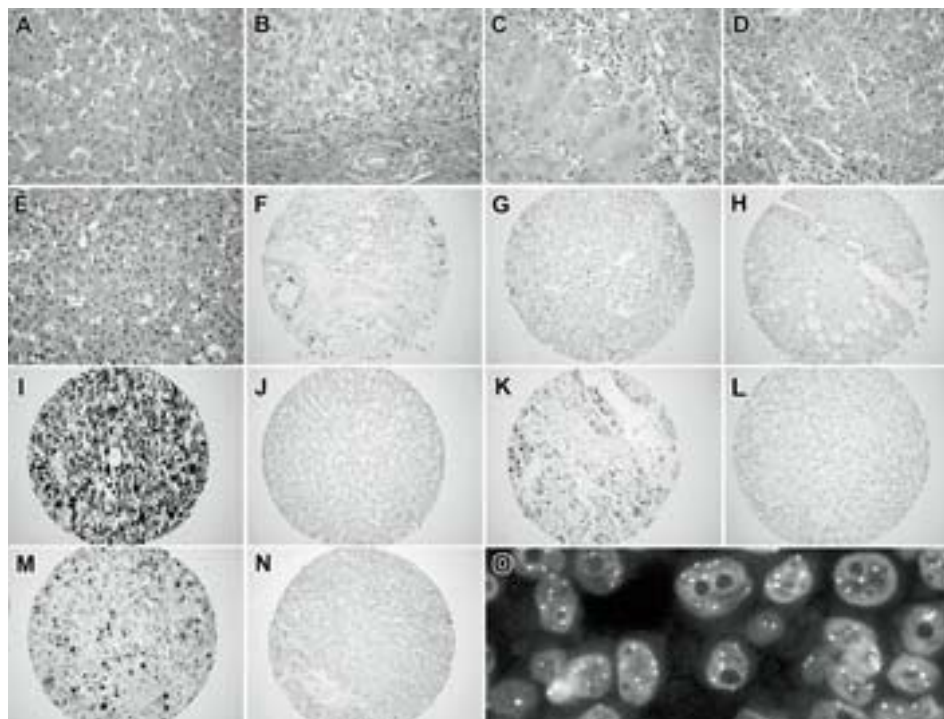


Figure 1. Images depicting morphological aspects, ploidy characteristics defined by fluorescent in situ hybridization (FISH), and changes in cellular proliferation and tumor suppressor protein expression, as measured by immunohistochemistry (IHC). (A–E) H&E staining illustrating normal, cirrhotic, dysplastic, carcinomatous and adenomatous liver, respectively. (F–H) (patient 47): Ki67 IHC showing many positive nuclei, i.e. highly increased proliferation in the HCC (F), moderately increased proliferation in adjacent dysplasia (G), and no proliferating hepatocytes in neighboring cirrhosis (H). (I,J) (patient 33): p16; strong protein overexpression in carcinoma cells (I), no overexpression in adjacent normal liver tissue (J). (K) (patient 26): p53 illustrating immunoreactivity in many cancer cell nuclei. (L) (patient 6): p53; scattered positively staining nuclei in adenoma cells. (M,N) (patient 52): Rb1; frequent protein overexpression in cancer cell nuclei of HCC (M), adjacent cirrhosis is negative (N). (O) (patient 28): FISH revealing an abnormal chromosome 1 number in HCC (cells with 42 spots/nucleus). A 40 objective was used for (A–E), a 20 objective for (F–N), and a 63 objective for (O).

Statistical evaluation

The Mann-Whitney-U test was used for comparisons between the specimen groups for the percentage of hyperdiploid cell nuclei (an abnormal chromosome 1 number). Fisher's Exact Test was applied for comparisons of the immunostaining results between groups, as well as tumor grade in relation to FISH and immunostaining. $P=0.05$ (two-sided) was taken as the limit of significance. A P-value between 0.05 and 0.10 was considered a statistical trend.

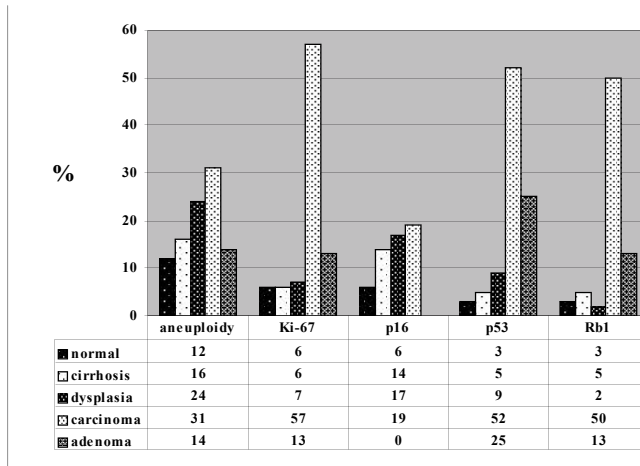


Figure 2. Bar histograms (and table) depicting all investigated liver tissues in relation to aneuploidy and cell biological perturbations. All positive immunostaining results (+ and ++) are grouped for better visualization of the cell biological alterations. Note the clear difference between HCC and the other liver tissues for cellular proliferation (Ki67) and tumor suppressors p53 and Rb1, but not p16. For hyperdiploidy the differences are more complex (see Table 2).

RESULTS

We constructed a liver tissue micro-array (TMA) representing 68 surgical specimens. Evaluation was completed of 56 primary liver tumors, i.e. 48 HCC's (31 male, 17 female; mean age 55.9 years, range 23-74) and 8 adenomas (1 male, 7 female; mean age 27.4, range 15-37). In addition, 2 dysplastic nodules in cirrhosis without HCC were included. Adjacent specimens comprised 44 dysplasias, 20 cirrhotic specimens and 28 normal liver samples. Both age and sex of the adenoma patients were significantly different from the HCC patients ($P < 0.001$ and $P = 0.016$, respectively). Twenty-five of the investigated HCC's were virus-associated, 23 were related to other causes; 25 of the 48 investigated HCC's developed in cirrhotic livers, 23 were not associated with cirrhosis.

The HCC and adenoma results are summarized in Table 1, illustrations are depicted in Figure 1. DNA ploidy was measured by fluorescent in situ hybridization (FISH) with a chromosome 1-specific peri-centromeric DNA probe. An abnormal chromosome 1 number, i.e. the percentage of hyperdiploid cells, was 11.0 (range 6-18), 13.7 (range 2-28), 16.1 (range 8-28), 23.7 (range 6-64) and 31.3 (range 2-70) for normal liver samples, adenomas, cirrhosis, dysplasias and HCC's, respectively. Carcinomas and dysplasias were clearly different from normal liver tissues ($P < 0.001$ and $P = 0.001$, respectively), whereas this was not discerned for cirrhotic and adenomatous specimens (Table 2). A significant difference was found for HCC versus cirrhosis ($P = 0.024$) or adenoma ($P = 0.033$), a trend was seen for dysplasia versus cirrhosis ($P = 0.094$; Table

TABLE 2. Statistical analysis of IHC (p16, p53, Rb1, Ki67) and FISH results.^{1,2}

p53	normal	cirrhosis	dysplasia	adenoma	carcinoma
normal					<0.001
cirrhosis					<0.001
dysplasia					<0.001
adenoma					
carcinoma	<0.001	<0.001	<0.001		
Rb1	normal	cirrhosis	dysplasia	adenoma	carcinoma
normal					<0.001
cirrhosis					<0.001
dysplasia					<0.001
adenoma					0.063
carcinoma	<0.001	<0.001	<0.001	0.063	
Ki67	normal	cirrhosis	dysplasia	adenoma	carcinoma
normal					<0.001
cirrhosis					<0.001
dysplasia					<0.001
adenoma					0.025
carcinoma	<0.001	<0.001	<0.001	0.025	
FISH³	normal	cirrhosis	dysplasia	adenoma	carcinoma
normal			<0.001		<0.001
cirrhosis			0.094		0.024
dysplasia	<0.001	0.094			
adenoma					0.033
carcinoma	<0.001	0.024		0.033	

¹ No significant associations (no matrix) for p16.² Open box, not significant; significant, P value below 0.05; trend, P value between 0.05 and 0.10 (borderline significance).³ Hyperdiploidy, i.e. an abnormal chromosome 1 number.

2). Protein (over)expression of tumor suppressor genes p16, p53 and Rb1 was assessed by immunohistochemistry, the proliferative capacity was examined by immunostaining of Ki67. Immunohistochemical protein expression of p53 and Rb1, as well as Ki67 defined proliferation, was clearly higher in HCC than in cirrhosis or dysplasia (all $P < 0.001$). P16 protein expression appeared low in all investigated liver tissue groups. Proliferation was higher in HCC than in adenoma ($P = 0.025$), whereas a trend was observed for Rb1 overexpression ($P = 0.063$; Table 2). No differences were observed between the normal, cirrhosis, dysplasia and adenoma groups for all investigated oncoprotein and proliferation markers. All of the data are schematically visualized in Figure 2. No statistical differences were found between FISH and IHC

results for tumor grade, viral and non-viral liver disease, and presence or absence of cirrhosis.

DISCUSSION

We used a tissue micro-array analysis comprising a total of 122 liver cell lesions and 28 normal controls. The results suggest that in the cirrhosis-dysplasia-carcinoma pathway aneuploidy occurs in liver cell dysplasia, which is followed by increased proliferation and cell biological perturbations involving p53 and Rb1 in HCC. Adenomas could be distinguished from carcinomas based on ploidy and proliferation characteristics, which could be of clinical utility. FISH with a chromosome-specific repetitive DNA probe might be most promising in this respect, as the difference in the mean percentage of hyperdiploid cells was large, i.e. 13.7 for adenomas and 31.3 for HCC's. This is in agreement with FISH and DNA flow cytometry studies that found aneuploidy in carcinomas, but not in adenomas (Nasarek et al., 1995; Ruschenburg et al., 2000). In our series both frequency and degree of aneuploidy in dysplastic liver lesions was comparable to those found in HCC. This has also been detected by DNA cytometry (Thomas et al., 1992; Rubin et al., 1994). Discriminating adenoma from dysplasia appeared difficult. Ki67 immunostaining profiles for benign neoplasms of the liver have been reported to show very low growth fractions, similar to those in normal or cirrhotic livers (Grigioni et al., 1989). Low percentages of p53-positive cells have also been described for cirrhotic, dysplastic and adenomatous liver lesions, when compared with carcinomas (Cohen and Derose, 1994; Ojanguren et al., 1995). From these and our results we conclude that with oncoprotein and proliferation markers it is not possible to confidently discriminate adenomas from liver cell dysplasias.

We found few p16-positive cells in cirrhosis, dysplasia and HCC, whereas immunostaining was basically absent in normal and adenomatous liver tissue. However, the p16 gene has been reported a major inactivation target in liver cancers (Jin et al., 2000). This phenomenon might be attributed to the immunohistochemical detection of p16, which does not visualize genetic alterations, such as homozygous deletion or promotor hypermethylation (Narimatsu et al., 2004). Promotor hypermethylation of p16 with absence of deletions was described in liver cell adenomas (Tannapfel et al., 2002), which is in line with our results. High proliferation rates and frequent p53 protein overexpression were seen in HCC, which is in accordance to published data (Wu et al., 1999; Ojanguren et al., 1995). Both immunomarkers can be used to discriminate HCC from dysplasia, whereas Ki67 measurements can be helpful in separating liver cell adenoma from cancer. A correlation between loss of Rb1 mRNA expression and Rb1 methylation has been shown (Edamoto et al., 2003). However, immunostaining of Rb1 visualizes the phosphorylated protein, which is

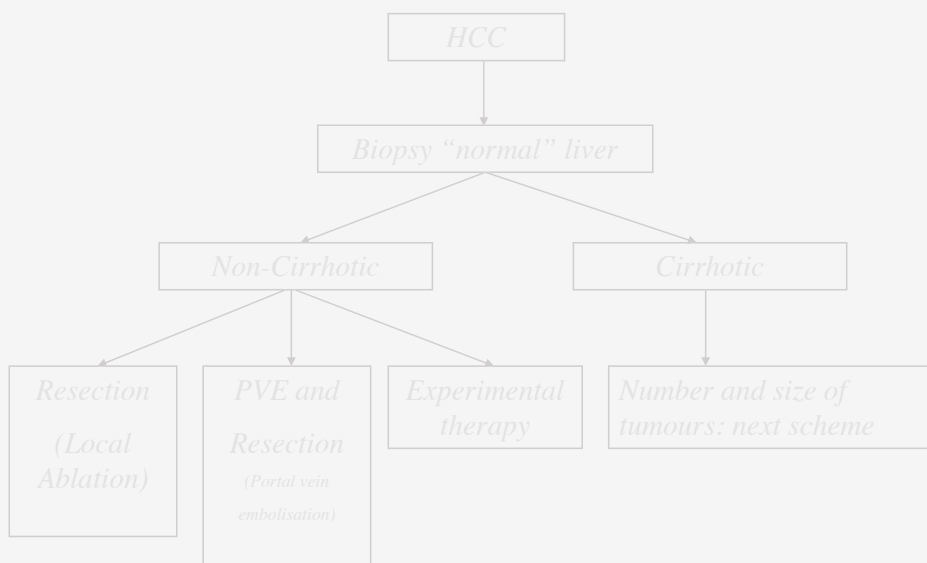
overexpressed in a variety of tumor cell lines (Bartek et al., 1992). This was also seen in our series, where liver cell carcinoma could be easily distinguished from dysplasia, but more difficult from adenoma.

The use of a tissue micro-array enabled us to screen a large number of liver cell lesions ranging from cirrhosis to cancer. From our data we conclude that it is unlikely that liver cell adenomas play a role in the pathway leading to liver cell carcinoma. Protein IHC with Ki67, p53 and Rb1 is capable to distinguish HCC from dysplasia and cirrhosis, whereas Ki67-defined proliferation index and FISH-measured ploidy can be utilized to discriminate liver cell adenomas from carcinomas.

References

- Alers JC, Van Dekken H. Interphase cytogenetic analysis of solid tumors by non-isotopic DNA in situ hybridization. *Progr Histochem Cytochem* 1996; 31: 1-137.
- Bartek J, Vojtesek B, Grand RJA, Gallimore PH, Lane DP. Cellular localization and T antigen binding of the retinoblastoma protein. *Oncogene* 1992; 7: 101-8.
- Biden K, Young J, Buttenshaw, Searle J, Cooksley G, Xu D-B, Leggett B. Frequency of mutation and deletion of the tumor suppressor gene CDKN2A (MTS1/p16) in hepatocellular carcinoma from an Australian population. *Hepatology* 1997; 25: 593-7.
- Borzio M, Bruno S, Roncalli M, Colloredo Mels G, Ramella G, Borzio F, Leandro G, Servida E, Podda M. Liver cell dysplasia is a major risk factor for hepatocellular carcinoma in cirrhosis. A prospective study. *Gastroenterology* 1994; 108: 812-7.
- Bruix J, Boix L, Sala M, Llovet JM. Focus on hepatocellular carcinoma. *Cancer Cell* 2004; 5: 215-9.
- Cohen C, Derose PB. Immunohistochemical p53 in hepatocellular carcinoma and liver cell dysplasia. *Mod Pathol* 1994; 7: 536-9.
- D'Errico A, Grigioni WF, Fiorentino M, Baccarini P, Grazi GL, Mancini AM. Overexpression of p53 protein and Ki67 proliferative index in hepatocellular carcinoma: an immunohistochemical study on 109 Italian patients. *Pathol Int* 1994; 44: 682-7.
- Ding S-F, Delhanty JDA, Carrillo A, Serra GD, Bowles L, Dooley JS, Wood CB, Habib NA. Lack of demonstrable chromosome allele loss in hepatocellular carcinoma. *J Clin Oncol* 1993; 2: 977-9.
- Edamoto Y, Hara A, Biernat W, Terracciano L, Cathomas G, Riehle HM, Matsuda M, Fujii H, Scoazec JY, Ohgaki H. Alterations of Rb1, p53 and Wnt pathways in hepatocellular carcinomas associated with hepatitis C, hepatitis B and alcoholic liver cirrhosis. *Int J Cancer* 2003; 106: 334-41.
- Edmondson HA, Steiner PE. Primary carcinoma of the liver. A study of 100 cases among 48900 necropsies. *Cancer* 1954; 7: 462-503.
- Feitelson MA, Sun B, Satioglu Tufan NL, Liu J, Pan J, Lian Z. Genetic mechanisms of hepatocarcinogenesis. *Oncogene* 2002; 21: 2593-604.
- Grigioni WF, D'Errico A, Bacci F, Gaudio M, Mazziotti A, Gozzetti, Mancini AM. Primary liver neoplasms: evaluation of proliferative index using moab Ki67. *J Pathol* 1989; 158: 23-9.
- International Working Party. Terminology of nodular hepatocellular lesions. *Hepatology* 1995; 22: 983-93.
- Jin M, Piao Z, Kim NG, Park C, Shin EC, Park JH, Jung HJ, Kim CG, Kim H. P16 is a major inactivation target in hepatocellular carcinoma. *Cancer* 2000; 89: 60-8. Kononen J, Bubendorf L, Kallioniemi A, Barlund M, Schraml P, Leighton S, Torhorst J, Mihatsch MJ, Sauter G, Kallioniemi OP. Tissue microarrays for high-throughput molecular profiling of tumor specimens. *Nat Genet* 1998; 4: 844-7.
- Kusano N, Shiraishi K, Kubo K, Oga A, Okita K, Sasaki K. Genetic aberrations detected by comparative genomic hybridization in hepatocellular carcinomas: their relationship to clinicopathological features. *Hepatology* 1999; 29: 1858-62.
- Marchio A, Meddeb M, Pineau P, Danglot G, Tiollais P, Bernheim A, Dejean A. Recurrent chromosomal abnormalities in hepatocellular carcinoma detected by comparative genomic hybridization. *Genes Chromosomes Cancer* 1997; 18: 59-65.
- Mion F, Grozel L, Boillot O, Paliard P, Berger F. Adult cirrhotic liver explants: Precancerous lesions and undetected small hepatocellular carcinomas. *Gastroenterology* 1996; 111: 1587-92.
- Nagai H, Pineau P, Tiollais P, Buendia MA, Dejean A. Comprehensive allelotyping of human hepatocellular carcinoma. *Oncogene* 1997; 14: 2927-33.
- Narimatsu T, Tamori A, Koh N, Kubo S, Hirohashi K, Yano Y, Arakawa T, Otani S, Nishiguchi S. P16 promoter hypermethylation in human hepatocellular carcinoma with or without hepatitis virus infection. *Intervirology* 2004; 47: 26-31.
- Nasarek A, Werner M, Nolte M, Klempnauer J, Georgii A. Trisomy 1 and 8 occur frequently in hepatocellular carcinoma, but not in liver cell adenoma and focal nodular hyperplasia. A fluorescence in situ hybridization study. *Virchows Arch* 1995; 427: 373-8.
- Ojanguren I, Ariza A, Castella EM, Fernandez-Vasalo A, Mate JL, Navas-Palacios JJ. P53 immunoreactivity in hepatocellular adenoma, focal nodular hyperplasia, cirrhosis and hepatocellular carcinoma. *Histopathology* 1995; 26: 63-8.

- Okabe H, Ikai I, Matsuo K, Satoh S, Momoi H, Kamikawa T, Katsura N, Nishitai R, Takeyama O, Fukumoto M, Yamaoka Y. Comprehensive allelotype study of hepatocellular carcinoma: Potential differences in pathways to hepatocellular carcinoma between hepatitis B virus-positive and -negative tumors. *Hepatology* 2000; 31: 1073-9.
- Parada LA, Hallen M, Tranberg KG, Hagerstrand I, Bondeson L, Mitelman F, Johansson B. Frequent rearrangements of chromosomes 1, 7, and 8 in primary liver cancer. *Genes Chromosomes Cancer* 1998; 23: 26-35.
- Piao Z, Kim H, Jeon BK, Lee WJ, Park C. Relationship between loss of heterozygosity of tumor suppressor genes and histologic differentiation in hepatocellular carcinoma. *Cancer* 1997; 80: 865-72.
- Riegler JL. Preneoplastic conditions of the liver. *Semin Gastrointest Dis* 1996; 7: 74-87.
- Rubin EM, Derosé PB, Cohen C. Comparative image cytometric DNA ploidy of liver cell dysplasia and hepatocellular carcinoma. *Mod Pathol* 1994; 7: 677-80.
- Ruschenburg I, Hofmann M, Diab E, Droese M. Comparison of the DNA content in liver cell adenoma, hepatocellular carcinoma and regenerative nodules. *Anticancer Res* 2000; 20: 1861-4.
- Scheuer PJ, Lefkowitz JH. Neoplasms and nodules. In: *Liver biopsy interpretation*. 6th ed. W.B. Saunders, London, UK, 2000; 191-227.
- Tannapfel A, Busse C, Geissler F, Witzigmann H, Hauss J, Wittekind C. INK4A-ARF alterations in liver cell adenoma. *Gut* 2002; 51: 253-8.
- Terris B, Ingster O, Rubbia L, Dubois S, Belghiti J, Feldmann G, Degott C, Hénin D. Interphase cytogenetic analysis reveals numerical chromosome aberrations in large liver cell dysplasia. *J Hepatol* 1997; 27: 313-9.
- Thomas RM, Berman JJ, Yetter RA, Moore GW, Hutchins GM. Liver cell dysplasia: a DNA aneuploid lesion with distinct morphologic features. *Hum Pathol* 1992; 23: 496-503.
- Van Dekken H, Wink J, Alers JC, de Man RA, IJzermans JN, Zondervan PE. Genetic evaluation of the dysplasia-carcinoma sequence in chronic viral liver disease: A detailed analysis of two cases and a review of the literature. *Acta Histochem* 2003; 105: 29-41.
- Wilkins L, Bredt M, Flemming P, Becker T, Klemphauer J, Kreipe HH. Differentiation of liver cell adenomas from well-differentiated hepatocellular carcinomas by comparative genomic hybridization. *J Pathol* 2001; 193: 476-82.
- Wong N, Lai P, Lee S-W, Fan S, Pang E, Liew C-T, Sheng Z, Lau JW-Y, Johnson PJ. Assessment of genetic changes in hepatocellular carcinoma by comparative genomic hybridization analysis. *Am J Pathol* 1999; 154: 37-43.
- Wu PC, Lau VK, Fang JW, Lai VC, Lai CL, Lau JY. Imbalance between cell proliferation and cellular DNA fragmentation in hepatocellular carcinoma. *Liver* 1999; 19: 444-51.
- Zhao M, Zhang NX, Laissue JA, Zimmermann A. Immunohistochemical analysis of p53 protein overexpression in liver cell dysplasia and in hepatocellular carcinoma. *Virchows Arch* 1994; 424: 613-21.
- Zimonjic DB, Keck CL, Thorgeirsson SS, Popescu NC. Novel recurrent genetic imbalances in human hepatocellular carcinoma cell lines identified by comparative genomic hybridization. *Hepatology* 1999; 29: 1208-14.
- Zondervan PE, Wink J, Alers JC, IJzermans JN, Schalm SW, de Man RA, van Dekken H. Molecular cytogenetic evaluation of virus-associated and non-viral hepatocellular carcinoma: analysis of 26 carcinomas and 12 concurrent dysplasias. *J Pathol* 2000; 192: 207-15.



HCC non-cirrhotic liver

Chapter VI

Good outcomes after resection of large hepatocellular carcinomas in the non-cirrhotic liver

Dig Surg 2004;21:380-386

ABSTRACT

Background: The results of partial liver resection of HCC in non-cirrhotic livers are not well known. Therefore a retrospective study was conducted.

Methods: The medical records of 180 patients with HCC were reviewed. In 40 patients (22%) HCC occurred in a non-cirrhotic liver. A detailed analysis of these patients was performed. The diagnosis HCC was based on imaging and/or percutaneous ultrasound-guided biopsy. A biopsy of the remaining liver and peroperative findings documented the absence of cirrhosis.

Results: Twenty-two patients underwent partial liver resection. There was no surgical mortality. The median tumour diameter in the operated patients was 10 cm. Survival rates for operated patients at one and five years were 96% and 68%, respectively. Significant factors reducing survival were portal vein thrombosis, positive lymph nodes, microscopic vascular invasion and tumour recurrence. Tumour size at the initial moment of diagnosis was not of predictive value. After surgery with curative intent disease free interval at 1 and 5 years were respectively 86% and 56%.

Conclusion: In selected patients without cirrhosis, HCC can be treated successfully by surgical resection, independent of the tumour diameter, with a 5-year survival rate of 68%.

INTRODUCTION

Hepatocellular carcinoma (HCC) is one of the most common cancers in man. Its world-wide annual incidence has been estimated to be 250.000 to 1 million people (1) with more than 1 million deaths each year (2). In North America and several European countries, HCC is uncommon and the estimated death rate is less than 5/100.000 inhabitants/year (3). Although many aspects of HCC have been studied in detail, less attention has been directed so far to the presence or absence of cirrhosis in the underlying liver in relation to the prognosis for patients with this disease.(4,5) Several studies have described the histopathological characteristics of HCC in a non-cirrhotic liver. Special attention was directed to the non-cirrhotic liver, the etiological factors and the clinical presentation.(6-15). However, the outcome of surgical resection of HCC in the non-cirrhotic liver has seldom been reported. We retrospectively analysed a group of 40 patients, with HCC in a non-cirrhotic liver, seen at our institution.

PATIENTS AND METHODS

Between January 1987 and July 2000, 180 patients with HCC were seen in the Erasmus Medical Centre, a tertiary referral center in the Netherlands. The medical charts of these 180 patients with HCC were analysed in retrospect. Cirrhosis was absent in samples of non-tumorous liver of 40 patients. These patients were selected for this study. In this non-cirrhotic HCC group the mean age was 56 years \pm 17 years (range 17-90 years). Males (n=22) and females (n=18) gender was more or less equally distributed, with a male-to-female ratio of 1.2 : 1. Male patients had a mean age of 59 years \pm 15 years, female patients a mean age of 52 years \pm 18 years. Thirteen patients had one or more markers for hepatitis B or C infection (33%); twelve patients were infected with Hepatitis B Virus (30%), one with a Hepatitis C Virus (3%) and two both (5%).

One pathologist (PEZ) reviewed all biopsies and resected specimen. All liver biopsies/resected specimen were evaluated according to the Knodell index (16). Sixteen patients (40%) had slight or moderate fibrosis, in one patient (3%) haemochromatosis and in 5 patients (13%) moderate steatosis was seen. Histopathological examination of the tumour is described in Table 1. Tumour differentiation was less in 7%, moderate in 48% and well-differentiated in 26%. In 19% of cases differentiation was not evaluated. In 40% of cases, vascular invasion was found, in 40% of cases vascular invasion was not found; it was not determined in 20% of cases.

Characteristics of the operations are displayed in Table 2. Twenty-two of the 40 patients (resection rate of 55%) were operated on. All resections had a tumour free margin. All resections were undertaken with the intent to cure. There was no opera-

tive mortality. No (neo) adjuvant therapy was given in the operated patients. Eighteen patients were not operated on. Six patients had multiple tumours in the right and left side of the liver. Two patients had a large tumour that had ruptured into the abdominal cavity and were therefore considered irresectable (at that time). Two patients had a poor cardiac function, 8 patients had vascular ingrowth and/or positive lymph nodes, demonstrated by CT and /or percutaneous puncture.

Operative mortality was defined as intraoperative death and death during hospital stay postoperatively. Actuarial survival was calculated from the date of diagnosis. Survival and survival without recurrence were analysed according to the Kaplan-Meier survival method. Continuous data will be shown as the median (range). The Log-rank test and Cox regression test were used to analyse prognostic factors according to survival and recurrence. The Cox-time dependent regression model was

Table 1 Characteristics of the study population.

	Operated	Not operated	Total Group
	22	18	40
Male	13	9	22
Female	9	9	18
Age (mean in years, range)	56 (23-77)	56 (17-90)	56 (17-90)
Race			
Caucasian	17	12	29
Black	1	1	2
Eastern	3	4	7
Hindu	1	1	2
Tumour (mean in cm, range)	10 (1,5-18)	9 (1,5-21)	10 (1,5-21)
Hep B/C infection	7	6	13
AFP (mean in µg/L, range)	6198 (1-128720)	62848 (1-810000)	30050 (1-810000)
Positive lymph nodes	1	5	6
V. porta thrombosis	1	10	11
Solitary tumour	18	9	27
Tumour location in liver			
Left half	10	2	12
Right half	11	10	21
Left and Right sides	1	6	7
Core biopsy tumour	17	16	33
Histopathological examination			
Trabecular type	5	8	13
Acinar type	4	2	6
Fibrolamellar type	2	1	3
Mixed Type	11	2	13
Unknown	0	5	5

Pts : Patients

used to analyse recurrence as a prognostic factor for survival. Calculations were performed on a personal computer using SPSS for Windows 95. Significance is defined as $P < 0.05$.

RESULTS

In Table 1 the characteristics of the patients of the operated and non-operated groups are described. Elevated levels ($> 30 \mu\text{g/L}$) of serum α fetoprotein (AFP) were found for 23 patients (55%). AFP levels were available on all patients.

The last patient included in this analysis was operated in July 2000. Follow-up was completed prospectively as to September 2003. One patient moved to China and therefore lost to follow-up. Cumulative survival for the non-operated group after 1 and 5 years was 24% and 6% respectively with a median survival time of 7 months, by Kaplan Meier method. Cumulative survival for the operated patients after 1 and 5 years was 96% and 68% respectively with a median survival of 79 months (figure 1). After operation the disease free interval after 1 and 5 years was 86% and 56% respectively. Ten of the 22 (45%) patients who were operated on developed recurrence of HCC during follow-up. An overview of the patients with recurrence is presented in table 3. Three patients developed 4 extrahepatic metastases and were operated (Pt 1, 5, 9). These (highly selected) patients are still alive 17 months, 59 months and 62 months after metastasectomy. Pt number 1 (table 3) developed a second recurrence (intra-abdominal) after 58 months. This was operated and patient is still alive, 84

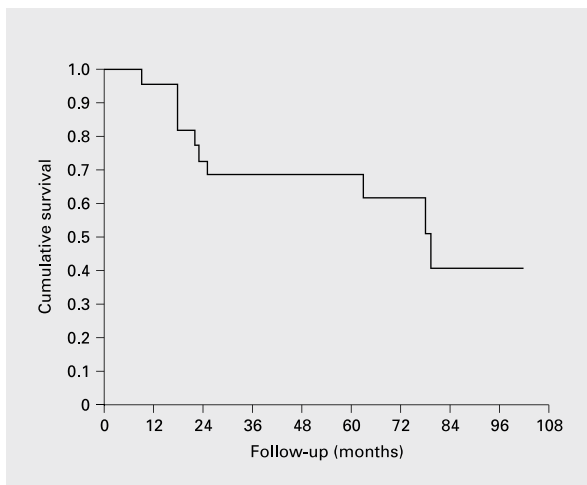


Fig. 1. Long-term survival after partial liver resection (Kaplan-Meier curve). The number of patients alive at follow-up (months) was as follows: 21 (12), 16 (24), 15 (36), 11 (48), 10 (60), 6 (72), 4 (84) and 1 (96).

Table 2. Operation characteristics (22 patients)

<i>Operation performed</i>	
4 segment resections	
9 right lobectomies	
7 left lobectomies	
2 extended left lobectomies	
<i>Hospital stay</i>	
Mean: 20 days	
Median: 16 days	
Range: 3–72 days	
<i>Complications and treatment</i>	
<i>Liver related</i>	
3 patients with ascites	diuretics, no drainage
2 patients with a biloma	1 patient had ERCP with stent, both had percutaneous drainage
<i>Not liver related</i>	
1 patient with fascial dehiscence (burst abdomen)	re-operation
3 patients with pneumonia	antibiotics
2 patients with urinary tract infection	antibiotics
1 patient with Horner syndrome	because of v. jugularis catheter injury

months after first resection. An example of a patient with a hemihepatectomy who did not suffer a recurrence in her 5 years of follow-up is seen in figure 2.

For the whole group of patients (n=40), operation, vascular invasion and portal vein thrombosis were highly significant ($p<0.0001$) prognostic factors for survival. The presence of more than one tumour nodule or positive lymph nodes had also a poorer survival ($p<0.05$). Not significant were tumour size, age, sex, race, viral status, serum AFP and pre operative serum haemoglobin levels. In the operated group of patients (n=22), portal vein thrombosis, microscopic vascular invasion, positive lymph nodes and tumour recurrence were significant prognostic factors for survival ($p<0.05$). Not significant factors were, among many others, tumour size, age, sex, race, viral status, more than one primary tumour, serum AFP or per operative bloodloss. Significant prognostic factors for tumour recurrence in the operated group were portal vein thrombosis and positive lymph nodes ($p<0.05$). Tumour size, age, sex, race, viral status, number of primary tumours, vascular invasion, serum AFP and per operative bloodloss were not found to be significant factors.

DISCUSSION

In this study we evaluated the outcome of surgical treatment and presentation of patients with HCC without liver-cirrhosis. Absence of underlying cirrhosis is found in approximately 5-40% of patients with HCC in Western countries. (6,7,9,17,18) Because the absence of cirrhosis leads to late presentation in the course of the disease, larger tumours are more likely to be seen in a patient with a non-cirrhotic than a cirrhotic liver. At our institute the size of the tumour was never a contraindication for operation as such. Despite the large resections encountered, there was no postoperative

Table 3. Overview of patients with recurrence HCC after partial liver resection

	Type of resection	Recurrence-site	Recurrence	Treatment	Status	Survival
Pt 1	Hemi hepatectomy	Subcutaneous seeding	22 months	Surgical resection	Alive	84 months
Pt 2	Hemi hepatectomy	Intra-hepatic	39 months	Local Ablation	Alive	69 months
Pt 3	Segmental resection	Intra-hepatic	7 months	Hemihepatectomy	Dead	78 months
Pt 4	Segmental resection	Intra-hepatic	11 months	None	Dead	18 months
Pt 5	Hemi hepatectomy	Subcutaneous seeding	25 months	Surgical resection	Alive	84 months
Pt 6	Hemi hepatectomy	Intra-abdominal/ Bones	8 months	None	Dead	9 months
Pt 7	Segmental resection	Intra-hepatic	15 months	None	Dead	18 months
Pt 8	Hemi hepatectomy	Lung/Intra-hepatic	36 months	None	Alive	50 months
Pt 9	Segmental resection	Intra-abdominal	29 months	Surgical resection	Alive	46 months
Pt 10	Segmental resection	Intra-hepatic	13 months	None	Dead	23 months

liver failure. This may be explained by the gradual growth of the large tumours which induces functional adaptation of the contralateral lobe.

In this study we had a relatively high percentage of percutaneous biopsies of the tumour (83%) pre-operatively. As a rule it was performed in the hospital where the patients were first seen. Our policy is not to perform a percutaneous biopsy of the tumour because of the risk of subcutaneous seeding.(19) In this study, 2 of the 35

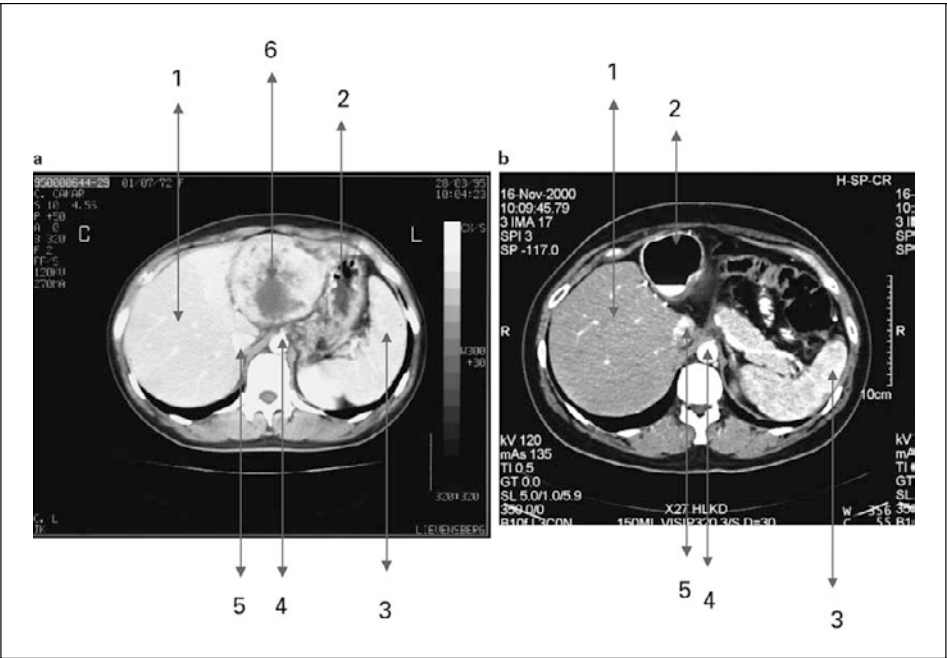


Fig. 2. An example of a patient with hemihepatectomy who did not suffer a recurrence in her 5 years of follow-up. 1 = Liver; 2 = stomach; 3 = spleen; 4 = aorta; 5 = inferior vena cava; 6 = HCC. **a** Before hemihepatectomy. **b** Five years after the resection.

Table 4. Long-term survival of HCC resections in a non-cirrhotic liver

Reference	No. of patients	Year of publication	5-year survival rate
Smalley et al. (22)	29	1988	25%
Adson et al. (33)	45	1988	35%
Iwatsuki et al. (34)	55	1988	25%
Ringe et al. (35)	86	1991	45%
Iwatsuki et al. (28)	59	1991	44%
Bismuth et al. (20)	68	1995	40%
Fong et al. (4)	54	1999	42%
Nagasue et al. (21)	100	2001	50%
Present series	22		68%

patients (6%) that underwent percutaneous tumour biopsies developed subcutaneous tumour seeding during follow-up, related to the biopsies. We advocate a percutaneous biopsy of the "normal" liver to exclude cirrhosis. We perform a biopsy of the lesion when characteristics obtained by imaging do not support a diagnosis and further management remains unclear.

The prognosis for patients with HCC in a non-cirrhotic liver is not as clearly described as that for patients with HCC in a cirrhotic liver. Only a few data are available. The 5-year survival rates range from 25% to 50% (Table 4). Bismuth et al. (20) and Nagasue et al. (21) reported a survival rate of 26% and 47%, respectively at 10 years. Nagasue et al. (21) reported a significant rise in intrahepatic recurrences in patients with hepatitis C virus infection. We found no differences in the patient group having hepatitis C virus infection or not regarding survival or recurrences. Probably because of the small numbers our study (n=3) we did not support this finding.

Considering the usually large size of these tumours, in the present series a median and mean of 10 cm, these results appear better than those reported for HCC in the cirrhotic liver. (5,20) A trend of an increasing 5-year survival rate for HCC in a non-cirrhotic liver was found. If we look at Table 4, the first three studies reported a 5-year survival rate of 25% to 35%. The last three studies had a 5-year survival rate of 42% to 68%. The improved outcomes might be related to a better patient selection.

Literature is in favor of surgical treatment if intra-hepatic recurrence has developed. (20-23) The role of surgery for extrahepatic recurrence of HCC is not well established. Extrahepatic recurrence occurs in about 30% of the patients (24). Literature on the subject of survival after treatment of extrahepatic recurrence is limited. To our knowledge, there are four studies reporting resection of extrahepatic recurrence in patients with HCC (24-27). Although small number of patients (8 - 14 patients), these studies report that long term survival can be achieved. In our study, three patients are still alive 17, 59 and 62 months after extra-hepatic metastasectomy. Therefore, we conclude that in this very selected patient group, resection must be considered. Long term survival can be achieved if radical resection can be performed.

Attempts to improve the treatment of hepatocellular carcinoma in non cirrhotics by performing total hepatectomy and liver transplantation have failed. The rates of post-transplant 5-year survival were 26% reported by Iwatsuki et al.(28). Pichlmayr et al.(29) and Houben/McCall (30) confirmed that patients should not be offered OLT for HCC (they specified it for the non fibrolamellar HCC) in a non-cirrhotic liver. Neuhaus et al.(31) reported that liver transplantation is also not appropriate for fibrolamellar carcinoma in the non-cirrhotic liver.

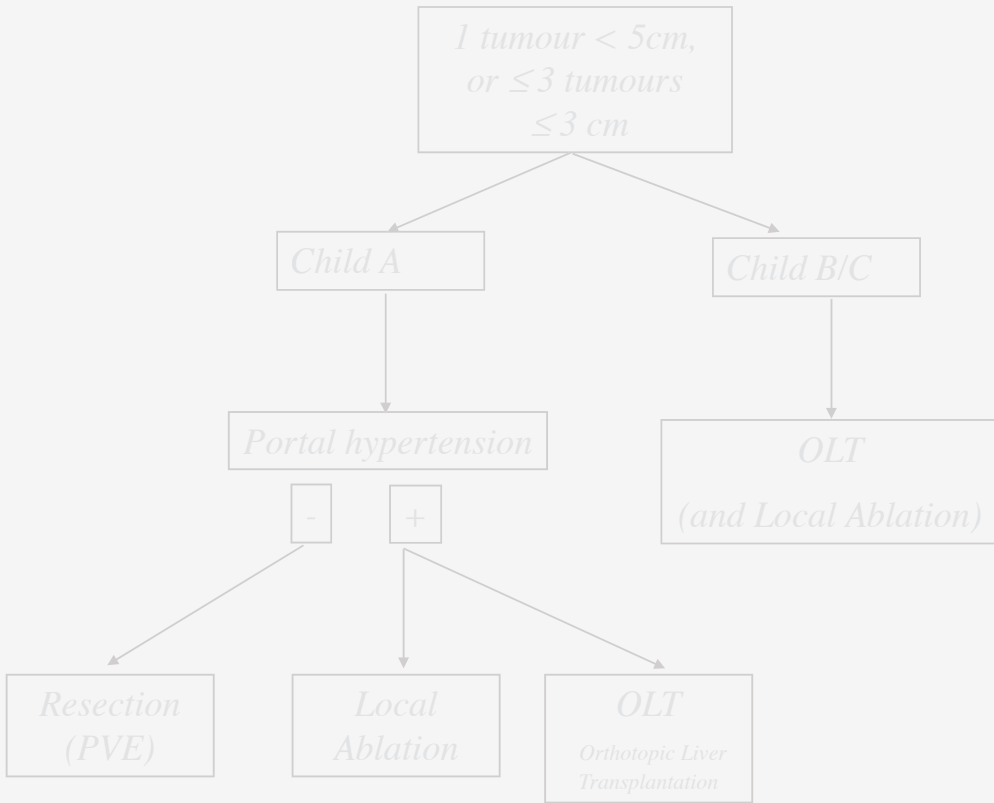
Three patients had a ruptured HCC in our series. This is not a contraindication for resection. Chiappa et al.(32) conclude, because of their own experience combined with a literature review of 755 cases of ruptured HCC, that surgical resection is associated with long-term survival. When conservative management was chosen, there were no long-term survivors.

In Conclusion: According to our experiences as well as current literature it appears that partial liver resection is the gold standard for treatment of HCC in the non-cirrhotic liver. We will emphasize that tumour size did not influence outcome. Patients without metastases, positive lymph nodes and portal vein thrombosis had a 5 year survival rate after resection, independent of clinical and biochemical characteristics, of 68% in our series.

References

1. Simonetti RG, Camma C, Fiorello F, *et al.* Hepatocellular carcinoma. A worldwide problem and the major risk factors. *Dig Dis Sci* 1991;36:962-72.
2. Rutsgl VK. Epidemiology of hepatocellular carcinoma. *Ann Int Med* 1988;108:390-91.
3. Ramsey WH, Wu GY. Hepatocellular carcinoma: Update on diagnosis and treatment. *Dig Dis* 1995;13:81-91.
4. Fong Y, Sun RL, Jarnagin W, *et al.* An analysis of 412 cases of hepatocellular carcinoma at a western center. *Ann Surg* 1999;229:790-800.
5. Bilimoria MM, Lauwers GY, Doherty DA, *et al.* Underlying liver disease, not tumor factors, predicts long-term survival after resection of hepatocellular carcinoma. *Arch Surg* 2001;136:528-33.
6. Nzeako UC, Goodman ZD, Ishak KG. Hepatocellular carcinoma in cirrhotic and non cirrhotic livers. A clinico-histopathologic study of 804 North American patients. *Am J Clin Path* 1996;105:65-75.
7. Trevisani F, D'Intimo PE, Caraceni P, *et al.* Etiologic factors and clinical presentation of hepatocellular carcinoma: differences between cirrhotic and noncirrhotic Italian patients. *Cancer* 1995;75:2220-32.
8. Bralet MP, Regimbeau JM, Pineau P, *et al.* Hepatocellular carcinoma occurring in nonfibrotic liver: Epidemiologic and histopathologic analysis of 80 French cases. *Hepatology* 2000;32:200-04.
9. Van Roey G, Fevery J, Van Steenberghe W. Hepatocellular carcinoma in Belgium: clinical and virological characteristics of 154 consecutive cirrhotic and non-cirrhotic patients. *Eur J Gastroenterol Hepatol* 2000;12(1):61-66.
10. Okuda K, Nakshima T, Kojiro M, *et al.* Hepatocellular carcinoma without cirrhosis in Japanese patients. *Gastroenterology* 1989;97:140-46.
11. Grando-Lemaire, Guettier C, Chevret S, *et al.*, for the Groupe d'Etude et de traitement du carcinome hepatocellulaire. Hepatocellular carcinoma without cirrhosis in the West: epidemiological factors and histopathology of the non-tumorous liver. *J Hepatol* 1999;31:508-13.
12. Blanc JF, De Ledinghen V, Bernard PH, *et al.* Increased incidence of HFE C282Y mutations in patients with iron overload and hepatocellular carcinoma developed in non-cirrhotic liver. *J Hepatol* 2000;32:805-11.
13. Britto MRC, Thomas LA, Balaratnam N, *et al.* Hepatocellular carcinoma arising in non-cirrhotic liver in genetic haemochromatosis. *Scand J Gastroenterol* 2000;35:889-93.
14. Kondo M, Yamamoto H, Nagano H, *et al.* Increased expression of COX-2 in nontumor liver tissue is associated with shorter disease-free survival in patients with hepatocellular carcinoma. *Clin Cancer Res* 1999;5:4005-12.
15. Turlin B, Juguet F, Moirand R, *et al.* Increased liver iron stores in patients with hepatocarcinoma developed on non-cirrhotic liver. *Hepatology* 1995;22:446-50.
16. Knodell RG, Ishak KG, Black WC, *et al.* Formulation and application of a numerical scoring system for assessing histological activity in asymptomatic chronic active hepatitis. *Hepatology* 1981;1:431-35.
17. Kubicka S, Rudolph KL, Hanke M, *et al.* Hepatocellular carcinoma in Germany: a retrospective epidemiological study from a low-endemic area. *Liver* 2000;20:312-18.
18. Bosch FX. Global epidemiology of hepatocellular carcinoma. In: *Liver Cancer*. Okuda K, Tabor E (editors). New York: Churchill Livingstone; 1997:13-28.
19. Schotman SN, De Man RA, Stoker J, *et al.* Subcutaneous seeding of hepatocellular carcinoma after percutaneous needle core biopsy. *Gut* 1999;45(4):626-27.
20. Bismuth H, Chiche L, Castaing D. Surgical treatment of hepatocellular carcinomas in noncirrhotic liver: experience with 68 liver resections. *World J Surg* 1995;19:35-41.
21. Nagasue N, Ono T, Yamanoi A, *et al.* Prognostic factors and survival after hepatic resection for hepatocellular carcinoma without cirrhosis. *Br J Surg* 2001;88:515-22.
22. Smalley SR, Moertel CG, Hilton JF, *et al.* Hepatoma in the noncirrhotic liver. *Cancer* 1988;62:1414-24.
23. Zhou XD, Tang ZY, Yu YQ, *et al.* Hepatocellular carcinoma: some aspects to improve long term survival. *J Surg Oncol* 1989;41:256-62.
24. Farges O, Regimbeau JM, Belghiti J. Aggressive management of recurrence following surgical resection of hepatocellular carcinoma. *Hepatogastroenterology* 1998;45 Suppl 3:1275-80.

25. Poon RT, Fan ST, O'Suilleabhain CB, Wong J. Aggressive management of patients with extrahepatic and intrahepatic recurrences of hepatocellular carcinoma by combined resection and locoregional therapy. *J Am Coll Surg* 2002;195(3):311-8.
26. Arai S, Monden K, Niwano M, Furutani M, Mori A, Mizumoto M, et al. Results of surgical treatment for recurrent hepatocellular carcinoma; comparison of outcome among patients with multicentric carcinogenesis, intrahepatic metastasis, and extrahepatic recurrence. *J Hepatobiliary Pancreat Surg* 1998;5(1):86-92.
27. Lo CM, Lai EC, Fan ST, Choi TK, Wong J. Resection for extrahepatic recurrence of hepatocellular carcinoma. *Br J Surg* 1994;81(7):1019-21.
28. Iwatsuki S, Starzl TE, Sheahan DG, et al. Hepatic resection versus transplantation for hepatocellular carcinoma. *Ann Surg* 1991;214:221-28.
29. Pichlmayr R, Weimann A, Oldhafer KJ, et al. Role of liver transplantation in the treatment of unresectable liver cancer. *World J Surg* 1995;19:807-13.
30. Houben KW, McCall JL. Liver transplantation for hepatocellular carcinoma in patients without underlying liver disease: a systematic review. *Liver Transplantation and Surgery* 1999;5:91-95.
31. Neuhaus P, Jonas S, Bechstein WO. Hepatoma of the liver, resection or transplantation ? *Langenbeck's Arch Surg* 2000;385:171-78.
32. Chiappa A, Zbar A, Audisio RA, et al. Emergency liver resection for ruptured hepatocellular carcinoma complicating cirrhosis. *Hepatogastroenterology* 1999;46:1145-50.
33. Adson MA. Primary hepatocellular cancers: Western experience. In *Surgery of the Liver and Biliary Tract* (2nd ed.), Blumgart LH editor. Edinburgh, Churchill Livingstone 1988:1153-65.
34. Iwatsuki S, Starzl TE. Personal experience with 411 hepatic resections. *Ann Surg* 1988;208:421-34.
35. Ringe B, Pichlmayr R, Wittekind C, et al. Surgical treatment of HCC: experience with liver resection and transplantation in 198 patients. *World J Surg* 1991;15:270-85.



HCC cirrhotic liver

Chapter VII

Interstitial laser coagulation with temporary hepatic artery occlusion for patients with cirrhosis and irresectable hepatocellular carcinoma

Br J Surg 2003;90:950-955

ABSTRACT

Background: To determine the degree of local control of hepatocellular carcinoma (HCC) in patients with cirrhotic liver disease when treated with ultrasound guided interstitial laser coagulation (ILC) with temporary hepatic artery occlusion.

Methods: Twenty-four HCC tumours in 16 patients were treated. Follow-up examination was by CT or MRI every 3 months.

Results: Nineteen out of 24 tumours showed complete necrosis immediately after treatment. In these 19 lesions, there was no tumour recurrence during follow-up (mean 14 months, median 12 months). No effect on liver function was observed after one week and there was no mortality. In 13 of 16 patients, new HCC foci developed at other sites.

Conclusion: Percutaneous ILC combined with temporary hepatic artery occlusion during a single session is effective local treatment for HCC nodules < 5cm. However, new HCC lesions develop in the majority of patients and this underscores the need for adjuvant therapy or repeated treatment in these patients.

INTRODUCTION

Hepatocellular carcinoma (HCC) is one of the most common cancers in men. Its world-wide annual incidence has been estimated to be 250.000 to 1 million ¹ and more than 1 million death per year occur world-wide ². In North America and several European countries, HCC is uncommon and the estimated death rate is less than 5/100.000/year ³. In the Netherlands the incidence rates for liver cancer are among the lowest in the world ⁴. However, its incidence increases in low-endemic areas, as has been reported for the United Kingdom ⁵, France ⁶ and the United States ⁷. Surgery is the gold standard as a treatment for HCC, but a partial hepatectomy is only an option in up to 40% of patients ⁸. Several other treatment modalities have been developed ⁹, one of which is percutaneous interstitial laser coagulation (ILC). A few studies have reported that this procedure is virtually free of significant side-effects and an effective treatment for patients with a nonresectable HCC ¹⁰⁻¹². Further refinement is needed to achieve elimination of viable tumour cells at the tumour host interface. To enhance the efficiency of ILC, experimental studies in a pig model found that if the bloodflow to the liver was temporarily interrupted the coagulated area was larger than without occlusion ¹³.

Based on these findings a prospective clinical study was initiated to assess the effectiveness of long-term local control after treatment with ILC with temporary hepatic arterial occlusion, in cirrhotic patients with HCC.

PATIENTS AND METHODS

Patient characteristics

None of the patients could have surgical resection because of anatomical restrictions (after previous surgery) or medical co-morbidity. The inclusion criteria for treatment with ILC were comparable with the surgical criteria. Patients with extra hepatic disease, more than 3 nodules or a diameter larger than 5 cm were excluded. To undertake a percutaneous approach the tumours had to be visible on ultrasound and triple phase CT-scan. All patients had underlying histologically documented liver cirrhosis. Underlying liver cirrhosis or portal hypertension was accepted if there was no ascites and Thromboplastin Time was at least 20%, International Normalised Ratio: < 2.

Treatment Technique

Three patients (= 5 lesions) were treated at laparotomy. The surgeon decided during operation that a resection was not possible. One patient was scheduled for a nephrectomy because of a Grawitz tumour and a hemihepatectomy because of HCC but because of the complicated nephrectomy, the surgeon selected for an ablation. The

remaining 13 patients (=19 lesions) were treated percutaneously. The patients were admitted to our hospital, one day before the procedure. They received low-molecular heparin 2500 IE subcutaneously. ILC was performed under general anaesthesia, and Heparin 5000 IE was administered intravenously. This was reversed with Protamine after the procedure. A single dose of 1500 mg Cefuroxim was given intravenously just prior the intervention. Analgesics were provided on request. ILC was performed using a neodymium-yttrium-aluminiumgranate laserlight ($\lambda = 1064\text{nm}$; Laserscope; Santa Clara, Calif., U.S). The power of the laserlight (6-20 W) and the time of exposure (6-12 min) were determined before the procedure and were tumour-diameter-dependent. In the experimental phase of this procedure on animals and resected liver specimen a reference table was constructed which combined the length of the fibertip, number of Watts and exposure time. One fiber (Cardiofocus), was enclosed in a transparent catheter and inserted into the tumour (3mm diameter; Powerapplicator; Somatex, Berlin, Germany). This catheter was irrigated with sterile saline to prevent carbonisation of the tip. The laserfiber tip was placed centrally in the tumour, under ultrasound guidance. The femoral artery was punctured in the groin and an occlusion-balloon-catheter was placed in the common hepatic artery by the radiologist. Just prior to laser application the intra-arterial balloon was inflated to occlude the arterial flow.

Follow-up

The safety of treatment with ILC was assessed at day 1 of clinical observation and monitored by routine laboratory tests, as previously reported¹⁴. The effectiveness in terms of local control was evaluated by means of triphasic, contrast-enhanced CT,

24 hours after the procedure and post-treatment follow-up was performed with triphasic, contrast-enhanced CT or MRI, every 3 months. The volume of the contrast-enhanced tumour was compared with the volume on the CT before the intervention^{15,16}. The part of tumour that had no contrast (compared with the first CT) was defined as the avascular zone. This was classified according the group of Amin^{15,16}: Grade 1 was 100% avascularity of the tumour (complete response), Grade 2: more than 50% avascularity and grade 3: less than 50% avascularity (Figure 1). The protocol was approved by the human study committee of the Erasmus Medical Centre

Table 1. Characteristics of the study population undergoing ILC

Number	16 patients
Gender	15 male / 1 female
Age (median/range) in years	64 (50 – 70)
Child-Pugh Classifications	10 Child-Pugh A 6 Child-Pugh B
No of Nodules	24
Size (median/range) in cm.	3.2 (2 - 6)

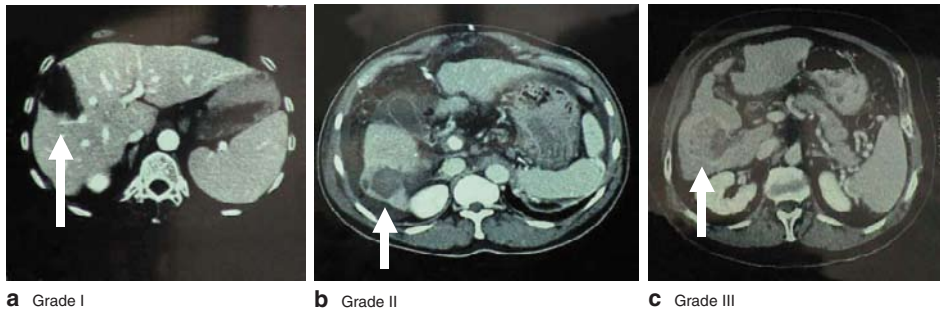


Fig. 1 Typical computed tomograms of tumours according to Amin grade. a Grade I, 100 per cent avascularity; b grade II, more than 50 per cent avascularity; c grade III, less than 50 per cent avascularity (arrows show the induced coagulative necrosis)

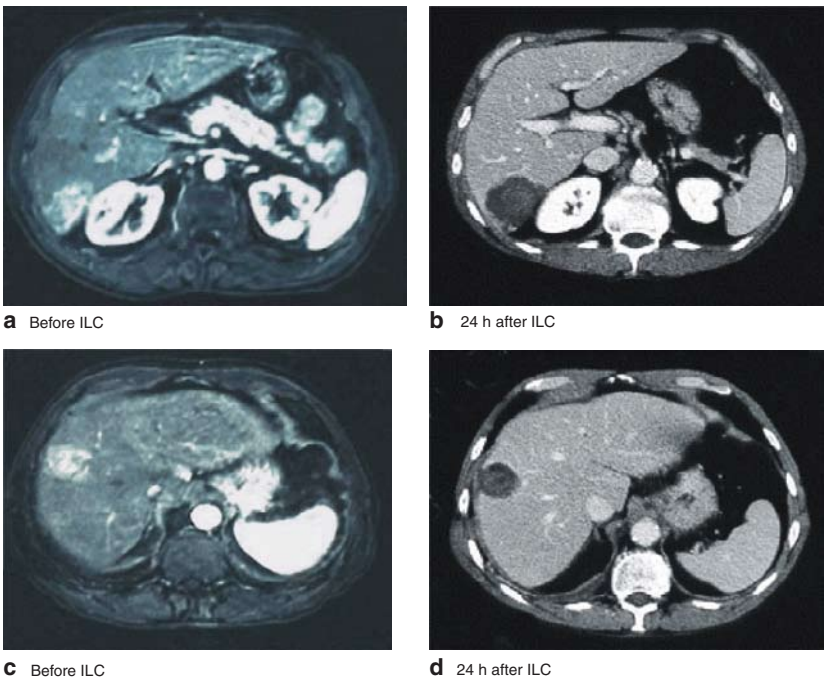


Fig. 2 Computed tomograms of two nodules of hepatocellular carcinoma in one patient. a and c Images obtained before interstitial laser coagulation (ILC) with temporary hepatic artery occlusion. b and d Nodules in a and c respectively 24 h after ILC with temporary hepatic artery occlusion

RESULTS

Between May 1998 and January 2001, 16 patients were treated (see table 1). All but 2 of the 24 lesions were smaller than 5 cm. All tumours had one treatment session, and in four patients two lesions were treated in one session.

Table 2.

Tumour diameter compared with initial effectiveness
(as measured 24 hours after ILC)

Tumour Diameter	Amin-grade*			Total
	I	II	III	
< 3 cm	8	0	1	9
3-4 cm	7	0	2	9
> 4 cm	4	2	0	6
Total	19	2	3	24

* Amin gradation: Grade I : 100% avascularity, Grade II : >50% avascularity,

Grade III : <50% avascularity (Figure 4 shows examples of Amin I-III).

Complications

Pain at the puncture side was the most common complication. No patient developed derangement of liver function after ILC. Two patients developed moderate fever (38 °C) without a focus. The temperature fell to normal within two days without specific treatment. One patient had referred pain to his right shoulder. One patient developed a pleural effusion and this complication required percutaneous drainage, requiring prolonged hospital stay. After 18 months this patient developed a new HCC and he was again successfully treated by ILC without complication.

Initial tumour response

Post-treatment CT showed a complete necrosis of the tumour (grade 1) in 19 out of 24 nodules. An example of this is shown in Figure 2. In three tumours there was no effect. In one session there was a false positioning of the tip of the ILC and in one session with two lesions the catheter broke because of a defect in the system and the session was halted after 5 minutes. The first patient mentioned was successfully treated by a second ILC session. The patient with two lesions refused another ILC session and was therefore treated by percutaneous ethanol injection. On an intention to treat basis, excluding the invalid performed sessions, complete necrosis occurred in 19 out of 21 nodules. Two patients with two nodules > 5 cm. had a grade 2 effect (>50% necrosis). Table 1 shows the effect of ILC in relation to the diameter of the tumour.

Long term control

In the 19 nodules with complete necrosis on CT scanning, no tumour recurrence was identified on follow-up CT scan/MRI or hepatectomy specimen (n=2) with a follow-up of 3 to 46 months and a mean of 14 months (median of 12 months). Eight patients died during follow-up and two patients underwent total hepatectomy and orthotopic liver transplantation. Thirteen patients developed new nodules and/or extrahepatic disease. Figure 3 shows the tumour free survival for patients who had

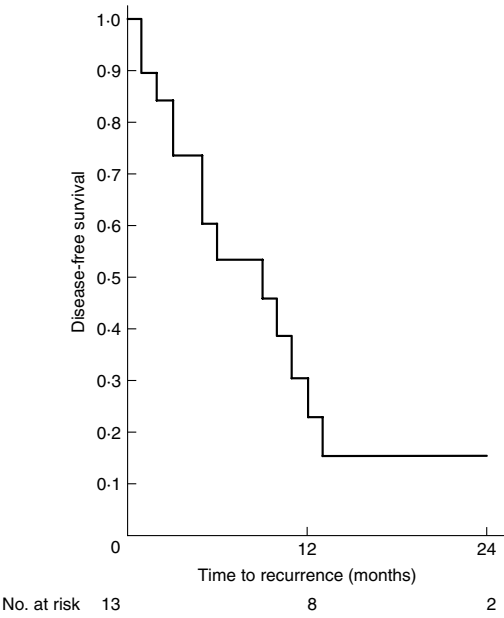
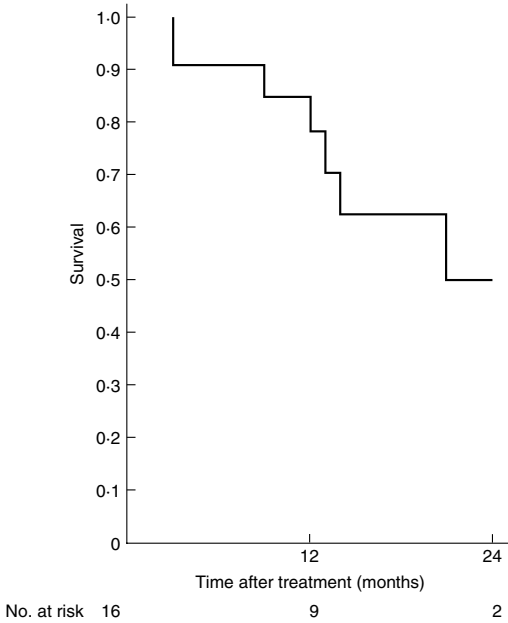


Fig. 3 Kaplan–Meier disease-free survival curve for patients who had complete necrosis after treatment

Fig. 4 Kaplan–Meier survival curve for all patients treated with interstitial laser coagulation



complete necrosis after treatment. Figure 4 shows the overall survival of all patients, after ILC treatment.

DISCUSSION

Because of the disadvantages of percutaneous ethanol injection alternative forms of percutaneous treatment have been developed, with RF and ILC being the most widely used. Both thermal methods induce a reproducible volume of necrosis¹⁷⁻¹⁹. RF has the disadvantage that it needs relatively large bore needles (14-17 G in diameter) and these are less handy than the fine needles that can be used for ILC (21-22 G in diameter), as previously described by Giorgio et al.¹¹. Also, RF needles are more expensive than ILC needles¹¹. Another advantage of ILC is that ILC is MRI compatible, so real time monitoring is possible.

ILC has mainly been described to treat patients with liver metastases from adenocarcinoma and HCC^{10,11,15}. Because almost all patients with HCC treated with a percutaneous ablation method have underlying liver cirrhosis, these groups must be separated in the evaluation ILC (or any other percutaneous ablation method). Because it has been suggested that tumour necrosis is facilitated by the surrounding cirrhotic tissue, resulting in larger ablations than would be expected²⁰. In addition, the residual capacity of the liver after percutaneous ablation may differ between cirrhotic patients and those with an otherwise normal liver.

Three previous studies described the treatment of HCC by ILC but none used temporary hepatic arterial occlusion. Cristophi and Muralidharan¹² described 8 patients with 18 lesions of HCC, with a size range of 3 – 7 cm. They had a 72% control of tumour size during follow-up. Vogl et al¹⁰ in their large series of 1914 lesions in 676 patients, included 16 patients with HCC lesions smaller than 5 cm. The results of the treated HCC lesions are not separately described in the article but in the whole group there was no local recurrence of tumour. Giorgio et al¹¹ published the largest series of 77 patients with 104 HCC nodules with a diameter range of 1-6.6 cm., mean 3.2 cm. During follow-up (mean 4.5 months) one recurrence occurred and in no case was intra-hepatic recurrence in different segments observed. Good local control of the tumour after ILC was also seen in the present series but in almost all cases new intra-hepatic recurrences occurred. An explanation for this striking difference is the relatively short follow-up, and the aetiology of the liver disease with multiple dysplastic nodules. Another explanation might be that post-treatment follow-up of patients was performed with US of the liver. The present study routinely used triple phase CT scans and dynamic contrast-enhanced MRI in these patients. Catalano et al²¹ found that at least half the HCC recurred after percutaneous ablation therapy, despite initial imaging and biopsy proven evidence of successful ablation²¹⁻²³. Others reported even higher recurrence rates of 81%²⁴ and 96%²⁵. Because of the probably

inferior quality of US as an imaging method after ablation the present local control effect after ILC with temporary arterial occlusion can not be compared with the results of the group Giorgio et al.¹¹ without temporary arterial occlusion.

The problem of subcutaneous seeding after diagnostic puncture of the liver in patients with HCC has been described²⁶. Llovet et al.²⁷ described neoplastic seeding in 12.5% patients with HCC after percutaneous RF ablation with cooled-tip needle. However, Livraghi²⁸ described in a series of 330 patients with 605 HCC lesions, only 0.6% neoplastic seeding. In the present study no patient had subcutaneous seeding. It is although reasonable to assume that a single session with one fiber minimizes the risk of complications (needle tract tumours and bleeding). The present data suggest that if temporary arterial occlusion was applied, a single session with one fiber was sufficient for tumours up to 5 cm. The major factor limiting the size of the thermal injury produced by ILC is hepatic perfusion. Various previous studies have shown preservation of viable cells surrounding larger vessels after ILC. The cells probably survive as the result of the cooling effect provided by the blood flow²⁹⁻³¹. In experimental studies^{13,32} hepatic inflow substantially reduces the size of lesion produced by ILC. In patients with severe liver cirrhosis, there is almost no portal circulation, and there may be even a retrograde flow³³.

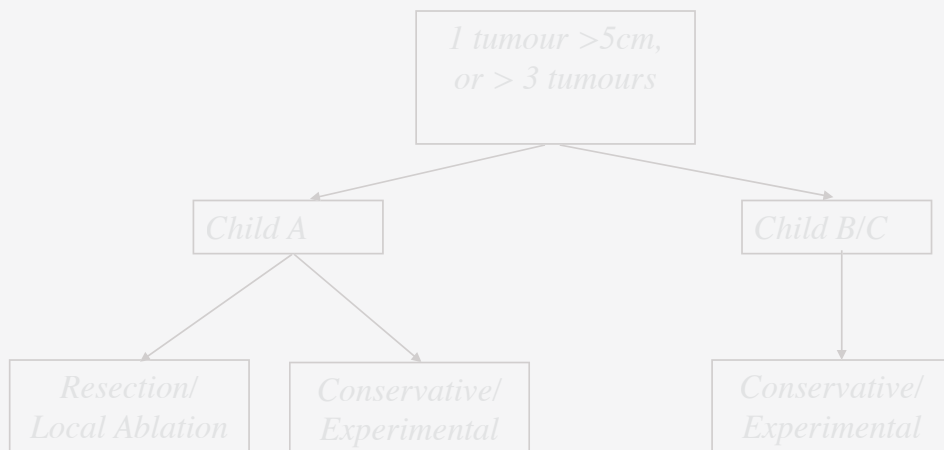
Vogl et al¹⁰ have published the largest group of patients treated with ILC and found the same percentage of complications. Pleural effusion was observed in 8% and in 33% of the patients they observed a temperature up to 38.4 °C. Pleural effusion can be a complication of the heating of normal structures adjacent to the tumour, in this case the pleural layers.

A single session of ILC with temporary hepatic artery occlusion results in good local control of small HCC nodules (< 5cm.) in patients with cirrhotic liver disease. However, the development of new liver lesions in 81% of patients stresses the need for adjuvant therapy or repeated sessions in these patients.

References

1. Simonetti RG, Camma C, Fiorello F, Politi F, D'Amico G, Pagliaro L. Hepatocellular carcinoma. A worldwide problem and the major risk factors. *Dig Dis Sci* 1991;**36**:962-72.
2. Rutsgl VK. Epidemiology of hepatocellular carcinoma. *Ann Int Med* 1988;**108**:390-1.
3. Ramsey WH, Wu GY. Hepatocellular carcinoma: Update on diagnosis and treatment. *Dig Dis* 1995;**13**:81-91.
4. Parkin DM, Muir CS. Cancer incidence in five continents. *IARC Sci Publ* 1992;**120**:45-173.
5. Taylor-Robinson SD, Foster GR, Arora S, Hargreaves S, Thomas HC. Increase in primary liver cancer in the UK, 1979-94. *Lancet* 1997;**350**:1142-3.
6. Deuffic S, Poynard T, Buffat L, Valleron AJ. Trends in primary liver cancer. *Lancet* 1998;**351**:214-5.
7. El-Serag HB, Mason AC. Rising incidence of hepatocellular carcinoma in the United States. *N Engl J Med* 1999;**340**:745-50.
8. Fong Y, Sun RL, Jarnagin W, Blumgart LH. An analysis of 412 cases of hepatocellular carcinoma at a western center. *Ann Surg* 1999;**229**:790-800.
9. Leyendecker JR, Dodd III. Minimally invasive techniques for the treatment of liver tumors. *Semin Liver Dis* 2001;**21**:283-91.
10. Vogl TJ, Eichler K, Straub R, Engelmann K, Zangos S, Woitaschek D *et al.* Laser-induced thermotherapy of malignant liver tumors: general principals, equipment(s), procedure(s) – side effects, complications and results. *Eur J Ultrasound* 2001;**13**:117-27.
11. Giorgio A, Tarantino L, de Stefano G, Farella N, Catalano O, Cusati B *et al.* Interstitial laser photocoagulation under ultrasound guidance of liver tumors: results in 104 treated patients. *Eur J Ultrasound* 2000;**11**:181-8.
12. Cristophi C, Muralidharan V. Treatment of hepatocellular carcinoma by percutaneous laser hyperthermia. *J Gastroenterol Hepatol* 2001;**16**:548-52.
13. Heisterkamp J, van Hillegersberg R, Mulder PGH, Sinofsky EL, IJzermans JNM. The importance of eliminating portal flow in producing large intra-hepatic lesions with interstitial laser coagulation. *Br J Surg* 1997;**84**:1245-8.
14. Heisterkamp J, van Hillegersberg R, de Man RA, Tilanus HW, Kuiper JW, Pattynama PM *et al.* Treatment of patients with irresectable tumours in the liver by percutaneous interstitial laser coagulation while the blood flow to the liver is interrupted. *Ned Tijdschr Geneesk* 2000;**144**:1542-8.
15. Amin Z, Bown SG, Lees WR. Local treatment of colorectal liver metastases: a comparison of interstitial laser photocoagulation (ILP) and percutaneous alcohol injection (PAI). *Clin Radiol* 1993;**48**:166-71.
16. Mumtaz H, Hall-Craggs MA, Wotherspoon A, Paley M, Buonaccorsi G, Amin Z *et al.* Laser therapy for breast cancer: MR imaging and histopathologic correlation. *Radiology* 1996;**200**:651-8.
17. Vogl TJ, Mack MG, Muller P, Phillip C, Bottcher H, Roggan A *et al.* Recurrent nasopharyngeal tumors: preliminary clinical results with interventional MR imaging-controlled laser-induced thermotherapy. *Radiology* 1995;**196**:725-33.
18. Vogl TJ, Mack MG, Scholz WR, Mueller P, Weinhold N, Philipp C *et al.* MR imaging guided laser-induced thermotherapy. *Min Invas Ther Allied Technol* 1996;**5**:243-8.
19. Leyendecker JR, Dodd III GD. Minimally invasive techniques for the treatment of liver tumors. *Semin Liver Dis* 2001;**21**:283-91.
20. Livraghi T, Goldberg SN, Lazzaroni S, Meloni F, Solbiati L, Gazelle GS. Small hepatocellular carcinoma: treatment with radiofrequency ablation versus ethanol injection. *Radiology* 1999;**210**:655-61.
21. Catalano O, Loianco R, Esposito M, Siani A. Hepatocellular carcinoma recurrence after percutaneous therapy: helical CT patterns. *Abdom Imaging* 2001;**26**:375-83.
22. Shiina S, Tagawa K, Niwa Y, Unuma T, Komatsu Y, Yoshiura K *et al.* Percutaneous ethanol injection therapy for hepatocellular carcinoma: results in 146 patients. *AJR Am J Roentgenol* 1993;**160**:1023-8.
23. Lencioni R, Bartolozzi C, Caramella D, Paolicchi A, Carrai M, Maltinti G *et al.* Treatment of small hepatocellular carcinoma with percutaneous ethanol injection: analysis of prognostic factors in 105 Western patients. *Cancer* 1995;**76**:1737-46.

24. Hasegawa S, Yamasaki N, Hiwaki T, Sako K, Komorizono Y, Baba Y *et al.* Factors that predict intra-hepatic recurrence of hepatocellular carcinoma in 81 patients initially treated by percutaneous ethanol injection. *Cancer* 1999;**86**:1682-90.
25. Tanikawa K, Majima Y. Percutaneous ethanol injection therapy for recurrent hepatocellular carcinoma. *Hepatogastroenterology* 1993;**40**:324-7.
26. Schotman SN, De Man RA, Stoker J, Zondervan PE, Yzermans JN. Subcutaneous seeding of hepatocellular carcinoma after percutaneous needle core biopsy. *Gut* 1999;**45**:626-7.
27. Llovet JM, Vilana R, Bru C, Biancchi L, Salmeron JM, Boix L *et al.* Increased risk of tumor seeding after percutaneous radiofrequency ablation for single hepatocellular carcinoma. *Hepatology* 2001;**33**:1124-9.
28. Livraghi T Letter to the editor. *Hepatology* 2001;**34**:608-9.
29. Matthewson K, Coleridge-Smith P, O'Sullivan JP, Northfield TC, Bown SG. Biological effects of intra-hepatic neodymium:yttrium-aluminium-garnet laser photocoagulation in rats. *Gastroenterology* 1987;**93**:550-7.
30. LaHaye M, Pow-Sang M, Orihuela E, Mothamedi M. Effect of temperature and flow rate of irrigant on coagulation necrosis in canine prostate treated with neodymium: YAG laser. *J Endourol* 1995;**9**:155-8.
31. Whelan WM, Wymann DR, Wilson BC. Investigations of large vessel cooling during interstitial laser heating. *Med Phys* 1995;**22**:105-15.
32. Heisterkamp J, Van Hillegersberg R, Zondervan PE, IJzermans JNM. Interstitial laser coagulation in porcine liver with portal inflow occlusion: Central versus peripheral lesions at long term. *J Vasc Interv Radiol* 1999;**10**:825-31.
33. Taourel P, Blanc P, Dauzat M, Chabre M, Pradel J, Gallix B *et al.* Doppler study of mesenteric, hepatic and portal circulation in alcoholic cirrhosis: relationship between quantitative Doppler measurements and the severity of portal hypertension and hepatic failure. *Hepatology* 1998;**28**:932-6.



HCC cirrhotic liver

Chapter VIII

Radiofrequency ablation in patients with primary and secondary hepatic malignancies

J Gastrointest Surg 2006;10(7):960-73

ABSTRACT

Background: The aims of this study were to assess the technical effectiveness of radiofrequency (RF) ablation in patients with primary or secondary hepatic malignancies, and to determine survival and complication rates.

Methods: This was a retrospective analysis of prospectively collected data of patients treated with RF-ablation and controlled for recurrence every 3 months by contrast enhanced computed tomography, or magnetic resonance imaging. The outcome is compared with a comprehensive review of data published in recent literature.

Results: Forty-seven patients underwent 50 RF-sessions for the ablation of 73 tumors. Local tumor progression was observed in 11 patients (23%). A tumor sized larger than 30 mm, a tumor load larger than 14 cm³, and a percutaneous approach were associated with a faster time to local tumor progression. At the end of a mean (\pm SD) follow-up period of 11.4 ± 7.5 months, 39 patients (83%) were alive, including eight patients with recurrent disease. The overall cumulative survival rates at 12 and 24 months were 87% and 70%, respectively.

Conclusion: In our center, RF-ablation can be safely performed to achieve adequate local control and survival rates. Time to local tumor progression was significantly related to initial size of the tumor and tumor load.

INTRODUCTION

Colorectal cancer (CRC) is a major cause of cancer related death in Europe. The cumulative lifetime risk in the Western world is approximately 5%, the incidence rate is 50/100,000. Nearly 50% of patients with colorectal carcinoma either have liver metastases at presentation (15-25%) or will subsequently develop them (20%)^{1, 2}. Without any treatment, the median survival after the detection of liver metastases is less than a year, depending on the extent of the disease at the time of diagnosis^{3, 4}. In contrast, resection of liver metastases from colorectal origin is associated with a 5-year survival rate of 30-50%, depending on the extent of liver involvement and provided that all disease can be removed safely⁴. Unfortunately, only 10-25% of the patients with colorectal liver metastases are amenable for liver resection, either because of tumor location, comorbidity or insufficient hepatic reserve^{5, 6}.

Hepatocellular carcinoma (HCC) is the fifth most common cancer in the world and the third most common cause of cancer mortality¹. In North America and in several European countries as well as in the Netherlands, HCC is uncommon with an incidence rate of less than 5/100,000 and a mortality rate of less than 5/100,000^{1, 2}. An increase of the incidence in low-endemic areas has been reported for the United Kingdom, France and The United States⁷⁻⁹. In contrast, Verhoef *et al* recently did not find any rising trend for the Netherlands¹⁰. In the last 10 years screening programs have resulted in a relative increase in the number of resectable cases, and the absolute number of resectable cases has increased as well. Surgical resection is the golden standard of therapy and appears to be the only effective way, aside from liver transplantation, to alter survival. However, due to advanced or decompensated liver cirrhosis, co-morbidity and multifocality of the tumors, only 10-37% of the patients with HCC are considered to be candidates for surgical resection^{11, 12}.

Thus, in approximately 80% of both patients with CRC and HCC, a partial liver resection is not possible and interest in other treatment modalities is growing. In our center, several locoregional treatment modalities have been studied, including isolated liver perfusion¹³, interstitial laser coagulation¹⁴, and radiofrequency ablation (RF-ablation). RF-ablation has several potential advantages over the other therapies, offering more comfort, less morbidity and severity due to its potential for minimal invasive application. Other advantages are reduced hospital stays (1-2 days), reduced costs, and the possibility of repeated treatment. To evaluate the outcome of RF-ablation in the treatment of primary and secondary hepatic malignancies at our department, we reviewed our records.

PATIENTS AND METHODS

We performed a retrospective analysis of data collected prospectively at the Erasmus MC - University Medical Center Rotterdam, The Netherlands, a tertiary referral hospital experienced in the field of interventional radiology. From July 2002 to December 2005 radiofrequency ablation was used to treat a total of 73 tumors in 47 consecutive patients with a primary or secondary hepatic malignancy. Assignment to RF-ablation and choice of treatment approach was determined by our institution's weekly multidisciplinary liver meeting, including the opinion of the intervention radiologist, the surgeon, the oncologist and the hepatologist. In our center RF-ablation was performed percutaneously, or as part of an open surgical procedure. A percutaneous approach was used whenever possible, but when the tumor was poorly visualised on US, or when the tumor was located in the high dome of the liver or near the liver capsule where percutaneous treatment could produce thermal injury to an adjacent visceral organ, ablation was performed via laparotomy. Also, some patients underwent a combined surgical hepatic resection and RF-ablation to treat multiple and bilobar disease.

All patients treated with RF-ablation were deemed to have unresectable hepatic disease based on tumor multifocality, the presence of advanced stage of cirrhosis with inadequate functional parenchymal reserve, high surgical risk, or surgical refusal. Tumors should be detectable by (intra-operative) ultrasound (US) and contrast enhanced spiral computed tomography (CT) or magnetic resonance imaging (MRI), and informed consent from the patient should be obtained. Patients were excluded if they had extrahepatic disease, uncontrollable ascites, tumor invasion of or a position too close to larger vessels or bile ducts, a life expectancy below six months, Child-Pugh C liver cirrhosis, a thromboplastin time below 40%, or a blood platelet count less than 50,000/ μ L. Baseline evaluation included a history and physical examination, serum laboratory tests, and imaging with US and contrast enhanced CT or MRI.

Technique

RF-ablation was performed primarily by an interventional radiologist under general anaesthetics. A 17-gauge internally cooled single or cluster RF electrode (Radionics, Burlington, Massachusetts, USA) was introduced into the hepatic malignancies by ultrasound guidance. The RF electrodes were attached to a 480-kHz RF generator (Radionics Cool-tipTM RF system, Burlington, Massachusetts, USA) capable of producing 200 W of power. During the procedure the applied current, power output, and tissue impedance were monitored constantly. After RF exposure, the cooling system was stopped to measure the local tissue temperature with the electrode tip. When temperature exceeded 60 °C, the ablation was considered adequate. At the end of

the procedure, the generator was reactivated as the RF-electrode was withdrawn to ablate the needle track and prevent tumor seeding.

Follow-up

Within 24 hours, a contrast enhanced CT was performed to assess any possible complications which might necessitate longer hospitalisation. The effectiveness in terms of local control was evaluated by means of triphasic contrast enhanced CT, carried out 6 weeks after the RF-procedure. Follow-up included imaging with contrast enhanced CT, or MRI when the treated lesions were not easily detected, as well as monitoring of the tumor-specific tumor markers α -fetoprotein (AFP) or carcinoembryonic antigen (CEA), every three months.

Definitions and statistical analysis

To assess the treatment effectiveness local tumor progression was scored, comprising both incompletely ablated tumor tissue (local failure) as well as progression of initially completely ablated tumors confirmed by contrast-enhanced CT or MRI. The local failures were included to avoid bias, because of the impossibility to differentiate between incompletely ablated tumor tissue that continued to grow, and new tumor foci growing at the original ablated site. Tumor size was scored in 3 dimensions to calculate an estimate of the tumor volume by using the equation for an ellipsoid (volume = $4/3\pi (x/2) (y/2) (z/2)$). The 30 mm cut-off point for tumor size corresponds to a 14 cm³ limit for tumor load per patient. Tumor load was defined as the sum of tumor volume per patient.

Time to first local tumor progression or time to death for each patient was modelled with a Kaplan-Meier survival analysis¹⁵. To avoid bias, the date of last imaging was used as the cut-off point for censoring patients. When a patient received radiotherapy at the initial ablation site, or chemotherapy in addition to an earlier ablation procedure, we considered the patient censored. Censoring was assumed independent to patient prognosis. If a patient had more than one tumor, only the largest tumor in diameter was included in the analysis so that each patient contributes only one observation to the data, and the sample size did not become incorrectly inflated due to repeated measurements within patients. If an ablated tumor showed local tumor progression, all of patients' other tumors were considered censored in this measure at that time.

Distribution of survival time and time to local tumor progression or death were analyzed in relation to the different variables collected. Univariate tests (Log Rank) were used to test for differences in these distributions by any single factor. The factors that solely appeared to have a significant impact were selected for entrance into a Cox proportional hazards model in order to analyze their effect on survival while adjusting for each other¹⁶. A backward elimination procedure was used for further covariate selection in the Cox proportional hazards model.

Student's *t*-test was used to perform pair wise comparisons between continuous variables. Categorical variables were tested using Fisher's Exact Test, or Pearson Chi-square test. Significance was determined at the 95% confidence interval (95% CI, $P < 0.05$). All data were collected in a computerized Microsoft Excel® database (Microsoft Inc., Redmond, Washington, USA). The analysis was performed using SPSS® (version 11.5) for Windows (SPSS Inc., Chicago, Illinois, USA) statistical software.

Review

To compare our data with the state of the art, a review was performed by searches in PubMed using the search terms "radiofrequency ablation", "colorectal liver metastases", "hepatocellular carcinoma", and "liver cancer". Reviews, letters, case reports, editorials, and articles not written in English were excluded. Because research and improvements on RF-ablation are rapidly evolving, we excluded papers published before January 2000 to make a fair comparison. Manual cross-referencing was done based on the bibliography of studies identified in the original searches. Papers were excluded if they were duplicate publications or involved the treatment of 24 patients or fewer.

RESULTS

Patient and tumor characteristics

Between July 2002 and October 2005, 47 consecutive patients underwent ablation for 73 primary and secondary hepatic malignancies. Of these, 30 (64%) were men and 17 (36%) were women, with a mean (\pm SD) age of 60.7 ± 12.0 years (range, 32.8-81.2 years). Hepatocellular carcinoma was diagnosed in 22 patients and colorectal liver metastases in 21 patients, of whom 17 received chemotherapy prior to the RF treatment (90% were responder). Four patients were diagnosed with either a gastrinoma, medullar thyroid carcinoma, carcinoid cancer or adrenal cell carcinoma. Fifty ablations were performed via 27 ultrasound-guided percutaneous procedures and 23 intra-operative procedures. Fifteen of them were treated in combination with simultaneous partial liver resection, cholecystectomy to prevent gallbladder damage, or both. Three patients underwent a sequential ablation for either remnant tumor tissue (2) or intra-hepatic progressive liver disease (1).

Of the 73 treated tumors, 31 (42%) were HCC and 32 (44%) were metastases from malignancies of the colon and rectum. Other metastatic tumors included four adrenal cell carcinomas, three gastrinomas, two medullar thyroid carcinomas, and one carcinoid tumor. RF-ablation was used to treat an average of 1.6 tumors per patient (range, 1-4) with a mean (\pm SD) size of $22 \text{ mm} \pm 12 \text{ mm}$ (range, 6-80 mm). The average (\pm SD) hospital stay was 1.3 ± 0.8 days (median, 1day; range, 0-4 days) for patients

treated percutaneously, and 12.4 ± 9.1 days (median, 11 days; range, 5-36 days) for patients treated in combination with resection.

Local tumor progression

Post-treatment contrast enhanced spiral CT at 6 weeks showed complete ablation in 44 of 47 patients (94%) and in 70 of 73 tumors (96%). In 2 of 3 patients with residual viable tumor tissue a sequential ablation was performed, showing complete response on post-treatment imaging.

During a mean (\pm SD) follow-up period of 11.4 ± 7.5 months (range, 4-35 months), 11 of 47 patients (23%) developed local tumor progression confirmed by contrast-enhanced CT or MRI. Demographics of patients in which local control was achieved, or who developed a local tumor progression, are shown in Table 1. Mean (\pm SD) actuarial survival time until local tumor progression was 26 ± 2.3 months (95% CI: 22-31 months). The median time until local tumor progression occurred was not measurable with the Kaplan-Meier method due to the small number of events observed. However, the Kaplan-Meier estimated local tumor progression rate at 6 months for all patients was 24%. Only one local tumor progression was observed after six months (10 months). Time to local tumor progression, stratified by tumor histology showed no significant differences (Fig. 1).

When tumor size was treated as a continuous variable, Cox regression showed that time to local tumor progression was significantly related to size of the tumor with a hazard ratio (HR) of 1.071 and a 95% CI of 1.024-1.120 ($P = 0.002$). Stratified by HCC and metastatic tumors, Cox regression showed a significant relation between time to local tumor progression and tumor size with a hazard ratio (HR) of 1.065 and a 95% CI of 1.016-1.116 ($P = 0.009$). Having a tumor sized larger than 30 mm was significantly

Table 1. Comparison of demographics and baseline characteristics of patients with or without local tumor progression

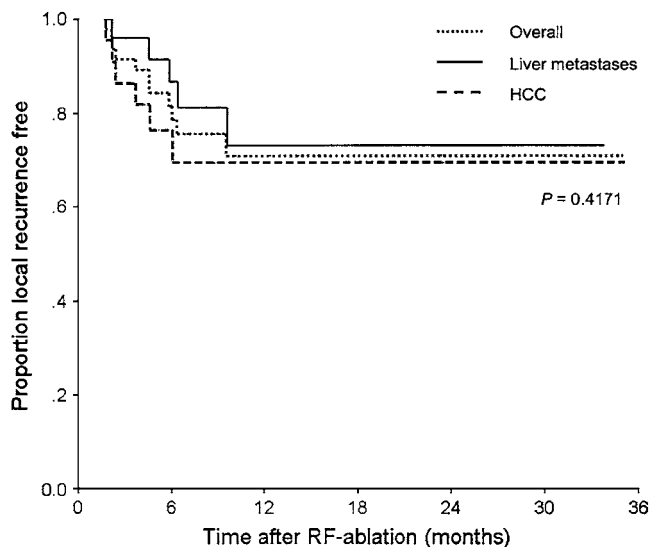
	Local control (n = 36)	Local tumor progression (n = 11)	P value
Age in years (mean \pm SD)	59.5 \pm 12.9	64.5 \pm 7.9	0.133* (NS)
Sex ratio (male:female)	24:14	6:3	0.486* (NS)
Number of tumors	62	11	
Number of tumors per patient (mean \pm SD)	1.6 \pm 1.0	1.5 \pm 1.2	0.753* (NS)
Tumor histology of patients (tumors)			0.495† (NS)
HCC	16 (25)	6 (6)	
CRC	16 (27)	5 (5)	
Other	4 (10)	0 (0)	
RF approach			0.036‡
Percutaneous	15	9	
Open	21	2	
Index tumor size in mm (mean \pm SD)	20 \pm 9.1	32 \pm 19	0.001*
Mean (\pm SD) tumor volume in cm ³	8.2 \pm 11	26 \pm 43	0.029*
Index AFP count in μ g/L (mean \pm SD)	433 \pm 830	2112 \pm 3452	0.084* (NS)
Index CEA count in μ g/L (mean \pm SD)	27.4 \pm 39.3	10.7 \pm 10.5	0.181* (NS)

AFP 5 a-fetoprotein; CEA 5 carcinoembryonic antigen; NS 5 not significant.

*Student's t-test.

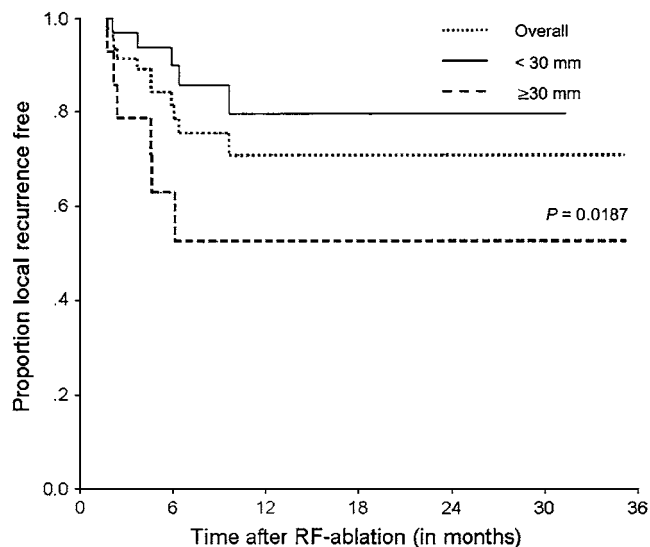
†Pearson chi-square test.

‡Fisher's exact test.



No. at risk							
Overall	47	28	12	7	3	3	0
Liver metastases	25	17	7	2	1	1	0
HCC	22	11	5	5	2	2	0

Fig. 1. Time to local tumor progression by number of patients, stratified by tumor histology.



No. at risk							
Overall	47	28	12	7	3	3	0
< 30 mm	33	22	10	5	1	1	0
≥ 30 mm	14	6	2	2	2	2	0

Figure 2 Time to local tumor progression by number of patients, stratified by tumor diameter

associated ($P = 0.0284$) with a faster time to local tumor progression with a HR of 3.831 and a 95% CI of 1.153-12.736. Survival curves for patients until local tumor progression occurred stratified by tumor diameter are shown in **Fig 2**. Both curves differ statistically significant from each other with a Log Rank statistic of 5.53 (1 df) and a P -value of 0.0187.

Tumor load per patient was also significantly related to local tumor progression with a HR of 1.040 and a 95% CI of 1.012-1.069 ($P = 0.0052$). Again, after stratification by HCC and metastatic tumors, Cox regression showed a significant relation between tumor load per patient and local tumor progression with a HR of 1.040 and a 95% CI of 1.012-1.069 ($P = 0.0052$). Patients with a tumor load larger than 14 cm³ significantly developed ($P = 0.0459$) an earlier local tumor progression with a HR of 3.366 and a

Table 2. Correlation between increasing tumor markers and onset of local recurrence

		Local tumor progression		Odds Ratio	<i>P</i> value	95% CI
		No.	Yes			
HCC	AFP decreased	12	1	(ref)	0.023*	1.325–169.870
	AFP increased	4	5	15.000		
CRC	CEA decreased	10	1	(ref)	0.047*	1.048–169.557
	CEA increased	3	4	13.333		
Total	Marker decreased	23	2	(ref)	0.001*	2.569–85.107
	Marker increased	7	9	14.786		

Ref [reference.

*Fisher's exact test.

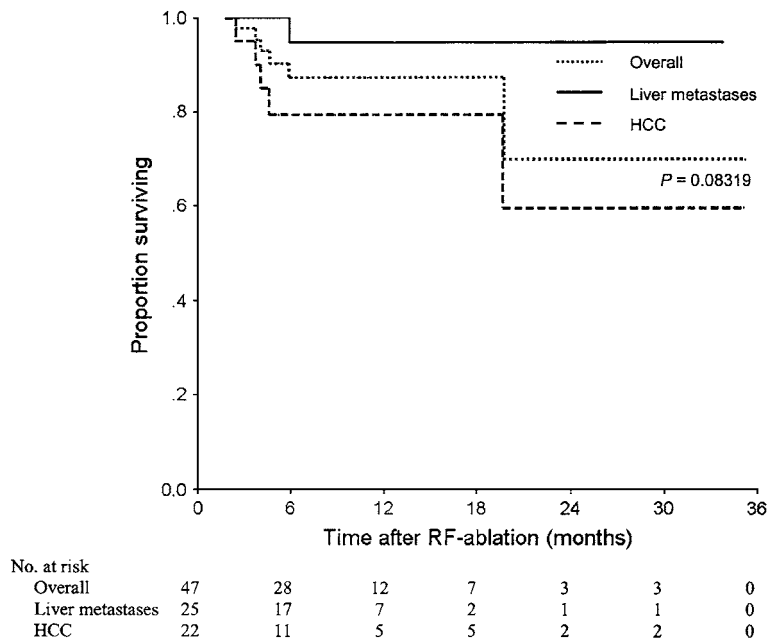


Figure 3 Time to local tumor progression by number of patients, stratified by tumor histology

Table 3 Results of studies using RF as a treatment modality for hepatocellular carcinoma.

Hepatocellular carcinoma (HCC)							
	origin approach	tum [pts]	tumor size (in mm)	follow-up time (in months)	local tumor progression	survival rates	complications
Livraghi ¹³⁸ Radiology 2000 Italy	HCC perc: all	126 [114] mean: 1.1 range: 1-3	mean: 54 range: 31-95	mean: 10.2 range: 5-30	pts: - tum: 66 (52)	1 yr: - 2 yr: - 3 yr: -	minor: 5 (4.4) major: 2 (1.8) death: 1 (0.9) total: 8 (7.0)
Curley ²⁸ Ann Surg 2000 Italy & USA	HCC perc: 76 lap: 31 open: 3	149 [110] mean: 1.4 range: 1-4	perc: mean: 28±8 open: mean: 46±17	median: 19 range: -	pts: 4 (3.6) tum: -	1 yr: - 2 yr: - 3 yr: -	minor: 7 (6.4) major: 7 (6.4) death: 0 (0) total: 14 (13)
Buscarini ²⁷ Eur Radiol 2001 Italy	HCC perc: all	101 [88] mean: 1.1 range: 1-3	All ≤35	mean: 34 range: 2-73	pts: 12 (14) tum: -	1 yr: 89 3 yr: 62 5 yr: 33 median: 48mo	minor: 14 (16) major: 2 (2.3) death: 0 (0) total: 16 (18)
Guglielmi ¹³⁷ Hepatogastroenterol 2003 Italy	HCC perc: all	65 [53] mean: 1.2 range: -	mean: 40±13 range: 10-70	mean: 18 range: 8-41	pts: - tum: 4 (6.2)	1 yr: 87 2 yr: 63 3 yr: 45	minor: 11 (21) major: 0 (0) death: 0 (0) total: 11 (21)
Harrison ³⁰ J Am Coll Surg 2003 USA	HCC perc: 46 open: 4	54 [50] mean: 1.1 range: 1-2	median: 35 range: 10-120	median: 16 range: 1-28	pts: 18 (36) tum: -	1 yr: - 2 yr: - 3 yr: -	minor: - major: - death: - total: -
Giovannini ²⁹ J Gastrointest Surg 2003 France	HCC perc: all	71 [56] mean: 1.3 range: 1-3	mean: 41 range: 8-60	mean: 20 range: 6-36	pts: 8 (14) tum: -	1 yr: 96 2 yr: 94 3 yr: 94 mean: 36mo	minor: 2 (3.6) major: - death: - total: 2 (3.6)
Choi ³⁶ Radiology 2004 Korea	HCC perc: all	53 [45] mean: 1.2 range: 1-2	mean: 21 range: 8-40	mean: 23 range: 10-40	pts: - tum: 11 (21)	1 yr: 82 2 yr: 72 3 yr: 54	minor: - major: - death: - total: -
Lam ³¹ Br J Surg 2004 China	HCC perc: 18 open/lap: 33	70 [51] mean: 1.4 range: -	<30: 25 pts 30-50: 17 pts >50: 9 pts	mean: - range: -	pts: 18 (35) tum: -	1 yr: 73 1½ yr: 61 2 yr: -	minor: - major: - death: 1 (2.0) total: -

Hepatocellular carcinoma (HCC)							
	origin approach	tum [pts]	tumor size (in mm)	follow-up time (in months)	local tumor progression	survival rates	complications
Vivarelli ³³ Ann Surg Oncol 2004 Italy	HCC perc: all	- [79] mean: - range: -	≤30: 22 pts >30: 57 pts	mean: 15.6±11.7 range: -	pts: 12 (15) tum: -	1 yr: 78 2 yr: - 3 yr: 33	minor: - major: - death: 0 (0) total: -
Xu ³⁹ Clin Radiol 2004 China	HCC perc: 43 microwave: 54	190 [97] mean: 2 range: 1-5	mean: 25±12 range: 9-88	mean: 27.4 range: 2-53	pts: - tum: 18 (9.5)	1 yr: 76 2 yr: 59 3 yr: 50 mean: 32mo	minor/major: 9 (9.0) death: 1 (1.0) total: 10 (10)
Lin ³⁵ Gastroenterology 2004 Taiwan	HCC perc: all	69 [52] mean: 1.3 range: 1-3	mean: 29±8 range: 10-40	mean: 24.5±11.3 range: -	pts: 7 (14) tum: 8 (12)	1 yr: 90 2 yr: 82 3 yr: 74	minor/major: 4 (7.7) death: 0 (0) total: 4 (7.7)
Tateishi ³² § Cancer 2005 Japan	HCC perc:	2140 [664] mean: 3.2 range: -	mean: 26 range: 8-97	median: 27.6 range: 2.0-61	2.4% at a median follow-up of 19 months	1 yr: 95 2 yr: 86 3 yr: 78 4 yr: 67 5 yr: 54	minor: 17 (2.6) major: 40 (6.0) death: 0 (0) total: 57 (8.6)
Lencioni ³⁴ Radiology 2005 Italy	HCC perc: all	240 [187] mean: 1.3 range: 1-3	mean: 28±7 range: 15-50	mean: 24±21 range: 3-78	pts: 38 (20) tum: 41 (17)	1 yr: 97 2 yr: 89 3 yr: 71 4 yr: 57 5 yr: 48 median: 57	minor: 9 (4.8) major: 3 (1.6) death: 0 (0) total: 12 (6.4)
De Meijer Current study 2005 The Netherlands	HCC perc: 15 open: 7	31 [22] mean: 1.4 range: 1-4	mean: 31±16 range: 14-80	mean: 10±9.5 range: 2-35	pts: 6 (27) tum: 6 (19)	1 yr: 79 2 yr: - 3 yr: -	minor: 3 (14) major: 0 (0) death: 0 (0) total: 3 (14)

- = not given / tum = tumor(s) / pts = patient(s) / yr = year(s) / mo = month(s)

perc = percutaneous / open = intra-operative / lap = laparoscopic / microwave = microwave ablation

Numbers in parentheses refer to percentages.

§ for the analysis of local recurrence and survival rates, only patients who received RF-ablation as the initial treatment for HCC were included.

95% CI of 1.022-11.079. The survival curves which are not shown were significantly different with a Log Rank statistic of 4.49 (1 df) and a *P*-value of 0.0341.

Increasing AFP and CEA levels during follow-up were significantly associated with local tumor progression in patients with HCC (OR 15.000, *P* = 0.023) and CRC (OR 13.333, *P* = 0.047), respectively (Table 2). Tumor markers were obtained in all patients

Table 4 Results of studies using RF as a treatment modality for colorectal liver metastases.

Colorectal carcinoma liver metastases (CRC)							
	origin approach	tum [pts]	tumor size (in mm)	follow-up time (in months)	local tumor progression	survival rates	Complications
Solbiati ⁴³ Radiology 2001 Italy	CRC perc: all chemo: 84	179 [117] mean: range: 1.5 range: 1-4	mean: 28±12 range: 6-96	mean: - range: 6-52	pts: 64 (55) tum: 70 (39)	1 yr: 93 2 yr: 69 3 yr: 46 median: 36mo	minor: 1 (0.9) major: 1 (0.9) death: 0 (0) total: 2 (1.7)
Cheng ⁴⁷ Surg Endosc 2003 USA	CRC: lap: all chemo: 15	- [20] mean: 2.1±1.2 range: -	≤40: 14 pts >40: 6 pts mean: range: -	mean: 11.5±7.8 range: 1-38	pts: - tum: -	1 yr: - 2 yr: - 3 yr: - mean: 25±3.4	minor: - major: 0 (0) death: 0 (0) total: 0 (0)
Livraghi ⁴² Cancer 2003 Italy	CRC perc: all chemo: 70	134 [88] mean: 1.5 range: 1-3	mean: 21 range: 6-40	median: 28 range: -	pts: 35 (40) tum: 49 (37)	1 yr: - 2 yr: - 3 yr: -	minor: 2 (2.3) major: 1 (1.1) death: 0 (0) total 3 (3.4)
Oshowo ⁴⁶ Br J Surg 2003 UK	CRC perc: all chemo: 22	25 [25] mean: 1 range: -	mean: 30 range: 10-100	median: 37 range: 9-67	pts: - tum: -	1 yr: - 2 yr: - 3 yr: 53 median: 37mo	minor: 0 (0) major: 1 (4.0) death: 0 (0) total: 1 (4.0)
Abdalla ⁴⁰ Ann Surg 2004 USA	CRC: open: all chemo: -	110 [578] mean: 1.9 range: 1-8	median: 25 range: -	median: 21 range: 4-112	pts: 5 (8.8) tum: -	1 yr: 92 2 yr: 60 3 yr: 37 4 yr: 22 median: 25mo	minor: - major: - death: - total: -
Gillams ⁴¹ Eur Radiol 2004 UK	CRC perc: all chemo: 134	- [167] mean: 4.1 range: 1-27	mean: 39 range: 10-120	mean: 17 range: 0-89	pts: 72 (43) tum: -	1 yr: 71 3 yr: 21 5 yr: 14 median: 22mo	minor: 22 (13) major: 14 (8.4) death: 0 (0) total: 36 (22)
White ⁴⁴ Dig Surg 2004 UK	CRC perc: all chemo: 15	56 [30] mean: 1.9 range: -	median: 30 range: 8-70	median: 17 range: 3-37	pts: - tum: 22 (39)	1 yr: 75 2 yr: 45 3 yr: - median: 22mo	minor: 2 (6.7) major: 1 (3.3) death: 0 (0) total: 3 (10)
De Meijer Current study 2005 The Netherlands	CRC perc: 7 open: 14 chemo: 12	32 [21] mean: 1.5 range: 1-4	mean: 20±6.9 range: 6-35	mean: 8.3±4.4 range: 2-18	pts: 5 (24) tum: 5 (16)	1 yr: 95 2 yr: - 3 yr: -	minor: 0 (0) major: 0 (0) death: 0 (0) total: 0 (0)

- = not given / tum = tumor(s) / pts = patient(s) / yr = year(s) / mo = month(s)

perc = percutaneous / open = intra-operative / lap = laparoscopic / chemo = prior chemotherapy

Numbers in parentheses refer to percentages.

Table 5 Results of studies using RF as a treatment modality for both hepatocellular carcinoma and liver metastases.

Mixed tumor origin							
	origin: hcc crc oth approach:	tum size [pts]	tumor size (in mm)	follow-up time (in months)	local tumor progression	survival rates	complications
De Baere ¹⁸ ¶ AJR 2000 France	0 - - perc: 33 lap: 0 open: 21	100 [54] mean: 1.9 range: -	mean: 21±11 range: 5-42	mean: 13.7 range: 4-23	pts: 9 (16) tum: 9 (9.0)	1 yr: - 2 yr: - 3 yr: -	minor: 4 (7.4) major: 3 (5.6) death: 0 (0) total: 7 (13)
Siperstein ²¹ Ann Surg Oncol 2000 USA	4 18 20 lap: all	181 [43] mean: 4.2 range: 1-14	mean volume: 8.7±1.1 cm3 size range: 10-100	mean: 13.9 range: 5-38	pts: 12 (29) tum: 22 (12)	1 yr: - 2 yr: - 3 yr: -	minor: 0 (0) major: 0 (0) death: 0 (0) total: 0 (0)
Wood ²⁴ Ann Surg Oncol 2000 USA	11 37 36 perc: 18 lap: 27 open: 39	231 [84] mean: 2.8 range: -	median: 20 range: 3-90	median: 9 range: 1-27	pts: 15 (18) tum: -	1 yr: - 2 yr: - 3 yr: -	minor: 4 (4.8) major: 3 (3.6) death: 1 (1.2) total: 8 (9.5)
Bowles ²⁵ Arch Surg 2001 Hawaii	25 39 12 perc: 44 lap: 6 open: 26	328 [76] mean: 4.3 range: 1-14	median: 30 range: 10-180	mean: 15 range: -	pts: - tum: 30 (9.1)	1 yr: 80 2 yr: 50 3 yr: -	minor: 10 (13) major: 7 (9.2) death: 1 (1.3) total: 18 (24)
Wong ²³ Am J Surg 2001 USA	2 31 7 perc: 1 open: 39	122 [40] mean: 3.1 range: 1-10	mean: - range: -	median: 9.5 range: -	pts: 6 (15) tum: -	1 yr: - 2 yr: - 3 yr: - median: 9.5	minor/major: 8 (20) death: 0 (0) total: 8 (20)
Kosari ²⁶ J Gastrointest Surg 2002 USA	12 18 15 perc: - lap: - open: -	143 [45] mean: 3.2 range: -	mean: 20 range: -	median: 19.5 range: 6-34	pts: - tum: 11 (7.7)	1 yr: - 2 yr: - 3 yr: -	minor: 3 (6.7) major: 8 (18) death: 1 (2.2) total: 12 (27)

Table 5 Results of studies using RF as a treatment modality for both hepatocellular carcinoma and liver metastases.

Mixed tumor origin							
	origin: hcc crc oth approach:	tum [pts]	tumor size (in mm)	follow-up time (in months)	local tumor progression	survival rates	complications
Jiang ¹⁹ World J Gastroent 2002 China	21 12 3 perc: 20 open: 16	48 [36] mean: 1.3 range: -	mean: 25 range: 5-90	mean: 10 range: 1-24	pts: 6 (17) tum: -	1 yr: - 2 yr: - 3 yr: -	minor: 3 (8.3) major: 1 (2.8) death: 0 (0) total: 4 (11)
Bleicher ¹⁷ Ann Surg Oncol 2003 USA	21 59 73 perc: - lap: - open: -	447 [153] mean: 2.9 range: 1-13	mean: 29±16 range: 5-135	mean: 11 range: -	pts: 32 (21) tum: 52 (12)	1 yr: - 2 yr: - 3 yr: -	minor/major: 36 (24) death: 0 (0) total: 36 (24)
Pawlik ²⁰ Ann Surg Oncol 2003 USA	5 124 43 open: all	350 [172] mean: 2.0 range: -	mean: 18 range: 3-55	median: 21.3 range: -	pts: 8 (4.7) tum: 8 (2.3)	1 yr: - 2 yr: - 3 yr: - median: 45.5	minor: 0 (0) major: 1 (0.6) death: 0 (0) total: 1 (0.6)
Curley ⁴⁸ Ann Surg 2004 USA & Italy	206 258 144 perc: 226 open: 382	1225 [608] mean: 2.0 range: 1-12	mean: 27 range: 4-120	mean: - range: -	pts: - tum: -	1 yr: - 2 yr: - 3 yr: -	minor/major: 58 (9.5) death: 3 (0.5) total: 61 (10)
Tepel ²² Eur J Surg Oncol 2004 Germany	4 18 4 open: all	56 [26] mean: 2.5 range: -	mean: 39±26 range: -	mean: 14.6±9.2 range: 2-36	pts: 3 (12) tum: -	1 yr: 79 2 yr: - 3 yr: - median: 18	minor: 0 (0) major: 7 (27) death: 0 (0) total: 7 (27)
De Meijer Current study 2005 The Netherlands	31 32 10 perc: 24 open: 23	73 [47] mean: 1.6 range: 1-4	mean: 22±12 range: 6-80	mean: 11.5±7.5 range: 4-35	pts: 11 (23) tum: 11 (15)	1 yr: 87 2 yr: 70 3 yr: - mean: 28±2.8	minor: 6 (13) major: 0 (0) death: 0 (0) total: 6 (13)

- = not given / tum = tumor(s) / pts = patient(s) / yr = year(s) / mo = month(s)

perc or p. = percutaneous / open or o. = intra-operative / lap = laparoscopic

Numbers in parentheses refer to percentages.

[†] only those patients included in the analysis with a follow-up of at least four months

diagnosed with HCC, however, in three patients with CRC the CEA level was not measured at base line. None of these three patients developed a local recurrence.

Survival

At the end of follow-up, six patients (13%) had died of progressive disease and 41 patients (87%) were alive, including eight patients in which local tumor progression was observed. Mean (\pm SD) actuarial survival time until death was 28 ± 2.8 months with a 95% CI of 23-34 months and is shown in Fig. 3. Again, the median time was not yet reached. The overall cumulative survival rates at 12 and 24 months were 87% and 70%, respectively. Fig. 3 also shows the overall survival stratified by tumor histology. Differences in survival were not statistically significant with a *P*-value of 0.0831 (Log Rank = 3.00, 1 df).

Complications

In six patients (13%) a minor complication occurred, requiring no intervention or extension of hospital stay. Three patients developed some ascites, and in three other patients a small intrahepatic hematoma was found at the post-intervention spiral-CT. No major complications observed were observed, nor any mortality related to the RF-procedure.

DISCUSSION/CONCLUSION

Reports in literature on the use of RF-ablation are increasing. Although many favourable reports have encouraged the use of RF by both surgeons and radiologists, we do not advocate RF-ablation as an alternative, but rather as an adjunct to hepatic resection, which remains the golden standard for the treatment of hepatic malignancies. In our study, RF-ablation was used as an adjunct to resection in fifteen procedures. Eight patients were ablated during laparotomy, and percutaneous RF-ablation was the primary procedure in the remaining patients, who were poor candidates for surgery. It is essential that the technique of RF-ablation should be optimized before proper comparison with surgical resection can be initiated. One of the main issues to be addressed is the completeness of ablation, which was the primary endpoint in our study.

We observed a patient-based local tumor progression rate of 23% and a tumor-based local tumor progression rate of 15%. Compared with studies in patients with both primary and secondary hepatic malignancies in prior literature, our results showed a little more recurrences than the reported patient-based local tumor progression rates of 4.7-21%¹⁷⁻²⁴, and also more than the tumor-based local tumor progression rates of 2.3-12%^{17, 18, 20, 21, 25, 26} (Table 5). Compared with more homogeneous patient populations, we observe similar local tumor progression rates of 2.4-36%²⁷⁻³⁵ patient-based and 6.2-52%³⁴⁻³⁹ tumor-based for HCC (Table 3), and local tumor progression rates of 8.8-55%⁴⁰⁻⁴³ patient-based and 37-39%⁴²⁻⁴⁴ tumor-based for CRC (Table 4), respectively. We realise that it is difficult to compare studies on RF-ablation due to differences in patient selection, adjuvant treatment and approach. Nevertheless, this comparison raises the question whether it is justified to apply a treatment modality with these local tumor

progression rates to all patients. Given our results, we feel that RF should be used with caution for tumors larger than 30 mm in diameter. When applied, extra care should be taken to increase the local technical success. As local tumor progression usually occurs at the radial margins of the ablated tumor, it's essential to have a reliable monitoring of the ablation, especially when overlapping ablations are required to encompass both the tumor and an ablation margin. Currently, the main problem in monitoring is the absence of reliable real-time peroperative imaging techniques. This is also well illustrated by the statistical significantly higher local failure rate in patients treated percutaneously compared to patients who were treated intra-operative, because the latter benefitted by the availability of more accurate intra-operative US (Table 1).

A way to achieve adequate local control is the method presented by Tateishi *et al* in patients diagnosed with a HCC³². They inserted the RF electrode under real-time ultrasound guidance and performed a dynamic CT scan directly at the end of the session to evaluate the ablation effect. When the result was judged as incomplete, additional sessions were performed until complete ablation was achieved. They also performed transcatheter arterial embolisation at least 7 days prior to the RF treatment to occlude the arterial flow. This combination resulted in a very low local tumor progression rate of 2.4% during a median follow-up of 19 months, indicating that adequate local control can be achieved. With respect to the follow-up of patients treated with RF ablation, we found a statistically significant relation between the elevation of tumor markers and the onset of a local tumor progression. Although there are novel biomarkers coming up, and more advanced markers already in use, monitoring the tumor markers AFP and CEA still play a significant role besides routinely scanning for local, intrahepatic, or extrahepatic recurrences.^{45,46}

At the end of follow-up, six patients had died of progressive disease including three patients in which local tumor progression was observed. The first patient had a history of hepatitis C and liver transplantation, in which the virus recurred. The second patient died of progression of chronic obstructive pulmonary disease, and the third patient died of pulmonary metastases. Thus, in all three patients local tumor progression did not directly influenced survival.

In our study we observed 1 and 2-year survival rates of 87% and 70%, respectively. Although there was no significant difference in overall survival between patients with a primary or secondary hepatic malignancy, it appears that Figure 3 shows a ttbetter survival in patients with a hepatic metastasis. This finding may relate with the strict selection of patients with metastatic cancer who are candidate for RF-ablation in our center. As either local recurrence or death could both count as an event, the problem of dependent competing risks might arise. However, since all cases of local tumor progression occurred within six months and only one patient died before that time, the assumption was made that in our study dependency of competing risks did not play a role of significance, and that for the end point local tumor progression the patient who died could be properly considered censored at time of death. Also, when a patient was treated with chemotherapy (or radiotherapy) in addition to an earlier ablation procedure, we consid-

ered the patient censored at the date of last imaging to remain the ability to investigate the initial therapeutic efficacy of RFA. This possibly have lead to an underestimation of the survival analysis.

Because studies which include both patients with a primary or secondary hepatic malignancy rarely publish survival rates (Table 5), we can only compare our results with an earlier study by Bowles *et al*²⁵ showing similar 1 and 2-year survival rates of 80% and 50%, respectively. Although our study population was relatively small and the data was retrospectively collected, our findings are consistent with the literature. Considering all studies in Table 3, 4 and 5, 1 and 2-year survival rates ranged from 71-97%^{22, 25, 27, 29, 31-37, 39-41, 43, 44}, and 45-94%^{25, 29, 32, 34-37, 39, 40, 43, 44, 47}, for primary and secondary hepatic malignancies, respectively. Three and 5-year survival rates ranged from 21-94%^{27, 29, 32-37, 39-41, 43, 48}, and 14-54%^{27, 32, 34, 41}.

Cox regression showed no significant relation between tumor diameter, tumor histology, and overall survival.

Although RF has many advantages in the treatment of liver tumors, it has disadvantages and complications as well, ranging from 0-27%^{17-29, 32, 34, 35, 37-39, 41-44, 48-50}. A large systematic review of 1931 patients treated with RF-ablation from 1995 to 2002 by Mulier *et al*⁵¹ showed that major complications occurred in 7.1% of all patients. The most common complications were impairment of hepatic function, haemorrhage, infection and biliary damage. The most severe complication is treatment related death, occurring in 0-2.2%^{17-28, 31-33, 37-39, 41-44, 48-50}. Mulier *et al*⁵¹ published a death rate of 0.7%.

We recorded any adverse event related to the procedure. Major complications were defined as events that might lead to substantial morbidity, disability or mortality, or result in hospital admission or substantially lengthened hospital stay⁵². All other complications were considered minor. Our study showed no major complications. Only six minor complications (three small intrahepatic hematomas, and in three patients some ascites) were observed, requiring no intervention.

Radiofrequency ablation techniques have continued to evolve since the current study was conducted. Our results relate to currently available techniques and it is likely that with the development of new tumor ablation techniques, real-time imaging and new probes, even better results might be obtained. Current evidence suggests that in small tumors, RF can be performed with adequate local control and with few complications. Larger series and randomised clinical trials with other techniques and treatment algorithms are necessary to determine the exact role of radiofrequency ablation as a treatment modality for primary and secondary hepatic malignancies. Until then, proper selection of patients for RF treatment in experienced hepatobiliary centres with a multidisciplinary team should be advocated.

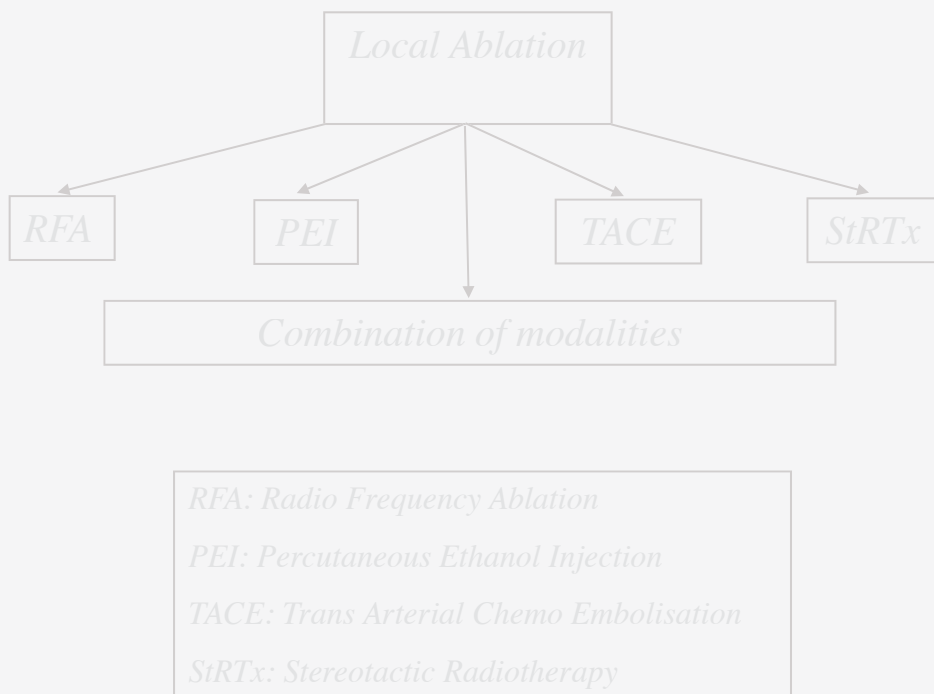
References

1. Levi F, Lucchini F, Negri E, Boyle P, La Vecchia C. Cancer mortality in Europe, 1995-1999, and an overview of trends since 1960. *Int J Cancer* 2004;**110**(2): 155-169.
2. Visser O, Siesling S, van Dijk JAAM. Incidence of cancer in the Netherlands 1999/2000. *Utrecht: Vereniging van Integrale Kankercentra* 2003: <http://www.ikcnet.nl> [24 April 2005].
3. Stangl R, Altendorf-Hofmann A, Charnley RM, Scheele J. Factors influencing the natural history of colorectal liver metastases. *Lancet* 1994;**343**(8910): 1405-1410.
4. Scheele J. Hepatectomy for liver metastases. *Br J Surg* 1993;**80**(3): 274-276.
5. Bruinvels DJ, Stiggelbout AM, Kievit J, van Houwelingen HC, Habbema JD, van de Velde CJ. Follow-up of patients with colorectal cancer. A meta-analysis. *Ann Surg* 1994;**219**(2): 174-182.
6. Cady B, Jenkins RL, Steele GD, Jr., Lewis WD, Stone MD, McDermott WV *et al.* Surgical margin in hepatic resection for colorectal metastasis: a critical and improvable determinant of outcome. *Ann Surg* 1998;**227**(4): 566-571.
7. Taylor-Robinson SD, Foster GR, Arora S, Hargreaves S, Thomas HC. Increase in primary liver cancer in the UK, 1979-94. *Lancet* 1997;**350**(9085): 1142-1143.
8. Deuffic S, Poynard T, Buffat L, Valleron AJ. Trends in primary liver cancer. *Lancet* 1998;**351**(9097): 214-215.
9. El-Serag HB, Mason AC. Rising incidence of hepatocellular carcinoma in the United States. *N Engl J Med* 1999;**340**(10): 745-750.
10. Verhoef C, Visser O, de Man RA, de Wilt JH, IJzermans JNM, Janssen-Heijnen ML. Hepatocellular carcinoma in the Netherlands incidence, treatment and survival patterns. *Eur J Cancer* 2004;**40**(10): 1530-1538.
11. Fong Y, Sun RL, Jarnagin W, Blumgart LH. An analysis of 412 cases of hepatocellular carcinoma at a Western center. *Ann Surg* 1999;**229**(6): 790-799; discussion 799-800.
12. Colella G, Bottelli R, De Carlis L, Sansalone CV, Rondinara GF, Alberti A *et al.* Hepatocellular carcinoma: comparison between liver transplantation, resective surgery, ethanol injection, and chemoembolization. *Transpl Int* 1998;**11 Suppl 1**: S193-196.
13. van Etten B, Brunstein F, van IMG, Marinelli AW, Verhoef C, van der Sijp JR *et al.* Isolated hypoxic hepatic perfusion with orthograde or retrograde flow in patients with irresectable liver metastases using percutaneous balloon catheter techniques: a phase I and II study. *Ann Surg Oncol* 2004;**11**(6): 598-605.
14. Verhoef C, Kuiper JW, Heisterkamp J, de Man RA, Pattynama PM, IJzermans JNM. Interstitial laser coagulation with temporary hepatic artery occlusion for patients with cirrhosis and irresectable hepatoma. *Br J Surg* 2003;**90**(8): 950-955.
15. Kaplan ES, Meier P. Nonparametric estimation from incomplete observations. *J Am Stat Assoc* 1958;**53**: 457-481.
16. Cox DR. Regression models and life tables. *J R Stat Soc* 1972;**B34**: 187-220.
17. Bleicher RJ, Allegra DP, Nora DT, Wood TF, Foshag LJ, Bilchik AJ. Radiofrequency ablation in 447 complex unresectable liver tumors: lessons learned. *Ann Surg Oncol* 2003;**10**(1): 52-58.
18. de Baere T, Elias D, Dromain C, Din MG, Kuoch V, Ducreux M *et al.* Radiofrequency ablation of 100 hepatic metastases with a mean follow-up of more than 1 year. *AJR Am J Roentgenol* 2000;**175**(6): 1619-1625.
19. Jiang HC, Liu LX, Piao DX, Xu J, Zheng M, Zhu AL *et al.* Clinical short-term results of radiofrequency ablation in liver cancers. *World J Gastroenterol* 2002;**8**(4): 624-630.
20. Pawlik TM, Izzo F, Cohen DS, Morris JS, Curley SA. Combined resection and radiofrequency ablation for advanced hepatic malignancies: results in 172 patients. *Ann Surg Oncol* 2003;**10**(9): 1059-1069.
21. Siperstein A, Garland A, Engle K, Rogers S, Berber E, Foroutani A *et al.* Local recurrence after laparoscopic radiofrequency thermal ablation of hepatic tumors. *Ann Surg Oncol* 2000;**7**(2): 106-113.
22. Tepel J, Hinz S, Klomp HJ, Kapischke M, Kremer B. Intraoperative radiofrequency ablation (RFA) for irresectable liver malignancies. *Eur J Surg Oncol* 2004;**30**(5): 551-555.
23. Wong SL, Edwards MJ, Chao C, Simpson D, McMasters KM. Radiofrequency ablation for unresectable hepatic tumors. *Am J Surg* 2001;**182**(6): 552-557.

24. Wood TF, Rose DM, Chung M, Allegra DP, Foshag LJ, Bilchik AJ. Radiofrequency ablation of 231 unresectable hepatic tumors: indications, limitations, and complications. *Ann Surg Oncol* 2000;**7**(8): 593-600.
25. Bowles BJ, Machi J, Limm WM, Severino R, Oishi AJ, Furumoto NL *et al.* Safety and efficacy of radiofrequency thermal ablation in advanced liver tumors. *Arch Surg* 2001;**136**(8): 864-869.
26. Kosari K, Gomes M, Hunter D, Hess DJ, Greeno E, Sielaff TD. Local, intrahepatic, and systemic recurrence patterns after radiofrequency ablation of hepatic malignancies. *J Gastrointest Surg* 2002;**6**(2): 255-263.
27. Buscarini L, Buscarini E, Di Stasi M, Vallisa D, Quaretti P, Rocca A. Percutaneous radiofrequency ablation of small hepatocellular carcinoma: long-term results. *Eur Radiol* 2001;**11**(6): 914-921.
28. Curley SA, Izzo F, Ellis LM, Nicolas Vauthey J, Vallone P. Radiofrequency ablation of hepatocellular cancer in 110 patients with cirrhosis. *Ann Surg* 2000;**232**(3): 381-391.
29. Giovannini M, Moutardier V, Danisi C, Bories E, Pesenti C, Delperro JR. Treatment of hepatocellular carcinoma using percutaneous radiofrequency thermoablation: results and outcomes in 56 patients. *J Gastrointest Surg* 2003;**7**(6): 791-796.
30. Harrison LE, Koneru B, Baramipour P, Fisher A, Barone A, Wilson D *et al.* Locoregional recurrences are frequent after radiofrequency ablation for hepatocellular carcinoma. *J Am Coll Surg* 2003;**197**(5): 759-764.
31. Lam CM, Ng KK, Poon RT, Ai V, Yuen J, Fan ST. Impact of radiofrequency ablation on the management of patients with hepatocellular carcinoma in a specialized centre. *Br J Surg* 2004;**91**(3): 334-338.
32. Tateishi R, Shiina S, Teratani T, Obi S, Sato S, Koike Y *et al.* Percutaneous radiofrequency ablation for hepatocellular carcinoma. An analysis of 1000 cases. *Cancer* 2005;**103**(6): 1201-1209.
33. Vivarelli M, Guglielmi A, Ruzzenente A, Cucchetti A, Bellusci R, Cordiano C *et al.* Surgical resection versus percutaneous radiofrequency ablation in the treatment of hepatocellular carcinoma on cirrhotic liver. *Ann Surg* 2004;**240**(1): 102-107.
34. Lencioni R, Cioni D, Crocetti L, Franchini C, Pina CD, Lera J *et al.* Early-stage hepatocellular carcinoma in patients with cirrhosis: long-term results of percutaneous image-guided radiofrequency ablation. *Radiology* 2005;**234**(3): 961-967.
35. Lin SM, Lin CJ, Lin CC, Hsu CW, Chen YC. Radiofrequency ablation improves prognosis compared with ethanol injection for hepatocellular carcinoma < or =4 cm. *Gastroenterology* 2004;**127**(6): 1714-1723.
36. Choi D, Lim HK, Kim MJ, Lee SH, Kim SH, Lee WJ *et al.* Recurrent hepatocellular carcinoma: percutaneous radiofrequency ablation after hepatectomy. *Radiology* 2004;**230**(1): 135-141.
37. Guglielmi A, Ruzzenente A, Battocchia A, Tonon A, Fracastoro G, Cordiano C. Radiofrequency ablation of hepatocellular carcinoma in cirrhotic patients. *Hepatogastroenterology* 2003;**50**(50): 480-484.
38. Livraghi T, Goldberg SN, Lazzaroni S, Meloni F, Ierace T, Solbiati L *et al.* Hepatocellular carcinoma: radio-frequency ablation of medium and large lesions. *Radiology* 2000;**214**(3): 761-768.
39. Xu HX, Xie XY, Lu MD, Chen JW, Yin XY, Xu ZF *et al.* Ultrasound-guided percutaneous thermal ablation of hepatocellular carcinoma using microwave and radiofrequency ablation. *Clin Radiol* 2004;**59**(1): 53-61.
40. Abdalla EK, Vauthey JN, Ellis LM, Ellis V, Pollock R, Broglio KR *et al.* Recurrence and outcomes following hepatic resection, radiofrequency ablation, and combined resection/ablation for colorectal liver metastases. *Ann Surg* 2004;**239**(6): 818-825; discussion 825-817.
41. Gillams AR, Lees WR. Radio-frequency ablation of colorectal liver metastases in 167 patients. *Eur Radiol* 2004;**14**(12): 2261-2267.
42. Livraghi T, Solbiati L, Meloni F, Ierace T, Goldberg SN, Gazelle GS. Percutaneous radiofrequency ablation of liver metastases in potential candidates for resection: the «test-of-time approach». *Cancer* 2003;**97**(12): 3027-3035.
43. Solbiati L, Livraghi T, Goldberg SN, Ierace T, Meloni F, Dellanoce M *et al.* Percutaneous radio-frequency ablation of hepatic metastases from colorectal cancer: long-term results in 117 patients. *Radiology* 2001;**221**(1): 159-166.
44. White TJ, Roy-Choudhury SH, Breen DJ, Cast J, Maraveyas A, Smyth EF *et al.* Percutaneous radiofrequency ablation of colorectal hepatic metastases - initial experience. An adjunct technique to sys-

temic chemotherapy for those with inoperable colorectal hepatic metastases. *Dig Surg* 2004;**21**(4): 314-320.

45. Goldstein MJ, Peterson Mitchell E. Carcinoembryonic antigen in the staging and follow-up of patients with colorectal cancer. *Cancer Invest* 2005;**23**(4): 338-351.
46. Yuen M-F, Lai C-L. Serological markers of liver cancer. *Best Pract Res Clin Gastroenterol* 2005;**19**(1): 91-99.
47. Adam R, Delvart V, Pascal G, Vaeleau A, Castaing D, Azoulay D *et al.* Rescue surgery for unresectable colorectal liver metastases downstaged by chemotherapy: a model to predict long-term survival. *Ann Surg* 2004;**240**(4): 644-657; discussion 657-648.
48. Oshowo A, Gillams A, Harrison E, Lees WR, Taylor I. Comparison of resection and radiofrequency ablation for treatment of solitary colorectal liver metastases. *Br J Surg* 2003;**90**(10): 1240-1243.
49. Cheng J, Glasgow RE, O'Rourke RW, Swanstrom LL, Hansen PD. Laparoscopic radiofrequency ablation and hepatic artery infusion pump placement in the evolving treatment of colorectal hepatic metastases. *Surg Endosc* 2003;**17**(1): 61-67.
50. Curley SA, Marra P, Beaty K, Ellis LM, Vauthey JN, Abdalla EK *et al.* Early and late complications after radiofrequency ablation of malignant liver tumors in 608 patients. *Ann Surg* 2004;**239**(4): 450-458.
51. Mulier S, Mulier P, Ni Y, Miao Y, Dupas B, Marchal G *et al.* Complications of radiofrequency coagulation of liver tumors. *Br J Surg* 2002;**89**(10): 1206-1222.
52. Goldberg SN, Grassi CJ, Cardella JF, Charboneau JW, Dodd GD, 2nd, Dupuy DE *et al.* Image-guided Tumor Ablation: Standardization of Terminology and Reporting Criteria. *Radiology* 2005;**235**(3): 728-739.



Chapter IX

Resection of extrahepatic Hepatocellular Carcinoma metastasis can result in long term survival

Acta Chir Belg 2005;105(5):533-6

ABSTRACT

Hepatocellular carcinoma (HCC) is one of the most common primary cancers in the world and the third most common cause of cancer mortality world-wide. Surgery is the gold standard in the treatment of patients with HCC. The prognosis is mainly determined by the underlying liver disease and recurrent rates. In the Western World, up to 30% of the patients with HCC have a non-cirrhotic liver. The main prognostic factor in this special group of patients are the recurrences. Most recurrences are intrahepatic, however, 30% of the recurrences are extrahepatic. The role of resection in case of intrahepatic recurrences is widely accepted, particularly in the non-cirrhotic liver. The role of resection in extrahepatic HCC recurrences is not well established and unknown among many physicians. We present two patients with HCC in a non-cirrhotic liver with extrahepatic recurrences and long term survival after resection. The corresponding literature support an aggressive approach in case of extrahepatic HCC recurrence in selected cases: Resectable metastasis, Preserved liver function, Absence of intracranial metastasis and Control of the primary tumour. Further research is warranted because of the limited number of reports and the absence of randomised trials.

INTRODUCTION

Hepatocellular carcinoma (HCC) is one of the most common primary cancers in the world (1) and the third most common cause of cancer mortality world-wide (2). In the Western World it is less common with e.g. incidence rates for males of 1.6/100.000/year and for females 0.3/100.000/year in the Netherlands (3). The treatment of choice is partial liver resection. The improved preoperative diagnostic modalities, which detect HCC at an earlier stage (4), result in a better selection of patients. Still a high number of recurrences after partial hepatic resection are found (5, 6, 7). While the majority of recurrences occur intrahepatic (5, 8, 9), extrahepatic recurrences are also seen (6). The preferred treatment of intrahepatic recurrences is repeat hepatectomy, which may offer long term survival (8, 10). When resection of an intrahepatic recurrence is not possible, local ablation methods and transarterial chemoembolization (TACE) have been applied successfully (11). The role of surgery for extrahepatic recurrence of HCC is not well established. We present two patients who have been treated surgically at our institution for extrahepatic recurrence of HCC and reviewed the corresponding literature.

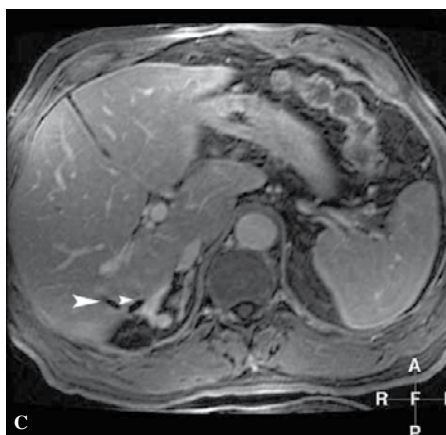
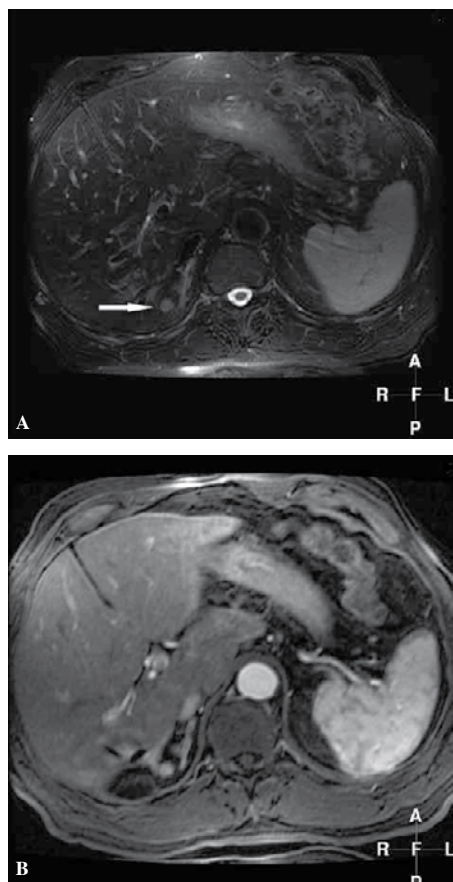
CASE REPORTS

Patient n° 1

A 74-year-old male was analysed at our hospital for a liver tumour found by coincidence. Magnetic resonance Imaging (MRI) showed a large lesion in segment 6 of the liver, suspect for HCC. There was no cirrhosis and no infection with Hepatitis B Virus (HBV) or Hepatitis C Virus (HCV). The alpha-fetoprotein (AFP) level was 206 µg. A resection of segment 6 and 7 and a partial resection of the diaphragm was performed in March 2000. Histology showed a HCC with a diameter of 9 cm with clear margins without infiltration of the diaphragm. The liver tissue was fibrotic, no cirrhotic tissue was found and microscopic vascular invasion was seen. During follow-up a MRI scan 14 months postoperatively showed a lesion in Gerota's fascia on the right side (Figure 1). This lesion was not seen on the MRI pre-operatively. AFP was 3 µg/l. A resection of the lesion was performed 15 months after the first resection and histology confirmed the diagnosis metastatic Hepatocellular carcinoma. To date, 44 months after resection of the extrahepatic metastasis and 59 months after partial liver resection the patient is still alive and well, and no new recurrence has been found.

Patient n° 2

A 39-year-old woman with a medical history of HBV and no cirrhosis or HCV, was admitted to our hospital for pain in the right upper quadrant of the abdomen. The AFP level was 23020 µg/l. Analysis showed an HCC, confirmed by biopsy, for which a right

**Fig. 1**

A. T2 weighted image of May 2001. The lesion (□) is visible ;
 B. Arterial phase, May 2001. The adrenal gland shows enhancement, as do the spleen and aorta, this is characteristic for the arterial phase. The lesion also shows enhancement. A combination of high signal intensity on T2 and intense arterial enhancement is typical for recurrent HCC in this patient ;
 C. Late phase : the lesion decreases in enhancement. Furthermore artefacts of the operationclips of the primary operation are visible (□).

hemihepatectomy was performed in October 1996. Histology showed an HCC with a diameter of 9.5 cm with central necrosis. No microscopic vascular invasion was found. After partial liver resection, AFP values returned to normal. After 11 months of follow-up, there was an increase of AFP to 560 $\mu\text{g/l}$. MRI revealed a possible metastasis in the thoracic wall, at the location of the biopsy. The lesion was excised and histology confirmed the diagnosis of a metastasis of HCC. After the excision the AFP level decreased to normal values. Sixty months after primary resection, a second rise of the AFP was found (10701 $\mu\text{g/l}$). A lesion in the lower abdomen was found on CT. A tumour, localised behind the right side of the uterus, was resected and the diagnosis HCC metastasis was confirmed by histology. To date, 101 months after partial liver resection and 41 months after resection of the intra-abdominal recurrence, the patient is still alive and well.

Table 1 Survival of patients with extrahepatic metastases of HCC treated with surgery according to the literature

Author	N° of patients	Location of extra-hepatic metastases	Survival
LO <i>et al.</i> (25)	12	Abdominal wall, Lung, Omentum, Peritoneum	Median survival : 19.7 months
FARGES <i>et al.</i> (10)	14	Bone, cerebral, pulmonary and abdominal wall	Median survival : 8 months
LAM <i>et al.</i> (26)	9	Pulmonary	Median survival : 42 months
ARIJ <i>et al.</i> (7)	8	Lung, Omentum, bone, spleen	5-year survival : 37.5 %
SHUTO <i>et al.</i> (27)	4	Adrenal	10, 20, 25 and 63 months survival
POON <i>et al.</i> (5)	10	Lung, diaphragm, lymphnode, abdominal wall, adrenal gland	Median survival : 44 months
MOMOI <i>et al.</i> (28)	13	Adrenal	5-year survival : 34 %
CHANG <i>et al.</i> (29)	25*	Intracranial	Median survival : 4 months*
GWAK <i>et al.</i> (30)	4	Pulmonary	29, 43, 54 and 72 months survival

* 8 patients underwent excision, 1 patient radiosurgery, 16 patients radiotherapy.

DISCUSSION

Most of the literature about HCC is coming from in the Eastern part of the World, where over 90% of the HCC patients have underlying liver cirrhosis. This is substantially lower in the Western World with up to 30% of HCC occur in a non-cirrhotic liver (12). The prognosis for this special group of patients is not as clearly described as that for patients with HCC in a cirrhotic liver. There are recent reports that describe the results of surgery in HCC patients without underlying liver cirrhosis (12 - 15). Usually these patients present with large tumours (median size between 8 and 10 cm are described) and 5-year survival rates have been reported between 42 and 68% after partial liver resection. These results appear to be better than those reported for HCC in the cirrhotic liver with comparable size. De novo tumor or local recurrence of HCC is the predominant cause of death following resection of HCC. Although much effort has been done to reduce the recurrence rates of HCC after partial liver resection, there are no (neo) adjuvant therapies of proven benefit (16). Microvascular infiltration is one of the main prognostic factors. In HCC associated with cirrhosis, tumor size has a clear relationship with microvascular infiltration. This correlation is not well established in the non-cirrhotic group (13). We will emphasize that large tumour size of HCC in non-cirrhotic liver is not a drawback for an aggressive approach. Intrahepatic recurrence of HCC without treatment results in poor survival. Farges et al reported a 1-, 3-, and 5 year survival of patients with intrahepatic metastases of respectively 20%, 4% and 0% (10). When a patient with intrahepatic recurrence of HCC is eligible for surgery these survival rates are respectively 75%, 46% and 30%. These numbers harbour a bias, because the patients were not randomised. What these numbers do display, is the fact that long term survival can be achieved after resection of intrahepatic HCC recurrences. If surgery is not possible in case of intrahepatic recurrences, nonsurgical procedures such as percutaneous ablation therapies and transcatheter arterial chemoembolization (TACE) are widely employed (11). In case of underlying liver cirrhosis, only a small portion of the patients are eligible.

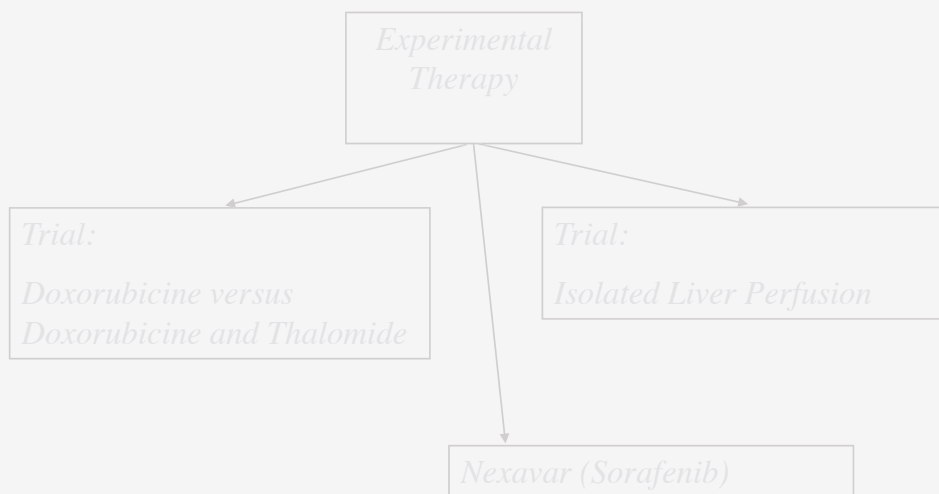
Because of the preserved liver function of patients with HCC in a non-cirrhotic liver, intrahepatic recurrence can be treated by TACE, local ablation or even resection. Therefore, this group of patients (HCC in a non-cirrhotic liver) might be the group of patients who may benefit the most from an aggressive management regarding extra-hepatic recurrences. Extrahepatic recurrence occurs in 30% of the patients (10). It has been reported that systemic chemotherapy for extrahepatic metastasis of HCC has unsatisfactory survival outcomes (17,18). Resection of isolated extrahepatic HCC metastasis has been advocated to obtain a possibility of long-term survival. The literature is scarce about this issue, possibly because extrahepatic disease is often considered to be a contraindication for any further treatment. Table 1 depicts nine studies reporting resection of extrahepatic recurrence in patients with HCC. This table shows that long-term survival can be achieved in selected cases. If we summarize the results of these studies, patients who may benefit from surgical resection are the patients with resectable extrahepatic metastasis, no intracranial metastasis and a compensated liver function. The primary hepatic tumor must be radical resected or must be under control. Partial pulmonary resections, spleen resections and adrenal resections (if necessary in combination with partial vena cava resections) have been described. Therefore, even when a vital organ is involved by a metastasis, long-term survival can be achieved by resection. In case of an AFP producing HCC, the sensitivity of screening with AFP has a high sensitivity (19) for the detection of recurrent HCC. An increasing level of circulating AFP may indicate the recurrence of HCC, though elevated levels of AFP can also be the result of an active hepatitis (20). If there is a suspicion of extrahepatic disease, subsequent extensive imaging should be done (CT thorax, MRI abdomen). The role of PET-scan in identifying intra-hepatic HCC is limited (21,22). Some reports displayed an additional role PET in identifying extrahepatic metastases (23, 24). However, the role of PET in metastatic HCC needs further validation.

When extrahepatic recurrence of HCC is found in patients without liver cirrhosis, the patient may be candidate for resection. Our two cases demonstrate that long-term survival can be achieved in patients with resection of an extrahepatic recurrence. The patients are alive, 59 and 101 months after the hepatic resection, 44 and 41 months after resection of the extrahepatic metastasis without recurrent disease. After reviewing the literature, surgery can be indicated for patients with extrahepatic recurrence of HCC if there is a preserved liver function, absence of intracranial metastasis and if complete tumor removal can be expected.

References

- Okuda K. Hepatocellular carcinoma. *J Hepatol* 2000;32 Suppl 1:225-37.
- Parkin DM, Bray F, Ferlay J, Pisani P. Estimating the world cancer burden: Globocan 2000. *Int J Cancer* 2001;94(2):153-6.
- Verhoef C, Visser O, de Man RA, de Wilt JHW, IJzermans JNM, Janssen-Heijnen MLG. HCC in the Netherlands: incidence treatment and survival patterns. *EJC* 2004;40:1530-8
- Hussain SM, Semelka RC, Mitchell DG. MR imaging of hepatocellular carcinoma. *Magn Reson Imaging Clin N Am* 2002;10(1):31-52, v.
- Poon RT, Fan ST, O'Suilleabhain CB, Wong J. Aggressive management of patients with extrahepatic and intrahepatic recurrences of hepatocellular carcinoma by combined resection and locoregional therapy. *J Am Coll Surg* 2002;195(3):311-8.
- Tung-Ping Poon R, Fan ST, Wong J. Risk factors, prevention, and management of postoperative recurrence after resection of hepatocellular carcinoma. *Ann Surg* 2000;232(1):10-24.
- Arii S, Monden K, Niwano M, Furutani M, Mori A, Mizumoto M, et al. Results of surgical treatment for recurrent hepatocellular carcinoma; comparison of outcome among patients with multicentric carcinogenesis, intrahepatic metastasis, and extrahepatic recurrence. *J Hepatobiliary Pancreat Surg* 1998;5(1):86-92.
- Sugimachi K, Maehara S, Tanaka S, Shimada M. Repeat hepatectomy is the most useful treatment for recurrent hepatocellular carcinoma. *J Hepatobiliary Pancreat Surg* 2001;8(5):410-6.
- Arii S, Teramoto K, Kawamura T, Okamoto H, Kaido T, Mori A, et al. Characteristics of recurrent hepatocellular carcinoma in Japan and our surgical experience. *J Hepatobiliary Pancreat Surg* 2001;8(5):397-403.
- Farges O, Regimbeau JM, Belghiti J. Aggressive management of recurrence following surgical resection of hepatocellular carcinoma. *Hepatogastroenterology* 1998;45 Suppl 3:1275-80.
- Chen WT, Chau GY, Lui WY et al. Recurrent hepatocellular carcinoma after hepatic resection: prognostic factors and long-term outcome. *EJSO* 2004;30:414-420.
- Verhoef C, de Man RA, Zondervan PE, Tilanus HW, IJzermans JNM. Good outcomes after resection of large hepatocellular carcinoma in the non-cirrhotic liver. *Dig Surg* 2004;21:380-386
- Lang H, Sotiropoulos GC, Doemland M, et al. Liver resection for hepatocellular carcinoma in non-cirrhotic liver without underlying viral hepatitis. *Br J Surg* 2005;92:198-202.
- Nagasue N, Ono T, Yamanoi A, et al. Prognostic factors and survival after hepatic resection for hepatocellular carcinoma without cirrhosis. *Br J Surg* 2001;88:515-522.
- Fong Y, Sun RL, Jarnagin W, et al. An analysis of 412 cases of hepatocellular carcinoma at a western centre. *Ann Surg* 1999;229:790-800
- Schwartz JD, Schwartz M, Mandeli J, Sung M. Neoadjuvant and adjuvant therapy for resectable hepatocellular carcinoma: review of the randomised clinical trials. *Lancet Oncol* 2002;3(10):593-603.
- Okasaka T, Okada S, Ishii H, et al. Prognosis of hepatocellular carcinoma patients with extrahepatic metastases. *Hepatogastroenterology* 1997;44:251-7
- Schwartz JD, Beutler AS. Therapy for unresectable hepatocellular carcinoma: review of the randomized clinical trials-II: systemic and local non-embolization-based therapies in unresectable and advanced hepatocellular carcinoma. *Anti-Cancer Drugs* 2004;15:439-452
- Gambaran-Gelwan M, Wolf DC, Shapiro R, Schwartz ME, Min AD. Sensitivity of commonly available screening tests in detecting hepatocellular carcinoma in cirrhotic patients undergoing liver transplantation. *Am J Gastroenterol* 2000;95(6):1535-8.
- Di Bisceglie AM, Hoofnagle JH. Elevations in serum alpha-fetoprotein levels in patients with chronic hepatitis B. *Cancer* 1989;64(10):2117-20.
- Verhoef C, Valkema RA, de Man RA et al. Fluorine-18 FDG imaging in hepatocellular carcinoma using positron coincidence detection and single photon emission computed tomography. *Liver* 2002;22:51-56.
- Sharlene A. Teefey, Charles C, et al Detection of Primary Hepatic Malignancy in Liver Transplant Candidates: Prospective Comparison of CT, MR Imaging, US, and PET. *Radiology* 2003;126:533-42
- Hain SF, Fogelman I Recent advances in imaging hepatocellular carcinoma: diagnosis, staging and response assessment: functional imaging. *Cancer J* 2004;10:121-7

24. Sugiyama M, Sakahara H, Torizuka T, et al. 18F-FDG PET in the detection of extrahepatic metastases from hepatocellular carcinoma. *J Gastroenterol* 2004;39:961-68.
25. Lo CM, Lai EC, Fan ST, Choi TK, Wong J. Resection for extrahepatic recurrence of hepatocellular carcinoma. *Br J Surg* 1994;81(7):1019-21.
26. Lam CM, Lo CM, Yuen WK, et al. Prolonged survival in selected patients following surgical resection for pulmonary metastasis from hepatocellular carcinoma. *Br J Surg* 1998;85:1198-1200
27. Shuto T, Hirohashi K, Kubo S, et al. Treatment of adrenal metastases after hepatic resection of a hepatocellular carcinoma. *Dig Surg* 2001;18:294-97
28. Momoi H, Shimahara Y, Terajima H, et al. Management of adrenal metastasis from hepatocellular carcinoma. *Surg Today* 2002;32:1035-41
29. Chang L, Chen YL, Kao MC. Intracranial metastasis of hepatocellular carcinoma: review of 45 cases. *Surg Neurol* 2004;62:172-77.
30. Kwak GY, Jung JO, Sung SW, Lee HS. Long-term survival after pulmonary metastectomy of hepatocellular carcinoma; treatment outcome or natural history. *Hepato-Gastroenterol* 2004;51:1428-33.



Chapter X

Identification of somatostatin receptors subtypes in human hepatocellular carcinomas: a clinical study.

Dig Surg 2008: in press



ABSTRACT

Background: The evidence on the efficacy of somatostatin analogues in the treatment of hepatocellular carcinoma (HCC) in humans is conflicting. Somatostatin receptors (SS-Rs) have been demonstrated in a variety of human tumors. At least 5 different human subtypes (SS-R subtype 1 – 5) have been cloned. All subtypes bind human somatostatin with high affinity, while somatostatin analogues bind with high affinity to SS-R subtype 2 (ssr_2)

Aim of the study: We investigated the ssr_2 expression in HCC and examined whether HCC's expressing ssr_2 are a distinct subgroup at the cell biological, clinical or pathological level.

Patients and Methods: We constructed a tissue micro-array and tested 45 human HCC's for ssr_2 expression and genetic alterations. The proliferative capacity of the tumours was determined with Ki67 immunostaining and the DNA ploidy status was measured by fluorescent in situ hybridization (FISH) with a chromosome 1-specific repetitive DNA probe. Expression of tumour suppressor genes (p16, p53 and Rb1) was measured by immunohistochemistry.

Results: Of 45 tumours, ssr_2 expression was detected in 30 tumours (67%). Age, gender, α -fetoprotein levels, tumour size, tumour grade and underlying liver disease of the ssr_2 positive tumours were not significantly different from the ssr_2 negative tumours. No correlation existed between ssr_2 expression and the immunoprofiles of the tumor suppressor genes, aneuploidy or proliferation.

Conclusion: In 67% of the patients with HCC, ssr_2 could be detected in the tumour. No clinical or pathological characteristics were specific for ssr_2 positive tumours and these are not a distinct subgroup at the genetic level. Clinical studies with somatostatin analogues should be limited to those patients expressing ssr_2 in their liver tumour.

INTRODUCTION

Hepatocellular carcinoma (HCC) is the most common primary liver cancer and fifth most common cancer in the world. Recent reports suggest an increase of the incidence of HCC in the Western World, however, this may reflect a referral bias (1,2). Only a minority of patients can be treated by partial liver resection, liver transplantation or local treatment (radiofrequency, percutaneous ethanol injection, trans arterial chemo embolization). Because HCC is not sensitive to systemic chemotherapy (3), other therapies are tried. Results of studies investigating the effect of somatostatin analogues on HCC in humans are conflicting (4-8). Somatostatin receptors (SS-Rs) have been demonstrated in a variety of human tumors. At least 5 different human subtypes (SS-R subtype 1 – 5) have been cloned. All subtypes bind human somatostatin with high affinity, while somatostatin analogues bind with high affinity to SS-R subtype 2 (sst₂). Literature data on the expression of SS-Rs in HCC are scarce. There is no study published, investigating whether HCC tumours expressing SS-Rs are a distinct subgroup at the genetic level. To investigate the SS-Rs in HCC and to test whether specific genetic alterations are associated with SS-Rs-positive or SS-Rs-negative HCC's, we examined protein (over) expression of tumour suppressor genes (p16, p53 and Rb1) by immunohistochemistry. Further, the proliferative capacity was examined by immunostaining of Ki67 and DNA ploidy status (aneuploidy) was measured by fluorescent in situ hybridization (FISH) with a chromosome 1-specific repetitive DNA probe. Our results will indicate the existence of SS-Rs in human HCC and we will describe whether there is a correlation between SS-Rs expression and clinical and pathological characteristics, or alterations of investigated proto-oncogenes.

MATERIAL AND METHODS

Patient material

Tissue of surgically resected tumours of patients with HCC were analysed in this study. The diagnosis was formulated according to the guidelines issued by the World Health Organisation (9). We collected representative paraffin blocks from neoplastic liver cell specimens. HCC's were graded using a standard grading system (10). Tumour samples from surgical resections of 58 Patients with HCC were selected for the tissue micro-array (TMA). Of each resection specimen 0.6 mm tissue cylinders were punched out of the tissue blocks, and brought into the array block with regular spacing between the cylindrical biopsies. From each patient, 2 tissue cores were included in the TMA. A standard H&E stained histological section of the TMA was made for quality control. In 10 cases no adequate carcinoma tissue cores were available for analysis due to absence or inadequate numbers of tumor cells. In three cases, SS-Rs

could not be determined by technical errors. A total of 90 liver tissue samples were available for analysis, i.e. 45 HCC's.

Fluorescent in situ hybridization

FISH was performed on a 4- μ m-thick tissue section of the TMA that was adhered to a aminoacetylsilane (AAS) coated slide (Starfrost, Berlin, Germany). The (peri) centromeric DNA probe for chromosome 1 was labeled with Spectrum Green using a Nick Translation Reagent Kit (Vysis, Downers Grove IL, USA) according to the manufacturer's directions. The FISH procedure was carried out basically as described before by us (11,12). Briefly, after appropriate pepsin digestion, sections were heat-denatured for 2 min in 70% formamide in 2x SSC, and hybridized overnight at 37°C with the denatured probes in a hybridization mixture containing 2 ng/ μ l DNA probe, 500 ng/ μ l herring sperm DNA (Sigma, St. Louis MO, USA), 0.1% Tween-20, 10% dextran sulphate, and 60% formamide in 2x SSC at pH 7.0. Then, a series of stringent washes followed to remove unbound probe. Finally, the section was counterstained with DAPI in antifade solution (Vectashield; Vector, Burlingame CA, USA). The FISH results were analyzed on a computer screen. Images of each of the 2 fluorochromes were collected using an epifluorescence microscope (Leica DM, Rijswijk, The Netherlands) equipped with appropriate excitation and emission filter sets (Leica), and a cooled CCD camera (Photometrics, Tucson AZ, USA). The green and blue images were collected sequentially by changing the excitation filter using CW4000 FISH software (Leica). Two investigators scored a minimum of 50 interphase cell nuclei per tissue core, and the number of green fluorescent centromere 1 spots per nucleus was scored (0, 1, 2, 3, 4, >4 spots/nuclear slice). Then, the percentage of hyperdiploid cell nuclei was determined.

Immunohistochemistry p16, p53, Rb1 and Ki67 antigen

The immunohistochemistry was carried out as described before by us (13). Basically, 4 μ m consecutive tissue sections of the TMA were mounted on aminoacetylsilane (AAS) coated slides (Starfrost, Berlin, Germany), and immunostaining was performed using the UltraVision Large Volume Detection System Anti-Polyvalent, HRP (Labvision, Fremont, CA). After deparaffinization microwave (700 W) pretreatment was performed for 15 minutes using citrate buffer (10mM citric acid monohydrate, pH 6.0). The p16 gene product was evaluated using antibody E6H4 (DAKO, Glostrup, Denmark), diluted 1/25 in phosphate-buffered saline/5% BSA. To assess overexpression of the p53 protein, the primary antibody DO-7, recognizing both wild type and mutant p53, (DAKO) was used, diluted 1/50 in phosphate-buffered saline/5% BSA. The Retinoblastoma gene product was evaluated with clone Rb1 (DAKO), diluted 1/25 in phosphate-buffered saline/5% BSA. This antibody reacts with cell the cycle-related phosphorylated form of Rb protein. To estimate proliferation rate primary labelling of the Ki67 antigen was performed with antibody Mib-1 (Immunotech,

Marseille, France), diluted 1/100 in phosphate buffered saline/5% BSA. As a positive control a cytokeratin 8/18 antibody was used, as a negative control the primary antibody was omitted. At least 50 cells were scored by two independent investigators. Ki67: A percentage >1% was regarded as increased proliferation. For p16, p53 and Rb1 an identical scoring system was used: A percentage exceeding 1% of positive cells was regarded as protein overexpression of these tumor suppressor genes. The cut-off value of 1% was based on immunostaining profiles of normal liver controls.

Somatostatin receptor immunohistochemistry

Five μm sections of the TMA were mounted on aminoacetylsilane (AAS) coated slides (Starfrost, Berlin, Germany). This was deparafinized, dehydrated, exposed to microwave heating (in citric acid buffer, 10 min. at 100 °C), rinsed in tap water and phosphate buffered saline (PBS) and incubated for 15 min. in normal goat serum (1:10 dilution in PBS + 5% bovine serum albumin (BSA)). Thereafter, the cells were incubated overnight at 4 °C with antibody against sst_2 . The antibodies were used at a dilution of 1:1000 in PBS + 5% BSA. A standard streptavidin-biotinylated-peroxidase complex (ABC) kit (Biogenix, San Ramon, CA, USA) was used according to the manufacturers to visualise the bound antibodies. In our laboratory we tested the determination of ssr subtypes with immunohistochemistry followed by a determination with PCR as the gold standard. The most reliable subtype determination was sst_2 and sst_3 (100% score). The other subtypes are not reproducible. Because ssr_2 is the most clinical significant, we tested this subtype.

Statistical evaluation

The Mann-Whitney-U test was used for comparisons between the specimen groups for the percentage of hyperdiploid cell nuclei (aneuploidy). It was further used to evaluate the clinical parameter age and tumour size. Fisher's Exact Test was applied

TABLE I Clinical and pathological data from 45 patients with HCC

	sst_2 +	sst_2 -	TOTAL	difference
Total number of patients	30 (67%)	15 (33%)	45 (100%)	
Age (years)	59 (23 – 74)	53 (39-74)	57 (23-74)	NS
Male	19 (63%)	9 (60%)	28 (62%)	NS
Female	11 (37%)	6 (40%)	17 (38%)	
Diameter Tumour (cm)	5 (1-16)	4 (2-12)	5 (1-16)	NS
Grade I or II Tumour	19 (63%)	9 (60%)	28 (62%)	NS
Grade III Tumour	11 (37%)	6 (40%)	17 (38%)	
Underlying liver cirrhosis	20 (67%)	9 (60%)	29 (64%)	NS
Without liver cirrhosis	10 (33%)	6 (40%)	16 (36%)	

TABLE II. Genetic alterations in 45 HCC's in relation to ssr_2 expression

	ssr_2 +	ssr_2 -	TOTAL	difference
Number of patients	30 (67%)	15 (33%)	45	
P16 +	6 (20%)	2 (13%)	8 (18%)	NS
P16 -	24 (80%)	13 (87%)	37 (82%)	
P53 +	15 (50%)	8 (53%)	23 (51%)	NS
P53 -	15 (50%)	7 (47%)	22 (49%)	
Rb1 +	15 (50%)	8 (53%)	23 (51%)	NS
Rb 1 -	15 (50%)	7 (47%)	22 (49%)	
Ki67 +	17 (57%)	9 (60%)	26 (58%)	NS
Ki 67 -	13 (43%)	6 (40%)	19 (42%)	
Aneuploidy	33 (8-70)	19 (10-66)	28 (8 – 70)	NS

for comparisons of the immunostaining results between groups, as well as tumor grade in relation to FISH and immunostaining. Also the parameter gender was evaluated using this test. $P=0.05$ (two-sided) was taken as the limit of significance. A P-value between 0.05 and 0.10 was considered a statistical trend.

RESULTS

Somatostatin receptor 2 expression was assessed by immunohistochemistry. In our series of 45 tumours, ssr_2 expression was detected in 30 tumours (67%). Patient and tumour characteristics compared with ssr_2 status of the tumour are summarized in table I. Twenty-eight men and 17 women were investigated with a median age of 57 years (23-74) and a median tumour size of 5 cm (1-16). Twenty-nine patients had underlying liver cirrhosis. Age, gender, tumour size, tumour grade and underlying liver disease of the ssr_2 + tumours were not significantly different from the ssr_2 – tumours.

Protein (over) expression of tumour suppressor genes (p16, p53 and Rb1) was examined by immunohistochemistry. The proliferative capacity was examined by immunostaining of Ki67 and DNA ploidy status (aneuploidy) was measured by fluorescent in situ hybridization (FISH) with a chromosome 1-specific repetitive DNA probe. The results are shown in Table II.

Aneuploidy, i.e. the percentage of hyperdiploid cells, was 33 (range 8-70) in the ssr_2 + tumours versus 19 (range 10-66) in the ssr_2 – tumours (NS). No differences were observed between the ssr_2 – and + tumours for p53, p16, Rb1 oncoprotein or proliferation markers.

TABLE III. Somatostatin receptors in patients with HCC

	No of pts	SSR2 + (tumor)	Method
Reubi et al	59	41%*	Autoradiography
Bläker et al.	56	41%	Immunohistochemistry
Reynaert et al.	6	67%	Immunohistochemistry
Erasmus MC	45	67%	Immunohistochemistry

*: all ssr subtypes (1-5)

DISCUSSION

In pre-clinical studies Somatostatin analogues (SS) inhibit the growth of a wide variety of tumours *in vivo* and *in vitro* (14-16). The published studies regarding the efficacy of SS on survival in patients with HCC are conflicting. Some studies did not display an improve in survival in patients with unresectable HCC's (4-6) while others found a significant survival benefit (7,8,17). The placebo controlled randomized trials did not show significant benefit of SS on patient survival (4,18).

There is no explanation for these contradictory results. If you analyse the number of studies regarding the efficacy of SS in the treatment of HCC, it is striking that studies investigating the somatostatin receptor in human HCC are limited. The variations in receptor expression may explain differences in clinical efficacy. To our knowledge, 3 studies described the expression of tumour ssr in patients with HCC (Table III). The studies of Blaker et al (19) and Reubi et al. (20) studied the correlation between ssr and tumour characteristics. Our study confirmed their results that there is no correlation between tumour stage, tumour differentiation and underlying liver disease. Moreover, there was no correlation between ssr and age or gender. Therefore it is not possible to predict the existence of ssr in human HCC based on available clinical parameters. If the expression of ssr in HCC plays a role in the outcome regarding SS treatment in patients with HCC, it is not possible to stratify the patients based on clinical characteristics.

It is known that there are 5 subtypes of ssr. All ssr's (1-5) have been implicated in antiproliferative signalling (21). Our study investigated the ssr-2 and not the other subtypes ssr 1, 3-5. There is a difference in binding affinity between analogues of SS and the ssr subtypes. Octreotide, an often used SS analogue, has a high binding affinity with ssr-2 compared to the other ssr subtypes. The absence or presence of ssr-2 subtype in HCC might be the cause of the divergent biological responses in trials with octreotide in patients with advanced HCC. This is one of the reasons we tested ssr-2 in human HCC. Most important decisive factor to test ssr-2 is the fact that we examined the determination of ssr subtypes with immunohistochemistry followed by a determination with PCR as the gold standard. The most reliable subtype determination was ssr-2 and ssr-3 (100% score). Testing for the other subtypes is in our hands not reproducible. Because of the high affinity with SS analogues, we

determined that *ssr-2* is the most clinical significant subtype. In our series, 67% of the HCC's expressed *ssr-2*, what is exact the same percentage *ssr-2* found in the study of Reynaert et al. (22) and higher than the 41% Blaeker et al. (19) found. Because of the higher binding affinity of *ssr-2* to SS analogues compared to the other *ssr* subtypes and the variable *ssr-2* expression in HCC found in our study and others, clinical trials evaluating the treatment of SS analogues in patients with HCC, should take these findings into account.

Somatostatin receptors may play a role in the progression of cancers. Binding studies suggested that *ssr*'s were preferentially expressed in well differentiated compared to less differentiated tumors (23,24). In other words, *ssr*'s may play a role in the differentiation in some cancers. Loss of *ssr* expression in tumour cells would confer a proliferative advantage to those cells and their progeny. In regard of this point genes of the *ssr*'s can be regarded as tumour suppressor genes. This suggestion is supported by the observation that a point mutation in *ssr-2* gene results in a proliferative advantage in small cell lung cancer cells in vitro (25). If *ssr*'s can be regarded as tumour suppressor genes, it might be that *ssr* + subgroup is a distinct group of patients. Maybe specific genetic alterations are associated with *ssr*-positive HCC's and this may be another possible explanation for the conflicting results regarding the efficacy of SS analogues on survival in patients with HCC.

The p53 oncosuppressor is the gene which has been found to be most frequently altered in human cancers. Moreover, it is the most commonly mutated gene in HCC (26-29). In a large study of Qin et al. (29), nuclear staining for p53 were found in 50.5% of the cases (112 of the 222 cases). Some reports are indicating that p53 is an independent prognostic marker regarding survival (28,29). Among the known tumor suppressor genes, the inactivation of p16 is reported to be second only to p53 inactivation in human neoplasia (30). Also in human HCC, p16 is a major inactivation target (31,32). Edamoto et al. recently demonstrated that alterations in the RB1 pathways commonly occur in HCC's (33). In a selected group of 45 patients we investigated whether any of the genetic alterations that are frequently observed in HCC's (p53, p16 and RB1) were specific for the *ssr*+ or *ssr*- subgroups. None of the investigated oncogenes are specific for the subgroups.

Conclusion: In 67% of the patients with HCC, *ssr₂* could be detected in the tumour. No clinical characteristics were specific for *ssr₂* + or – tumours. There are no specific genetic alterations, aneuploidy or proliferation markers associated with *ssr₂*-positive or -negative HCC's

References

1. El-Serag H, Davilla JA, Petersen NJ, McGlynn KA. The continuing increase in the incidence of hepatocellular carcinoma in the United States: an update. *Ann Intern Med* 2003;139:817-823.
2. Verhoef C, Visser O, de Man RA, de Wilt JHW, Ijzermans JNM, Janssen-Heijnen MLGI. HCC in the Netherlands: incidence treatment and survival patterns. *EJC* 2004;40:1530-8.
3. Schwartz JD, Beutler AS. Therapy for unresectable hepatocellular carcinoma: review of the randomized clinical trials-II: systemic and local non-embolization-based therapies in unresectable and advanced hepatocellular carcinoma. *Anti-Cancer Drugs* 2004;15:439-452.
4. Yuen MF, Poon RT, Lai CL, et al. A randomized placebo-controlled study of long-acting octreotide for the treatment of advanced hepatocellular carcinoma. *Hepatology* 2003;36:687-91.
5. Rabe C, Pilz T, Allgaier, et al. Clinical outcome of a cohort of 63 patients with hepatocellular carcinoma treated with octreotide. *Z Gastroenterol* 2002;40:395-400.
6. Raderer M, Hejna MH, Muller C, et al. Treatment of hepatocellular cancer with the long acting somatostatin analog lanreotide in vitro and in vivo. *Int J Oncol* 2000;16:1197-201.
7. Dimitroulopoulos D, Xinopoulos D, Tsamakidis K, et al. The role of sandostatin LAR in treating patients with advanced hepatocellular cancer. *Hepatogastroenterology* 2002;49:1245-50.
8. Samonakis DN, Moschandreass J, Arnaoutis T, et al. Treatment of hepatocellular carcinoma with long acting somatostatin analogues. *Oncol Rep* 2002;9:903-7.
9. Gibson JB, Sobin LH. Histological typing of tumours of the liver, biliary tract and pancreas. In: *International histological classification of tumours*, 20 Geneva: World Health Organisation, 1978.
10. Edmondson HA, Steiner PE. Primary carcinoma of the liver. A study of 100 cases among 48,900 necropsies. *Cancer* 1954;7:462-503.
11. Alers JC, Van Dekken H. Interphase cytogenetic analysis of solid tumors by non-isotopic DNA in situ hybridization. *Progr Histochem* 1996;31:1-137.
12. Van Dekken H, Wink J, Alers JC, de Man RA, Ijzermans JN, Zondervan PE. Genetic evaluation of the dysplasia-carcinoma sequence in chronic viral liver disease: A detailed analysis of two cases and a review of the literature. *Acta Histochem* 2003;105:29-41.
13. Van Dekken H, Verhoef C, Wink J, van Marion R, Vissers KJ, Hop WC, de Man RA, Ijzermans JN, van Eijck CHJ, Zondervan PE. Cell biological evaluation of liver cell carcinoma, dysplasia and adenoma by tissue micro-array analysis. *Acta Histochem* 2005;107(3):161-71.
14. Schally AV. Oncological applications of somatostatin analogues. *Cancer Res* 1988;48:6977-85.
15. Lamberts SW, Krenning EP, Reubi JC. The role of somatostatin and its analogs in the diagnosis and treatment of tumors. *Endocr Rev* 1991;12(4):450-82.
16. Weckbecker G, Raulf F, Stolz B, Bruns C. Somatostatin analogs for diagnosis and treatment of cancer. *Pharmacol Therap* 1993;60(2):245-64.
17. Kouroumalis E, Skordilis P, Thermos K, Vasilaki A, Moschandreass J, Manousos ON. Treatment of hepatocellular carcinoma with octreotide: a randomised controlled study. *Gut* 1998;42:442-447.
18. Allgaier HP, Becker G, Olschewski M, et al. Octreotide treatment in patients with advanced hepatocellular carcinoma: first results of the randomized placebo-controlled double blind Hector trial. *Hepatology* 2003;38:760A.
19. Blaeker M, Schmitz M, Gocht A, et al. Differential expression of somatostatin receptor subtypes in hepatocellular carcinomas. *J Hepatol* 2004;41:112-118.
20. Reubi JC, Zimmerman A, Jonas S, Waser B, Neuhaus P, Laederach U, Wiedenmann B. Regulatory peptide receptors in human hepatocellular carcinomas. *Gut* 1999;45:766-774.
21. Kumar U, Grigorakis SI, Watt HL, Sasi R, Snell L, Watson P, Chaudhari S. Somatostatin receptors in primary human breast cancer: quantitative analysis of mRNA for subtypes 1-5 and correlation with receptor protein expression and tumor pathology. *Breast Cancer Res Treat* 2005;92:175-186.
22. Reynaert H, Rombouts K, Vandermonde A, et al. Expression of somatostatin receptors in normal and cirrhotic human liver and in hepatocellular carcinoma. *GUT* 2004;53:1180-1189.
23. Reubi JC. Octreotide and nonendocrine tumors. Basic knowledge and therapeutic potential. In: Lomax P, Scarpignato C, Vessel E, eds. *Octreotide from basic science to clinical medicine*. Basel: Karger;1996:246-269.

24. Reubi JC, Laissue J, Krenning E, Lamberts SW. Somatostatin receptors in human cancer: incidence, characteristics, functional correlates and clinical implications. *J Steroid Biochem Mol Biol.* 1992;43:27-35.
25. Zhang CY, Yokogoshi Y, Yoshimoto K, Fujinaka Y, Matsumoto K, Saito S. Point mutation of the somatostatin receptor 2 gene in the human small cell lung cancer cell line COR-L103. *Biochem Biophys Res Commun.* 1995;210:805-815.
26. Hsu HC, Tseng HJ, Lai PL, et al. Expression of p53 gene in 184 unifocal hepatocellular carcinomas: association with tumour growth and invasiveness. *Cancer Re* 1993;53:4691-4.
27. Hsu HC, Peng SY, Lai PL, et al. Mutations of p53 gene in hepatocellular carcinoma (HCC) correlate with tumor progression and patient prognosis: a study of 138 patients with unifocal HCC. *Int J Oncol* 1994;4:1341-7.
28. Peng SY, Chen WJ, Lai PL, et al. High α -fetoprotein level correlates with high stage, early recurrence and poor prognosis of hepatocellular carcinoma: significance of hepatitis virus infection, age, p53 and b-catenin. *Int J Cancer* 2004;112:44-50.
29. Qin LX, Tang ZY, Ma ZC, et al. p53 immunohistochemical scoring: an independent prognostic marker for patients after hepatocellular carcinoma resection. *World J Gastroenterol* 2002;8:459-463.
30. Sherr CJ. Cancer cell cycles. *Science* 1996;274:1672-7.
31. Baek MJ, Piao Z, Kim NG, et al. P16 is a major inactivation target in hepatocellular carcinoma. *Cancer* 2000;89:60-8.
32. Matsuda Y, Ichida T, Genda T, et al. Loss of p16 contributes to p27 sequestration by cyclin D1-Cyclin-dependent kinase 4 complexes and poor prognosis in hepatocellular carcinoma. *Clin Cancer Res* 2003;9:3389-3396.
33. Edamoto Y, Hara A, Biernat W, et al. Alterations of RB1, p53 and Wnt pathways in hepatocellular carcinomas associated with hepatitis c, hepatitis b and alcoholic liver cirrhosis. *Int J Cancer* 2003;106:334-341.

Chapter XI

Summary and Conclusions

New Developments in Rotterdam

The most common primary liver cancer is hepatocellular carcinoma (HCC). With an estimated 0.5 million new patients per year world-wide and about one million death yearly, HCC is the fifth most common cancer in the world and the third most common cause of cancer mortality¹.

It is a disease with a highly uneven geographical distribution. In North America and several European countries, HCC is uncommon and the estimated death rate is less than 5/100,000 inhabitants/year^{2,3}. This in contrast to countries in the East and Africa where the incidence rates exceeds 30/100,000/year. However, the incidence has been increasing in low-endemic areas, as has been reported for the United Kingdom⁴, France⁵ and the United States⁶. Publications describing epidemiological, treatment and prognosis figures of patients with HCC are mostly derived from a selected group of patients⁷⁻¹⁰. This may be of limited relevance. In **Chapter II** the results are described of a population-based study in the Netherlands including all patients with HCC diagnosed between 1989 and 2000¹¹. In contrast to previous reports of sub-populations in non-endemic areas, we found no rising incidence of HCC in the Netherlands between 1989 and 2000. In 2000 the ESR for males was 1.6/100,000/year and for females 0.3/100,000/year. There was no change in treatment pattern (1989-1998). Remarkably 73% of patients with HCC received no cancer-related therapy during this period of analysis. A treatment with a curative intent, either partial liver resection or orthotopic liver transplantation was only noted in twelve percent of patients. There may be various explanations for this finding. Without adequate surveillance programs the diagnosis may be made in a phase of the disease too late to offer a curative treatment. However, as many patients are visiting hospitals at a regular base for the treatment of the underlying liver disease, including viral or alcohol induced cirrhosis, it may also be speculated that there is a certain reluctance to offer such an aggressive therapy as liver resection or liver transplantation. Review of casus with HCC in specialised centres may be advocated to minimise the number of patients not receiving possible curative therapy¹¹. Within the near future an update will be done to expand the data and to review the outcome of the management of HCC in the Netherlands.

Although solid experimental evidence for a single causative agent of HCC is lacking, there is a clear association of HCC with chronic inflammation. A large number of diseases have been related to the carcinogenesis of HCC, including hepatitis B or C virus, aflatoxin, alcoholic liver disease, haemochromatosis and tyrosinaemia. Epidemiological evidence has lead to the hypothesis that cirrhosis resulting from any cause is the seedbed for HCC¹². The occurrence of unknown co-factors is very likely to play a role in the likelihood to develop HCC. Moreover, a significant proportion of patients with HCC in a non-cirrhotic liver has no risk factor identified. In **Chapter III** we investigated a potential risk factor that may induce chronic hepatitis. In 1994 it was demonstrated for the first time in mice that infection with *Helicobacter hepaticus* resulted in hepatitis and hepatic tumour induction^{13,14}. In 1997 a significantly higher prevalence of

immunoglobulin G (IgG) antibody against *H. pylori* in patients with liver cirrhosis than in controls was reported¹⁵. Various studies reported an increased prevalence of *Helicobacter* DNA in the liver of patients with HCC, further supporting the notion that *Helicobacter* might play a role in the carcinogenesis of HCC in humans¹⁶⁻²⁰. As these studies were based mostly on the analysis of biopsy materials from cirrhotic livers, it remained unclear whether the presence of *Helicobacter* species was the cause or merely the result of the cirrhosis. To address this issue, we studied the presence of *Helicobacter* DNA in liver samples of patients with HCC in non-cirrhotic livers and the detection of *Helicobacter* species in their stomach was explored. Analysis indicated that *Helicobacter* DNA was observed at a higher frequency in the non-cirrhotic liver of patients with HCC ($P < 0.004$). Sequence analysis of PCR products obtained from HCC patients indicated that they were related most closely to the 16S rDNA sequence of *Helicobacter pylori* but that they always differed at the same two positions. The same *H. pylori* subspecies was present in the stomach of patients with HCC. This finding suggests that gastric *Helicobacter* colonization may play a role in the induction of HCC, either directly via colonization of the liver or indirectly, e.g. via secretion of specific toxins by *Helicobacter* residing in the stomach²¹.

If patients have a liver tumor, with or without a known risk-factor, the imaging tests to make a diagnosis most commonly used are ultrasonography, angiography, computed tomography and magnetic resonance imaging. There is a growing interest in the development of in vivo methods of assessing functional parameters and metabolism in normal and diseased tissues^{22,23}. Positron emission tomography with fluorine-18-deoxyglucose (¹⁸FDG-PET) is one example of such a technique. PET is currently not widely available, mainly because of its high costs. Recently, alternative techniques for ¹⁸FDG imaging have become available: SPECT using special high-energy collimators²⁴ and coincidence detection using adapted multi-head gamma cameras²⁵.

In a pilot study (**Chapter V**) we prospectively evaluated if ¹⁸FDG Positron Coincidence Detection (PCD) and single photon emission computed tomography (SPECT) provide additional benefit to our conventional preoperative evaluation of patients with a suspected HCC (CT and ultrasonography). The literature regarding PET in patients with HCC has been reviewed.

SPECT has a lower sensitivity for the detection of intrahepatic lesions compared to CT. After reviewing the literature, we concluded that PET has no additional value in detection intrahepatic HCC. PET is optional in detecting extra-hepatic disease. PET/SPECT/PCD is not a standard imaging modality in the work-up of patients with HCC.²⁶

The most commonly used serum marker to detect HCC is serum alpha fetoprotein (AFP). A large case-control study displays a sensitivity of 62% and a specificity of 89% with a cut off value > 15 ng/ml. At a value of > 200 ng/ml, the sensitivity is 22%, with a specificity of 99%.²⁷ **Chapter VI** depicts the sensitivity of AFP in patients with

a HCC in a non-cirrhotic liver. Of those patients treated in the ErasmusMC, 55% had an AFP > 15 ng/ml.²⁸ If there is a liver lesion suspected to be a HCC but the diagnosis cannot be confirmed by serum analysis or imaging techniques, a percutaneous biopsy can be performed. The risk of seeding by the needle track varied between 2 and 5%. However even after histological examination the risk on a false negative outcome can be up to 23%.²⁹ It may be difficult to distinguish a well differentiated HCC from liver lesion due to dysplasia in a cirrhotic liver or from an adenoma in a non-cirrhotic liver. **Chapter IV** describes the difference in cell biological markers, DNA ploidy status and proliferative capacity between adenomas and HCC. The results suggest that adenomas can be distinguished from carcinomas, based on ploidy and proliferation characteristics.³⁰

Despite the high numbers of patients diagnosed worldwide, HCC continues to pose challenging clinical problems. The assessment of the tumor and the decision on the most adequate treatment option may benefit from a multi-disciplinary approach in which the surgeon plays a central role. In 1970's, a cirrhotic liver was a contraindication for partially liver resection. Nowadays, partial hepatic resection is the first treatment option that is considered for a curative treatment of patients with HCC and a compensated liver cirrhosis.

The prognosis for patients with HCC in a non-cirrhotic liver is not as clearly described as that for patients with HCC in a cirrhotic liver. Absence of underlying cirrhosis is found in approximately 30% of patients with HCC in Western countries. **Chapter VI** describes the results of patients with a HCC in a non-cirrhotic liver, treated in ErasmusMC. As the absence of cirrhosis leads to late presentation in the course of the disease, larger tumours are more likely to be seen in a patient with a non-cirrhotic than a cirrhotic liver. The median and mean tumour diameter of 40 patients analysed was 10 cm. We found that size of the tumour was not a significant factor to predict resectability. Despite the large resections performed no postoperative liver failure was observed. This may be explained by the gradual growth of the large tumours which induces functional adaptation of the contralateral lobe. Independent of the diameter of the tumour the outcome of the surgical treatment of HCC in non-cirrhotic livers may be correlated with a five year survival rate of 68% in our series.²⁸

Among patients who have cirrhosis, strict selection criteria for resection are required to avoid treatment related complications. Surgical resection is the golden standard of therapy and appears to be the only effective way, aside from liver transplantation, to alter survival. However, due to advanced or decompensated liver cirrhosis, comorbidity and multifocality of the tumors, only 10-37% of the patients with HCC are considered to be candidates for surgical resection.^{11,12} Regional and local ablation techniques are accepted alternative therapies for unresectable HCC. Trans Arterial Chemoembolization (TACE), Interstitial Laser Coagulation (ILC), Cryotherapy, Micro Wave ablation, Percutaneous Ethanol injection (PEI) and Radiofrequency Ablation (RFA) are the most widely used. In **Chapter VII** the results of ILC in patients with HCC

in a cirrhotic liver are described treated in the ErasmusMC. To enhance the efficiency of ILC, experimental studies in a pig model found that if the bloodflow to the liver was temporarily interrupted the coagulated area was larger than without occlusion. Based on these findings a prospective clinical study was initiated to assess the effectiveness of long-term local control after treatment with ILC with temporary hepatic arterial occlusion, in cirrhotic patients with HCC. Most of the procedures were done percutaneously. In the 24 tumours treated, 19 tumours had complete necrosis on CT-scanning. The majority of the patients developed new lesions (intra and extra hepatic).³¹

Reports in the literature on the use of RF-ablation are increasing. The results of RFA in the ErasmusMC are described in **Chapter VIII**. RF-ablation can be safely performed to achieve adequate local control and survival rates. Time to local tumor progression was significantly related to initial size of the tumor and tumor load. The tumour should not exceed 3cm, to achieve good local control.³²

If resectable intra-hepatic recurrences occur without extra-hepatic disease, partial liver resection and/or RFA is first choice with acceptable results.³³ If there is extra-hepatic recurrence, the surgical treatment remains controversial. In **Chapter IX** the results of resection of extrahepatic HCC resection are described. The conclusion after a systemic review of the literature and our own data support an aggressive approach in case of extrahepatic HCC recurrence in selected cases defined by a completely resectable metastasis, a well-preserved liver function, and the absence of intracranial metastases. Of course complete treatment of the primary tumor is a prerequisite to consider the resection of extrahepatic metastases of HCC. Further research is warranted because of the limited number of reports and the absence of randomised trials.³⁴

HCC is relatively resistant to conventional chemotherapy and therefore chemotherapy is not used as (neo)adjuvant and/or palliative therapy.³⁵ Because of the low response rates to chemotherapy, other drugs with immunomodulatory and anti-angiogenic properties are under investigation. The published studies regarding the efficacy of somatostatin analogues (SS) on survival in patients with HCC are conflicting. Some studies did not display an improved survival in patients with unresectable HCC's^{36,37} while others found a significant survival benefit³⁸⁻⁴⁰. However, placebo controlled randomized trials did not show significant benefit of SS on patient survival^{41,42}.

The number of studies investigating the somatostatin receptor in human HCC is limited. **Chapter X** describes our results on sst₂ expression in HCC. We examined whether HCC's expressing sst₂ can be defined as a distinct subgroup with genetic, clinical or pathological characteristics. We investigated sst-2 as Octreotide, an often used SS analogue, has a high binding affinity with sst-2 compared to the other sst subtypes. In 67% of the patients with HCC, sst₂ could be detected in the tumour. However, no clinical or pathological characteristics were specific for sst₂ positive

tumours; furthermore these tumors cannot be defined as a distinct subgroup at the genetic level.⁴³

New developments in Rotterdam

Partial liver resection, OLT, living related liver transplantation (LDLTx) and local ablation methods are the four curative treatment options that can be offered in the Erasmus MC. Recently the first living related liver transplantation was performed.⁴⁴ Because of the absence of waiting-time, LDLTx may have an advantage compared to transplantation with a liver of a deceased donor. Others already postulated that HCC may become the prime indication for LDLTx.⁴⁵ It should be noted, however, that a number of reports have been published recently, indicating inferior results in survival after LDLTx in the treatment of HCC. As a waiting time may offer information on the biological behaviour of the malignancy a selection of patients with more or less aggressive tumors may be realized by observation while waiting. Thus patients with early vascular ingrowth and early metastasis may not benefit from LDLTx as the disease will recur soon after transplantation. A waiting time of three to six months seems advisable to select patients with HCC eligible for LDLTx.

Stereotactic Radiotherapy is a relatively new technique with promising results. The initial experience in ErasmusMC has been published recently.⁴⁶ From pre-clinical studies it is known, that a combination of radiotherapy plus angiogenesis inhibitors may be either additive or synergistic.^{47,48} Jain and co-workers found in in vivo experiments that angiogenesis inhibitors normalize the vasculature of tumors and alleviate hypoxia.⁴⁹ Winkler et al. described a decrease in hypoxia using angiogenesis inhibitors in a mouse model of brain tumor.⁵⁰ In humans, a similar effect may be expected and further exploration of the combination of stereotactic radiotherapy and angiogenesis inhibitors seems warranted. There will be an increase in the use of RFA in patients with HCC in the coming years. RFA as bridging to transplant or as potential curative treatment will be explored with the combination of TACE in our prospective database.

Others suggested that an isolated liver perfusion may be of beneficial value⁵¹. The magnitude of the procedure is a major drawback for wide clinical application. A new technique of hypoxic isolated liver perfusion has been developed in the Erasmus MC, with a median operation time of 3.5 hours, less than 1 litre bloodloss without peri-operative mortality. The first 25 patients have been treated and it might be applied to patients with HCC confined to the liver in the near future.⁵²

The promising results of angiogenesis inhibitors in cancer treatment can not be disregarded.⁵³ For patients with unresectable disease, a prospective randomized trial is current, receiving doxorubicine regimen with or without thalomid. Another angiogenesis inhibitor is Sorafenib, a multitargeted tyrosine kinase inhibitor. Sorafenib has shown clinical activity in patients with renal cell cancer and hepatocellular cancer. In a recent phase III trial presented at ASCO 2007, treatment with Sorafenib

resulted in a significant survival benefit of 12 weeks in patients with metastatic HCC compared to placebo controls.⁵⁴ Sorafenib was administered in the standard dose of 400mg bd with limited toxicity. The response rate in this study was only 2.3% partial responses. At the same meeting another study reported that the standard dose of Sorafenib could be increased to 1600mg bd with manageable toxicity and increased response rates. However, the primary tumor studied was renal cell cancer.⁵⁵ Based on these findings, we hypothesize that the response rate of Sorafenib against HCC can be increased by escalating its dose. To study this hypothesis, we will develop a dose escalating study with Sorafenib for patients with resectable HCC. Furthermore, we will join European trials of Sorafenib in adjuvant setting and in combination of RFA.

References

1. Parkin DM, Bray F, Ferlay J, Pisani P. Estimating the world cancer burden: GLOBOCAN 2000. *Int J Cancer* 2001;94:153-156.
2. Ramsey WH, Wu GY. Hepatocellular carcinoma: Update on diagnosis and treatment. *Dig Dis* 1995;13:81-91.
3. Bosch FX, Ribes J. Epidemiology of liver cancer in Europe. *Can J Gastroenterol* 2000;14(7):621-630.
4. Taylor-Robinson SD, Foster GR, Arora S, Hargreaves S, Thomas HC. Increase in primary liver cancer in the UK, 1979-94. *Lancet* 1997;350:1142-43.
5. Deuffic S, Poynard T, Buffat L, Valleron AJ. Trends in primary liver cancer. *Lancet* 1998;351:214-15.
6. El-Serag HB, Mason AC. Rising incidence of hepatocellular carcinoma in the United States. *N Engl J Med* 1999;340(10):745-50.
7. Stuart KE, Anand AJ, Jenkins RL. Hepatocellular carcinoma in the United States. Prognostic features, treatment outcome and Survival. *Cancer* 1996;77:2217-2222.
8. Fong Y, Sun RL, Jarnagin W, Blumgart LH. An analysis of 412 cases of hepatocellular carcinoma at a Western center. *Ann Surg* 1999;229:790-800.
9. Zhou XD, Tang ZY. Management of hepatocellular carcinoma: long-term outcome in 2639 cases. *Gan To Kagaku Ryoho* 1997;24(suppl1):9-16.
10. Cance WG, Stewart AK, Menck HR. The national cancer database report on treatment patterns for hepatocellular carcinomas. *Cancer* 2000;88:912-920.
11. Verhoef C, Visser O, de Man RA, de Wilt JHW, Ijzermans JNM, Janssen-Heijnen MLG. *HCC in the Netherlands: incidence treatment and survival patterns*. *EJC* 2004;40:1530-8.
12. Schafer DF, Sorrell MF. Hepatocellular carcinoma. *Lancet* 1999;353:1253-57.
13. Fox JG, Dewhirst FE, Tully JG, Paster BJ, Yan L, Taylor NS, et al. *Helicobacter hepaticus* sp. nov., a microaerophilic bacterium isolated from livers and intestinal mucosal scrapings from mice. *J Clin Microbiol* 1994; 32:1238-1245.
14. Ward JM, Fox JG, Anver MR, Haines DC, George CV, Collins MJ, Jr, et al. Chronic active hepatitis and associated liver tumours in mice caused by a persistent bacterial infection with a novel *Helicobacter* species. *J Natl Cancer Inst* 1994; 86:1222-1227.
15. Siringo S, Vaira D, Menegatti M, Piscaglia F, Sofia S, Gaetani M, Miglioli M. High prevalence of *Helicobacter pylori* in liver cirrhosis. Relationship with clinical and endoscopic features and the risk of peptic ulcer. *Dig Dis Sci* 1997; 42:2024-2030.
16. Avenaud P, Marais A, Monteiro L, LeBail B, Bioulac Sage P, et al. Detection of *Helicobacter* species in the liver of patients with and without primary liver carcinoma. *Cancer* 2000; 89:1431-1439.
17. Ponzetto A, Pellicano R, Leone N, Cutufo MA, Turrini F, Grigioni WF, et al. *Helicobacter* infection and cirrhosis in hepatitis C virus carriage: is it an innocent bystander or a troublemaker? *Med Hypotheses* 2000; 54:275-277.
18. Nilsson HO, Mulchandani R, Tranberg KG, Wadstrom T. *Helicobacter* species identified in liver from patients with cholangiocarcinoma and hepatocellular carcinoma. *Gastroenterology* 2001; 120:323-324.
19. Magalhães Queiroz de DM, Santos A. Isolation of a *Helicobacter* strain from the human liver. *Gastroenterology* 2001; 121:1023-1024.
20. Dore MP, Realdi G, Mura D, Graham DY, Sepulveda AR. *Helicobacter* infection in patients with HCV-related chronic hepatitis, cirrhosis and hepatocellular carcinoma. *Dig Dis Sci* 2002; 47:1638-1643.
21. Verhoef C, Pot RG, de Man RA, et al. Detection of identical *Helicobacter* DNA in the stomach and in the non-cirrhotic liver of patients with hepatocellular carcinoma. *Eur J Gastroenterol Hepatol*. 2003 Nov;15(11):1171-4.
22. Wagner HN Jr, Conti PS. Advances in medical imaging for cancer diagnosis and treatment. *Cancer* 1991;67:1121-28.
23. Srauss LG, Conti PS. The applications of PET in clinical oncology. *J Nucl Med* 1991;32:623-48.
24. Van Lingen A, Huijgens PC, Visser FC, et al. Performance characteristics of a 511-keV collimator for imaging positron emitters with a standard gamma-camera. *Eur J Nucl Med* 1992; 19: 315-21.
25. Patton JA. Instrumentation for coincidence imaging with multihead scintillation cameras. *Semin Nucl Med* 2000; 30: 239-54.

26. Verhoef C, Valkema RA, de Man RA et al. Fluorine-18 FDG imaging in hepatocellular carcinoma using positron coincidence detection and single photon emission computed tomography. *Liver* 2002;22:51-56.
27. Trevisani F, D'Intino PE, Morselli-Labate AM, et al. Serum alpha-fetoprotein for diagnosis of hepatocellular carcinoma in patients with chronic liver disease: influence of HBsAG and anti-HCV status. *J Hepatol* 2001;34:570.
28. Verhoef C, de Man RA, Zondervan PE, Tilanus HW, IJzermans JNM. Good outcomes after resection of large hepatocellular carcinoma in the non-cirrhotic liver. *Dig Surg* 2004;21:380-386.
29. Hertz G, Reddy VB, Green L, et al. Fine-needle aspiration biopsy of the liver: a multicenter study of 602 radiologically guided FNA. *Diagn Cytopathol* 2000;23:326-328.
30. Van Dekken H, Verhoef C, Wink J, van Marion R, Vissers KJ, Hop WC, de Man RA, IJzermans JN, van Eijck CHJ, Zondervan PE. Cell biological evaluation of liver cell carcinoma, dysplasia and adenoma by tissue micro-array analysis. *Acta Histochem* 2005; 107(3):161-71.
31. Verhoef C, Kuiper JW, Heisterkamp J, de Man RA, Pattynama PM, IJzermans JNM. Interstitial laser coagulation with temporary hepatic artery occlusion for patients with cirrhosis and irresectable hepatoma. *Br J Surg* 2003;90(8): 950-955.
32. V.E. de Meijer, C. Verhoef, J.W. Kuiper, I.P.J. Alwayn, G. Kazemier, J.N.M. IJzermans. *Radiofrequency ablation in patients with primary and secondary hepatic malignancies*. *J Gastro Intest Surg* 2006; Jul-Aug;10(7):960-73.
33. Taura K, Ikai I, Hatano E, et al. Implication of frequent local ablation therapy for intrahepatic recurrence in prolonged survival of patients with hepatocellular carcinoma undergoing hepatic resection. An analysis of 610 patients over 16 years old. *Ann Surg* 2006;244:265-273.
34. Verhoef C, Holman FA, de Man RA, Hussain SM, IJzermans JNM. *Resection of extra-hepatic HCC can result in long term survival*. *Acta Chir Belg*. 2005 Sep-Oct;105(5):533-6.
35. Schwartz JD, Beutler AS. Therapy for unresectable hepatocellular carcinoma: review of the randomized clinical trials-II: systemic and local non-embolization-based therapies in unresectable and advanced hepatocellular carcinoma. *Anti-Cancer Drugs* 2004;15:439-452.
36. Rabe C, Pilz T, Allgaier, et al. Clinical outcome of a cohort of 63 patients with hepatocellular carcinoma treated with octreotide. *Z Gastroenterol* 2002;40:395-400.
37. Raderer M, Hejna MH, Muller C, et al. Treatment of hepatocellular cancer with the long acting somatostatin analog lanreotide in vitro and in vivo. *Int J Oncol* 2000;16:1197-201.
38. Dimitroulopoulos D, Xinopoulos D, Tsimakidis K, et al. The role of sandostatin LAR in treating patients with advanced hepatocellular cancer. *Hepatogastroenterology* 2002;49:1245-50.
39. Samonakis DN, Moschandreas J, Arnaoutis T, et al. Treatment of hepatocellular carcinoma with long acting somatostatin analogues. *Oncol Rep* 2002;9:903-7
40. Kouroumalis E, Skordilis P, Thermos K, Vasilaki A, Moschandrea J, Manousos ON. Treatment of hepatocellular carcinoma with octreotide: a randomised controlled study. *Gut* 1998;42:442-447.
41. Yuen MF, Poon RT, Lai CL, et al. A randomized placebo-controlled study of long-acting octreotide for the treatment of advanced hepatocellular carcinoma. *Hepatology* 2003;36:687-91.
42. Allgaier HP, Becker G, Olschewski M, et al. Octreotide treatment in patients with advanced hepatocellular carcinoma: first results of the randomized placebo-controlled double blind Hector trial. *Hepatology* 2003;38:760A.
43. C Verhoef, H van Dekken, LJ Hofland, PE Zondervan, JHW de Wilt, R van Marion, RA de Man, JNM IJzermans, CHJ van Eijck. Somatostatin receptor in human hepatocellular carcinomas: genetic, patient and tumour characteristics. *Dig Surg* 2008 in press.
44. Slooff MJ, Kazemier G. Liver transplantation from a living donor *Ned Tijdschr Geneesk*. 2004 Nov 13;148(46):2257-9.
45. Gondolessi G, Munoz L, Matsumoto C, et al. Hepatocellular carcinoma: A prime indication for living donor liver transplantation. *J Gastrointest Surg* 2002;6:102-107.
46. Mendez Romero A, Wunderink W, Hussain SM, De Pooter JA, Heijmen BJ, Nowak PC, Nuytens JJ, Brandwijk RP, Verhoef C, IJzermans JN, Levendag PC. Stereotactic body radiation therapy for primary and metastatic liver tumors: A single institution phase I-II study. *Acta Oncol*. 2006;45(7):831-7.
47. Teicher BA. A systems approach to cancer therapy. (Antioncogenics+ standard cytotoxics--> mechanism(s) of interaction). *Cancer Metastasis Rev* 1996; 15: 247-272.

48. Zips D, Krause M, Hessel F, Westphal J, Bruchner K, Eicheler W, *et al.* Experimental study on different combination schedules of VEGF-receptor inhibitor PTK787/ZK222584 and fractionated irradiation. *Anticancer Res* 2003; 23: 3869-3876.
49. Jain RK. Normalization of tumor vasculature: an emerging concept in antiangiogenic therapy. *Science* 2005; 307: 58-62.
50. Winkler F, Kozin SV, Tong RT, Chae SS, Booth MF, Garkavtsev I, *et al.* Kinetics of vascular normalization by VEGFR2 blockade governs brain tumor response to radiation: role of oxygenation, angiopoietin-1, and matrix metalloproteinases. *Cancer Cell* 2004; 6:553-563.
51. Feldman ED, Wu PC, Beresneva T, *et al.* Treatment of patients with unresectable primary hepatic malignancies using hyperthermic isolated hepatic perfusion. *J Gastrointest Surg.* 2004 Feb;8(2):200-7.
52. Verhoef C, de Wilt JHW, Brunstein F, *et al.* Isolated hypoxic hepatic perfusion with retrograde out-flow in patients with irresectable liver metastases; A New Simplified Technique in Isolated Hepatic Perfusion. *Ann Surg Oncol* 2008 accepted.
53. Verhoef C, de Wilt JHW, Verheul HM. Angiogenesis inhibitors: perspectives for medical, surgical and radiation oncology. *Curr Pharm Des.* 2006;12(21):2623-30.
54. Llovet J, Ricci S, Mazzaferro V, *et al.* Sorafenib improves survival in advanced HCC: Results of a phase III randomized placebo-controlled trial (SHARP-trial). *JCO* 2007;25(18S):LBA1.
55. Amato RJ, Harris P, Dalton M, *et al.* A phase II trial of intra-patient dose-escalated sorafenib in patients with metastatic renal cell cancer. *JCO* 2007;25(18S):5026.

Chapter XII

Samenvatting en Conclusies

Nieuwe ontwikkelingen in Rotterdam

Het hepatocellulair carcinoom (HCC) is de meest voorkomende vorm van primair leverkanker. Van alle maligniteiten is het HCC wereldwijd de vijfde meest voorkomende maligniteit en staat het derde op de lijst van de meest voorkomende oorzaak van kanker gerelateerde mortaliteit. Jaarlijks worden er ongeveer 0.5 miljoen mensen gediagnosticeerd met een HCC.¹ De geografische spreiding van het HCC is opvallend met een hoge incidentie in Aziatische en in enkele Afrikaanse landen. In de westerse wereld is er een lage incidentie, met een geschatte mortaliteit van 5/100.000 inwoners/jaar.^{2,3} Er zijn recente publicaties die in een aantal ontwikkelde landen een stijging van de incidentie laten zien.⁴⁻⁶ Publicaties over epidemiologische cijfers, behandeling en prognose zijn vaak van subpopulaties.⁷⁻¹⁰ Deze cijfers kunnen minder relevant zijn. In **Hoofdstuk II** worden de resultaten beschreven van een studie naar de incidentie van het HCC in Nederland tussen 1989 en 2000. In Nederland is er een incidentie van 0.3/100.000/jaar voor vrouwen en 1.6/100.000/jaar voor mannen in het jaar 2000.¹¹ In tegenstelling tot andere publicaties van laag-incidentie landen kan op basis van dit onderzoek worden geconcludeerd dat er tussen 1989 en 2000 in Nederland geen stijging van incidentie bij de man of vrouw is waargenomen. Er was geen verandering in behandelingspatroon (1889-1998). Opvallend was dat 73% van de patiënten geen kanker-gerelateerde therapie kregen. Twaalf procent van de patiënten ondergingen een mogelijke curatieve behandeling middels levertransplantatie of een partiële leverresectie. Zonder adequaat screenings programma kan het zijn dat de diagnose in een te late fase wordt ontdekt om de curatieve opties nog te kunnen aanbieden. Echter, omdat een groot percentage van de patiënten onder controle zijn bij hun ziekenhuis i.v.m. onderliggende leverziekte, zoals virale en alcoholische levercirrhose, kan het eventueel zo zijn, dat er misschien een zekere terughoudend is om agressieve therapie aan te bieden, in de vorm van partiële leverresectie. Het lage percentage van 12%, suggereert dat patiënten met een HCC in een gespecialiseerd centrum moeten worden besproken.¹¹ In de nabije toekomst zal de behandeling van patiënten met een HCC in Nederland opnieuw worden geanalyseerd.

Iedere oorzaak van levercirrhose is een risicofactor voor het ontstaan op HCC. Hepatitis B en Hepatitis C zijn de meest bekende virale oorzaken en alcohol de meest bekende niet-virale oorzaak. Andere risicofactoren voor het ontstaan op HCC zijn haemachromatose, tyrosinaemia en aflatoxin B1.¹² Het is zeer waarschijnlijk dat er co-factoren bestaan die het ontstaan van HCC bevorderen bij de bekende risicofactoren. Daarbij ontstaat in de Westerse wereld het HCC in ongeveer 30% in een niet-cirrhotische lever. Bij deze groep tumoren ontbreekt vaak een van de bekende risicofactoren. In **Hoofdstuk III** wordt een potentiële risicofactor onderzocht. In 1994 werd gepubliceerd dat een infectie met een *Helicobacter Hepaticus* resulteerde in hepatitis en tumor groei in muizen.^{13,14} In 1997 werd een hogere prevalentie van IgG antilichaam tegen *Helicobacter Pylori* beschreven in patiënten met een levercirrhose dan in een controle groep.¹⁵ Meerdere studies hebben laten zien dat in een cirrhotische lever met HCC, *Helicobacter* DNA kan worden geïsoleerd, waarmee de suggestie wordt gewekt dat *Helicobacter* een rol speelt bij het ontstaan van HCC.¹⁶⁻²⁰ Het is nog onduidelijk of de aanwezigheid van *Helicobacter* een oorzaak of gevolg is van cirrhose. Om dit vraagstuk te onderzoeken werd er een studie verricht naar de aanwezigheid van een *Helicobacter* DNA in de niet cirrhotische lever van patiënten

met een HCC, en de aanwezigheid van dit *Helicobacter* DNA in de maag van diezelfde patiënten. Als controle groep werd leverweefsel gebruikt van patiënten met colorectale levermetastasen. In de groep van HCC patiënten werd significant vaker *Helicobacter* DNA in de lever gevonden dan bij patiënten met colorectale metastasen. Dit correleerde met de aanwezigheid van *Helicobacter* DNA materiaal in de maag. Sequentie analyse liet zien dat het *Helicobacter* DNA het meest paste bij dat van *Helicobacter Pylori*, met echter een consistente afwijking in 2 specifieke base paren (in 16SrDNA). Deze studie suggereert dat maag *Helicobacter* een rol kan spelen in de inductie van HCC, direct via colonisatie van de lever of indirect, via secretie van specifieke toxines door een *Helicobacter* in de maag.²¹

Afbeeldend onderzoek speelt een belangrijke rol in het stellen van de diagnose HCC. Toegepaste onderzoeken zijn echografie, angiografie, CT-scan en MRI. Naast deze technieken is er een toename van interesse in de ontwikkeling van in vivo methoden voor de bepaling van functionele parameters en metabolisme in normaal en aangedaan weefsel.^{24,25} Positron Emission Tomography (PET) met gelabelled deoxyglucose is een voorbeeld van zo'n techniek. De PET-scan is (nog) niet wereldwijd beschikbaar en is kostbaar in aanschaf. Een alternatief is de Single Photon Emission Computed Tomography (SPECT) en Positron Coincidence Detection (PCD).^{26,27} In **Hoofdstuk V** wordt een prospectieve studie beschreven over de diagnostische waarde van een SPECT/PCD en de uitkomst wordt vergeleken met die van echografisch en CT onderzoek van patiënten met verdenking op HCC. De resultaten van de PET-scan bij HCC, zoals tot op heden gerapporteerd, worden nader besproken. De SPECT/PCD heeft een lagere sensitiviteit dan de CT-scan voor intrahepatisch HCC. PET scan heeft evenmin additionele waarde voor detectie van intra-hepatische laesies. Een mogelijke waarde van PET in de diagnose van HCC kan zijn de detectie van extra-hepatische ziekte. Dit is optioneel en (nog) geen standaard beleid. Derhalve kan uit onze studie geconcludeerd worden dat PET/SPECT/PCD scan niet tot de standaard work-up hoort van het HCC.²⁸

De meest gebruikte tumor marker in het serum is het α foetoproteïne (AFP). Een grote case-control studie laat een sensitiviteit van 62% en een specificiteit 89% zien bij een grenswaarde van AFP >15 ng/mL. Bij een waarde > 200ng/ml wordt de sensitiviteit 22% met een specificiteit van 99%.²⁹ **Hoofdstuk VI** laat de sensitiviteit zien van het AFP bij patiënten met een HCC in een niet-cirrhotische lever. De patiënten die gezien zijn in het ErasmusMC met een HCC in een niet-cirrhotische lever, heeft 55% een AFP > 15 ng/ml.³⁰ Bij twijfel aan de diagnose kan een punctie worden overwogen om histologisch materiaal te verkrijgen indien dit klinische consequenties heeft. De kans op entmetastasen is tussen de 2 en 5%. Vals negatieve uitslag na een punctie van kleine tumoren kan oplopen tot 23%.³¹ Met name het onderscheid tussen het goed gedifferentieerde HCC en het adenoom is moeilijk. In **Hoofdstuk IV** worden de resultaten van een studie beschreven waarin de verschillen van biologische markers, DNA ploidy status en de proliferatieve capaciteit in adenomen, HCC

en dysplasie worden onderzocht. Op basis van deze studie kan er, indien het onderscheid tussen HCC en een adenoom moeilijk is, de diagnose worden ondersteund op basis van ploidy status en proliferatie karakteristieken.³²

Ondanks het hoog aantal patiënten met een HCC, blijft dit een moeilijk te behandelen klinisch probleem. In 1977 was een cirrhotische lever nog een contra-indicatie voor een partiële leverresectie. Tegenwoordig is het de behandeling van eerste keus bij patiënten met een gecompenseerde levercirrhose en HCC, in de aanwezigheid van donor schaarste. De prognose van patiënten met een HCC in een niet-cirrhotische lever is niet zo uitgebreid beschreven als die voor patiënten met een onderliggende cirrhotische lever. In de Westerse Wereld ontstaat het HCC in 30% zonder onderliggende levercirrhose. In **Hoofdstuk VI** worden de resultaten beschreven van de patiënten die zijn behandeld in het ErasmusMC. In deze studie was er een gemiddelde tumor diameter van 10 cm. In de gehele groep patiënten met een HCC in een niet cirrhotische lever was de grootte van de tumor niet bepalend voor de operabiliteit. Derhalve moet iedere patient met een HCC in een niet cirrhotische lever beoordeeld worden door een leverchirurg, ongeacht de grootte. Ondanks de grote gemiddelde diameter van deze tumoren, kunnen de meeste patiënten een partiële lever resectie ondergaan, met een in onze studie behaalde 5-jaars overleving van 68% in de geopereerde groep patiënten.

De patiënten met een onderliggende levercirrose worden strenger geselecteerd voor partiële lever resectie om de kans op behandelings-gerelateerde complicaties te verlagen.

Door ernstige levercirrhose, co-morbiditeit en/of multifocaliteit van de tumor, is tussen de 10 en 37% van de patiënten met een HCC geschikte kandidaten voor partiële leverresectie. Regionale en Lokaal Ablatieve therapieën zijn geaccepteerde alternatieve behandelingen bij patiënten met niet resectabele HCC's.

In **Hoofdstuk VII** worden de resultaten beschreven van interstitiele laser coagulatie bij patiënten met een HCC in een cirrhotische lever. Om de effectiviteit van de ILC te vergroten, hebben experimentele studies op varkens laten zien, indien de bloedtoevoer naar de lever tijdelijk wordt onderbroken, het gecoaguleerde gebied groter was dan zonder tijdelijke occlusie. Gebaseerd op deze resultaten is een prospectieve, klinische studie gestart de effectiviteit op locale controle te evalueren na ILC en tijdelijke arteriele occlusie, in patiënten met een HCC en onderliggende levercirrhose. De gehele procedure werd bij voorkeur percutaan verricht. In 19 van de 24 tumoren werd een complete tumor necrose vastgesteld dmv CT-scan. De meerderheid van de patiënten ontwikkelden nieuwe laesies elders (intra- of extrahepatisch).⁴⁵

Wereldwijd is RFA nu de meest gebruikte techniek. De resultaten van RFA in het ErasmusMC worden beschreven in **Hoofdstuk VIII**. Deze resultaten bevestigen de veiligheid van RFA echter benadrukken dat het succes vooral wordt bepaald door de grootte van de tumoren en geconcludeerd wordt dat RFA gebruikt kan worden voor tumoren < 3 cm.⁴⁶

Indien er een intrahepatisch recidief ontstaat, en dit is resectabel en/of te behandelen met een lokaal ablatieve methode, is dit een geaccepteerde behandeling en de eerste therapie keuze mits geen extrahepatische ziekte.³⁵ De meningen zijn meer verdeeld indien er sprake is van resectabel extra-hepatisch recidief. In **Hoofdstuk IX** worden de resultaten in het ErasmusMC besproken van de resecties van het extra-

hepatisch recidief van het HCC en de bestaande literatuur wordt onderzocht. Als eindconclusie kan gesteld worden dat indien een extra-hepatisch recidief kan worden gereserceerd, dit kan resulteren in lange-termijn overleving, onder voorwaarde dat er een optimale behandeling voor de primaire tumor kan worden verricht. Hersenmetastasen zijn hierop een uitzondering en moeten als “inoperabel” worden beschouwd. Verder onderzoek is nodig omdat publicaties ten aanzien van dit onderwerp schaars zijn en er geen gerandomiseerde trials zijn.³⁶

Systemische chemotherapie voor HCC is uitgebreid onderzocht en wordt als niet effectief gezien (palliatief danwel (neo)-adjuvant).⁴⁹ Enkele studies laten goede resultaten zien van Octreotide behandelingen in palliatieve setting echter de resultaten kunnen niet worden behaald in prospectieve gerandomiseerde studies. Er zijn maar een zeer gering aantal die gekeken hebben naar de aanwezigheid van somatostatine receptoren in het HCC. In **Hoofdstuk X** worden de resultaten beschreven van een studie naar de somatostatine receptoren in het HCC. In 67% van de patiënten met een HCC werd een somatostatine receptor subtype 2 (ssr-2) geconstateerd in de tumor. Op basis van dit onderzoek werd geen relatie gevonden met klinische, pathologische of biologische parameters en het aanwezig zijn van een ssr-2.⁵⁷

NIEUWE ONTWIKKELINGEN IN ROTTERDAM

Partiële leverresectie, orthotopie levertransplantatie (OLT), leverdonatie bij leven (LDLTx) en lokaal ablatieve methoden zijn de 4 curatieve opties die geboden kunnen worden in het ErasmusMC. Recent is de eerste leverdonatie bij leven verricht.⁴⁴ Er is een potentieel verschil in wachtlijst voor patiënten die een levertransplantatie moeten ondergaan tussen leverdonatie bij leven en OLT. Sommige centra hebben al gepostuleerd dat een leverdonatie bij leven de eerste keus zou moeten zijn bij patiënten met een HCC.⁴⁵ Recent zijn er ook meerdere artikelen verschenen die een inferieur resultaat lieten zien na LDLTx voor patiënten met een HCC. Omdat de wachttijd voor een orgaan, informatie kan geven over het biologisch gedrag van het HCC, is er een natuurlijke selectie met meer of minder agressieve HCC's gedurende de wachttijd. Patiënten met microscopische vaatingroei en vroege metastasen zullen geen voordeel hebben van een LDLTx vanwege het vroege recidief na transplantatie. Een wachttijd van 3 tot 6 maanden lijkt de aangewezen tijdsduur om patiënten te selecteren voor LDLTx.

Stereotactische Radiotherapie is een relatief nieuwe techniek met veelbelovende resultaten. De eerste ervaringen zijn gepubliceerd.⁴⁶ Mogelijk dat het gebruik van de “cyber-knife” in stereotactische radiotherapie de resultaten nog beter maakt. Vanuit pre-klinische studies weten we dat de angiogenese remmers additief en synergistisch kunnen werken in combinatie met radiotherapie^{47,48} Jain en collegae lieten in in-vivo experimenten zien dat bij gebruik van angiogenese remmers vasculatuur al-

Iereerst normaliseert en hiermee de tumor hypoxie opheft.⁴⁹ Winkler beschreef over hersen tumoren in een muizenmodel, dat het toedienen van angiogenese remmers de hypoxie afnam.⁵⁰ In de humane situatie kan men veronderstellen dat dit hetzelfde effect heeft en derhalve zou de combinatie van stereotactische radiotherapie en angiogenese remmers verder moeten worden onderzocht. Het gebruik van RFA zal in de komende jaren nog verder toenemen. De resultaten van RFA als “brug” naar transplantatie (ter voorkoming van progressie gedurende de wachttijd) en als potentiële curatieve optie in combinatie met TACE zullen worden geregistreerd in onze prospectieve database.

Sommige onderzoeksgroepen suggereerden het nut van geïsoleerde leverperfusie bij patiënten met een HCC⁵¹. De morbiditeit en mortaliteit van de ingreep is een groot nadeel van de procedure, en daarom is er terughoudendheid om de techniek wereldwijd toe te passen. Een nieuwe techniek voor geïsoleerde, hypoxische leverperfusie is ontwikkeld in het ErasmusMC, met een mediane operatie duur van 3.5 uur, minder dan 1 liter bloedverlies, zonder peri-operatieve mortaliteit. De eerste 25 patiënten zijn behandeld en het zou gebruikt kunnen worden bij patiënten met een HCC in de nabije toekomst.⁵²

De veelbelovende resultaten van de angiogene remmers in de behandeling van patiënten met een maligniteit kunnen niet meer worden genegeerd.⁵³ Voor patiënten met een gevorderd HCC, is een prospectieve studie lopende in het ErasmusMC waarbij er een randomisatie plaatsvindt tussen wel of geen thalomid gecombineerd met doxorubicine. Een andere angiogenese remmer is Sorafenib (Nexavar), een multi tyrosine kinase remmer. In een gerandomiseerde fase III studie (recent gepresenteerd op ASCO 2007) heeft Sorafenib een significant overlevings voordeel van 12 weken aangetoond bij patiënten met een niet resectabel HCC ten opzichte van een placebo.⁵⁴ Sorafenib werd tweemaal daags gegeven in een dosis van 400 mg. In 2.3% van de patiënten was er maar sprake van een partiele respons. Op hetzelfde congres werden de resultaten gepresenteerd van een studie waarbij de dosis Sorafenib werd verhoogd tot 2 daags 800 mg met beperkte toxiciteit en een hoger respons percentage bij patiënten met niercel carcinoom.⁵⁵ Gebaseerd op deze bevindingen, is er een vraag ontstaan of er bij patiënten met een HCC, een hoger respons percentage kan worden bereikt, indien de dosis Sorafenib wordt opgehoogd. Om dit te onderzoeken, proberen we een prospectieve studie op te zetten bij patiënten en een resectabel HCC met een stapsgewijze verhoging van Sorafenib in de wachttijd tot resectie. Verder zullen we participeren in Europese studies waarbij Sorafenib als adjuvante therapie wordt gegeven en in combinatie met RFA.

Referenties

1. Parkin DM, Bray F, Ferlay J, Pisani P. Estimating the world cancer burden: GLOBOCAN 2000. *Int J Cancer* 2001;94:153-156.
2. Ramsey WH, Wu GY. Hepatocellular carcinoma: Update on diagnosis and treatment. *Dig Dis* 1995;13:81-91.
3. Bosch FX, Ribes J. Epidemiology of liver cancer in Europe. *Can J Gastroenterol* 2000;14(7):621-630.
4. Taylor-Robinson SD, Foster GR, Arora S, Hargreaves S, Thomas HC. Increase in primary liver cancer in the UK, 1979-94. *Lancet* 1997;350:1142-43.
5. Deuffic S, Poynard T, Buffat L, Valleron AJ. Trends in primary liver cancer. *Lancet* 1998;351:214-15.
6. El-Serag HB, Mason AC. Rising incidence of hepatocellular carcinoma in the United States. *N Engl J Med* 1999;340(10):745-50.
7. Stuart KE, Anand AJ, Jenkins RL. Hepatocellular carcinoma in the United States. Prognostic features, treatment outcome and Survival. *Cancer* 1996;77:2217-2222.
8. Fong Y, Sun RL, Jarnagin W, Blumgart LH. An analysis of 412 cases of hepatocellular carcinoma at a Western center. *Ann Surg* 1999;229:790-800.
9. Zhou XD, Tang ZY. Management of hepatocellular carcinoma: long-term outcome in 2639 cases. *Gan To Kagaku Ryoho* 1997;24(suppl1):9-16.
10. Cance WG, Stewart AK, Menck HR. The national cancer database report on treatment patterns for hepatocellular carcinomas. *Cancer* 2000;88:912-920.
11. Verhoef C, Visser O, de Man RA, de Wilt JHW, Ijzermans JNM, Janssen-Heijnen MLG. *HCC in the Netherlands: incidence treatment and survival patterns*. *EJC* 2004;40:1530-8.
12. Schafer DF, Sorrell MF. Hepatocellular carcinoma. *Lancet* 1999;353:1253-57.
13. Fox JG, Dewhirst FE, Tully JG, Paster BJ, Yan L, Taylor NS, et al. *Helicobacter hepaticus* sp. nov., a microaerophilic bacterium isolated from livers and intestinal mucosal scrapings from mice. *J Clin Microbiol* 1994; 32:1238-1245.
14. Ward JM, Fox JG, Anver MR, Haines DC, George CV, Collins MJ, Jr, et al. Chronic active hepatitis and associated liver tumours in mice caused by a persistent bacterial infection with a novel *Helicobacter* species. *J Natl Cancer Inst* 1994; 86:1222-1227.
15. Siringo S, Vaira D, Menegatti M, Piscaglia F, Sofia S, Gaetani M, Miglioli M. High prevalence of *Helicobacter pylori* in liver cirrhosis. Relationship with clinical and endoscopic features and the risk of peptic ulcer. *Dig Dis Sci* 1997; 42:2024-2030.
16. Avenaud P, Marais A, Monteiro L, LeBail B, Bioulac Sage P, et al. Detection of *Helicobacter* species in the liver of patients with and without primary liver carcinoma. *Cancer* 2000; 89:1431-1439.
17. Ponzetto A, Pellicano R, Leone N, Cutufo MA, Turrini F, Grigionio WF, et al. *Helicobacter* infection and cirrhosis in hepatitis C virus carriage: is it an innocent bystander or a troublemaker? *Med Hypotheses* 2000; 54:275-277.
18. Nilsson HO, Mulchandani R, Tranberg KG, Wadstrom T. *Helicobacter* species identified in liver from patients with cholangiocarcinoma and hepatocellular carcinoma. *Gastroenterology* 2001; 120:323-324.
19. Magalhães Queiroz de DM, Santos A. Isolation of a *Helicobacter* strain from the human liver. *Gastroenterology* 2001; 121:1023-1024.
20. Dore MP, Realdi G, Mura D, Graham DY, Sepulveda AR. *Helicobacter* infection in patients with HCV-related chronic hepatitis, cirrhosis and hepatocellular carcinoma. *Dig Dis Sci* 2002; 47:1638-1643.
21. Verhoef C, Pot RG, de Man RA, et al. Detection of identical *Helicobacter* DNA in the stomach and in the non-cirrhotic liver of patients with hepatocellular carcinoma. *Eur J Gastroenterol Hepatol*. 2003 Nov;15(11):1171-4.
22. Wagner HN Jr, Conti PS. Advances in medical imaging for cancer diagnosis and treatment. *Cancer* 1991;67:1121-28.
23. Srauss LG, Conti PS. The applications of PET in clinical oncology. *J Nucl Med* 1991;32:623-48.
24. Van Lingen A, Huijgens PC, Visser FC, et al. Performance characteristics of a 511-keV collimator for imaging positron emitters with a standard gamma-camera. *Eur J Nucl Med* 1992; 19: 315-21.
25. Patton JA. Instrumentation for coincidence imaging with multihead scintillation cameras. *Semin Nucl Med* 2000; 30: 239-54.

26. Verhoef C, Valkema RA, de Man RA et al. Fluorine-18 FDG imaging in hepatocellular carcinoma using positron coincidence detection and single photon emission computed tomography. *Liver* 2002;22:51-56.
27. Trevisani F, D'Intino PE, Morselli-Labate AM, et al. Serum alpha-fetoprotein for diagnosis of hepatocellular carcinoma in patients with chronic liver disease: influence of HBsAG and anti-HCV status. *J Hepatol* 2001;34:570.
28. Verhoef C, de Man RA, Zondervan PE, Tilanus HW, IJzermans JNM. Good outcomes after resection of large hepatocellular carcinoma in the non-cirrhotic liver. *Dig Surg* 2004;21:380-386.
29. Hertz G, Reddy VB, Green L, et al. Fine-needle aspiration biopsy of the liver: a multicenter study of 602 radiologically guided FNA. *Diagn Cytopathol* 2000;23:326-328.
30. Van Dekken H, Verhoef C, Wink J, van Marion R, Vissers KJ, Hop WC, de Man RA, IJzermans JN, van Eijck CHJ, Zondervan PE. Cell biological evaluation of liver cell carcinoma, dysplasia and adenoma by tissue micro-array analysis. *Acta Histochem* 2005; 107(3):161-71.
31. Verhoef C, Kuiper JW, Heisterkamp J, de Man RA, Pattynama PM, IJzermans JNM. Interstitial laser coagulation with temporary hepatic artery occlusion for patients with cirrhosis and irresectable hepatoma. *Br J Surg* 2003;90(8): 950-955.
32. V.E. de Meijer, C. Verhoef, J.W. Kuiper, I.P.J. Alwayn, G. Kazemier, J.N.M. IJzermans. *Radiofrequency ablation in patients with primary and secondary hepatic malignancies*. *J Gastro Intest Surg* 2006: Jul-Aug;10(7):960-73.
33. Taura K, Ikai I, Hatano E, et al. Implication of frequent local ablation therapy for intrahepatic recurrence in prolonged survival of patients with hepatocellular carcinoma undergoing hepatic resection. An analysis of 610 patients over 16 years old. *Ann Surg* 2006;244:265-273.
34. Verhoef C, Holman FA, de Man RA, Hussain SM, IJzermans JNM. *Resection of extra-hepatic HCC can result in long term survival*. *Acta Chir Belg*. 2005 Sep-Oct;105(5):533-6.
35. Schwartz JD, Beutler AS. Therapy for unresectable hepatocellular carcinoma: review of the randomized clinical trials-II: systemic and local non-embolization-based therapies in unresectable and advanced hepatocellular carcinoma. *Anti-Cancer Drugs* 2004;15:439-452.
36. Rabe C, Pilz T, Allgaier, et al. Clinical outcome of a cohort of 63 patients with hepatocellular carcinoma treated with octreotide. *Z Gastroenterol* 2002;40:395-400.
37. Raderer M, Hejna MH, Muller C, et al. Treatment of hepatocellular cancer with the long acting somatostatin analog lanreotide in vitro and in vivo. *Int J Oncol* 2000;16:1197-201.
38. Dimitroulopoulos D, Xinopoulos D, Tsamakidis K, et al. The role of sandostatin LAR in treating patients with advanced hepatocellular cancer. *Hepatogastroenterology* 2002;49:1245-50.
39. Samonakis DN, Moschandreas J, Arnaoutis T, et al. Treatment of hepatocellular carcinoma with long acting somatostatin analogues. *Oncol Rep* 2002;9:903-7.
40. Kouroumalis E, Skordilis P, Thermos K, Vasilaki A, Moschandreas J, Manousos ON. Treatment of hepatocellular carcinoma with octreotide: a randomised controlled study. *Gut* 1998;42:442-447.
41. Yuen MF, Poon RT, Lai CL, et al. A randomized placebo-controlled study of long-acting octreotide for the treatment of advanced hepatocellular carcinoma. *Hepatology* 2003;36:687-91.
42. Allgaier HP, Becker G, Olschewski M, et al. Octreotide treatment in patients with advanced hepatocellular carcinoma: first results of the randomized placebo-controlled double blind Hector trial. *Hepatology* 2003;38:760A.
43. C Verhoef, H van Dekken, LJ Hofland, PE Zondervan, JHW de Wilt, R van Marion, RA de Man, JNM IJzermans, CHJ van Eijck. Somatostatin receptor in human hepatocellular carcinomas: genetic, patient and tumour characteristics. *Dig Surg* 2008 in press.
44. Slooff MJ, Kazemier G. Liver transplantation from a living donor *Ned Tijdschr Geneesk*. 2004 Nov 13;148(46):2257-9.
45. Gondolesi G, Munoz L, Matsumoto C, et al. Hepatocellular carcinoma: A prime indication for living donor liver transplantation. *J Gastrointest Surg* 2002;6:102-107.
46. Mendez Romero A, Wunderink W, Hussain SM, De Pooter JA, Heijmen BJ, Nowak PC, Nuytens JJ, Brandwijk RP, Verhoef C, IJzermans JN, Levendag PC. Stereotactic body radiation therapy for primary and metastatic liver tumors: A single institution phase i-ii study. *Acta Oncol*. 2006;45(7):831-7.
47. Teicher BA. A systems approach to cancer therapy. (Antioncogenics+ standard cytotoxics-->mechanism(s) of interaction). *Cancer Metastasis Rev* 1996; 15: 247-272.

48. Zips D, Krause M, Hessel F, Westphal J, Bruchner K, Eicheler W, *et al.* Experimental study on different combination schedules of VEGF-receptor inhibitor PTK787/ZK222584 and fractionated irradiation. *Anticancer Res* 2003; 23: 3869-3876.
49. Jain RK. Normalization of tumor vasculature: an emerging concept in antiangiogenic therapy. *Science* 2005; 307: 58-62.
50. Winkler F, Kozin SV, Tong RT, Chae SS, Booth MF, Garkavtsev I, *et al.* Kinetics of vascular normalization by VEGFR2 blockade governs brain tumor response to radiation: role of oxygenation, angiopoietin-1, and matrix metalloproteinases. *Cancer Cell* 2004; 6:553-563.
51. Feldman ED, Wu PC, Beresneva T, *et al.* Treatment of patients with unresectable primary hepatic malignancies using hyperthermic isolated hepatic perfusion. *J Gastrointest Surg.* 2004 Feb;8(2):200-7.
52. Verhoef C, de Wilt JHW, Brunstein F, *et al.* Isolated hypoxic hepatic perfusion with retrograde out-flow in patients with irresectable liver metastases; A New Simplified Technique in Isolated Hepatic Perfusion. *Ann Surg Oncol* 2008 accepted.
53. Verhoef C, de Wilt JHW, Verheul HM. Angiogenesis inhibitors: perspectives for medical, surgical and radiation oncology. *Curr Pharm Des.* 2006;12(21):2623-30.
54. Llovet J, Ricci S, Mazzaferro V, *et al.* Sorafenib improves survival in advanced HCC: Results of a phase III randomized placebo-controlled trial (SHARP-trial). *JCO* 2007;25(18S):LBA1.
55. Amato RJ, Harris P, Dalton M, *et al.* A phase II trial of intra-patient dose-escalated sorafenib in patients with metastatic renal cell cancer. *JCO* 2007;25(18S):5026.

NAWOORD

Vele mensen hebben een bijdrage aan de totstandkoming van dit proefschrift geleverd. Zonder hun hulp zou het niet gelukt zijn en daarom is de dank aan hen groot. Een aantal mensen wil ik toch in het bijzonder noemen. Ik had me voorgenomen om het nawoord zeer kort en bondig te houden. Tsjja, het is best lang geworden, story of my life.....

Allereerst mijn ouders die, ondanks allerei omzwervingen van hun jongste zoon, altijd net bleven doen, alsof ze er vertrouwen in hadden dat het wel goed zou komen.

Dank jullie wel!!!!!! Ik ben blij dat jullie er bij zijn.

Hooggeleerde heer IJzermans, beste Jan, dank om mij in aanraking te brengen met de lever- en transplantatiechirurgie. Wat heb ik nu bewondering voor je geduld (voor je technical skills had ik dat al), om mij destijds de technische vaardigheden van de lever- en transplantatie chirurgie bij te brengen. Daarbij lag een promotie-onderwerp op dit gebied voor de hand en dank dat je me destijds getipt hebt om het Hepatocellulair Carcinoom bij de hoorns te nemen onder jouw begeleiding.

Dr de Man, beste Rob, dank voor de kritische beoordelingen en zeer nuttige adviezen bij de geschreven artikelen; onmisbaar. Grote dank dat je als co-promotor mij terzijde hebt gestaan.

Hooggeleerde heren Kuipers, Eggermont en Tollenaar, beste Ernst, Lex en Rob, hartelijke dank voor de getoonde interesse en beoordeling van dit proefschrift.

De mede-auteurs van de gebruikte artikelen zijn van grote waarde geweest. Hoofdstuk 2 zou niet gelukt zijn zonder de hulp van de Intergrale Kanker Centra. Speciale dank gaat uit naar Prof dr Jan-Willem Coebergh en dr Marieke Janssen-Heijnen van het IKZ en dr Otto Visser van het IKN. Voor het artikel in hoofdstuk 3 heeft de MDL-onderzoeksgroep van dr Hans Kusters meer gedaan dan alleen maar alle bepalingen. Hans Kusters en Raymond Pot, veel dank voor jullie toewijding, geduld en grote inzet. Zonder alle scan beoordelingen, correcties en schrijfwerk van dr Roelf Valkema (nucleair geneeskundige), had Hoofdstuk 4 niet bestaan. De pathologie groep, o.a. bestaande uit Josiane Wink, Ronald van Marion, Kees Vissers hebben een grote bijdrage geleverd aan de hoofdstukken 5 en 10. De 2 pathologen, dr Herman van Dekken (hoofdstukken 5 en 10) en dr Pieter Zondervan (hoofdstukken 3, 5, 6 en 10) zijn meer dan alleen (co-)auteurs. De kunde van de interventie-radiologen is onmisbaar in onze dagelijkse praktijk. Ook voor de hoofdstukken 7 en 8 waren drs Jan Willem Kuipers, Prof dr Peter Pattynama van groot belang. Hoofdstuk 10 is tot stand

gekomen door een goede samenwerking met de groep van dr Leo Hofland (Endocrinologie). Verder wil ik mijn waardering uitspreken voor het vele werk van drs Fabian Holman en drs Vincent de Meijer. Joos Heisterkamp, groot dokter, groot doctor, en meest belangrijke persoon van hoofdstuk 7. Prof dr HW Tilanus, dr G Kazemier en dr IPJ Alwayn, gewaardeerde co-auteurs van hoofdstuk 6 en 8. Beste Huug, je enthousiasme en nimmer aflatende werklust zullen me altijd bij blijven. Dank voor je vele opleidings momenten, de "10M tijd" is onwisbaar! Beste Geert en Ian, naast co-auteurs ook participanten van de leverwerkgroep. Ik ben ervan overtuigd dat de sterkte van een werkgroep afhankelijk is van de individuen, en daarom mag de werkgroep zich gelukkig prijzen met jullie in de gelederen. Als laatste co-auteur, die nog niet genoemd is, wil ik dr Casper van Eijck bedanken. Casper, tijdens mijn opleidingstijd heb ik op vele vlakken veel van je geleerd. (ik wist al dat rood en wit DE kleuren waren) Ik ben blij dat ik nog steeds een "achterwacht" heb, waar ik voor klinische en chirurgisch-technische problematiek op terug kan vallen. (Jaja, die fles wijn komt echt nog wel)

Paranymfen: dr JHW de Wilt (tevens mede-auteur van dit proefschrift) en dr GD Slooter. Vrienden, oud collega-assistenten, golfgenoten, cabaretmakers, kaftdelers en vakbroeders in één. De zeer goede opleidingstijd in het Zuiderziekenhuis en het Dijkzigt, heeft o.a. een basis gelegd voor onze vriendschap. Ik ben zeer vereerd dat jullie aan mijn zijde willen staan. We hebben met zijn drieën al vele mooie momenten meegemaakt en ik hoop dat er nog vele zullen volgen!

Cas van Oort, Rudolf Tutein Nolthenius, Tom Gerard Pablo Piet Fred Collet. Dank aan jullie voor de bijna jaarlijkse "ruime week" sessies in Spanje te La Xara. Dag en nacht wordt er dan over wetenschap nagedacht en gesproken met zijn 4'en in de wei, aan de kaarttafel en rechtop in het mandje. Ik hoop oprecht dat we dit jaarlijkse uitstapje nog in lengte van jaren zullen doen, ondanks dat de promotie nu is afgerond.

Verder dank ik alle collegae chirurgen, assistenten en fellows, internisten, radiologen, radiotherapeuten, gynaecologen, urologen, medewerkers op de O.K., verpleegafdelingen en polikliniek in het ErasmusMC centrum lokatie en lokatie Daniel den Hoed voor de goede samenwerking. Veel dank aan het secretariaat in de DDHK. Het was de afgelopen jaren niet altijd rozegeur en bekende maneschijn door personeels tekort, maar het werk werd wel gedaan en de patiënten zijn vol lof over jullie. Toch nog een speciale dank aan Nelis, die altijd alle zaken regelde, ondanks alle chaos bij mij. Corine, sterkte..... en dank nu al voor al je inspanningen. Ik ben trots op de afdeling Chirurgische Oncologie en het geeft een goed gevoel om daarbij te mogen horen.

Omdat de voltooiing van het proefschrift enige tijd geduurd heeft, zijn er vele mensen geweest die interesse hebben getoond en op zeer stimulerende wijze hebben gevraagd wanneer het nu dan wel kwam. Een aantal wil ik toch nog even noemen; Prof

dr Henk Verheul (staat goed!), Xander van't Hoff, Eduard Prins, Gerrit Dekker, Stefan Nix en Peter Jan de Koning (t'is toch gewoon een scriptie?), mijn broer Rob en zus Marion (oh leuk, dan zie ik die en die eens!) en nog veel meer dierbaren.

Ja, nu kom ik bij jou, Heike. Misschien toch nog allereerst een paar woorden aan dr Laurens Stassen, de intimi zullen begrijpen waarom. Laurens, zeer veel dank voor de "tip". Je had er echter bij moeten zeggen dat ze Duits was.....

Heike, je bent het mooiste en belangrijkste in mijn leven en je hebt me het mooiste en belangrijkste in mijn leven gegeven; de drie fantastische jongens.

LIST OF PUBLICATIONS:

- Verhoef C, Topaz S, Topaz D, Golub D, Bishop N, Shelton A, Kolff WJ. Corrugated diaphragms for adult and baby-size artificial ventricles. *Artificial Heart 4, Heart Replacement*. Springer 1993:93-101.
- Verhoef C, van Eijck CH, Jeekel H. Preoperative bile duct drainage in patients with malignant obstructive jaundice- a Review. *Chir Gastroenterol* 1998;14:71-76.
- Verhoef C, Valkema R, de Man RA, Krenning EP, IJzermans JNM. 18FDG imaging in patients with HCC with positron coincidence detection and single photon emission computed tomography. *Liver* 2002;22:51-56. (**Chapter IV**)
- Verhoef C, Kuiper JW, Heisterkamp J, de Man RA, Pattynama PM, IJzermans JNM. Interstitial laser coagulation with temporary hepatic artery occlusion for patients with cirrhosis and irresectable hepatoma. *Br J Surg* 2003;90(8):950-5. (**Chapter VII**)
- Verhoef C, Pot R, De Man RA, Zondervan PEZ, Kuipers EJ, IJzermans JNM, Kusters JG. Detection of identical *Helicobacter* DNA in the stomach and in the non-cirrhotic liver of patients with hepatocellular carcinoma. *Eur J Gastroenterol Hepatol* 2003;15(11):1171-4. (**Chapter III**)
- DeWilt JH, van Etten B, Verhoef C, Eggermont AMM. Isolated hepatic perfusion: experimental evidence and clinical utility. *Surg Clinics North Am* 2004;84(2):627-41.
- van Etten B, Brunstein F, Van Ijken MG, Marinelli AW, Verhoef C, vder Sijp JR, Guestens G, De Boeck G, De Bruijn EA, de Wilt JH, Eggermont AMM. Isolated Hypoxic perfusion with orthograde or retrograde flow in patients with irresectable liver metastases using percutaneous balloon catheter techniques: A phase I and II study. *Ann Surg Oncol* 2004;11(6):598-605.
- Vermaas M, Ferenschild F, Verhoef C, Nuytens J, Wiggers T, Marinelli A, Eggermont AMM, JHW de Wilt. Pre-operative radiotherapy improves outcome of multimodality treatment in recurrent rectal cancer. *Dis Colon Rectum* 2005;48:918-28.
- Han-Geurts IJ, Verhoef C, Tilanus HW. Relaparotomy following complications of feeding jejunostomy in esophageal surgery. *Dig Surg*. 2004;21(3):192-6.
- Verhoef C, Visser O, de Man RA, de Wilt JHW, IJzermans JNM, Janssen-Heijnen MLGI. HCC in the Netherlands: incidence treatment and survival patterns. *EJC* 2004;40:1530-8. (**Chapter II**)
- Verhoef C, de Man RA, Zondervan PE, Tilanus HW, IJzermans JNM. Good outcomes after resection of large hepatocellular carcinoma in the non-cirrhotic liver. *Dig Surg* 2004;21:380-386. (**Chapter VI**)
- Verhoef C, Holman FA, de Man RA, Hussain SM, IJzermans JNM. Resection of extra-hepatic HCC can result in long term survival. *Acta Chir Belg*. 2005 Sep-Oct;105(5):533-6. (**Chapter IX**)
- Van Dekken H, Verhoef C, Wink J, Van Marion R, Vissers KJ, de Man RA, IJzermans JN, van Eijck CHJ, Zondervan PE. Cell biological evaluation of liver cell carcinoma, dysplasia and adenoma by microarray analysis. *Acta Histochem*. 2005;107(3):161-71. (**Chapter V**)
- Vermaas M, Ferenschild FT, Hofer SO, Verhoef C, Eggermont AM, de Wilt JH. Primary and secondary reconstruction after surgery of the irradiated pelvis using a gracilis muscle flap transposition. *Eur J Surg Oncol*. 2005 Nov;31(9):1000-5.
- Ferenschild FT, Vermaas M, Hofer SO, Verhoef C, Eggermont AM, de Wilt JH. Salvage abdominoperineal resection and perineal wound healing in local recurrent or persistent anal cancer. *World J Surg*. 2005 Nov;29(11):1452-7.
- Grunhagen DJ, de Wilt JH, van Geel AN, Graveland WJ, Verhoef C, Eggermont AM. TNF dose reduction in isolated limb perfusion. *Eur J Surg Oncol*. 2005 Nov;31(9):1011-9.
- Grunhagen DJ, de Wilt JH, Verhoef C, van Geel AN, Eggermont AM. TNF-based isolated limb perfusion in unresectable extremity desmoid tumours. *Eur J Surg Oncol*. 2005 Oct;31(8):912-6.

- Verhoef C, Kazemier G. Hepatocellular Carcinoma, a surgical perspective. *Daniel den Hoed Cancer News* 2005;3:23-24.
- van Akkooi AC, de Wilt JH, van Geel AN, Verhoef C, Eggermont AM. [Sentinel lymph node biopsy for melanoma: prognostic value and disadvantages in 300 patients] *Ned Tijdschr Geneesk*. 2005 Nov 5;149(45):2538-9.
- van Akkooi AC, de Wilt JH, Verhoef C, Graveland WJ, van Geel AN, Kliffen M, Eggermont AM. High positive sentinel node identification rate by EORTC melanoma group protocol. Prognostic indicators of metastatic patterns after sentinel node biopsy in melanoma. *Eur J Cancer* 2006 Feb;42(3):372-80.
- Grunhagen DJ, de Wilt JH, Graveland WJ, Verhoef C, van Geel AN, Eggermont AM. Outcome and prognostic factor analysis of 217 consecutive isolated limb perfusions with tumor necrosis factor-alpha and melphalan for limb-threatening soft tissue sarcoma. *Cancer*. 2006;106:1776-84.
- Han-Geurts IJM, van Geel AN, van Doorn L, den Bakker M, Eggermont AM, Verhoef C. Aggressive angiomyxoma: multimodality treatments can avoid mutilating surgery. *Eur J Surg Oncol*. 2006;32:1217-21.
- ACJ van Akkooi, C Verhoef, AN van Geel, AM Eggermont, JHW de Wilt. Sentinel node biopsy for clear cell sarcoma. *Eur J Surg Oncol*. 2006;32:996-9.
- M Vermaas, FTJ Ferenschild, JJ Nuyttens, AWKS Marinelli, T Wiggers, JR van der Sijp, C Verhoef, WJ Graveland, AM Eggermont, JHW de Wilt. Präoperative strahlentherapie verbessert das ergebnis bei rezidiven eines rektumkarzinoms. *Coloproctology* 2006; 28:85-96.
- Verhoef C, de Wilt JHW, Verheul HMW. Angiogenesis Inhibitors: Perspectives in Medical, Surgical and Radiation Oncology. *Current Pharmaceutical Design* 2006; 12(21): 2623-2630.
- M. Vermaas, C. Verhoef, J.W. Kuiper, A.M.M. Eggermont, J.H.W de Wilt. Utility of Repeat - radiofrequency ablation to provide long-term local control in recurrent rectal cancer. *Surgery* 2006 Jul;140(1):120.
- V.E. de Meijer, C. Verhoef, J.W. Kuiper, I.P.J. Alwayn, G. Kazemier, J.N.M. IJzermans. Radiofrequency ablation in patients with primary and secondary hepatic malignancies. *J Gastro Intest Surg* 2006; Jul-Aug;10(7):960-73. **(Chapter VIII)**
- van Akkooi AC, de Wilt JH, Verhoef C, Schmitz PIM, WJ, van Geel AN, Eggermont AM Clinical relevance of melanoma micrometastases (<0.1 mm) in sentinel nodes: are these nodes to be considered negative? *Ann Oncol*. 2006 Oct;17(10):1578-85.
- Ferenschild FT, Vermaas M, Nuyttens JJ, Graveland WJ, Marinelli AW, van der Sijp JR, Wiggers T, Verhoef C, Eggermont AM, de Wilt JH. Value of intraoperative radiotherapy in locally advanced rectal cancer. *Dis Colon Rectum*. 2006 Sep;49(9):1257-65.
- Mendez Romero A, Wunderink W, Hussain SM, De Pooter JA, Heijmen BJ, Nowak PC, Nuyttens JJ, Brandwijk RP, Verhoef C, IJzermans JN, Levendag PC. Stereotactic body radiation therapy for primary and metastatic liver tumors: A single institution phase-II study. *Acta Oncol*. 2006;45(7):831-7.
- Terkivatan T, Kliffen M, de Wilt JH, van Geel AN, Eggermont AM, Verhoef C. Giant solitary fibrous tumour of the liver. *World J Surg Oncol*. 2006 Nov 21;4:81.
- Han I, Hop W, Verhoef C, Tran KT, Tilanus HW. Randomized clinical trial comparing feeding jejunostomy with nasoduodenal tube placement in patients undergoing esophagectomy. *Br J Surg*. 2007 Jan;94(1):31-5.
- C Verhoef, BW Kuiken, JNM IJzermans, JHW de Wilt. Partial hepatic resection for liver metastases of non-colorectal origin, is it justified? *Hepatogastroenterology* 2007; 54:1517-21.

- Vermaas M, Ferenschild FT, Verhoef C, Nuyttens JJ, Marinelli AW, Wiggers T, Kirkels WJ, Eggermont AM, de Wilt JH. Total pelvic exenteration for primary locally advanced and locally recurrent rectal cancer. *Eur J Surg Oncol*. 2007; 33:432-8.
- de Wilt JH, van Leeuwen DH, Logmans A, Verhoef C, Kirkels WJ, Vermaas M, Ansink AC. Pelvic exenteration for primary and recurrent gynaecological malignancies. *Gyn Obstet Reprod Biol* 2007; 134:243-8.
- van Akkooi AC, Bouwhuis MG, van Geel AN, Hoedemaker R, Verhoef C, Grunhagen DJ, Schmitz PI, Eggermont AM, de Wilt JH. Morbidity and prognosis after therapeutic lymph node dissections for malignant melanoma. Morbidity and prognosis after therapeutic lymph node dissections for malignant melanoma. *Eur J Surg Oncol*. 2007 Feb;33(1):102-8.
- Verhoef C, de Wilt JHW, den Bakker MA. Giant Myositis Ossificans of the Leg. *Int J Surg Pathology* 2007; 15:170-71.
- Verhoef C, Nuyttens JJ, Plantingh AS, de Wilt JH. Neoadjuvant chemotherapy and resection of advanced synchronous liver metastases before treatment of the colorectal primary. *Br J Surg*. 2007 Jan 29;94(2):250-251.
- van Akkooi AC, de Wilt JH, Verhoef C, Schmitz PIM, WJ, van Geel AN, Eggermont AM. Importancia clinica de las micrometastasis de melanoma (<0,1 mm) en ganglios centinela: hay que considerar estos ganglios como negativos? *Ann of Oncol (Ed. Esp.)* 2007;4:25-32.
- de Wilt JHW, Vermaas M, Ferenschild FTJ, Verhoef C. Management of Locally Advanced Primary and Recurrent Rectal Cancer. *Clinics of Colon and Rectal Surgery* 2007; 20:255-63.
- Verhoef C, de Wilt JHW, IJzermans JNM. Behandeling van patiënten met colorectale levermetastasen. State of the art en de Nederlandse richtlijn. *Oncologie magazine* 2007;3:8-13.
- A Romero, W Wunderink, R. van Os, P. Nowak, B Heijmen, J Nuyttens, R Brandwijk, C Verhoef, J IJzermans, P Levendag, Quality of life after stereotactic body radiation therapy for primary and metastatic liver tumors. *Int J Radiat Oncol Biol Phys* 2007 [Epub ahead of print].
- C. Verhoef, Grunhagen DJ, de Wilt JHW, ten Hagen T, Eggermont AMM. Isolated limb perfusion with TNF in the treatment of limb sarcoma. *Curr Treat Options Oncol*. 2007 Dec 8; [Epub ahead of print].
- Verhoef C, ten Hagen TLM, de Wilt JHW, Eggermont AMM. Isolated liverperfusion; sunset or sunrise? *Surg Oncol Clinics North Am* 2008; in press.
- C Verhoef, H van Dekken, LJ Hofland, PE Zondervan, JHW de Wilt, R van Marion, RA de Man, JNM IJzermans, CHJ van Eijck. Somatostatin receptor in human hepatocellular carcinomas: biological, patient and tumour characteristics. *Dig Surg* 2008 in press. (**Chapter X**)
- Verhoef C, de Wilt JHW, Brunstein F, Marinelli AWKS, van Etten B, Vermaas M, Guetens G, de Boeck G, de Bruijn EA, Eggermont AMM. Isolated hypoxic hepatic perfusion with retrograde outflow in patients with irresectable liver metastases; A New Simplified Technique in Isolated Hepatic Perfusion. *Ann Surg Oncol* 2008 in press.
- A.C.J. van Akkooi, J.H.W. de Wilt, C. Verhoef, A.M.M. Eggermont. Isolated Tumor Cells in the Sentinel Node Affect Long-Term Prognosis of Patients with Melanoma *Ann Surg Oncol* 2008. in press.
- Mearadji, M.A. den Bakker, A.N. van Geel, A.M.M. Eggermont, S. Sleijfer, J. Verweij, J.H.W. de Wilt, Verhoef C. Decrease of CD 117 expression as possible prognostic marker for recurrence in the resected specimen after imatinib treatment in patients with initially unresectable Gastro Intestinal Stromal Tumors: a clinicopathological analysis. *Anti-Cancer Drugs* 2008.
- A.C.J. van Akkooi, J.H.W. de Wilt, C. Verhoef, A.M.M. Eggermont. Sentinel Lymph Node Biopsy in Cutaneous Melanoma: A Case-Control Study" *Ann Surg Oncol* 2008. in press.

- AFJ De Bruin, JJ Nuyttens, FTJ Ferenschild, AST Planting, C Verhoef, JHW de Wilt. Preoperative chemoradiation with capecitabine in locally advanced rectal cancer. *Neth J Med* 2008; in press.
- DJ Grünhagen, JHW de Wilt, AN van Geel, C Verhoef, AMM Eggermont. Isolated limb perfusion with tumour necrosis factor alpha and melphalan in locally advanced soft tissue sarcomas of the extremities. *Recent Results Cancer Res* 2008; in press.

|

Curriculum Vitae

CURRICULUM VITAE

Cornelis Verhoef werd geboren op 17 oktober 1966 te Dordrecht. Na het behalen van het diploma op het VWO "De Lage Waard" in Papendrecht, begon hij in 1986 alereerst met de studie economie en veranderde in 1987 naar de studie geneeskunde, aan de Erasmus Universiteit te Rotterdam, waar hij in 1994 zijn artsexamen behaalde (cum laude). Gedurende 1990 en 1991 heeft hij doorgebracht op het laboratorium van Prof Dr WJ Kolff, "the arteficial heart lab" in Salt Lake City, Utah, USA. In 1996 startte hij de opleiding tot chirurg in het toenmalige Zuiderziekenhuis (Opleider dr KJ Brouwer), tegenwoordig Medisch Centrum Rijnmond Zuid, locatie Zuider en in 1999 vervolgde hij de opleiding in het toenmalige Dijkzigt ziekenhuis (Opleiders Prof dr HA Bruining en Prof dr HJ Bonjer), tegenwoordig ErasmusMC, centrumlocatie. Na het afronden van de opleiding tot chirurg in 2002 heeft hij zich toegelegd op de bovenbuik- en transplantatiechirurgie (ErasmusMC te Rotterdam met een kleine uitstap naar Seoul/Korea en Kyoto/Japan). Vanaf maart 2003 is hij stafid in het Erasmus MC (Hoofd Prof dr JJ van Lanschot), op de locatie Daniel den Hoed Kliniek (Afdelingshoofd Prof dr AMM Eggermont). In het ErasmusMC zijn zijn aandachtsgebieden naast "alle" chirurgische oncologie, leverchirurgie, locoregionale perfusies, sarcomen/melanomen (waarvoor hij programmaleider is in het ErasmusMC) en het "advanced" colorectale carcinoom. Samen met Heike Buda en hun 3 prachtige zonen woont hij in Barendrecht.