

Harmonic long shears further reduce operation time in transanal endoscopic microsurgery

Pleun E. A. Hermsen · Ifesegun D. Ayodeji ·
Wim H. C. Hop · Geert W. M. Tetteroo ·
Eelco J. R. de Graaf

Received: 1 June 2008 / Accepted: 7 October 2008 / Published online: 6 December 2008
© The Author(s) 2008. This article is published with open access at Springerlink.com

Abstract

Background Previous research indicates that application of 5-mm harmonic shears rather than diathermia significantly reduces operation time in transanal endoscopic microsurgery (TEM). Frequently, however, additional instruments were required to complete resection. We investigated whether the new 5-mm harmonic long shears (H-LS) are better equipped for TEM compared with regular harmonic shears (HS).

Methods Between 2001 and 2006, 162 tumors (117 adenomas, 42 carcinomas, and 3 other tumors; mean distance 6.6 cm, mean area 40 cm²) were excised in 161 patients (82 men, 79 women; mean age 66 years).

Results Eighty-eight resections were performed with HS and 74 with H-LS. Tumor and patient characteristics were similar except for specimen area. Tumors resected by H-LS were on average smaller than those resected by HS (34.4 versus 44.1 cm²; Mann–Whitney *U*-test: $p = 0.027$). Mean operation time was 48 min and proportional to area in both

groups (univariate analysis of variance $p < 0.001$). Mean operation time was 54 min using HS and 41 min using H-LS (*t*-test: $p < 0.001$). After correction for area, operation time for H-LS was reduced by 14% compared with HS (*t*-test: $p < 0.001$). H-LS is singly capable of completing resection in 88% compared with 26% for HS (Mann–Whitney *U*-test: $p < 0.001$). Mean blood loss was 16 cc for HS and 3 cc for H-LS ($p < 0.001$). Morbidity (11%) and mortality (0.6%) were not different between the two groups (Fisher's exact test).

Conclusion Performing transanal endoscopic microsurgery with 5-mm harmonic long shears reduces operation time compared with regular shears, and completing resection seldom requires other instruments.

Keywords Transanal endoscopic microsurgery · TEM · Harmonic · Ultracision · Rectal Tumor · Rectal adenoma

Presented orally at the 15th International Congress at the European Association of Endoscopic Surgery in Athena, Greece, July 5th 2007.

P. E. A. Hermsen · G. W. M. Tetteroo · E. J. R. de Graaf (✉)
Department of Surgery, IJsselland Hospital,
Prins Constantijnweg 2, Capelle aan den IJssel 2906 ZC,
The Netherlands
e-mail: edgraaf@ysl.nl

I. D. Ayodeji
Department of Surgery, Maxima Medical Center,
Ds Th Flidnerstraat 1, Eindhoven 5631 BM,
The Netherlands

W. H. C. Hop
Department of Epidemiology and Biostatistics,
Erasmus Medical Center, Dr Molewaterplein 40,
Rotterdam 3015 GD, The Netherlands

Transanal endoscopic microsurgery (TEM) is a minimal invasive technique for local resection of rectal tumors. Because of the excellent results in safety and radicality and because of low rates of recurrence, TEM is the method of choice for resecting adenomas in the rectosigmoid [1–8].

Despite the attribution of negative properties to monopolar diathermia, such as capacitive coupling, burns, and thermal damage, it remains the preferred method for dissection in both open and endoscopic surgery [9–11]. The original TEM set applied a high-frequency knife for monopolar cutting and coagulation. Evolution of TEM technology resulted in a purpose-designed multifunctional tool with bipolar cutting and monopolar coagulation: the TEM 400 instrument (T400) [12, 13]. Other studies suggest use of regular endoscopic instruments in TEM, applying

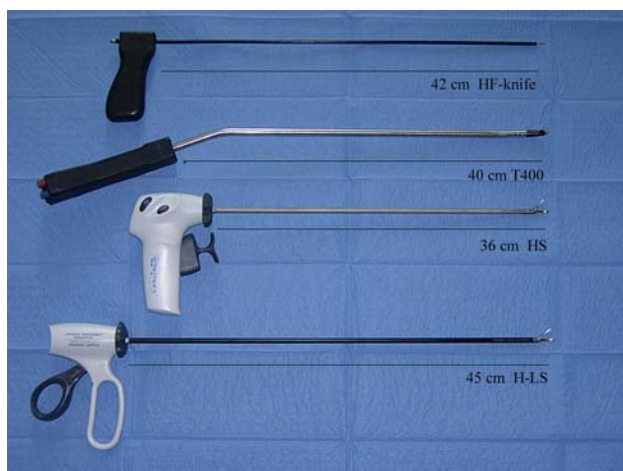

Fig. 1 HF-knife, monopolar diathermia T400, and bipolar instrument HS and H-LS ultrasonic instruments

ultrasonic technology [14, 15]. Several studies, both in vitro and in vivo, suggest that bipolar dissection is safer compared with monopolar diathermia [12, 13] and clinical studies show a reduction of tissue damage and operative time for ultrasonic dissection compared with monopolar diathermia [12, 14, 15] (Fig. 1).

Previous research comparing bipolar dissection and ultracision indicates that use of 5-mm harmonic shears (HS) in TEM results in a safe and successful procedure with a 26% reduction of operating time compared with bipolar electrocautery [15]. However, HS frequently failed to complete resection, requiring the application of an additional instrument such as the purpose-designed electrocautery T400. This was hypothesized to result from the limited HS shaft length failing to clear the rectoscope's optical system, hampering maneuverability (Fig. 2A).

Recently harmonic long shears (H-LS) have been developed for bariatric endoscopic surgery. These are an extended version of the regular HS (45 cm vs. 36 cm shaft). According to Ayodeji et al.'s conjecture this could

further accelerate operating time and reduce the number of cases in which additional instruments are required besides HS to complete resection.

In this prospective study, we compared the results of applying HS and H-LS, respectively, in TEM. Endpoints were operation time, safety, and ability to resect a tumor without help of additional instruments.

Material and methods

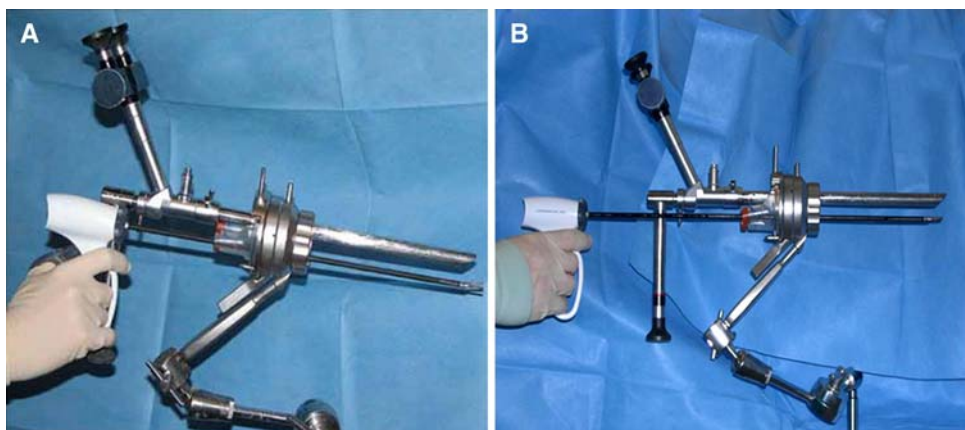
Study population

All patients were analyzed according to a standard protocol consisting of history, physical examination including digital rectal examination, blood tests, colonoscopy with biopsy, rigid rectoscopy, endorectal ultrasound, chest X-ray, and liver ultrasound. Rigid rectoscopy was performed to assess the tumor's exact distance from the dentate line, its location on the bowels circumference, and percentage of bowel circumference captured by the tumor.

The two groups of operations were defined based on the instrument intended to be applied in accordance with the intention-to-treat principle. TEM has been performed in the IJsselland Hospital since 1996. Initially, T400 was used until the introduction of HS in 2001 when a prospective study compared the results of both systems [15]. On the basis of estimation of cost-benefit ratio it was decided to use HS only in larger tumors. Where an additional instrument was required to complete resection, T400 was used. In 2005 H-LS was introduced and subsequently became the instrument of choice for all TEM procedures.

Endpoints were operation time, blood loss, and requirement for an additional instrument to complete resection. Operation time was defined as the period from the introduction of the TEM apparatus until completion of the last suture. Morbidity, mortality, and microscopic radicality were recorded as safety parameters. To determine radicality,

Fig. 2 A HS with rectoscope. B H-LS with rectoscope



the resected specimen was sampled horizontally and serially every 0.5 cm. Resection was considered radical when the disease-free margin was >1 mm. When the margin was ≤ 1 mm, the resection was considered irradical.

A total of 581 patients were prospectively collected in a database between January 1996 and November 2007. One surgeon (E.d.G) performed all TEM operations. All patients from September 2001 to March 2007 were extracted for this study. Before operating on the first patient included in this study, E.d.G. performed over 250 TEM procedures.

Instruments

TEM applies a rectoscope with a diameter of 4 cm and a length of 20 cm. It is introduced transanally. Instruments are introduced for dissection. Specially designed instruments such as the monopolar high-frequency knife [3] and the bipolar T400 multifunctional tool [13] are over 40 cm long in shaft length, slender, and have a curved tip (Fig. 1).

Harmonic shears (Ethicon Endo-Surgery, Cincinnati, OH, USA) apply a piezoelectric crystal to convert electrical energy into mechanical energy. This conversion takes place in the handpiece and the mechanical energy is then transferred to the tip of the active blade of the harmonic long shears. It vibrates longitudinally at 55,500 cycles per second. Tissue clamped in the tip is simultaneously dissected and coagulated when the instrument is activated. As using ultracision does not involve electrical current, resulting temperatures are relatively low ($<100^{\circ}\text{C}$), and desiccation and charring do not occur. Other advantages compared with electrosurgery include minimal lateral thermal spread and improved visibility due to the absence of smoke.

The initial ultracision harmonic shears (HS) (Ethicon Endo-Surgery, Cincinnati, OH, USA; www.ethicon.com) feature a shaft diameter of 5 mm and length of 36 cm. Their rotating shaft bears slightly curved blades with a length of 15 mm and a clamp arm. Harmonic long shears (H-LS) are a modification with a longer shaft (45 cm) (Figs. 1 and 2B). Both instruments have the innate ability to singly coagulate, cut, grasp, and dissect, barring the need for interchanging instrument.

Statistical analysis

For statistical analysis percentages and continuous data were compared using the chi-squared test and the Mann–Whitney *U*-test, respectively. Multiple regressions were used to evaluate factors simultaneously with regarding to their effects on operation time. The latter was logarithmically transformed. Correlations given are Spearman

coefficients. A *p* value of 0.05 was considered the limit of significance.

Results

Between September 2001 and July 2006, 162 tumors were excised in 161 patients. HS was used for 88 tumors and H-LS for 74 tumors. Tumor and patient characteristics were the same in both groups except for tumor area. Tumors resected by H-LS were smaller than those resected by HS (median area 34.4 cm^2 versus 44.1 cm^2 , $p = 0.027$) (Table 1).

Median operation time was 54 min for HS and 41 min for H-LS ($p = 0.005$) (Table 2, Fig. 3). Operation time was monovariately proportionate to area for the whole group ($p < 0.001$; correlation coefficient 0.770), and for both groups separately (H-LS $p < 0.001$, correlation coefficient 0.785; HS $p < 0.001$, correlation coefficient 0.739). After correction for tumor area, univariate analysis of variance showed a 14% reduction in operation time in favor of H-LS, regardless of tumor area ($p \leq 0.001$).

Generally blood loss was limited in both groups (overall range 0–200 ml). There was still a significant reduction where H-LS was applied (overall median 10 ml, H-LS median 3 ml; HS median 16 ml; $p \leq 0.001$) (Table 2). Blood loss was not proportionate to tumor area (HS: $p = 0.364$; H-LS: $p = 0.408$).

H-LS required an additional instrument in 12% of all cases, HS required this in 74% of the cases ($p < 0.001$) (Table 2). Only when using HS, increased tumor size, specifically increased rate of captured circumference, was associated with inability to complete resection without using an extra instrument (HS alone: median 30% of circumference; HS with help of an extra instrument: median 49% of circumference; $p = 0.020$). On the other hand, when using H-LS, tumor circumference was not a significant factor (H-LS alone: median 35% of circumference; H-LS with an extra instrument: 32% of circumference; $p = 0.196$). Neither rate of invasion ($p = 0.274$) nor distance from dentate line ($p = 0.244$) differed significantly for procedures where an additional instrument was required in order to complete resection in both groups.

Total morbidity was 13.5%. This was similar for both groups. A total of 16 patients (9.9%) experienced 17 minor complications: urinary tract infection in one patient, urinary retention in four patients, abscess in three patients, and postoperative blood loss in seven patients, suture line stenosis in one patients, and unexplained fever in one patient. All minor complications could be treated conservatively. Four major complications occurred in four patients (2.5%). Anastomotic dehiscence occurred in one patient. The resulting intraperitoneal abscess required laparotomy, resuturing, and temporarily diverting ileostomy.

Table 1 Patient and tumor characteristics

Total	All cases, <i>n</i> (range)	HS, <i>n</i> (range)	H-LS, <i>n</i> (range)	<i>p</i> Value
<i>n</i>	162	88	74	
Sex (male:female) ^a	82:79	43:45	39:35	NS
Age (years)	67 (35–95)	67 (35–95)	67 (44–87)	NS
ASA ^a				NS
1	85	43	42	
2	45	25	20	
3	27	19	8	
Histology				NS
Adenoma	117	63	56	
T1	27	14	13	
T2	15	11	4	
Other	3	0	3	
Distance (cm) ^{b,c}	6.6 (0–18)	7.1 (0–17)	6.1 (0–18)	NS
Tumor area (cm ²) ^c	39.8 (1.0–346.5)	44.1 (2.5–346.5)	34.4 (1.0–208.0)	0.027
Location				NS
Posterior	48	26	22	
Left lateral	42	25	17	
Right lateral	36	16	20	
Anterior	29	17	12	
Circular	4	3	1	
Circumference captured (%) ^c	40	40	40	NS

HS harmonic shears, H-LS harmonic long shears, NS not significant, ASA American Society of Anesthesiology

^a Number of patients = 161

^b From dentate line

^c Median

Table 2 Results

Total	All cases, <i>n</i> (range)	HS, <i>n</i> (range)	H-LS, <i>n</i> (range)	<i>p</i> Value
<i>n</i>	162	88	74	
Operating time (min) ^a	48 (5–260)	54 (13–260)	41 (5–125)	0.006
Blood loss (ml) ^a	10 (0–200)	16 (0–200)	3 (0–50)	<0.001
Extra instrument required to complete resection (%)	46%	74%	12%	<0.001
Morbidity				
Minor (%)	11.0%	8.0%	12.0%	NS
Major (%)	2.5%	3.4%	1.3%	NS
Mortality (%)	0.6%	1.0%	0%	NS
Histologic radicality (%)	85%	83%	88%	NS

HS harmonic 5-mm shears, H-LS harmonic long shears, NS not significant

^a Median

Two patients developed pneumonia. The fourth complication occurred in a case where simultaneously a right-sided hemicolectomy was performed. Postoperatively this patient sustained a cerebrovascular accident and anastomotic dehiscence of the right hemicolectomy. The latter was corrected by relaparotomy and construction of an ileostomy. After developing sepsis this patient eventually died. Overall mortality was one patient (0.6%) (Table 2).

All tumors but one were resected in one piece, rendering them suitable for determining microscopic radicality circumferentially. Microscopic radicality was 85% for all cases (H-LS 88%; HS 83%; ns). There was a comparable percentage of carcinoma and adenoma in the two groups (Table 1).

Discussion

TEM was first developed by G. Buess as recently as 1983 [1, 3, 16]. A growing group of surgeons presently perform the procedure and a substantial body of literature has been published on its various aspects. It is a safe technique for resecting lesions from the rectosigmoid regardless of the instrument used [14, 15, 17]. Our results sustain this.

The instruments applied in TEM in the initial setup proved time consuming. Ayodeji et al. described the significant 26% reduction in operative time that can be realized by applying ultracision HS in TEM rather than the bipolar T400 [15]. However, HS proved incapable of singly completing resection of the lesion in 50% of procedures

(and additional application of T400 was required). It was hypothesized that the HS shaft is too short to bridge the TEM optical system, causing the operators' hands to come into conflict with the scope, limiting maneuverability (Fig. 2A).

The recently introduced modified version of HS, the 5-mm harmonic long sheers (H-LS), features an extended 45-cm shaft, capable of clearing the TEM optic system (Fig. 2B). This study was motivated by the potential advantages of applying this instrument in TEM. Results illustrate that extension of the shaft resulted in a further 14% reduction in operation time, on top of the 26% reduction HS already achieved. Evidently, increased maneuverability makes it possible to excise tumors faster (Figs. 3 and 4A, B).

H-LS singly sufficed in 88% of TEM resections, a huge improvement in comparison to HS. Failure to complete resection in HS was related to circumference captured by the tumor area. For H-LS there was no relation between failure to complete resection and circumference. We ascribe this increased performance to the fact that the handles of the H-LS clear the rectoscope (Fig. 2A, B). This improved performance is achieved without concession in terms of safety and radicality of the TEM procedure as performed by the HS instrument.

The cause for the remaining failure to singly resect is believed to lie in the general design of H-LS. In order for an instrument to be applicable in TEM it not only requires a long slender shaft to bridge the optical system but also

requires a curved tip that projects the working end of the instrument into the surgeon's line of sight. In the case of ultracision, the curve in the active tip is far less pronounced than it is in the dedicated instruments. This is inherent to ultracision's design as the kinetic energy upon which this technology relies is a high-frequency longitudinal oscillation conducted from the hand piece, through the shaft in its solid core, to the tip. This longitudinal oscillation has to date not been transferred to an offset active tip for technical reasons. Although the curve of the H-LS is less than we deem desirable it remains an efficient instrument for performing TEM. This might be due to its bloodless dissecting, which makes the suction tube, and the space it occupies in the rectoscope, obsolete, thereby allowing more room for maneuvering (Fig. 4A, B). Changing the stereo optics for a single-monitor display as used in the Storz apparatus is another way of increasing maneuverability. In our opinion the Wolf apparatus outweighs this potential benefit [17].

We investigated whether the difference in tumor size between the studied groups could have compromised our results. We believe that the aforementioned differences in tumor area are the result of the fact that more patients are being referred to our hospital and they are referred in an earlier stage. Application of H-LS in every tumor, whereas HS was only applied in larger tumors, also contributed to this difference. Previous research agrees with our results, i.e., that operating time is proportionate to tumor area; the surface area of a lesion is monovariously indicative of the operation time needed for its resection [15]. Secondly operating time for larger tumors is further increased due to the implicit reduction in the bowel lumen, which reduces maneuverability, whereas there is a need for increased maneuverability of the instrument for resecting. Using an instrument that accelerates excision would give a larger absolute reduction of operation time when used to excise larger tumors. The difference in tumor size between our study groups was taken into account and does not compromise our results because it was corrected for statistically. Operating time reduction remained significant after correction.

Nothing is known about the correlation between operation time and learning curve in TEM, nor for the use of a new instrument in TEM. Data concerning learning curve and conversion rates in TEM show that, after performing 30 TEMs, the percentage of conversion to laparotomy decreases from 7.1% to 2.5%, with a further reduction to 1.2% after performing more than 100 TEMs [18]. Studies regarding the learning curve in complex laparoscopic colon surgery suggest that experience in 55 laparoscopic right hemicolectomies and in 62 left hemicolectomies is necessary to reach the plateau in the learning curve [19]. For complex laparoscopic colorectal surgery the learning curve

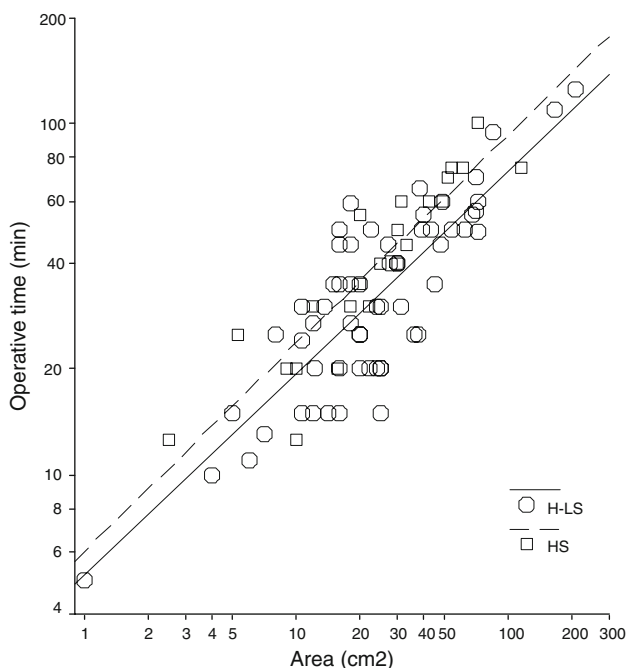



Fig. 3 Effect of area on operation time. Dotted and solid lines represent least-squares regression lines for HS and H-LS, respectively. Note the logarithmic scaling of both axes

Fig. 4 **A** Rectoscope with high-frequency knife (HF) suction tube, and forceps, showing degree of curvature to the tip of the instrument. **B** Rectoscope with H-LS, suction tube, and forceps, showing greater space for maneuverability and the tip of the H-LS, which is less curved compared with the HF



ranges from 30 to 80 cases [20–22]. Until further research determines the learning curve for TEM, one can assume that it consists of a comparable amount of cases. Whether the reduction in operating time is simply the result of the surgeon's learning curve in this series or the result of more feasible equipment we cannot know for sure. Since the surgeon followed an intensive training program in TEM [23] and performed over 250 TEMs before the start of this study, we think it likely that the reduction in operating time is an effect of the instrument rather than of the learning curve.

High costs for equipment and instruments may be one of the major reasons for the still limited use of TEM worldwide. Recent cost–benefit analysis shows that TEM is an extremely cost-effective approach for excision of selected rectal tumors, including rectal adenomas, compared with open resection [24]. Although a complete cost–benefit analysis was not performed in this study it is safe to say that the increased capacity to singly resect results in a reduction in costs such as those for sterilization, compounding the cost reduction achieved by reduced operating time. Furthermore these costs are low compared with those of open resection [24].

The modification of the shaft length is a clear improvement for its application in TEM. Further development of instruments and optics for optimally efficient operation may prove beneficial. The authors feel that it would be advantageous to provide the H-LS with manual control. The stereo optics used in TEM provides an excellent image but they are ergonomically taxing due to their position. This is far more the case than in open surgery or normal endoscopic surgery where the position of the surgeon is upright. Recent developments in high-definition cameras may provide an opportunity to resolve this aspect. This may further diminish operation time in TEM and increase H-LS's capacity to resect all tumors without help from additional instruments. These improvements may lead the way to discover more uses for rectoscope and instruments, for example, as port d'entrée in natural orifice transluminal endoscopic surgery (NOTES) [25].

Conclusion

The recently introduced extended harmonic long shears with a 45-cm shaft are more suitable for performing TEM than their 36-cm predecessor. Their application reduces operation time by 14% and increases the capacity to singly complete resection of lesions by TEM.

Open Access This article is distributed under the terms of the Creative Commons Attribution Noncommercial License which permits any noncommercial use, distribution, and reproduction in any medium, provided the original author(s) and source are credited.

References

1. Buess G, Theiss R, Hutterer F, Pichlmaier H, Pelz C, Holfeld T, Said S, Isselhard W (1983) Transanal endoscopic surgery of the rectum—testing a new method in animal experiments. *Leber Magen Darm* 13:73–77
2. Said S, Stippel D (1996) 10 years experiences with transanal endoscopic microsurgery. Histopathologic and clinical analysis. *Chirurg* 67:139–144
3. Buess G (1993) Review: transanal endoscopic microsurgery (TEM). *J R Coll Surg Edinb* 38:239–245
4. Cocilovo C, Smith LE, Stahl T, Douglas J (2003) Transanal endoscopic excision of rectal adenomas. *Surg Endosc* 17:1461–1463
5. Langer C, Liersch T, Markus P, Suss M, Ghadimi M, Fuzesi L, Becker H (2002) Transanal endoscopic microsurgery (TEM) for minimally invasive resection of rectal adenomas and “Low-risk” carcinomas (uT1, G1–2). *Z Gastroenterol* 40:67–72
6. Lev-Chelouche D, Margel D, Goldman G, Rabau MJ (2000) Transanal endoscopic microsurgery: experience with 75 rectal neoplasms. *Dis Colon Rectum* 43:662–667; discussion 667–668
7. Lezoche E, Guerrieri M, Paganini A, Feliciotti F, Di Pietrantonj F (1996) Is transanal endoscopic microsurgery (TEM) a valid treatment for rectal tumors? *Surg Endosc* 10:736–741
8. Smith LE, Ko ST, Saclarides T, Caushaj P, Orkin BA, Khanduja KS (1996) Transanal endoscopic microsurgery. Initial registry results. *Dis Colon Rectum* 39:S79–84
9. Gossot D (1998) Ultrasonic dissectors in endoscopic surgery. *Ann Chir* 52:635–642
10. Protell RL, Gilbert DA, Silverstein FE, Jensen DM, Hulett FM, Auth DC (1981) Computer-assisted electrocoagulation: bipolar vs. monopolar in the treatment of experimental canine gastric ulcer bleeding. *Gastroenterology* 80:451–455

11. Nduka CC, Super PA, Monson JR, Darzi AW (1994) Cause and prevention of electrosurgical injuries in laparoscopy. *J Am Coll Surg* 179:161–170
12. Kanehira E, Raestrup H, Schurr MO, Wehrmann M, Manncke K, Buess GF (1993) Transanal endoscopic microsurgery using a newly designed multifunctional bipolar cutting and monopolar coagulating instrument. *Endosc Surg Allied Technol* 1:102–106
13. Farin G (1993) Pneumatically controlled bipolar cutting instrument. *Endosc Surg Allied Technol* 1:97–101
14. Langer C, Markus P, Liersch T, Fuzesi L, Becker H (2001) UltraCision or high-frequency knife in transanal endoscopic microsurgery (TEM)? Advantages of a new procedure. *Surg Endosc* 15:513–517
15. Ayodeji ID, Hop WC, Tetteroo GW, Bonjer HJ, de Graaf EJ (2004) Ultracision Harmonic Scalpel and multifunctional tem400 instrument complement in transanal endoscopic microsurgery: a prospective study. *Surg Endosc* 18:1730–1737
16. Buess G, Kipfmuller K, Ibald R, Heintz A, Hack D, Braunstein S, Gabbert H, Junginger T (1988) Clinical results of transanal endoscopic microsurgery. *Surg Endosc* 2:245–250
17. Lirici MM, Di Paola M, Ponzano C, Huscher CG (2003) Combining ultrasonic dissection and the Storz operation rectoscope. *Surg Endosc* 17:1292–1297
18. Salm R, Lampe H, Bustos A, Matern U (1994) Experience with TEM in Germany. *Endosc Surg Allied Technol* 2:251–254
19. Tekkis PP, Senagore AJ, Delaney CP, Fazio VW (2005) Evaluation of the learning curve in laparoscopic colorectal surgery: comparison of right-sided and left-sided resections. *Ann Surg* 242:83–91
20. Schlachta CM, Mamazza J, Seshadri PA, Cadeddu M, Gregoire R, Poulin EC (2001) Defining a learning curve for laparoscopic colorectal resections. *Dis Colon Rectum* 44:217–222
21. Dincler S, Koller MT, Steurer J, Bachmann LM, Christen D, Buchmann P (2003) Multidimensional analysis of learning curves in laparoscopic sigmoid resection: eight-year results. *Dis Colon Rectum* 46:1371–1378; discussion 1378–1379
22. Bennett CL, Stryker SJ, Ferreira MR, Adams J, Beart RW Jr (1997) The learning curve for laparoscopic colorectal surgery. Preliminary results from a prospective analysis of 1194 laparoscopic-assisted colectomies. *Arch Surg* 132:41–44; discussion 45
23. Kipfmuller K, Buess G, Naruhn M, Junginger T (1988) Training program for transanal endoscopic microsurgery. *Surg Endosc* 2:24–27
24. Maslekar S, Pillinger SH, Sharma A, Taylor A, Monson JR (2007) Cost analysis of transanal endoscopic microsurgery for rectal tumours. *Colorectal Dis* 9:229–234
25. Whiteford MH, Denk PM, Swanstrom LL (2007) Feasibility of radical sigmoid colectomy performed as natural orifice transluminal endoscopic surgery (NOTES) using transanal endoscopic microsurgery. *Surg Endosc* 21:1870–1874