

Pulmonary wedge injections yielding left-sided echocardiographic contrast*

RICHARD S MELTZER, PATRICK W SERRUYS, JACKIE MCGHIE,
NELLIE VERBAAN, JOS ROELANDT

From the Thoraxcentre, Erasmus University, and Dijkzigt Hospital, Rotterdam, The Netherlands

SUMMARY Ultrasound contrast on the left side of the heart without the need for left heart catheterisation was achieved by hand injections of 8 to 10 ml 5 per cent dextrose solution through a catheter in the pulmonary wedge position. Injections were performed in 18 patients undergoing routine cardiac catheterisation and M-mode or two-dimensional echocardiography was used. An adequate wedge position was attained in 17 of the 18 patients. Nine had injections through Cournand catheters, three through Swan-Ganz catheters, and five through both. In 11 of these 17 patients left atrial or left ventricular echocardiographic contrast was seen immediately after wedge injection. Two patients showed diminished or absent contrast on later injections from the same position. Better results were obtained with the Cournand catheter (11/15 positive) than with the Swan-Ganz (1/8 positive) catheter. Pulmonary artery injections proximal to the wedge position did not cause left-sided contrast. No complications were observed. The safety of this method remains to be determined.

In the late 1960s, Gramiak and Shah¹ noted that indocyanine green and other solutions caused intracardiac ultrasonic contrast. They speculated that the source of this contrast was microbubbles of air. Since then, further work has more definitely identified the ultrasonic contrast targets to be microbubbles of air introduced during injection.²⁻³ Peripheral contrast echocardiology has become an important diagnostic technique.⁴⁻⁶ Normally, contrast injected peripherally or in the right side of the heart is entirely removed by the lungs, so contrast appearing on the left side of the heart implies an intracardiac right-to-left shunt or an intrapulmonary arteriovenous shunt. In the absence of these anatomical abnormalities, there has been no method of creating left-sided ultrasonic contrast without direct injection, requiring left heart catheterisation.⁷

Several years ago we unsuccessfully attempted to produce contrast in the left side of the heart using Swan-Ganz balloon catheters in the wedge position in six patients (unpublished data). The balloons were inflated during these wedge injections.

* This work was supported in part by grants from the Dutch Heart Association and Interuniversity Cardiology Institute, and in part by a Clinician-Scientist Award from the American Heart Association.

Received for publication 20 February 1980

Recently, Bommer *et al.*⁸ from Davis noted that forceful injections in the wedge position in dogs caused ultrasonic contrast on the left side of the heart. We undertook the present study to retest the hypothesis that pulmonary wedge injections may yield left-sided echocardiographic contrast in humans without known pulmonary or intracardiac shunts. Success in attaining left-sided contrast might allow more sensitive diagnosis of left-to-right shunts and better imaging of left-sided cardiac structures by echocardiography, thereby reducing the need in some cases for left heart catheterisation and radiological contrast angiograms.

Patients and methods

Eighteen patients undergoing right and left heart catheterisation for routine clinical indications were studied. There were eight men and 10 women. Their ages ranged from 20 to 67 years (mean 44 years). The diagnoses are listed in the Table.

Number 7 French Cournand or Swan-Ganz catheters were introduced via a right antecubital cutdown and advanced to the wedge position. This was attained without balloon inflation in any of the patients in whom Swan-Ganz catheters were used. Confirmation of wedge position was obtained by

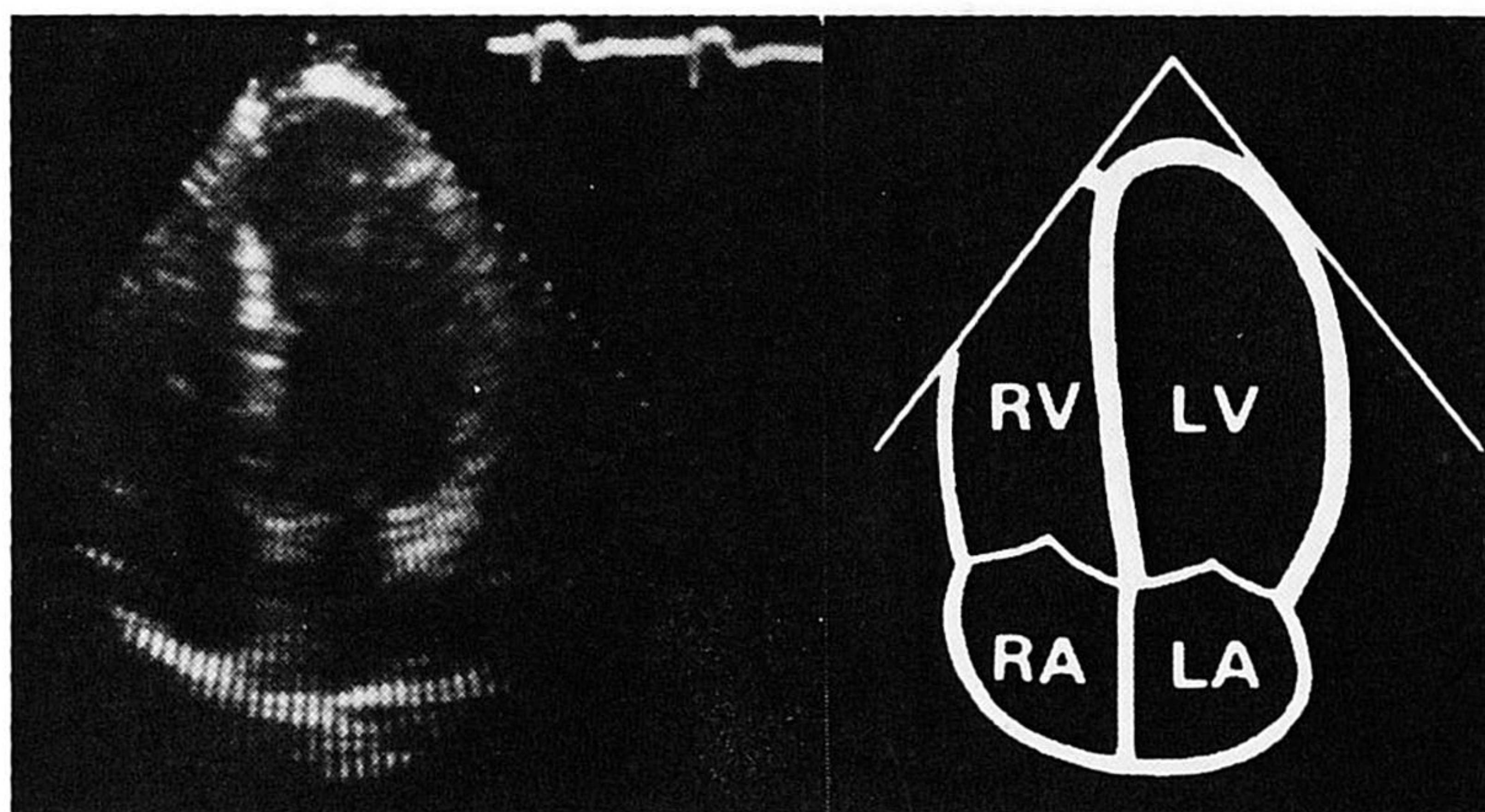


Fig. 1 Left—stop-frame photograph from the two-dimensional echocardiogram of a subject immediately before wedge injection. Apical four chamber view. Right—diagram of left-hand panel. Abbreviations: LA, left atrium; LV, left ventricle; RA, right atrium; RV, right ventricle.

fluoroscopy and pressure tracings. Three to seven rapid hand injections of eight to 10 ml 5 per cent dextrose solution were given during normal quiet respiration.

Echocardiographic imaging of the left heart during each injection was performed with the patient in either the supine or slight left lateral decubitus position. An Organon Teknika Echocardiovisor 01 M-mode instrument or a Toshiba SSH-10A phased array two-dimensional ultrasonograph was used.

The symptoms experienced by the patient during injection and subsequent stay in the catheterisation laboratory were carefully monitored, along with electrocardiogram and haemodynamic state. Most of the first 10 patients had post-catheterisation chest films, or lung scans in the anterolateral and left lateral positions between 12 and 36 hours after catheterisation.

Results

An adequate wedge position was attained in 17 of the 18 patients. In the patient in whom the wedge position could not be obtained (Table, case 4), right pulmonary artery injections failed to yield left heart echocardiographic contrast. In 11 of the 17 patients echocardiographic contrast was seen in the left heart immediately after wedge injection. Still frames from a two-dimensional echocardiogram before and immediately after wedge injection in one of these patients are shown in Fig. 1 and 2. Contrast is seen in the left ventricular cavity. Fig. 3 shows an M-mode study at the aorta-left atrial level from another subject, with appearance of contrast in the left atrium after wedge injection.

No patient developed symptoms, deteriorated clinically, or showed any haemodynamic or electrocardiographic changes after the wedge injections.

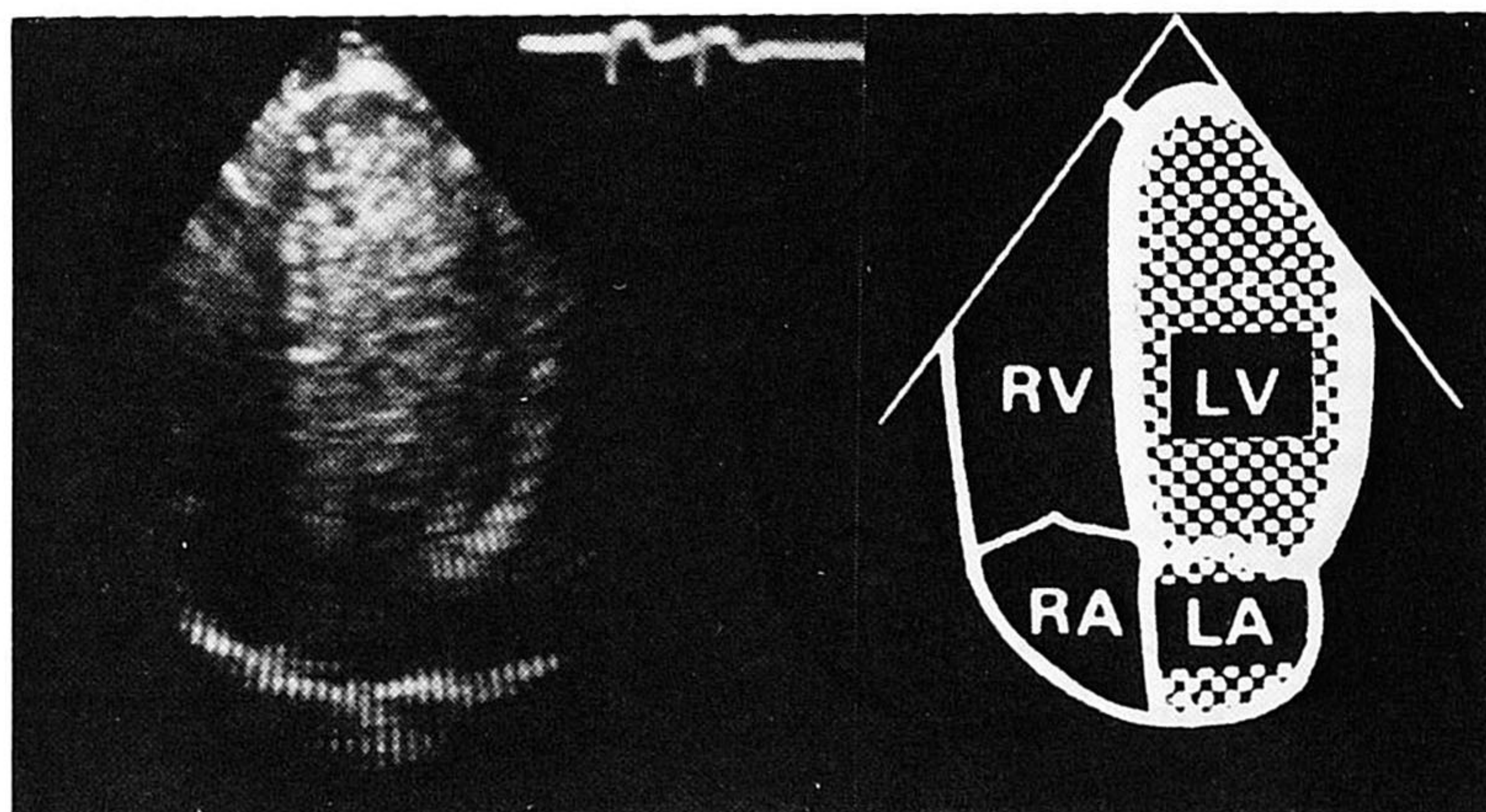


Fig. 2 Left—stop-frame photograph from the two-dimensional echocardiogram of the subject in Fig. 1, immediately after wedge injection. Apical four chamber view. Right—diagram of left-hand panel. Note contrast (shaded area) filling the left atrium and left ventricle. Abbreviations as in Fig. 1.




Fig. 3 M-mode tracing of a subject in the catheterisation laboratory immediately after wedge injection. Note the appearance of fine contrast in the left atrium (arrows). Abbreviations: Ao, aorta; LA, left atrium; RVOT, right ventricular outflow tract.

Chest films were taken between six and 24 hours after catheterisation in five of the first 10 patients studied and were compared with the pre-catheterisation films. None showed new lesions. Lung scans were also negative in the seven patients of the initial first 10 in whom they were performed.

All 17 patients in whom the wedge position was

attained had repeated injections. Six persistently showed no left-sided contrast, and two others showed a definite decrease in the amount of left-sided contrast on later compared to earlier injections. In these patients the catheter position was held constant. The other nine patients showed positive findings for three or more injections.

Table Patient data and outcome of wedge injections

Case no.	Age/sex	Diagnosis	PA pressure systolic/diastolic, mean	Mean wedge pressure	O ₂ saturation (%)		Contrast results	
					Arterial	Venous	Cournand	Swan-Ganz
1	54 M	AS/AR	32/16, 23	13	98	73	+	ND
2	44 M	CAD	×	6	98	×	+	ND
3	37 M	CAD	×	13	96	×	+	ND
4	20 F	ASD	30/16, 19	×	97	MV 62, PA 93	-	ND
5	21 F	Coarct	19/12, 15	7	97	80	-	-
6	48 F	Subvalv AS	21/8, 13	6	96	80	+	ND
7	59 F	CAD	×	×	97	×	+	ND
8	42 M	CAD, MR	19/7, 13	5	98	80	+	ND
9	67 F	AS/AR, MR	32/12, 20	14	95	73	+	ND
10	44 F	CAD	×	15	96	×	+	ND
11	33 F	AR/MR	×	15	×	×	+	ND
12	48 M	CAD	29/15, 21	14	96	75	ND	-
13	51 M	AS/AR	54/22, 34	15	96	70	ND	-
14	50 M	CAD	23/6, 13	7	96	84	ND	-
15	37 F	MS	×	14	×	×	-	-
16	49 F	MS/MR	48/20, 35	31	95	77	-	-
17	31 M	CAD	27/15, 20	15	96	77	+	-
18	58 F	MS/MR	83/33, 54	27	93	67	-, +	+

All pressures are in mmHg.

Abbreviations: AS, aortic stenosis; AR, aortic regurgitation; CAD, coronary artery disease; ASD, atrial septal defect; Subvalv, subvalvular; MR, mitral regurgitation; MS, mitral stenosis; MV, mixed venous; PA, pulmonary artery; ND, injection not done with this catheter. ×, information not obtained or not available; +, left-sided contrast attained; -, no left-sided contrast seen.

Eleven positive studies were obtainable using a Cournand catheter (Table). Injections in an initial position were negative in one patient (case 18) through a Cournand catheter, but became positive after its position was changed. Only one of the eight studies performed with a Swan-Ganz catheter was positive (case 18). Three patients had negative studies with both catheters (cases 5, 15, 16). Except for the patient in whom wedge position could not be obtained (case 4), who had an atropic septal defect, none of the 18 patients had intracardiac shunts. No right-sided contrast was seen after either wedge injections or pulmonary artery injections.

We had the subjective impression that the left-sided contrast was finer than that seen in the right heart after peripheral injections. This finding can be noted in Fig. 3.

Discussion

The results of this study show that in the majority of subjects rapid hand injections in the wedge position cause echocardiographic contrast on the left side of the heart. This could be of help in excluding a left-to-right shunt when performing a right-sided catheterisation as a quick and simple alternative to a saturation run. Its sensitivity needs to be determined, but the high success rate of peripheral venous contrast echocardiography in imaging right-to-left shunts suggests that left-to-right shunts might be very sensitively detected. The high success rate of echocardiographic detection of left-to-right shunting after intracardiac injections leads to the same conclusion.

While it seems likely that the pulmonary capillary "sieve" effect is overcome by rapid wedge injections the exact mechanism by which wedge injections transmit microbubbles through the pulmonary capillary bed is uncertain. Perhaps capillaries are dilated by the force of injection, or, alternatively, the short transit time permits microbubbles which are small enough to pass through pulmonary capillaries and which normally rapidly dissolve because of surface tension effects, to survive long enough to reach the left side of the heart. The "fineness" of the echocardiographic contrast observed in our patients suggests that passage through the pulmonary capillaries alters the microbubble content of the blood but this is a subjective observation and very dependent on individual control settings.

There was no obvious factor apart from the use of the Cournand catheter which strongly correlated with the successful achievement of contrast. Age, sex, diagnosis, pulmonary artery or pulmonary

wedge pressure, and arterial and venous oxygen saturations were similar in the groups with successful and unsuccessful studies. Catheter position may be important, for in one patient (case 18) previously negative left-sided contrast was followed by a positive study after catheter repositioning. Injection technique, too, may influence results, especially in regard to the force of injection and the possibility of the inclusion of tiny amounts of air with each bolus.

The technique has not yet been shown to be totally safe, but there are reasons to expect that with care serious complications are unlikely to occur. Firstly, the flushing of catheters in the wedge position in an attempt to improve wedge tracings is a not uncommon occurrence, and, secondly, microbubbles are probably routinely introduced during left-sided injections and flushing during catheterisation, as judged by echocardiography—indeed, echocardiographic contrast was first noted in this way.¹ There is no demonstrable harm attributable to these injections, and it is likely that the smaller microbubbles that pass the pulmonary capillary "sieve" are even less harmful. However, it is important to be aware of the potential hazards from wedge injections: these are (1) lung damage from too forceful an injection (excessive pressure in a pulmonary artery branch from a Swan-Ganz catheter balloon may cause pulmonary artery rupture⁹); (2) prolonged wedging, which may cause pulmonary infarction¹⁰; and (3) gas embolisation to the coronary, cerebral, or systemic circulations. Thus, a meticulous technique, particularly in excluding obvious air from the wedge injections, as in left-sided intracardiac injections, is mandatory. Until the safety of this technique has been more firmly established, therefore, it must be considered an experimental procedure.

The authors wish to thank Willem Gorissen for technical assistance.

References

- 1 Gramiak R, Shah PM. Echocardiography of the aortic root. *Invest Radiol* 1968; **3**: 356-66.
- 2 Barrera JG, Fulkerson PK, Rittgers SE, Nerem RM. The nature of contrast echocardiographic "targets" (abstract). *Circulation* 1978; **57** & **58**, suppl II: 233.
- 3 Meltzer RS, Tickner EG, Sahines TP, Popp RL. The source of ultrasonic contrast effect. *J Clin Ultrasound* 1980; **8**: 121-7.
- 4 Kerber RE, Kioschos JM, Lauer RM. Use of an ultrasonic contrast method in the diagnosis of valvular regurgitation and intracardiac shunts. *Am J Cardiol* 1974; **34**: 722-7.
- 5 Seward JB, Tajik AJ, Spangler JG, Ritter DG.

- Echocardiographic contrast studies. Initial experience. *May Clin Proc* 1975; **50**: 163-92.
- 6 Serruys PW, Hagemeyer F, Roelandt J. Echocardiological contrast studies with dynamically focussed multiscan. *Acta Cardiol* 1979; **34**: 283-90.
- 7 Serruys PW, van den Brand M, Hugenholtz PG, Roelandt J. Intracardiac right-to-left shunts demonstrated by two-dimensional echocardiography after peripheral vein injection. *Br Heart J* 1979; **42**: 429-37.
- 8 Bommer WJ, Mason DT, DeMaria AN. Studies in contrast echocardiography: development of new agents with superior reproducibility and transmission through lungs (abstract). *Circulation* 1979; **59** & **60**, suppl II: 17.
- 9 Golden MS, Pinder T Jr, Anderson WT, Cheitlin MD. Fatal pulmonary hemorrhage complicating use of a flow-directed balloon-tipped catheter in a patient receiving anticoagulant therapy. *Am J Cardiol* 1973; **32**: 865-7.
- 10 Hagemeyer F, Storm CJ. Fan-shaped shadows due to pulmonary artery catheters: heparin prophylaxis. *Br Med J* 1977; **ii**: 1124.

Requests for reprints to Dr Richard Meltzer, Thoraxcentre, Erasmus University, Box 1738, Rotterdam, The Netherlands.