

## **Effects of short-term administration of verapamil on left ventricular relaxation and filling dynamics measured by a combined hemodynamic-ultrasonic technique in patients with hypertrophic cardiomyopathy**

FOLKERT J. TENCATE, M.D., PATRICK W. SERRUYS, M.D., SIMON MEY, MSc,  
AND JOS ROELANDT, M.D.

**ABSTRACT** The effects of short-term administration of verapamil on left ventricular isovolumetric relaxation and early and late diastolic filling dynamics were studied in 10 patients with hypertrophic cardiomyopathy by a combined hemodynamic-ultrasonic technique. Left ventricular pressures (recorded with high-fidelity micromanometers) were determined simultaneously with M mode echocardiography. After 10 mg of verapamil was given intravenously (2 mg/min), left ventricular contractility and systolic pressure dropped significantly ( $p < .05$ ). Left ventricular  $dP/dt$  fell from  $1947 \pm 544$  to  $1489 \pm 334$  mm Hg/sec, maximal velocity of the contractile element at zero load fell from  $50 \pm 17$  to  $42 \pm 15$  1/sec, peak velocity contraction of the contractile element fell from  $37 \pm 10$  1/sec to  $29 \pm 10$  1/sec ( $p < .05$ ), and left ventricular systolic pressure fell from  $149 \pm 30$  to  $127 \pm 22$  mm Hg. Left ventricular negative  $dP/dt$  increased from  $1770 \pm 479$  to  $1477 \pm 377$  mm Hg/sec ( $p < .05$ ), and the time constant of isovolumetric pressure decay was prolonged from  $48 \pm 9$  to  $64 \pm 15$  msec ( $p < .05$ ). Left ventricular end-diastolic pressure rose from  $21 \pm 7$  to  $23 \pm 6$  mm Hg ( $p < .05$ ). The time constant of isovolumetric pressure decay was calculated in three different ways, but none of these measurements was influenced by verapamil. Time of isovolumetric relaxation, duration of rapid ventricular filling, and peak rate of left ventricular lengthening were not significantly influenced by verapamil and remained highly abnormal. In contrast, peak rate of left ventricular posterior wall thinning declined further after verapamil from  $2.9 \pm 1.2$  to  $2.4 \pm 1.4$  1/sec ( $p < .05$ ). The constructed pressure-dimension loops did not show any change after verapamil. Plasma levels of verapamil in eight of the 10 patients were in the therapeutic range ( $\bar{m}$ : 90 to 180 ng/ml); heart rate did not change. Our data indicate that abnormal relaxation and disturbed filling dynamics of the left ventricle persisted after short-term administration of verapamil. Further studies in well-defined subgroups of patients after long-term oral treatment with verapamil are needed to establish the merits of medical treatment of hypertrophic cardiomyopathy.

*Circulation* 68, No. 6, 1274-1279, 1983.

SEVERAL authors<sup>1,2</sup> have described a beneficial effect of verapamil on left ventricular diastolic filling and relaxation in patients with hypertrophic cardiomyopathy using different methods after both intravenous and oral administration of the drug. It has been

proposed from their findings that verapamil probably increases left ventricular "distensibility" in patients with this disease.<sup>3</sup> However, a direct pressure-dimension relationship could not be constructed from the presented data of either study. Therefore, we undertook a study using high-fidelity pressure measurements and M mode echocardiography simultaneously to assess the short-term effects of verapamil on left ventricular relaxation and filling. To our knowledge, this method has not been used before to determine the effects of verapamil in patients with hypertrophic cardiomyopathy.

From the Thoraxcenter, Erasmus University, Rotterdam, The Netherlands.

This study has been supported by grant 82.048 from the Dutch Heart Foundation, Sophialaan 10, 's-Gravenhage, The Netherlands.

Address for correspondence: Dr. F.J. TenCate, Cardiovascular Research, 23rd floor, P.O. Box 1738, Erasmus University, Rotterdam, The Netherlands.

Received April 12, 1983; revision accepted August 4, 1983.



## Methods

**Patients.** Ten patients with hypertrophic cardiomyopathy were studied (five men and five women, mean age 42.2 years) with M mode echocardiography (Echo-cardiovisor; Organon Teknika) and right and left cardiac catheterization (table 1). The diagnosis of hypertrophic cardiomyopathy was based on combined echocardiographic,<sup>4</sup> angiocardigraphic, and hemodynamic evaluation.<sup>5</sup> Echocardiography revealed that all patients had hypertrophied nondilated left ventricles without having any other acquired or congenital heart disease.<sup>6</sup> All of them had a disproportionate increase of the interventricular septum compared with the left ventricular posterior wall (ratio of interventricular septum to posterior wall  $\geq 1.3$ ), decreased systolic septal thickening (25% or less), and an abnormal left ventricular shape on two-dimensional echocardiographic imaging.<sup>4</sup>

Two-dimensional echocardiography revealed that left ventricular hypertrophy involved substantial portions of both the interventricular septum and left ventricular free wall.<sup>7</sup>

Left heart catheterization demonstrated a systolic pressure gradient in five patients at baseline, whereas one patient exhibited a gradient on provocation with the Valsalva maneuver. In the five patients with a systolic pressure gradient at baseline, this gradient increased after provocation by Valsalva maneuver or by atrial pacing.

No provocative tests were performed in one patient with a systolic pressure gradient of 104 mm Hg at baseline. The other patients did not exhibit a gradient at baseline or under provocation.

All drug treatment was discontinued at least 48 hr before our study of the effects of verapamil was undertaken. None of the patients had been treated by verapamil before. All patients were functionally limited at the time of study despite treatment with propranolol (mean dosage  $160 \pm 40$  mg/day). Nine of them were in functional class II and one was in functional class III according to criteria of the New York Heart Association.

Selection for the present study was based on lack of improvement of symptoms when treated with propranolol and, therefore, the patients were considered for treatment with verapamil<sup>3</sup> or for surgery.

Informed consent was obtained from all patients.

**Cardiac catheterization and angiography.** All patients underwent cardiac catheterization, which included complete hemodynamic evaluation, cineangiocardiology of the left ventricle, and selective coronary arteriography by Sones' technique.<sup>8</sup> Coronary arteriograms were judged by two independent observers. Resting gradients across the left ventricular outflow tract were determined by simultaneous registrations of left ventricular pressures by two tip-micromanometers (No. 7F; Millar) while one catheter was pulled back slowly under continuous fluoroscopy; left ventricular dP/dt (both positive and negative), maximal velocity of the contractile element at zero load ( $V_{max}$ ), and peak velocity contraction of the contractile element (peak  $V_{ce}$ ) were calculated on-line with an automated data processing system, which has been described earlier.<sup>9</sup> The time constant of isovolumetric pressure decay was measured after completion of the study from the left ventricular pressure tracings. This was done by plotting the natural logarithm of pressure against time after peak negative dP/dt. The time constant was calculated as the slope of this monoexponential curve during the first 40 msec after peak negative dP/dt ( $T_1$ ). The data obtained after the first 40 msec and until the level of the left ventricular end-diastolic pressure of the preceding beat were plotted the same way as  $T_1$  and revealed  $T_2$ . Also, when the asymptote ( $P_B$ ) of the monoexponential relationship of pressure against time was calculated by the formula  $P(t) = P_0 e^{-t/T_3} + P_B$ ,  $T_3$  was found ( $P_0$  = pressure at  $t = 0$ ;  $t$  = time). The method for calculation of this time constant of relaxation has been described in detail elsewhere.<sup>10</sup>

Provocative tests included a stress test of atrial pacing in incremental steps of 10 beats/min and the Valsalva maneuver. Left ventricular cineangiocardiology was recorded in the right and left anterior oblique projections to assess the presence of mitral incompetence. Reference levels for zero pressure measurements were taken at midthorax and were adjusted when necessary during the procedure by use of the fluid channel of the tip-micromanometer. The study of verapamil and its effect on left ventricular filling dynamics and relaxation was carried out as follows: left ventricular pressures, aortic pressures, left ventricular dP/dt, and electrocardiograms (three standard limb leads) were recorded on paper at high (200 mm/sec) and low speed as necessary. Left ventricular pressure and aortic pressure were determined simultaneously with the recording of electrocardiograms and M mode echocardiograms during baseline (control), during 5 min of verapamil infusion (2 mg/min), and for 15 min after completion of administration of the drug. Immediately after completion of the study, blood samples were drawn for determination of plasma levels of verapamil.

**Echocardiography.** M mode echocardiograms of the left ventricle were made in all patients at a paper speed of 50 mm/sec. We used a 0.5 inch diameter, 2.25 MHz transducer focused at 7.5 cm. The M mode echocardiograms were recorded in a standard fashion we described earlier.<sup>4</sup>

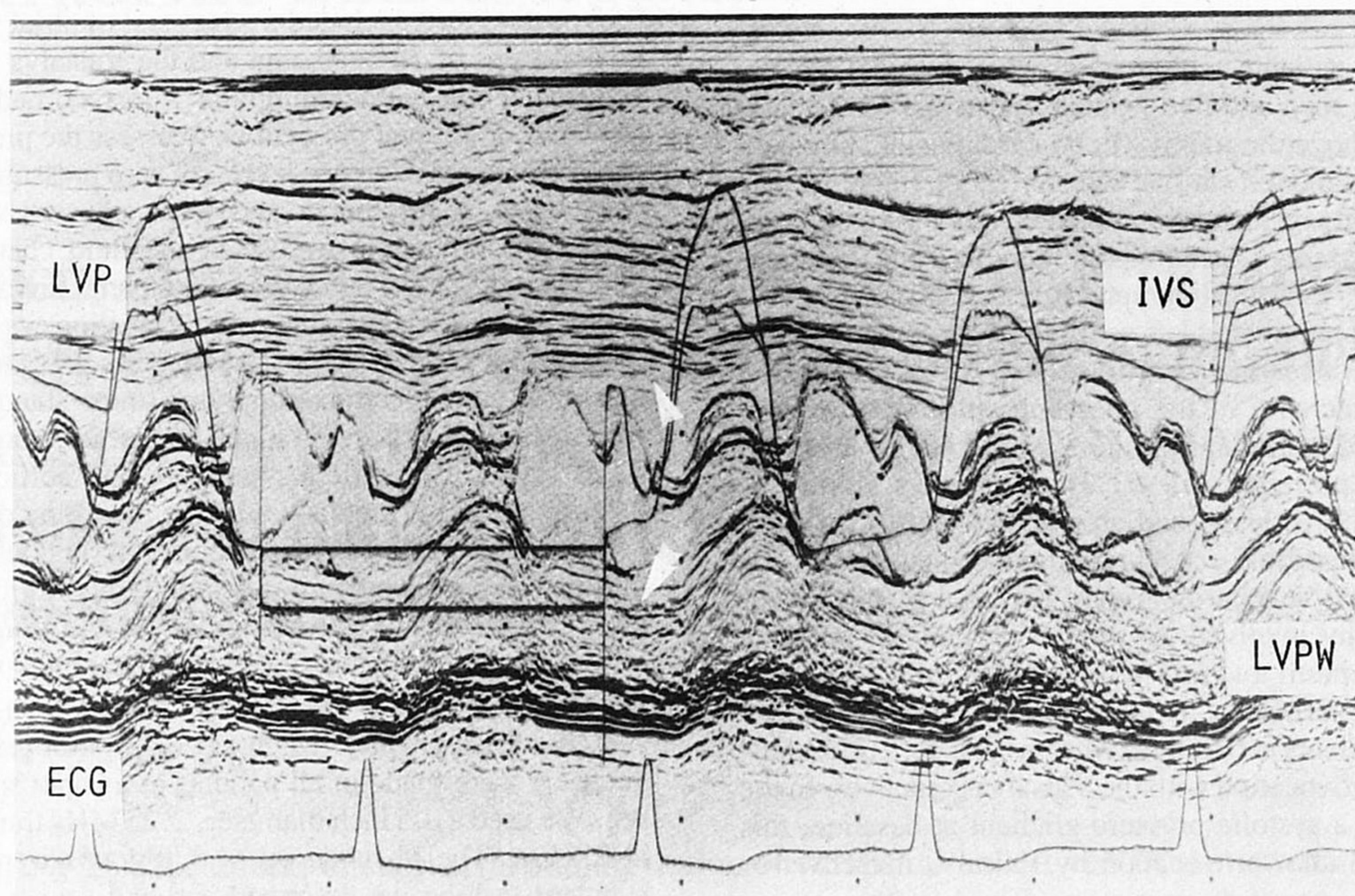
Briefly, during examination with the patient in the supine or slightly lateral decubitus position, several M mode sector scans were taken from the level of the aortic root across the left ventricular cavity to the left ventricular apex. The transducer was placed on the chest wall and was held perpendicularly when the largest amplitude of motion of the anterior mitral leaflet was recorded. The M mode echocardiograms of the left ventricle were always obtained at a level just below the tips of both mitral leaflets, and gain settings were continuously adjusted to obtain optimal resolution of endocardial surfaces of both interventricular septum and left ventricular posterior wall. The left ventricular and aortic pressures were recorded simultaneously with the recording of M mode echocardiograms and electrocardiograms. To analyze the same beats for left ventricular pressures and echocardiograms, "precise" timing by zero-calibration markers was used (see figure 1).

After completion of the study of the effects of verapamil, two-dimensional echocardiographic studies were performed for all patients with a Toshiba SSH-10A phased-array sector scanner with a 2.25 MHz transducer. These studies were obtained from the same position as the M mode transducer in a plane parallel to the long-axis of the left ventricle and by tilting the transducer 90 degrees for the short-axis cross section. This examination technique to obtain short-axis cross sections from various levels of the left ventricle for the determination of the extent and distribution of left ventricular hypertrophy in patients with hypertrophic cardiomyopathy has been described in detail elsewhere.<sup>7</sup>

All our patients showed extensive left ventricular hypertrophy involving substantial portions of the interventricular septum and left ventricular free wall that was comparable to group III left ventricular hypertrophy described by Maron et al.<sup>7</sup> Two-dimensional echocardiographic analysis therefore indicated that area of the posterior wall, as examined by M mode echocardiography, was involved in the hypertrophic (or cardiomyopathic) process.

**Analysis of M mode echocardiograms.** Earlier data of our laboratory show that in patients with hypertrophic cardiomyopathy, both rates of systolic thickening and thinning of the interventricular septum are reduced when compared with that of normal subjects (peak thinning rate: normal,  $3.0 \pm 1.3$  sec<sup>-1</sup>; hypertrophic cardiomyopathy,  $1.2 \pm 0.6$  sec<sup>-1</sup>;  $p < .005$ ). Normal values for rates of peak lengthening ( $3.4 \pm 0.6$  sec<sup>-1</sup>)





**FIGURE 1.** M mode echocardiogram and left ventricular and aortic pressures (calibrated). The beats directly after the zero calibration mark were used for combined analysis of pressure- and ultrasound-derived parameters of left ventricular diastolic function. Arrows indicate endocardial surface of the interventricular septum and left ventricular posterior wall. ECG = electrocardiogram; IVS = interventricular septum; LVPW = left ventricular posterior wall; LVP = left ventricular pressure.

and rates of posterior wall thinning ( $4.5 \pm 0.6 \text{ sec}^{-1}$ ) have also been obtained before from 15 normal individuals. We therefore restricted our study to the analysis of left ventricular internal dimension and posterior wall dynamics. The echocardiograms were calibrated at time intervals of 500 msec with 1 cm depth markers. Each parameter was calculated as the mean value of 5 digitized consecutive beats, and all were analyzed twice. The parameters for the endocardium of the left side of the interventricular septum and the left ventricular posterior wall were digitized with a hand-controlled crosswire cursor connected to a PDP 11/10 computer (16K words memory, disc and Decwriter) that yielded a continuous plot of change in left ventricular internal dimension and its first derivative.<sup>11</sup> Thereafter the parameters for the endocardium and epicardium of the left ventricular posterior wall were digitized. Continuous change in left ventricular posterior wall thickness and its first derivative were obtained in this way. The onset of the QRS complex on the electrocardiogram was taken as the zero reference point. All calculated values were normalized for their end-diastolic dimension and were expressed as seconds<sup>-1</sup> where appropriate.

The following parameters were calculated: end-diastolic left ventricular internal dimension (mm) and end-diastolic left ventricular posterior wall thickness (mm) measured at the onset of the QRS complex on the electrocardiogram; fractional shortening of left ventricular internal dimension (percent); end-systolic left ventricular internal dimension (mm) and end-systolic left ventricular posterior wall thickness (mm) measured at zero rates of lengthening and myocardial wall thinning; peak rate of lengthening of left ventricular internal dimension ( $\text{sec}^{-1}$ ) determined as the minimal value from the digitized M mode echocardiogram of left ventricular internal dimension; peak rate of thinning of the left ventricular posterior wall ( $\text{sec}^{-1}$ ) determined as the maximal value from the digitized M mode echocardiogram of the left ventricular posterior wall; time interval from end-systole to maximal rate of lengthening of left ventricular internal dimension ( $t_{\text{max dD/dt}}$  [msec]); isovolumetric relaxation (time from the incisura measured on the aortic pressure recording to opening of the mitral valve as determined by echo-

cardiography [msec]); rapid filling periods (from opening of mitral valve to 50% decrease in rate of left ventricular posterior wall thinning [msec]).<sup>1</sup>

**Construction of pressure-dimension loops.** After completion of the digitizing procedure for the various structures visualized by echocardiography, the left ventricular pressure was digitized both for control and after verapamil administration. This reveals construction of a loop of pressure vs dimension, which ideally should have a rectangular area.<sup>12</sup> Cycle efficiency was calculated as the ratio from the constructed loop vs the rectangular area and was also determined both for the control state and after verapamil administration. As has been described earlier, cycle efficiency actually indicates the stroke work of the left ventricle over the ranges of pressures and dimensions measured.<sup>12</sup>

**Statistical analysis.** Interobserver and intraobserver variability were calculated as variance of the means. Interobserver and intraobserver variability was 3% and 2% for left ventricular lengthening and 4% and 3% for left ventricular posterior wall thinning, respectively. Beat-to-beat variation for left ventricular lengthening and left posterior wall thinning were 4% and 7%, respectively. Statistical significance was assessed as means  $\pm$  2 SDs by Student's *t* test.<sup>13</sup>

## Results

The clinical and hemodynamic features of our patients are shown in table 1. Coronary arteriograms were normal in all.

In the five patients with a systolic pressure gradient at baseline (patient Nos. 2, 3, 7, 8, and 9), the magnitude of this gradient did not change in one (patient 3), decreased from 85 mm Hg to 70 mm Hg in patient 2, and decreased from 90 mm Hg to 80 mm Hg in patient 8. The systolic pressure gradient was abolished in pa-



**TABLE 1**  
Clinical and hemodynamic features

Patient No.	Age (yr)	Sex	Validity <sup>A</sup>	LV-Ao gradient (mm Hg)		LVEDP (mm Hg)	Mitral incompetence
				Resting	Provocation	(resting heart rate)	
1	51	M	II	0	0	15	Grade I
2	55	M	II	85	145	33	0
3	47	F	II/III	76	124	22	Grade I
4	30	M	II	0	0	20	Grade II
5	54	F	II	0	0	24	Grade II
6	55	M	II	0	45	19	0
7	27	M	II	70	140	10	0
8	33	F	II	90	120	12	0
9	30	F	II	104	No provocation	29	Grade I
10	45	F	II	0	0	18	Grade I

LV = left ventricular; Ao = aorta; LVEDP = left ventricular end-diastolic pressure.

<sup>A</sup>Validity is judged according to New York Heart Association criteria.

tient 7. In one patient (No. 9), this gradient increased from 104 to 200 mm Hg with a simultaneous drop in systemic systolic blood pressure from 95 to 50 mm Hg.

**Pressure-derived measurements.** Tables 2A and 2B show the results of the pressure-derived contraction and relaxation parameters before and after administration of verapamil. Table 2A shows that left ventricular end-diastolic pressure rose significantly from  $21 \pm 7$  to  $23 \pm 6$  mm Hg after verapamil ( $p < .05$ ). In all patients a slight but significant decrease in systolic systemic pressure (from  $120 \pm 5$  to  $100 \pm 5$  mm Hg ( $p < .05$ )) was seen. In addition, left ventricular contractility decreased, as can be seen from the various parameters that were determined: positive left ventricular dP/dt,  $V_{max}$ , and peak  $V_{ce}$ . Table 2B shows that negative left ventricular dP/dt significantly increased ( $p < .05$ ) after verapamil, and the time constant of

**TABLE 2A**  
Pressure-derived measurements before and after verapamil

	Before	After	p value <sup>A</sup>
LVEDP (mm Hg)	$21 \pm 7$	$23 \pm 6$	$<.01$
LVSP (mm Hg)	$149 \pm 30$	$127 \pm 22$	$<.05$
LV dP/dt (pos) (mm Hg/sec)	$1947 \pm 544$	$1489 \pm 334$	$<.05$
$V_{max}$ (l/sec)	$50 \pm 17$	$42 \pm 15$	$<.05$
Peak $V_{ce}$ (l/sec)	$37 \pm 10$	$29 \pm 10$	$<.05$
Heart rate (beats/min)	$85 \pm 19$	$81 \pm 16$	NS

LVEDP = left ventricular end-diastolic pressure; LVSP = LV peak systolic pressure; LV dP/dt = first derivative of left ventricular pressure; pos = positive;  $V_{max}$  = maximal velocity of contractile element at zero load; peak  $V_{ce}$  = peak velocity contraction of contractile element.

<sup>A</sup>p value by Student's t test (paired).

**TABLE 2B**  
Pressure-derived measurement before and after verapamil

	Before	After	p value
LV dP/dt (negative) (mm Hg/sec)	$1770 \pm 479$	$1477 \pm 377$	$<.05$
Time constant of relaxation			
T <sub>1</sub> (msec)	$48 \pm 9$	$64 \pm 15$	$<.05$
T <sub>2</sub> (msec)	$47 \pm 15$	$55 \pm 18$	NS
T <sub>3</sub> (msec)	$66 \pm 25$	$78 \pm 28$	NS
LV end-systolic pressure (mm Hg)	$88 \pm 22$	$78 \pm 10$	NS

See text for explanation of T<sub>1</sub>, T<sub>2</sub>, and T<sub>3</sub>.

relaxation was significantly prolonged. It is also evident from Table 2B that various measurements of the time constant did not change after verapamil.

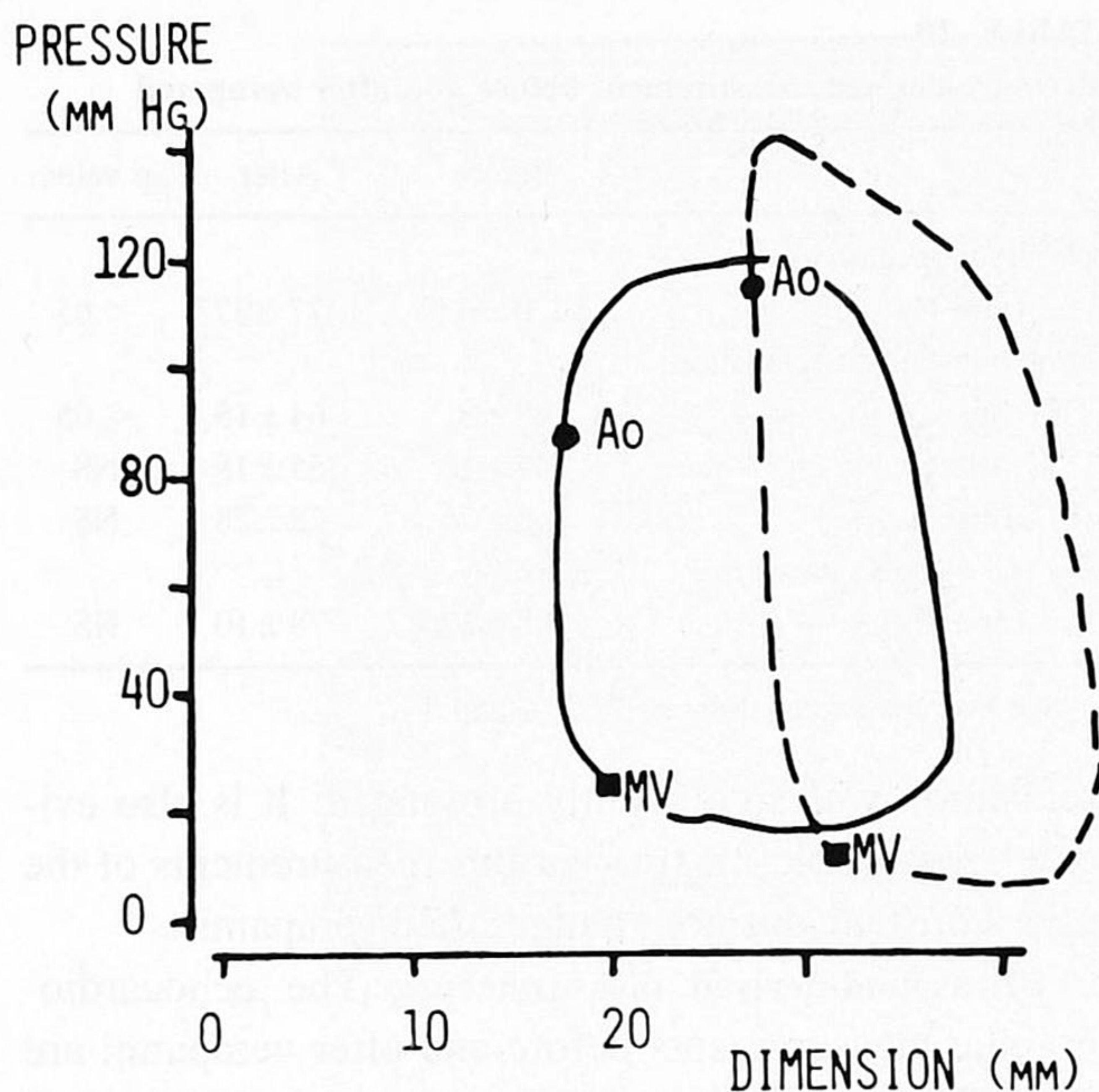
**Ultrasound-derived measurements.** The echocardiographic measurements before and after verapamil are shown in tables 3A and 3B. It is apparent that left ventricular dimensions and wall thicknesses at both end-diastole and end-systole were not influenced by verapamil. Also, fractional shortening and myocardial thickening were not changed. Although rate of left ventricular lengthening was not changed, peak rate of left ventricular posterior wall thinning decreased significantly from  $2.9 \pm 1.2$  to  $2.4 \pm 1.4$  sec<sup>-1</sup> ( $p < .05$ ). Other parameters of diastolic function such as isovolumetric relaxation time, rapid filling period, and t max dD/dt did not change either. None of the pressure-dimension loops for the patients shows any change compatible with an improved distensibility at any point in the cardiac cycle. Figure 2 shows a characteristic example of a pressure-dimension loop (patient 8); a leftward or upward diastolic shift compatible with decreased distensibility is shown. Cycle efficiency changed from 68% to 62% ( $p = NS$ ) after verapamil.

**Blood levels of verapamil.** In eight patients plasma levels of verapamil were determined, which varied from 90 to 180 ng/ml (therapeutic range, 60 to 140 ng/ml). In the other two patients, plasma levels of verapamil could not be determined.

## Discussion

It has been suggested that the beneficial effects of verapamil treatment are related to an increased left ventricular filling and improved relaxation resulting in an increased distensibility.<sup>1-3</sup> Hanrath et al.<sup>1</sup> found increased rates of left ventricular lengthening and posterior wall thinning after short-term administration of verapamil. Bonow et al.,<sup>2</sup> using radionuclide angiography, showed that peak rate of left ventricular filling increased and time to peak filling was reduced after oral verapamil treatment.





**FIGURE 2.** Representative pressure-dimension loop. Observe that after verapamil administration (solid line) the pressure-dimension loop has shifted leftward and upward for its diastolic portion, indicating decreased "distensibility." Ao = aortic valve closure determined from aortic pressure recording; MV = mitral valve opening determined from the echocardiogram. Broken line represents pressure-dimension loop before verapamil administration.

In contrast to these studies, we were not able to demonstrate an improvement in left ventricular relaxation nor filling after short-term administration of verapamil. This was true even though an effective dosage was achieved as demonstrated by the drop in left ventricular systolic pressures and contractility.

During early diastole, when left ventricular pressures and left ventricular dimensions were changing rapidly, both rates of relaxation and regional thinning were further impaired. Moreover, left ventricular end-diastolic pressure increased without a change in left ventricular dimension, indicating decreased distensibility.

These effects cannot be completely attributed to our patient selection because the relevant hemodynamic

**TABLE 3A**  
Ultrasound-derived measurements before and after verapamil

	Before	After	p value
LVED (mm)	37.6 ± 4.1	36.4 ± 4.7	NS
LVES (mm)	24.0 ± 5.5	23.4 ± 5.4	NS
Peak rate of shortening (l/sec)	2.6 ± 0.9	2.8 ± 1.0	NS
LVPW <sub>ED</sub> (mm)	14.1 ± 2.1	14.5 ± 3.4	NS
LVPW <sub>ES</sub> (mm)	20.3 ± 4.5	21.6 ± 4.0	NS
Peak rate of thickening (l/sec)	2.3 ± 0.7	2.9 ± 1.8	NS

LVED = left ventricular end-diastolic dimension; LVES = left ventricular end-systolic dimension; LVPW = left ventricular posterior wall.

**TABLE 3B**  
Ultrasound-derived measurements before and after verapamil

	Before	After	p value
LVID peak rate of lengthening (l/sec)	3.4 ± 1.1	3.1 ± 1.4	NS
LVPW peak rate of thinning (l/sec)	2.9 ± 1.2	2.4 ± 1.4	<.05
Isovolumetric relaxation time (msec)	79 ± 28	67 ± 31	NS
Rapid filling period (msec)	96 ± 27	94 ± 30	NS
t max dD/dt (msec)	120 ± 12	124 ± 14	NS

LVID = left ventricular internal dimension; LVPW = left ventricular posterior wall. For further explanation of abbreviations see text.

data (left ventricular end-diastolic pressure and subvalvular left ventricular gradient) did not suggest that the disease was in a late stage (see table 1). However, analysis by two-dimensional echocardiography showed extensive left ventricular hypertrophy involving substantial portions of the interventricular septum and left ventricular free wall.<sup>7</sup> Furthermore, the absolute end-diastolic posterior wall thickness was increased in all as determined by M mode echocardiography, and rates of posterior wall thinning were low, suggesting that magnitude of thickening and a decreased regional myocardial diastolic function were present.

Although our methodology is state of the art, several strong limitations are present that should be discussed before tentative conclusions are drawn. Beat-to-beat variations of both M mode echocardiograms<sup>14</sup> and of the time constant can be substantial. Since we recorded left ventricular pressures and M mode echocardiograms simultaneously, we avoided analyzing those beats where large variations in these parameters due to technical inadequacies or respiration were found. Moreover, intraobserver and interobserver variability of the echocardiographic measurements and beat-to-beat variation of indexes derived by echocardiography were small and comparable with current findings in the literature.<sup>1, 15</sup>

The M mode echocardiogram has specific limitations and is therefore not suitable to detect global changes in left ventricular function. This is illustrated by our findings, because significant changes in left ventricular contractility as seen by the pressure-derived measurements of contractility could not be determined from the echocardiogram. On the other hand, the method can be used to detect regional changes in left ventricular function.<sup>16</sup> This is shown by decreased rates of posterior wall thinning after verapamil and is supported by a concomitant increase in the time constant of isovolumetric relaxation and a decrease in neg-



ative left ventricular dP/dt. Because, to our knowledge, this is the first study that has used this method to study the effects of verapamil in patients with hypertrophic cardiomyopathy, no comparison is available with respect to the relationship of the time constant of relaxation and rates of posterior wall thinning.

Our results are probably not entirely comparable with results described after oral verapamil treatment,<sup>2</sup> because in the present short-term study a significant drop in left ventricular contractility occurred that was not present in other studies.<sup>1-3</sup> Tissue distribution of verapamil after oral treatment is probably different from that after short-term administration. Thus, although we reached therapeutic plasma levels in our patients, these levels probably bear no relationship to plasma levels reached after long-term oral treatment.

The heterogeneous aspects of hypertrophic cardiomyopathy, both in its clinical and hemodynamic expression as in the presence of left ventricular hypertrophy in various areas of the left ventricle<sup>7</sup> and the presence of variations in regional systolic wall thickening in normal subjects of 10% or more<sup>16</sup> make it more difficult to compare our results with findings of others.

Finally, it should be remembered that before verapamil became available, an increased distensibility was found that explained the symptomatic improvement of patients with hypertrophic cardiomyopathy treated with  $\beta$ -blocking drugs. But a recent study that used methods comparable to ours have convincingly shown that diastolic pressure-volume relationships were not influenced by  $\beta$ -blockade and that the earlier observations therefore were not correct.<sup>17</sup>

Despite the limitations of the study as described above, several of our findings support our belief that the area of left ventricular myocardium we studied is involved in the hypertrophic (or cardiomyopathic) process. Individual values of end-diastolic posterior wall thickness as determined by M mode echocardiography varied between 13 and 18 mm and were significantly larger than normal values. Furthermore, two-dimensional echocardiographic analysis with a recently evolved method described by Maron et al.<sup>7</sup> showed that all our patients had extensive left ventricular hypertrophy, which could have been underestimated by M mode echocardiography.<sup>7</sup> Peak rate of lengthening and peak rate of posterior wall thinning were significantly ( $p < .05$ ) lower than those for normal subjects in our laboratory, suggesting a depressed regional myocardial diastolic function.

Thus, our observations show no improvement in left ventricular diastolic function after short-term administration of verapamil. These results therefore support

clinical observations that potential complications after oral verapamil treatment might occur due to systemic hypotension and decreased contractility.<sup>18</sup> Extrapolation of our results to clinical management should be carried out with caution because of the short-term nature of this study.

We greatly appreciate the technical support of Harald TenKaten, Gerard van Zwieten, and Hans Eggink, and the statistical advice of Ron Brower, Ph.D. Knoll Nederland BV Mydrecht is acknowledged for providing determination of plasma levels of verapamil.

## References

1. Hanrath P, Mathey DG, Kremer P, Sonntag F, Bleifield W: Effect of verapamil on left ventricular isovolumic relaxation time and regional left ventricular filling in hypertrophic cardiomyopathy. *Am J Cardiol* **45**: 1258, 1980
2. Bonow RO, Rosing DR, Bacharach SL, Green MV, Kent KM, Lipson LC, Maron BJ, Leon MB, Epstein SE: Effects of verapamil on left ventricular systolic function and diastolic filling in patients with hypertrophic cardiomyopathy. *Circulation* **64**: 787, 1981
3. Rosing DR: Verapamil — therapeutic success, but how? *Int J Cardiol* **1**: 253, 1982
4. TenCate FJ, Hugenholtz PG, Van Dorp WG, Roelandt J: Prevalence of diagnostic abnormalities in patients with genetically transmitted asymmetric septal hypertrophy. *Am J Cardiol* **43**: 731, 1979
5. Braunwald E, Morrow AG, Cornell WP, Aygen MM, Hillbush TF: Idiopathic hypertrophic subaortic stenosis: hemodynamic and angiographic manifestations. *Am J Med* **29**: 924, 1960
6. Maron BJ, Epstein SE: Hypertrophic cardiomyopathy: recent observations regarding the specificity of three hallmarks of the disease: asymmetric septal hypertrophy, septal disorganization and systolic anterior motion of the anterior mitral leaflet. *Am J Cardiol* **45**: 141, 1980
7. Maron BJ, Gottdiener JS, Epstein SE: Patterns and significance of distribution of left ventricular hypertrophy in hypertrophic cardiomyopathy. A wide-angle, two-dimensional echocardiographic study in 125 patients. *Am J Cardiol* **48**: 418, 1981
8. Sones FM, Shirey EK: Cine coronary arteriography. *Mod Concepts Cardiovasc Dis* **31**: 735, 1962
9. Brower RW, Meester GT, Zeelenberg C, Hugenholtz PG: Automatic data processing in the cardiac catheterization laboratory. *Comput Programs Biomed* **7**: 99, 1977
10. Thompson DS, Waldron CB, Yuul SM, Nagvi N, Swanton RH, Coltart DJ, Jenkins BS, Webb-Pepploe MM: Analysis of left ventricular pressure during isovolumic relaxation in coronary artery disease. *Circulation* **65**: 690, 1982
11. VanZwieten G, Vogel JA, Bom AHA, Rysterborgh H: Computer assisted analysis of M-mode echocardiograms. *Comput Cardio* **77**: 1234, 1977
12. Gibson DG, Brown DR: Use of echocardiography in the evaluation of left ventricular function. *Proc R Soc Med* **67**: 141, 1974
13. Fisher RA: Statistical methods for research workers. Edinburgh, 1970, Oliver and Boyd
14. Belk YHN, Dryburgh LG: Beat to beat variation in echocardiographic measurements of left ventricular dimensions and function. *J Clin Ultrasound* **9**: 119, 1980
15. Lorell BH, Paulus WJ, Grossman W, Wynne J, Cohn PF: Modification of abnormal left ventricular diastolic properties by nifedipine in patients with hypertrophic cardiomyopathy. *Circulation* **65**: 499, 1982
16. Haendchen RV, Wyatt HL, Maurer G, Zwehl W, Bear M, Meerbaum S, Corday E: Quantitation of regional cardiac function by two-dimensional echocardiography. I. Patterns of contraction in the normal left ventricle. *Circulation* **67**: 1243, 1983
17. Speiser KW, Krayenbuehl H: Reappraisal of the effect of acute betablockade on left ventricular filling dynamics in hypertrophic cardiomyopathy. *Eur Heart J* **2**: 21, 1981
18. Epstein SE, Rosing DR: Verapamil: its potential for causing serious complications in patients with hypertrophic cardiomyopathy. *Circulation* **64**: 437, 1981