

Coronary Stenting With a New, Radiopaque, Balloon-Expandable Endoprosthesis in Pigs

Willem J. van der Giessen, MD; Patrick W. Serruys, MD; Heleen M.M. van Beusekom, MSc;
Leon J. van Woerkens, MSc; Heleen van Loon, BSc; Loe Kie Soei, MSc;
Bradley H. Strauss, MD; Kevin J. Beatt, MD; and Pieter D. Verdouw, PhD

Background. Intracoronary stents may be effective when used as "bail-out" devices for acute complications after percutaneous transluminal coronary angioplasty. Furthermore, preliminary reports have demonstrated some promising results with stents with regard to the reduction of restenosis. Several stent devices are available for preclinical and clinical evaluation. The use of these stainless-steel stents has been limited by poor visibility during fluoroscopy and thrombogenicity during the first days to weeks after implantation. We therefore investigated the immediate and short-term effects on arterial patency of a new, radiopaque, balloon-expandable coil stent in normal coronary arteries of pigs.

Methods and Results. In 10 animals, a stent was placed in two of the three epicardial coronary arteries. During the implantation procedure, the animals received heparin; after the procedure, no antithrombotic drugs were administered. After 1 week (five animals and 10 stents) or 4 weeks (five animals and 10 stents), repeat angiography was performed, followed by pressure-fixation of the coronary arteries for light and electron microscopic examination. Angiographic analysis revealed that all stented coronary segments were patent and without signs of intraluminal defects. Scanning electron microscopy showed complete endothelial covering of all stents within 7 days. Light microscopy showed a reduced tunica media locally under the stent wires, which resulted from exerted pressure. The neointima on top of the stent wires measured 56 μm (range, 42–88 μm) after 1 week and 139 μm (range, 84–250 μm) after 4 weeks.

Conclusions. Results from this study show that this radiopaque endoprosthesis can be safely placed in normal coronary arteries of pigs. After 4 weeks, all stents were patent and there was no need for additional antithrombotic treatment, whereas neointimal proliferation was limited. (*Circulation* 1991;83:1788–1798)

Percutaneous transluminal coronary angioplasty can be used to treat patients with atherosclerotic coronary artery disease and has a high initial success rate.^{1,2} However, in 2–5% of cases, acute or subacute occlusion at the angioplasty site occurs.^{3–4} Although the occluded artery can occasionally be successfully redilated, it is frequently necessary to proceed to emergency coronary bypass graft surgery.^{1,3} The efficacy of pharmacological therapy on acute complications is still undetermined, although the administration

of aspirin appears to be an accepted approach.^{5–9} Restenosis after successful coronary angioplasty remains, however, the second important factor that limits the efficacy of this procedure.^{10,11} Pharmacological treatment to reduce the incidence of restenosis has so far been without effect,¹² although the addition of ω -3 fatty acids to standard antithrombotic drugs has shown some promise.¹³ The implantation of vascular endoprostheses, attempted in the early days of angioplasty for the treatment of procedure-related complications,¹⁴ may be useful in avoiding acute surgical intervention or preventing coronary restenosis.¹⁵ Experimental and clinical experiences with these devices, however, indicate that their poor fluoroscopic visibility can make the implantation arduous. Furthermore, the thrombogenic nature of stainless-steel devices remains a concern, necessitating the administration of stringent anticoagulant therapy.^{16,17} We therefore studied the short-term angiographic patency of a new, radiopaque, tantalum stent after implantation in the coronary circulation in pigs.

From the Department of Cardiology, Thoraxcenter, Erasmus University Rotterdam, and the Academic Hospital Dijkzigt, Rotterdam, The Netherlands.

Presented in part at the 62nd Annual Scientific Sessions of the American Heart Association, November 13–16, 1989, New Orleans, La.

Supported by Netherlands Heart Foundation grant NHS 88-077 and by Medtronic, Inc., Minneapolis, Minn.

Address for correspondence: Patrick W. Serruys, MD, Department of Cardiology, Thoraxcenter, Erasmus University Rotterdam, P. O. Box 1738, 3000 DR Rotterdam, The Netherlands.

Received July 11, 1990; revision accepted January 8, 1991.

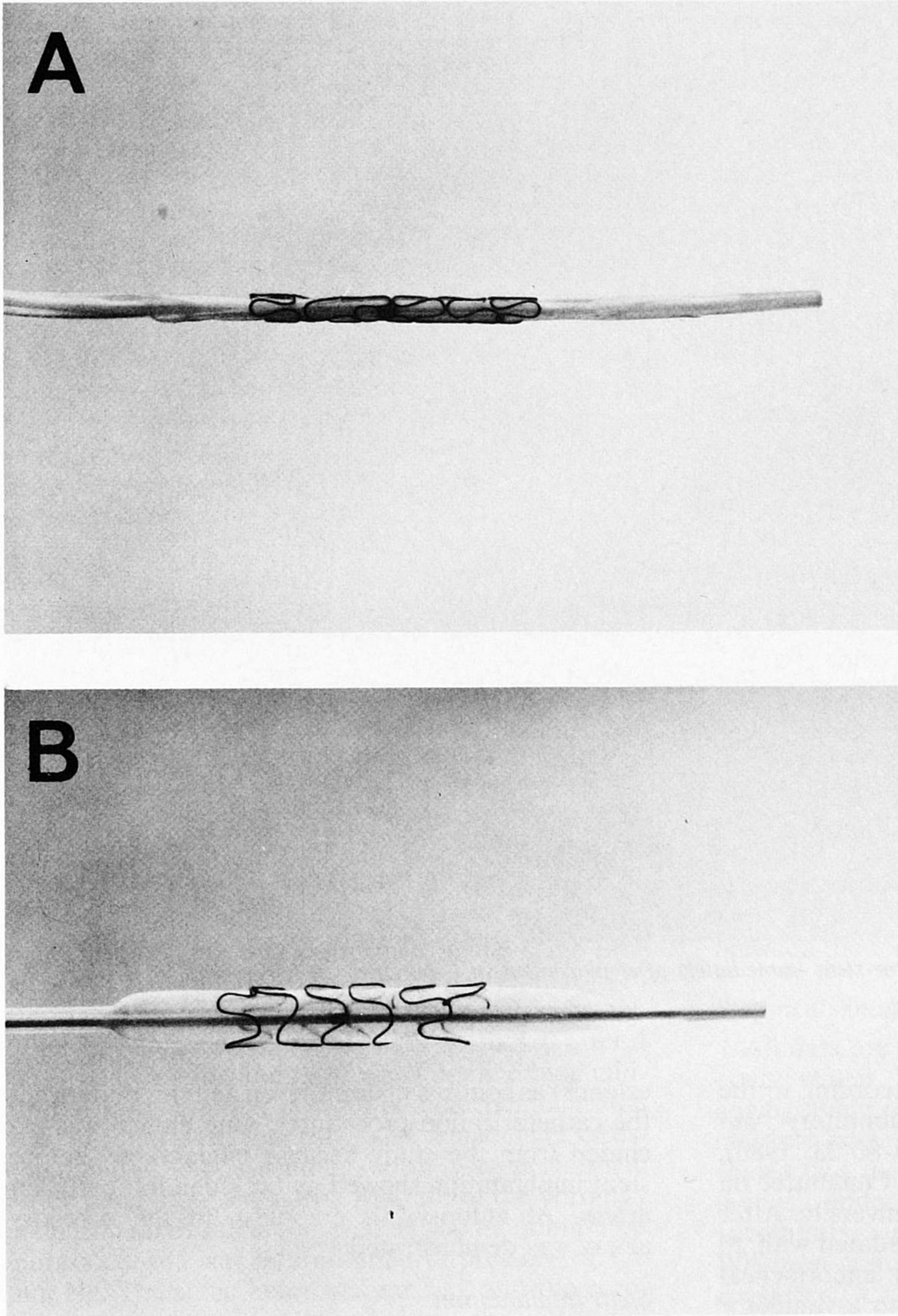


FIGURE 1. Panel A: Photograph of Wiktor stent crimped on balloon of a standard balloon angioplasty catheter. Panel B: Photograph of Wiktor stent fully expanded by inflation of balloon to 8 atm.

Methods

Balloon-Expandable Intracoronary Stent

The balloon-expandable stent used in the present study (Wiktor, Medtronic, Inc., Minneapolis, Minn.) is constructed of a single tantalum wire (0.127 mm diameter) formed into a sinusoidal wave and wrapped into a helical coil structure. This prosthesis is crimped onto the deflated polyethylene balloon of a standard angioplasty catheter (Figure 1A). By inflating the balloon, the diameter of the stent increases without alteration of its length (Figure 1B). The maximal diameter of the balloon after inflation determines the ultimate size of the prosthesis after implantation. One inflation at 8 atm is sufficient to open the stent and allows the safe withdrawal of the deflated balloon (Figure 2). The diameters of the balloons of the mounted angioplasty

catheters used in the present study were 3.0 and 3.5 mm, and the lengths of the prostheses ranged from 14 to 16 mm. For the balloon catheters used with stents of these sizes, the crimped stent profile is approximately 1.5 mm. An advantage of the delivery system used is that after stent expansion, the balloon will rewrap tightly without excessive winging, which will facilitate balloon removal from the deployed stent. The manufacturer has indicated that although this device may be deliverable with a variety of catheters, the device will be marketed as a ready-to-use complete delivery system to ensure the safe delivery of the stent by controlling the difficult crimping process during manufacture.

Animal Preparation

Experiments were performed in Yorkshire pigs (weight, 40–46 kg; HVC, Hedel, The Netherlands).

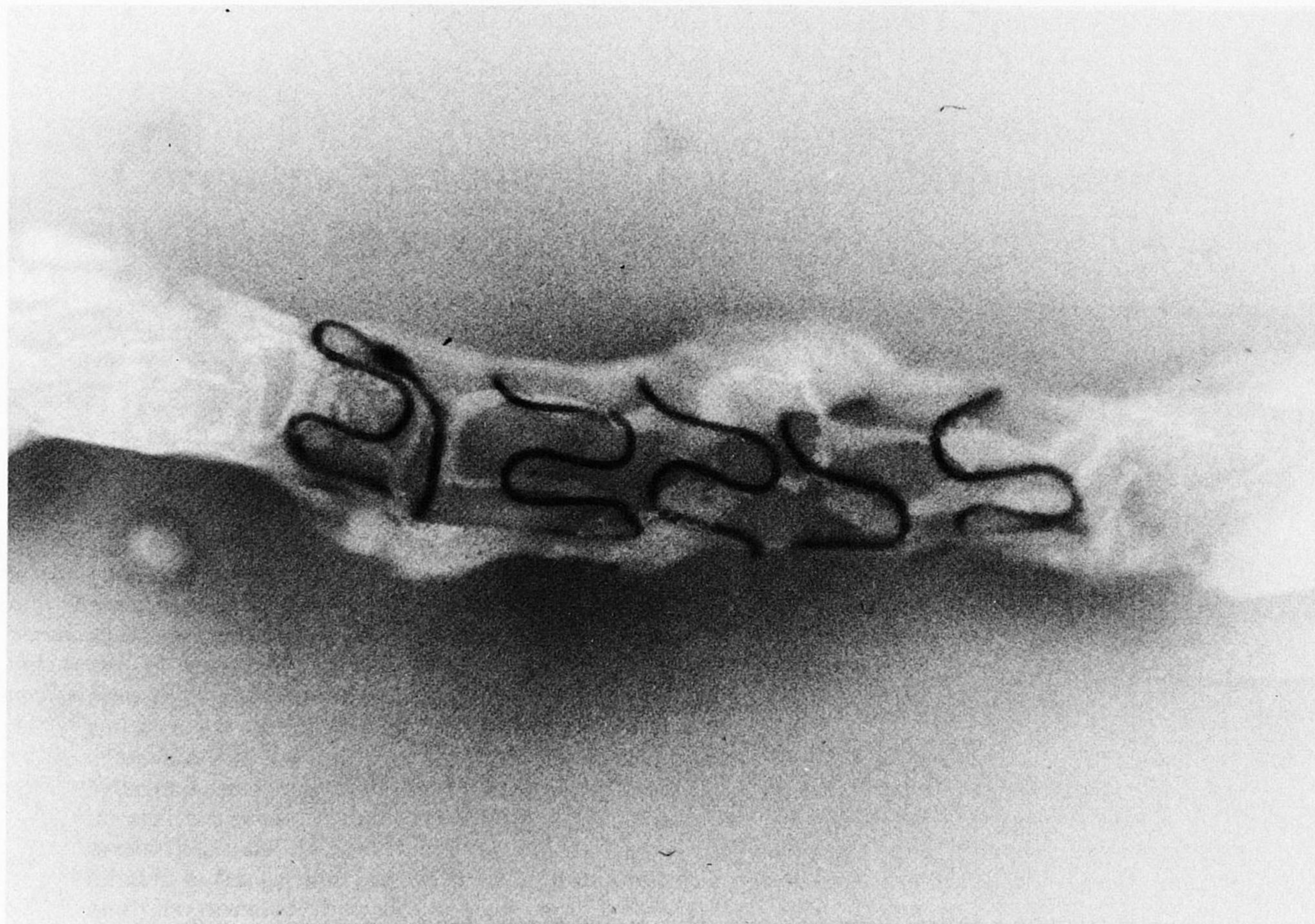


FIGURE 2. Photograph of expanded Wiktor stent immediately after placement in a porcine coronary artery from which the adventitia has been removed.

The investigations were performed according to the "Guide for the Care and Use of Laboratory Animals" (DHEW publication No. NIH-80-23, 1980), and the protocol was approved by the Committee on Experimental Animals of Erasmus University. After an overnight fast, the animals were sedated with 20 $\mu\text{g}\cdot\text{kg}$ ketamine hydrochloride. After endotracheal intubation, the pigs were connected to a ventilator that administered a mixture of oxygen and nitrous oxide (1:2 vol/vol). Anesthesia was maintained with 1–4 vol% enflurane, and pancuronium bromide was used as a muscle relaxant. Antibiotic prophylaxis was administered by an intramuscular injection of 1,000 mg of a mixture of procaine penicillin G and benzathine penicillin G.

Under sterile conditions, an arteriotomy of the left carotid artery was performed, and a 9F introduction sheath was placed. Next, 5,000 IU heparin sodium was administered, and an 8F guiding catheter was advanced to the ascending aorta. After measurement of arterial blood pressure and heart rate and withdrawal of an arterial blood sample for the measurement of blood gases and acid-base balance (settings of the ventilator were corrected if necessary), left and right coronary angiography was performed using iopamidol (Iopamiro 370, Dagra, Diemen, The Neth-

erlands) as contrast agent. Eleven animals underwent the catheterization procedures. One animal was excluded from the study because angiography before stent implantation showed an occluded left coronary artery. At autopsy, air embolism of the coronary artery was demonstrated.

Stent Implantation

After angiography and with the diameter of the guiding catheter used as a reference, a segment with a diameter of 2.5 or 3.0 mm was selected in two of the three large coronary arteries (left anterior descending coronary artery, left circumflex coronary artery, and right coronary artery). No attempt was made to avoid side branches or angulated coronary segments. Then, a 3.0-mm (for 2.5-mm coronary segments) or 3.5-mm (for 3.0-mm coronary segments) balloon angioplasty catheter with a stent coil crimped on its deflated balloon was advanced over a 0.014-in. steerable guide wire to the site preselected for implantation. During all of our experiments, tracking and ease of placement in the coronary vasculature was good. After administration of an additional 2,500 IU heparin through the guiding catheter, the balloon was first inflated to a pressure of 8 atm for 30 seconds and then deflated, and negative pressure was maintained

TABLE 1. Stents and Implant Sites

Stent diameter (mm)	Stents (n)	Coronary artery sites	Sites (n)
3.0	10	RCA	1
		LAD	5
		LCx	4
3.5	10	RCA	4
		LAD	2
		LCx	4

RCA, right coronary artery; LAD, left anterior descending coronary artery; LCx, left circumflex coronary artery.

for 20 seconds. The angioplasty catheter was advanced slightly; if the marker in the middle of the balloon could be moved independent of the stent, the catheter was slowly withdrawn while leaving the stent in place. This implantation procedure was repeated in the second chosen coronary artery. (Implant sites are listed in Table 1). After repeat angiography of the stented coronary arteries, the guiding catheter and the introducer sheath were removed, the arteriotomy was repaired, and the skin was closed in two layers. The animals were allowed to recover from anesthesia; no postprocedure antithrombotic drugs were administered.

Follow-up Angiography

The catheterization procedure for follow-up angiography was identical to that described above. Coronary angiography was performed in the same projection as during implantation. Five animals (10 stents) were restudied after 1 week, whereas the other five animals (10 stents) were restudied after 4 weeks. Thereafter, the thorax was opened by a mid-sternal split, a lethal dose of sodium pentobarbital was injected intravenously, and immediate cross-clamping of the ascending aorta was performed. After puncturing the aortic root above the coronary ostia, 500 ml of saline followed by 400 ml of buffered glutaraldehyde was infused under a pressure of 120 mm Hg. Then, the heart was excised, and the coronary arteries were dissected from the epicardial surface. The stented segments and adjacent unstented segments were placed in 4% formaldehyde and 1% glutaraldehyde in phosphate buffer (pH 7.3) for at least 48 hours in preparation for microscopy.

Angiographic Analysis

Coronary angiograms (preimplantation, immediately after implantation, and after 1 or 4 weeks) were analyzed using the quantitative coronary angiography analysis system (CAAS).¹⁸⁻²⁰ Mean interpolated diameter at the site of stent placement was compared with the mean arterial diameter measured proximal and distal to the site of the stent.

Microscopic Examination

After fixation, the stent-containing arterial segments were divided lengthwise into two equal parts with a pair of fine scissors. The stent wires were

removed from one half of each vessel. Both halves were washed in 0.1 M cacodylate buffer (pH 7.3), postfixed in 1% osmium tetroxide, and washed overnight in 0.1 M cacodylate buffer. The specimens were placed in 1% tannic acid for 60 minutes and 1% sodium sulfate for 10 minutes and again washed in 0.1 M cacodylate buffer. The vessel half containing the stent wires was dehydrated in graded ethanol series and critical point dried with liquid CO₂. Thereafter, it was mounted on a specimen table and sputtercoated with gold before examination in a scanning microscope (ISI-DS-130, Akashi Beam Technology, Tokyo, Japan). The other half of each vessel was dehydrated in graded acetone and embedded in epon. After sectioning and staining, microscopy was performed with a light microscope (BH2, Olympus, Tokyo, Japan) and an electron microscope (EM400, Philips, Eindhoven, The Netherlands). For measurement of the thicknesses of the various layers of the arterial wall, at least two sections of each stented coronary segment were selected. The sections were cut 90° transverse (as determined by the diameter of the stent wire) and projected onto a video screen, and the outer contours, external and internal elastic lamina, and endothelial lining were traced using an integrated image analysis system (IBAS-2000, Kontron, Oberkochen, FRG).²¹ The distance between the endothelial lining and the internal elastic lamina was taken as the thickness of the intima.²² The media was defined as the layer between the internal and the external elastic lamina.

Statistical Analysis

All data are expressed as mean ± SEM unless otherwise stated. The significance of the changes in the angiographic data was evaluated by Duncan's new multiple-range test once an analysis of variance revealed that the samples represented different populations (random block design). The histological measurements were analyzed by the two-sample Wilcoxon test. A probability of less than 0.05 was considered statistically significant.

Results

Systemic Hemodynamics and Blood Gases During Implantation and Follow-up Angiography

During implantation and follow-up angiography, heart rates (89 ± 6 and 92 ± 7 beats/min, respectively), systolic arterial blood pressures (120 ± 6 and 119 ± 6 mm Hg), and diastolic arterial blood pressures (82 ± 6 and 77 ± 6 mm Hg) were comparable. The oxygenation of arterial blood and acid-base balance were also similar during stent placement and follow-up angiography and within the normal ranges (pH, 7.38 ± 0.01 ; PO₂, 144 ± 9 mm Hg; PCO₂, 43 ± 1 mm Hg; base excess, 0.4 ± 0.5 mmol/l).

Placement of Stent and Follow-up Angiography

A pilot study revealed that inflating the mounted balloon to as much as 6 atm was not sufficient to

ensure the safe withdrawal of the balloon after deflation. Furthermore, withdrawal of the catheter after a deflation period of less than 10 seconds could also disengage the device. We were able to avoid these situations by using a single inflation of 30 seconds to 8 atm followed by at least 20 seconds of deflation before the catheter was withdrawn. Special care proved to be necessary when inserting the device through hemostasis valves, guiding catheters, or coronary segments too narrow for the catheter profile to avoid dislodging the stent from the loaded balloon. Therefore, the position of the stent mounted on the balloon was inspected after passing the hemostasis valve and before leaving the guiding catheter.

In all 20 predetermined coronary segments (Table 1), a stent could be placed. Quantitative analysis of the angiograms confirmed that we chose to use mounted angioplasty catheters with 3.0-mm balloons (supplier specified) for stent placement in 2.5 ± 0.1 -mm artery diameters, that maximal inflated balloon diameters in these vessels were 3.0 ± 0.1 mm (oversizing, $19 \pm 4\%$), and that the stented coronary segments after balloon deflation measured 2.6 ± 0.1 mm (recoil, $9 \pm 5\%$). For the supplier-specified, 3.5-mm balloon catheters, these values were preimplantation, 2.7 ± 0.2 mm; during maximal inflation, 3.2 ± 0.1 mm (oversizing, $22 \pm 5\%$); and immediately after deflation, 2.9 ± 0.1 mm (recoil, $9 \pm 4\%$). All animals survived the follow-up period. Repeat angiography revealed that all stented coronary arteries were patent after 1 and 4 weeks (Figure 3). Quantitative angiography showed that the mean diameters of the stented coronary segments after 1 and 4 weeks follow-up showed no statistically significant changes compared with the diameters immediately after placement (Figure 4). The diameter stenoses of the stent-containing coronary segments relative to the reference diameters proximal and distal to the stents measured $8 \pm 2\%$ immediately after stent implantation, $15 \pm 4\%$ at 1 week, and $17 \pm 4\%$ at 4 weeks.

Light Microscopic Measurements

The stent wires were incorporated in the arterial wall as early as 1 week after implantation. Measurement of the several arterial layers showed that the neointima covering the wires had a median thickness of $56 \mu\text{m}$ (range, $42\text{--}88 \mu\text{m}$) after 1 week and increased to $139 \mu\text{m}$ (range, $84\text{--}250 \mu\text{m}$) after 4 weeks (Figure 5). The neointima in the open or nonstrut areas of the stented segments had a median thickness of $25 \mu\text{m}$ (range, $9\text{--}38 \mu\text{m}$) after 1 week and increased to $48 \mu\text{m}$ (range, $6\text{--}120 \mu\text{m}$) after 4 weeks. The arterial media was considerably compressed under the stent wire. It was observed that in several vessels, the internal elastic lamina was disrupted at the wire site.

Light and Transmission Electron Microscopy

During the first week after stent implantation, neointimal hyperplasia was confined to the area in direct contact with the stent wires and consisted

mainly of organized thrombi with a few layers of smooth muscle cells under the endothelial lining (Figure 6A).

After 4 weeks, neointimal hyperplasia completely covered the stented coronary segments. A few foam cells and some erythrocytes were found in the neointima as a trace of the thrombotic event that took place at the time of implantation. The bulk of the neointima comprised smooth muscle cells with their typical organization, changing from a longitudinal to a circumferential orientation, beginning at the luminal side of the vessel (Figure 6B).

No inflammatory or foreign body reaction was observed at 1 or 4 weeks, based on the absence of giant cells or infiltrative changes in either layer of the vessel wall.

Scanning Electron Microscopy

Scanning electron microscopy showed that at 1 week after placement of the stents, all wires were completely covered with endothelium (Figure 7A). The coronary arteries, however, showed an undulated luminal surface. After 4 weeks, the stent wires were barely detectable under the neointimal surface (Figure 7B). Fine corrugation of this surface could be demonstrated, although adherent thrombi or platelet aggregates were not observed.

Discussion

Radiopacity

Vascular endoluminal prostheses (stents) are undergoing clinical evaluation for their usefulness as scaffolding devices for acute occlusion after coronary angioplasty.^{15,16,23,24} The efficacy of these devices has also been studied in the prevention and treatment of restenosis in aortocoronary bypass grafts and the native coronary circulation.^{15,25–28} Although the long-term effect of stents used for these indications is still not determined, immediate angiographic results are excellent, and there is improvement during the first 24 hours.²⁹ However, the poor visibility of thin-wired, stainless-steel devices during fluoroscopy is a disadvantage during implantation. Both the inability to place stainless-steel, balloon-expandable stents at preselected arterial sites and systemic embolization have been reported experimentally and clinically.^{30–32} Furthermore, uncertainty about the precise placement of nonradiopaque stents will complicate the determination of immediate efficacy and late restenosis in the coronary segments in which the stent purportedly was placed. The stent used in the present study has the distinct advantage of being clearly visible under fluoroscopy (Figure 3), thus facilitating its safe placement.³³ With this device, there can be no discussion about which coronary segment is covered by it and which is not. Quantitative angiographic assessment is simplified, but not all problems have been solved; preliminary (unpublished) data from our laboratory show that videoden-

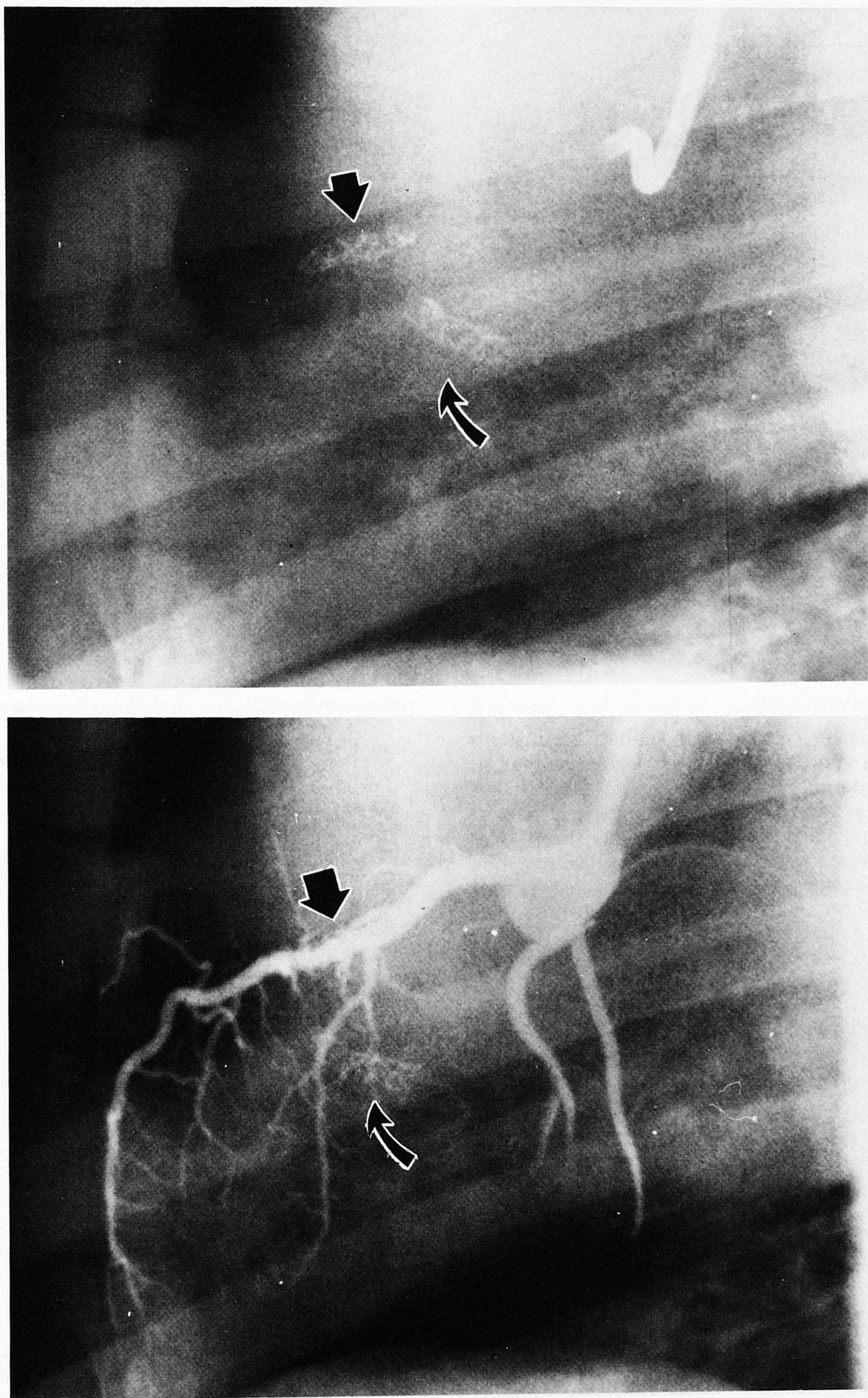


FIGURE 3. Top panel: Nominal 3.0-mm-diameter Wiktor stent placed 4 weeks previous in left anterior descending coronary artery (large arrow) and nominal 3.5-mm-diameter Wiktor stent placed in right coronary artery (small arrow) clearly visible during radiography. Bottom panel: Coronary angiogram in left inferior oblique projection showing patent left anterior descending coronary artery without intraluminal defects associated with stent (large arrow).

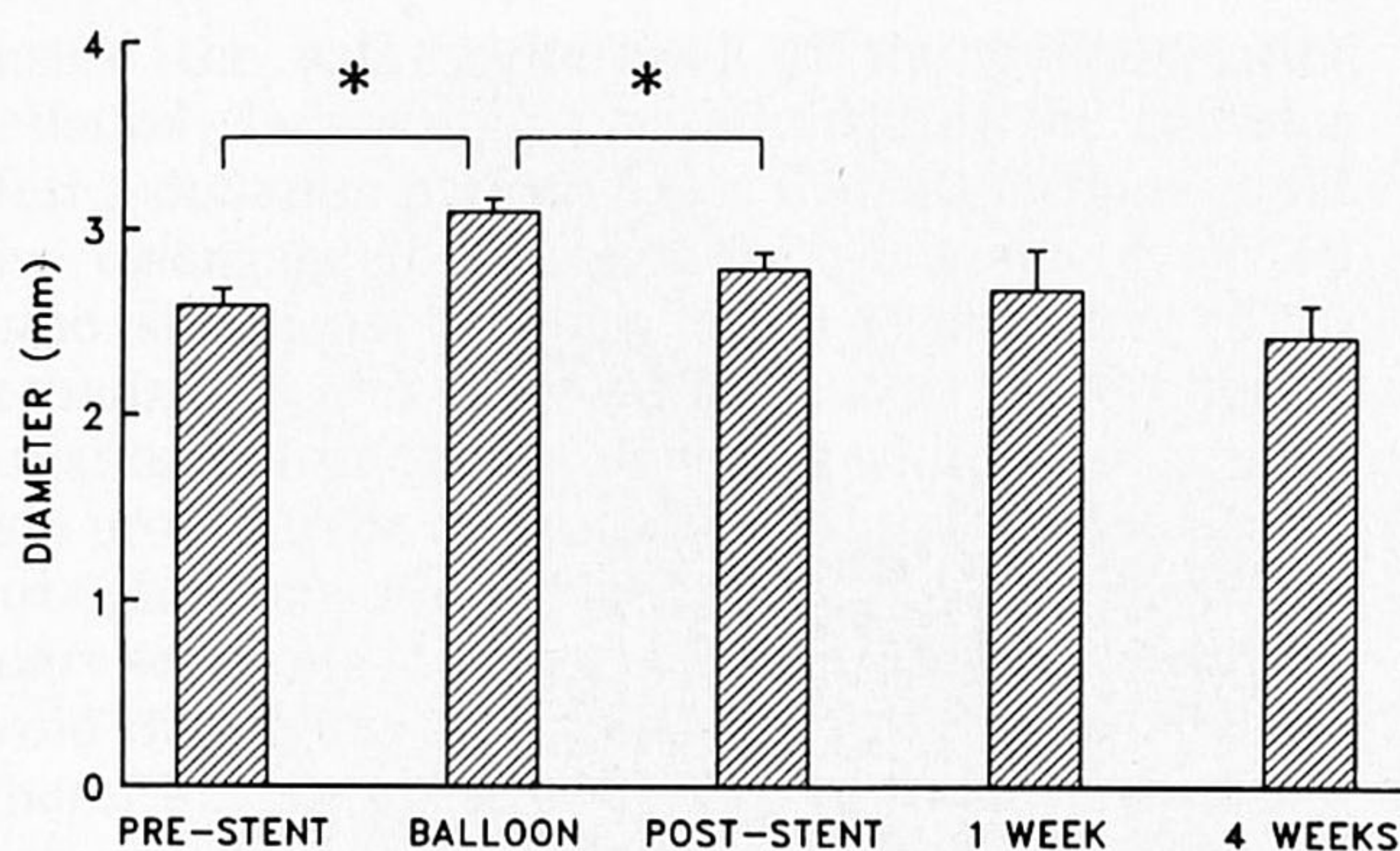


FIGURE 4. Bar graph of quantitative angiographic assessment of stented coronary segments. Data are expressed as mean \pm SEM and represent pooled data of both balloon sizes. PRE-STENT, coronary segment immediately before stenting ($n=20$); BALLOON, balloon diameter during maximal inflation to 8 atm during placement of stent ($n=19$); POST-STENT, coronary segment immediately after stent placement ($n=20$); 1 WEEK, measurements of five animals (nine stents) 1 week after stent placement; 4 WEEKS, measurements of five animals (10 stents) 4 weeks after stent placement. * $p<0.05$ versus balloon.

sitometric assessment will be influenced by the presence of any type of stent.

Thrombogenicity

Another major problem with stainless-steel stents is that they require elaborate anticoagulation therapy after implantation because of their thrombogenicity, which will increase the risk of complications associated with a hemorrhagic diathesis. In the present study, all stented coronary arterial segments were angiographically patent after 1 and 4 weeks without any signs of intraluminal defects, with antithrombotic drugs not administered during follow-up. Although we cannot exclude that intercurrent thrombi or plate-

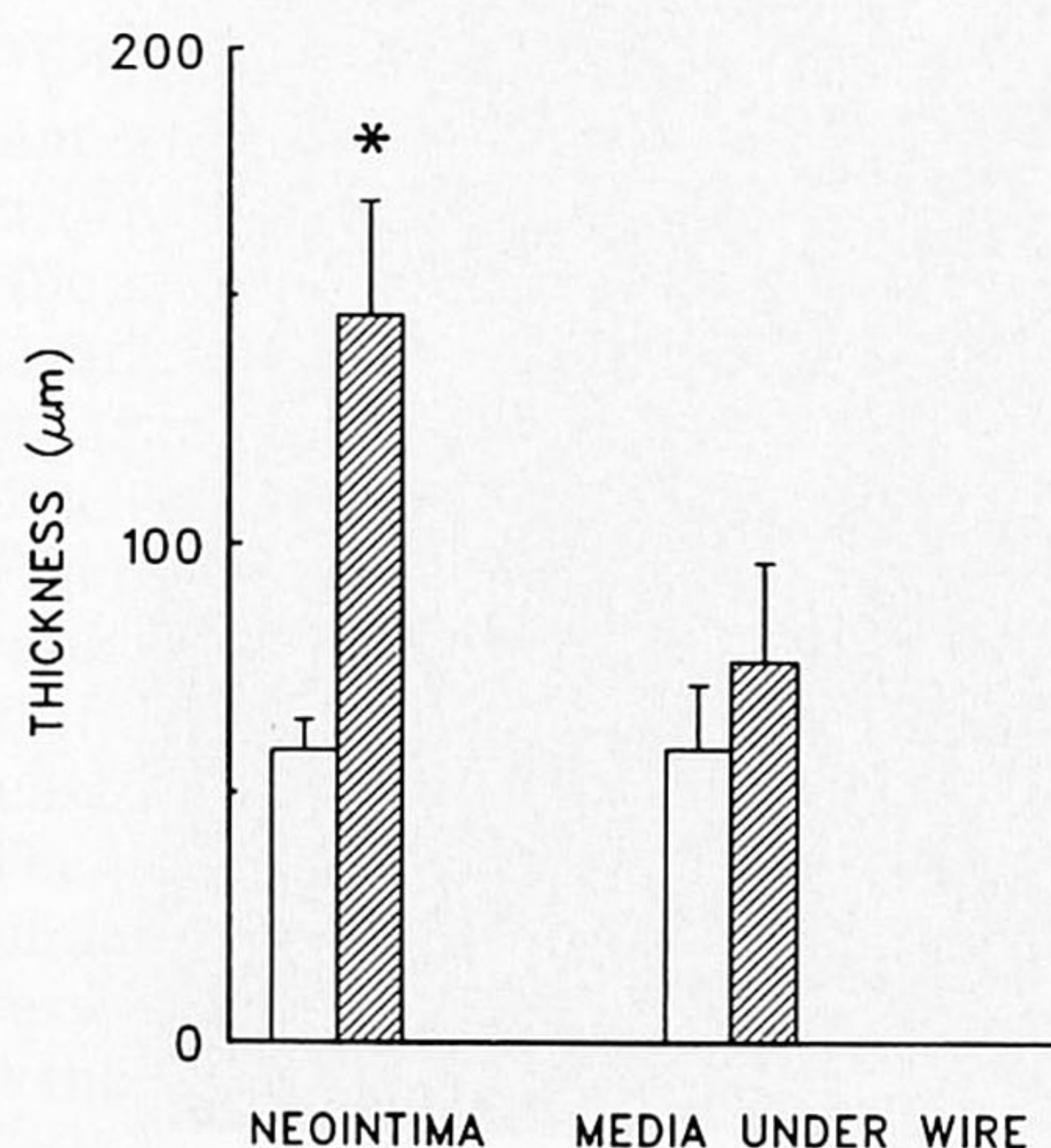


FIGURE 5. Bar graph of thickness of neointima above stent wires and media under wires 1 week (open columns) and 4 weeks (striped columns) after stent implantation. Data are expressed as mean \pm SEM ($n=7$). * $p<0.05$ versus 1 week.

let aggregates were formed during the first few days after implantation, stent occlusion did not occur; after 1 week, scanning microscopy showed a clean endothelial surface covering the stents. If thrombotic material of considerable size had embolized before that time, deaths would have occurred because the risk of lethal arrhythmias after coronary occlusion is very high in this species. That all animals survived may serve as circumstantial evidence against the occurrence of embolization of thrombus material. Thrombotic events associated with the stent have been reported experimentally in as many as 40% of study groups using other stents but can be reduced by choosing appropriate antithrombotic regimens.^{30,31,34,35} The nonthrombogenic feature of this stent is not determined, but several factors may be involved. First, the metal itself (tantalum) may be a major determinant. The wire surface of any stent may undergo oxidation after implantation, and the resultant oxide, in this case, tantalum oxide, is not only very stable (implying fewer changes in surface charge) but also corrosion resistant.³⁶ Second, there is a large area of open space (91.6% and 92.3% for 3.0- and 3.5-mm expanded diameters, respectively) between the wires, resulting in less metal per surface area. Third, the entire stent surface is smooth. Finally, there is early endothelial covering (after 1 week, the Wiktor stents were completely covered by an endothelium-covered neointima).

Neointimal Hyperplasia

At 1 week after implantation, the luminal surface of the artery showed an undulated appearance. This may cause local turbulence in blood flow and fluctuations in wall shear stress, which may be factors determining endothelial cell turnover and intimal hyperplasia.³⁷⁻⁴⁰ We could demonstrate that the thickness of the neointimal layer had considerably increased between 1 and 4 weeks after implantation. After 4 weeks, the luminal surfaces of the stented coronary segments were smooth. Future studies are necessary to determine whether the increase in intimal thickness levels off after 4 weeks. However, the median thickness of the neointima in the present study was not different from that reported for other types of stents.^{30,31,41} Schwartz et al⁴² emphasized that rupture of the internal elastic membrane after stenting may form a trigger for accelerated neointimal hyperplasia, but we observed considerable damage to this elastic lamina in several cases without significant restenosis (e.g., see Figure 6B). Other factors, such as considerable oversizing of the prosthesis with resultant damage to the arterial media, are probably involved.

Elastic Recoil

A potential beneficial effect of self-expanding stents is the prevention of elastic recoil after coronary angioplasty.²⁹ The balloon-expandable Wiktor stent lacks this effect, perhaps because of its passive radial force and relatively large area of open space. Quantitative angiographic assessment showed a recoil of 9% immediately after placement of the stent (Figure 4). Data

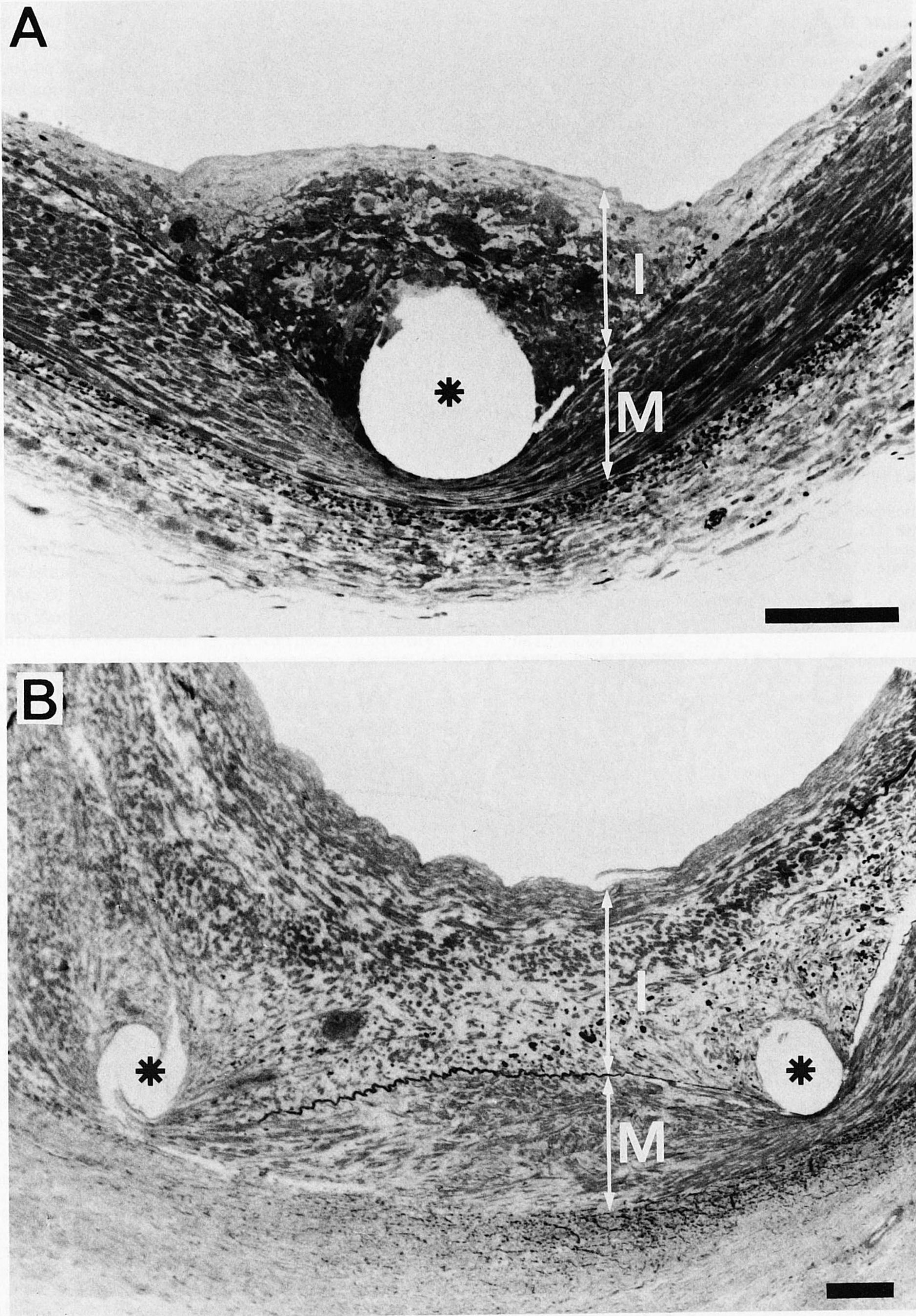


FIGURE 6. Panel A: Photomicrograph of transverse section of left anterior descending coronary artery 1 week after placement of a Wiktor stent. Panel B: Photomicrograph of transverse section of left circumflex coronary artery 4 weeks after stent implantation (toluidine blue stain). I, intima; M, media. *Void formerly occupied by stent wire. Bar, 100 μ m.

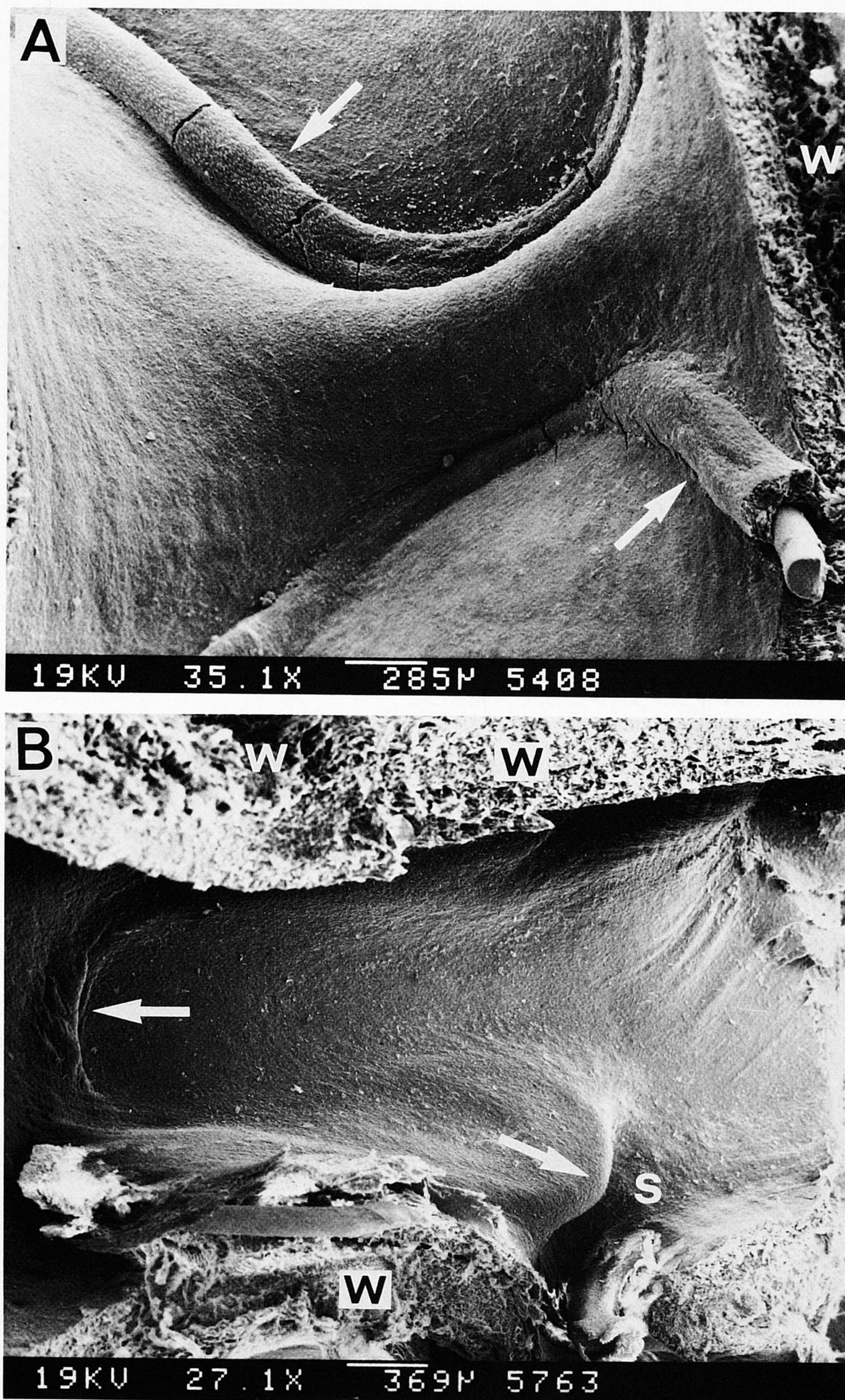


FIGURE 7. Panel A: Photomicrograph from scanning electron microscope of left circumflex coronary artery 1 week after stent placement. Two parts of endothelium-covered stent wire coil (arrows) can be seen. Between the coils, part of the vessel wall (W) is bulging out. Panel B: Photomicrograph from scanning electron microscope of right coronary artery 4 weeks after stent placement. Under a layer of neointimal hyperplasia, the stent wire coil (arrows) is hardly visible. An embedded stent wire partly overhangs a side branch (S). W, cut face of vessel wall.

from other balloon-expandable stents are not available or inconclusive. In vitro studies using another type of balloon-expandable tantalum stent also point toward considerable recoil.⁴³ However, which feature (metal or design) determines the elastic properties of a stent remains unknown.

Conclusion

Interpretation of the data obtained in the present study must be made with consideration that it involves the evaluation of a new device in normal coronary arteries of experimental animals. However, comparison of the results of the present study with data obtained for other stent devices in healthy experimental animals indicates that the Wiktor stent is less thrombogenic.^{30,31,35} Whether this will also be true in atherosclerotic coronary arteries in swine, in which at least one of the other stent devices showed a low complication rate,⁴⁴ remains to be demonstrated. Also, the clear visibility of the Wiktor stent under fluoroscopy is a distinct advantage.

Acknowledgments

The authors wish to thank Mrs. Marjo van Ee for her assistance in the preparation of this manuscript and Mr. B. Klazema (General Electric Plastics, Bergen op Zoom, The Netherlands) for the use of the scanning microscope. Mr. E. Ridderhof, Laboratory of Experimental Surgery, is thanked for his indispensable help during animal anesthesia. Mrs. W. van Leeuwen, Department of Radiology, is thanked for the preparation of the films. Finally, we wish to thank Mr. W.J. Visser, Department of Cell Biology, for assisting with the microscopy.

References

1. Anderson HV, Roubin GS, Leimgruber PP, Douglas JS Jr, King SB III, Gruntzig AR: Primary angiographic success rates of percutaneous transluminal angioplasty. *Am J Cardiol* 1985; 56:712-717
2. Myler RK, Topol EJ, Shaw RE, Stertz SH, Clark DA, Fishman J, Murphy MC: Multiple vessel coronary angioplasty: Classification, results and patterns of restenosis in 494 consecutive patients. *Cathet Cardiovasc Diag* 1987;13:1-15
3. Bredlau CE, Roubin GS, Leimgruber PP, Douglas JS Jr, King SB III, Gruntzig AR: In-hospital morbidity and mortality in patients undergoing elective coronary angioplasty. *Circulation* 1985;72:1044-1052
4. Simpfendorfer C, Belardi J, Bellamy G, Galan K, Franco I, Hollman J: Frequencies, management and follow-up of patients with acute coronary occlusion after percutaneous transluminal angioplasty. *Am J Cardiol* 1987;59:267-269
5. Schwartz L, Bourassa MG, Lespérance J, Aldridge HE, Kazim F, Salvatori VA, Henderson M, Bonan R, David PR: Aspirin and dipyridamole in the prevention of restenosis after percutaneous transluminal coronary angioplasty. *N Engl J Med* 1988;318:1714-1719
6. Pow TK, Varricchio TR, Jacobs AK, Ruocco NA, Ryan TJ, Christelis EM, Faxon DP: Does pretreatment with heparin prevent abrupt closure following PTCA (abstract)? *J Am Coll Cardiol* 1988;11:238A
7. Mufson L, Black A, Roubin G, Wilentz J, Mead S, McFarland K, Weintraub W, Douglas JS Jr, King SB III: A randomized trial of aspirin in PTCA: Effect of high vs low dose aspirin on major complications and restenosis (abstract). *J Am Coll Cardiol* 1988;11:236A
8. Lembo NJ, Black AJ, Roubin GS, Mufson LH, Wilentz JR, Douglas JS Jr, King SB III: Does the addition of dipyridamole to aspirin decrease acute coronary angioplasty complications? The results of a prospective randomized clinical trial (abstract). *J Am Coll Cardiol* 1988;11:237A
9. Chesebro JH, Webster MWI, Reeder GS, Mock MB, Grill DE, Bailey KR, Steichen S, Fuster V: Coronary angioplasty: Antiplatelet therapy reduces acute complications but not restenosis (abstract). *Circulation* 1989;80(suppl II):II-64
10. Serruys PW, Luijten HE, Beatt KJ, de Feyter PJ, van den Brand M, Reiber JHC, ten Katen HJ, van Es GA, Hugenholtz PG: Incidence of restenosis after successful coronary angioplasty: A time-related phenomenon. *Circulation* 1988;77: 361-371
11. Detre K, Holubkov R, Kelsey S, Cowley M, Kent K, Williams D, Myler R, Faxon D, Holmes D, Bourassa M, Block P, Gosselin A, Lamberto B, Leatherman L, Dorros G, King SB, Galichia J, Al-Bassam M, Leon M, Robertson T, Passamani E, Coinvestigators of the National Heart, Lung and Blood Institute's Percutaneous Transluminal Coronary Angioplasty Registry: Percutaneous transluminal coronary angioplasty in 1985-1986 and 1977-1981. *N Engl J Med* 1988;318:265-270
12. Blackshear JL, O'Callaghan WG, Califf RM: Medical approaches to prevention of restenosis after coronary angioplasty. *J Am Coll Cardiol* 1987;9:834-848
13. Dehmer GJ, Popma JJ, Van den Berg EK, Eichhorn EJ, Prewitt JB, Campbell WB, Jennings L, Willerson JT, Schmitz JM: Reduction in the rate of restenosis after angioplasty by a diet supplemented with n-3 fatty acids. *N Engl J Med* 1988; 319:733-740
14. Dotter CT: Transluminally placed coil springs and arterial tube grafts: Long-term patency in the canine popliteal artery. *Invest Radiol* 1969;4:329-332
15. Sigwart U, Puel J, Mirkovitch V, Joffre F, Kappenberg L: Intravascular stent to prevent occlusion and restenosis after transluminal angioplasty. *N Engl J Med* 1987;316:701-706
16. Serruys PW, Strauss BH, Beatt KJ, Bertrand ME, Puel J, Rickards AF, Meier B, Goy J-J, Vogt P, Kappenberg L, Sigwart U: Angiographic follow-up after placement of a self-expanding coronary-artery stent. *N Engl J Med* 1991;324: 13-17
17. Serruys PW, Beatt KJ, van der Giessen WJ: Stenting of coronary arteries: Are we the sorcerer's apprentice? *Eur Heart J* 1989;10:774-782
18. Reiber JHC, Kooijman CJ, Slager CJ, Gerbrands JJ, Schuurbijs JCH, den Boer A, Wijns W, Serruys PW, Hugenholtz PG: Coronary artery dimensions from cineangiograms—methodology and validation of a computer-assisted analysis procedure. *IEEE Trans Med Imag* 1984;MI-3:131-141
19. Reiber JHC, Serruys PW, Kooijman CJ, Wijns W, Slager CJ, Gerbrands JJ, Schuurbijs JCH, den Boer A, Hugenholtz PG: Assessment of short-, medium-, and long-term variations in arterial dimensions from computer-assisted quantitation of coronary cineangiograms. *Circulation* 1985;71:280-288
20. Serruys PW, Reiber JHC, Wijns W, van den Brand M, Kooijman CJ, ten Katen HJ, Hugenholtz PG: Assessment of percutaneous transluminal coronary angioplasty by quantitative coronary angiography: Diameter versus densitometric area measurements. *Am J Cardiol* 1984;54:482-488
21. Polimeni PI, Cunningham P, Otten MD, McCrea D: Morphometric quantification of atherosclerotic plaques by computer-assisted image-analysis of histographs. *Comput Biomed Res* 1987;20:113-124
22. Weiner BH, Ockene JS, Jarmolych J, Fritz KE, Daoud AS: Comparison of pathologic and angiographic findings in a porcine preparation of coronary atherosclerosis. *Circulation* 1985;72:1081-1086
23. Roubin GS, Douglas JS Jr, Lembo NJ, Black AJ, King SB III: Intracoronary stenting for acute closure following percutaneous transluminal coronary angioplasty (PTCA) (abstract). *Circulation* 1988;78(suppl II):II-407
24. Sigwart U, Vogt P, Goy JJ, Urban P, Stauffer JC, Kappenberg L, Fischer A: Creatine kinase levels after bail-out

- stenting for post-angioplasty coronary occlusion (abstract). *Circulation* 1989;80(suppl II):II-258
25. Schatz RA, Baim DS, Leon M, Ellis SG, Goldberg S, Hirshfeld JW, Cleman MW, Cabin HS, Walker C, Stagg J, Buchbinder M, Teirstein PS, Topol EJ, Savage M, Perez JA, Curry RC, Whitworth H, Sousa JE, Tio F, Almagor Y, Ponder R, Penn IM, Leonard B, Levine SL, Fish RD, Palmaz JC: Clinical experience with the Palmaz-Schatz coronary stent. Initial results of a multicenter study. *Circulation* 1991;83:148-161
 26. Serruys PW, Beatt KJ, de Feyter PJ, Suryapranata H, van den Brand M, Geuskens R: Stent implantation for the treatment of coronary artery bypass graft stenosis (abstract). *J Am Coll Cardiol* 1989;13:107A
 27. Urban P, Sigwart U, Golf S, Kaufmann U, Sadeghi H, Kappenberg L: Intravascular stenting for stenosis of aorto-coronary venous bypass grafts. *J Am Coll Cardiol* 1989;13:1085-1091
 28. Muller DW, Ellis SG, Debowey DL, Topol EJ: Superior immediate quantitative angiographic outcome for coronary atherectomy and stenting: Results of a matched pair comparison with balloon angioplasty (abstract). *Circulation* 1989;80(suppl II):II-259
 29. Beatt KJ, Bertrand M, Puel J, Rickards T, Serruys PW, Sigwart U: Additional improvement in vessel lumen in the first 24 hours after stent implantation due to radial dilating force (abstract). *J Am Coll Cardiol* 1989;13:224A
 30. Schatz RA, Palmaz JC, Tio FC, Garcia F, Garcia O, Reuter SR: Balloon-expandable intracoronary stents in the adult dog. *Circulation* 1987;76:450-457
 31. Roubin GS, Robinson KA, King SB III, Gianturco C, Black AJ, Brown JE, Siegel RJ, Douglas JS Jr: Early and late results of intracoronary arterial stenting after coronary angioplasty in dogs. *Circulation* 1987;76:891-897
 32. Baim DS, Schatz R, Cleman M, Curry C: Predictors of unsuccessful placement of the Schatz-Palmaz coronary stent (abstract). *Circulation* 1989;80(suppl II):II-174
 33. White CJ, Ramee SR, Ross TC, Banks AK, Wiktor D, Graeber GM, Goldstein RE, Price HL, Isner JM: A new percutaneous balloon-expandable stent (abstract). *Circulation* 1988;78(suppl II):II-409
 34. Palmaz JC, Sibbitt RR, Tio FO, Reuter SR, Peters JE, Garcia F: Expandable intraluminal vascular graft: A feasibility study. *Surgery* 1986;99:199-205
 35. Rousseau H, Puel J, Joffre F, Sigwart U, Dubouchier C, Imbert C, Knight C, Kropf L, Wallsten H: Self-expanding endovascular prosthesis: An experimental study. *Radiology* 1987;163:709-714
 36. Zitter H, Plenk H: The electrochemical behavior of metallic implant materials as an indicator of their biocompatibility. *J Biomed Mater Res* 1987;21:881-896
 37. Urban P, Sigwart U, Kaufmann U, Kappenberg L: Restenosis within coronary stents: Possible effect of previous angioplasty (abstract). *J Am Coll Cardiol* 1989;13:107A
 38. Austin GE, Ratliff NB, Hollman J, Tabei S, Phillips DF: Intimal proliferation of smooth muscle cells as an explanation for recurrent coronary artery stenosis after percutaneous transluminal coronary angioplasty. *J Am Coll Cardiol* 1985;6:369-375
 39. Liu MW, Roubin GS, King SB: Restenosis after coronary angioplasty: Potential biologic determinants and role of intimal hyperplasia. *Circulation* 1989;79:1374-1387
 40. Litvack F: Intravascular stenting for prevention of restenosis: In search of the magic bullet. *J Am Coll Cardiol* 1989;13:1092-1093
 41. van der Giessen WJ, Serruys PW, Visser WJ, Verdouw PD, van Schalkwijk WP, Jongkind JF: Endothelialization of intravascular stents. *J Intervent Cardiol* 1988;1:109-120
 42. Schwartz RS, Murphy JG, Edwards WD, Camrud AR, Vlietstra RE, Holmes DR: Restenosis after balloon angioplasty: A practical proliferative model in porcine coronary arteries. *Circulation* 1990;82:2190-2200
 43. Barth KH, Virmani R, Strecker EP, Savin MA, Lindisch D, Matsumoto AH, Teitelbaum GP: Flexible tantalum stents implanted in aortas and iliac arteries: Effects in normal canines. *Radiology* 1990;175:91-96
 44. Rodgers GP, Minor ST, Robinson K, Cromeens D, Woolbert SC, Stevens LC, Guyton JR, Wright K, Roubin GS, Raizner AE: Adjuvant therapy for intracoronary stents: Investigations in atherosclerotic swine. *Circulation* 1990;82:560-569

KEY WORDS • percutaneous transluminal coronary angioplasty
• stents • prostheses • electron microscopy