

# Predictive Value of Reactive Hyperemic Response on Reperfusion on Recovery of Regional Myocardial Function After Coronary Angioplasty in Acute Myocardial Infarction

Harry Suryapranata, MD, PhD; Felix Zijlstra, MD, PhD; Donald C. MacLeod, MRCP, PhD; Marcel van den Brand, MD, PhD; Pim J. de Feyter, MD, PhD; Patrick W. Serruys, MD, PhD

**Background** The objective of the study was to determine the coronary vasodilatory reserve in reperfused myocardium in patients with acute myocardial infarction and its relation to regional myocardial function.

**Methods and Results** The study population consisted of 22 patients with acute myocardial infarction who underwent successful coronary angioplasty. The vasodilatory reserve in the reperfused myocardium was assessed quantitatively using computer-assisted digital subtraction cine-angiography immediately after angioplasty and at follow-up angiography before hospital discharge. Myocardial contrast medium appearance time and density were determined before and after pharmacological hyperemia induced by an intracoronary injection of 12.5 mg papaverine. Global and regional left ventricular functions were determined from contrast angiography. After papaverine, the mean contrast medium appearance time decreased significantly from  $3.5 \pm 0.7$  to  $2.7 \pm 0.7$  cardiac cycles ( $P < .000005$ ) immediately after successful coronary angioplasty and from  $3.8 \pm 0.7$  to  $2.7 \pm 0.9$  cardiac cycles ( $P < .000005$ ) at angiography before hospital discharge. The mean contrast medium density increased significantly from  $48.7 \pm 13.8$  to  $61.0 \pm 19.0$  pixels ( $P < .003$ ) and from  $49.6 \pm 19.7$  to  $80.3 \pm 29.6$  pixels ( $P < .000005$ ), respectively. As a consequence, the calcu-

lated coronary flow reserve increased significantly from  $1.8 \pm 0.7$  to  $2.6 \pm 1.0$  ( $P < .0008$ ). The global ejection fraction increased significantly from  $52 \pm 12\%$  to  $58 \pm 14\%$  ( $P < .03$ ), primarily because of a significant improvement in the regional myocardial function of the infarct zone from  $20.8 \pm 9.0\%$  to  $26.0 \pm 10.5\%$  ( $P < .0001$ ). Coronary flow reserve correlated well with regional myocardial function both during the acute phase ( $R = .79$ ,  $P < .002$ ) and at follow-up angiography ( $R = .82$ ,  $P < .000004$ ). Interestingly, coronary flow reserve measurement on reperfusion, immediately after angioplasty, correlated significantly with regional myocardial function at follow-up angiography ( $R = .81$ ,  $P < .00003$ ).

**Conclusions** The results indicate that there is a pharmacologically inducible vasodilatory reserve in reperfused ischemic myocardium after successful coronary angioplasty in patients with acute myocardial infarction and that this is increased at 10-day follow-up angiography. More important, the degree of reactive hyperemic response on reperfusion has a predictive value regarding the ultimate degree of recovery of regional myocardial function. Quantitative assessment of reperfusion may be useful in investigating the role of coronary reperfusion and salvage of myocardial function. (*Circulation*. 1994;89:1109-1117.)

**Key Words** • reperfusion • infarcts

**R**eduction in mortality and limitation of myocardial infarct size through early recanalization are the major goals in the management of patients with acute myocardial infarction (AMI). Previous studies have shown not only that percutaneous transluminal coronary angioplasty (PTCA) can be performed safely and effectively in patients with AMI but also that regional left ventricular function of the infarct zone can be improved after successful PTCA.<sup>1-4</sup> However, the effect on regional blood flow reserve in the reperfused myocardium remains to be established.

The potential merit of measuring coronary flow reserve in an area of myocardium supplied by a stenosed coronary artery has been recognized.<sup>5-9</sup> Evidence has accumulated that in AMI, vascular injury and the "no-reflow" phenomenon in the reperfused myocardium may be related to the accumulation of neutrophils

or to the production of leukotrienes, which may exacerbate myocardial ischemia by increasing vascular permeability and coronary vascular resistance.<sup>10,11</sup> Consequently, one may question whether the (ir)reversibility of vascular damage could be clinically explored using pharmacologically induced hyperemia during cardiac catheterization in the setting of AMI.

This study was undertaken to assess quantitatively the vasodilatory reserve in reperfused myocardium and its impact on the recovery of regional myocardial function after successful PTCA in patients with AMI.

## Methods

### Patients

Patients selected for the study were those who underwent successful PTCA within 4 hours of AMI managed with thrombolysis and had persistent patency of the infarct-related vessel at follow-up angiography before hospital discharge. The study population consisted of 22 patients, of whom 16 were men. Clinical and angiographic data are summarized in Tables 1 and 2. All patients had chest pain of less than 4 hours' duration at the time of admission and had ST-segment elevation typical of AMI on their ECG. Those with a history of systemic hypertension, cardiac hypertrophy, anemia, polycythemia, previous

Received August 9, 1993; revision accepted December 9, 1993.  
From the Thoraxcenter, Erasmus University Hospital Rotterdam, The Netherlands.

Correspondence to Harry Suryapranata, MD, PhD, Department of Cardiology, Hospital De Weezenlanden, Groot Weezenland 20, 8011 JW Zwolle, The Netherlands.

**TABLE 1. Clinical Characteristics of Patients With Infarction**

No. of patients	22	(16 men)
Mean age, y (range)	57	(42 to 66)
Infarct location		
Anterior	11	(50%)
Inferior	11	(50%)
Time from symptom onset to PTCA, h (range)	2.5	(1 to 3.5)
Peak creatinine phosphokinase, U/L (range)	995	(221 to 2208)
Time to follow-up angiography, d (range)	10	(6 to 16)

PTCA indicates percutaneous transluminal coronary angioplasty.

myocardial infarction, valvular heart disease, hemorrhagic diathesis, or previous cerebrovascular accident were excluded. Informed consent was obtained from the patients for the additional investigation. Immediately after admission, 500 000 U of streptokinase was administered intravenously, and the patients were transferred to the catheterization laboratory. All were studied without premedication.

### Intracoronary Thrombolysis and Coronary Angioplasty

Initial angiography of the suspected infarct-related artery and administration of intracoronary streptokinase were performed as previously described.<sup>1-3</sup> Briefly, intracoronary perfusion with streptokinase was carried out at a rate of 4000 U/min to a maximum of 250 000 U. Repeat coronary angiography was performed on multiple projections and followed by the coronary angioplasty procedure. Coronary angiography was then repeated in multiple views corresponding to those used before the angioplasty procedure. Angioplasty was considered successful when a reduction of the severity of the obstruction to <50% luminal diameter narrowing was achieved with the abolition of acute ischemic symptoms and without recurrent ischemia, coronary bypass surgery, or death. Left ventricular angiography and the measurement of coronary flow reserve were performed at the end of the procedure. Before hospital discharge, coronary and left ventricular angiography and a further measurement of coronary flow reserve were repeated using the same procedure.

### Analysis of Coronary and Left Ventricular Angiography

The quantitative analysis of the target coronary segment before and after coronary angioplasty and at follow-up angi-

**TABLE 2. Angiographic Data for Study Patients**

	No. (%)
Infarct-related artery	
Left anterior descending coronary artery	11 (50)
Right coronary artery	11 (50)
Initial totally occluded vessel	
Left anterior descending coronary artery	4 (36)
Right coronary artery	5 (45)
Extent of coronary disease	
One vessel	11 (50)
Two vessels	9 (41)
Three vessels	2 (9)

ography was performed using the computer-assisted Coronary Angiography Analysis System (CAAS), which has been described in detail previously.<sup>12,13</sup> Briefly, to analyze a coronary arterial segment in a selected frame of 35-mm cine-film, an optically magnified portion of the image encompassing the segment is converted into video format by means of a cine-video converter. The contours of the vessel are detected automatically on the basis of the weighted sum of first- and second-derivative functions applied to the digitized brightness information. Calibration of the diameter of the vessel in absolute values (mm) is achieved by using the angiography/guiding catheter as a scaling device. To this end, the contours of a user-defined portion of the optimally magnified catheter, empty of contrast, are detected automatically and corrected for pincushion distortion caused by the image intensifier. From the contours, the vessel diameter functions (mm) are determined by computing the shortest distances between the left and right contour positions.

Global and regional left ventricular functions were evaluated in the 30° right anterior oblique projection. The method of analysis is based on automated, high-resolution, frame-to-frame edge detection of the left ventricular contour and has been described in detail previously.<sup>14,15</sup> Systolic regional wall displacement was determined along a system of 20 coordinates on the pattern of actual endocardial wall motion and generalized as a mathematic expression amenable to automatic data processing. The left ventricular end-diastolic cavity was divided into 20 half-slices. The regional contribution to global ejection fraction was determined from the systolic decrease of volume of the half-slice that corresponds to a particular wall segment. When normalized for end-diastolic volume, the systolic segmental volume change was considered as a parameter of regional pump function. During systole, this parameter expresses quantitatively the contribution of a particular segment to global ejection fraction. The sum of the values for all 20 segments equals the global ejection fraction.

### Coronary Flow Reserve

The calculation of coronary flow reserve was based on digital subtraction cine-angiographic determination of the appearance time and density of myocardial contrast.<sup>8,9,16</sup> The analysis involves the digitization of selected end-diastolic cine-frames and the application of logarithmic nonmagnified mask-mode background subtraction. Measurement was performed after the administration of 2 mg intracoronary isosorbide dinitrate.<sup>17,18</sup> The heart was atrially paced at a rate just above the spontaneous heart rate. An ECG-triggered injection (300 milliseconds after the R wave) of a fixed amount of nonionic contrast medium (iopamidol at 37°C) into the coronary artery was made using a Medrad Mark IV infusion pump. This nonionic contrast medium has a viscosity of 9.4 cP at 37°C, an osmolality of 0.796 osm/kg, and an iodine content of 370 mg/mL. Injection rates were constant and judged adequate if back-flow of contrast medium into the aorta was seen. For the left coronary artery, 7 mL was injected at a flow rate of 4 mL/s, and for the right coronary artery, 5 mL was injected at a flow rate of 3 mL/s. The field size of the radiographic equipment was 7 in. The angiogram was repeated during pharmacological hyperemia, 30 seconds after a bolus injection of 12.5 mg of papaverine into the coronary artery.<sup>9,17</sup>

For the quantification of the relative coronary blood flow, five to eight end-diastolic cine-frames were selected from successive cardiac cycles. Logarithmic nonmagnified mask-mode background subtraction was applied to the image subset to eliminate noncontrast medium densities. The last end-diastolic frame before administration of contrast was chosen as the mask. Each digitized image was also corrected for the dark current of the video camera. From the sequence of background-subtracted images, a contrast arrival time image was determined with the use of a fixed-density threshold.<sup>9</sup> In this image, each pixel was labeled with the sequence number of the

cardiac cycle in which pixel intensity level for the first time exceeded the threshold, starting from the beginning of the ECG-triggered contrast injection. This density threshold has been derived empirically by analyzing the relation between the threshold, baseline and hyperemic myocardial contrast medium appearance times, and the resulting coronary flow reserve in 12 patients.<sup>9</sup> In addition to the contrast arrival time image, a density image was computed with each pixel intensity value being representative of the maximal local contrast medium accumulation. Finally, the information from these two images was combined into a dual-parameter image, the contrast medium appearance picture. In this picture, the appearance time was color-coded, and the contrast medium accumulation was represented by color intensity. Coronary flow reserve was defined as the ratio of the regional flow computed from a hyperemic image divided by the regional flow of the corresponding baseline image. Regional flow values were determined using the following videodensitometric principle:

$$\text{Regional blood flow (Q)} = \frac{\text{Regional vascular volume (RVV)}}{\text{Transit time}}$$

Regional vascular volume was assessed from the logarithmic mask-mode subtraction images. At the flow rates used, essentially all epicardial blood is replaced by contrast medium; therefore, the brightness information is proportional to the local thickness of the projected vascular system, and thus  $RVV = k \int_R V(p) dp$ , where  $k$  is constant,  $R$  is the selected region of interest,  $V(p)$  is the intensity distribution function of the subtraction image, and  $dp$  is the pixel position (Beers-Lambert relation). If the same regions of interest are used for baseline and hyperemic conditions, the coronary flow reserve can be determined from the regional blood flow values,  $Q_h$  and  $Q_b$ , at the hyperemic ( $h$ ) and baseline ( $b$ ) states, respectively:

$$Q_h/Q_b = (CD_h/AT_h)/(CD_b/AT_b)$$

where  $CD$  is the mean contrast density, and  $AT$  is the mean appearance time.

Mean contrast medium appearance time and density were computed with user-defined regions of interest. The regions of interest were selected and analyzed in an area of myocardium supplied by the infarct-related coronary artery, using a writing tablet that is interfaced with the computer, and were chosen in such a way that the epicardial arteries visible on the angiogram, including side-branches, aortic root, coronary sinus, and great cardiac vein, were excluded from the analysis. Care was taken to ensure that the analyzed regions of interest as well as cine-angiographic projections and radiograph gantry settings in the multiplicate determinations were identical.

### Statistical Analysis

Values are given as mean  $\pm$  SD. Student's paired  $t$  test was applied where appropriate. Pearson's correlation coefficient was used to define the relation between coronary flow reserve and regional myocardial function. A value of  $P < .05$  was considered significant.

## Results

### Stenosis Geometry

The mean obstruction area of the target coronary segment was  $0.76 \pm 0.24$  mm<sup>2</sup> before PTCA,  $3.61 \pm 1.62$  mm<sup>2</sup> immediately after angioplasty, and  $4.45 \pm 1.82$  mm<sup>2</sup> at angiography before hospital discharge. Follow-up angiography was performed at a mean of 10 days (range, 6 to 16 days) after PTCA.

### Global and Regional Left Ventricular Functions

Table 3 shows the changes in parameters of left ventricular function between the acute stage, immedi-

TABLE 3. Global and Regional Left Ventricular Functions

	Acute	Follow-up	P
Heart rate, beats per minute	82 $\pm$ 14	81 $\pm$ 10	NS
Mean aortic pressure, mm Hg	86 $\pm$ 12	91 $\pm$ 12	NS
End-diastolic pressure, mm Hg	16 $\pm$ 9	10 $\pm$ 6	.04
End-diastolic volume index, mL/m <sup>2</sup>	70 $\pm$ 17	72 $\pm$ 14	NS
End-systolic volume index, mL/m <sup>2</sup>	34 $\pm$ 13	30 $\pm$ 13	.03
Global ejection fraction, %	52 $\pm$ 12	58 $\pm$ 14	.03
Regional ejection fraction, %	20.8 $\pm$ 9.0	26.0 $\pm$ 10.5	.0001
Anterior infarction (n=11)	16.3 $\pm$ 7.8	20.8 $\pm$ 9.9	.003
Inferior infarction (n=11)	25.3 $\pm$ 8.0	31.2 $\pm$ 8.8	.008
Initially patent IRV* (n=13)	20.2 $\pm$ 9.0	25.3 $\pm$ 10.8	.01
Initially occluded IRV* (n=9)	21.7 $\pm$ 9.4	27.1 $\pm$ 10.7	.0002

\*Patency of the infarct-related vessel (IRV) at the time of angioplasty.

Values are given as mean  $\pm$  SD.

ately after successful PTCA, and at follow-up angiography before hospital discharge. There were no significant changes in heart rate and mean aortic pressure, whereas end-diastolic pressure decreased significantly from  $16 \pm 9$  to  $10 \pm 6$  mm Hg ( $P < .04$ ). Because end-diastolic volume remained unchanged while end-systolic volume decreased significantly, the mean global ejection fraction increased significantly from  $52 \pm 12\%$  to  $58 \pm 14\%$  ( $P < .03$ ). This improvement in global ejection fraction was primarily the result of a significant increase, from  $20.8 \pm 9.0\%$  to  $26.0 \pm 10.5\%$  ( $P < .0001$ ), in the regional contribution of the infarct zone, as shown in Fig 1 and Table 3.

### Vasodilatory Reserve in Reperfused Myocardium

The changes in myocardial contrast medium appearance time and density, before and 30 seconds after pharmacologically induced hyperemia, are shown in Table 4. Mean myocardial contrast medium appearance time decreased significantly from  $3.5 \pm 0.7$  to  $2.7 \pm 0.7$  cardiac cycles ( $P < .000005$ ) immediately after successful PTCA and from  $3.8 \pm 0.7$  to  $2.7 \pm 0.9$  cardiac cycles ( $P < .000005$ ) at follow-up angiography. Mean contrast medium density increased significantly from  $48.7 \pm 13.8$  to  $61.0 \pm 19.0$  pixels ( $P < .003$ ) and subsequently from  $49.6 \pm 19.7$  to  $80.3 \pm 29.6$  pixels ( $P < .000005$ ). As a consequence, the calculated coronary flow reserve increased significantly from  $1.8 \pm 0.7$  immediately after PTCA to  $2.6 \pm 1.0$  ( $P < .0008$ ) at follow-up angiography. Fig 2 shows the individual changes in coronary blood flow reserve from the acute stage to follow-up angiography.

### Relation With Regional Myocardial Function of Infarct Zone

The relation between coronary flow reserve and the regional function of the infarct zone is shown in Table 5 and Figs 3 and 4. These two parameters correlated well both during the acute phase ( $R = .79$ ,  $P < .002$ ) and at follow-up angiography ( $R = .82$ ,  $P < .000004$ ), as shown in

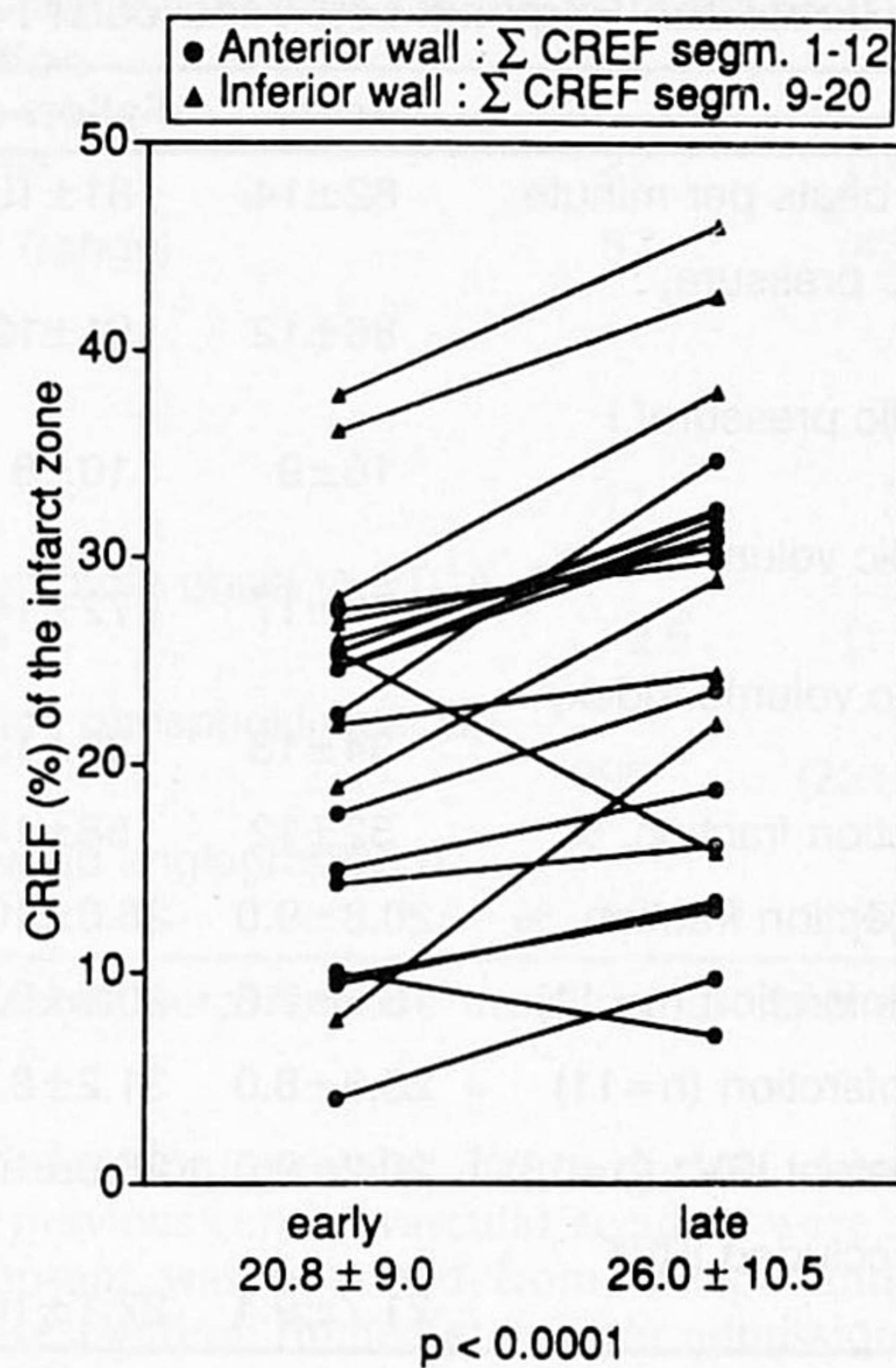


FIG 1. Plot of individual changes in regional contribution to global ejection fraction (CREF) of the infarct zone from the acute stage (early) to follow-up angiography before hospital discharge (late). Circles represent patients with anterior wall myocardial infarction, and triangles represent those with inferior infarction. The sums of segmental CREF values were analyzed in the anterobasal, anterolateral, and apical wall regions (segments 1 through 12) for anterior infarction and in the inferoposterior and apical wall regions (segments 9 through 20) for inferior infarction.

Fig 3. A significant negative correlation ( $R = -.714$ ,  $P < .002$ ) was also observed between coronary flow reserve and the peak creatinine phosphokinase value (Fig 3D). Coronary flow reserve measured on reperfusion, immediately after PTCA, correlated significantly ( $R = .81$ ,  $P < .00003$ ) with the regional myocardial function of the infarct zone at follow-up angiography (Fig 4). These relations were comparable in patients with either anterior or inferior infarction and in patients with or without a patent infarct-related artery before angioplasty (Table 5). In addition, no significant correlation could be demonstrated between time from symptom onset to vessel opening and regional myocardial function or coronary flow reserve.

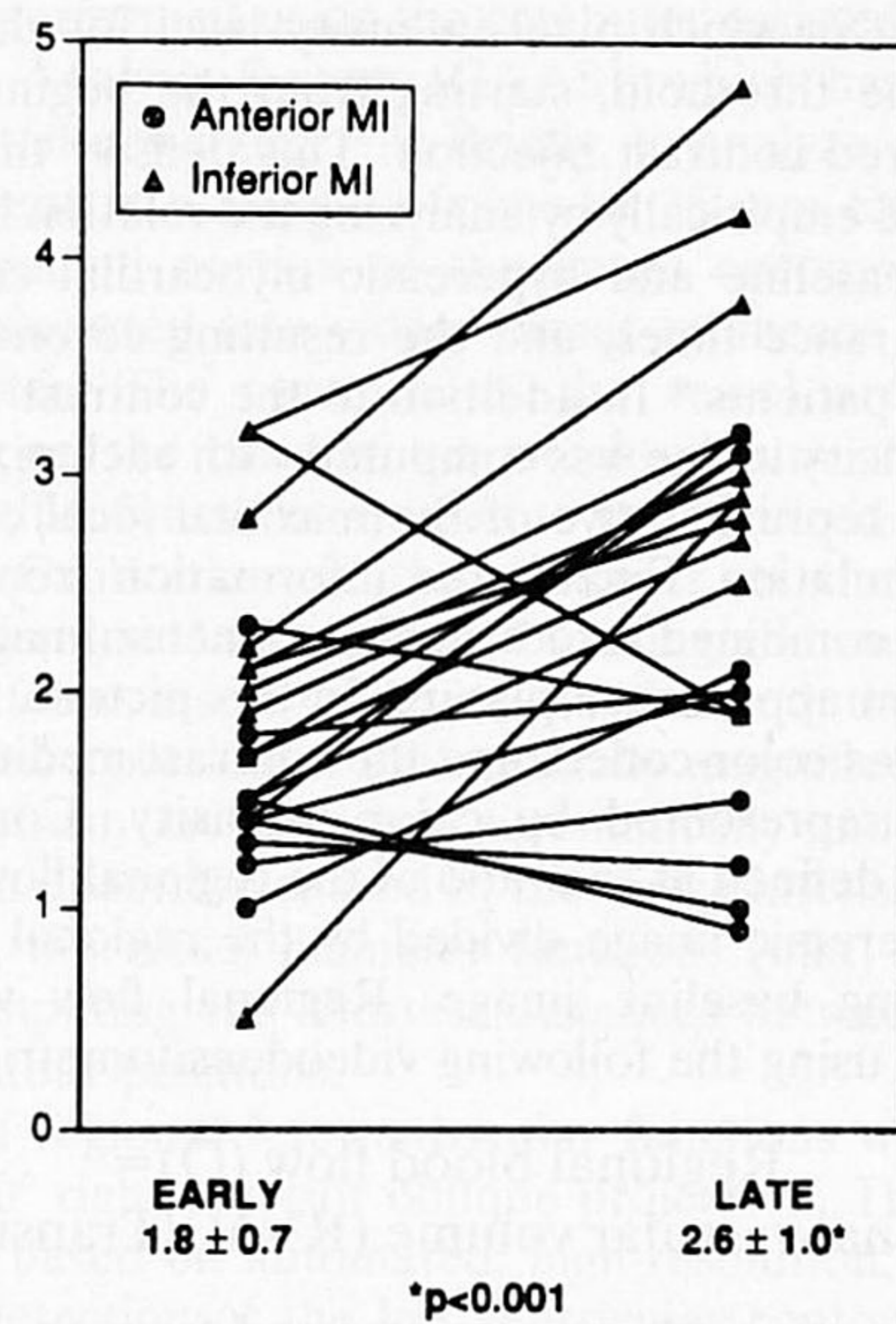


FIG 2. Plot of individual changes in the calculated coronary blood flow reserve from the acute stage (EARLY), immediately after successful coronary angioplasty, to follow-up angiography before hospital discharge (LATE). Circles represent patients with anterior myocardial infarction (MI), and triangles represent those with inferior infarction.

### Discussion

This study examined coronary vasodilatory reserve and regional myocardial function in reperfused myocardium during acute and chronic phases of myocardial infarction. The patient group was highly selected in that all underwent successful PTCA of the infarct-related artery within 4 hours of AMI and that in all patients the dilated vessel was still patent at follow-up angiography before hospital discharge. Furthermore, patients with a history of systemic hypertension, cardiomyopathy, cardiac hypertrophy, hematological or endocrinological disorders, previous AMI, valvular heart disease, hemorrhagic diathesis, or previous cerebrovascular accident were excluded from the study. Thus, the findings should not be extrapolated to the majority of patients with an infarct. However, because previous clinical reports on regional coronary flow in the context of infarction and reperfusion are limited,<sup>19-21</sup> this study is the first to document the relation between coronary flow reserve,

TABLE 4. Myocardial Contrast Medium Appearance Time and Density

	Immediately After PTCA		At Follow-up Angiography	
	Baseline	Hyperemia	Baseline	Hyperemia
Appearance time	3.5±0.7	2.7±0.7‡	3.8±0.7	2.7±0.9‡
Density	48.7±13.8	61.0±19.0†	49.6±19.7	80.3±29.6‡
Coronary flow reserve		1.8 ± 0.7		2.6 ± 1.0†
Anterior infarction (n=11)		1.5 ± 0.3		2.0 ± 0.8
Inferior infarction (n=11)		2.1 ± 0.8		3.2 ± 0.8†
Initially patent IRV (n=13)		1.8 ± 0.8		2.5 ± 0.8*
Initially occluded IRV (n=9)		1.8 ± 0.5		2.7 ± 1.3*

PTCA indicates percutaneous transluminal coronary angioplasty; IRV, patency of the infarct-related vessel at the time of angioplasty (see also Table 3). Values are expressed as mean±SD. \* $P < .02$ , † $P < .003$ , ‡ $P < .000005$ .

TABLE 5. Correlations Between Coronary Flow Reserve and Regional Myocardial Function

Correlation	Anterior MI (n=11)		Inferior MI (n=11)		Patent IRV (n=13)		Occluded IRV (n=9)	
	R	P	R	P	R	P	R	P
CREF acute-ΔCREF	.39	.2	-.25	.5	-.04	.9	.45	.2
CFR acute-ΔCFR	-.27	.4	-.55	.08	-.59	.04	.73	.03
CFR acute-CREF acute	.81	.003	.47	.1	.63	.03	.77	.02
CFR at F/U-CREF at F/U	.65	.03	.65	.03	.64	.02	.89	.002
ΔCFR-ΔCREF	.63	.04	.76	.007	.74	.004	.71	.03
CFR acute-CREF at F/U	.69	.02	.81	.002	.77	.002	.84	.005

MI indicates myocardial infarction; IRV, patency of the infarct-related vessel at the time of angioplasty; CREF, regional contribution of the infarct zone to global ejection fraction; CFR, coronary flow reserve; and Δ, changes between acute stage and follow-up angiography before hospital discharge (F/U).

measured with radiographic technique, and functional recovery of reperfused myocardium in a series of patients with AMI.

The results indicate that a pharmacologically inducible vasodilatory reserve may persist in AMI and increase significantly with recovery. Furthermore, the extent of increase in flow reserve was found to correlate positively and significantly with early improvement in global and regional myocardial functions.

**Vasodilatory Reserve in Reperfused Myocardium**

In this patient group, despite successful PTCA and a significant increase documented at follow-up angiography, vasodilatory reserve remained abnormal. Our previous study<sup>9</sup> established the relation between cross-sectional obstruction area and coronary flow reserve in patients with stable angina and one-vessel coronary artery disease. Fig 5 shows this relation with the present study's early and late measurements of obstruction area

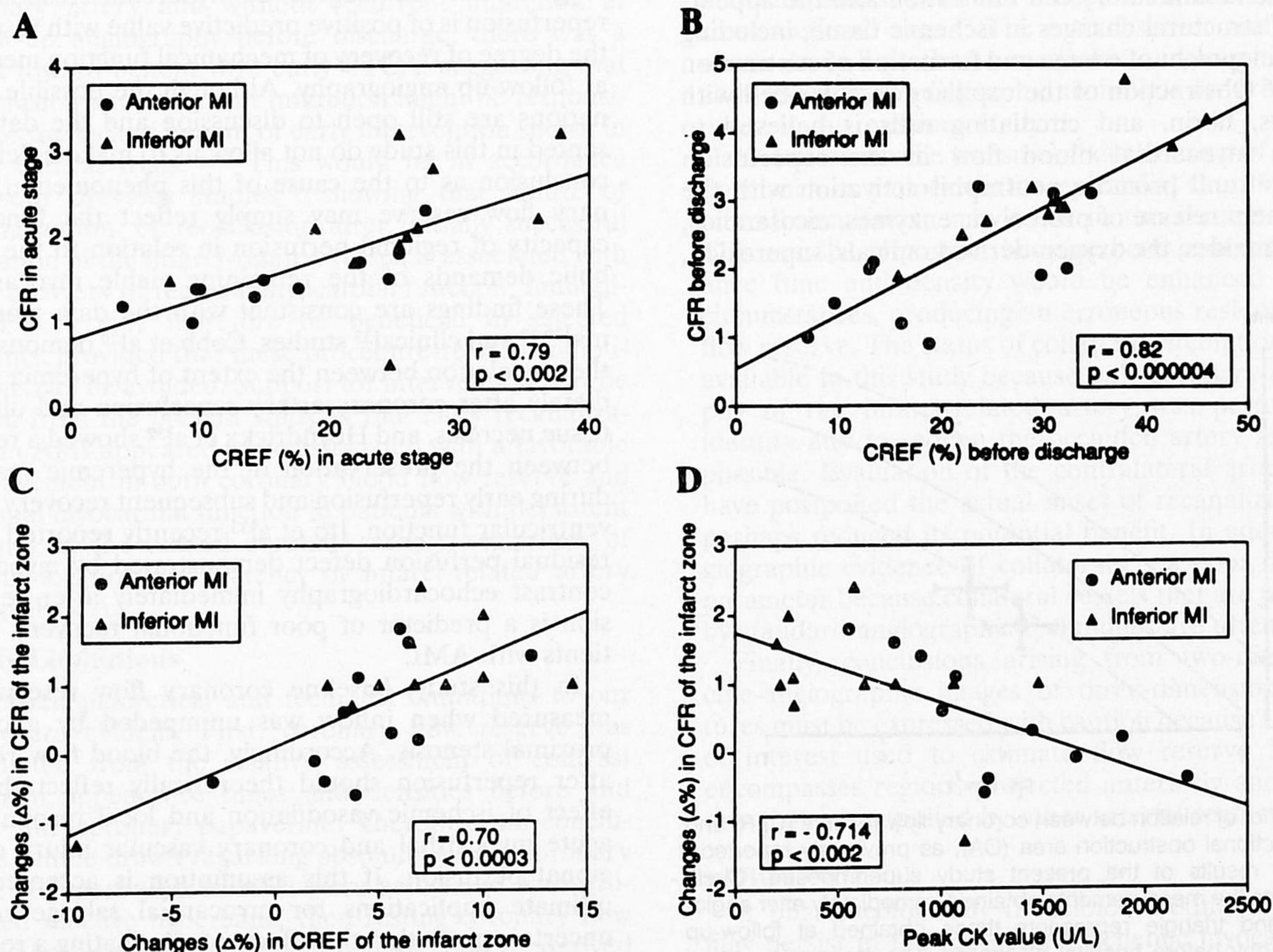


FIG 3. Scatterplots of relation between coronary flow reserve (CFR) and regional myocardial function (CREF) of the infarct zone at the acute stage, immediately after successful coronary angioplasty (A), and at follow-up angiography before hospital discharge (B). A significant correlation was also observed between changes (Δ%) in coronary flow reserve and those in regional function of the infarct zone (C), as well as peak creatinine phosphokinase (CK) value (D). Circles represent patients with anterior myocardial infarction (MI), and triangles represent those with inferior infarction.

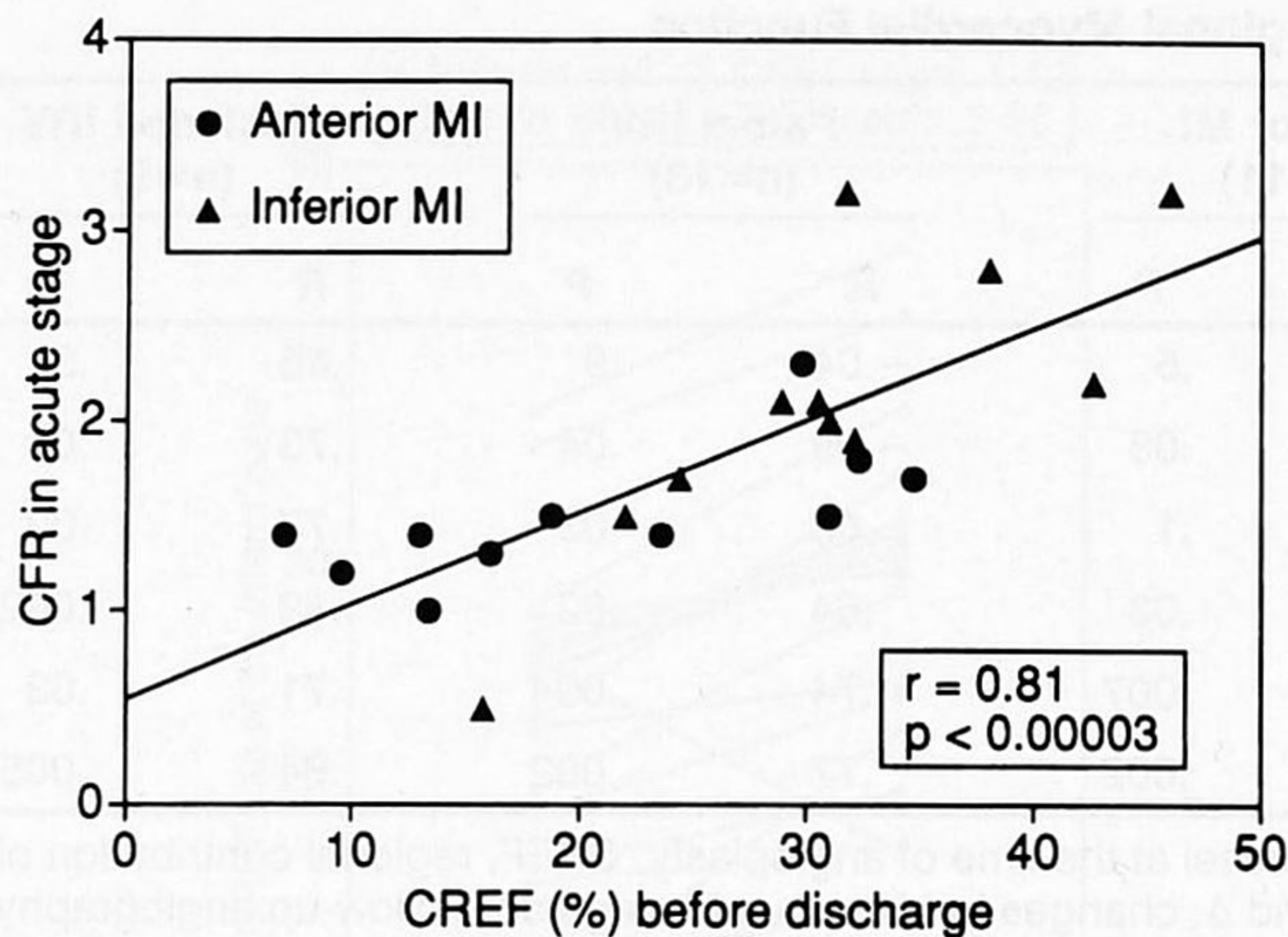


FIG 4. Scatterplot of relation between coronary flow reserve (CFR) at the acute stage, immediately after successful angioplasty, and regional myocardial function (CREF) of the infarct zone at follow-up angiography before hospital discharge. MI indicates myocardial infarction.

and flow reserve superimposed; the values lie just outside the 95% confidence limits of the relation. Thus, for the given obstruction areas, the corresponding flow reserve is reduced. This relative lack of hyperemia may represent the "no-reflow" or, more accurately, the impaired reflow phenomenon.<sup>22</sup> Prolonged ischemia resulting in cellular injury may initiate local responses altering myocardial perfusion.<sup>22-25</sup> Coronary reflow accelerates inflammatory cell infiltration and the appearance of structural changes in ischemic tissue, including the development of edema and formation of contraction bands.<sup>25</sup> Obstruction of the capillary vascular bed with platelets, fibrin, and circulating cells is believed to impede myocardial blood flow in the reperfusion phase<sup>10,11</sup> and promote neutrophil activation with the subsequent release of proteolytic enzymes, eicosanoids, lipid peroxides, the oxygen-derived radicals, superoxide,

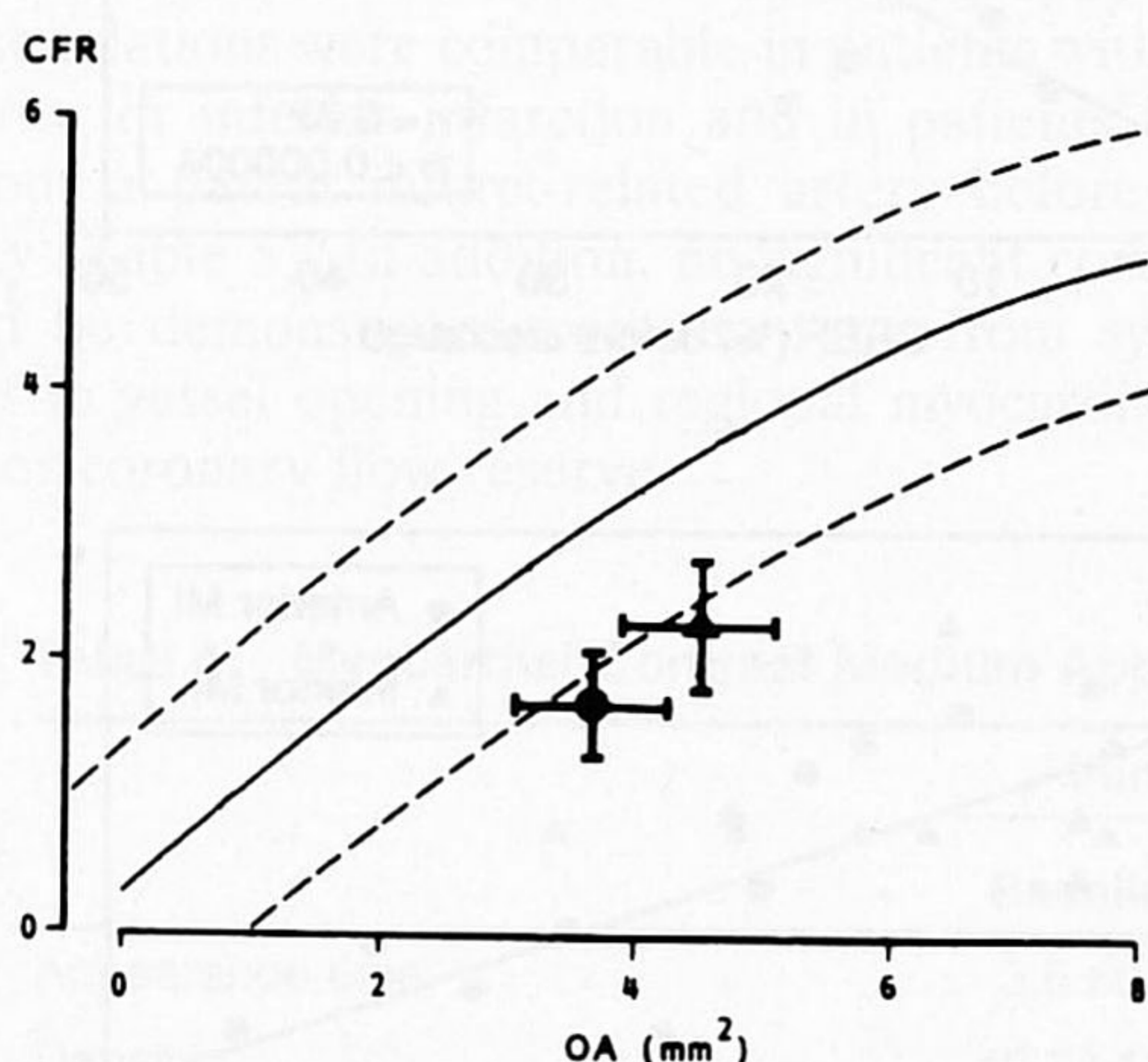


FIG 5. Plot of relation between coronary flow reserve (CFR) and cross-sectional obstruction area (OA), as previously reported,<sup>9</sup> with the results of the present study superimposed. Circle represents the measurements obtained immediately after angioplasty, and triangle represents those obtained at follow-up angiography before hospital discharge. The mean values and standard deviations of the calculated coronary flow reserve and obstruction area, as obtained in the present study, fall just outside the 95% confidence limits (dashed lines) of this relation. For any given obstruction area, the corresponding coronary flow reserve for this group of patients is below the expected value.

and hydrogen peroxide.<sup>10,11,26</sup> Increasing vascular permeability completes a vicious circle by exacerbating interstitial edema and the extravascular resistance to blood flow.<sup>11,26</sup>

Regardless of these pathological phenomena, acute cellular injury producing myocardial necrosis<sup>27</sup> and acute coronary occlusion<sup>28</sup> in the dog does not completely eliminate hyperemic responses. The magnitude of hyperemic responses in experimental infarction was reduced in direct proportion to the extent of eventual histological necrosis<sup>29</sup>; findings consistent with our results as shown in Fig 3D. Furthermore, Cobb et al,<sup>29</sup> showed that reduced regional flow was similar at 4 hours and 3 days after reperfusion, indicating that local tissue responses reducing perfusion were elicited and completed within 4 hours.

### Preservation of Regional Left Ventricular Function

Although several studies have focused on the potential for reperfusion to produce additional myocardial injury, both experimental<sup>30</sup> and clinical<sup>1,31</sup> studies have established that coronary reperfusion implemented early after the ischemic insult can prevent threatened myocardium from deteriorating to complete necrosis, resulting in limitation of infarct size, preservation of left ventricular function, and reduction in mortality. Of interest in our study is the relation between coronary blood flow reserve and regional left ventricular function, as shown in Figs 3 and 4. Indeed, these results suggest that the degree of hyperemic response on reperfusion is of positive predictive value with respect to the degree of recovery of mechanical function measured at follow-up angiography. Although the possible explanations are still open to discussion and the data presented in this study do not allow us to make a definitive conclusion as to the cause of this phenomenon, coronary flow reserve may simply reflect the functional capacity of regional perfusion in relation to the metabolic demands of the remaining viable myocardium. These findings are consistent with the data from animal<sup>29,32</sup> and clinical<sup>33</sup> studies. Cobb et al<sup>29</sup> demonstrated the correlation between the extent of hyperemia immediately after coronary artery reperfusion and ultimate tissue necrosis, and Heyndrickx et al<sup>32</sup> showed a relation between the preservation of the hyperemic response during early reperfusion and subsequent recovery of left ventricular function. Ito et al<sup>33</sup> recently reported that a residual perfusion defect demonstrated by myocardial contrast echocardiography immediately after reperfusion is a predictor of poor functional recovery in patients with AMI.

In this study, baseline coronary flow reserve was measured when inflow was unimpeded by a critical proximal stenosis. Accordingly, the blood flow reserve after reperfusion should theoretically reflect the net effect of ischemic vasodilation and local responses to acute myocardial and coronary vascular injury on regional perfusion. If this assumption is accepted, the ultimate implications for myocardial salvage remain uncertain given that the effects of eliminating a residual stenosis on recovery of left ventricular function have not been well documented. Clinical studies have suggested that recovery of left ventricular function and the incidence of reocclusion may be related to the degree of residual stenosis after thrombolysis<sup>34</sup> and that recovery

of left ventricular function may be improved by PTCA.<sup>1,3,4,35</sup> However, large-scale randomized clinical trials have reported the lack of benefit of either immediate or delayed (18 to 48 hours) angioplasty<sup>36,37</sup> in patients treated with alteplase and infer that the experimental justification for such an approach is weak. It could be argued that a critical residual stenosis could exert a beneficial effect by attenuating the degree of early reflow and thereby limiting the amount of reperfusion-induced microvascular and myocardial injury. Alternatively, by restricting the immediate hyperemic response and limiting the degree of reflow, a critical stenosis may reduce the effectiveness of reperfusion and therefore jeopardize myocardial salvage. Experimental studies have examined the effects of partial reperfusion after coronary occlusion,<sup>38-41</sup> but findings are inconsistent. Staged versus sudden reperfusion in dogs resulted in less ventricular arrhythmia and in improved early recovery of left ventricular function,<sup>39</sup> but other studies investigating the effects of a sustained residual stenosis during reperfusion have provided conflicting results, with some demonstrating larger infarction in those animals with a residual stenosis<sup>40</sup> and others showing no difference.<sup>38,41</sup> What is clear is that these studies, where observations were made after relatively short reperfusion periods (hours), cannot exclude more prolonged (days to weeks) effects on left ventricular functional recovery. Furthermore, a recent clinical study<sup>42</sup> has shown that among patients with a patent infarct-related coronary artery and without recurrent infarction at follow-up angiography before discharge, there was a trend toward benefit with early PTCA, suggesting that reocclusion and recurrent infarction might be responsible for the lack of benefit of early intervention shown in large clinical trials.<sup>36,37</sup> This would be in accordance with our previous studies<sup>1-3</sup> showing that failure of recanalization, or reocclusion after initially successful dilatation of the infarct-related vessel, is associated with poor recovery of regional myocardial function. Immediate PTCA may therefore be beneficial in selected patients, provided that these procedure-related complications can be avoided. Support for intervention may be drawn from the present study in that early recanalization in AMI appeared to be associated with a favorable improvement in both coronary blood flow reserve and regional myocardial function in patients with persistent patency of the dilated coronary artery, regardless of infarct location and patency of infarct-related artery before PTCA.

### Study Limitations

Certain theoretical and technical limitations to our study are evident. First, coronary flow reserve was calculated from the relative assessment of contrast medium appearance times and densities before and after intracoronary papaverine. Therefore, no conclusions can be drawn regarding absolute resting coronary flow. If reperfusion in AMI were associated with prolonged reactive hyperemia, then resting coronary flow would be elevated. Consequently, flow reserve, derived in the manner we describe, would be misleadingly low. However, baseline contrast appearance time and density proved reassuringly comparable at acute and follow-up angiography (Table 3), consistent with clinical<sup>21</sup> and animal<sup>28</sup> research showing a lack of reactive hyper-

emia during reperfusion after 2 to 6 hours of coronary occlusion.

Although nonionic contrast media may disturb blood flow less than ionic agents, intracoronary administration of contrast medium results in profound alterations in coronary blood flow characterized by a transient depression in the first seconds, followed by hyperemia.<sup>16</sup> The magnitude and timing of these changes depend primarily on contrast medium iodine concentration and injection rate.<sup>43</sup> The ratio of hyperemic to baseline coronary blood flow, nevertheless, remains unchanged within the first 5 seconds after contrast injection, when care is taken to keep these factors constant.<sup>16,43</sup>

Changes in vasomotor tone not only are an important source of variability in the analysis of coronary angiograms<sup>12</sup> but also may influence coronary flow reserve measurement. To permit a valid comparison on both baseline and hyperemic conditions, changes in vasomotor tone must be avoided. This is also a prerequisite if a comparison of two or more coronary flow reserve measurements at different times is to be made. In particular, long-term study might be influenced by changes in neurohumoral factors. Therefore, pretreatment with intracoronary isosorbide dinitrate in all patients in this study effectively removes any error caused by changes in vasomotor tone. Moreover, although intracoronary papaverine does have a vasodilatory effect on both stenotic and nonstenotic coronary segments, this is the same as that produced by isosorbide dinitrate, and it does not induce a further increase in cross-sectional area.<sup>17</sup> The intraobserver and interobserver as well as short-, medium-, and long-term variabilities of this radiographic technique have been validated in our previous study.<sup>44</sup>

Alterations in the transmural distribution of coronary flow, such as endocardial-to-epicardial shunting or collateral circulation, may occur in the context of AMI. This may be important because both contrast appearance time and density would be enhanced in these circumstances, producing an erroneous residual resting flow reserve. The status of collateral circulation was not available in this study because only coronary angiography of the infarct-related artery was performed to identify and to reopen the occluded artery as soon as possible. Evaluation of the contralateral artery would have postponed the actual onset of recanalization and perhaps reduced its potential benefit. In addition, angiographic evidence of collaterals is a poor diagnostic parameter because collateral vessels that are not visible by standard angiographic techniques are often present.

Finally, conclusions arising from two-dimensional cine-angiographic images of three-dimensional structures must be expressed with caution because the region of interest used to estimate flow reserve inevitably encompasses regions projected anteriorly and posteriorly that are supplied by other arterial segments.

### Conclusions

A pharmacologically inducible vasodilatory reserve may persist in the reperfused ischemic myocardium of patients with AMI undergoing early successful PTCA. An increase in flow reserve documented before hospital discharge is associated with a significant improvement in global and regional left ventricular functions. Importantly, the degree of reactive hyperemic response on

reperfusion is of predictive value with respect to the ultimate degree of functional recovery of the reperfused myocardium. Whether coronary flow reserve increases further at a later stage remains to be determined. Quantitative assessment of reperfusion may be useful in assessing the reversibility of coronary vascular and myocardial damage.

### Acknowledgments

We thank the cardiac catheterization team of the Thoracentric and Ton Slagboom, MD, as well as Doreen M. Westers for her expert secretarial assistance in the preparation of the manuscript.

### References

- Serruys PW, Simoons ML, Suryapranata H, Vermeer F, Wijns W, van den Brand M, Bar F, Krauss XH, Remme WJ, Res J, Verheugt FWA, van Domburg R, Lubsen J, Hugenholtz PG. Preservation of global and regional left ventricular function after early thrombolysis in acute myocardial infarction. *J Am Coll Cardiol*. 1986;7:729-742.
- Suryapranata H, Serruys PW, de Feyter PJ, van den Brand M, Beatt K, van Domburg R, Kint PP, Hugenholtz PG. Coronary angioplasty immediately after thrombolysis in 115 consecutive patients with acute myocardial infarction. *Am Heart J*. 1988;115:519-529.
- Suryapranata H, Serruys PW, Vermeer F, de Feyter PJ, van den Brand M, Simoons ML, Bar FW, Res J, van der Laarse A, van Domburg R, Beatt K, Lubsen J, Hugenholtz PG. Value of immediate coronary angioplasty following intracoronary thrombolysis in acute myocardial infarction. *Cathet Cardiovasc Diagn*. 1987;13:223-232.
- Zijlstra F, de Boer MJ, Hoorntje JCA, Reiffers S, Reiber JHC, Suryapranata H. A comparison of immediate coronary angioplasty with intravenous streptokinase in acute myocardial infarction. *N Engl J Med*. 1993;328:680-684.
- Gould KL, Libscomb K, Hamilton GW. Physiologic basis for assessing critical coronary stenosis. *Am J Cardiol*. 1974;33:87-94.
- Marcus M, Wright C, Doty D, Easthan C, Laughlin D, Krumm P, Fastenow C, Brody M. Measurements of coronary velocity and reactive hyperemia in the coronary circulation of humans. *Circ Res*. 1981;49:877-891.
- Hoffman JIE. Maximal coronary flow and the concept of coronary vascular reserve. *Circulation*. 1984;70:153-159.
- Hodgson JM, Le Grand V, Bates ER, Mancini GBJ, Auerson FM, O'Neill WW, Simon SB, Beauman GJ, LeFree MT, Vogel RA. Validation in dogs of a rapid digital angiographic technique to measure relative coronary blood flow during routine cardiac catheterization. *Am J Cardiol*. 1985;55:188-193.
- Zijlstra F, van Ommeren J, Reiber JHC, Serruys PW. Does quantitative assessment of coronary artery dimensions predict the physiologic significance of a coronary stenosis? *Circulation*. 1987;75:1154-1161.
- Engler RL, Schmid-Schonbein GW, Pavelec RS. Leukocyte capillary plugging in myocardial ischemia and reperfusion in the dog. *Am J Pathol*. 1983;111:98-111.
- Engler RL, Dahlgren MD, Morris DD, Peterson MA, Schmid-Schonbein GW. Role of leukocytes in response to acute myocardial ischemia and reflow in dogs. *Am J Physiol*. 1986;251:H314-H322.
- Reiber JHC, Serruys PW, Kooijman CJ, Wijns W, Slager CJ, Gerbrands JJ, Schuurbijs JCH, den Boer A, Hugenholtz PG. Assessment of short-, medium-, and long-term variation in arterial dimensions from computer-assisted quantitation of coronary cineangiograms. *Circulation*. 1985;71:280-288.
- Serruys PW, Reiber JHC, Wijns W, van den Brand M, Kooijman CJ, ten Katen HJ, Hugenholtz PG. Assessment of percutaneous transluminal coronary angioplasty by quantitative coronary angiography: diameter versus densitometric area measurements. *Am J Cardiol*. 1984;54:482-488.
- Slager CJ, Hooghoudt TEH, Serruys PW, Schuurbijs JCH, Reiber JHC, Meester GT, Verdouw PD, Hugenholtz PG. Quantitative assessment of regional left ventricular motion using endocardial landmarks. *J Am Coll Cardiol*. 1986;7:317-326.
- Serruys PW, Wijns W, van den Brand M, Mey S, Slager CJ, Schuurbijs JCH, Hugenholtz PG, Brower RW. Left ventricular performance, regional blood flow, wall motion and lactate metabolism during transluminal angioplasty. *Circulation*. 1984;70:25-36.
- Vogel RA. The radiographic assessment of coronary blood flow parameters. *Circulation*. 1985;72:460-465.
- Zijlstra F, Reiber JHC, Serruys PW. Does intracoronary papaverine dilate epicardial coronary arteries? Implications for the assessment of coronary flow reserve. *Cathet Cardiovasc Diagn*. 1988;14:1-6.
- Wilson RF, White CW. Intracoronary papaverine: an ideal coronary vasodilator for studies of the coronary circulation in conscious humans. *Circulation*. 1986;73:444-451.
- Bates ER, Krell MJ, Dean EN, O'Neill WW, Vogel RA. Demonstration of the 'no-reflow' phenomenon by digital coronary arteriography. *Am J Cardiol*. 1986;57:177-178.
- Nicklas JM, Diltz EA, O'Neill WW, Bourdillon PDV, Walton JA Jr, Pitt B. Quantitative measurement of coronary flow during medical revascularization (thrombolysis or angioplasty) in patients with acute infarction. *J Am Coll Cardiol*. 1987;10:284-289.
- Ishihara M, Sato H, Tateishi H, Kawagoe T, Yoshimura M, Muraoka Y. Impaired coronary flow reserve immediately after coronary angioplasty in patients with acute myocardial infarction. *Br Heart J*. 1993;69:288-292.
- Kloner RA, Ganote CE, Jennings RB. The 'no-reflow' phenomenon after temporary coronary occlusion in the dog. *J Clin Invest*. 1974;54:1496-1508.
- Willerson JT, Watson JT, Hutton I, Templeton GH, Fixler DE. Reduced myocardial reflow and increased coronary vascular resistance following prolonged myocardial ischemia in the dog. *Circ Res*. 1975;36:771-781.
- Jennings RB, Reimer KA. Factors involved in salvaging ischemic myocardium: effect of reperfusion of arterial blood. *Circulation*. 1983;68(suppl I):I-25-I-36.
- Sommers HM, Jennings RB. Experimental acute myocardial infarction. *Lab Invest*. 1964;13:1491-1503.
- Engler RL. Free radical and granulocyte-mediated injury during myocardial ischemia and reperfusion. *Am J Cardiol*. 1989;63:19E-23E.
- Cobb FR, McHale PA, Rembert JC. Effects of acute cellular injury on coronary vascular reactivity in awake dogs. *Circulation*. 1978;57:962-968.
- Bloor CM, White C. Coronary artery reperfusion: effects of occlusion duration on reactive hyperemia responses. *Basic Res Cardiol*. 1975;70:148-158.
- Cobb FR, Bache RJ, Rivas F, Greenfield JC Jr. Local effects of acute cellular injury on regional myocardial blood flow. *J Clin Invest*. 1976;57:1359-1368.
- Lavallee M, Cox D, Patrick TA, Vatner SF. Salvage of myocardial function by coronary artery reperfusion 1, 2, and 3 hours after occlusion in conscious dogs. *Circ Res*. 1983;53:235-247.
- van de Werf F, Arnold AER, for the European Co-operative Study Group for rt-PA. Effect of intravenous tissue plasminogen activator on infarct size, left ventricular function and survival in patients with acute myocardial infarction. *Br Med J*. 1988;297:1374-1379.
- Heyndrickx GR, Amano J, Patrick TA, Manders WT, Rogers GG, Rosendorff C, Vatner SF. Effects of coronary artery reperfusion on regional myocardial blood flow and function in conscious baboons. *Circulation*. 1985;71:1029-1037.
- Ito H, Tomooka T, Sakai N, Yu H, Higashino Y, Fujii K, Masuyama T, Kitabatake A, Minamino T. Lack of myocardial perfusion immediately after successful thrombolysis: a predictor of poor recovery of left ventricular function in anterior myocardial infarction. *Circulation*. 1992;85:1699-1705.
- Sheehan FH, Mathey DG, Schofer J, Dodge HT, Bolson EL. Factors determining recovery of left ventricular function following thrombolysis in acute myocardial infarction. *Circulation*. 1985;71:1121-1128.
- O'Neill WW, Timmis GC, Bourdillon PD, Lai PY, Gangadharan V, Walton JA, Ramos RG, Laufer N, Gordon S, Shork A, Linert DP, Pitt B. A prospective randomized clinical trial of intracoronary streptokinase versus coronary angioplasty for acute myocardial infarction. *N Engl J Med*. 1986;314:812-818.
- TIMI Research Group. Immediate vs delayed catheterization and angioplasty following thrombolytic therapy for acute myocardial infarction. *JAMA*. 1988;260:2849-2858.
- Simoons ML, Arnold AER, Betriu A, De Bono DP, Col J, Dougherty FC, von Essen R, Lambert H, Lubsen J, Meier B, Michel PL, Raynaud P, Rutsch W, Sanz GA, Schmidt W, Serruys PW, Thery C, Uebis R, Vahanian A, van de Werf F, Willems GM, Wood D, Verstraete M. Thrombolysis with tissue plasminogen



activator in acute myocardial infarction: no additional benefit from immediate percutaneous coronary angioplasty. *Lancet*. 1988;1:197-203.

38. Lefkowitz CA, Pace DP, Gallagher KP, Buda AJ. The effects of a critical stenosis on myocardial blood flow, ventricular function, and infarct size after coronary reperfusion. *Circulation*. 1988;77:915-926.

39. Yamazaki S, Fujibayashi Y, Rajagopalan RE, Meerbaum S, Corday E. Effects of staged versus sudden reperfusion after acute coronary occlusion in the dog. *J Am Coll Cardiol*. 1986;7:564-572.

40. Schmidt SB, Varghese PJ, Bloom S, Yackee JM, Ross AM. The influence of residual stenosis on size of infarction after reperfusion in a canine preparation. *Circulation*. 1986;73:1354.

41. Granato JE, Watson DD, Flanagan TL, Gascho JA, Beller GA. Myocardial thallium-201 kinetics during coronary occlusion and reperfusion: influence of method of reflow and timing of thallium-201 administration. *Circulation*. 1986;73:150.

42. Arnold AER, Serruys PW, Rutsch W, Simoons ML, de Bono DP, Tijssen JGP, Lubsen J, Verstraete M. Reasons for the lack of benefit of immediate angioplasty during recombinant tissue plasminogen activator therapy for acute myocardial infarction: a regional wall motion analysis. *J Am Coll Cardiol*. 1991;17:11-21.

43. Hodgson JM, Mancini GBJ, Le Grand V, Vogel RA. Characterization of changes in coronary blood flow during the first 6 seconds after intracoronary contrast injection. *Invest Radiol*. 1985;20:246-252.

44. Zijlstra F, den Boer A, Reiber JHC, van Es GA, Lubsen J, Serruys PW. Assessment of the immediate and long-term functional result of percutaneous transluminal coronary angioplasty. *Circulation*. 1988;78:15-24.