

# Circulation

JOURNAL OF THE AMERICAN HEART ASSOCIATION



## Frontiers in Interventional Cardiology

Eric J. Topol and Patrick W. Serruys

*Circulation* 1998;98;1802-1820

Circulation is published by the American Heart Association, 7272 Greenville Avenue, Dallas, TX 75214  
Copyright © 1998 American Heart Association. All rights reserved. Print ISSN: 0009-7322. Online  
ISSN: 1524-4539

The online version of this article, along with updated information and services, is  
located on the World Wide Web at:

<http://circ.ahajournals.org/cgi/content/full/98/17/1802>

Subscriptions: Information about subscribing to *Circulation* is online at  
<http://circ.ahajournals.org/subscriptions/>

Permissions: Permissions & Rights Desk, Lippincott Williams & Wilkins, a division of Wolters  
Kluwer Health, 351 West Camden Street, Baltimore, MD 21202-2436. Phone: 410-528-4050. Fax:  
410-528-8550. E-mail:  
[journalpermissions@lww.com](mailto:journalpermissions@lww.com)

Reprints: Information about reprints can be found online at  
<http://www.lww.com/reprints>

## Frontiers in Interventional Cardiology

Eric J. Topol, MD; Patrick W. Serruys, MD, PhD

In more than 20 years since the first percutaneous coronary revascularization procedures, the field of interventional cardiology has proliferated beyond all expectations. Now more than 1 million procedures are performed worldwide each year. Stenting has revolutionized the field, which previously relied on balloon dilatation in the majority of patients. With  $\approx 50\%$  of patients now undergoing stent implantation, the groundwork is laid for further important advances. In this article, we discuss the 4 most important new advances in the field of interventional cardiology: platelet inhibition, prevention of restenosis, stent evolution, and angiogenesis.

### Platelets

#### Proximate Cause of Stent Thrombosis

Considerable progress in the field of percutaneous coronary revascularization has been made by appreciation of the pivotal role of platelets and the development of new therapies directed against platelet aggregation. The entire field of stenting was catapulted forward with the realization that subacute thrombosis was predominantly attributable to a platelet thrombus. Since the beginning of coronary stenting in 1986, thromboprophylaxis consisted of full doses of heparin and coumarin, along with aspirin and dipyridamole.<sup>1,2</sup> This regimen resulted in the necessity for prolonged hospital stays to achieve therapeutic anticoagulation and in excessive bleeding complications and was still ineffective in preventing stent thrombosis in at least 4% to 5% of patients.<sup>2-6</sup> The prevailing belief was that stent thrombosis, which occurred primarily several days after the index procedure, was due to a fibrin-rich (red) thrombus.<sup>7-9</sup> Many of the cases of stent thrombosis were linked to suboptimal anticoagulation.<sup>8,9</sup> The complication of stent thrombosis is dreaded, because it may result in myocardial infarction (MI) or death.<sup>10</sup> The possibility that stent thrombosis was precipitated by inadequate expansion of the stent was explored<sup>11,12</sup> independently of the search for a better pharmacological protective strategy.

Evidence for causal white thrombus came from platelet flow cytometry data, indicating the increased expression of the platelet glycoprotein IIb/IIIa receptor in patients who developed this complication of stenting.<sup>13</sup> Rather than abnormalities in markers of coagulation activation, such as the cleaved fragment of prothrombin (F1.2) or thrombin-antithrombin complexes, a series of consecutive patients demonstrated that the dominant biochemical abnormality was related to platelet activation.

Angioscopic data from patients with subacute stent thrombosis showed white (platelet-rich) thrombus as the culprit,<sup>14</sup> and reports of failure of plasminogen activators to achieve lysis of stent thrombosis<sup>15</sup> corroborated the sense that the pathogenesis of this entity was largely attributable to platelet aggregation. Clinical trials were mounted to test the value of a platelet-directed strategy of aspirin and ticlopidine compared with the full anticoagulation approach of prolonged heparin and coumarin.<sup>16,17</sup> Furthermore, trials compared aspirin as a sole antiplatelet agent with the combination of aspirin and the ADP receptor antagonist ticlopidine.<sup>17-20</sup> These trials are summarized in Table 1. The benefit of an antiplatelet approach over the traditional strategy was striking, as first shown in the Munich Intracoronary Stenting and Antithrombotic Regimen (ISAR) trial and later confirmed in the Stent Anticoagulation Regimen Study (STARS) trial.<sup>16,17</sup> These findings, coupled with the benefit of an intensified dual antiplatelet inhibitor approach as opposed to aspirin alone,<sup>17-20</sup> provide a very strong foundation for platelet thrombus to be regarded as the principal pathogenic factor in stent thrombosis. The incidence of subacute stent thrombosis is now regarded as <1% to 2%. Accounting for this are the 2 cardinal changes in approach: more optimal deployment by use of higher balloon dilatation pressures, and combination antiplatelet therapy with aspirin and ticlopidine. The marked reduction in the incidence of stent thrombosis and the simplification of the pharmacological regimen has greatly reduced the cost of stenting by making overnight hospital stays routine, along with the possibility of transforming stent deployment to an outpatient procedure in select patients.<sup>21</sup>

Recently, ticlopidine has been associated with thrombocytopenic thrombotic purpura.<sup>22,23</sup> A new ADP receptor antagonist, clopidogrel, has thus far not been shown to induce this serious microangiopathic disorder or been implicated in bone marrow toxicity. Clopidogrel is currently being assessed in coronary stent trials for comparative efficacy and safety compared with ticlopidine.

#### Development of IIb/IIIa Inhibitors

Parallel to the improvement in pharmacological coverage to protect against stent thrombosis, a new class of drugs was being explored for balloon PTCA. For several years, it had been known that a final common pathway for platelet aggregation existed. Elucidation of the biology of this glycoprotein IIb/IIIa receptor, the most densely expressed adhesion molecule on the platelet surface, laid the groundwork for

From the Department of Cardiology, Cleveland Clinic Foundation, Cleveland, Ohio, and the Department of Interventional Cardiology, Thorax Center, Erasmus University, Rotterdam, Netherlands.

Correspondence to Eric J. Topol, MD, Cleveland Clinic Foundation, 9500 Euclid Ave, Cleveland, OH 44195.  
(*Circulation*. 1998;98:1802-1820.)

© 1998 American Heart Association, Inc.

**TABLE 1. Stent Randomized Thromboprophylaxis Trials**

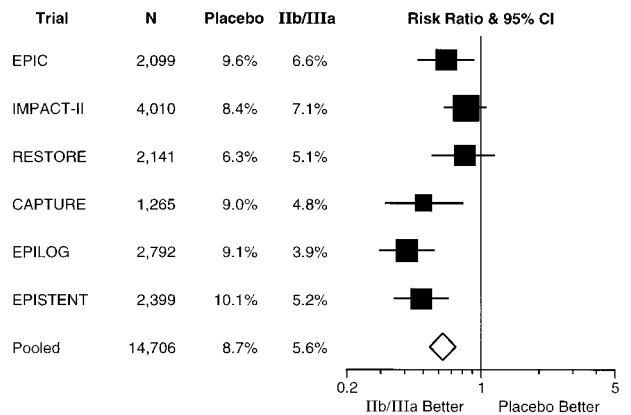
Trial	n	Composite Event Rates (Death, MI, Revascularization), %		
		ASA+Ticlid	ASA only	ASA+Coumarin
Hall et al <sup>18</sup>	226	0.8	3.9	...
ISAR <sup>16</sup>	517	1.6	...	6.2
FANTASTIC <sup>19</sup>	485	5.7	...	8.6
STARS <sup>17</sup>	1652	0.6	3.6	2.4
MATTIS <sup>20</sup>	350	5.6	...	11.0

ASA indicates aspirin; ISAR, Intracoronary Stenting and Antithrombotic Regimen trial; FANTASTIC, Full ANTicoagulation versus Ticlopidine and Aspirin after STent Implantation: a randomized multiCenter European study; STARS, Stent Anticoagulation Regimen Study; and MATTIS, Multicenter Aspirin and Ticlopidine Trial after Intracoronary Stenting in high-risk patients.

Coller<sup>24</sup> to develop a monoclonal antibody.<sup>25</sup> The antibody was the first agent to enter clinical trials, later followed by a peptide and several small-molecule competitive inhibitors of this adhesion molecule receptor.

Six large placebo-controlled, double-blind trials were undertaken to test IIB/IIIa antagonists in patients undergoing PTCA, as summarized in Table 2.<sup>26-31</sup> The Evaluation of IIB/IIIa platelet receptor antagonist 7E3 in Preventing Ischemic Complications (EPIC) trial<sup>26</sup> was the first "proof of concept" and demonstrated a marked, 36% reduction in the incidence of death or MI within 30 days of the procedure (Figure 1). This trial was conducted in high-risk patients, eligible because of an acute coronary syndrome or known angiographic liabilities for acute complications.<sup>25</sup> Either PTCA or directional atherectomy was the revascularization procedure. Of note, only the bolus and sustained infusion (>12 hours) but not the bolus per se strategy was effective in reducing adverse outcomes. This strongly suggested that the duration of IIB/IIIa blockade would play out as an important modulator of therapeutic potential.

The subsequent 5 trials confirmed and extended the EPIC findings in many ways.<sup>27-31</sup> First, each trial showed benefit of IIB/IIIa inhibition (Figure 1), with reduction of major adverse events. Second, the field of patients was expanded to include any routine percutaneous intervention rather than only a high-risk inclusion criterion. Third, the bleeding complications encountered in EPIC were related to excessive heparin



**Figure 1.** Death or nonfatal MI at 30 days for 5 trials of IIB/IIIa inhibitors in interventional cardiology procedures. EPIC indicates Evaluation of IIB/IIIa platelet receptor antagonist 7E3 in Preventing Ischemic Complications; IMPACT, Integrilin to Manage Platelet Aggregation to prevent Coronary Thrombosis; RESTORE, Randomized Efficacy Study of Tirofiban for Outcomes and Restenosis; CAPTURE, Chimeric 7E3 Anti-Platelet in Unstable angina Refractory to standard treatment; EPILOG, Evaluation of PTCA to Improve Long-term Outcome by c7E3 GPIIb/IIIa receptor blockade; and EPISTENT, Evaluation of Platelet IIB/IIIa Inhibitor for Stenting.

and prolonged indwelling vascular sheath time. In the trials that followed, using lower doses of weight-adjusted heparin and reducing the time of vascular sheaths, the initial doubling of bleeding in the patients receiving IIB/IIIa was reduced to levels similar to those in the control group.<sup>30</sup>

**Stents and IIB/IIIa Inhibitors**

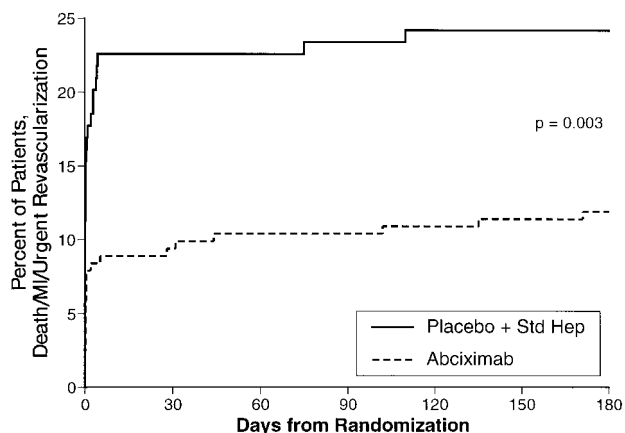
By virtue of the benefit of 2 different and distinct mechanisms, the concept of using both arterial scaffolding and protection from platelet thrombosis represents an attractive clinical strategy. Supportive data for this combination in patients receiving stents were demonstrated in subgroups of randomized trials.<sup>32,33</sup> As shown in Figure 2, in the Evaluation of PTCA to Improve Long-term Outcome by c7E3 GPIIb/IIIa Receptor Blockade (EPILOG) trial, >300 patients underwent stenting because of suboptimal balloon angioplasty results, and the benefit for IIB/IIIa inhibition with respect to reduction of MI and emergency revascularization was striking.<sup>32</sup> Of note, the favorable effects for combined IIB/IIIa inhibition

**TABLE 2. Principal Features of the 6 Large Trials of IIB/IIIa Inhibitors in Interventional Cardiology**

Trial	n	Drug	Patients	Heparin	Sheath Time, h
EPIC	2099	Abciximab	High-risk	Full	>24
IMPACT	4010	Eptifibatide	No restriction*	100 U/kg, weight adjusted	≈6
RESTORE	2139	Tirofiban	Unstable angina, acute MI	Full	≈6
CAPTURE	1265	Abciximab	Unstable angina	Full	>24
EPILOG	2792	Abciximab	No restriction*	70 or 100 U/kg, weight adjusted	<6
EPISTENT	2399	Abciximab	No restriction*	70 or 100 U/kg, weight adjusted	<6

EPIC indicates Evaluation of IIB/IIIa platelet receptor antagonist 7E3 in Preventing Ischemic Complications; IMPACT, Integrilin to Manage Platelet Aggregation to prevent Coronary Thrombosis; RESTORE, Randomized Efficacy Study of Tirofiban for Outcomes and Restenosis; CAPTURE, Chimeric 7E3 Anti-platelet in Unstable angina Refractory to standard treatment; EPILOG, Evaluation of PTCA to Improve Long-term Outcome by c7E3 GPIIb/IIIa receptor blockade; and EPISTENT, Evaluation of Platelet IIB/IIIa Inhibitor for Stenting.

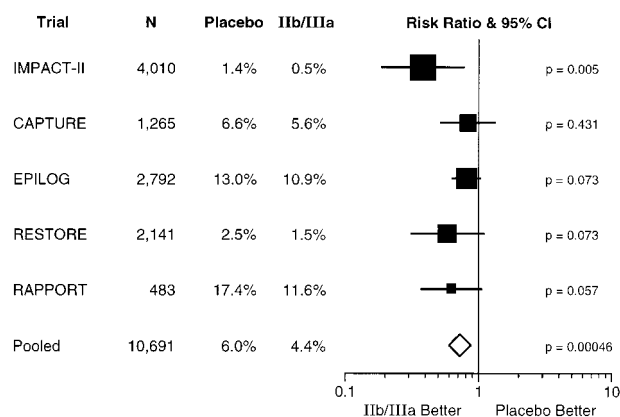
\*No restriction refers to enrollment of all patients suitable for percutaneous intervention using a Food and Drug Administration-approved device. Rotablation as a planned revascularization was not an entry criterion in EPILOG.



**Figure 2.** Reduction of death, MI, or need for urgent revascularization in prophylactic abciximab arm of a subgroup of 322 patients in EPILOG who underwent stenting for suboptimal results.

(administered on a prophylactic basis) and stenting had thus far been shown only in patients with poor or suboptimal initial results. A dedicated trial (known as Evaluation of Platelet IIb/IIIa Inhibitor for Stenting [EPISTENT]) studied the use of IIb/IIIa blockade with elective stenting.<sup>31</sup> In this trial, balloon angioplasty and abciximab was compared with either stenting and placebo or stenting and abciximab in a total of 2399 patients. For the combination of stenting and abciximab, compared with stenting and placebo, a striking (>50%) reduction of death and MI at 30 days and 6 months was demonstrated.<sup>31</sup> The balloon-abciximab arm also was significantly improved compared with stenting and placebo.<sup>31</sup> These findings accentuate the need for improved antiplatelet therapy with percutaneous intervention, whether it be with stenting or balloon angioplasty.

The IIb/IIIa trials in interventional cardiology, interestingly, have consistently reduced the need for emergency or “bailout” stenting<sup>33,34</sup> (Figure 3). Each trial that was performed in an era in which stents were available showed a lesser need, with an overall 24% reduction. All of these trials were performed in a double-blind fashion. This, along with



**Figure 3.** Need for stenting for bailout or suboptimal results in double-blind, placebo-controlled trials of IIb/IIIa inhibitors for interventional cardiology. RAPPORT indicates Reo Pro and Primary PTCA Organization and Randomized Trial; other abbreviations as in Figure 1.

the consistent findings across trials and the magnitude of the reduction, bespeaks a prominent effect of improved antiplatelet coverage for achieving better results in percutaneous intervention without stenting. Whether indeed stenting should be avoided when possible or actually applied more frequently is an unsettled issue.<sup>35</sup> Notwithstanding the provisional stent debate, the interaction of stenting and antiplatelet therapy is clearly a critical one for future optimization of patient outcomes.

### Restenosis

Initially, it was thought that IIb/IIIa blockade might have a salutary effect on clinical restenosis.<sup>36</sup> This was based on the long-term effects of the original EPIC trial, in which there was a 24% reduction of target-vessel revascularization at 6 months in the abciximab bolus and infusion treatment group.<sup>36</sup> Furthermore, this benefit was sustained even at 3 years of follow-up.<sup>37</sup> Theoretically, this occurred on the basis of potent platelet inhibition before and for the first few days after the arterial dilatation. By attenuation of the platelet-aggregation response, less growth factor (such as platelet-derived growth factor) and vasoactive amine (eg, serotonin, thromboxane A<sub>2</sub>) would be released. In addition, abciximab is known to inhibit the vitronectin receptor, an integrin with homology to IIb/IIIa because of the shared  $\beta$ -3 subunit and >70% of the  $\alpha$ -subunit. Because abciximab cross-reacts fully with the vitronectin receptor<sup>38,39</sup> and this is a critical pathway for governing smooth muscle cell migration, theoretically a dual approach of platelet and smooth muscle cell antagonism was operational. However, when the same IIb/IIIa inhibitor was used in the subsequent EPILOG trial, there was no 6-month effect on target-vessel revascularization.<sup>30</sup> This was also the case in both the ERASER and RAPPORT trials,<sup>40,41</sup> as summarized in Table 3.

As shown in Figure 4, however, there was a pronounced change in the need for target-vessel revascularization from the initial to the more contemporary abciximab trial. This reduction in the placebo group of the respective trials is quite impressive and probably reflects the era of more aggressive dilatation that has characterized percutaneous intervention since backup stenting was widely available in 1995. More recently, however, data from the EPISTENT 6 month follow-up results have become available. An overall 18% reduction in the need for repeat target vessel revascularization was demonstrated for abciximab compared with placebo in stent assigned patients (from 10.6% to 8.7%) with >50% reduction in diabetic patients (16.6% vs 8.1%,  $P=0.02$ ). Thus, in-stent restenosis, especially in diabetics, is favorably influenced by abciximab.<sup>31</sup>

### Periprocedural MI

Since the first randomized trial of directional atherectomy versus balloon angioplasty,<sup>42</sup> debate has arisen as to the significance of periprocedural non-Q-wave MI, which clearly occurs more frequently than expected. In aggregate, a number of studies with ample follow-up have shown that patients with a periprocedural MI characterized by a 3-fold elevation of total creatine kinase (CK), positive for myocardial band (MB), have a compromised long-term prognosis.<sup>43</sup> The pa-

**TABLE 3. Major 6-Month End Points of the 5 Trials of IIb/IIIa Blockade in Interventional Cardiology**

Trial	n	% Death/MI		% Death/MI/Any Revasc		% TVR	
		Placebo	Drug	Placebo	Drug	Placebo	Drug
EPIC	2099	12.8	8.8	35.1	27.0	22.3	16.5*
IMPACT	4010	11.6	10.3	31.5	30.1	20.7	20.9
RESTORE	2139	8.6	7.8	27.1	24.1	17.1	15.7
CAPTURE	1265	10.9	9.0	31.6	31.4	25.9	25.8
EPILOG	2792	11.1	6.0	25.8	22.5	18.1	16.6
Pooled	12 305	10.9	8.5	29.8	26.9	20.2	18.6

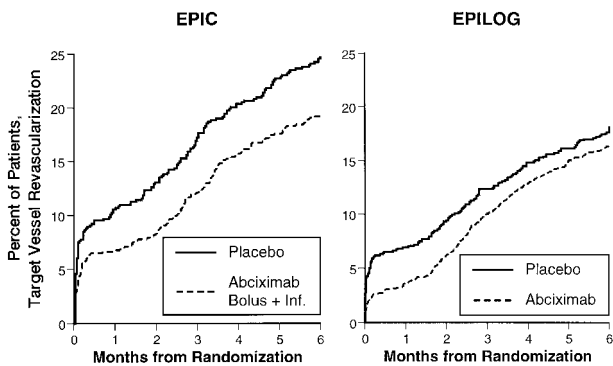
TVR indicates target vessel revascularization; EPIC, Evaluation of IIb/IIIa platelet receptor antagonist 7E3 in Preventing Ischemic Complications; IMPACT, Integrelin to Manage Platelet Aggregation to prevent Coronary Thrombosis; RESTORE, Randomized Efficacy Study of Tirofiban for Outcomes and Restenosis; CAPTURE, Chimeric 7E3 Anti-platelet in Unstable angina Refractory to standard treatment; and EPILOG, Evaluation of PTCA to Improve Long-term Outcome by c7E3 GPIIb/IIIa receptor blockade.

tients most apt to have a periprocedural non-Q-wave MI are those with diffuse atherosclerotic involvement, with long lesions or saphenous vein graft target stenoses, along with procedures that induce a deeper level of arterial injury, particularly atherectomy.<sup>44,45</sup> Common to these higher-risk subsets is the responsiveness of IIb/IIIa inhibitors for the reduction of periprocedural MI. Although the predominant therapeutic effect of the IIb/IIIa inhibitors is in large MIs, Q-wave or non-Q-wave, there is clear-cut reduction of periprocedural MIs in the range of 3- to 5-fold CK elevation.<sup>26-31</sup> Accordingly, using this drug class as a mechanistic probe, we know that at least some of these events are attributable to platelet aggregation, whether it be the site of arterial dilatation or in the microcirculation. The weight of evidence suggests that the chief hazard of periprocedural MI is increased death rate during extended follow-up,<sup>43</sup> which appears to be directly related to the size of the MI. This may explain the favorable impact of IIb/IIIa blockade on mortality during 3-year follow-up of a cohort of patients with acute coronary syndromes in the initial EPIC trial.<sup>37</sup> Nevertheless, periprocedural MIs still occur despite full doses of IIb/IIIa inhibitors, so that other factors, such as side-branch closure, atherosclerotic emboli, and overriding intimal disruption, play a role in some patients.

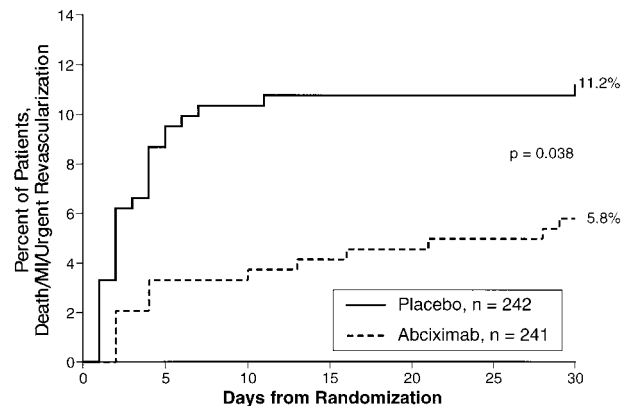
**Use in Acute MI**

One of the most exciting frontiers in cardiovascular medicine is the ability to disaggregate platelets in the setting of acute MI.<sup>46</sup> The underlying pathophysiology has been further elucidated, with the white clot central to the response to plaque fissure or erosion and the attendant exposure of subendothelial matrix. Until recently, there was no tool in our therapeutic armamentarium to dissolve the platelet clot—that is, to achieve “platelet lysis.” Indeed, the prothrombotic effects of plasminogen activators led to failure of angioplasty in the early randomized trials.<sup>46-49</sup> This has been completely turned around by exploiting our newfound ability to dissolve white clot in the acute setting, with or without fibrinolytic therapy. Use of IIb/IIIa inhibition alone has resulted in infarct vessel patency rates approximating the use of streptokinase therapy.<sup>50</sup>

In the recently completed RAPPORT trial,<sup>41</sup> of 483 patients undergoing PTCA for acute MI, the IIb/IIIa inhibitor group had a >40% reduction in death, MI, or urgent revascularization at 30 days (Figure 5). Neumann and colleagues,<sup>51</sup> from Munich, Germany, reported a trial of 200 patients undergoing primary stenting for acute MI with a similar reduction of adverse outcomes with abciximab compared with conventional pharmacological therapy. Recent data from dose-finding trials in the TIMI-14 and GUSTO-4 trials indicate



**Figure 4.** Proportion of patients requiring repeat target-vessel revascularization in control groups of EPIC trial (conducted in 1992; control group, n=639) vs EPILOG trial (conducted primarily in 1995; control group, n=939) shows marked reduction in more contemporary trial (TVR required in 22.3% in EPIC, 16.6% in EPILOG).



**Figure 5.** RAPPORT trial event rates of death, MI, and urgent revascularization for abciximab vs placebo.



**TABLE 4. Use of Percutaneous Coronary Revascularization While on IIb/IIIa Blockade Therapy in 3 Trials of Empirical Therapy in Acute Coronary Syndromes**

	Proportion (%) of Patients Undergoing		30-Day Death/MI Event Rates, %		Absolute Reduction in PTCA Patients, %
	Angiography	PTCA	Placebo	IIb/IIIa	
PARAGON A	10.8	3.2	15.2	2.6	12.6
PRISM Plus	89.7	30.5	14.4	8.4	6.0
PURSUIT	79.0	34.0	16.8	11.5	5.3

PARAGON A indicates Platelet IIb/IIIa Antagonist for the Reduction of Acute coronary syndrome events in a Global Organization Network; PRISM Plus, Platelet Receptor inhibition for Ischemic Syndrome Management study; and PURSUIT, Platelet IIb/IIIa Underpinning the Receptor for Suppression of Unstable Ischemia Trial.

that half-dosing of tissue plasminogen activator (alteplase) or recombinant tissue plasminogen activator (reteplase), respectively, given in combination with full-dose abciximab, can achieve infarct vessel patency in >90% of patients by 60 to 90 minutes into therapy.<sup>52,53</sup> In the related trials of acute coronary syndromes, the patients receiving IIb/IIIa blockers on presentation who had subsequent percutaneous coronary intervention during drug infusion derived the most benefit of all of the subgroups analyzed (Table 4).<sup>54–56</sup>

It is thus likely that a pivotal component of future management of MI patients will involve more potent antiplatelet therapy. The long-standing debate as to whether to perform catheter-based reperfusion or use pharmacological therapy could be preempted by a pharmacological strategy that markedly facilitates (rather than compromises) acute-phase intervention. Because one of the most important features of acute intervention is the “door-to-balloon” time,<sup>57,58</sup> the use of a platelet-lysis approach to restore coronary blood flow while the patient is being transported to cardiac catheterization has important infarct-size limitation and practical appeal. Furthermore, the enhanced stability of the infarct vessel that has been passivated by the use IIb/IIIa blockade opens the potential for consideration of very early hospital discharge. Thus, IIb/IIIa blockade has set the stage for a veritable revolution in our care of the patient with acute MI eligible for reperfusion therapy.

### Antirestenosis Strategies

The focus of the treatment of restenosis over the last 2 decades has been through the application of pharmacologically active agents and mechanical approaches using a host of different devices. Unfortunately, this frequent and costly complication of percutaneous revascularization techniques has proved refractory to all such therapies. The restenosis process is characterized by neointimal proliferation, which involves the migration of vascular smooth muscle cells from the media to the intima and their subsequent proliferation. The inciting stimuli involved in restenosis include disruption of the endothelial barrier layer, mechanical factors that disrupt the medial smooth muscle layer and serve as stimuli for smooth muscle cell proliferation and migration, and the contact of this disrupted layer with circulating blood factors and mitogens that serve as further stimuli to neointimal formation. Vascular injury sets into motion a cascade of events that results in the final hyperplastic response shown by the neointima. Early in our understanding of the pathophys-

iological processes involved in restenosis, attention was concentrated on factors that interact with smooth muscle cells through cell surface receptors. These include such compounds as thrombin, platelet-derived growth factor, angiotensin II, interleukin 1, insulin growth factor-1, basic fibroblast growth factor, and a whole host of other mitogenic factors. Initial treatments for restenosis targeted these receptors with pharmacological agents in an attempt to inhibit their effects. It soon became apparent, however, that none of these stimuli work through a unique or final common pathway. Instead, these signals interact at an intracellular level through redundant second-messenger systems, which confers redundancy to the system. Ultimately, these second-messenger systems converge on a final common pathway at the cellular DNA level known as the cell cycle.

The life cycle of a normal cell can be considered in 5 different cell phases. G<sub>0</sub> (G=gap) is the quiescent state in which the cell is biologically active but is neither actively dividing or replicating. Under appropriate stimuli, the cell can then enter the G<sub>1</sub>, or interphase, in which biosynthetic activities of the cell prepare it to enter into the next phase of the cell cycle, or S phase. The S phase begins when DNA synthesis starts and ends when the DNA content of the nucleus has doubled and the chromosomes have replicated. The S phase is followed by G<sub>2</sub>, which ends when mitosis starts, signaling the start of the M phase. Activation of the cell cycle is responsible for both normal physiological growth and cell division, as well as for pathophysiological processes such as restenosis.

A large number of genes are involved in the control of cell cycle progression in eukaryotic cells. They can be divided into early G<sub>1</sub> genes (such as *c-fos* *c-myc*, etc), late G<sub>1</sub> genes (*c-myb*, *Rb*, etc), genes involved in G<sub>1</sub>/S transition (*cdc/ckd* kinases, etc), S-phase genes involved in DNA synthesis (DNA polymerases, proliferating cell nuclear antigen, etc), genes involved in G<sub>2</sub>/M transition (*cdc/ckd* kinases, etc), and genes involved in mitosis (cytoskeletal proteins, mitosis-specific kinases, etc). In theory, suppression of any 1 of these genes will lead to interruption of cell cycle progression, a strategy that is being explored for the prevention of restenosis as we approach the new millennium. Two different tactics are currently being tested. Brachytherapy bombards the nuclear material with ionizing radiation, disrupting the templates for the production of cell cycle regulatory proteins. With the correct radiation dose, the target smooth muscle cell remains

viable but unable to replicate. The other approach depends on a biological attack on the cell regulatory machinery using gene therapy technology for the introduction of foreign-fragment nuclear material to halt the pathophysiological processes typical of restenosis.

A number of different approaches using the basic techniques of gene therapy are currently being tested for the prevention of neointimal hyperplasia. The most straightforward involve the transfer of a gene directly into the proliferating smooth muscle cells. This gene can encode for a cytotoxic protein (eg, herpes virus thymidine kinase), a cell cycle-inhibitory protein (eg, p53, p21, Rb, cdk), angiogenic proteins (eg, vascular endothelial growth factor [VEGF], angiogenin, basic fibroblast growth factor), or proteins with vasodilatory, antithrombotic, or antiproliferative properties (eg, nitric oxide synthase, cox-1, plasminogen activator inhibitor type 1). This kind of approach has been shown to be effective in several animal models of restenosis. With adenovirus used as a vector, herpes virus thymidine kinase has been successfully transfected into vascular smooth muscle cells at the site of balloon injury in the femoral arteries of swine.<sup>59</sup> This was followed by systemic administration of the nucleoside analogue ganciclovir, which in the presence of the foreign thymidine kinase can be incorporated into the cellular DNA. With this technique, both smooth muscle cell proliferation and luminal narrowing were shown to be inhibited.<sup>59</sup> Adenovirus-mediated transfer of the retinoblastoma (*Rb*) gene, whose protein product inhibits cell cycle progression, has also been shown to be successful in a similar animal model.<sup>60</sup> Transfer of the gene coding for nitric oxide synthase using both a protein/liposome hybrid vector<sup>61</sup> and an adenovirus vector,<sup>62</sup> as well as of angiotensin II type 2 receptor<sup>63</sup> and the thrombin inhibitor hirudin<sup>64</sup> using adenovirus vectors, has also been shown to be effective for the prevention of restenosis in the rat carotid model of vessel injury.

Other targets being investigated for the prevention of restenosis are the matrix metalloproteinases (MMPs). Smooth muscle cell migration and proliferation are normally hindered by the inhibitory constraints of the extracellular matrix.<sup>65,66</sup> Matrix remodeling by matrix-degrading metalloproteinases is therefore essential for smooth muscle proliferation and migration into the intima. Synthetic inhibitors of MMPs have been shown to inhibit smooth muscle migration and proliferation in several *in vitro* systems.<sup>66-70</sup> There are several naturally occurring tissue inhibitors of metalloproteinases (TIMPs) that can inhibit their activity. To date, 3 TIMPs have been well characterized (TIMP-1, -2, and -3),<sup>71</sup> and a fourth has been cloned.<sup>72</sup> The identification of these inhibitors has led to the idea that overexpression of TIMPs may have potential as a gene therapy approach for the prevention of neointimal formation. Support for TIMP gene therapy comes from recent work by George and colleagues<sup>73</sup> at the Bristol Heart Institute. In human saphenous vein in tissue culture, these investigators were able to demonstrate that highly localized overexpression of TIMP-1 after recombinant adenovirus-mediated transfection markedly inhibited neointimal formation. These results not only provide proof of principle for *ex vivo* gene therapy with TIMP-1 for the reduction of neointimal formation in vein grafts but also

suggest an *in vivo* application at the time of intervention for the prevention of coronary artery restenosis.

Another "nuclear weapon" being developed for the prevention of restenosis involves antisense oligonucleotide technology. Antisense oligodeoxynucleotides are short pieces of DNA with sequences that are complementary to specific regions of messenger RNA. The major mechanisms of action of these compounds are through the sequence-specific interaction with messenger RNA, although sequence-specific and sequence-nonspecific effects have also been demonstrated. On binding to the target, the antisense compound sterically inhibits the interaction of ribosomes with the messenger RNA. Another mechanism of action, which may be as important as the steric inhibition of ribosome binding, is a consequence of the DNA/RNA hybrid being more susceptible to degradation by intracellular RNase than single-stranded messenger RNA. This results in an increased clearance of target mRNA from the cell. In principle, any gene may be selected for antisense suppression; inhibition of certain genes will certainly be more biologically effective. Important in this regard are the abundance of the messenger RNA, the half-life of the protein product, and the existence of redundancy within the cell such that other proteins are capable of performing functions similar to that which is targeted. Given these considerations, it is not surprising that most of the attention of antisense technology has been focused on the short-lived regulators of the final common pathway of mitogenic stimuli, the cell cycle. Inhibition of the production of several of the mediators of the cell cycle with antisense oligonucleotides has been shown to be effective for the prevention of restenosis in several different animal models of vascular injury (Table 5).<sup>74-84</sup> The results of a single-center clinical trial performed in Rotterdam that examined the effectiveness of antisense compound directed against messenger RNA for the protein product of the *c-myc* gene will soon be reported. This will be the first human trial to use an antisense DNA strategy for the prevention of restenosis.

With our increased understanding of vascular molecular biology, more sophisticated approaches that use the basics of gene therapy are being investigated. For instance, cell-based vascular gene-delivery techniques are now being explored as means to provide biologically relevant amounts of therapeutic agents to the site of vessel damage. This strategy involves the isolation of autologous endothelial or smooth muscle cells, *ex vivo* gene transfer, followed by the reintroduction of the genetically modified cells back to the region selected for therapy. The disadvantages of this approach include the requirement to isolate and modify cells from each patient, with the consequent delay in therapy, and the failure to date, with few exceptions, to show a relevant expression of recombinant protein *in vivo*. To circumvent these problems, the laboratory of one of the authors (P.W.S.) is focusing on the xenotransplantation of genetically modified endothelial cells for the prevention of restenosis. For this purpose, animals have been engineered that are doubly transgenic in that they carry not only a human gene that can produce an agent for the prevention of restenosis but also gene coding for human cell surface markers so that they may be effectively xenotransplanted into humans and therefore provide a local

TABLE 5. In Vivo Antisense Studies

Investigators	Experimental Model	Gene	Delivery Vehicle	% Intimal Suppression
Simons et al <sup>74</sup>	Rat	<i>c-myb</i>	Pluronic gel	84
Edelman et al <sup>75</sup>	Rat	<i>c-myb</i>	EVav	80
Azrin et al <sup>76</sup>	Pig	<i>c-myb</i>	Hydrogel catheter	NR
Gunn et al <sup>77</sup>	Pig	<i>c-myb</i>	None	65
Bennet et al <sup>78</sup>	Rat	<i>c-myb</i>	Pluronic gel	53
Edelman et al <sup>75</sup>	Rat	<i>c-myb</i>	EVac	90
Shi et al <sup>79</sup>	Pig	<i>c-myb</i>	None	70
Morishita et al <sup>80</sup>	Rat	<i>cdc-2/PCNA</i>	HVJ	68
Abe et al <sup>81</sup>	Rat	<i>cdc-2</i>	Pluronic gel	47
Abe et al <sup>81</sup>	Rat	<i>cdk-2</i>	Pluronic gel	55
Morishita et al <sup>82</sup>	Rat	<i>cdk-2</i>	HVJ	40
Simons et al <sup>83</sup>	Rat	<i>PCNA</i>	Pluronic gel	80
Sirois et al <sup>84</sup>	Rat	PDGD- $\beta$ receptor	EVac	70

EVac indicates ethylenevinylacetate; HVJ, hemagglutinating virus of Japan; and NR, not reported.

source of bioactive compounds. These animals provide a limitless supply of endothelial cells producing controllable levels of active compound, which can be used for xenotransplantation at the site of vessel injury in humans. These foreign cells act as a kind of Trojan horse, graciously accepted as self by the host organism but capable of modifying the pathophysiological response to vessel damage typified by the process of restenosis. Once implanted, the production of the bioactive compound is under exogenous control by means of “designer” genes coding for modified cell-surface receptors that are introduced. In this system, interaction of an orally administered compound with the modified cell receptor can switch on the transgene, whereas in its absence the transgene remains dormant. The feasibility of this type of approach has been demonstrated in other animal species, and it shows great potential for application to humans. The applicability of this type of therapeutic delivery system to other pathophysiological conditions and the shortage of tissue for organ transplantation are the fuel for continued high research activity in this direction.

As our understanding of the molecular control of cellular function increases and our knowledge of the pathophysiology of restenosis expands, new types of gene therapy approaches will be developed for the treatment of this iatrogenic complication. An area of active investigation is the development of new techniques for the introduction of foreign DNA into whole cells. All of the currently available viral and nonviral vectors have significant limitations to their use. The introduction of an effective, nonimmunogenic delivery vehicle is on the horizon. As the last decade was the era of mechanical and pharmacological approaches to the prevention of restenosis, developments in the coming decade will be aimed at manipulating the genetic material of the proliferating cell.

### Stents

The use of coronary stent implantation as a primary treatment modality in interventional cardiology has increased at a staggering rate. In most interventional centers, stents are used

in  $\geq 50\%$  of all coronary angioplasty procedures. This “stentomania” is driven both by the gratifying short-term results seen by the interventionalist using these devices and by results extrapolated from observational and randomized trials. The “bigger is better” dogma first proposed by Kuntz and his colleagues<sup>85</sup> has been adopted by many operators, who feel that the greater the acute gain in lumen diameter, the smaller the chances of short- and long-term failure.<sup>86</sup> Inherent in this concept is that the stent is merely a means to an end, and therefore, irrespective of the particular stent or other dilating or debulking device used, success of the procedure is determined solely by the acute results. Whether differences between various stent designs and materials are sufficient to impact their clinical effects remains to be demonstrated in controlled “stent versus stent” trials. The positive results of the few completed randomized trials have been enthusiastically applied to almost every other patient and lesion subcategory. The unequivocal indications for stenting are currently only those few that have been supported by observational and randomized trials and are limited to very few stent types. The definitive evidence for the use of stents for several specific clinical indications is still lacking. As results of the many ongoing randomized stent trials become available, the indications for stenting will have to be adapted accordingly. Currently, there is solid evidence from observational studies and randomized trials to support the use of coronary stents for the following indications: (1) treatment of abrupt or threatened vessel closure during angioplasty, (2) primary reduction in restenosis in de novo focal lesions in vessels  $>3.0$  mm in diameter, (3) focal lesions in saphenous vein grafts, (4) totally occluded vessels, and (5) treatment of acute MI.

### Are They All Equivalent?

With the current and future plethora of intracoronary stenting devices, the obvious question that must be answered is whether the choice of a particular stent makes a difference with respect to clinical outcome. Two lines of evidence, 1 experimental and the other clinical, suggest that a difference



**TABLE 6. Angiographic Follow-Up of Stent Versus Stent Trials**

	ACSENT		SMART		GR II	
	Palmaz-Schatz	Multi-Link	Palmaz-Schatz	Micro Stent II	Palmaz-Schatz	GR II
Short-term results						
No. of patients	520	520	331	330	364	364
ACC B2/C (%)	60§	63§	63§	62§	48‡	45‡
LAD (%)	43	43	42	47	40	43
Reference diameter (mm)	2.97	2.95	2.93	2.93	3.08	3.07
Post stent stenosis (%)	10	8	8	5†	10	16†
Follow-up results						
MLD (mm)	1.91	1.97	2.00	1.86	1.92	1.51*
Diameter stenosis (%)	35	32	34	37	35	50*
Binary restenosis rate	21	17	23	25	19	45

ACC B2/C indicates lesion morphology according to ACC/AHA Task Force Report, *J Am Coll Cardiol.* 1993;22:2033–2054; LAD, left anterior descending coronary artery; MLD, minimal luminal diameter; and binary restenosis rate, diameter stenosis >50% at follow-up.

\* $P > 0.001$  vs Palmaz-Schatz.

† $P < 0.05$  vs Palmaz-Schatz.

‡Graded on site.

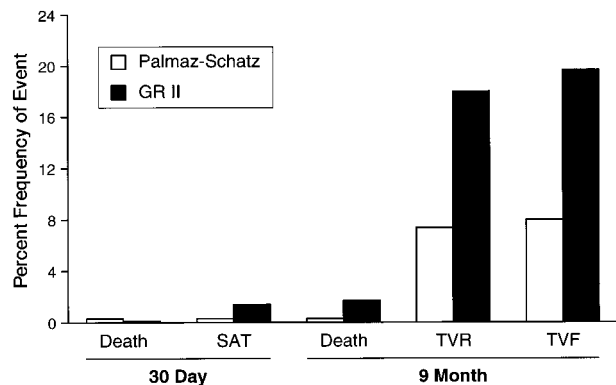
§Graded by angiographic core laboratory.

does indeed exist between different stents.<sup>87–90</sup> In an animal model, it has been suggested that stent surface material and geometric configuration may be more important than operator-dependent variables in determining the degree of neointimal hyperplasia and thrombosis.<sup>87</sup> Design characteristics such as hoop strength<sup>91</sup> and metallic surface area<sup>92</sup> have been shown to influence neointimal formation in experimental models. The metal composition and characteristics of the stent surface may also be important for the performance of the implanted stent.<sup>93–102</sup>

Another factor that must be considered when assessing stent design is the mode of delivery: self-expanding versus balloon-expandable. The currently available self-expanding stents are configured as a slotted tube (Radius) or as a wire mesh (Wallstent) and are composed of either nitinol (Radius) or stainless steel (Wallstent). Although different in configuration and metal composition, they have in common a continued expansion after deployment. The nitinol device will continue to expand to its nominal programmed diameter, whereas the Wallstent expands to the point at which tissue forces overcome the radial forces of the expanding stent.<sup>103,104</sup> It must be kept in mind, however, that excessive oversizing of the Wallstent (>0.7 mm larger than the reference diameter) has been shown to be a powerful predictor of subsequent restenosis.<sup>105</sup> Further studies are necessary to better define the particular advantages and disadvantages of the 2 different modes of delivery.

To resolve the issue of whether stent configuration plays a major role in determining long-term outcome, large randomized trials are currently under way comparing various stent designs “head to head.” The equivalency design of these trials in simple “BELgian NETHERlands STENT study [BENESTENT]-like” lesions is predicated on showing similarity in safety and efficacy between the test stent and the Palmaz-Schatz stent, which serves as the standard with which all others are compared. These trials were not designed to test for subtle and perhaps clinically

unimportant differences between stent designs, because an unreasonably large sample size would be required. Three trials have been completed. In all of these, stents were implanted in noncomplex lesions with a length of <25 mm in native coronary vessels. In addition to clinical end points, angiography was obtained in a subset of the patients, and all trials were powered to detect a 0.2-mm difference in minimal luminal diameter at 6 to 9 months after stent implantation by quantitative coronary arteriography. The ACS stENT Clinical Equivalence in de Novo Lesions (ACSENT) trial included 1040 patients randomized to either Palmaz-Schatz or Multi-Link stent implantation. Statistical equivalence in both the late clinical and angiographic (Table 6) outcomes were demonstrated for the Multi-Link and the Palmaz-Schatz stents. Likewise, clinical and angiographic (Table 6) equivalence between the Palmaz-Schatz stent and the Micro Stent II was shown in the Study of AVE-Micro Stent Ability to Limit Restenosis (SMART) trial, in which 613 patients with focal de novo or restenotic native coronary lesions were randomized. Equivalence between the GR II and the Palmaz-Schatz stent was not demonstrated in the GR II trial. Differences at 6-month follow-up were seen in the 6-month clinical outcomes of target-vessel revascularization and target-vessel failure (composite of death, MI, and target-vessel revascularization) (Figure 6). Significant differences were also seen in the 6-month follow-up angiographic parameters of minimal luminal diameter, percent diameter stenosis, and binary restenosis rate (Table 6). The reasons for these differences are not clear but may be due in part to a higher acute residual stenosis after stent implantation, a higher loss index in the GR II–treated vessels (0.76 versus 0.57;  $P = 0.007$ ), or as a result of GR II stent undersizing or longer stent length in the GR II group. With the large number of stents currently available, it is questionable what practical purpose will be served by comparing all the available stents with the “standard” (Palmaz-Schatz) or with each other. Also, is similar performance at 6-month follow-up angiography in a select patient population adequate to indicate equivalency?



**Figure 6.** Clinical outcome of GR II trial comparing GR II stent (n=364) to Palmaz-Schatz stent (n=364) showing frequency of death and subacute thrombosis (SAT) at 30 days and frequency of death, target-vessel revascularization (TVR), and target-vessel failure (TVF) (death, TVI, MI) at 9 months. Differences can be seen in frequency of both TVF and TVR between Palmaz-Schatz stent and GR II stent.

Other issues that must be considered when evaluating a stent, other than equivalency to an arbitrary standard, are ease of use, versatility, and cost.

### Custom-Designed Stents

With recent improvements in deployment techniques for intracoronary stents and increased operator experience, lesions previously considered not amenable to percutaneous treatment are now being treated with intracoronary stent implantation. Industry has responded to the demand with the

production of myriad customized stents for very particular applications.


### Bifurcation Lesions

Several new stent designs are available that are constructed specifically for use in bifurcation lesions. The Jostent B (Jomed International AB) is 1 such device. The configuration and size of the cells at 1 end of the Jostent B is similar to the first-generation Jostent M stent, with the cells connected with V-shaped bridges. At the other end of the stent, the cells are larger and connected with straight bridges (Figure 7A). On full expansion, the larger cells have a diameter of 3.5 mm, allowing easy access to the other arm of the vessel bifurcation.

CR Bard Inc is testing a true bifurcation stent. The Bard Bifurcation stent is shaped like a Y and is mounted on 2 balloons (Figure 7B). The main body of the stent is a single coil, through which the 2 balloons pass. The balloons diverge at the crux of the Y to pass separately through the 2 arms. Implantation into animals is currently under way, and the first human implants are being planned.

### Side Branch

Stents specifically designed for use in the treatment of lesions at the site of significant side branches are also available. SciMed Life Systems supplies the NIRSide, which has the same basic design as the standard family of NIR stents; however, the cells in the center of the stent are larger than those at the ends. When properly positioned, the number of obstructing struts over the entrance to the side branch is



**Figure 7.** A, Photograph of Jostent B showing larger cells at 1 extreme of stent. B, Photograph of Bard Bifurcation Stent, a true bifurcated device. C, Photograph of Devon Side-Arm Stent showing region with omitted struts. D, Photograph of Devon Ostial Stent showing reinforced struts at 1 extreme of stent. E, Photograph of end of a Jostent Coronary Stent Graft showing expandable PTFE material sandwiched between 2 thin-strut metal stents.

minimized and side-branch access is facilitated. The design concept of the Jostent S (Jomed International AB) is similar to that of the NIRSide stent (Figure 7C).

### Ostial Lesions

Devon Medical produces a stent designed exclusively for use in ostial lesions. The base design for the stent is the Pura-Vario A. At 1 end of the stent, however, the terminal row of cells is slightly longer and the struts slightly thicker (Figure 7D). This not only increases the radial force of this portion of the stent but also increases its radiopacity, which facilitates precise positioning.

### Aneurysms or Perforations

The Jostent Coronary Stent Graft (Jomed International AB) is a unique integration of graft material into a coronary stent. This device was constructed with a sandwich technique whereby an ultrathin layer of expandable PTFE, specially developed for integration into a stent graft system, is placed between 2 stents with reduced strut thickness (Figure 7E). The Stent Graft is also offered coated with the Corline Heparin Surface, which has the potential to reduce the risk of thrombus formation after stent implantation.

A novel approach to stent customization for the treatment of vessel rupture and aneurysms has been developed by Drs Stefanadis and Toutouzas.<sup>106</sup> Their approach involves passivation of the stent surface through the application of a segment of autologous vascular tissue. The technique uses a segment of cephalic vein or ulnar artery to cover the stent. The results of implantation of a device with a vein graft covering only the external surface of the stent have been reported both for elective indications<sup>106-109</sup> and in the setting of an acute MI.<sup>108-110</sup> Radial artery-covered stents have also been successfully implanted in saphenous vein bypass grafts,<sup>111,112</sup> as well as in both the body and ostia of native coronary vessels.<sup>112</sup> Further studies are necessary to clarify the potential of this technique.

### Radioactive Stents

The use of stents as platform for the delivery of radiation to the vessel wall has been receiving considerable attention.<sup>113,114</sup> Stent-bound radioactive sources can deliver effective doses of radioactivity to all levels of the vessel wall. It is also believed that radioactive stents can act by culling the smooth muscle cell population as these cells pass through the "electron fence" at the plane of the stent wires.<sup>115</sup>

Hehrlein and colleagues<sup>116,117</sup> were the first to describe the use of radioactive stents, which they implanted in nondiseased rabbit iliac arteries. The stainless steel stents were made radioactive by ion bombardment in a cyclotron and emitted both  $\gamma$ - and  $\beta$ -radiation from the radionuclides <sup>55,56,57</sup>Co, <sup>52</sup>Mg, and <sup>55</sup>Fe. Stents with activities of 3.9, 17.5, and 35 mCi were tested. At 4 weeks, exposure to the 2 higher dose levels resulted in a significant reduction in neointimal formation, and all treated animals exhibited a significant reduction in proliferating cell nuclear antigen-positive cell and smooth muscle cell counts. Vascular reendothelialization occurred despite prolonged irradiation; however, the time to complete

endothelial cell coverage was delayed in a dose-dependent manner.

Laird et al<sup>118</sup> also examined the effects of a radioactive coil stent. They first ion-implanted the nonradioactive element <sup>31</sup>P beneath the surface of the stent. The stents were then made radioactive by exposure to neutron irradiation, which converts a fraction of the <sup>31</sup>P atoms to <sup>32</sup>P, a pure  $\beta$ -particle emitter. This technique results in an even distribution of <sup>32</sup>P within the stent, which ensures homogeneous distribution of  $\beta$ -particle irradiation from the stent. This technique, however, generates other short-lived radioisotopes. Intraluminal exposure for 28 days to these radioactive stents, with an initial activity of 0.014 mCi, caused a significant reduction in neointimal area and percent area stenosis compared with the effects of nonradioactive stents.

The efficacy of a relatively low-dose, pure  $\beta$ -emitting stent for the inhibition of intimal hyperplasia was first demonstrated by Hehrlein and colleagues.<sup>119</sup> <sup>32</sup>P, produced by neutron bombardment, was ionized and ion-implanted beneath the outer surface of titanium-nickel stents. <sup>32</sup>P has several characteristics. <sup>32</sup>P-emitting stents with activities of 4 and 13 mCi were implanted in rabbit iliac arteries, and histomorphometry was performed at 4 and 12 weeks.<sup>119</sup> At 4 weeks, both groups showed significant reductions in neointimal formation, whereas at 12 weeks, only the group receiving the highest radiation dose showed a significant reduction in neointima compared with nonradioactive stents.

With a similar radioactive stent, the neointimal responses to implantation in a porcine coronary restenosis model were examined in stents with activities from 0.15 to 23 mCi. Neointimal formation was seen to be reduced 28 days after the implantation of low-activity (0.15 to 0.5 mCi) and high-activity (3 to 23 mCi) stents, but increased neointimal formation was observed with stents of 1-mCi initial activity. These results highlight the complexity of the response of the vascular wall to ionizing radiations. The stent used in this trial has subsequently become known as the Fischell IsoStent (IsoStent/Cordis Corp, a Johnson & Johnson Interventional Systems Co).<sup>120</sup> It is a stainless steel Palmaz-Schatz stent that has been modified to be  $\beta$ -particle-emitting by ion implantation as described above. Prompted by the encouraging results of  $\beta$ -particle-emitting stents on neointimal hyperplasia in animal models,<sup>117-119,121,122</sup> a multicenter pilot study examining the feasibility and safety of the implantation of 1-mCi Palmaz-Schatz stents has been completed, and the larger randomized IsoStent for Restenosis Intervention Study (IRIS) trial is under way.

Proton activation of nitinol produces the predominantly  $\beta$ -emitting isotope <sup>48</sup>V. The Act-One stent (Progressive Angioplasty Systems Inc), the predecessor of the Paragon stent, has been made radioactive through proton activation and tested in pig coronary arteries.<sup>123</sup> Radioactive Act-One stents with 1.5 mCi of <sup>48</sup>V activity had no effect on lumen narrowing or vessel histology, whereas 10-mCi <sup>48</sup>V stents inhibited neointimal thickening compared with nonradioactive stented control segments. Further studies are necessary to assess the effectiveness of radioactive nitinol stents for the prevention of restenosis.

**TABLE 7. Coating Material Considered for Use With Metal Intracoronary Stents**

Synthetic Substances	Naturally Occurring Substances
Polyurethane <sup>113–115</sup>	Collagen/laminin <sup>121</sup>
Segmented polyurethaneurea/heparin <sup>116</sup>	Heparin <sup>122–125</sup>
Poly-L-lactic acid <sup>117</sup>	Fibrin <sup>126</sup>
Cellulose ester <sup>118</sup>	Phosphorylcholine <sup>112</sup>
Polyethylene glycol <sup>119</sup>	AZ1 adsorbed to cellulose <sup>127,128</sup>
Polyphosphate ester <sup>120</sup>	AZ1/UK adsorbed to cellulose <sup>129,130</sup>

AZ1 indicates monoclonal antibody directed against rabbit platelet integrin  $\alpha_{IIb}\beta_3$ ; AZ1/UK, monoclonal antibody directed against rabbit platelet integrin  $\alpha_{IIb}\beta_3$ /urokinase conjugate.

### Stent Coatings

The list of materials used to coat metal stents in an attempt to reduce their inherent thrombogenicity and decrease the incidence of in-stent restenosis is long and ever increasing<sup>124–142</sup> (Table 7). A few, however, deserve special attention. Most coatings tested are placed mainly to provide a biologically inert barrier between the stent surface and the circulating blood. Commercially available are the gold-coated InFlow and NIR stents and the silicon carbide-coated Tensum and Tenax stents. In contrast to these, immobilized-heparin surface coatings have been studied as a means of providing a biologically active exterior that interacts with the circulating blood. Many techniques have been applied to attach heparin to synthetic surfaces; however, the description of a process for end-point attachment of heparin to polymer-coated surfaces that preserves the activity of the antithrombin binding site made the production of heparin-coated stents feasible.<sup>143</sup> Heparin-coated stents were shown to be effective in reducing thrombosis in rabbit peripheral vessels<sup>135</sup> and in porcine coronary arteries.<sup>136,137</sup> Three heparin-coated stents are currently available for clinical use: the Cordis/Johnson & Johnson heparin-coated Palmaz-Schatz stent, on which heparin is end-linked to the stent surface with a patented Carmeda coating technology; the Wiktor heparin-coated stent (Hepamed coating)<sup>144</sup>; and the Jostent (Corline heparin coating), on which heparin is randomly attached. Random covalent binding of heparin to the stent surface results in variable exposure of antithrombin binding sites, whereas high-activity end-point attachment, as on the Cordis/Johnson & Johnson product, ensures that all of the anti-thrombin III binding sites remain functionally intact. Animal studies using the high-activity heparin-coated stents have shown that up to 80% of the antithrombin III binding activity is lost 4 weeks after stent implantation.<sup>145</sup> Nevertheless, reduction in rates of stent thrombosis in animal studies led to the evaluation of the high-activity end-point-attached heparin-coated stents in the BENESTENT II pilot study<sup>146</sup> and the BENESTENT II randomized trial.<sup>147</sup> In the 616 patients receiving a heparinized stent in these studies, there was only 1 episode of subacute thrombosis (incidence <0.2%).

Another commercially available coated device is the divYsio stent (Biocompatibles Ltd), which is phosphorylcholine-coated. Phosphorylcholine is the major phospholipid component of biological membranes. On the basis of promising results *in vitro*<sup>148</sup> and *in vivo* in animal

models,<sup>149–151</sup> it is anticipated that these coated devices will behave as intact tissue elements, a form of biomimicry, and result in a reduction in the incidence of subacute occlusion and an improvement in the long-term patency rates of treated segments. These stents are now being evaluated in clinical trials in Europe for their ability to reduce the incidence of subacute occlusion and improve the long-term outcome in stented coronary segments.

Fibrin coating of intravascular stents has been proposed as a means of passivating the stent surface and providing a platform for the recolonization of endothelial cells.<sup>138</sup> Fibrin-coated Palmaz-Schatz stents were shown to be free of thrombus and foreign body reaction when examined 8 weeks after implantation in dog peripheral arteries.<sup>139</sup> This was compared with the 45% incidence of thrombosis seen with the implantation of naked stents. More notable was the finding of endothelialization of 96% of the surface of the fibrin-coated stents, whereas the uncoated controls were covered with endothelial cells over only 18% of their surface. Similar results were seen with implantation in pig coronary arteries. In this model, no significant foreign-body, giant-cell, or inflammatory reaction was seen up to 1 year after stent implantation.<sup>152</sup>

Polymeric coating of the stent *in situ* has also been shown to be feasible, a technique referred to as “gel paving.”<sup>142</sup> In a recently reported study, the application of polyethylene-glycol-lactide hydrogel polymers to the surface of Palmaz stents implanted in the porcine femoral artery model has been described.<sup>153</sup> The applied polymer is then photopolymerized *in situ* to form a short-term, semipermeable barrier. Stented segments treated in such a manner showed less gross thrombosis, less microscopic platelet adherence, and enhanced vessel patency compared with control stented segments. Many more animal data must be collected before this type of technology can be considered for clinical application.

As a result of their long residence times, attention has become focused on endovascular stents as a reservoir for prolonged local drug administration for the prevention of restenosis. This can be done by coating metallic stents with controlled-release matrices or incorporating a pharmacologically active compound into a polymeric stent or a polymer-metal composite stent.

Drug-polymer composites are referred to as monolithic matrices. When nondegradable matrices are used, drugs are delivered through sustained release by way of particle dissolution and diffusion through the cavitating network of the matrix. Extended drug release is possible through this approach, with formulations with release duration from hours to decades having been reported. Biodegradable polymer systems have also been used to formulate drug-delivery matrices. Biodegradable polymer matrices provide sustained delivery of pharmacological agents both by drug dissolution and by matrix degradation *in vivo*, leading to release of entrapped agents. The coating of a pharmaceutical stent with a biodegradable polymer also offers the attractive possibility that the drug-polymer system could disappear after a desired period of drug release.

Several candidate drugs for stent coatings have been considered. Undergoing clinical assessment is an InFlow



stent (InFlow Dynamics AG) coated with a polylactic acid carrier containing 5% polyethylene-glycol-hirudin and 1% prostaglandin I<sub>2</sub> analog (Iloprost). In vitro analysis demonstrated favorable degradation properties of the carrier and time-release characteristics of the incorporated antithrombotic and platelet-inhibiting drugs.<sup>154</sup> Analysis of the hirudin and Iloprost-eluting stents tested during stasis in a human shunt model demonstrated a significant effect on both platelet activation and blood coagulation,<sup>155</sup> and when implanted in sheep coronary arteries, they have been shown to exhibit a favorable effect on neointimal formation.<sup>156</sup> Another carrier/active agent system that appears promising is a cellulose polymer with passively adsorbed glycoprotein IIb/IIIa receptor antibody.<sup>140,141,157</sup> Active compound elutes from the stents in an exponential manner, with 48% of the bound agent eluted at 12 days when studied in vitro.<sup>158</sup> When investigated in a rabbit iliac artery model, antibody to glycoprotein IIb/IIIa eluted from cellulose-polymer-coated stents significantly reduced platelet aggregation in the stent microenvironment, reduced thrombus formation, improved blood flow and arterial patency rates, and inhibited cyclic blood flow variation.<sup>157</sup>

The use of gene therapy in conjunction with a pharmaceutical delivery stent could involve the transfer of a desired gene from the stent coating to the cells of the arterial wall. This should result in the expression and synthesis of a desirable product by the cells of the arterial wall. This approach would involve the incorporation of DNA or a viral vector into a polymeric matrix system under conditions that would facilitate cellular uptake and translation of the DNA. Another important possible strategy for a pharmaceutical stent approach might involve the incorporation of antisense oligonucleotides into an appropriate polymeric matrix.<sup>159,160</sup>

Interest in the development of a suitable biodegradable stent with pharmacologically active agents incorporated into the polymeric matrix, once a very active area of research, has waned considerably. To be effective, a drug-releasing biodegradable stent must be biocompatible, it must not cause an inflammatory reaction, and the breakdown products must be nontoxic. One such biodegradable device, however, that warrants mention is the Duke Biodegradable Stent, which is made from a special form of poly-L-lactide capable of incorporating pharmacologically active agents.<sup>161</sup> Both self-expanding and balloon-expandable versions of the Duke stent have been designed and tested in animals,<sup>162</sup> with promising results.

The seeding of intravascular stents with endothelial cells to passivate the stent surface has been an area of ongoing research for >9 years. Both self-expanding<sup>163</sup> and balloon-expandable<sup>164</sup> stents have been successfully seeded with endothelial cells and have been shown to retain a significant number of viable cells after deployment in vitro.<sup>163-165</sup> Using autologous endothelial cells derived from sheep saphenous veins, a group at the National Heart, Lung, and Blood Institute (NHLBI) has successfully seeded metallic stents and implanted the stents into the femoral arteries of the donor animals.<sup>166</sup> The transplanted endothelial cells could be detected in 6 of 9 animals treated in this manner 10 days after stent implantation. Scott and colleagues<sup>167</sup> also were successful in identifying endothelial cells on seeded stents 3 hours

after intracoronary implantation in pigs. These investigators used immortalized human microvascular cells that retain the phenotypic characteristics of endothelial cells after >50 passages.<sup>168</sup> The relevance of continued investment into the development of endothelium-covered stents may lie in the future possibility of seeding the stents with genetically modified endothelial cells capable of producing compounds for the treatment of restenosis.

### Future Advances

Despite the phenomenal pace of stent design technology, the incidence of stent restenosis remains unacceptably high. To address this problem, intense investigation into new stent coatings continues, with new biocompatible and drug-eluting polymers being developed for application to the metal stent scaffold. As novel biocompatible drug delivery stent coatings are developed, pharmacological compounds that failed to prevent restenosis when administered systemically and those with significant systemic toxicity are now being reexamined. The new drug-eluting stents also provide a unique platform for the administration of proteinaceous compounds, antisense oligonucleotides, and DNA that cannot be given systemically. In addition, metal stents provide a convenient means for the application of brachytherapy by use of ionizing radiation. Although initial clinical results seem promising, issues of correct dosimetry and the long-term effects of cytotoxic therapies on the arterial wall have arisen. Despite recent significant strides in stent design technology, it is apparent that much has yet to be learned and further advances are necessary to improve the long-term outcome of patients treated with intravascular stents.

### Angiogenesis and Transmyocardial Revascularization

Perhaps the most intriguing and exciting frontier in interventional cardiology is the ability to induce the growth of new blood vessels, a radically different therapeutic orientation compared with bypassing or deblocking diseased arteries. Several approaches have undergone pilot studies and have entered clinical trials involving either local angiogenic polypeptide growth factor administration, transfection of angiogenic genes, or the development of small channels in the endocardium to promote the passage of blood from the left ventricular cavity into the myocardium. The principal mechanism of improved myocardial blood flow for the latter approach, known as transmyocardial revascularization, is most likely related to stimulating angiogenesis, because the holes created by the laser (or other means) become fibrotic and occlude within weeks after the procedure.<sup>168-170</sup>

Therapeutic angiogenesis is undergoing intensive early clinical investigation. Isner et al<sup>171,172</sup> transfected the peripheral arteries with the cDNA for VEGF<sub>165</sub> via a hydrogel-coated balloon catheter. This was successful in a few patients for improving peripheral arterial ischemia and served as proof of concept; then the same group initiated intramuscular injection of the VEGF<sub>165</sub> naked human plasmid cDNA in 9 patients (10 ischemic limbs). In this initial series of intramuscular (rather than intra-arterial) injection of an angiogenic gene, 8 of 10 limbs had improved blood flow demonstrated

by MRI, and there was an overall 30% increase in the ankle-brachial index, a key measure of ameliorated limb blood supply. Patients were excluded for any known malignancy, diabetic retinopathy, or other conditions that might be associated with untoward sequelae from “inappropriate” angiogenesis.

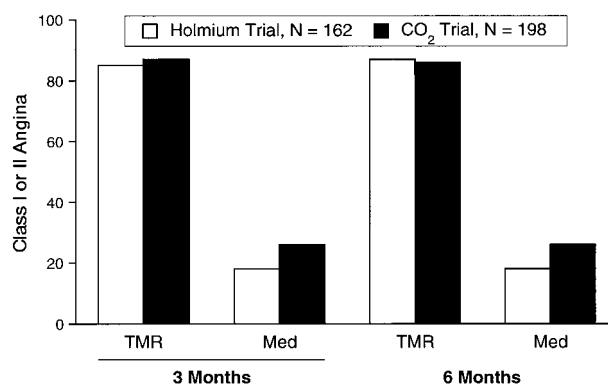
More recently, the initial forays into coronary angiogenesis have been reported. Schumacher et al,<sup>173</sup> from Freiburg, Germany, published the results of a randomized trial of 40 patients who had intramyocardial injection of acidic fibroblast growth factor (FGF-1) into the distal anterior wall at the time of internal mammary artery bypass graft surgery. Within 12 weeks, the 20 patients randomized to active FGF-1 had digital angiographic evidence of neovascularization.<sup>173</sup> During 3 years of follow-up, the ejection fraction improved from 50.3% to 63.8% in the treated group compared with 51.5% to 59.4% in the control (heat-inactivated FGF-1) group. No accelerated atherosclerosis or other untoward events were found.

In a parallel clinical investigation, intramyocardial injection of the gene for VEGF<sub>121</sub> was initiated using an adenoviral vector at the time of bypass surgery.<sup>174</sup> Like the clinical studies of Schumacher and colleagues, there was evidence from this preclinical porcine model of Mack et al<sup>175</sup> of extensive neovascularization at 4 weeks after VEGF transfection.

Henry and colleagues<sup>176</sup> presented their findings on intracoronary VEGF administration in a small dose-finding pilot trial of 15 patients, which showed marked improvement in perfusion in 7 patients (47%) by thallium scintigraphy and improved collateralization in 5 of 7 patients who underwent follow-up angiography. A larger follow-up study that combines intracoronary and subsequent intravenous VEGF has just been initiated. Laham and associates<sup>177</sup> used epicardial microcapsules with basic fibroblast growth factor in 8 patients at the time of bypass surgery, 4 of whom had enhanced perfusion by nuclear scans and MRI.

It was not fully anticipated that a single injection of either angiogenic protein or gene would produce prolonged neovascularization. This raises the question as to whether there is upregulation of angiogenic factors or their receptors once the stimulus is initiated.<sup>178</sup> The process of new blood vessel formation is such a complex and well-orchestrated series of events, requiring a multitude of growth factors and regulatory proteins, that it is probably naive to think that a 1-time application of a single growth factor will yield optimal angiogenesis. The gene transfer approach may be preferred over the protein with regard to potential for durability, but with the adenoviral vector, issues including gene regulation over time and the potential for induction of a host inflammatory response are poorly understood. The naked cDNA plasmid strategy, applied for the peripheral arterial insufficiency indication, is fraught with low efficiency of transfer and probably more transient gene expression.

Although the angiogenesis can be demonstrated by imaging modalities, it is uncertain whether it will lead to normalization of perfusion or complete mitigation of provokable ischemia. It remains to be seen whether the collateral supply will be enhanced for long-term follow-up, but the functional



**Figure 8.** Incidence of class I or II angina among patients randomized in 2 trials of transmyocardial revascularization (TMR) vs medical therapy (Med) (References 74 and 75). All patients had class 3 or 4 angina at time of enrollment.

data provided by Schumacher’s group are, at the very least, encouraging. Still, the unknown effects of accelerating atherosclerosis or facilitation of a latent malignancy need to be carefully assessed. Notwithstanding these concerns, large-scale clinical investigation for coronary angiogenesis with either the protein or gene for specific growth factors is warranted.

Substantial clinical pilot studies of transluminal myocardial revascularization (TMR) have suggested the potential for relief of angina.<sup>179–185</sup> Three clinical trials have been completed with TMR performed at the time of open-heart surgery. With the CO<sub>2</sub> laser, 198 patients were randomized to TMR or initial medical therapy.<sup>186</sup> Holmium laser was also the subject of a randomized trial that enrolled 162 patients.<sup>187</sup> The results of these 2 trials are remarkably concordant with reduction of angina, improvement of functional status, and in select patients with ancillary nuclear imaging, improved perfusion. As summarized in Figure 8, these salutary effects were also associated with less need for repeat hospitalization and less antianginal medication. For example, in the study by Allen et al,<sup>187</sup> the need for cardiac hospitalization at 3 months was reduced from 43% in medically managed patients to 20% in the group treated with TMR. Thus, it appears that TMR is effective for reducing angina, but the mechanism is not fully elucidated. Because the holes occlude fairly quickly, over just a few weeks in postmortem studies and experimental models, the most likely explanation for the benefit is angiogenesis.<sup>168–170,188</sup> However, neuronal dysfunction induced by the laser has been raised as a plausible explanation for some of the antianginal effect based on elegant experimental modeling that focused on reflexes to systemic hypotension with bradykinin applied directly to the epicardium after TMR.<sup>189</sup> Recent mechanistic studies have verified improvement in dobutamine-induced angina threshold, myocardial blood flow by PET, and even on indices of ventricular repolarization.<sup>190–192</sup> With regard to safety, there were some initial concerns regarding a high operative mortality in these series (in the 8% to 10% range), but more recent experience suggests that this may have been attributable to patient selection or an obligatory operator learning curve.

The encouraging results in the initial surgical trials have led to clinical investigation with the use of holmium or

excimer laser via the percutaneous approach.<sup>193,194</sup> To date, no randomized trial data are available, but pilot studies demonstrate feasibility and apparent safety in the first few hundred patients treated. Clearly, the ability to direct the laser to the ischemic myocardial bed is lessened with the percutaneous approach, but new catheter-based sensor systems that are nonfluoroscopic and use electroanatomic mapping are being investigated to improve on the precision of where the holes are applied.<sup>195,196</sup> Because the dominant mechanism may relate to stimulation of angiogenesis, it is not clear that precision is vital. The damage to the myocardium that is anticipated in the form of non-ST-elevation MI and its long-term effects has not been amply studied. A percutaneous strategy has obvious advantages, because it will allow more ready application to patients who are truly inoperable or can be used as an adjunct in patients with a chronic total occlusion that is not amenable to a routine epicardial strategy. Nevertheless, TMR will need considerable study and comparison with pharmacological or genetic forms of angiogenesis. Even the concept of injected angiogenic factors at the time the holes are created has been subjected to experimental study and, if shown clinically to be synergistic, may someday prove to be a useful combined strategy.<sup>197</sup>

Another highly provocative strategy is a tissue-engineered blood vessel. L'Heureux and associates,<sup>198</sup> in Quebec, have demonstrated the feasibility of cloning new arteries via cultured human smooth muscle cells, endothelial cells, and fibroblasts. Although this seems futuristic, it is possible that larger, bioengineered vessels cloned from patients who have significant ischemia may be a viable alternative in the next millennium to the conventional epicardial or emerging angiogenesis interventions of today.

### Overall Perspective

The field of interventional cardiology is poised to go through significant further development. By the start of the 2000s, improved platelet coverage will be routine in all patients undergoing procedures, and oral therapies for more extended periods during follow-up will be more thoroughly investigated. It would not be at all surprising if angiogenesis therapy, be it by intracoronary, intramyocardial (at the time of surgery), or transmyocardial laser revascularization, became an important adjunctive means of achieving improved myocardial blood flow. Restenosis therapies will undoubtedly blossom beyond the initial application of radiation for in-stent restenosis, ideally taking advantage of the increased understanding that we now have of genetic control of cell proliferation and matrix production. Although stents are already being used in >60% of patients at the time of interventional procedures, their use will also increase further with improved designs, coatings, and the newfound ability to use the stent as an effective drug delivery station.

### References

1. Sigwart U, Puel J, Mirkovitch V, Joffre F, Kappenberger L. Intravascular stents to prevent occlusion and restenosis after transluminal angioplasty. *N Engl J Med.* 1987;316:701-706.
2. Serruys PW, Strauss BH, Beatt KJ, Bertrand ME, Puel J, Richards AF, Meier B, Goy J, Vogt P, Kappenberger L, Sigwart U. Angiographic

follow-up after placement of a self-expanding coronary-artery stent. *N Engl J Med.* 1990;324:13-17.

3. Serruys PW, de Jaegere P, Kiemeneij F, Macaya C, Rutsch W, Heyndrickx G, Emanuelsson H, Marco J, Legrand V, Materne P, Belardi J, Sigwart U, Colombo A, Goy JJ, Van den Heuvel P, Delcan J, Morel M-A, for the BENESTENT Study Group. A comparison of balloon expandable-stent implantation with balloon angioplasty in patients with coronary artery disease. *N Engl J Med.* 1994;331:489-495.
4. Fischman DL, Leon MB, Baim DS, Schatz RA, Savage MP, Penn I, Detre K, Veltri L, Ricci D, Nobuyoshi M, Cleman M, Heuser R, Almond D, Teirstein PS, Fish RD, Colombo A, Brinker J, Moses J, Shakhovich A, Hirshfeld J, Bailey S, Ellis S, Rake R, Goldberg S. A randomized comparison of coronary stent placement and balloon angioplasty in the treatment of coronary artery disease. *N Engl J Med.* 1994;331:496-501.
5. Topol EJ. Caveats about elective coronary stenting. *N Engl J Med.* 1994;331:539-541.
6. Mak KH, Belli G, Ellis SG, Moliterno DJ. Subacute stent thrombosis: evolving issues and current concepts. *J Am Coll Cardiol.* 1996;27:494-503.
7. Rozenman Y, Lotan C, Mosseri M, Gotsman MS. Relation of thrombotic occlusion of coronary stents to the indication for stenting, stent size, and anticoagulation. *Am J Cardiol.* 1995;75:84-85.
8. Bux JJ, de Scheerder I, Beatt K, Van den Brand M, Suryapranata H, de Feyter PJ, Serruys PW. The importance of adequate anticoagulation to prevent early thrombosis after stenting of stenosed venous bypass grafts. *Am Heart J.* 1991;121:1389-1396.
9. George BS, Voorhees WD III, Roubin GS, Fearnot NE, Pinkerton CA, Raizner AE, King SB, Holmes DR, Topol EJ, Kereiakes DJ, Hartzler GO. Multicenter investigation of coronary stenting to treat acute or threatened closure after percutaneous transluminal coronary angioplasty: clinical and angiographic outcomes. *J Am Coll Cardiol.* 1993;22:135-143.
10. Nath FC, Muller DWM, Ellis SG, Rosenschein U, Chapekis A, Quain L, Zimmerman C, Topol EJ. Thrombosis of a flexible coil coronary stent: frequency, predictors and clinical outcome. *J Am Coll Cardiol.* 1993;21:622-627.
11. Colombo A, Goldberg SL, Almagor Y, Maiello L, Finci L. A novel strategy for stent deployment in the treatment of acute or threatened closure complicating balloon coronary angioplasty. *J Am Coll Cardiol.* 1993;22:1887-1891.
12. Moussa I, Di Mario C, Di Francesco L, Reimers B, Blengino S, Colombo A. Subacute stent thrombosis and the anticoagulation controversy: changes in drug therapy, operator technique, and the impact of intravascular ultrasound. *Am J Cardiol.* 1996;78(suppl 3A):13-17.
13. Neumann FJ, Gawaz M, Ott I, May A, Mossmer G, Schomig A. Prospective evaluation of hemostatic predictors of subacute stent thrombosis after coronary Palmaz-Schatz stenting. *J Am Coll Cardiol.* 1996;27:15-21.
14. Lehmann KG, van Suylen RJ, Stibbe J, Slager CJ, Oomen JA, Maas A, di Mario C, de Feyter P, Serruys PW. Composition of human thrombus assessed by quantitative colorimetric angiographic analysis. *Circulation.* 1997;96:3030-3041.
15. Hasdai D, Garratt KN, Holmes DR, Berger PB, Schwartz RS, Bell MR. Coronary angioplasty and intracoronary thrombolysis are of limited efficacy in resolving early intracoronary stent thrombosis. *J Am Coll Cardiol.* 1996;28:361-367.
16. Schömig A, Neumann FJ, Kastrati A, Schühlen H, Blasini R, Hadamitzky M, Walter H, Zitzmann-Roth EM, Richardt G, Alt E, Schmitt C, Ulm K. A randomized comparison of antiplatelet and anticoagulant therapy after the placement of coronary artery stents. *N Engl J Med.* 1996;334:1084-1089.
17. Leon MB, Baim DS, Gordon P, Giambartolomei A, Williams DO, Diver DD, Senerchia C, Fitzpatrick M, Popma JJ, Kuntz RE. Clinical and angiographic results from the Stent Anticoagulation Regimen Study (STARS). *Circulation.* 1996;94(suppl 1):I-685. Abstract.
18. Hall P, Nakamura S, Maiello L, Itoh A, Belengino S, Martini G, Ferraro M, Colombo A. A randomized comparison of combined ticlopidine and aspirin therapy versus aspirin therapy alone after successful intravascular ultrasound-guided stent implantation. *Circulation.* 1996;93:215-222.
19. Bertrand M, Legrand V, Boland J, Fleck E, Bonnier J, Emmanuelson H, Vrolix M, Missault L, Chierchia S, Casaccia M, Nicolini L. Full anticoagulation versus ticlopidine plus aspirin after stent implantation: a randomized multicenter European study: the FANTASTIC trial. *Circulation.* 1996;94(suppl 1):I-685. Abstract.



20. Urban P, Macaya C, Rupprecht H-J, Kiemeneij F, Emanuelsson H, Fontanelli A, Pieper M, Wesseling T, Sagnard L, for the MATTIS Investigators. Multicenter Aspirin and Ticlopidine Trial after Intracoronary Stenting in high risk patients (MATTIS). *J Am Coll Cardiol*. 1998;31(suppl A):397A. Abstract.
21. Kiemeneij F, Laarman GJ, Slagboom T, van der Wieken R. Outpatient coronary stent implantation. *J Am Coll Cardiol*. 1997;29:323–327.
22. Bennet CL, Weinberg PD, Rozenberg-Ben-Dror K, Yarnold PR, Kwaan HC, Green D. Thrombolytic thrombocytopenic purpura associated with ticlopidine. *Ann Intern Med*. 1998;128:541–544.
23. Kupfer Y, Tessler S. Ticlopidine and thrombotic thrombocytopenic purpura. *N Engl J Med*. 1997;337:1245. Letter.
24. Collier BS. Platelet GP IIb/IIIa antagonists: the first anti-integrin receptor therapeutics. *J Clin Invest*. 1997;99:1467–1471.
25. Lefkowitz J, Plow EF, Topol EJ. Platelet glycoprotein IIb/IIIa receptors in cardiovascular medicine. *N Engl J Med*. 1995;332:1553–1559.
26. The EPIC Investigators. Use of a monoclonal antibody directed against the platelet glycoprotein IIb/IIIa receptor in high-risk coronary angioplasty. *N Engl J Med*. 1994;330:956–961.
27. The IMPACT II Investigators. Randomized placebo-controlled trial of effect of eptifibatid on complications of percutaneous coronary intervention. *Lancet*. 1997;349:1422–1428.
28. The CAPTURE Investigators. Randomized placebo-controlled trial of abciximab before and during intervention in refractory unstable angina: the CAPTURE study. *Lancet*. 1997;349:1429–1435.
29. The RESTORE Investigators. Effects of platelet glycoprotein IIb/IIIa blockade with tirofiban on adverse cardiac events in patients with unstable angina or acute myocardial infarction undergoing coronary angioplasty. *Circulation*. 1997;96:1445–1453.
30. EPILOG Investigators. Effect of the platelet glycoprotein IIb/IIIa receptor inhibitor abciximab with lower heparin dosages on ischemic complications of percutaneous coronary revascularization. *N Engl J Med*. 1997;336:1689–1696.
31. The EPISTENT Investigators. Randomised controlled trial to assess safety of coronary stenting with use of abciximab. *Lancet*. 1998;352:85–90.
32. Kereiakes DJ, Lincoff AM, Miller DP, Tchong JE, Weisman HF, Anderson KM, Cabot K, Califf RM, Topol EJ, for the EPILOG Trial Investigators. Abciximab therapy and unplanned coronary stent deployment: favorable effects on stent utilization, clinical outcomes and bleeding complications. *Circulation*. 1998;97:857–864.
33. Zidar JP, Kruse RKR, Thel MC, Kereiakes DJ, Muhlestein JB, Davidson CJ, Teirstein PS, Tenaglia A, Yakubov SJ, Popma JJ, Tanguay J, Kitt MM, Lorenz TJ, Tchong JE, Lincoff AM, Califf RM, Topol EJ. Integrelin for emergency coronary artery stenting. *J Am Coll Cardiol*. 1996;37:138A. Abstract.
34. Bhatt DL, Lincoff AM, Kereiakes DJ, Tchong JE, Godfrey N, Califf RM, Topol EJ. Reduction in the need for unplanned stenting with the use of platelet glycoprotein IIb/IIIa blockade in percutaneous coronary intervention. *Eur Heart J*. 1998;19(suppl):239. Abstract.
35. Narins CR, Holmes DR, Topol EJ. A call for provisional stenting: the balloon is back! *Circulation*. 1998;97:1298–1305.
36. Topol EJ, Califf RM, Weisman HF, Ellis SG, Tchong JE, Worley S, Ivanhoe R, George BS, Fintel D, Weston M, Sigmon K, Anderson KM, Lee KL, Willerson JT, on behalf of the EPIC Investigators. Randomized trial of coronary intervention with antibody against platelet IIb/IIIa integrin for reduction of clinical restenosis: results at six months. *Lancet*. 1994;343:881–886.
37. Topol EJ, Ferguson JJ, Weisman HF, Tchong JE, Ellis SG, Wang AL, Anderson KM, Califf RM, on behalf of the EPIC Investigators. Long term protection from myocardial ischemic events after brief integrin  $\beta_3$  blockade with percutaneous coronary intervention. *JAMA*. 1997;278:479–484.
38. Jones JJ, Prevette T, Gockerman A, Clemmons DR. Ligand occupancy of the alpha-V-beta3 integrin is necessary for smooth muscle cells to migrate in response to insulin-like growth factor. *Proc Natl Acad Sci U S A*. 1996;93:2482–2487.
39. Matsuno H, Stassen JM, Moons L, Vermeylen J, Hoylaerts MF. Neointima formation in injured hamster carotid artery is effectively prevented by the combination G4120 and quinapril. *Thromb Haemost*. 1996;76:263–269.
40. Ellis SG, Serruys PW, Popma JJ, Teirstein PS, Ricci DR, Gold HK, Effron MB. Can abciximab prevent neointimal proliferation in Palmaz-Schatz stents? The final ERASER results. *Circulation* 1997;96(suppl I):I-87. Abstract.
41. Brener SJ, Barr LA, Burchenal JEB, Katz S, George BS, Jones AA, Cohen ED, Gainey PC, White HJ, Cheek HB, Moses JW, Moliterno DJ, Effron MB, Topol EJ, on behalf of the RAPPORT Investigators. A randomized, placebo-controlled trial of platelet glycoprotein IIb/IIIa blockade with primary angioplasty for acute myocardial infarction. *Circulation*. 1998;98:734–741.
42. Topol EJ, Leya F, Pinkerton CA, Whitlow PL, Hofling B, Simonton CA, Masden RR, Serruys PW, Leon MB, Williams DO, King SB, Mark DB, Isner JM, Holmes DR, Ellis SG, Lee KL, Keeler G, Berdan LG, Hinojara T, Califf RM, on behalf of the CAVEAT Study Group. A comparison of coronary angioplasty with directional atherectomy in patients with coronary artery disease. *N Engl J Med*. 1993;329:221–227.
43. Abdelmeguid AE, Topol EJ. The myth of the myocardial “infarctlet” during percutaneous coronary revascularization procedures. *Circulation*. 1996;94:3369–3375.
44. Kong TQ, Davidson CJ, Meyers SN, Tauke JT, Parker MA, Bonow RO. Prognostic implication of creatine kinase elevation following elective coronary artery interventions. *JAMA*. 1997;277:461–466.
45. Abdelmeguid AE, Topol EJ, Whitlow PL, Sapp SK, Ellis SG. Significance of mild transient release of creatine kinase-MB fraction after percutaneous coronary interventions. *Circulation*. 1996;94:1528–1536.
46. Topol EJ. Toward a new frontier in myocardial reperfusion therapy: emerging platelet preeminence. *Circulation*. 1998;97:211–218.
47. Topol EJ, Califf RM, George BS, Kereiakes DJ, Abbottsmith CW, Candela RJ, Lee KL, Pitt B, Stack RS, O’Neill WW, and the Thrombolysis and Angioplasty in Myocardial Infarction (TAMI) Study Group. A randomized trial of immediate versus delayed elective angioplasty after intravenous tissue plasminogen activator in acute myocardial infarction. *N Engl J Med*. 1987;317:581–588.
48. Simoons ML, Arnold AER, Betriu A, DeBono DP, Col J, Dougherty FC, von Esen R, Lambertz H, Lubsen J, Meier B, Michel PL, Raynaud P, Rutsch W, Sanz GA, Schmidt W, Serruys PW, Thery C, Vevis R, Vahanian A, Van de Werf F, Willems GM, Wood G, Verstraete M. Thrombolysis with tissue plasminogen activator in acute myocardial infarction: no additional benefit from immediate percutaneous transluminal coronary angioplasty. *Lancet*. 1988;1:197–203.
49. TIMI Research Group. Immediate vs delayed catheterization and angioplasty following thrombolytic therapy for acute myocardial infarction: TIMI IIA results. *JAMA*. 1988;260:2849–2858.
50. Gold HK, Garabedian HD, Dinsmore RE, Guerrero LJ, Cigarroa JE, Palacios IF, Leinbach RC. Restoration of coronary flow in myocardial infarction by intravenous chimeric 7E3 antibody without exogenous plasminogen activators: observations in animals and humans. *Circulation*. 1997;95:1755–1759.
51. Neumann FJ, Blasini R, Dirschinger J, Schmitt C, Alt E, Gawaz MP, Fakhoury L, Huppman R, Schömig A. Intracoronary stent implantation and antithrombotic regimen in acute myocardial infarction: randomized placebo controlled trial of the fibrinogen receptor antagonist abciximab. *Circulation*. 1997;96(suppl):I-398. Abstract.
52. Braunwald E. TIMI 14 (Fibrinolytics + IIb/IIIa Blockade). Presented at the Cleveland Clinic’s XI Annual Myocardial Reperfusion International Symposium at the American College of Cardiology (ACC), Atlanta, Ga, March 28, 1998.
53. Ohman EM. GUSTO 4 Pilot. Presented at the Cleveland Clinic’s XI Annual Myocardial Reperfusion International Symposium at the American College of Cardiology (ACC), Atlanta, Ga, March 28, 1998.
54. The PURSUIT (Platelet glycoprotein IIb/IIIa in Unstable angina. Receptor Suppression Using Integrilin Therapy) Trial Investigators. Inhibition of the platelet glycoprotein IIb/IIIa with eptifibatid in patients with acute coronary syndromes without persistent ST-segment elevation. *N Engl J Med*. 1998;339:436–443.
55. The Platelet Receptor Inhibition for Ischemic Syndrome Management in Patients Limited by Unstable Signs and Symptoms (PRISM-PLUS) Study Investigators. Inhibition of the platelet glycoprotein IIb/IIIa receptor with tirofiban in unstable angina and non-Q-wave myocardial infarction. *N Engl J Med*. 1998;338:1488–1497.
56. The PARAGON Investigators. An international, randomized, controlled trial of lamifiban, a platelet glycoprotein IIb/IIIa inhibitor, heparin, or both in unstable angina. *Circulation*. 1998;97:2386–2395.
57. Berger PB, Ellis SG, Holmes DR, Granger CB, Criger DA, Betriu A, Topol EJ, Califf RM, for the GUSTO-I Investigators. Relationship between delay in performing direct coronary angioplasty and early clinical outcome in patients with acute myocardial infarction: results from the Global Use of Strategies to Open Occluded Arteries in Acute Coronary Syndromes (GUSTO-IIb) Trial. *Circulation*. 1998. In press.



58. Brodie BR, Stuckey TD, Wall TC, Muncy DB, Hansen CJ, de France AC, Weintraub RA, Kelly TA, Berry JJ. Importance of time to reperfusion for hospital and long-term survival and recovery of left ventricular function after primary angioplasty for acute myocardial infarction. *Circulation*. 1997;96(suppl 1):I-32. Abstract.
59. Ohno T, Gordon D, San H, Pompili VJ, Imperiale MJ, Nabel GJ, Nabel EG. Gene therapy for vascular smooth muscle cell proliferation after arterial injury. *Science*. 1994;265:781-784.
60. Chang MW, Barr E, Seltzer J, Jiang YQ, Nabel GJ, Nabel EG, Parmacek MS, Leiden JM. Cytostatic gene therapy for vascular proliferative disorders with a constitutively active form of the retinoblastoma gene product. *Science*. 1995;267:518-522.
61. von der Leyen HE, Gibbons GH, Morishita R, Lewis NP, Zhang L, Nakajima M, Kaneda Y, Cooke JP, Dzau VJ. Gene therapy inhibiting neointimal vascular lesion: in vivo transfer of endothelial cell nitric oxide synthase gene. *Proc Natl Acad Sci U S A*. 1995;92:1137-1141.
62. Janssens S, Flaherty D, Nong Z, Varenne O, van Pelt N, Hausermans C, Zoldhelyi P, Gerard R, Collen D. Human endothelial nitric oxide synthase gene transfer inhibits vascular smooth muscle cell proliferation and neointima formation after balloon injury in rats. *Circulation*. 1998;97:1274-1281.
63. Nakajima M, Hutchinson HG, Fujinaga M, Hayashida W, Morishita R, Zhang L, Horiuchi M, Pratt RE, Dzau VJ. The angiotensin II type II receptor antagonizes the growth effects of the AT1 receptor: gain-of-function study using gene transfer. *Proc Natl Acad Sci U S A*. 1995;92:10663-10667.
64. Rade JJ, Schulick AH, Virmani R, Dichek DA. Local adenoviral-mediated expression of recombinant hirudin reduces neointima formation after arterial injury. *Nat Med*. 1996;2:293-298.
65. Dollery CM, McEwan JR, Henney AM. Matrix metalloproteinases and cardiovascular disease. *Circ Res*. 1995;77:863-868.
66. Newby AC, Fabunmi RP, George SJ, Southgate KM, Banning AP, Thurston VJ, Williams A. Neointimal fibrosis in vascular pathologies: role of growth factors and metalloproteinases in vascular smooth muscle proliferation. *Exp Nephrol*. 1995;3:108-113.
67. Bendeck MP, Irvin C, Reidy MA. Inhibition of matrix metalloproteinase activity inhibits smooth muscle cell migration but not neointimal thickening after arterial injury. *Circ Res*. 1996;78:38-43.
68. Southgate KM, Davies M, Booth RFG, Newby AC. Involvement of extracellular-matrix-degrading metalloproteinases in rabbit aortic smooth-muscle cell proliferation. *Biochem J*. 1992;288:93-99.
69. Zempo N, Koyama N, Kenagy RD, Lea HJ, Clowes AW. Regulation of vascular smooth muscle cell migration and proliferation in vitro and injured rat arteries by a synthetic matrix metalloproteinase inhibitor. *Arterioscler Thromb Vasc Biol*. 1996;16:28-33.
70. George SJ, Newby AC. A metalloproteinase inhibitor (Ro 31-9790) inhibits smooth muscle cell proliferation and migration and neointimal formation in human saphenous vein. *Eur Heart J*. 1996;17:196. Abstract.
71. Willenbrock F, Murphy G. Structure-function relationships in the tissue inhibitors of metalloproteinases. *Am J Respir Crit Care Med*. 1994;150: S165-S170.
72. Greene J, Wang MS, Liu YLE, Raymond LA, Rosen C, Shi YNE. Molecular cloning and characterization of human tissue inhibitor of metalloproteinase 4. *J Biol Chem*. 1996;271:30375-30380.
73. George SJ, Johnson JL, Angelini AC, Newby AC, Baker AH. Adenovirus-mediated gene transfer of the human TIMP-1 gene inhibits smooth muscle cell migration and neointimal formation in human saphenous vein. *Hum Gene Ther*. 1998;9:867-877.
74. Simons M, Edelman ER, DeKeyser JL, Langer R, Rusenberg RD. Antisense c-myc oligonucleotides inhibit intimal arterial smooth muscle cell accumulation in vivo. *Nature*. 1992;359:67-70.
75. Edelman ER, Simons M, Sirois MG, Rosenberg RD. c-Myc in vasculoproliferative disease. *Circ Res*. 1995;76:176-182.
76. Azrin MA, Mitchel JF, Pedersen C. Inhibition of smooth muscle cell proliferation in vivo following local delivery of antisense c-myc oligonucleotide during angioplasty. *J Am Coll Cardiol*. 1994;23(suppl):396A. Abstract.
77. Gunn J, Holt CM, Shepherd L, Francis SE, Smith GH, Cumberland DC. Local delivery of c-myc antisense attenuates neointimal thickening in porcine model of coronary angioplasty. *J Am Coll Cardiol*. 1995;25(suppl):201A. Abstract.
78. Bennett MB, Anglin S, McEwan JR, Newby AC, Evan GI. Inhibition of vascular smooth muscle cell proliferation in vitro and in vivo by c-myc antisense oligodeoxynucleotides. *J Clin Invest*. 1994;93:820-828.
79. Shi Y, Fard A, Galeo A, Hutchinson HG, Vermani P, Dodge GR, Hall DJ, Shaheen F, Zalewski A. Transcatheter delivery of c-myc antisense oligomers reduces neointimal formation in a porcine model of coronary artery balloon injury. *Circulation*. 1994;90:944-951.
80. Morishita R, Gibbons GH, Ellison KE, Nakajima M, Zhang L, Kaneda Y, Oghihara T, Dzau VJ. Single intraluminal delivery of antisense cdc2 kinase and proliferating-cell nuclear antigen oligonucleotides results in chronic inhibition of neointimal hyperplasia. *Proc Natl Acad Sci U S A*. 1993;90:8474-8478.
81. Abe J, Zhou W, Taguchi J, Takuwa N, Miki K, Okazaki H, Kurokawa K, Kumada M, Takuwa Y. Suppression of neointimal smooth muscle cell accumulation in vivo by antisense cdc-2 and cdk-2 oligonucleotides in rat carotid artery. *Biochem Biophys Res Commun*. 1994;198:16-24.
82. Morishita R, Gibbons GH, Ellison KE, Nakajima M, von der Leyen H, Zhang L, Kaneda Y, Oghihara T, Dzau VJ. Intimal hyperplasia after vascular injury is inhibited by antisense cdk-2 oligonucleotides. *J Clin Invest*. 1994;93:1458-1464.
83. Simons M, Edelman ER, Rosenberg RD. Antisense PCNA oligonucleotides inhibit intimal hyperplasia in a rat carotid injury model. *J Clin Invest*. 1994;93:2351-2356.
84. Sirois MG, Simons M, Edelman BR, Rosenberg RD. Platelet release of platelet derived growth factor is required for intimal hyperplasia in rat vascular injury model. *Circulation*. 1994;90(suppl 1):I-511. Abstract.
85. Kuntz RE, Gibson CM, Nobuyoshi M, Baim DS. Generalized model of restenosis after conventional balloon angioplasty, stenting and directional atherectomy. *J Am Coll Cardiol*. 1993;21:15-25.
86. Macaya C, Serruys PW, Ruygrok P, Suryapranata H, Mast G, Klugman S, Urban P, den Heijer P, Koch K, Simon R, Morice MC, Crean P, Bonnier H, Wijns W, Danchin N, Bourdonnet C, Morel MA. Continued benefit of coronary stenting versus balloon angioplasty: one year clinical follow-up of Benestent trial. *J Am Coll Cardiol*. 1996;27:255-261.
87. Rogers C, Edelman ER. Endovascular stent design dictates experimental restenosis and thrombosis. *Circulation*. 1995;91:2995-3001.
88. Carter AJ, Scott D, Bailey L, Kim D, Devries J, Jones R, Virmani R. A comparison of stent designs in small diameter porcine coronary arteries. *J Am Coll Cardiol*. 1997;29(suppl A):170A. Abstract.
89. Goy JJ, Eeckhout E, Stauffer JC, Vogt P. Stenting of the right coronary artery for de novo stenoses: a comparison of the Wiktor and the Palmaz-Schatz stents. *Circulation*. 1995;92(suppl 1):I-536. Abstract.
90. Barth KL, Virmani R, Froelich J, Takeda T, Lossef SV, Newsome J, Jones R, Lindisch D. Paired comparison of vascular wall reactions to Palmaz stents, Strecker tantalum stents, and Wallstents in canine iliac and femoral arteries. *Circulation*. 1996;93:2161-2169.
91. Fontaine AB, Spigos DG, Eaton G, Dos Passos S, Christofordis G, Khabiri H, Jung S. Stent induced intimal hyperplasia: are there fundamental differences between flexible and rigid stent designs? *J Vasc Interv Radiol*. 1994;5:739-744.
92. Tominaga R, Kambic HE, Emoto H, Harasaki H, Sutton C, Hollman J. Effects of design geometry of intervascular endoprostheses on stenosis rate in normal rabbits. *Am Heart J*. 1992;123:21-27.
93. Baier R. Initial events in interaction of blood with a foreign surface. *J Biomed Mater Res*. 1969;3:191-206.
94. De Palma VE, Baier RE. Investigation of three-surface properties of several metals and their relation to blood biocompatibility. *J Biomed Mater Res*. 1972;6:37-75.
95. Zitter H, Plenck H Jr. The electrochemical behavior of metallic implant material as an indicator of their biocompatibility. *J Biomed Mater Res*. 1987;21:881-896.
96. Hehrlein C, Zimmerman M, Metz J, Ensinger W, Kübler W. Influence of surface texture and charge on the biocompatibility of endovascular stents. *Coron Artery Dis*. 1995;6:581-586.
97. De Scheerder I, Sohler J, Wang K, Verbeke E, Zhou XR, Frooyen L, Van Humbeek J, Piessens J. Metallic surface treatment using electrochemical polishing decreases thrombogenicity and neointimal hyperplasia after coronary stent implantation in a porcine model. *Eur Heart J*. 1997;18(suppl):153. Abstract.
98. Hearn JA, Robinson KA, Roubin GS. In-vitro thrombus formation of stent wires: role of metallic composition and heparin coating. *J Am Coll Cardiol*. 1991;17(suppl):302A. Abstract.
99. van der Giessen WJ, Serruys PW, van Beusekom HMM, van Woerkens LJ, van Loon H, Soei LK, Strauss BH, Beatt KJ, Verdouw PD. Coronary stenting with a new radiopaque, balloon-expandable endoprosthesis in pigs. *Circulation*. 1991;83:1788-1798.
100. Scott NA, Robinson KA, Nunes GL, Thomas CN, Viel K, King SB, Harker LA, Rowland SM, Juman I, Cipolla G, Hanson SR. Comparison

- of the thrombogenicity of stainless steel and tantalum coronary stents. *Am Heart J*. 1995;129:866–872.
101. Sheth S, Litvack F, Dev V, Fishbein MC, Forrester JS, Eigler N. Subacute thrombosis and vascular injury resulting from slotted-tube nitinol and stainless steel stents in a rabbit carotid artery model. *Circulation*. 1996;94:1733–1740.
  102. Sheth S, Dev V, Fishbein MC, Forrester JS, Litvack F, Eigler NL. Reduced thrombogenicity of nitinol versus stainless steel slotted stents in rabbit carotid arteries. *J Am Coll Cardiol*. 1995;25(suppl):240A. Abstract.
  103. Hong MK, Beyar R, Kornowski R, Tio FO, Bramwell O, Leon MB. Acute and chronic effects of self expanding nitinol stents in porcine coronary arteries. *Coron Artery Dis*. 1997;8:45–48.
  104. Schwartz RS, Huber KC, Murphy JG, Edwards WD, Camrud AR, Vlietstra RE, Holmes DR. Restenosis and proportional neointimal response to coronary artery injury: results in a porcine model. *J Am Coll Cardiol*. 1992;19:267–274.
  105. Strauss BH, Serruys PW, de Scheerder IK, Tijssen JGP, Bertrand ME, Peul J, Meier B, Kauffman U, Stauffer JC, Rickards AF, Sigwart U. A relative risk analysis of the angiographic predictors of restenosis in the coronary Wallstent. *Circulation*. 1991;84:1636–1643.
  106. Stefanadis C, Toutouzas P. Percutaneous implantation of autologous vein graft stent for the treatment of coronary artery disease. *Lancet*. 1995;345:1509. Letter.
  107. Stefanadis C, Eleftherios T, Toutouzas K, Vlachopoulos C, Kallikazaros I, Stratos C, Vavuranakis M, Sideris A, Toutouzas P. Autologous vein graft-coated stent for the treatment of coronary artery disease: immediate results after percutaneous placement in humans. *J Am Coll Cardiol*. 1996;27(suppl):179A. Abstract.
  108. Toutouzas K, Stefanadis C, Tsiamis E, Vlachopoulos C, Stratos C, Kallikazaros I, Toutouzas P. The clinical experience using the autologous vein graft-coated stent for the treatment of coronary artery disease. *Am J Cardiol*. 1997;80(suppl 7A):27S. Abstract.
  109. Toutouzas K, Stefanadis C, Tsiamis E, Stratos C, Vlachopoulos C, Kallikazaros I, Vavuranakis M, Trikas A, Toutouzas P. Primary autologous vein graft-coated stent in acute myocardial infarction: immediate and short-term results. *Circulation*. 1996;94(suppl I):I-576. Abstract.
  110. Toutouzas K, Stefanadis C, Tsiamis E, Vlachopoulos C, Stratos C, Kallikazaros I, Toutouzas P. Stents coated by an autologous arterial graft: the first application in human coronary arteries. *J Am Coll Cardiol*. 1983;31(suppl A):351A. Abstract.
  111. Tsiamis E, Stefanadis C, Toutouzas K, Vlachopoulos C, Giatrakos N, Vavuranakis M, Sideris A, Toutouzas P. Autologous arterial graft-coated stent implantation in diseased saphenous by-pass grafts: immediate results and mid-term outcome. *Eur Heart J*. 1997;18(suppl):154. Abstract.
  112. Stefanadis C, Toutouzas K, Tsiamis E, Vlachopoulos C, Vavuranakis M, Giatrakos N, Toutouzas P. Preliminary results by using the autologous arterial graft-coated stent for the treatment of coronary artery disease. *Eur Heart J*. 1997;18(suppl):154. Abstract.
  113. Friedman M, Felton L, Byers S. The antiatherogenic effect of iridium-192 upon the cholesterol-fed rabbit. *J Clin Invest*. 1964;43:185–192.
  114. Liermann D, Bottcher HD, Kollath J, Schopohl B, Strassmann G, Strecker EP, Breddin KH. Prophylactic endovascular radiotherapy to prevent intimal hyperplasia after implantation in femoropopliteal arteries. *Cardiovasc Intervent Radiol*. 1994;17:12–16.
  115. Fischell TA, Kharma BK, Fischell DR, Loges PG, Coffey CW, Duggan DM, Naftilan AJ. Low-dose  $\beta$ -particle emission from “stent” wire results in complete, localized inhibition of smooth muscle proliferation. *Circulation*. 1994;90:2956–2963.
  116. Hehrlein C, Zimmerman M, Metz J, Fehsenfeld P, von Hodenberg E. Radioactive coronary stent implantation inhibits neointimal proliferation in non atherosclerotic rabbits. *Circulation*. 1993;88(suppl I):I-651. Abstract.
  117. Hehrlein C, Gollan C, Donges K, Metz J, Reissen R, Fehsenfeld P, von Hodenberg E, Kubler W. Low-dose radioactive endovascular stents prevent smooth muscle cell proliferation and neointimal hyperplasia in rabbits. *Circulation*. 1995;92:1570–1575.
  118. Laird JR, Carter AJ, Kufs WM, Hoopes TG, Farb A, Nott SH, Fischell RE, Fischell DR, Virmani R, Fischell TA. Inhibition of neointimal proliferation with low-dose irradiation from a  $\beta$ -particle-emitting stent. *Circulation*. 1996;93:529–536.
  119. Hehrlein C, Stintz M, Kinscherf R, Huttel E, Friedrich L, Fehsenfeld P, Kubler W. Pure  $\beta$ -particle-emitting stents inhibit neointima formation in rabbits. *Circulation*. 1996;93:641–645.
  120. Fischell TA, Carter AJ, Laird JR. The  $\beta$ -particle-emitting radioisotope stent (Isostent): animal studies and planned clinical trials. *Am J Cardiol*. 1996;78(suppl 3A):45–50.
  121. Carter AJ, Laird JR, Bailey LR, Hoopes TG, Farb A, Fischell DR, Fischell RE, Fischell TA, Virmani R. Effects of endovascular radiation from a  $\beta$ -particle-emitting stent in a porcine restenosis model: a dose-response study. *Circulation*. 1996;94:2364–2368.
  122. Rivard A, Leclerc G, Bouchard M, Beaudoin G, Carrier R, Janicki C, Roorda S. Low-dose  $\beta$ -emitting radioactive stents inhibit neointimal hyperplasia in porcine coronary arteries: an histological assessment. *J Am Coll Cardiol*. 1997;29(suppl A):238A. Abstract.
  123. Eigler N, Whiting J, Makkar R, Li A, DeFrance A, Frimerman A, Fishbein MC, Litvack F. Effects of  $\beta^+$  emitting  $V^{48}$  Act-One nitinol stents on neointimal proliferation in pig coronary arteries. *J Am Coll Cardiol*. 1997;29(suppl A):237A. Abstract.
  124. Chronos NAF, Robinson KA, Kelly AB, Taylor A, Yianni J, King SB III, Harker LA, Hanson SR. Thromboresistant phosphorylcholine coatings for coronary stents. *Circulation*. 1995;92(suppl I):I-685. Abstract.
  125. Beusekom HMM, Whelan DM, Krabbendam SC, Vliet EA, Staal EE, Bac D, Serruys PW, Giesen WJ. Biocompatibility of phosphorylcholine coated stents in a porcine coronary model. *Circulation*. 1998;96(suppl):I-289. Abstract.
  126. De Scheerder IK, Wilczek K, Verbeken E, Van Dorpe J, Lan PN, Schacht EH, Piessens JH, De Geest H. Amphiphilic polyurethane coating of intracoronary stents decreases mortality due to subacute thrombosis in porcine coronary model. *J Am Coll Cardiol*. 1994;23(suppl):186A. Abstract.
  127. Holmes DR, Camrud AR, Jorgenson MA, Edwards WD, Schwartz RS. Polymeric stenting in the porcine coronary artery model: differential outcome of exogenous fibrin sleeves versus polyurethane-coated stents. *J Am Coll Cardiol*. 1994;24:525–531.
  128. Rechavia E, Litvack F, Fishbein MC, Eigler N. Biocompatibility of polyurethane coated stents: tissue and vascular aspects. *Am J Cardiol*. 1997;80(suppl 7A):31S. Abstract.
  129. Sheth S, Dev V, Jacobs H, Forrester JS, Litvack F, Eigler N. Prevention of subacute stent thrombosis by polymer-polyethylene oxide-heparin coating in the rabbit carotid artery. *J Am Coll Cardiol*. 1995;25(suppl):348A. Abstract.
  130. Staab ME, Holmes DR Jr, Schwartz RS. Polymers. In: Sigwart U, ed. *Endoluminal Stenting*. London, UK: WB Saunders; 1996:34–44.
  131. Cox DA, Anderson PG, Roubin GS, Chou CY, Agrawal SK, Cavender JB. Effects of local delivery of heparin and methotrexate on neointimal proliferation in stented porcine coronary arteries. *Coron Artery Dis*. 1992;3:237–248.
  132. Slepian MJ, Roth L, Wesselcouch E, Massia S, Khosravi F. Gel paving of intra arterial stents: a method for reducing stent and adjacent arterial wall thrombogenicity. *J Invas Cardiol*. 1995;7:5A. Abstract.
  133. Schwartz RS, Murphy JG, Edwards WD, Holmes DR. Bioabsorbable, drug eluting, intracoronary stents: design and future applications. In: Sigwart U, Frank GI eds. *Coronary Stents*. Berlin, Germany: Springer-Verlag; 1992:135–154.
  134. van Beusekom HMM, van Vleit HHDM, van der Giessen WJ. Fibrin and basement membrane components, as a biocompatible and thromboresistant coating for metal stents. *Circulation*. 1993;88(suppl I):I-645. Abstract.
  135. Bailey SR, Paige S, Lunn A, Palmaz J. Heparin coating of endovascular stents decreases subacute thrombosis in a rabbit model. *Circulation*. 1992;86(suppl I):I-186. Abstract.
  136. van der Giessen WJ, Hårdhammar PA, van Beusekom HMM, Emanuelsson HU, Tang ZH, Verdouw PD, Serruys PW. Prevention of (sub)acute thrombosis using heparin-coated stents. *Circulation*. 1994;90(suppl I):I-650. Abstract.
  137. Hårdhammar PA, van Beusekom HMM, Emanuelsson HU, Hofma SH, Albertsson PA, Verdouw PD, Boersma E, Serruys PW. Reduction in thrombotic events with heparin-coated Palmaz-Schatz stents in normal porcine coronary arteries. *Circulation*. 1996;93:423–430.
  138. Kipshidze N, Baker JE, Nikolaychik V. Fibrin coated stents as an improved vehicle for endothelial cell seeding. *Circulation*. 1994;90(suppl I):I-597. Abstract.

139. Baker JE, Horn JB, Nikolaychik V, Kipshidze NN. Fibrin stent coatings. In: Sigwart U ed. *Endoluminal Stenting*. London, UK: WB Saunders; 1996:84–89.
140. Aggarwal RK, Martin W, Ireland DC, Azrin MA, de Bono DP, Gershlick AH. Effects of polymer-coated stents eluting antibody to platelet integrin glycoprotein IIb/IIIa on platelet deposition and neointima formation. *Eur Heart J*. 1996;17(suppl):176. Abstract.
141. Aggarwal RK, Martin WA, Azrin MA, Ezekowitz MD, de Bono DP, Gershlick AH. Effects of platelet GPIIb/IIIa antibody and antibody-urokinase conjugate adsorbed to stents on platelet deposition and neointima formation. *Circulation*. 1996;94(suppl I):I-258. Abstract.
142. Aggarwal RK, Ireland DC, Ragheb A, de Bono DP, Gershlick AH. Reduction in thrombogenicity of polymer-coated stents by immobilization of platelet-targeted urokinase. *Eur Heart J*. 1996;17(suppl):177. Abstract.
143. Larm O, Larsson R, Olsson P. A new non-thrombogenic surface prepared by selective covalent binding of heparin via a reducing terminal residue. *Biomater Med Devices Artif Organs*. 1983;11:161–174.
144. Vrolix MC, Grolier G, Legrand V, Brunel P, Schaliq MJ, Martinez-Elbal, Bertrand M, Bär F, Colombo A, Brachmann J. Heparin-coated wire coil (Wiktor) for elective stent placement: the MENTOR Trial. *Eur Heart J*. 1997;18(suppl):152. Abstract.
145. Hardhammar PA, van Beusekom HMM, Emanuelsson HU, Hofma SH, Albertsson PA, Verdouw PD, Boersma E, Serruys PW, van der Giessen WJ. Reduction in thrombotic events with heparin-coated Palmaz-Schatz stents in normal porcine coronary arteries. *Circulation*. 1996;93:423–430.
146. Serruys PW, Emanuelsson H, van der Giessen W, Lunn AC, Kiemeny F, Macaya C, Rutsch W, Heyndrickx G, Suryapranata H, Legrand V, Goy JJ, Materne P, Bonnier H, Morice MC, Fajadet J, Belardi J, Colombo A, Garcia E, Ruygrok P, de Jaegere P, Morel MA, on behalf of the BENESTENT II Study Group. Heparin-coated Palmaz-Schatz stents in human coronary arteries: early outcome of the BENESTENT II Pilot Study. *Circulation*. 1996;93:412–422.
147. Legrand V, Serruys PW, Emanuelsson H, Fajadet J, Haude M, Klugmann S, Bär F, Fernández-Avilés F, Suryapranata H, Morel MA. BENESTENT-II Trial: final results of visit I: a 15-day follow-up. *J Am Coll Cardiol*. 1997;29(suppl A):170A. Abstract.
148. Colombo A. Use of a second-generation flexible stent in small vessels and bifurcation lesions. Data presented at the XVIIIth Congress of the European Society of Cardiology, Birmingham, UK, August 25, 1996.
149. Garratt K, O'Shaughnessy CD, Leon MB, Fry ETA, Dean LS, Keriakes DJ, Voorhees WD, on behalf of the GR II™ Clinical Investigators. Improved early outcomes after coronary stent placement for abrupt or threatened closure: results of a multicenter trial using second generation stents. *Eur Heart J*. 1997;18(suppl):388. Abstract.
150. O'Shaughnessy CD, Popma JJ, Dean LS, Leon MB, Fry ETA, Carrozza JP, Knopf WD, Keriakes DJ, George BS, Thompson MA, Brinker JA, Raizner AE, Leon MB. The new Gianturco-Roubin coronary stent is an improved therapy for abrupt and threatened closure syndrome. *J Am Coll Cardiol*. 1997;29(suppl A):416A–417A. Abstract.
151. Leon MB, Fry ETA, O'Shaughnessy CD, Yakubov SJ, Carrozza JP, Keriakes DJ, Popma JJ, Warth DC, Thompson MA, Rogers EW, Dean LS, Pinkerton C. Preliminary multicenter experiences with the new GR-II stent for abrupt and threatened closure syndrome. *Circulation*. 1996;94(suppl I):I-207. Abstract.
152. McKenna CJ, Camrud AR, Wolff R, Edwards WD, Holmes DR, Schwartz RS. Evaluation of the biocompatibility and safety of fibrin-film stenting up to one year post deployment in a porcine coronary injury model. *Am J Cardiol*. 1997;80(suppl 7A):155. Abstract.
153. Slepian MJ, Khosravi F, Massia SP, Kieras M, Khera GS, Hubbell JA. Gel paving of intraarterial stents in vivo reduces stent and adjacent arterial wall thrombogenicity. *J Vasc Interv Radiol*. 1995;6:50. Abstract.
154. Alt E, Beilharz C, Preter D, Schmidmaier G, Pasquantonio J, Erhard W, Stemberger A, Schömig A. Biodegradable stent coating with polylactic acid, hirudin and prostacyclin reduces restenosis. *J Am Coll Cardiol*. 1997;29(suppl A):238A. Abstract.
155. Schmidmaier G, Stemberger A, Alt E, Gawaz M, Neumann F-J, Schömig A. A new biodegradable polylactic acid coronary stent-coating, releasing PEG-hirudin and a prostacycline analog, reduces both platelet activation and plasmatic coagulation. *J Am Coll Cardiol*. 1997;29(suppl A):354A. Abstract.
156. Schmidmaier G, Stemberger A, Alt E, Gawaz M, Schömig A. Non-linear time release characteristics of a biodegradable polylactic acid coating releasing PEG hirudin and a PG12 analog. *Eur Heart J*. 1997;18(suppl):571. Abstract.
157. Aggrawal RK, Ireland DC, Azrin MA, Ezekowitz MD, de Bono DP, Gershlick AH. Antithrombotic potential of polymer-coated stents eluting platelet glycoprotein IIb/IIIa receptor antibody. *Circulation*. 1996;94:3311–3317.
158. Baron JH, Aggrawal R, de Bono D, Gershlick AH. Adsorption and elution of c7E3 Fab from polymer-coated stents in-vitro. *Eur Heart J*. 1997;18(suppl):503. Abstract.
159. Simons M, Rosenberg RD. Antisense nonmuscle myosin heavy chain and *c-myb* oligonucleotides suppress smooth muscle cell proliferation in vitro. *Circ Res*. 1992;70:835–843.
160. Simons M, Edelman ER, DeKeyser JL, Langer R, Rosenberg RD. Antisense *c-myb* oligonucleotides inhibit intimal arterial smooth muscle cell accumulation in vivo. *Nature*. 1992;359:67–70.
161. Gammon RS, Chapman GD, Agrawal GM, Bauman RP, Phillips HR, Clark HG, Stack RS. Mechanical features of the Duke biodegradable intravascular stent. *J Am Coll Cardiol*. 1991;17(suppl):235A. Abstract.
162. Labinaz M, Zidar JP, Stack RS, Phillips HR. Biodegradable stents: the future of interventional cardiology? *J Intervent Cardiol*. 1995;8:395–405.
163. van der Giessen WJ, Serruys PW, Visser WJ, Verdouw PD, van Schalkwijk WP, Jongkind JF. Endothelialization of intravascular stents. *J Intervent Cardiol*. 1988;1:109–120.
164. Dichek DA, Neville RF, Zwiebel JA, Freeman SM, Leon MB, Anderson WF. Seeding of intravascular stents with genetically engineered endothelial cells. *Circulation*. 1989;80:1347–1353.
165. Flugelman MY, Virmani R, Leon MB, Bowman RL, Dichek DA. Genetically engineered endothelial cells remain adherent and viable after stent deployment and exposure to flow in vitro. *Circ Res*. 1992;70:348–354.
166. Flugelman MY, Rome JJ, Virmani R, Neuman KD, Dichek DA. Detection of genetically engineered endothelial cells seeded on endovascular prosthesis ten days after in vivo deployment. *J Mol Cell Cardiol*. 1993;25(suppl I):S-83. Abstract.
167. Scott NA, Candal FJ, Robinson KA, Ades EW. Seeding of intracoronary stents with immortalized human microvascular endothelial cells. *Am Heart J*. 1995;129:860–866.
168. Malekan R, Reynolds C, Kelley S, Suzuki Y, Bridges C. Angiogenesis in transmural revascularization: a nonspecific response to injury. *Circulation*. 1997;96(suppl I):I-564. Abstract.
169. Yamamoto N, Kohmoto T, Gu A, Derosa C, Smith CR, Burkhoff D. Transmural revascularization enhances angiogenesis in a canine model of chronic ischemia. *Circulation*. 1997;96(suppl I):I-563. Abstract.
170. Kohmoto T, Fisher P, DeRosa C, Smith C, Burkhoff D. Evidence of angiogenesis in regions treated with transmural laser revascularization. *Circulation*. 1996;94(suppl I):I-294. Abstract.
171. Isner JM, Walsh K, Symes J, Pieczek A, Takeshita S, Lowry J, Rossow S, Rosenfield K, Weir L, Brogi E. Arterial gene therapy for therapeutic angiogenesis in patients with peripheral artery disease. *Circulation*. 1995;91:2687–2692.
172. Isner JM, Pieczek A, Schainfeld R, Blair R, Haley L, Asahara T, Rosenfield K, Razvi S, Walsh K, Symes JF. Clinical evidence of angiogenesis after arterial gene transfer of phVEGF165 in patient with ischemic limb. *Lancet*. 1996;348:370–374.
173. Schumacher B, Pecher P, von Specht BU, Stegmann TH. Induction of neoangiogenesis in ischemic myocardium by human growth factors. *Circulation*. 1998;97:645–650.
174. Winslow R. Test begins on gene therapy for clogged arteries. *Wall Street Journal*. New York, NY: 1998; January 6.
175. Mack CA, Patel SR, Schwarz EA, Zanzonico P, Hahn RT, Ilterci A, Devereux RB, Goldsmith SJ, Christian TF, Sanborn TA, Koveshi I, Hackett N, Isom OW, Crystal RG, Rosengart TK. Biologic bypass with the use of adenovirus-mediated gene transfer of the complementary deoxyribonucleic acid for vascular endothelial growth factor 121 improves myocardial perfusion and function in the ischemic porcine heart. *J Thorac Cardiovasc Surg*. 1998;115:168–177.
176. Henry TD, Rocha-Singh K, Isner JM, Kereiakes DJ, Giordano FJ, Simons M, Losordo DW, Hendel RC, Bonow RO, Rothman JM, Borbas ER, McCluskey ER. Results of intracoronary recombinant human vascular endothelial growth factor (rhVEGF) administration trial. *J Am Coll Cardiol*. 1998;31(suppl A):65A. Abstract.
177. Laham RJ, Sellke FW, Edelman ER, Pearlman JD, Simons M. Local perivascular basic fibroblast growth factor (bFGF) treatment in patients



- with ischemic heart disease. *J Am Coll Cardiol*. 1998;31(suppl A):394A. Abstract.
178. Folkman J. Angiogenic therapy of the human heart. *Circulation*. 1998; 97:628–629.
  179. Horvath KA, Mannting F, Cummings N, Shernan SK, Cohn LH. Transmyocardial laser revascularization: operative techniques and clinical results at two years. *J Thorac Cardiovasc Surg*. 1996;111: 1047–1053.
  180. Cooley DA, Frazier OH, Kadipasaoglu KA, Lindenmeir MH, Pehlivanoglu S, Kolff JW, Wilansky S, Moore WH. Transmyocardial laser revascularization: clinical experience with twelve-month follow-up. *J Thorac Cardiovasc Surg*. 1996;111:791–797.
  181. Jeevanandam V, Auteri J, Oz M, Watkins J, Rose E, Smith C. Myocardial revascularization by laser-induced channels. *Surg Forum*. 1991; 41:225–227.
  182. Saurbier B, Geibel A, Gabelmann M, Schaefer M, Wagner I, Lutter G, Spillner G, Kletzin F, Beyersdorf F, Just H. Transmyocardial laser revascularization: echocardiographic findings and results. *Circulation*. 1997;96(suppl I):I-246. Abstract.
  183. Mirhoseini M, Cayton MM, Shelgikar S, Fisher JC. Laser myocardial revascularization. *Lasers Surg Med*. 1986;6:459–461.
  184. Dowling R, Patracek M, Sellinger S, Allen K. Transmyocardial revascularization with a holmium laser in patients with refractory angina who are unstable. *Circulation*. 1997;96(suppl I):I-247. Abstract.
  185. Cooley DA, Frazier OH, Kadipasaoglu KA, Pehlivanoglu S, Shannon RL, Angelini P. Transmyocardial laser revascularization: anatomic evidence of long-term channel patency. *Tex Heart Inst J*. 1994;21: 220–224.
  186. Horvath KA, Cohn LH, Cooley DA, Crew JR, Frazier OH, Griffith BP, Kadipasaoglu K, Lansing A, Mannting F, March R, Mirhoseini MR, Smith C. Transmyocardial laser revascularization: results of a multi-center trial with transmyocardial laser revascularization used as sole therapy for end-stage coronary artery disease. *J Thorac Cardiovasc Surg*. 1997;113:645–653; discussion 653–654.
  187. Allen K, Fudge TS, Dowling R. Prospective Randomized Multicenter Trial of Transmyocardial Revascularization versus Maximal Medical Management in Patients with Class IV Angina. *Circulation*. 1997; 96(suppl I):I-564. Abstract.
  188. Fleischer KJ, Goldschmidt-Clermont PJ, Fonger JD, Hutchins GM, Hruban RH, Baumgartner WA. One-month histologic response of transmyocardial laser channels with molecular intervention. *Ann Thorac Surg*. 1996;62:1051–1058.
  189. Kwong K, Kanellopoulos G, Schuessler R, Saffitz J, Sundt T III. Endocardial laser treatment incompletely denervates canine myocardium. *Circulation*. 1997;96(suppl I):I-565. Abstract.
  190. Donoghue JA, Macioch JE, Neuman A, Soble JS, Liebson PR, March RJ. Transmyocardial laser revascularization increases dobutamine-induced angina threshold in patients with refractory angina. *J Am Coll Cardiol*. 1998;31(suppl A):226A. Abstract.
  191. Burns SM, Schofield PM, Rosen SD, Rimoldi O, Wistow TE, Camici PG. Measurement of myocardial blood flow using positron emission tomography before and after transmyocardial revascularization. *J Am Coll Cardiol*. 1998;31(suppl A):226A. Abstract.
  192. Malik FS, Mehra MR, Ali A, Ventura HO, Stapleton DD, Ochsner JL, Smart FW. The impact of laser transmyocardial revascularization on indices of ventricular repolarization. *J Am Coll Cardiol*. 1998;31(suppl A):226A. Abstract.
  193. Shawl FA, Kaul U, Singh B, Rigali G. Percutaneous transluminal myocardial revascularization (PTMR): procedural results and early clinical outcome. *J Am Coll Cardiol*. 1998;31(suppl A):223A. Abstract.
  194. Knopf W, Londero H, Kaul U, O'Neill W, Shawl FA. Feasibility study of percutaneous transluminal myocardial revascularization (PTMR) with a holmium laser and fiberoptic delivery system. *J Am Coll Cardiol*. 1998;31(suppl A):235A. Abstract.
  195. Ben-Haim SA, Osadchy D, Schuster I, Gepstein L, Hayam G, Josephson ME. Nonfluoroscopic, in vivo navigation and mapping technology. *Nat Med*. 1996;2:1393–1395.
  196. Gepstein L, Hayam G, Ben-Haim SA. A novel method for nonfluoroscopic catheter-based electroanatomical mapping of the heart: in vitro and in vivo accuracy results. *Circulation*. 1997;95:1611–1622.
  197. Altman LK. Injectable heart drug grows blood vessels. *The New York Times*. February 24, 1998, section F, page 7.
  198. L'Heureux N, Paquet S, Labbe R, German L, Auger FA. A completely biological tissue-engineered human blood vessel. *FASEB J*. 1998;12: 47–56.

---

KEY WORDS: revascularization ■ stents ■ platelets ■ restenosis ■ angiogenesis