

# RECENT ADVANCES IN FLEXOR TENDON REPAIR<sup>1</sup>

by

DR. J. C. VANDER MEULEN<sup>2</sup>

The prognosis for restoration of good function after the treatment of a tendon lesion in 'no-man's land' is influenced by a number of factors which may be summarized as follows:

- The nature of the injury.
- The amplitude of the tendon excursion.
- The motility of the hand.
- The age of the patient.
- The rehabilitation of the patient.

Excellent results may usually be achieved when the preoperative conditions are favourable. Unsatisfactory results usually follow when:

- the neurovascular bundles are injured and the posterior wall of the tendon sheath is damaged,
- the amplitude of excursion of the divided tendon is large,
- the skin of the hand is thick and tough,
- the patient is more than 20 years old,
- the rehabilitation of the patient is insufficient.

In our department the number of patients sent for treatment who fulfil all the requirements for the achievement of satisfactory results is relatively small compared with the number of patients who do not fulfil these requirements.

Dissatisfaction with the results of treatment when we followed conventional procedures in the latter group of patients and the conviction that a surgical result although poor by objective criteria may well be of importance when evaluated by subjective criteria (Fig. 1) brought us to analyse our problems connected with tendon surgery in general and caused us to look for a possible solution to the problems we were faced with especially in the group of patients with a bad prognosis any way.

Because the fact that good results are difficult to achieve in the treatment of tendon lesions is largely due to the process of healing, the following factors must be discussed:

- the anatomy of the tendon, its blood supply and the tissues surrounding it,
- the capacity for healing of these structures,
- the possible methods of tendon repair.

<sup>1</sup>Submitted for publication August 1970

<sup>2</sup>From the Department of Plastic Surgery, Academic Hospital Dijkzigt, Rotterdam, The Netherlands.

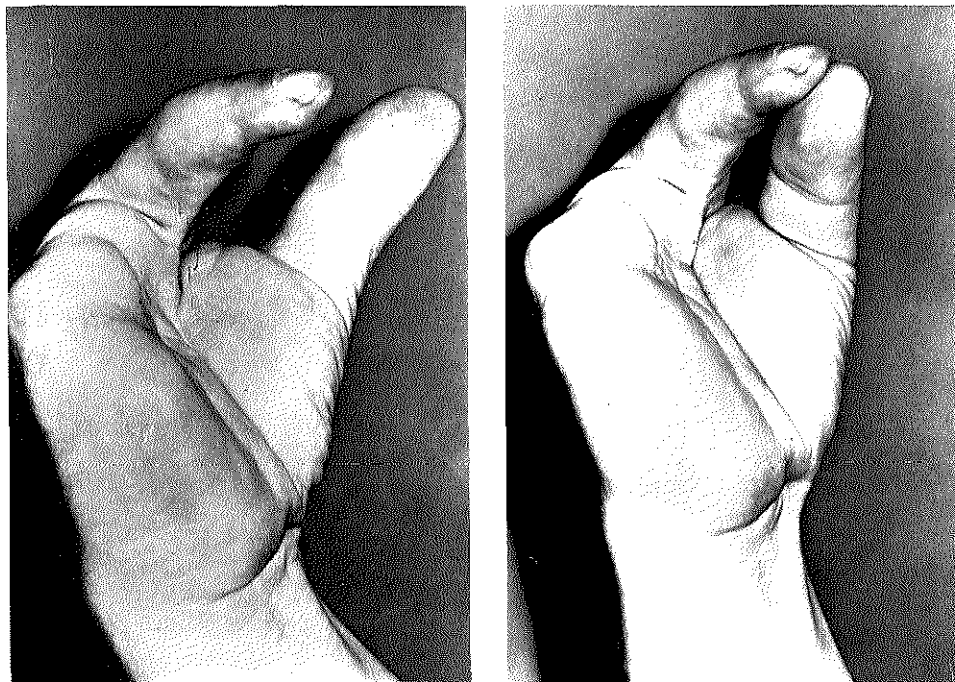


Fig. 1. Severely mutilated hand after tendon grafting of the index finger. a. objectively: a poor result, b. subjectively: a satisfactory result.

## ANATOMY

### 1. *The Tendon*

The structure of a tendon is built up of 3 parts: (Fig. 4)

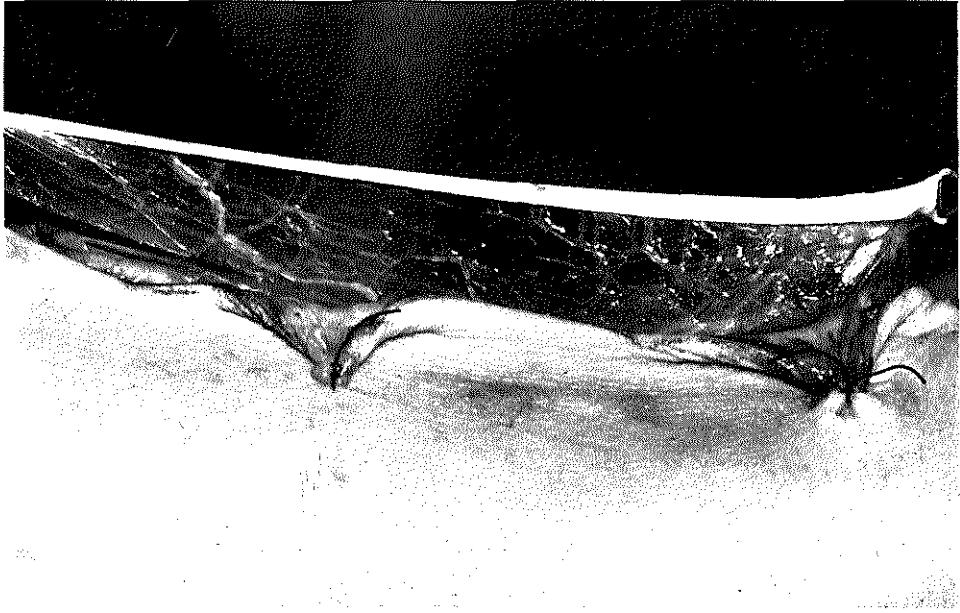
- a. the collagen fibres which contain 3 separate elements: collagen, the groundsubstrate and fibroblasts,
- b. the endotenon which divides the tendon into bundles,
- c. the epitenon which holds the bundles together.

### 2. *The blood circulatory system*

The blood supply of the tendon stems from 3 sources:

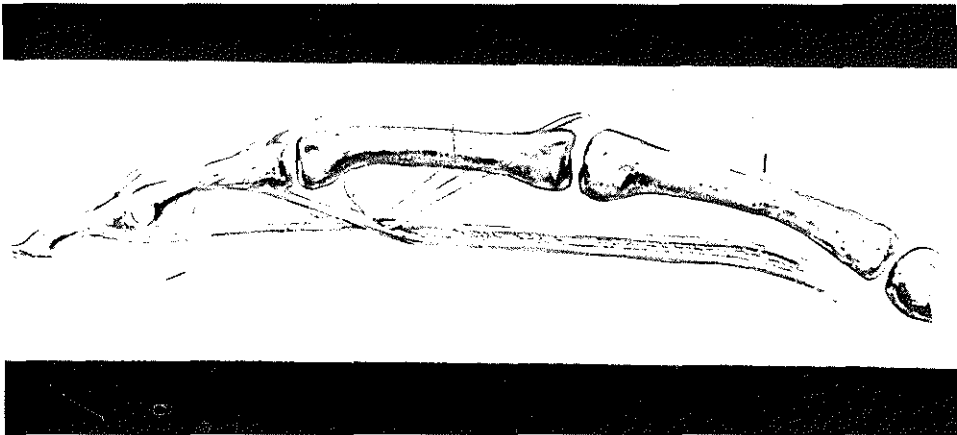
- a. the mesotenon,
- b. the muscular origin of the tendon,
- c. the periosteal insertion of the tendon.

The mesotenon is of paramount importance to the adequate circulation of blood in the tendon sheath. It can be compared to the mesentery of the intestines (Fig. 2). Inside the tendon sheath the mesotenon is condensed into vincula (Fig. 3).



*Fig. 2.* Mesotenon of palmaris tendon.

The muscular origin of the tendon and the periosteal insertion of the tendon are of comparatively little value to the blood circulation in the tendon. PEACOCK observed that blood circulation in tendons is impossible over distances longer than  $1/3$  of their length, Smith found 1–2 cm to be the limit for this. A tendon freed from its bed must therefore be considered to be a graft.



*Fig. 3.* In the finger the mesotenon is condensed into vincula.

### 3. *The peritendinous tissues*

The nature of these depends on the absence or on the presence of a tendon sheath. (Fig. 4).

- in its absence the tendon is surrounded by paratenon,
- in its presence by synovia.

No vascular connections between the paratenon and the tendon or the synovia and tendon exist.

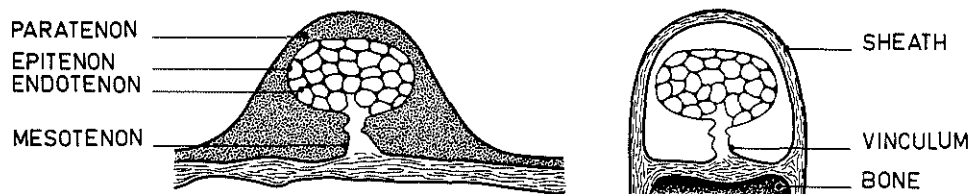


Fig. 4. Different nature of structures surrounding the tendon.

## PROCESS OF HEALING

Considering the healing capacity of the structures involved, we are lucky that any reasonable restoration of function is ever possible at all. A discussion of the role of these structures in the process of healing will illustrate this.

### 1. *The role of the tendon*

We know that healing of a tendon takes place by an invasion of fibroblasts from the surrounding tissues.

POTENZA proved that atraumatic suturing of the tendons within their sheath was followed by a disintegration of the synovia and the formation of granulation tissue. This tissue invades the tendon at those places where the surface of it is wounded. It forms new collagen and repairs the continuity of the tendon. As soon as this scar tissue matures, the adhesions become looser and the integrity of the sheath is repaired.

Potenza also observed that when contact between the tendon and its sheath is made impossible by the introduction of poly-ethylene tubes or millipore, healing of the tendon wound will be postponed, until granulation tissue has invaded the tube from its end and has reached the wound along the surface of the tendon.

However, trauma is not always restricted to a loss of continuity, circulatory loss may also occur and the consequences of deprivation of the blood supply from the tendon force us to study the role of the blood circulation of a tendon during the process of healing.

### 2. *The role of the blood circulatory system of the tendon*

Any evaluation of the role played by this system calls for an answer to three questions:

- a. what is the fate of a tendon deprived of its circulation?

- b. does a tendon graft have the capacity to survive?
- c. how does it survive?

Ad. a. The answer to the first question was given by SKOOG and PERSSON. They blocked tendon grafts with stainless steel foil and observed that such a procedure results in degeneration and death of the tendon, an observation which was later confirmed by Potenza's work.

Ad. b. The answer to the second question seems to be positive. BIRDSELL and collaborators measured the production of collagen in the centre of a tendon graft by the injection of tritium – labelled proline, which is almost exclusive to collagen tissue and is taken up at sites of collagen synthesis. Their observations suggest that the reaction of the graft is mild and that the tendon tissue is *not* being replaced per se.

The conclusion therefore might well be drawn that a tendon graft, as in the case of any other graft, is capable of survival only provided the ambient conditions are favourable.

Ad. c. The answer to the third question must be twofold. PEACOCK has demonstrated that a tendon with its low metabolic requirements and respiratory rates is able to survive for a short term by the diffusion of gases and nutrients. For ultimate survival of the tendon graft, however, he regards the establishment of vascular connections between the tendon graft and the surrounding tissues to be quite indispensable.

BRAITHWAITE and BROCKIS have long ago shown us that a restoration of the tendon circulation indeed takes place. 'In our case in which a graft had been implanted after resection of the sheath revascularisation had taken place by means of vascular connections with the surrounding tissues'.

SMITH and CONWAY have given us valuable information concerning the revascularisation of a tendon by three series of experiments in which no resection of the sheath was carried out:

In the first series: – tendons were transplanted together with their paratenon and mesotenon,

In the second series: – tendons were transplanted without their paratenon and mesotenon,

In the third series: – tendons were transplanted without their paratenon and with their mesotenon.

Though these observations, obtained by injection of the blood vessels and newly formed blood vessels, make it clear that the circulation of a tendon is indeed restored via the insertion of the mesotenon, they do not give any information as to the source of this revascularisation.

SMITH and CONWAY assume that it is achieved by capillary ingrowths from outside the sheath of the tendon and by remnants of the vincula inside the sheath. They are probably right but if the tendon sheath does not contribute itself to this revascularisation what then is its role in the process of healing?

### 3. *The role of the peritendinous tissues*

Peacock has often stated that the capacity that an intact tendon sheath has for producing collagen is very limited.

LINDSAY and BIRCH studied the site of origin and route of migration of fibroblasts

in tendon healing by the injection of tritiated thymidine. Fibroblast migration appeared to take place across a bridge formed by the merging of the tendon and its sheath in the region of areas of inflammation. Merging however did not occur at the central portion of the graft. These observations justify the conclusion that the role of an intact sheath in the process of healing is – essentially – a passive one. They also indicate that the formation of adhesions between the tendon and the sheath is either caused by an injury which allows granulation tissue to enter or – and this is just a suggestion – by degeneration and the subsequent death of the tendon itself. It seems that nature confronts us with a problem which it is impossible to solve by technical means alone for the simple reason that: We want to restore the circulation of a tendon, and at the same time we want to prevent adhesions from forming. As always we cannot have our cake and eat it.

Nevertheless, the restoration of good function is our primary goal and over the years a number of methods have been developed to help us to reach it.

#### METHODS OF REPAIR

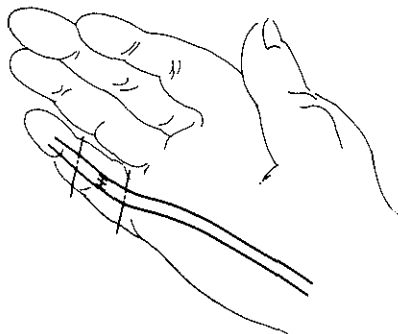
In a discussion about the methods of repair, a distinction should be made between:

1. The restoration of the continuity of the tendon.
2. The restoration of the continuity of the vascular structures.
3. The restoration of the continuity of the tendon sheath.

Ad. 1 Restoration of the continuity of the tendon – inside ‘no-man’s-land’ – can be achieved in four ways by:

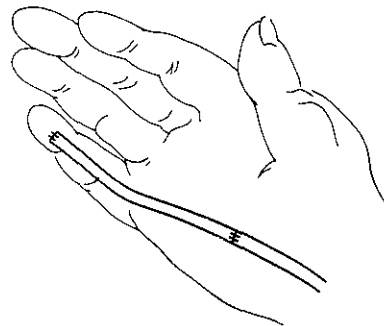
1. Tendon suture (Fig. 5)
2. Tendon transplantation (Fig. 6)
3. Tendon transposition (Fig. 7)
4. Tendon plasty (Fig. 8)

However the results of the treatment will always depend on the nature of the adhesion formation, whether this takes place in the finger or in the palm of the hand, and



tendon suture

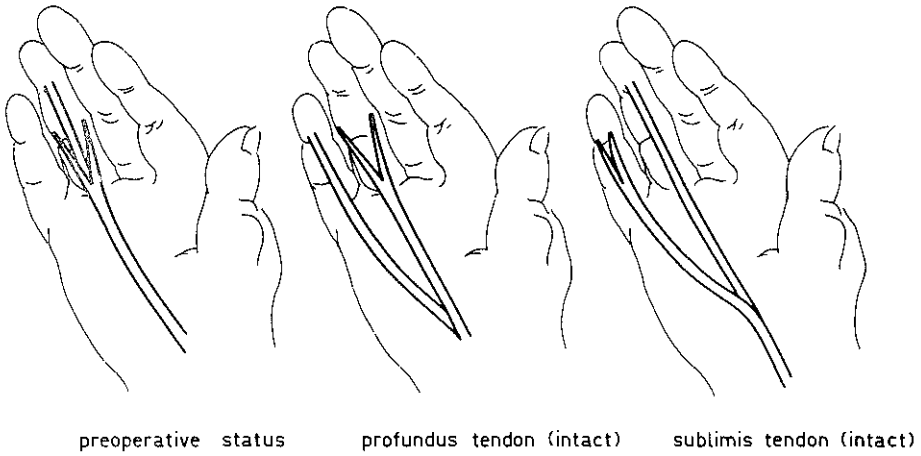
*Fig. 5.* Tendon suture.



tendon transplantation

*Fig. 6.* Tendon transplantation.

tendon transposition



tendon transposition

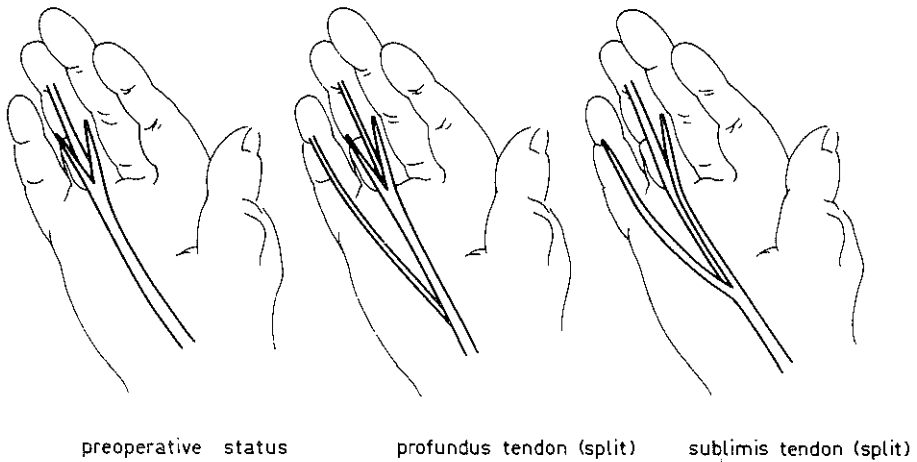
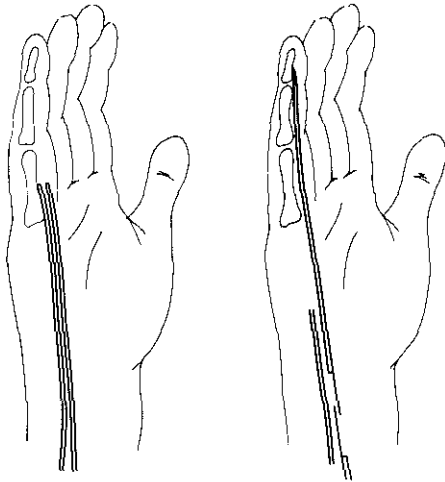


Fig. 7. Tendon transposition.

whether these adhesions are caused by the healing of the fibrous structures or the healing of the vascular structures. In the case of a tendon suture, adhesion formation remains limited to the actual region of the wound.

With a tendon transplantation, we find adhesion formation occurring in the finger as a result of the revascularisation of the graft, and in the palm of the hand as a result of the healing of the anastomosis. With a tendon transposition, the adhesion formation remains limited to that part of the tendon which has to be revascularized.



tendon plasty

Fig. 8. Tendon plasty.

With a tendon interposition, we find adhesion formation in the finger, the palm and in the wrist.

If the conditions for tendon repair are ideal – and this means a minimum of trauma to the neurovascular bundles and the tendon sheath – it is possible to achieve excellent results with the use of all methods.

However the prognosis becomes worse if the conditions are less ideal and in view of this fact it is not surprising that in recent years more attention has been given to the restoration of the continuity of the circulatory system and of the tendon sheath.

Ad. 2 Methods of restoring the continuity of the circulatory system.

- a. Preservation of the mesotenon of a tendon graft as suggested by SMITH and CONWAY.
- b. Resection of parts of the tendon sheath to bring the tendon into contact with more richly vascularized tissues.

These methods may promote the survival of a tendon graft but they do not in themselves increase the blood supply to the injured finger. Their influence on the prognosis of the tendon repair is still very much open to discussion.

Ad.3. Methods to restore the continuity of the tendon sheath. Two different methods are at our disposal:

1. Reconstruction of the sheath by the use of a slit silicone rubber tube. In this method, suggested by REIS, the tendon graft is ensheathed by a slit silicone rubber tube. Revascularization through the slit enables the tendon to survive. The tube is removed after a certain period.
2. Reconstruction of the sheath by the use of a silicone rubber 'rod'. The capacity of cell-poor tissue to form collagen is rather limited. Since the tendon sheath has a relatively small number of cells, the grafting of a tendon in an intact sheath would seem to offer advantages in the form of a collagen-poor adhesion formation with little



limitation of function. Attempts to induce tendon sheath formation by the implantation of artificial material were first made 3 decades ago.

MAYER (1940) used celloidine tubes and replaced these tubes after the formation of the new sheath by a tendon graft, but this material proved to be insufficiently inert.

CARROLL and BASSETT (1964) employed Silastic spacers, which they attached to the distal phalanx – they obtained very satisfactory results.

HUNTER (1965) utilized Silastic spacers reinforced with Mersilene. These spacers were attached not only to the distal phalanx but also to the proximal end of the tendon, which made active movement possible. In a number of patients these prostheses were removed after a certain period or time and replaced by an autologous graft.

GAISFORD (1966) used a technique similar to that used by CARROLL and BASSETT, and obtained satisfactory results in the treatment of 73 tendon injuries. NICOLLE (1969), like HUNTER, used reinforced spacers which he sutured to the proximal and distal stumps of the profundus tendon. The spacers were replaced after two to three months by an autogenous tendon graft. His experiments clearly showed that only minimal adhesions will be sufficient for the survival of a tendon graft and that maturation of these adhesions occurs more rapidly.

GELDMACHER (1969) demonstrated that the amount of traction required to pull a tendon graft out of a sheath induced by a Silastic spacer is 9 to 10 times lower than the amount required when such a spacer is not used.

GELDMACHER'S conclusion that the indications for tendon repair in the hand with the use of Silastic spacers for the induction of a new tendon sheath may well be appreciably extended, is entirely in agreement with our experience.

#### PERSONAL EXPERIENCE

In view of the advantages – attributed to the last method by some authors – it was decided to test its merits in a consecutive series of patients. No exception was made for patients with ideal pre-operative conditions. 25 tendon grafts were done in 24 patients. In 5 of the 24 patients the preoperative condition was ideal, in 19 of the 24 patients the pre-operative condition was non-ideal.

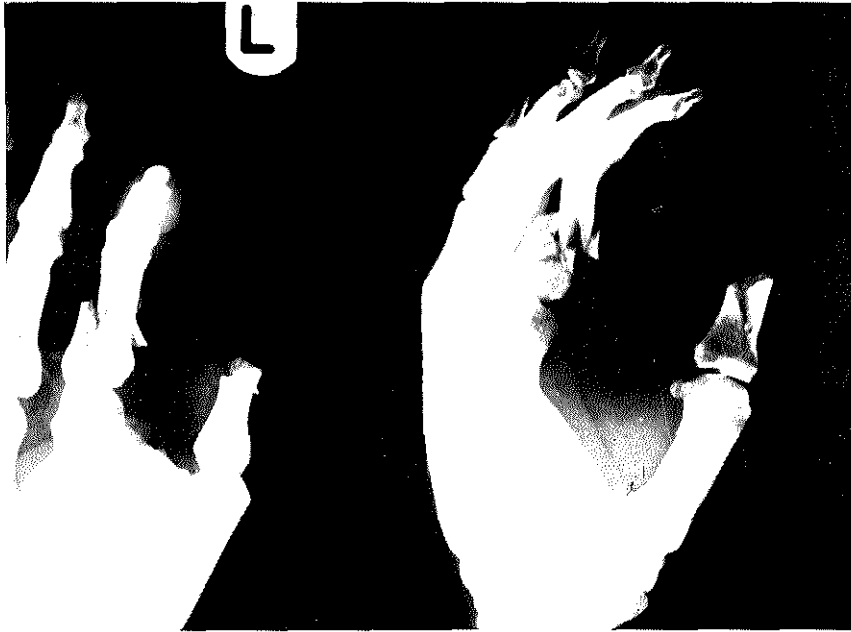In 2 of the 24 patients the Silastic spacer was introduced immediately after the accident as a primary procedure (Fig. 9).

One of the 24 patients was treated for an injury of both the index and middle fingers (Fig. 10).

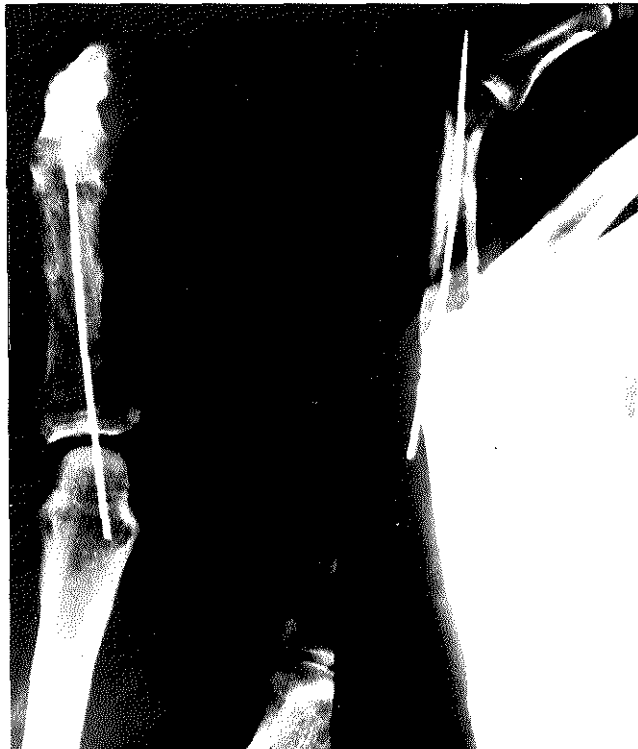#### TECHNIQUE

##### *First stage*

The skin incision is made in a Z-shaped fashion. Only as much of the tendon sheath is resected as is necessary to allow removal of the remnants of the sublimis and profundus tendons. When possible, the vincula at the level of the p.i.p. and d.i.p. joints are spared. A Silastic spacer with a diameter of 3 mm is then implanted and fixed at



*Fig. 9a*



*Fig. 9b*

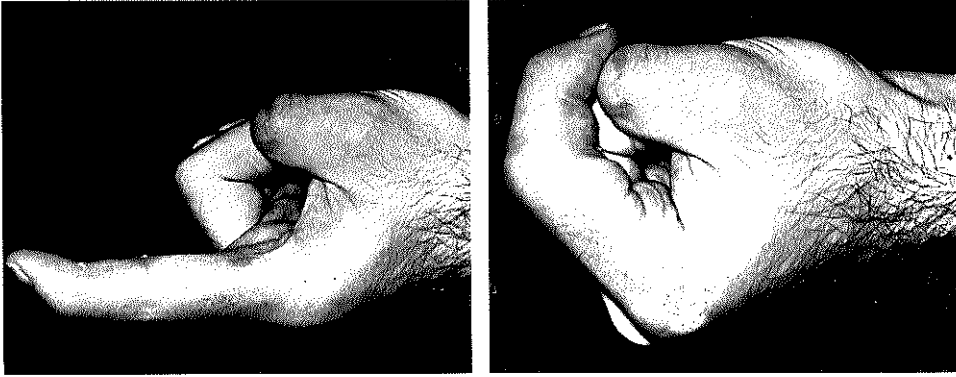


Fig. 9. Severe fracture and tendon lesion of index finger caused by circular saw: a. and b. primary immobilization of fracture with K. wire, and the implantation of 'Silastic' spacer. c. and d. satisfactory result after replacement with tendon graft.

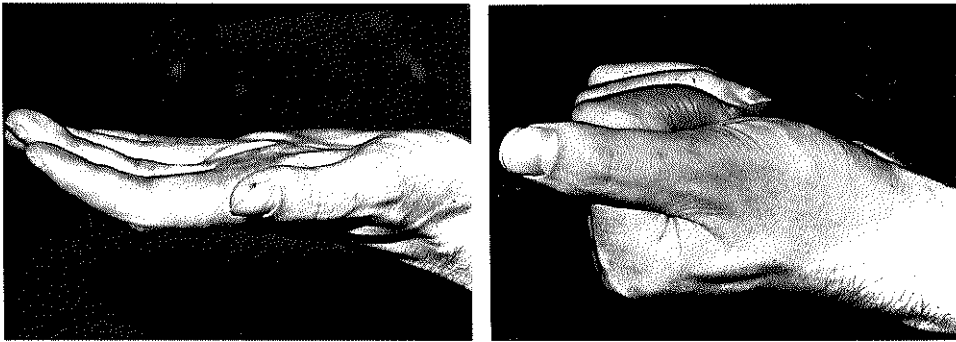


Fig. 10. a. severe tendon lesions of index and middle finger caused by circular saw, b. satisfactory result after replacement with tendon graft.

the level of the insertion of the profundus tendon by means of one or two wire sutures. The proximal end of the spacer is slid along the proximal stump of the profundus tendon until it overlaps the latter over a distance of several centimetres. Before the hand is closed, the *m. lumbricalis* is divided proximal to the lumbrical canal. This last step has been performed routinely by us for some time because we believe that restoration of the delicate paradoxal extension mechanism of this muscle is not to be expected and malfunction of this muscle will have an adverse effect on the restoration of the function of the flexor tendon. About a week after the operation, passive and active exercise is started.

#### *Second stage*

Two or three months after implantation of the Silastic spacer the new sheath is opened through the old scars in the palm of the hand and also through the integument

of the distal phalanx. The proximal end of the spacer is connected to the tendon graft, for which the palmaris longus tendon is used whenever feasible. The mesotenon of this graft is left intact, because the blood supply occurs via this structure (SMITH and CONWAY 1966, COLVILLE 1969). The tendon graft is drawn into the sheath by pulling out the spacer via the distal incision. Both the anastomoses and the terminal stages of the procedure are conventionally done.

## RESULTS

The information gained by an objective assessment of the results is necessarily restricted. Recovery of function depends on the absence of a series of pre-operative and postoperative conditions, which – each of them individually – may impede a potentially good result.

### PRE-OPERATIVE CONDITIONS

All of the 19 patients in which the pre-operative condition were non-ideal, had neuro-vascular disturbances caused by a lesion of one or both neuro-vascular bundles. Among these 19 patients there were 7 in whom the passive motility was less than normal, 4 in whom the tendon injury was complicated by an infection, 3 in whom previous attempts had been made to restore function, and 2 who required an improvement in the skin coverage.

### POST-OPERATIVE CONDITIONS

#### *1. Limitation of extension of the finger*

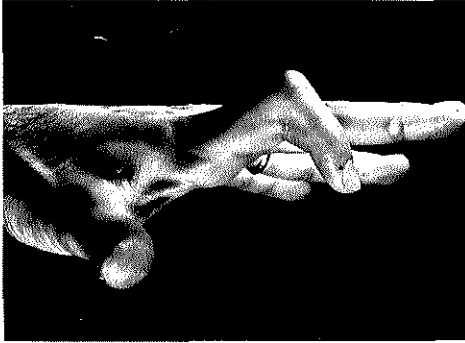
Postoperatively – for whatever reason – a strong flexion contracture may develop and may abolish the potential range of motion (Fig. 11).

#### *2. Collaps of the p.i.p. joint*

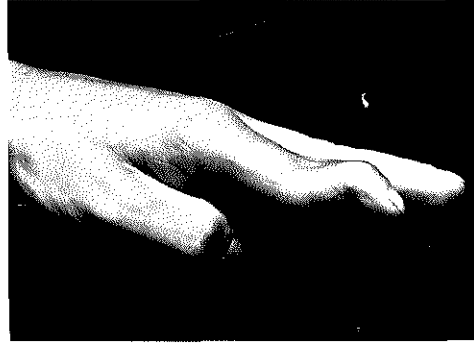When loss of the stabilizing function of the sublimis tendon is associated with a dislocation of the retinacular ligaments, an attempt to flex the d.i.p. joint will be accompanied by hyper-extension or collaps of the p.i.p. joint. A ‘Swan-neck’ deformity will be the result (Fig. 12).

#### *3. The lumbrical-plus phenomenon*

When the power exerted by the flexor muscle is not transmitted to the flexor tendon but rather – by traction via the m. lumbricalis – to the extension apparatus of the finger, a short-circuit mechanism develops. An attempt to flex the finger will then result in extension. We believe this phenomenon, which was recently analyzed by Athol Parkes, to be rather common. For that reason we divide the lumbrical muscle as a routine in tendon graft procedures.



*Fig. 11.* A severe flexion contracture of the p.i.p.-joint of the index finger occurring after the replacement of a 'Silastic' spacer by a tendon graft made amputation necessary. Dissection of the amputated finger revealed that the tendon graft was surrounded by loose adhesions. The range of motion was however severely restricted due to the massive fibrosis outside the newly formed tendon sheath.



*Fig. 12.* Swan-neck deformity.

#### 4. Blocking

The potential range of motion of the flexor tendon in the reconstruction sheath also cannot be realized when the range of motion of the proximal anastomosis is limited by intensive scarring within the palm of the hand. In our group of patients more than once it was noted that the reproduction of smooth tendon gliding was faster in the finger than in the palm of the hand (Fig. 13).

In view of the multitude of factors influencing the prognosis of tendon repair and our difficulty in evaluating this influence, an objective assessment of the results we obtained is clearly of little use. We therefore entirely agree with THOMPSON when he says:

'In the past undue emphasis has been placed on the objective assessment of results after tendon graft operations; each surgeon striving to make his series nearer perfection than the last. While this is a creditable attitude on the part of the surgeon, it is evident from the many papers written that until there is some fundamental advance in the reproducing of tendon gliding, one can go only so far with perfection of technique'.

What we wanted to know when we started to use the method described above is whether indeed some fundamental advance was made in the reproduction of tendon gliding. Our experience has led us to believe that this is definitely the case.

In 24 of the 25 tendon grafts gliding capacity was restored to some degree. This observation was based on the presence of active flexion in 21 cases and on the findings on amputation of the finger in 2 cases and surgical exploration in 1 case.

In only one of the 25 tendon grafts was gliding capacity absent. Amputation of the finger revealed intensive scar tissue formation.

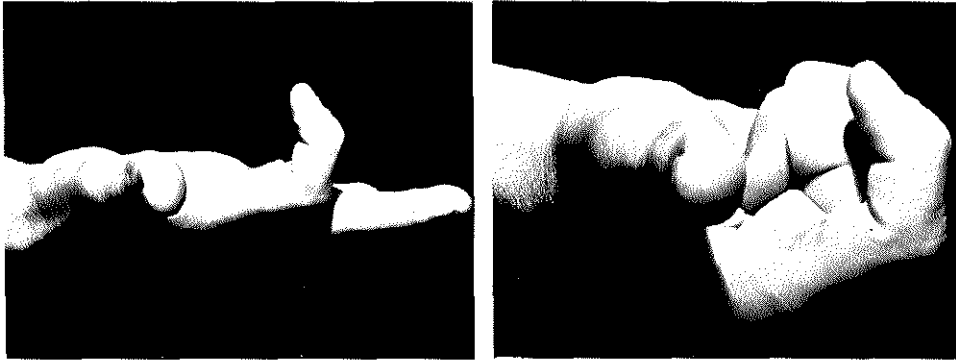


Fig. 13. Six weeks after repair of a tendon lesion of the index finger with a graft.

a. almost normal flexion exists in the p.i.p. and d.i.p.-joints of the finger when the m.p.-joints are held extended. This quick recovery of function is probably made possible by the presence of collagen poor adhesions in the reconstructed sheath.

b. an attempt to make a fist shows that the available amplitude of tendon gliding has been used up and that further flexion is impossible due to the presence of collagen rich adhesions in the palm of the hand at the site of the tendon suture.

More information about the value of this method is gained by a subjective assessment of the results. These may be summarized as follows:

- Patients with ideal pre-operative condition (5). In all 5 patients a complete recovery of active flexion was achieved.
- Patients with non-ideal pre-operative condition (19). In 15 patients there was a recovery of active flexion. In 5 of these 15 patients the degree of recovery was in fact complete. In 9 useful active flexion was achieved and in 1 only a useless degree of flexion resulted. In 4 patients recovery of active flexion was absent. This was caused: in one case by intensive scar tissue formation, in one case by a severe flexion contracture, and in two cases by collapse of the p.i.p. joint.

Not only do we believe that the reproduction of tendon gliding is more easily restored by the reconstruction of a tendon sheath, but we are also under the impression that the recovery of function – when achieved – occurs much more rapidly than is normally the case. This is not surprising since the inhibiting influence on function arising from collagen poor adhesions is considered to be low and our observation is in agreement with the findings of GELDMACHER.

#### COMPLICATIONS

Complications resulting from the implantation of a Silastic spacer may be summarized as follows:

##### 1. Extrusion

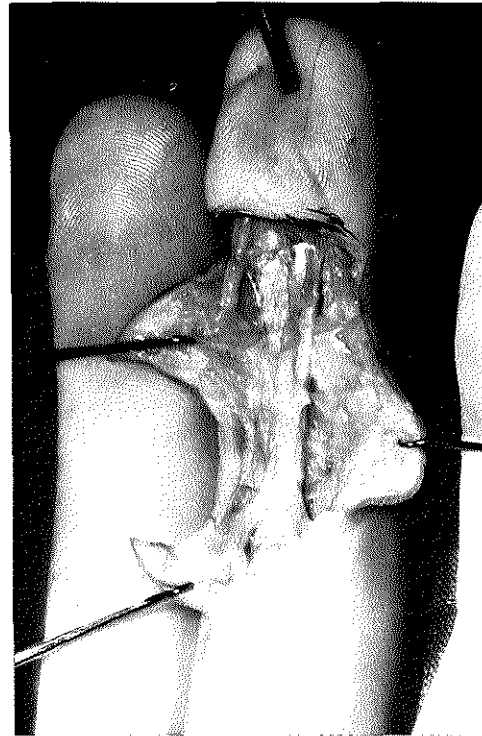
When the covering skin is scarred or infection is present, extrusion may take place. In this particular group of patients however this did not happen.

### 2. Swelling

In two patients implantation of the spacer was accompanied by severe oedema in the vicinity of the implant, this swelling completely disappeared in the course of a few weeks.

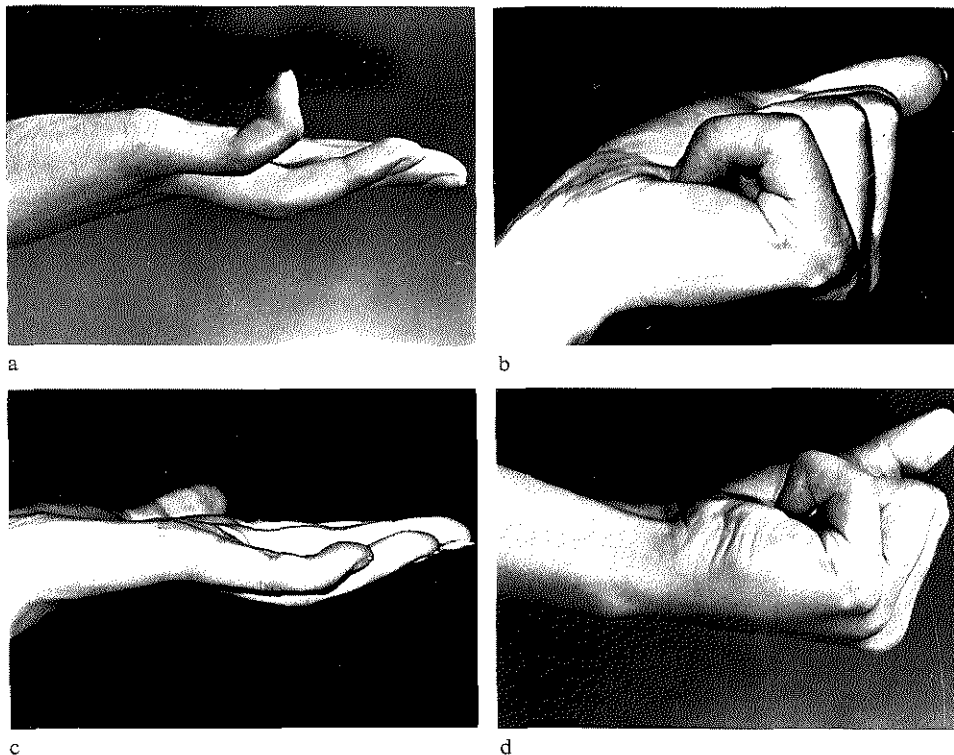
### 3. Contractures

In some patients a certain degree of flexion contractures of the finger developed after the implant had been replaced by an autogenous tendon graft. These contractures were caused by polarization of the scar tissue that had formed between the wall of the tendon sheath and the skeleton. This polarization did not develop until active function had been recovered (Fig. 14). It is of course possible that in these patients the scar tissue had formed as a reaction to a contamination of the implant and that the cause of the contracture must be sought in the implant, inert as it may seem to be. We are under the impression, that individual factors are involved here and that the reaction of a patient to the implant may be related to such factors as the colour of the hair, the age, sex and/or gravidity (Fig. 15).<sup>1</sup>



*Fig. 14.* Polarization of scar-tissue surrounding the newly formed sheath.

<sup>1</sup>Differentiation between disturbance of sensibility and circulation has been deliberately omitted. When there is an injury to the neurovascular bundle, very infrequently either the vessel or the nerve is not affected. It is generally accepted that a nerve lesion has an unfavourable influence on the results of a tendon graft, but the reason for the acceptance of this is obscure. We believe that more emphasis should be placed upon the vascular injury, for the revascularization of a tendon graft depends directly on the local blood supply.



*Fig. 15.* Severe flexion contractures occurring in young girls (one blond, the other red-haired). Exploration revealed that the range of motion inside the newly formed sheaths was quite satisfactory. The contractures were in both cases caused by peri sheath polarization of scar tissue. Satisfactory function was obtained by reinsertion of the distal end of the graft in the base of the middle phalanx after resection of the scar tissue at the level of the d.i.p.-joint. a. and b. range of motion after tendon grafting of the little finger. c. and d. range of motion after reinsertion of the tendon graft.

#### SUMMARY

The number of patients fulfilling the requirements for satisfactory results after the repair of tendon lesions is usually small compared with the number that does not fulfil these requirements.

In the latter group of patients conventional methods of treatment are not as a rule followed by satisfactory functional results. A desire to improve these results led to a study of the recent literature about the healing and repair of tendons. From this study it became clear that the results in tendon repair depend to a large extent on the quality of the adhesions, which are formed between the tendon and the surrounding tissues.

When these adhesions contain little collagen, the gliding capacity of a tendon will be the more easily restored.

The capacity of cell-poor tissue to form collagen is limited and the reconstruction of



a tendon sheath by implantation of a 'Silastic' spacer preceding the transplantation of a tendon graft, is therefore advocated by some surgeons. A report is presented of the experience gained by the author using this method for the treatment of a series of 25 patients.

#### RÉSUMÉ

Le nombre de patients atteints d'une lésion tendineuse qui ne remplit pas les conditions requises pour l'obtention d'un bon résultat, est élevé par rapport à celui des patients chez lesquels ces conditions se trouvent remplies.

Pour cette raison, le pronostic d'une tentative de restauration fonctionnelle par les méthodes classiques est mauvais dans la majorité des cas.

Le désir d'améliorer également chez ces patients les résultats de la restauration d'un tendon, nous a amené à entreprendre une étude de la littérature récente qui a fait apparaître que les résultats de la réparation d'un tendon dépendent dans une large mesure de la nature des adhérences qui se forment entre le tendon et le tissu environnant. Lorsque ces adhérences renferment peu de collagène, le pouvoir du tendon de glisser dans sa gaine se rétablira facilement.

Le pouvoir qu'un tissu pauvre en cellules a de former du collagène est restreint et certains chirurgiens sont, pour cette raison, partisans de la reconstitution d'une gaine tendineuse par l'implantation d'un cylindre en Silastic ('spacer') avant de procéder à une greffe tendineuse. L'auteur rapporte ensuite les résultats de son expérience de cette méthode chez une série de 25 patients.

#### ZUSAMMENFASSUNG

Die Zahl der Patienten mit einer Verletzung einer Beugsehne, welche die nötigen Voraussetzungen, ein günstiges Resultat zu erzielen, nicht besitzen, ist groß im Vergleich mit der Zahl derer, welche diesen Voraussetzungen entsprechen.

In der Majorität der Fälle hat darum der Versuch, die Wiederherstellung der Funktion mit Hilfe der konventionellen Methoden zu erzielen, eine schlechte Prognose.

Da wir danach streben, die Resultate auch in dieser Gruppe zu verbessern, haben wir die neuere Literatur zu Rate gezogen und daraus gelernt, daß die Resultate der Sehnenwiederherstellung in hohem Maße von der Art der Verwachsungen, die sich zwischen der Sehne und dem umgebenden Gewebe gebildet haben, abhängig sind. Wenn nämlich diese Verwachsungen nur wenig Kollagen enthalten, dann kann sich das Gleitvermögen der Sehne in seiner Scheide leicht wiederherstellen.

Das Vermögen zellarmen Gewebes, um Kollagen zu formen, ist beschränkt; darum stehen einige Chirurgen auf dem Standpunkt, die Sehnenscheide mit Hilfe eines Silikat-zylinders (Spacer) zu rekonstruieren, bevor das Sehnen-transplantat eingepflanzt wird.

Der Verfasser berichtet über seine eigenen Erfahrungen mit dieser Methode bei einer Serie von 25 Patienten.

#### SAMENVATTING

Het aantal patienten met een buigpeesletsel, dat niet voldoet aan de voorwaarden, die noodzakelijk zijn voor het verkrijgen van een goed resultaat is groot in vergelijking met het aantal dat wel aan deze voorwaarden voldoet.

In de meerderheid der gevallen heeft een poging tot functieherstel met behulp van conventionele methodes daarom een slechte prognose.

Het verlangen om de resultaten van het peesherstel ook in deze groep te verbeteren, bracht ons tot

een studie van de recente literatuur, waaruit bleek dat de resultaten van de pees-reparatie in hoge mate afhangen van de aard van de adhesies die zich vormen tussen de pees en het omringende weefsel. Wanneer deze adhesies weinig collageen bevatten zal het glij-vermogen van de pees in zijn schede zich gemakkelijk herstellen.

Het vermogen van cel-arm weefsel om collageen te vormen is beperkt en sommige chirurgen zijn daarom voorstander van de reconstructie van een pees-schede door implantatie van een 'Silastic' cylinder ('spacer') voordat tot pees-transplantatie wordt overgegaan. Er wordt verslag uitgebracht van schrijver's ervaringen met deze methode bij een serie van 25 patienten.

## REFERENCES

- BASSETT, C. A. L., CARROLL, R. E. Formation of tendon sheath by silicone rod implant, *J. Bone Jt Surg.* 45A: 884, 1963.
- BIRDSELL, D. C., TUSTANOFF, E. R. Collagen production in regenerating tendon, *Plast. reconstr. Surg.*, 37:504, 1966.
- LINDSAY, W. K. The vascularisation of a tendon graft. *Brit. J. plast. Surg.* 4: 130, 1951-52.
- BRAITHWAITE, F., and BROCKIS, J. G. Role of mesotenon in tendon blood supply. *Plast. reconstr. Surg.*, 43:53, 1969.
- COLVILLE, J. *et al* Tendon grafting, a suggested technique. *Plast. reconstr. Surg.*, 38: 302, 1966.
- GAISFORD, J. C. Die zweizeitige freie Beugesehnentransplantation, *Handchir.*, 3: 109, 1969.
- GELDMACHER, J. Artificial tendons, *Amer. J. Surg.* 109: 325, 1965.
- HUNTER, J.: The fibroblast in flexor tendon healing, *Plast. Reconstr. Surg.*, 34:223, 1964.
- LINDSAY, W. K., BIRCH, J. R. Reconstruction of the digital tendon sheath, *J. BONE JT SURG.*, 18:607, 1936.
- MAYER, L., RANSOHOFF, N. A silastic tendon prothesis as an adjunct to flexor tendon grafting: An experimental and clinical evaluation, *BRIT. J. PLAST. SURG.*, 22:224, 1969.
- NICOLLE, F. V. The lumbrical plus finger, *BRITISH SOC. FOR SURGERY OF THE HAND, November-meeting* 1969.
- PARKES, A. The repair of flexor tendons in the hand, *Surg. Gynec. Obstet.*, 113:1961.
- PEACOCK, E. E., HARTRAMPF, C. R. Some technical aspects and results of flexor tendon repair, *Surgery*, 58:330, 1965.
- PEACOCK, E. E. Fundamental aspects of wound healing relating to the restoration of gliding function after tendon repair, *Surg Gynec. Obstet.*, 119:241, 1964.
- PEACOCK, E. E. Physiology of tendon repair, *Amer. J. Surg.*, 109: 283-286, March 1965.
- PEACOCK, E. E. Physiology of tendon repair, *Amer. J. Surg.*, 109:283-286, March 1965.
- PEACOCK, E. E. Biological principles in the healing of long tendons, *Surg. Clin. N. Amer.* 45:461, 1965.
- PEACOCK, E. E. Biology of tendon repair, *New Engl. J. Med.*, 276:680, 1967.
- PEACOCK, E. E. A study of the circulation in normal tendons and healing grafts, *Ann. Surg.* 149:415, 1959.
- PEACOCK, E. E. Symposium on biological control of scar tissue, *Plast. reconstr. Surg.*, 41:8, 1968.

- POTENZA, A. D. Critical evaluation of flexor-tendon healing and adhesion formation within artificial digital sheaths, *J. Bone Jt Surg.*, 45-A: 1217, 1963.
- POTENZA, A. D. Tendon healing within the flexor digital sheath in the dog, *J. Bone Jt Surg.*, 44-A:49, 1962.
- REIS, N. D. Experimental tendon repair, *Brit. J. plast. Surg.*, 22:134, 1969.
- SKOOG, T., PERSSON, B. H. An experimental study of the early healing of tendons, *Plast. reconstr. Surg.*, 13:384, 1954.
- SMITH, J. W., CONWAY, H. La dynamique du glissement des tendons normaux et greffés, *Rev. Chir. Orthop.*, 52:185, 1966.
- SMITH, J. W., CONWAY, H. Blood supply of tendons, *Amer. J. Surg.*, 109:272, 1965.
- THOMPSON, R. V. An evaluation of flexor tendon grafting, *Brit. J. Plast. Surg.*, 20:21, 1967.



# Stöpler. En de tweede jeugd.

Stöpler werkt hard aan zijn operatie transformatie. Een recente stap naar die metamorfose was het betrekken van een nieuw en praktisch pand in Utrecht-Overvecht.

De aanloop tot die stap werd ingezet in 1902, toen Stöpler werd gevestigd. Stöpler is sinds zijn oprichting vrijwel voortdurend gegroeid, een trend die de laatste paar jaar een climax beleeft.

Oorzaken: het uitgebalanceerde leveringspakket. De excellente kwaliteit van het assortiment. Het jonge, dynamische management. En de eigen vakopleiding voor

personeel, waardoor het verkoopapparaat in binnen- en buitendienst diepgaande kennis heeft van Stöplers medisch areaal. Met die vakopleiding staat Stöpler trouwens nog immer alleen in Nederland.

Wat zit daar achter? Stöpler wil door zijn eigen efficiency een impuls geven aan uw efficiency. Dat is in de eerste plaats gelukkig voor uw patiënten en - mis - en mogen we dat wel eens memoreren - het is niet minuscule in het belang van uw eigen rentabiliteit.

## Stöpler. En de operatie Transformatie.

