

## Initial Results of Combined Anterior Mitral Leaflet Extension and Myectomy in Patients With Obstructive Hypertrophic Cardiomyopathy

MARCEL J. KOFFLARD, MD, LEX A. VAN HERWERDEN, MD, PhD, DAVID J. WALDSTEIN, MD,\*  
PETER RUYGROK, MD, ERIC BOERSMA, MSc, MEINDERT A. TAAMS, MD, PhD,  
FOLKERT J. TEN CATE, MD, PhD, FACC

Rotterdam, The Netherlands and Chicago, Illinois

**Objectives.** The purpose of this study was to describe the clinical and functional results of combined anterior mitral leaflet extension and myectomy in patients with hypertrophic obstructive cardiomyopathy.

**Background.** Septal myectomy is the most commonly performed surgical procedure in patients with hypertrophic cardiomyopathy and left ventricular outflow tract obstruction. Because of the role of the mitral valve in creating the outflow tract gradient, mitral valve replacement or plication is performed in selected cases in combination with myectomy, often with better hemodynamic results than those of myectomy alone. Mitral valve leaflet extension, in which a glutaraldehyde-preserved autologous pericardial patch is used to enlarge the mitral valve along its horizontal axis, is a novel surgical approach in patients with hypertrophic obstructive cardiomyopathy.

**Methods.** Eight patients with hypertrophic obstructive cardiomyopathy were treated with mitral leaflet extension and myectomy. Preoperative and postoperative data (New York Heart Association functional class, number of drugs prescribed, width of the interventricular septum, severity of mitral valve regurgitation,

severity of systolic anterior motion of the mitral valve and outflow tract gradient) were compared with those of 12 patients undergoing myectomy alone.

**Results.** Preoperative evaluation demonstrated that mitral regurgitation and systolic anterior motion of the mitral valve were more severe in the group undergoing mitral valve extension ( $p < 0.001$  and  $p < 0.05$ , respectively). There were no deaths associated with either surgical procedure. Two patients, both treated by myectomy alone, died during the follow-up period. Postoperatively, patients treated with mitral valve extension had less mitral regurgitation ( $p < 0.005$ ), less residual systolic anterior motion ( $p < 0.01$ ), greater improvement in functional class ( $p = 0.05$ ) and greater reduction in the number of drugs ( $p < 0.005$ ) and in septal thickness ( $p < 0.05$ ).

**Conclusions.** Mitral leaflet extension in combination with myectomy is a promising new surgical approach that may provide superior results to those of myectomy alone. Further studies are needed to determine the clinical value of this procedure.

(*J Am Coll Cardiol* 1996;28:197-202)

Surgery for hypertrophic cardiomyopathy is generally performed in patients who have a significant left ventricular outflow tract gradient and severe symptoms despite maximal medical therapy (1-4). The most commonly performed procedure is septal myectomy (the Morrow procedure) (5), which usually results in adequate reduction in the obstruction to outflow (6-9). Because of the contribution of the mitral valve in generating the outflow tract gradient (10-13), mitral valve replacement alone or in combination with myectomy is also performed, often with better hemodynamic results than those of myectomy alone (8,9,14,15). However, the long-term risks of

thromboembolism and hemorrhage associated with prosthetic valves and the need for anticoagulant therapy make mitral valve replacement an unattractive option for many patients with hypertrophic cardiomyopathy, who are frequently young and physically active (1,16). Mitral leaflet plication in combination with myectomy has recently been proposed (17) as a successful alternative to mitral valve replacement in hypertrophic cardiomyopathy. Another alternative procedure is anterior mitral leaflet extension, one of several valve repair techniques developed by Carpentier (18) and Chauvaud et al. (19), in which a glutaraldehyde-preserved autologous pericardial patch is used to enlarge the mitral valve along its horizontal axis. The application of mitral leaflet extension in patients with obstructive hypertrophic cardiomyopathy has not been reported previously. In this report we present the immediate results and early follow-up data (up to 4 years) in 8 patients treated with combined anterior mitral leaflet extension and myectomy. Results are compared with those of 12 patients undergoing myectomy alone. The possible mechanisms of action of mitral leaflet extension are also discussed.

From the Thoraxcenter, Department of Cardiology, Clinical Epidemiology and Cardiopulmonary Surgery, University Hospital Dijkzigt and Erasmus University Rotterdam, The Netherlands; and \*University of Chicago, Chicago, Illinois.

Manuscript received July 5, 1995; revised manuscript received January 23, 1996, accepted March 4, 1996.

Address for correspondence: Dr. Folkert J. Ten Cate, University Hospital Dijkzigt, Thoraxcenter Ba 350, Dr. Molewaterplein 40, 3015 GD Rotterdam, The Netherlands.

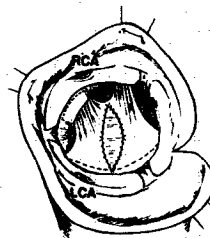
## Methods

**Indications.** Indications for surgery in our Hypertrophic Cardiomyopathy Clinic include a rest or provokable left ventricular outflow tract gradient  $\geq 50$  mm Hg and persistent symptoms despite an adequate trial of medical therapy, consisting of beta-adrenergic blocking agents, calcium channel blocking agents, or both. Preoperative echocardiography and cardiac catheterization for invasive hemodynamic measurements and angiography are performed in all patients for whom surgery is proposed. Postoperative assessment includes repeat echocardiography 1 week and again several months after operation. Repeat cardiac catheterization is not routinely performed unless clinically indicated.

The decision to perform anterior mitral leaflet extension in conjunction with myectomy is made at the time of operation if, in the surgeon's view, myectomy alone is likely to yield a suboptimal result. Conditions that favor inclusion of a valve procedure include atrial fibrillation, limited septal hypertrophy, marked systolic anterior motion of the mitral valve and significant mitral regurgitation (1,4,5).

**Patients.** Between 1986 and 1988, the myectomy procedure was performed by two surgeons (L.A.H. and an older colleague who taught L.A.H. the myectomy procedure). From 1988 on, all operations, including all mitral valve procedures, were carried out by a single surgeon (L.A.H.). A total of 20 patients underwent septal myectomy, 8 of whom underwent concomitant anterior mitral leaflet extension. The primary reason for performing mitral leaflet extension was mitral regurgitation and systolic anterior motion of the mitral valve of particular severity; one patient had chronic atrial fibrillation associated with significant mitral regurgitation.

**Surgical technique.** Open chest epicardial echocardiography is used extensively during the procedure for ongoing assessment of septal thickness, systolic anterior motion of the mitral valve and detailed structure of the mitral leaflets. Continuous wave and Doppler color echocardiography are used to quantify the outflow tract gradient and mitral regurgitation and their responses to physiologic manipulation such as volume infusion and administration of inotropic agents. The images are registered on videotape for off-line analysis. Patients are operated on with standard techniques of cardiopulmonary bypass with moderate hypothermia and crystalloid cardioplegic arrest (St. Thomas's solution). An autologous pericardial patch is harvested, trimmed of fat and extraneous tissue, immersed for 10 min in 0.62% glutaraldehyde and then placed in a normal saline bath. The aorta is opened by an oblique incision and septal myectomy is performed to the left of an imaginary line through the nadir of the right aortic cusp, with a locally designed electrocautery device, described in detail elsewhere (20). In brief, the cutting electrode of the device is a quadrangular monopolar electrode composed of a metal foil. The cutting electrode is connected to a pencil with a malleable connection to allow the electrode to be adjusted with respect to the orientation of the handle. The width and depth of the myectomy depend on the dimensions of the



**Figure 1.** Schematic representation of mitral leaflet extension. The pericardial patch is clearly seen in the middle of the drawing, within the anterior mitral leaflet. The area of the myectomy is seen in the interventricular septum, demarcated by dots. The ostia of both the left (LCA) and right (RCA) coronary arteries are indicated for orientation purposes.

electrode. Currently, three different electrode sizes are available:  $10 \times 6.5$ ,  $11 \times 9$  and  $16 \times 9$  mm (width  $\times$  depth). The procedure is guided by intraoperative echocardiography with the removal of additional septal myocardium if necessary.

Next, anterior mitral leaflet extension is performed according to the method described by Chauvaud et al. (19), with the following modifications: the pericardial patch harvested at the beginning of the procedure is cut to an oval shape approximately 3 cm wide and 2.5 cm long. The anterior mitral leaflet is incised longitudinally from its subaortic hinge point to the rough zone. The patch is sewn onto the ventricular surface of the leaflet at the site of the incision by using three running polypropylene monofilament sutures (Fig. 1). Immediate results are assessed by intraoperative echocardiography after weaning from cardiopulmonary bypass, with particular attention to residual systolic anterior motion, mitral regurgitation and the left ventricular outflow tract gradient. Reinstitution of bypass for the purpose of modifying the surgical result was not required in this cohort of patients.

**Data collection and analysis.** All patients were assessed clinically preoperatively and postoperatively by the same physician (F.J.T.C.), who was also responsible for their medical management. Transthoracic echocardiographic data were reviewed by two physicians who had access to data on the patients' histories and surgical procedures. Interventricular septal thickness was determined by two-dimensional echocardiography in the parasternal short-axis view at the site of the myectomy. Mitral regurgitation was assessed by color Doppler echocardiography and graded on a scale of 0 to 4+. Systolic anterior motion of the mitral valve was assessed from the two-dimensional images and graded as 0 (absent), 1+ (mild [minimal mitral-septal distance  $>10$  mm during systole]), 2+ (moderate [minimal mitral-septal distance  $\leq 10$  mm during systole]) or 3+ (marked [brief or prolonged contact between the mitral valve and septum]) (21). Peak left ventricular outflow tract gradient at rest or with provocation was estimated with Doppler echocardiography by using the modified Bernoulli equation,  $P = 4V^2$ , where P is pressure gradient and V is Doppler-determined blood velocity. When echocardi-

**Table 1.** Preoperative and Postoperative Clinical and Transthoracic Echocardiographic Data of Patients With Hypertrophic Obstructive Cardiomyopathy Treated With Either Combined Myectomy and Mitral Valve Extension or Myectomy Alone

Pt No.	Age (yr)/ Gender	Date of Operation	NYHA Class		Medication		IVS Width (mm)		MR		SAM		Peak LVOT Gradient (mm Hg)	
			Pre	Post	Pre	Post	Pre	Post	Pre	Post	Pre	Post	Pre	Post
<b>MM/MLE</b>														
1	57/M	5/91	III	I	A,C,D,W	C,W	27	20	3+	1+	3+	0	92	5
2	25/F	9/91	III	I	B	—	30	20	3+	1+	3+	1+	58	25
3	29/M	2/92	III	I	B,C	—	35	25	3+*	0	3+	0	74	9
4	54/M	1/93	II	I	B	—	22	15	3+	0	2+	0	100	9
5	31/M	3/93	III	I	C	—	22	15	2+	1+	3+	0	112	36
6	35/F	6/94	II	I	C	C	29	20	2+	0	3+	0	121	16
7	59/M	6/94	III	I	B	—	22	18	2+	0	3+	0	100	6
8	44/F	6/94	II	I	C	C	20	15	3+	1+	3+	1+	100	36
<b>MM alone</b>														
1	54/M	3/86	III	I	C	C,W	28	24	2+*	1+	2+	2+	80*	16
2	29/T	8/86	III	II	C	A	30	26	2+*	3+	3+	3+	60	50
3	52/F	2/87	III	II	C,W	B,D,W	27	18	1+*	1+	2+	0	100	7
4	61/F	12/87	III	I	B,C	A,D,I,W	26	21	1+	0	1+	0	80*	5
5	38/M	7/88	III	II	C	B	30	25	1+	0	3+	1+	81*	7
6	32/M	11/88	II	I	C	—	24	18	2+	1+	3+	3+	160	41
7	30/F	5/89	III	III	C	B,C,D	25	19	1+	0	1+	0	36	4
8	38/M	7/89	II	I	C	C	20	20	0	0	1+	1+	81	5
9	44/M	3/90	III	II	B	B	33	30	0	0	2+	1+	50	12
10	36/F	6/90	II	I	C	A	30	22	0	0	3+	0	100	36
11	35/F	4/91	III	II	B	B	20	18	1+	2+	3+	3+	70	64
12	44/F	2/93	III	I	B,C,W	B,C,W	31	27	0	1+	1+	1+	147	25

\*Assessed by angiography. A = antiarrhythmic agents; B = beta-adrenergic blocking agents; C = calcium channel blocker; D = diuretic drug; F = female; I = angiotensin-converting enzyme inhibitor; IVS = interventricular system; LVOT = left ventricular outflow tract; M = male; MM = myectomy; MM/MLE = myectomy and mitral valve extension; MR = mitral regurgitation; NYHA Class = New York Heart Association functional class; Post = postoperative; Pre = preoperative; Pt = patient; SAM = systolic anterior motion of the mitral valve; W = warfarin; — = none.

graphic data were inadequate or unavailable, catheterization data were used. Intraoperative epicardial echocardiograms were performed in all patients before and after cardiopulmonary bypass. The recordings of those patients who underwent anterior mitral leaflet extension were available for further analysis.

The left ventricular outflow tract and mitral valve leaflet areas were calculated according to previously described methods (21,22). In brief, the left ventricular outflow tract area is calculated in the short-axis view at the level of the mitral valve at the onset of systole. The first frame in the cardiac cycle (onset of ventricular systole) when the mitral valve appears closed is taken for analysis. On the stop frame the innermost margins of the outflow tract are traced on the screen and the demarcated area is calculated by utilizing an off-line computer and a dedicated software program (23). The mitral valve leaflet area is derived from the mitral valve opening area (MVOA). The latter is measured by tracing the innermost margins of the mitral valve in the parasternal short-axis view at the point of maximal opening. The mitral valve leaflet area (MLA) is then calculated by using the formula  $MLA = 2.19 + 3.06 \times MVOA$  validated by Klues et al. (22).

**Statistics.** Data were expressed as mean value  $\pm$  SD. The Wilcoxon test was used to compare clinical characteristics

before and after operation of the patients with combined myectomy and anterior mitral valve extension and those with myectomy alone. The characteristics compared were age, New York Heart Association functional class, number of drugs prescribed, width of the interventricular septum, severity of systolic anterior motion, severity of mitral insufficiency and left ventricular outflow tract gradient.

## Results

**Patient characteristics and surgical outcome.** Preoperative and postoperative clinical and transthoracic echocardiographic characteristics of the 8 patients undergoing myectomy combined with anterior mitral valve extension and the 12 patients undergoing myectomy alone are presented in Table 1. The postoperative clinical and echocardiographic data refer to the latest patient follow-up. There were no deaths or serious complications associated with the surgical procedures. Patients 4 and 6 in the group with myectomy alone died during follow-up: Patient 4 died of congestive heart failure 6 years after operation and Patient 6 died suddenly 2 years after the procedure.

Statistical differences between the two groups are presented in Table 2. Preoperative mitral regurgitation and systolic

**Table 2.** Baseline and Postoperative Characteristics in Patients Treated by Myectomy and Mitral Valve Extension and in Patients Treated by Myectomy Alone

	MM/MLE	MM	p Value
<b>Baseline</b>			
Age (yr)	42 ± 10	41 ± 10	0.94
NYHA class	2.6 ± 0.5	2.8 ± 0.5	0.59
Number of drugs	1.5 ± 1.1	1.3 ± 0.7	0.96
IVS width (mm)	26 ± 5	27 ± 4	0.56
Range	20-35	20-33	
MR* (grade)	2+/3+	0/2+	< 0.001
SAM† (grade)	2+/3+	1+/3+	< 0.05
LVOT gradient (mm Hg)	95 ± 20	87 ± 36	0.33
<b>Postoperative</b>			
NYHA class	1	1.7 ± 0.7	0.05
Number of drugs	0.5 ± 0.8	1.8 ± 1.2	< 0.005
IVS width (mm)	19 ± 4	22 ± 4	< 0.05
Range	15-25	18-30	
MR* (grade)	0/1+	0/3+	< 0.005
SAM† (grade)	0/1+	0/3+	< 0.01
LVOT gradient (mm Hg)	18 ± 13	23 ± 20	0.35

\*Range of mitral regurgitation observed in the two respective patient groups.

†Range of systolic anterior motion observed in the two respective patient groups. Data are presented as mean value ± SD, range or grade. IVS = width of the interventricular septum; other abbreviations as in Table 1.

anterior motion of the mitral valve were worse ( $p < 0.001$  and  $p < 0.05$ , respectively) in the patients who underwent combined myectomy and mitral valve extension than in the patients who underwent myectomy alone. Nonetheless, postoperative residual mitral regurgitation and systolic anterior motion were significantly better ( $p < 0.005$  and  $p < 0.01$ , respectively) in the group with the combined procedures. Moreover, this group had greater improvement in functional class ( $p = 0.05$ ) and a greater reduction in both the number of drugs prescribed ( $p < 0.005$ ) and the width of the interventricular septum ( $p < 0.05$ ).

**Mitral valve measurements.** The mitral valve leaflet and left ventricular outflow tract areas of patients undergoing


combined myectomy and mitral valve extension were calculated from intraoperative epicardial echocardiographic data according to previously described methods. The mean mitral valve leaflet area of  $15.9 \pm 2.0 \text{ cm}^2$  is considerably above mean values for the general population ( $< 12 \text{ cm}^2$ ). All patients belonged to a subset of patients with hypertrophic cardiomyopathy, as described by Klues et al. (24), with enlarged mitral leaflets, relatively large left ventricular outflow tract area ( $\geq 2.0 \text{ cm}^2$  [mean  $2.9 \pm 0.7$ ]) and a distinctive sharp-angled bend of the anterior mitral leaflet.

By transthoracic echocardiography, the anterior mitral valve extension procedure did not induce obvious changes in the length or thickness of the anterior mitral leaflets, although subjectively they appeared somewhat less flexible. Figure 2 shows a typical postoperative transthoracic echocardiogram without any residual systolic anterior motion of the mitral valve and with a widened left ventricular outflow tract.

## Discussion

Anterior mitral leaflet extension is a novel surgical approach to the treatment of obstructive hypertrophic cardiomyopathy. The procedure entails grafting a patch of autologous pericardium onto the center portion of the anterior mitral leaflet, effectively increasing the size (mainly the width) of the leaflet. In the eight patients who underwent anterior mitral leaflet extension in combination with septal myectomy, the extension procedure was safe and effective in abolishing or greatly reducing systolic anterior movement of the mitral valve and mitral regurgitation and in lessening symptoms. Patients undergoing the combined procedure had significantly greater improvement in functional class and required fewer number of drugs postoperatively than did the 12 patients undergoing myectomy alone.

The reduction of septal thickness in both groups is not in contrast to the results of other institutions (25-27). Nevertheless, our approach may not be as aggressive as the double



**Figure 2.** Two-dimensional, long-axis transthoracic echocardiograms from the same patient before and after combined anterior mitral leaflet extension and myectomy. Both are systolic frames from the same point in the cardiac cycle. **Left,** Preoperative image (PRE), demonstrating marked systolic anterior motion of the distal anterior mitral leaflet (SAM, single arrow). **Right,** Postoperative image (POST), showing no significant systolic anterior movement of the valve. Note also the widened outflow tract after myectomy and the probable position of the pericardial patch (double arrows). The mitral valve itself is not demonstrably longer or thicker, although differences in technical quality prevent direct comparison. IVS = interventricular septum; LV = left ventricle; LVOT = left ventricular outflow tract.

myotomy-myectomy procedure reported by Morrow (28). However, overzealous septal myectomy must be avoided, because it may cause complete heart block, septal defect or increased mortality (29-31). The optimal myectomy procedure reduces septal thickness to a minimum without augmenting morbidity and mortality. Starting in 1972 we performed myectomy with or without mitral valve extension in 46 patients with only 1 in-hospital death. We cannot exclude the possibility that these good results were obtained because of a less aggressive septal myectomy.

Although the principal benefit of anterior mitral leaflet extension appears to be abolition of systolic anterior movement and mitral regurgitation, the precise mechanism of this effect is not clear. In fact, the idea of enlarging the anterior mitral leaflet is counterintuitive, given the awareness of the role that the mitral valve plays in producing the systolic anterior movement.

**Mechanisms of outflow tract obstruction.** Outflow tract obstruction in patients with hypertrophic cardiomyopathy results from a combination of left ventricular outflow tract narrowing, due to basal septal hypertrophy, and systolic anterior motion of the mitral valve (1,11,32). Several mechanisms for systolic anterior motion have been proposed: 1) The Venturi mechanism, by which the hypertrophied septum and anterior displacement of the mitral valve create outflow tract narrowing, increased flow velocity, decreased pressure above the valve and, consequently, the development of systolic anterior motion, partly due to the abnormal laxity of the mitral valve (10,12-14,22,24,32-35). 2) Anatomic alterations in the mitral valve apparatus. These may predispose to systolic anterior motion due to flow drag, the combination of increased mitral leaflet area, length and laxity and anterior displacement of the papillary muscles allowing the mitral leaflets to protrude into the left ventricular outflow tract and thus exposing them to flow drag. 3) Inward displacement of the papillary muscles toward one another. This displacement can produce relative chordal slack in the central leaflet portions; consequently, the systolic anterior motion will be greatest in the center of the valve (36).

Recently a combined pathologic and echocardiographic review by Klues et al. (24) confirmed that an enlarged mitral valve is present in a subset of patients with hypertrophic cardiomyopathy. These investigators classified patients with obstructive hypertrophic cardiomyopathy into two categories: 1) patients with an enlarged mitral valve, relatively large left ventricular outflow tract area and distinctive sharp-angled bend of the anterior leaflet (typical systolic anterior motion), and 2) patients with a normal-sized mitral valve, small outflow tract area and "atypical" systolic anterior motion. All of our patients treated by the combined myectomy-mitral valve extension technique belonged to the subset of patients with an enlarged mitral valve. This finding is important because an enlarged mitral valve may predispose to residual systolic anterior motion of the valve after myectomy, resulting in a suboptimal outcome with persisting outflow tract obstruction.

**Possible mechanisms of action of mitral leaflet extension.** How, then, does further increasing the size of the anterior mitral leaflet with a pericardial patch abolish the systolic anterior motion? Both the Venturi mechanism and the flow drag of the leaflets described earlier may be counteracted by anterior mitral leaflet extension. The distal end of the patch lies in the proximity of the bending point of the anterior leaflet. The patch may merely serve to stiffen the leaflet, making it less lax and less likely to buckle in the presence of Venturi forces or flow drag forces. Subjectively, the anterior mitral leaflets after combined myectomy and mitral valve extension did appear less "floppy" by two-dimensional echocardiography, without compromise in leaflet mobility or coaptation.

The mitral valve extension technique increases the width (horizontal dimension), not the length (vertical dimension), of the anterior leaflet. Conceivably, increasing the width of the anterior mitral leaflet could erect the relatively lax chordae attaching central portions of the mitral leaflet and thus prevent buckling of central parts of the valve.

Currently we perform the mitral valve elongation procedure in patients undergoing surgery who are likely to have suboptimal results from myectomy alone. These may include patients with particularly severe systolic anterior motion of the mitral valve and mitral regurgitation, as well as patients with chronic atrial fibrillation or limited septal hypertrophy. In retrospect, all of our patients who underwent combined myectomy and anterior mitral valve elongation belonged to the subset of patients with an abnormally enlarged anterior mitral leaflet surface area. Whether equal results can be achieved in patients with a normal-sized mitral valve is unknown.

**Summary.** Adequate and predictable relief of outflow tract obstruction is the primary goal of surgery for hypertrophic cardiomyopathy. Many techniques, including simple septal myectomy, extended myectomy using intraoperative echocardiography and multiple periods of cardiopulmonary bypass (31), mitral valve replacement (1,8,9) and mitral leaflet plication (17), are currently available to the cardiac surgeon. Anterior mitral valve extension is a promising new surgical approach to obstructive hypertrophic cardiomyopathy that may provide more satisfactory results than those of myectomy alone. The mitral valve extension procedure is known to be a safe and reliable therapy in other conditions such as rheumatic valve disease and bacterial endocarditis with perforation (19). Further experience needs to be gained in obstructive hypertrophic cardiomyopathy before its widespread use can be recommended.

## References

1. McIntosh CL, Maron BJ. Current operative treatment of obstructive hypertrophic cardiomyopathy. *Circulation* 1988;78:487-95.
2. Fighali S, Krajcer Z, Leachman RD. Septal myomectomy and mitral valve replacement for idiopathic hypertrophic subaortic stenosis: short- and long-term follow-up. *J Am Coll Cardiol* 1984;3:1127-34.
3. Cooley DA. Surgical techniques for hypertrophic left ventricular obstructive myopathy including mitral valve plication. *J Card Surg* 1991;6:29-33.
4. Maron BJ, Bonow RO, Cannon RO, Leon MB, Epstein SE. Hypertrophic

- cardiomyopathy: interrelations of clinical manifestations, pathophysiology, and therapy. *N Engl J Med* 1987;316:780-9,844-52.
5. Morrow AG, Reitz BA, Epstein SE, et al. Operative treatment in hypertrophic subaortic stenosis: techniques, and the results of pre- and postoperative assessments in 83 patients. *Circulation* 1975;52:88-102.
  6. Maron BJ, Merrill WH, Freier PA, Kent KM, Epstein SE, Morrow AG. Long-term clinical course and symptomatic status of patients after operation for hypertrophic subaortic stenosis. *Circulation* 1978;57:1205-13.
  7. Cooper MM, Tucker E, McIntosh CL, Cannon RO, Clark RE. Effect of left ventricular septal myectomy on concurrent mitral regurgitation. *Ann Thorac Surg* 1989;48:251-6.
  8. Krajcer Z, Leachman RD, Cooley DA, Coronado R. Septal myotomy-myectomy versus mitral valve replacement in hypertrophic cardiomyopathy: ten-year follow-up in 185 patients. *Circulation* 1989;80 Suppl 1:1-57-64.
  9. Walker WS, Reid KG, Cameron EWJ, Walbaum PR, Kitchin AH. Comparison of ventricular septal surgery and mitral valve replacement for hypertrophic obstructive cardiomyopathy. *Ann Thorac Surg* 1989;48:528-35.
  10. Ellis JG, Terney OJ, Winters WL, Leachman RD. Critical role of the mitral valve leaflet in hypertrophic subaortic stenosis and amelioration of the disease by mitral valve replacement. *Chest* 1971;59:378-82.
  11. Maron BJ, Epstein SE. Clinical significance and therapeutic implications of the left ventricular outflow tract pressure gradient in hypertrophic cardiomyopathy [editorial]. *Am J Cardiol* 1986;58:1093-6.
  12. Klues HG, Roberts WC, Maron BJ. Anomalous insertion of papillary muscle directly into anterior mitral leaflet in hypertrophic cardiomyopathy: significance in producing left ventricular outflow obstruction. *Circulation* 1991;84:1188-97.
  13. Klues HG, Maron BJ, Dollar AL, Roberts WC. Diversity of structural mitral valve alterations in hypertrophic cardiomyopathy. *Circulation* 1992;85:1651-60.
  14. Cooley DA, Leachman RD, Wukasz DC. Diffuse muscular subaortic stenosis: surgical treatment. *Am J Cardiol* 1973;31:1-6.
  15. McIntosh CL, Greenberg GJ, Maron BJ, Leon MB, Cannon RO, Clark RE. Clinical and hemodynamic results after mitral valve replacement in patients with obstructive hypertrophic cardiomyopathy. *Ann Thorac Surg* 1989;47:236-46.
  16. Roberts WC. Operative treatment of hypertrophic obstructive cardiomyopathy: the case against mitral valve replacement. *Am J Cardiol* 1973;32:377-81.
  17. McIntosh CL, Maron BJ, Cannon RO, Klues HG. Initial results of combined anterior mitral leaflet plication and ventricular septal myotomy-myectomy for relief of left ventricular outflow tract obstruction in patients with hypertrophic cardiomyopathy. *Circulation* 1992;86 Suppl II:II-60-7.
  18. Carpentier A. Cardiac valve surgery—the "French correction." *J Thorac Cardiovasc Surg* 1983;86:323-37.
  19. Chauvaud S, Jebara V, Chachques JC, et al. Valve extension with glutaraldehyde-preserved autologous pericardium. *J Thorac Cardiovasc Surg* 1991;102:171-8.
  20. Maat LP, Slager CJ, van Herwerden LA, et al. Spark erosion myectomy in hypertrophic obstructive cardiomyopathy. *Ann Thorac Surg* 1994;58:536-40.
  21. Spirito P, Maron BJ. Significance of left ventricular outflow tract cross-sectional area in hypertrophic cardiomyopathy: a two-dimensional echocardiographic assessment. *Circulation* 1983;67:1100-8.
  22. Klues HG, Proschan MA, Dollar AL, Spirito P, Roberts WC, Maron BJ. Echocardiographic assessment of mitral valve size in obstructive hypertrophic cardiomyopathy. Anatomic validation from mitral valve specimen. *Circulation* 1993;88:548-55.
  23. Van der Borden SG, Roelandt J, Rijsterborgh H. Computer-aided analysis of Doppler echocardiograms. In: Roelandt J, editor. Colour flow imaging and other advances in Doppler echocardiography. Dordrecht (The Netherlands): Martinus Nijhoff, 1986:39-49.
  24. Klues HG, Roberts WC, Maron BJ. Morphological determinants of echocardiographic patterns of echocardiographic patterns of mitral valve systolic anterior motion in obstructive hypertrophic cardiomyopathy. *Circulation* 1993;87:1570-9.
  25. Seiler C, Hess OM, Schoenbeck M, et al. Long-term follow-up of medical versus surgical therapy for hypertrophic cardiomyopathy: a retrospective study. *J Am Coll Cardiol* 1991;17:634-42.
  26. Schulte HD, Bircks WH, Loesse B, Godehardt EAJ, Schwartzkopff B. Prognosis of patients with hypertrophic obstructive cardiomyopathy after transaortic myectomy: late results up to twenty-five years. *J Thorac Cardiovasc Surg* 1993;106:709-17.
  27. ten Berg JM, Suttrop MJ, Knaepen PJ, Ernst SMPG, Vermeulen FEE, Jaarsma W. Hypertrophic obstructive cardiomyopathy: initial results and long-term follow-up after Morrow septal myectomy. *Circulation* 1994;90:1781-5.
  28. Morrow AG. Hypertrophic subaortic stenosis: operative methods utilized to relieve left ventricular outflow obstruction. *J Thorac Cardiovasc Surg* 1978;76:423-30.
  29. Heric B, Lytle BW, Miller DP, Rozenkranz ER, Lever HM, Cosgrove DM. Surgical management of hypertrophic obstructive cardiomyopathy: early and late results. *J Thorac Cardiovasc Surg* 1995;110:195-208.
  30. Kirklín J, Barratt-Boyes B. Hypertrophic obstructive cardiomyopathy. In: Kirklín JW, Barratt-Boyes BG, editors. *Cardiac Surgery*. 2nd ed. New York: Churchill-Livingston, 1992:1239-62.
  31. Marwick TH, Stewart WJ, Lever HM, et al. Benefits of intraoperative echocardiography in the surgical management of hypertrophic cardiomyopathy. *J Am Coll Cardiol* 1992;20:1066-72.
  32. Jiang L, Levine RA, King ME, Weyman AE. An integrated mechanism for systolic anterior motion of the mitral valve in hypertrophic cardiomyopathy based on echocardiographic observations. *Am Heart J* 1987;113:633-44.
  33. Cape EG, Simons D, Jimoh A, Weyman AE, Yoganathan AP, Levine RA. Chordal geometry determines the shape and extent of systolic anterior mitral motion: in vitro studies. *J Am Coll Cardiol* 1989;13:1438-48.
  34. Levine RA, Vlahakes GJ, Gieseck E, et al. New insights into the mechanism of obstruction in hypertrophic cardiomyopathy: experimental models [abstract]. *Circulation* 1989;80 Suppl II:II-662.
  35. Sherrid MV, Chu CK, Delia E, Mogtader A, Dwyer EM. An echocardiographic study of the fluid mechanics of obstruction in hypertrophic cardiomyopathy. *J Am Coll Cardiol* 1993;22:816-25.
  36. Levine RA, Vlahakes GJ, Lefebvre X, et al. Papillary muscle displacement causes systolic anterior motion of the mitral valve. Experimental validation and insights into the mechanism of subaortic obstruction. *Circulation* 1995;91:1189-95.