



## A new surgical technique for deep stromal, anterior lamellar keratoplasty

Gerrit R J Melles, Frank Lander, Frank J R Rietveld, Lies Remeijer, W Houdijn Beekhuis and Perry S Binder

*Br. J. Ophthalmol.* 1999;83;327-333

---

Updated information and services can be found at:  
<http://bjournal.com/cgi/content/full/83/3/327>

---

*These include:*

### References

This article cites 20 articles, 1 of which can be accessed free at:  
<http://bjournal.com/cgi/content/full/83/3/327#BIBL>

6 online articles that cite this article can be accessed at:  
<http://bjournal.com/cgi/content/full/83/3/327#otherarticles>

### Rapid responses

You can respond to this article at:  
<http://bjournal.com/cgi/eletter-submit/83/3/327>

### Email alerting service

Receive free email alerts when new articles cite this article - sign up in the box at the top right corner of the article

---

### Topic collections

Articles on similar topics can be found in the following collections  
[Ophthalmology](#) (1575 articles)

---

### Notes

---

To order reprints of this article go to:  
<http://www.bmjournals.com/cgi/reprintform>

To subscribe to *British Journal of Ophthalmology* go to:  
<http://www.bmjournals.com/subscriptions/>

# A new surgical technique for deep stromal, anterior lamellar keratoplasty

Gerrit R J Melles, Frank Lander, Frank J R Rietveld, Lies Remeijer, W Houdijn Beekhuis, Perry S Binder

## Abstract

**Aims**—To describe a new surgical technique for deep stromal anterior lamellar keratoplasty.

**Methods**—In eye bank eyes and sighted human eyes, aqueous was exchanged by air, to visualise the posterior corneal surface—that is, the “air to endothelium” interface. Through a 5.0 mm scleral incision, a deep stromal pocket was created across the cornea, using the air to endothelium interface as a reference plane for dissection depth. The pocket was filled with viscoelastic, and an anterior corneal lamella was excised. A full thickness donor button was sutured into the recipient bed after stripping its Descemet’s membrane.

**Results**—In 25 consecutive human eye bank eyes, a 12% microperforation rate was found. Corneal dissection depth averaged 95.4% (SD 2.7%). Six patient eyes had uneventful surgeries; in a seventh eye, perforation of the lamellar bed occurred. All transplants cleared. Central pachymetry ranged from 0.62 to 0.73 mm.

**Conclusion**—With this technique a deep stromal anterior lamellar keratoplasty can be performed with the donor to recipient interface just anterior to the posterior corneal surface. The technique has the advantage that the dissection can be completed in the event of inadvertent microperforation, or that the procedure can be aborted to perform a planned penetrating keratoplasty.

(Br J Ophthalmol 1999;83:327-333)

Rotterdam Eye Hospital, Netherlands  
G R J Melles  
L Remeijer  
W H Beekhuis

Dutch Ophthalmic Research Center, Zuidland, Netherlands  
F Lander

Department of Pathology, University of Nijmegen, Netherlands  
F J R Rietveld

Vision Surgery and Laser Center, San Diego, USA  
P S Binder

Correspondence to:  
Gerrit R J Melles, MD,  
Rotterdam Eye Hospital,  
Schiedamse Vest 180, PO  
Box 70030, 3000 LM  
Rotterdam, Netherlands.

Accepted for publication  
28 September 1998

Anterior lamellar keratoplasty is a surgical procedure in which the anterior layers of the cornea (epithelium, its basement membrane, Bowman’s layer, and stroma) to a variable depth, are replaced by donor tissue.<sup>1-10</sup> Commonly, the anterior stroma is incised with a trephine that can be set to a depth not exceeding the corneal thickness. From the bottom of the incision, several corneal layers may be dissected until the desired depth of the recipient stromal bed is obtained.

Compared with a penetrating keratoplasty, a lamellar procedure has the advantage of avoiding most complications associated with “open sky” surgery, easier postoperative management, and less risk of allograft rejection and other long term complications. Despite these benefits, surgeons commonly perform a penetrating keratoplasty for anterior corneal disorders because the latter technique is easier to perform, and lamellar transplants often show decreased best corrected visual acuity owing to irregular astigmatism and/or scarring at the donor to recipient interface.<sup>11 12</sup> Less scarring may occur with deeper—that is, smoother keratectomies, and techniques such as air injection in, and hydrodelamination or photoablation of the posterior stroma have been advocated to obtain a deep recipient stromal bed.<sup>10 13-18</sup>

With all these techniques the stromal dissection depth relative to the corneal thickness cannot be optically visualised. The posterior corneal surface is invisible through an operating microscope, owing to the small difference in the refractive index between corneal tissue and aqueous.<sup>19</sup> Lamellar dissection techniques therefore bear the risk of inadvertent perforation when deeper dissections are intended. If perforation occurs completion of the stromal dissection can be difficult, so that the donor button may have to be sutured into an imperfectly prepared recipient bed. When conversion of the procedure into a penetrating keratoplasty is required, donor tissue with good quality endothelium may not be available.

The purpose of our study was to design a lamellar keratoplasty surgical technique in which a stromal dissection can be made to a visually controlled depth during surgery, and which allows for completion of the dissection in the event of a microperforation, or abortion of the entire procedure until a planned penetrating keratoplasty can be performed.

## Materials and methods

### HUMAN EYE BANK EYE MODEL

Sixty two human eye bank eyes were obtained through Bio Implant Services, Leiden, and the Cornea Bank of the Netherlands Ophthalmic Research Institute, Amsterdam. Thirty eyes

Table 1 Experimental and clinical corneas evaluated

Eye No	Recipient	Donor	Purpose and outcome
	Human eye bank eyes 1-5	—	Measurement of corneal dissection depth: 95.4% (SD 2.7%)
	Human eye bank eyes 6-30	Organ cultured corneas from eyes 31-55	Evaluation surgical procedure in vitro; 12% microperforation
	Patient eyes 1-7	Organ cultured corneas from eyes 56-62	Clinical evaluation surgical procedure (see Table 2)

(eyes 1–30; Table 1) were used to perform experimental surgical procedures. From 32 eyes (eyes 31–62; Table 1) corneoscleral buttons were excised less than 36 hours post mortem and stored by organ culture in modified minimum essential medium (EMEM) at 31°C, to act as “donor” tissue for transplantation to “recipient” eyes.<sup>20</sup>

Whole globes were placed in an eye holder for immobilisation and to control the intraocular pressure.<sup>21</sup> The epithelium was gently removed with a cellulose sponge. Corneas were dehydrated at an intraocular pressure of 50–60 mm Hg (Schiotz tonometer) at room temperature for 30–60 minutes until central corneal thickness was less than 0.65 mm (Pach-pen XL, Mentor, Norwell, MA, USA).<sup>21</sup>

#### PATIENTS

Seven patients enrolled in the study (Table 2), after institutional review board approved informed consent was obtained. Before and after surgery a complete ocular examination was performed, and central pachymetry measurements and slit lamp photographs were taken (Kodak Ektachrome 160T, colour slide film). Under local or general anaesthesia, corneal transplantation procedures (Fig 1) were performed by one of us (GM). At the end of each operation, 0.5 ml gentamicin sulphate (Garamycin 40 mg/ml, Schering-Plough, Weesp,

NL) and 1.0 ml betamethasone (Celestone 5.3 mg/ml, Schering-Plough, Weesp, NL) were injected subconjunctivally.

#### SURGICAL TECHNIQUE

##### Recipient

In all recipient eyes (eyes 6–30 and patients 1–7; Table 1), a self sealing side port was made at the 9 o'clock limbus, to aspirate the aqueous using a blunt canula, and to completely fill the anterior chamber with air. At the 12 o'clock limbus, the conjunctiva was opened and a superficial scleral incision was made, 5.0 mm in length, 1 mm outside the limbus. With a custom made dissection blade (Dorc, Zuidland, NL),<sup>22</sup> a lamellar dissection was made to just within the superior cornea. At this point, the tip of the blade was slightly tilted downward to visualise the interface between the air bubble in the anterior chamber and the corneal endothelium; underneath the corneal “dimple”, the “air to endothelium” interface was seen as a specular light reflex localised at the tip of the blade (Fig 2A).<sup>23</sup> Between the blade tip and the light reflex, a non-reflective, dark band was seen, representing the non-incised corneal tissue between the blade and the air to endothelium interface. Because the dark band became thinner with advancement of the blade into the deeper stromal layers, the corneal depth of the blade could be judged from the thickness of the dark band (Fig 2B). When the tip of the blade appeared to touch the air to endothelium light reflex (Fig 2C)—that is, the posterior corneal surface, the blade was positioned parallel to the posterior surface, for dissection of a stromal pocket across the cornea, just anterior to the posterior corneal surface (Figs 1A and 3A).

After a deep stromal pocket was created up to the limbus over 360°, the air was removed from the anterior chamber, and a viscoelastic (hydroxypropylmethylcellulose, Ocucoat, Storz, Clearwater, FL, USA) was injected through the scleral incision into the stromal pocket (Figs 1B and 3B). Thus, the posterior corneal lamella was separated from the overlying anterior stroma, to avoid perforation of the posterior corneal surface during trephination. Then, a Hessburg–Barron suction trephine was centred over the anterior corneal surface (Fig 3C). The blade was turned downward until the stromal pocket was just entered—that is, until viscoelastic was seen to escape from the pocket through the trephine incision. Remaining, unincised stromal attachments of the anterior lamella were cut with curved microscissors, the anterior corneal lamella was removed, and the recipient bed was thoroughly irrigated to remove all viscoelastic and debris (Figs 1C and 3D).

##### Donor

Corneoscleral rims were mounted endothelial side up on a concave punch block (Medical Workshop, De Meern, NL). With a dry cellulose sponge, the posterior corneal surface was gently swabbed, to remove Descemet's membrane and the endothelium. Then, a 0.25

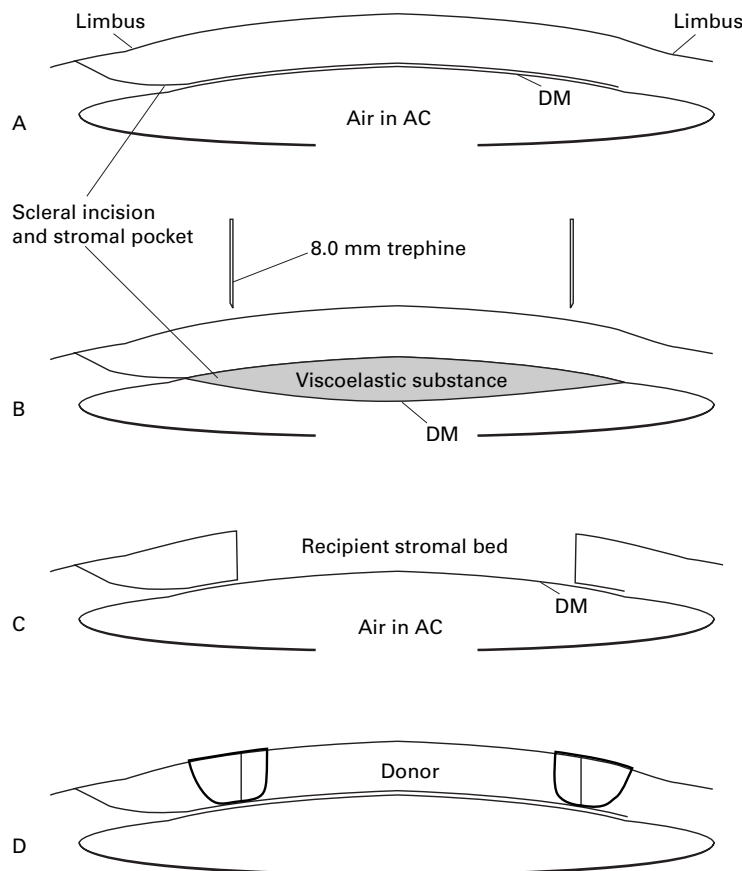
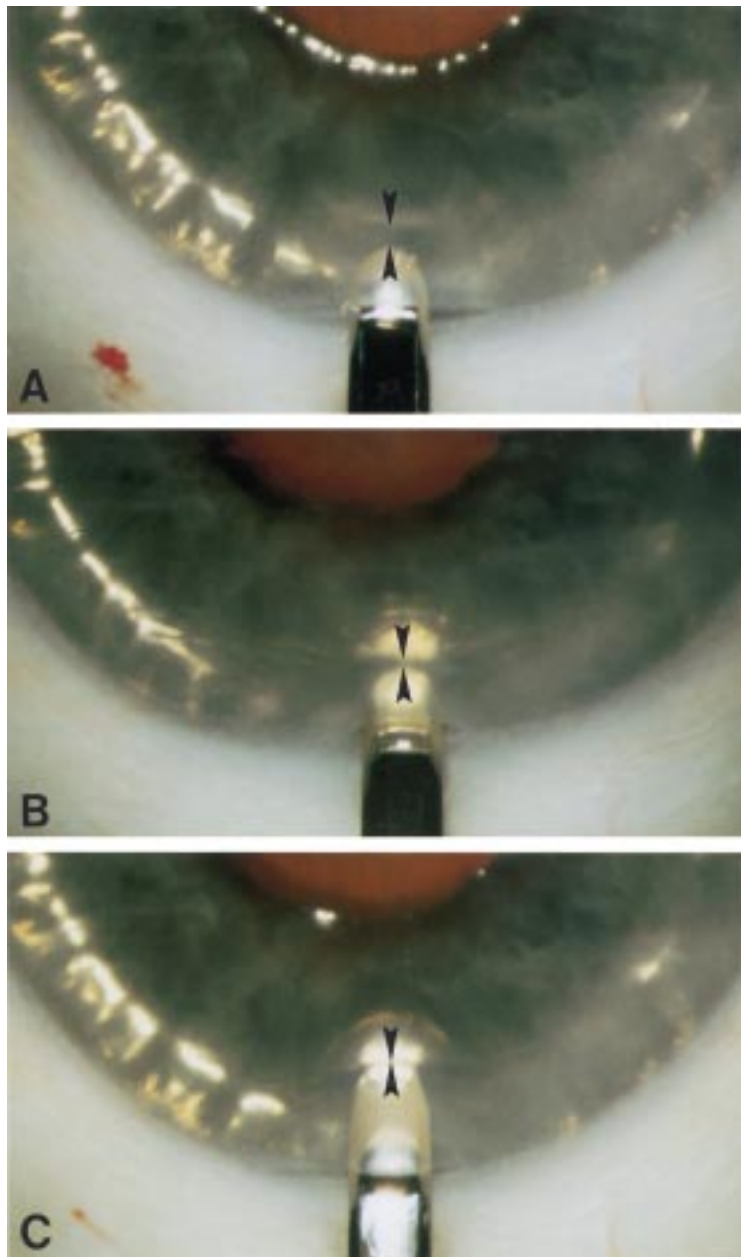


Figure 1 Diagrammatic representation of the deep, anterior lamellar keratoplasty technique. (A) After dissection of a deep stromal pocket through a scleral incision. (B and C) Viscoelastic is injected into the pocket, and an anterior corneal lamella is trephinated from the recipient cornea. (D) After stripping Descemet's membrane, a full thickness donor corneal button is sutured into the recipient stromal bed. Compare with Figures 2A–C and 3A–E



**Figure 2** Demonstration of the surgical technique in a human eye bank eye. (A) The anterior chamber has been filled with air. In between the blade tip and the air to endothelial interface light reflex, a dark band (arrowheads) is visible. (B) Because the dark band reflects unincised posterior corneal tissue, the dark band decreases in width when the blade is advanced into the deeper stromal layers. (C) When the blade appears to touch the air to endothelium interface, a stromal dissection level just anterior to the posterior corneal surface is reached.

or 0.5 mm oversized donor corneal button was punched out with a punch trephine (Ophtec, Groningen, NL).

The donor button was transferred to the recipient stromal bed, and the donor and recipient corneal surfaces were marked with an eight incision radial keratotomy marker (Fig 3E). The button was sutured into the recipient bed with two running, 10-0 monofilament nylon sutures (Alcon, Gorinchem, Netherlands) (Fig 3F). The tension of the sutures was adjusted until the anterior, donor corneal surface reflected a spherical image of a placido disc held about 3 cm above the recipient eye.

In human eye bank eyes 1–5, designated to evaluate corneal dissection depth (Table 1), a deep stromal pocket was made as described above. Indian ink was injected into the pocket to facilitate the identification of the pocket with subsequent light microscopy (Figs 4A and B).<sup>21 22</sup>

#### Microscopy

Corneoscleral buttons from human eye bank eyes 1–5 (Table 1) were fixed in neutral buffered 10% formaldehyde. Specimens were dehydrated through a graded series of ethanol followed by intermediate changes of methylbenzoate and xylene, and embedded in paraffin. Five  $\mu\text{m}$  sections were cut along the vertical meridian; sections were stained with haematoxylin and eosin, and photographed at  $\times 35$  and  $\times 450$  magnification (Vanox light microscope, Olympus Optical Co Ltd, Tokyo, Japan; Ektachrome 64 colour slide film, Kodak).<sup>22 23</sup>

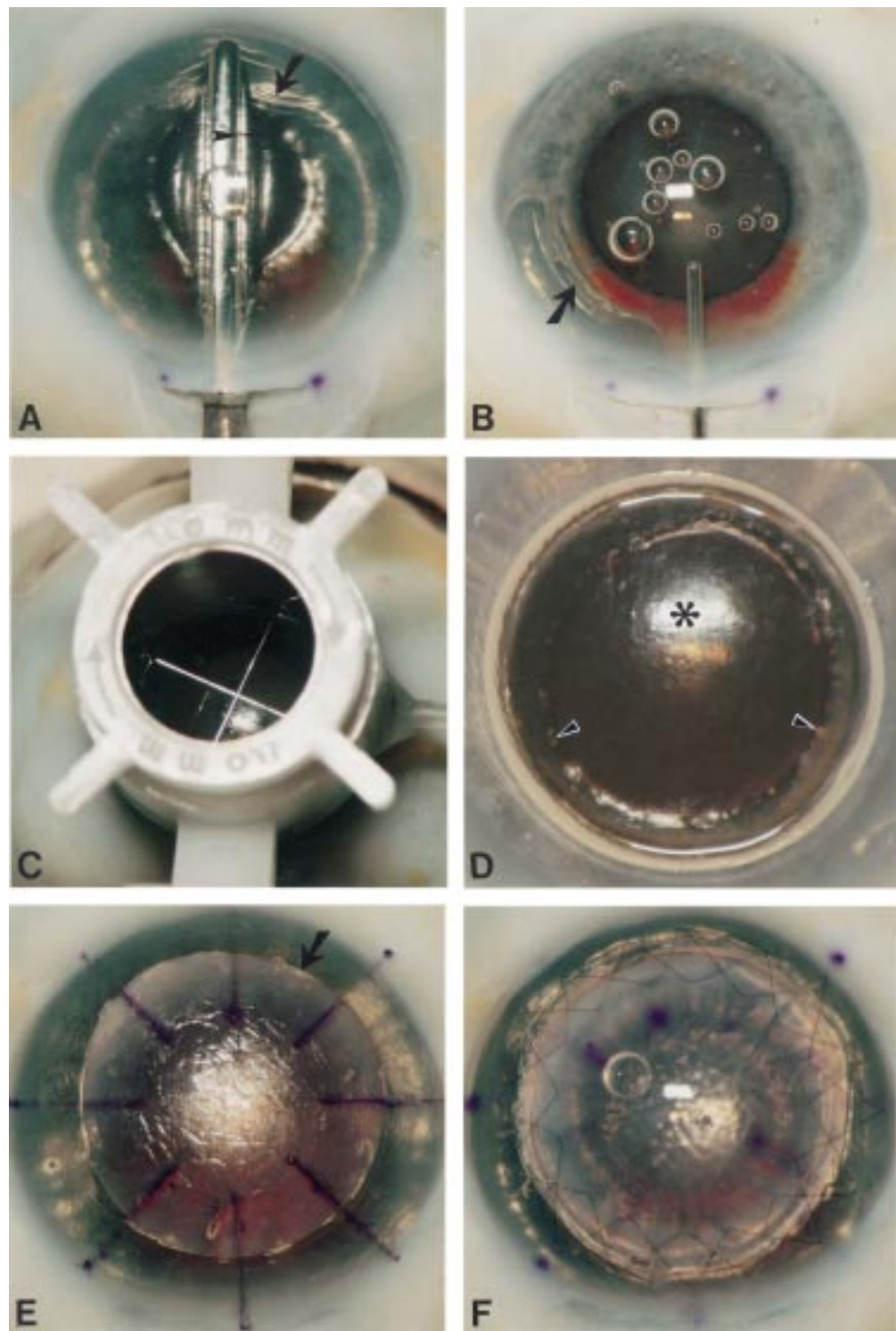
To evaluate the achieved corneal dissection depth, photomicrographs had a line drawn parallel to Bowman's layer, a second line at the level of the stromal dissection, and a third line at the junction of Descemet's membrane and the endothelium. Using these lines, measurements of the relative dissection depth were taken (Table 1).<sup>21–23</sup>

#### Results

The surgical procedure was completed in 25 consecutive human eye bank eyes (eyes 6–30; Table 1). In three eyes (12%) a microperforation occurred while the deep lamellar dissection was made. Microperforations were noted by the escape of air from the anterior chamber into the stromal pocket. In these eyes, the dissection could be completed across the cornea, after restoring the intraocular pressure by injection of additional air in the anterior chamber. Corneal dissection depth averaged 95.4% (SD 2.7%), as measured with light microscopy in eyes 1–5 (Figs 4A and B; Table 1).

Six of seven patients' eyes underwent uneventful surgeries (patients 1–4, 6, and 7; Table 2). In one eye (patient 5; Table 2), a perforation of the recipient, central stromal bed occurred after the removal of the recipient anterior lamella. To avoid central interface scarring and the potential development of an intrastromal "pseudoanterior chamber" after surgery, the procedure was converted into a penetrating keratoplasty. At the first postoperative day, one eye (patient 3; Table 2) had a layer of residual viscoelastic in the stromal interface. Because the viscoelastic was still present 1 month after surgery, it was removed by irrigation of the interface after partial removal of the donor button, and the button was sutured back in place.

Throughout the postoperative period, all eyes had clear transplants (Fig 5). Patients who had a deep lamellar keratoplasty (patients 1–4, 6, and 7; Table 2) maintained apposition of the donor and recipient stromal surfaces, with minimal interface scarring. For these eyes, best corrected visual acuity ranged from 0.25 to 1.0, and the astigmatic error ranged from 1 to 3.5 D. Central pachymetry ranged



**Figure 3** Demonstration of the surgical technique in a human eye bank eye. (A) The pocket is dissected first across the vertical meridian, and then extended sideways up to the limbus over 360°, with the same spatula. Note that the anterior chamber is completely filled with air, and that the dissection depth can be monitored by the width of the dark band (arrowhead) in between the spatula and the air to endothelium light reflex. Note also the wrinkling of the posterior corneal tissue (arrow). (B) After most air has been removed from the anterior chamber, the stromal pocket is filled with viscoelastic. Note the step ladder configuration of the relaxed posterior corneal tissue (arrow) which is pushed downward. (C) After trephination with a Hessburg–Barron trephine (D) an anterior corneal lamella is excised. Note the smooth recipient bed (asterisk) with some residual posterior stroma overlying the pupillary border (arrowheads). Pupillary dilatation was not intended as a part of the procedure. (E) After stripping Descemet's membrane, a "full thickness" donor button (arrow) is placed onto the recipient bed, and the donor and recipient corneal surfaces are marked with an eight incision radial keratotomy marker. (F) The donor button sutured in place with two running sutures. Pupillary dilatation was not an intended part of the procedure.

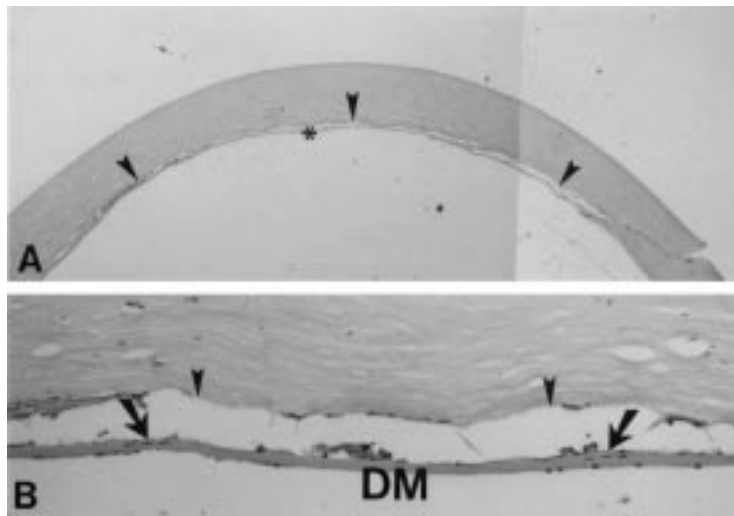


Figure 4 Light microscopy of a deep lamellar dissection through a scleral incision in a human eye bank eye. (A) A deep stromal dissection level (arrowheads) is seen (98% corneal depth). (B) Few stromal lamellae (arrows) are visible between the stromal dissection and Descemet's membrane; the dotted line indicates the junction of the stroma and Descemet's membrane (haematoxylin and eosin, original magnification  $\times 35$  and  $\times 450$ ).

from 0.62 to 0.73 mm, without evidence of epithelial or stromal oedema. One eye (patient 4; Table 2) that had been operated for keratoconus, had a meshwork-like wrinkling of Descemet's membrane which appeared to smooth with time.

### Discussion

Several lamellar keratoplasty dissection techniques have been described.<sup>1-10 13-18</sup> One flaw of these techniques is that the depth of the stromal dissection cannot be visualised during surgery, and that the procedures therefore bear the risk of perforation. Another flaw is that the recipient bed is created by a "layer for layer" removal of corneal tissue. Once started, the procedure must be completed as a lamellar or penetrating keratoplasty, although donor tissue requirements differ for each of these procedures. In lamellar keratoplasty, a donor corneal lamella is generally obtained from a fresh globe with unknown endothelial quality, or lyophilised corneal tissue. When the dissection of the recipient stromal bed cannot be completed owing to inadvertent perforation, donor tissue with good quality endothelium

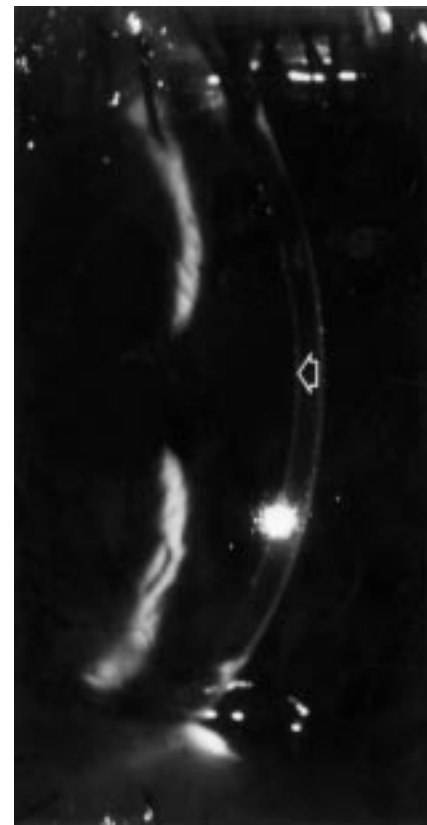


Figure 5 Slit lamp photograph 6 months (patient eye 1) after deep, anterior lamellar keratoplasty. A clear lamellar corneal transplant is visible, with a deep stromal, donor to recipient interface (arrow).

may not be available to convert to a penetrating keratoplasty. Alternatively, the donor lamella may be sutured into an imperfect recipient stromal bed, or the recipient lamella may be sutured back to perform a lamellar keratoplasty after the perforation site has healed.

In the current study, a three step surgical technique is described to perform a deep stromal, anterior lamellar keratoplasty procedure, in which the depth of the dissection relative to the corneal thickness can be visualised during surgery.<sup>23</sup> Furthermore, the procedure can be completed in the event of a microperforation, or it can be aborted to perform a planned penetrating keratoplasty. As a first step, a deep

Table 2 Patient data

Patient No	Age, sex	Eye	Indication keratoplasty	Surgical procedure*	Complications	Follow up (months)	BCVA	Spherical equivalent (D)	Keratometry (D)	Slit lamp	Pachymetry (mm)
1	48, F	L	Recurrence granular dystrophy in LKP	DALK 8.5/8.0 mm	None	9	1.0 (cl)	+1.0 (preop +2.0)	43.00/ 44.00	Clear	0.62
2	53, M	R	Quiet scar (after HSV)	DALK 8.75/8.5 mm	None	6.5	0.7 (cl)	+6.0 (preop 0.0)	36.00/ 39.50	Clear	0.66
3	54, M	L	Quiet scar (after bacterial ulcer)	DALK 8.75/8.5 mm	Viscoelastic at interface	6	1.0 (cl)	-6.0 (preop -10.0)	41.00/ 43.00	Clear	0.73
4	52, M	L	Keratoconus	DALK 9.25/9.0 mm	None	5.5	0.25 (sp)	0.0 (preop 0.0)	45.00/ 48.00	Clear	0.71
5	41, F	R	Keratoconus	PKP 7.75/7.5 mm	Perforation	4	—	—	—	Clear	—
6	34, F	L	Quiet scar (unknown cause)	DALK 8.75/8.5 mm	None	3	0.7 (sp)	-0.25 (preop +0.75)	41.50/ 42.00	Clear	0.62
7	28, F	L	Keratoconus	DALK 8.75/8.5 mm	None	0	nr	nr	nr	Clear	nr

\*DALK = deep, anterior lamellar keratoplasty; PKP = penetrating keratoplasty.  
BCVA = best corrected visual acuity with hard contact lens (cl) or spectacles (sp).  
nr = not recorded.

stromal, lamellar dissection is made to a visually controlled depth. Injection of air into the anterior chamber may facilitate deep stromal dissection for four reasons. Firstly, because the air to endothelium interface reflects the posterior corneal surface, its specular light reflex may be used as a reference plane for desired dissection depth. When the dissection blade is tilted slightly downward, the non-incised corneal tissue between the tip of the blade and the posterior corneal surface is visible as a dark band directly adjacent to the blade, and bordered by the air to endothelium light reflex. Because the thickness of the dark band decreases with deeper stromal blade depth, the light reflex can be used as a reference plane to direct the blade towards the posterior corneal surface—that is, to advance the blade downward until the dark band has disappeared.

Secondly, small folds in Descemet's membrane can be seen during the performance of deep stromal dissections. When the anterior chamber is filled with air, these folds are accentuated, and the number, width, and motility of the folds seem to indicate how close to Descemet's membrane the dissection is made. Thirdly, microperforations are easily noted during surgery, since a small air bubble is seen to escape from the anterior chamber into the stromal pocket, and the break in Descemet's membrane is sharply outlined over the underlying air bubble. Fourthly, in the event of a microperforation, the break in Descemet's membrane is self sealing by the air in the anterior chamber, and the dissection may be continued without loss of the intraocular pressure. As in conventional lamellar keratoplasty, the presence of a perforation site could be complicated by the formation of an intrastromal pseudoanterior chamber after surgery.

As a second step of the procedure, viscoelastic is injected into the stromal pocket to displace the entire posterior corneal surface toward the iris, thereby creating a "pseudo-anterior chamber". Because the stromal pocket is made through a self sealing scleral tunnel incision, the viscoelastic remains within the pocket when pressure is applied onto the anterior corneal surface. Thus, a "normal" intraocular pressure can be restored after the injection of viscoelastic into the stromal pocket, and the anterior, diseased recipient corneal tissue may be excised with routine trephination techniques, without damage to the posterior corneal surface. In one of our patients, residual viscoelastic remained in the stromal interface after surgery. After removal, the best corrected visual increased from finger counting to 0.4 in the first postoperative week. It seems therefore important to completely remove all viscoelastic at the recipient stromal bed before suturing the donor corneal button in place.

As a third step, a donor button is transplanted into the recipient bed using standard keratoplasty surgical instruments and techniques. After the deep keratectomy, the recipient wound edges are approximately 95% in stromal depth, and a full thickness donor button is sutured into

the recipient opening.<sup>5</sup> When the donor tissue thickness exceeds the depth of the recipient bed, the donor button still fits because the peripheral recipient cornea is split while the dissection is made, and the excess thickness of the button only causes little separation of the recipient, posterior stromal layers.

To obtain a safe method of dissection across the cornea, and to enable insertion of the instrument through a small incision, a spatula knife was designed with a semi-sharp, rounded tip, but sharp edges.<sup>22-24</sup> The tip of the blade can be used for dissection from a scleral or peripheral corneal incision toward the opposite limbus, and the pocket can be enlarged by moving the spatula sideways. Compared with the existing techniques for lamellar keratoplasty, our technique may offer the advantage that a smoother recipient stromal surface can be obtained, that may reduce the risk of interface scarring. To also obtain a smooth posterior stromal surface of the donor, and to remove the potential antigenic endothelium, Descemet's membrane was stripped from the donor button.<sup>18 25</sup>

Compared with the current technique for lamellar keratoplasty, a disadvantage of our technique is that the anterior chamber has to be opened for an aqueous to air exchange before performing a corneal dissection. It therefore bears a risk of intraocular infection and damage to the anterior chamber structures. The recipient endothelium may be damaged by inflating the anterior chamber with air, and/or performing a deep stromal dissection.<sup>26 27</sup> In our ongoing clinical study, preoperative and long term postoperative endothelial cell counts are performed to determine how endothelial cell loss with our technique compares with that after existing deep lamellar keratoplasty techniques, for which a 13% cell loss at 1 year has been reported.<sup>18</sup>

Since the 1960s, lamellar keratoplasty may have lost its popularity owing to the imperfections of the existing surgical techniques rather than poor visual outcomes. Although better microkeratomes have become available with the development of laser assisted in situ keratomileusis (LASIK), microkeratome lamellar resections cannot be used for disorders with deep stromal opacities, variable corneal thickness, and surface irregularities. Improvement of the manual technique for lamellar keratoplasty could therefore potentially broaden the interest for the procedure again, to manage anterior corneal disorders.

Sponsored by a grant for the Van Loenen Martinet Corneal Fellowship from the Rotterdamse Vereniging voor Blindenbelangen.

We thank the Cornea Bank of the Netherlands Ophthalmic Research Institute, Amsterdam, Netherlands; and Bio Implant Services, Leiden, Netherlands, for their valuable cooperation.

- 1 Polack FM. Lamellar keratoplasty. Malbran's "peeling off" technique. *Arch Ophthalmol* 1971;86:293-5.
- 2 Barraquer JL. Lamellar keratoplasty (special techniques). *Ann Ophthalmol* 1972;4:437-69.
- 3 Anwar M. Dissection technique in lamellar keratoplasty. *Br J Ophthalmol* 1972;56:711-13.
- 4 Gasset AR. Lamellar keratoplasty in the treatment of keratoconus: conectomy. *Ophthalmic Surg* 1979;10:26-33.

- 5 Morrison JC, Swan KC. Full-thickness lamellar keratoplasty. A histologic study in human eyes. *Ophthalmology* 1982;**89**:715-19.
- 6 Barraquer J, Rutllán J, eds. Technique for lamellar keratoplasty. In: *Microsurgery of the cornea*. Barcelona: Ediciones Scriba, 1984:195-212.
- 7 Rich LF, MacRae SM, Fraunfelder FT. An improved method for lamellar keratoplasty. *CLAO J* 1988;**14**:42-6.
- 8 Ehrlich MI, Phinney RB, Mondino BJ, et al. Techniques of lamellar keratoplasty. *Int Ophthalmol Clin* 1988;**28**:24-9.
- 9 Bessant DAR, Dart JKG. Lamellar keratoplasty in the management of inflammatory corneal ulceration and perforation. *Eye* 1994;**8**:22-8.
- 10 Krumeich JH, Daniel J. Lebend-Epikeratophakie und Tiefe Lamelläre Keratoplastik zur Stadiengerechten chirurgischen Behandlung des Keratokonus (KK) I-III. *Klin Monatsbl Augenheilkd* 1997;**211**:94-100.
- 11 Richard JM, Paton D, Gasset AR. A comparison of penetrating keratoplasty and lamellar keratoplasty in the surgical management of keratoconus. *Am J Ophthalmol* 1978;**86**:807-11.
- 12 Lyons CJ, McCartney AC, Kirkness CM, et al. Granular dystrophy. Visual results and pattern of recurrence after lamellar or penetrating keratoplasty. *Ophthalmology* 1994;**101**:1812-17.
- 13 Archila EA. Deep lamellar keratoplasty dissection of host tissue with intrastromal air injection. *Cornea* 1984/85;**3**:217-18.
- 14 Price FW. Air lamellar keratoplasty. *Refract Corneal Surg* 1989;**5**:240-3.
- 15 Chau GK, Dilly SA, Sheard CE, et al. Deep lamellar keratoplasty on air with lyophilised tissue. *Br J Ophthalmol* 1992;**76**:646-50.
- 16 Benson WH, Goosey CB, Prager TC, et al. Visual improvement as a function of time after lamellar keratoplasty for keratoconus. *Am J Ophthalmol* 1993;**116**:207-11.
- 17 Eckhardt HB, Hutz WW, Heinrich AW, et al. Lamellierende Keratoplastik mit dem Excimerlaser. Erste klinische Ergebnisse. *Ophthalmologie* 1996;**93**:242-6.
- 18 Sugita J, Kondo J. Deep lamellar keratoplasty with complete removal of pathological stroma for vision improvement. *Br J Ophthalmol* 1997;**81**:184-8.
- 19 Katz M. The human eye as an optical system. In: Tasman W, Jaeger AE, eds. *Duane's clinical ophthalmology*. Vol 1, Chapter 33. Philadelphia: JB Lippincott, 1993.
- 20 Pels E, Schuchard Y. Tissue storage. E: Organ culture and endothelial evaluation as a preservation method for human corneas. In: Brightbill FS, ed. *Corneal surgery. Theory, technique, and tissue*. St Louis: CV Mosby, 1986:93-102.
- 21 Melles GRJ, Wijdh RHJ, Cost B, et al. Effect of blade configuration, knife action, and intraocular pressure on keratotomy incision depth and shape. *Cornea* 1993;**12**:299-309.
- 22 Melles GRJ, ten Hoope GW, Rietveld FJR, et al. Depth predictability of stromal pockets in the posterior cornea. *Cornea* 1998;**17**:174-9.
- 23 Melles GRJ, Rietveld FJR, Beekhuis WH, et al. A technique to visualize corneal incision and lamellar dissection depth during surgery. *Cornea* (in press).
- 24 Melles GRJ, Lander F, Rietveld FJR, et al. A surgical technique for posterior lamellar keratoplasty. *Cornea* 1998;**17**:618-26.
- 25 Khoudadoust AA, Siverstein AM. Transplantation and rejection of individual layers of the cornea. *Invest Ophthalmol* 1969;**8**:180-95.
- 26 Eiferman RA, Wilkins EL. The effect of air on human corneal endothelium. *Am J Ophthalmol* 1981;**92**:328-31.
- 27 Kim EK, Cristol SM, Geroski DH, et al. Corneal endothelial damage by air bubbles during phacoemulsification. *Arch Ophthalmol* 1997;**115**:81-8.