



A consanguineous family with Hirschsprung disease, microcephaly, and mental retardation (Goldberg-Shprintzen syndrome)

Alice S Brooks, Martijn H Breuning, Jan Osinga, Jasper J vd Smagt, Corine E Catsman, Charles H C M Buys, Carel Meijers and Robert M W Hofstra

J. Med. Genet. 1999;36;485-489

Updated information and services can be found at:
<http://jmg.bmj.com/cgi/content/full/36/6/485>

These include:

References

This article cites 32 articles, 6 of which can be accessed free at:
<http://jmg.bmj.com/cgi/content/full/36/6/485#BIBL>

4 online articles that cite this article can be accessed at:
<http://jmg.bmj.com/cgi/content/full/36/6/485#otherarticles>

Rapid responses

You can respond to this article at:
<http://jmg.bmj.com/cgi/eletter-submit/36/6/485>

Email alerting service

Receive free email alerts when new articles cite this article - sign up in the box at the top right corner of the article

Topic collections

Articles on similar topics can be found in the following collections

[Genetics](#) (3948 articles)

Notes

To order reprints of this article go to:
<http://www.bmjournals.com/cgi/reprintform>

To subscribe to *Journal of Medical Genetics* go to:
<http://www.bmjournals.com/subscriptions/>

A consanguineous family with Hirschsprung disease, microcephaly, and mental retardation (Goldberg-Shprintzen syndrome)

Alice S Brooks, Martijn H Breuning, Jan Osinga, Jasper J vd Smagt, Corine E Catsman, Charles H C M Buys, Carel Meijers, Robert M W Hofstra

Department of Clinical Genetics, Erasmus University and University Hospital, Rotterdam, The Netherlands
A S Brooks
M H Breuning

Department of Paediatric Surgery, Erasmus University and University Hospital, Rotterdam, The Netherlands
A S Brooks
C Meijers

Department of Clinical Genetics, University Hospital Leiden, The Netherlands
M H Breuning
J J vd Smagt

Department of Medical Genetics, University of Groningen, The Netherlands
J Osinga
C H C M Buys
R M W Hofstra

Department of Child Neurology, Erasmus University and University Hospital, Rotterdam, The Netherlands
C E Catsman

Department of Cell Biology and Genetics, Erasmus University and University Hospital, Rotterdam, The Netherlands
C Meijers

Correspondence to:
Dr Meijers, Department of Cell Biology and Genetics, Erasmus University, PO Box 1738, 3000 DR Rotterdam, The Netherlands.

Received 10 June 1998
Revised version accepted for publication 22 October 1998

Abstract

Hirschsprung disease, mental retardation, microcephaly, and specific craniofacial dysmorphism were observed in three children from a large, consanguineous, Moroccan family. A fourth child showed similar clinical features, with the exception of Hirschsprung disease. The association of these abnormalities in these children represents the Goldberg-Shprintzen syndrome (OMIM 235730).

Mutation scanning of genes potentially involved in Hirschsprung disease, RET, GDNF, EDN3, and EDNRB, showed a sequence variant, Ser305Asn, in exon 4 of the EDNRB gene in the index patient of this family. The Ser305Asn substitution present in two of the four patients and four healthy relatives and absent in one of the remaining two patients illustrates the difficulties in interpreting the presence of mutations in families with Hirschsprung disease. It is unlikely that the EDNRB variant contributes to the phenotype. This consanguineous family might be useful for the identification of a Goldberg-Shprintzen locus.

(*J Med Genet* 1999;36:485-489)

Keywords: Hirschsprung disease; microcephaly; mental retardation; EDNRB variant

Hirschsprung disease (HSCR) is a congenital disorder characterised by the absence of ganglion cells from the bowel wall. The estimated incidence is 1 in 5000 live born children. Boys are affected four times as often as girls. Additional anomalies, mostly of the heart and kidneys, occur in 10-30%.^{1,2} HSCR is a variable feature in a large number of monogenic syndromes, such as Waardenburg syndrome, cartilage-hair hypoplasia syndrome, Smith-Lemli-Opitz syndrome, Nager acrofacial dysostosis, Kaufman-McKusick syndrome, Bardet-Biedl syndrome, and primary hypoventilation syndrome (Ondine-Hirschsprung disease).³⁻⁷ This variety of syndromes associated with HSCR implies considerable genetic heterogeneity in the aetiology of HSCR, although some of these syndromal associations may be through chance.

Traditionally, HSCR as an isolated entity is viewed as having a complex inheritance and being transmitted as a sex modified multifactorial trait. However, clear autosomal dominant and autosomal recessive inheritance have been

reported.⁸ Mutations in five genes have been implicated in isolated or syndromic HSCR: RET,^{9,10} which encodes a receptor tyrosine kinase and its ligand, glial cell line derived neurotrophic factor (GDNF),^{11,12} EDNRB, the gene encoding the endothelin B receptor,¹³ and endothelin 3 (EDN3), one of its ligands.^{14,15} Homozygous mutations in the latter two genes are associated with HSCR, pigmentary abnormalities, and deafness (Shah-Waardenburg syndrome). A similar phenotype is associated with heterozygous mutations in the SOX10 gene.¹⁶ RET mutations have been observed in approximately 50% of familial cases and 10-30% of sporadic cases. Mutations of EDNRB, EDN3, and GDNF have been reported in only a few cases.¹⁷

Here we describe a syndrome consisting of HSCR, mental retardation, microcephaly, and dysmorphic features in four patients of a large, consanguineous, Moroccan family. These phenotypic features are consistent with Goldberg-Shprintzen syndrome. A rare EDNRB variant was found, not cosegregating with the phenotype.

Case reports

Patient VI.1 is the first daughter of a consanguineous Moroccan couple; their maternal grandmothers were sisters (fig 1). After premature rupture of the membranes, there was spontaneously delivery at 40 weeks of gestation; her birth weight was 3280 g (50th centile) and occipitofrontal circumference (OFC) 33 cm (3rd centile). She was admitted to our hospital because passing of meconium was delayed and she had feeding problems. Short segment HSCR was diagnosed. She had a temporary colostomy at 2 weeks of age and intestinal reconstruction at the age of 6.5 months. At 2 weeks of age, she showed telecanthus (her ICD was 2.7 cm (>97th centile) and OCD 7 cm (75th-97th centile)), a prominent nasal bridge, tapering fingers, and widely spaced nipples. Involuntary movements of the head started from 3 months of age. She was able to sit without support at the age of 7 months, but showed titubation of the head when seated or vertically suspended. An MRI scan of the brain at 9 months of age showed a slight general brain atrophy with delayed myelinisation. At 2 years, she manifested the described dysmorphism, progressive microcephaly, mildly downward slanting palpebral fissures, a flat occiput, short philtrum, and large ears. At the age of 26 months, her development is retarded and is equivalent to a chronological age of 14 months.

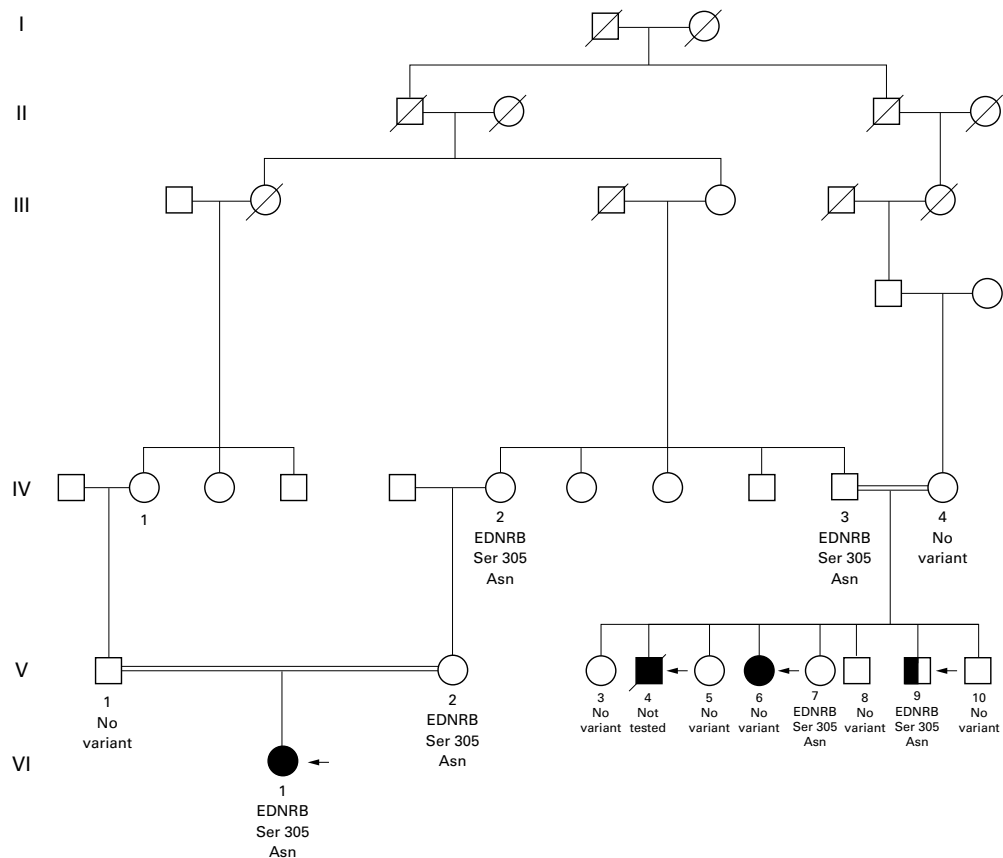


Figure 1 Pedigree of family. Subjects with the Goldberg-Shprintzen phenotype are indicated by blackened symbols. Patients VI.1, V.4, and V.6 have histologically proven Hirschsprung disease. V.9 has microcephaly, mental retardation, and characteristic facial abnormalities, but no Hirschsprung disease.

Patient V.4 was the second child of a consanguineous couple. The boy's father (IV.3) is the brother of the maternal grandmother of the case described above. Pregnancy and delivery (at 38 weeks) were uneventful. Birth weight was not recorded and OFC was 33.5 cm (3rd-10th centile). A broad nasal bridge, low set ears, and a short neck were reported. Failure to pass meconium and vomiting were indications for referral to the Department of Paediatric Surgery. Long segment HSCR was diagnosed and an ileostomy was made. He died from complications of sepsis at the age of 3 weeks. Necropsy was not permitted. He had a normal 46,XY karyotype.

Patient V.6, a 12 year old girl, is the fourth child of this couple. She was born at term after an uneventful pregnancy. Her birth weight was 4000 g (50th-97th centile) and OFC was 33.5 cm (3rd-50th centile). A lesion of the right inferior part of the brachial plexus or Erb-Duchenne palsy was noted. From 2 months of age, she developed progressive constipation, which prompted admission to our department. Her abdomen was distended. A barium enema was suggestive of HSCR. Absence of ganglion cells and increased acetylcholinesterase staining in nerve fibres were found at biopsy. A low anterior resection with a primary anastomosis was performed. The postoperative course was uncomplicated.

At the age of 5 months, the child neurologist saw her for suspected psychomotor retardation, microcephaly (OFC 39 cm, 3rd centile),

and a mild convergent strabismus. BERA (brain stem evoked response audiometry) and VEP (visual evoked potential) showed no overt abnormalities. Brain CT at the age of 5 years showed a slight asymmetry of the lateral ventricles and a hypoplastic septum pellucidum. The karyotype was 46,XX. Dysmorphological evaluation at 5 years (fig 2) showed high arched eyebrows, dense curled eyelashes, a broad nasal bridge, blue sclerae, large corneae (corneal diameter 13.5 mm), a mild thoracic scoliosis, mild syndactyly of digits II and III, and a broad hallux. She has mental retardation and a severe conductive hearing loss, related to therapy resistant middle ear infections. Follow up at 6, 8, and 11 years (fig 2) showed height following the 3rd centile and head circumference paralleling the 3rd centile. Progressive scoliosis and proximal muscle weakness were noted from 10 years of age. Lung function showed a strongly reduced vital capacity, not proportional to the severity of the kyphoscoliosis. Recurrent corneal infections suggested a primary corneal hypoaesthesia.

The seventh child (V.9) was born after a healthy girl and boy. Caesarean section was indicated because of a transverse lie. His birth weight was 4115 g (90th centile). When he was 8 months, the parents noticed developmental delay and remarkable physical resemblance to their older daughter (V.6) (fig 2). His OFC was 42 cm (<3rd centile). He had dense eyebrows with mild synophrys, a broad nasal bridge, low set ears, and large corneae (corneal diameter

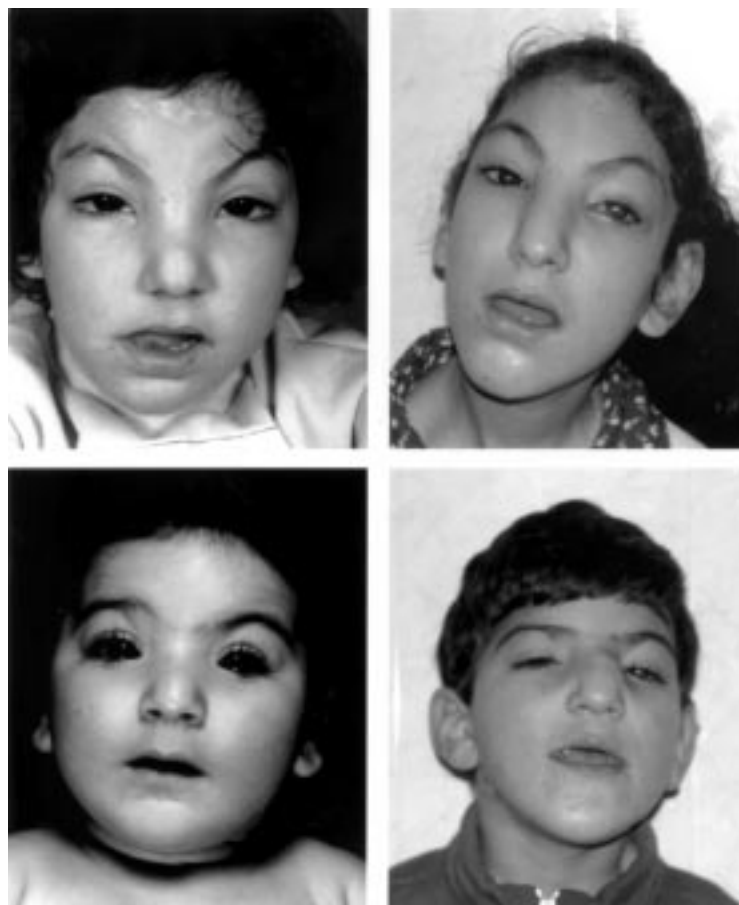

Figure 2 (Above) Patient V6 at 5 years and 12 years. Note hypertelorism and curled eyelashes and clouding of the cornea at the age of 12 years. (Below) Patient V9 at 8 months and 7 years. Note hypertelorism, synophrys, and curled eyelashes. Clouding of the cornea is present.

14.5 mm) with blue sclerae. Hypotonia and slipping through on vertical suspension were present. At the age of 13 months his height was 75 cm (10th-25th centile), OFC 43 cm (2 cm <3rd centile), ICD 3.2 cm (>97th centile), and OCD 8.8 cm (>97th centile). He had telecanthus, downward slanting palpebral fissures,

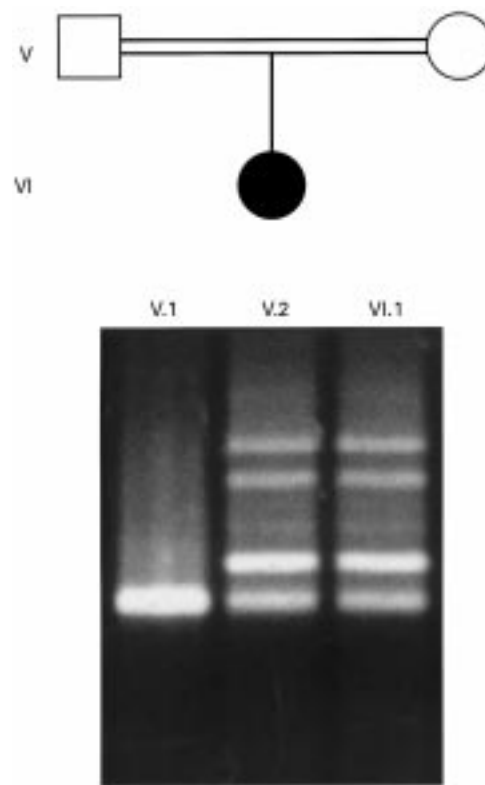


Figure 3 DGGE analysis of EDNRB exon 4. PCR products were amplified from genomic DNA from patient VI.1 (lane 3), her father V.1 (lane 1), and mother V.2 (lane 2). A mobility shift was found in the patient and her mother. Sequencing of PCR products showed the Ser305Asn substitution. Both mother and patient are heterozygous.

broad nasal bridge with a bulbous nose, a high arched palate with a bifid uvula, and large anteverted ears. His thumbs were short and broad and his toes overlapped. He had corneal hypoaesthesia and recurrent corneal infections (fig 2). Defecation was reportedly normal. Brain imaging was not performed. Table 1 lists the phenotypic features of all four patients.

Table 1 Phenotypic features in four Goldberg-Shprintzen syndrome patients

	Case 1 VI.1	Case 2 V.4	Case 3 V.6	Case 4 V.9
HSCR	SS-HSCR	TCA	SS-HSCR	No HSCR
Mental retardation	+	?	+	+
Hypotonia	+	?	-	-
Microcephaly	+	+	+	+
Brain scan	Abnormal	?	Abnormal	?
Arched, dense eyebrows	+	?	+	+
Curled eyelashes	+	?	+	+
Synophrys	+	?	+	+
Hypertelorism	+	?	+	+
Corneal ulcer	-	?	+	+
Megalocornea	?	?	+	+
Wide nasal bridge	+	+	+	+
Bulbous nasal tip	+	?	+	+
Anteverted ears	+	+	+	+
Bifid uvula	-	?	?	+
Anteverted ears	+	+	+	+
Toes			Broad hallux	Overlapping
Skeletal abnormalities	-	?	Scoliosis	-
Ataxia of the head	+	?	-	-
Karyotype	46,XX	46,XY	46,XX	46,XY
DNA analysis	S305N	?	-	S305N

TCA = total colonic aganglionosis.
 SS-HSCR = short segment Hirschsprung disease.
 ? = not evaluated/described.
 + = present.
 - = absent.

LABORATORY STUDIES

All four patients appeared to have a normal karyotype. DNA was isolated from leucocytes prepared according to standard methods. DGGE analysis of all exons of RET, GDNF, EDNRB, and EDN3 was performed on the index patient VI.1 as described before (R M W Hofstra and J Osinga).^{14 18} Apart from known neutral variants, a similar mobility shift of exon 4 of EDNRB was detected in index patient VI.1 (fig 3). Sequencing showed a G to A transition that at the amino acid level results in the replacement of a serine by an asparagine (Ser305Asn). On screening 12 available family members (IV.2, IV.3, IV.4, V.1, V.2, V.3, V.5, V.6, V.7, V.8, V.9, and V.10), five (IV.2, IV.3, V.2, V.7, and V.9) were found to be carriers of the EDNRB variant. The Ser305Asn substitution was not identified in 100 (unselected) HSCR patients or 70 healthy Dutch controls (140 chromosomes). However, we did not genotype unrelated Moroccan subjects for this substitution.

Discussion

The dysmorphic features in these four patients closely resemble the syndrome described by Goldberg and Shprintzen¹⁹ in 1981 and later by others.²⁰⁻²⁴ Common features in reported cases were microcephaly, mental retardation, distinctive face, and HSCR. Goldberg and Shprintzen¹⁹ only reported submucous cleft palate. Coloboma of the iris was not always present.^{19, 20} An autosomal recessive mode of inheritance was suggested, based upon two sibs in one pedigree with unaffected parents and one consanguineous pedigree. This mode of inheritance is also most likely in our consanguineous pedigree. This syndrome should not be confused with the Shprintzen-Goldberg syndrome (OMIM 182212, craniosynostosis, marfanoid habitus).

The neurological abnormalities seen in our patients have not been reported before. They might either belong to the clinical spectrum of Goldberg-Shprintzen syndrome, occurring at a later stage, or be caused by another autosomal recessive trait segregating in this family from a common ancestor. This second trait could cause proximal muscle weakness, hypotonia, and the eye abnormalities. Kim *et al*²⁵ recently reported a similar phenotype in a 15 year old boy with microcephaly, mental retardation, a characteristic face, HSCR, proximal muscle weakness, cerebellar dysfunction, and scoliosis. The parents were not consanguineous. His brother had mild developmental delay and a paternal cousin had isolated HSCR.

The eye abnormalities (megalocorneae and corneal hypoaesthesia) in two out of four patients have not been reported previously in Goldberg-Shprintzen syndrome. Their differential diagnosis includes megalocornea-mental retardation or MMR syndrome (OMIM 249310).²⁶ HSCR and mild microcephaly was described once in combination with familial dysautonomia (OMIM 223900).²⁷ Both syndromes can be excluded in our patients. Thus we propose that the Goldberg-Shprintzen syndrome can be associated with neurological and ophthalmic symptoms at a later age.

A CAUSATIVE ROLE FOR THE SER305ASN EDNRB VARIANT?

Among causative mutations involved in HSCR, 10 were reported to be in the EDNRB gene. They occurred predominantly in sporadic cases and were located in the transmembrane spanning domains.²⁸⁻³⁰ The Ser305Asn substitution was previously reported by Auricchio *et al*³¹ as a causative mutation in a sporadic Italian male patient with isolated HSCR. Biochemical data showed that in cows Serine305 is involved in post-translational modification (that is, phosphorylation) of the Ednrb protein.³² Therefore, substitutions of this amino acid might have functional consequences, resulting in HSCR. The Ser305Asn substitution cannot explain the Goldberg-Shprintzen phenotype by itself since it does not cosegregate with the phenotype (for example, while V.6 is affected with Goldberg-Shprintzen syndrome, but does not have the EDNRB variant, the reverse applies to V.7). The most likely explanation for the phenotype in this consanguineous family

seems to be homozygosity for a mutation in a presumed Goldberg-Shprintzen gene; none of the patients in this family was found to be homozygous for the Ser305Asn substitution. Although we do not know the frequency of Ser305Asn substitutions in the Moroccan population, it is unlikely that the EDNRB variant contributes to the phenotype in our family. This family might be instrumental in identifying a Goldberg-Shprintzen gene. The presence of a mutation in the EDNRB gene in this family illustrates the difficulties in interpreting the presence of mutations in families with HSCR.³³

Although the function and interactions of the multiple HSCR susceptibility genes await further clarification, mutation analysis in syndromic HSCR patients might offer insight into the pleiotropic effects of these genes. Detailed dysmorphological evaluation of syndromic HSCR patients may give clues as to additional susceptibility genes for HSCR.

We are grateful to Professor Martinus F Niermeijer for his helpful comments on the manuscript. The Clinical Genetic Foundation Rotterdam and the Sophia Foundation for Medical Research supported this work.

- Spouge D, Baird PA. Hirschsprung disease in a large birth cohort. *Teratology* 1985;32:171-7.
- Ikeda K, Goto S. Additional anomalies in Hirschsprung's disease: an analysis based on the nationwide survey in Japan. *Z Kinderchir* 1986;41:279-81.
- Passarge E. Whither polygenic inheritance: mapping Hirschsprung disease. *Nat Genet* 1993;4:325-6.
- Aylsworth AS, Lin AE, Friedman PA. Nager acrofacial dysostosis: male to male transmission in 2 families. *Am J Med Genet* 1991;41:83-8.
- Davenport M, Taitz LS, Dickson JAS. The Kaufman-McKusick syndrome: another association. *J Pediatr Surg* 1989;24:1192-4.
- Islek I, Kucukoduk S, Erkan D, *et al*. Bardet-Biedl syndrome: delayed diagnosis in a child with Hirschsprung disease. *Clin Dysmorphol* 1996;5:271-3.
- Haddad GG, Mazza NM, Defendini R, *et al*. Congenital failure of automatic control of ventilation, gastrointestinal motility and heart rate. *Medicine* 1978;57:517-26.
- Badner JA, Sieber WK, Garver KL, Chakravarti A. A genetic study of Hirschsprung disease. *Am J Hum Genet* 1990;46:568-80.
- Romeo G, Ronchetto P, Luo Y, *et al*. Point mutations affecting the tyrosine kinase domain of the Ret proto-oncogene in Hirschsprung's disease. *Nature* 1994;367:377-8.
- Edey P, Lyonnet S, Mulligan LM, *et al*. Mutations of the Ret proto-oncogene in Hirschsprung's disease. *Nature* 1994;367:378-80.
- Angrist M, Bolk S, Halushka M, Lapchak PA, Chakravarti A. Germline mutations in glial cell line-derived neurotrophic factor (*GDNF*) and *RET* in a Hirschsprung disease patient. *Nat Genet* 1996;14:341-3.
- Salomon R, Attie T, Pelet A, *et al*. Germline mutations of the Ret ligand *GDNF* are not sufficient to cause Hirschsprung disease. *Nat Genet* 1996;14:345-7.
- Puffenberger EG, Hosoda K, Washington S, *et al*. A missense mutation of the endothelin-b receptor gene in multigenic Hirschsprung disease. *Cell* 1994;79:1257-66.
- Hofstra RMW, Osinga J, Tan-Sindhuta G, *et al*. A homozygous mutation in endothelin-3 associated with combined Waardenburg type 2 and Hirschsprung phenotype. *Nat Genet* 1996;12:445-7.
- Edey P, Attie T, Amiel J, *et al*. Mutations of the endothelin-3 gene in the Waardenburg-Hirschsprung disease (Shah-Waardenburg syndrome). *Nat Genet* 1996;12:442-4.
- Pingault V, Bondurand N, Kuhlbrodt K, *et al*. SOX10 mutations in patients with Waardenburg-Hirschsprung disease. *Nat Genet* 1998;18:171-3.
- Chakravarti A. Endothelin receptor-mediated signalling in Hirschsprung's disease. *Hum Mol Genet* 1996;5:303-7.
- Hofstra RMW, Sijmons RH, Stelwagen T, *et al*. *RET* mutation screening in familial cutaneous lichen amyloidosis and in skin amyloidosis associated with multiple endocrine neoplasia type 2A. *J Invest Dermatol* 1996;107:215-18.
- Goldberg RB, Shprintzen RJ. Hirschsprung megacolon and cleft palate in two sibs. *J Craniofac Genet Dev Biol* 1981;1:185-9.
- Hurst JA, Markiewicz M, Kumar D, Brett EM. Unknown syndrome: Hirschsprung's disease, microcephaly, and iris coloboma: a new syndrome of defective neuronal migration. *J Med Genet* 1988;25:494-7.
- Halal F, Morel J. The syndrome of Hirschsprung disease, microcephaly, unusual face, and mental retardation. *Am J Med Genet* 1990;37:106-8.

- 22 Yomo A, Taira T, Kondo I. Goldberg-Shprintzen syndrome: Hirschsprung disease, hypotonia, and ptosis in sibs. *Am J Med Genet* 1991;41:188-91.
- 23 Tanaka H, Ito J, Cho K, Mikawa M. Hirschsprung disease, unusual face, mental retardation, epilepsy, and congenital heart disease: Goldberg-Shprintzen syndrome. *Pediatr Neurol* 1993;9:479-81.
- 24 Fryer AE. Goldberg-Shprintzen syndrome: report of a new family and review of the literature. *Clin Dysmorphol* 1998;7:97-101.
- 25 Kim JJ, Armstrong DD, Fishman MA. Multicore myopathy, microcephaly, aganglionosis, and short stature. *J Child Neurol* 1994;1:275-7.
- 26 Neuhauser G, Kaveggia EG, France TD, Opitz JM. Syndrome of mental retardation, seizures, hypotonic cerebral palsy and megalocorneae, recessively inherited. *Z Kinderheilkd* 1975;120:1-18.
- 27 Azizi E, Berlowitz I, Vinograd I, Reif R, Mundel G. Congenital megacolon associated with familial dysautonomia. *Eur J Pediatr* 1984;142:68-9.
- 28 Attie T, Till M, Pelet A, *et al.* Mutation of the endothelin-receptor B gene in Waardenburg-Hirschsprung disease. *Hum Mol Genet* 1995;4:2407-9.
- 29 Kusafuka T, Wang Y, Puri P. Novel mutations of the endothelin-B receptor in isolated patients with Hirschsprung's disease. *Hum Mol Genet* 1996;5:347-9.
- 30 Amiel J, Attie T, Jan D, *et al.* Heterozygous endothelin receptor B (EDNRB) mutations in isolated Hirschsprung disease. *Hum Mol Genet* 1996;5:355-7.
- 31 Auricchio A, Casari G, Staiano A, Ballabio A. Endothelin-B receptor mutations in patients with isolated Hirschsprung disease from a non-inbred population. *Hum Mol Genet* 1996;5:351-4.
- 32 Roos M, Soskic V, Poznanovic S, Godovac-Zimmermann J. Post-translational modifications of endothelin receptor B from bovine lungs analyzed by mass spectrometry. *J Biol Chem* 1998;273:924-31.
- 33 Hofstra RMW, Osinga J, Buys CHCM. Mutations in Hirschsprung disease: when does a mutation contribute to the phenotype. *Eur J Hum Genet* 1997;5:180-5.