

Somatostatin and somatostatin receptors in retinal diseases

P M van Hagen^{1,2}, G S Baarsma⁵, C M Mooy⁴, E M Ercoskan⁵, E ter Averst², L J Hofland², S W J Lamberts² and R W A M Kuijpers³

Departments of ¹Immunology, ²Internal Medicine, ³Ophthalmology and ⁴Pathology, Erasmus University Medical Centre, Rotterdam and ⁵The Eye Hospital, Rotterdam, The Netherlands

(Correspondence should be addressed to P M van Hagen, Department of Immunology and Internal Medicine, Erasmus University Medical Centre Rotterdam, Dr Molewaterplein 40, 3015 GD Rotterdam, The Netherlands; Email: vanhagen@immd.azr.nl)

Introduction

Somatostatin is a small neuropeptide that is produced in the central nervous system, where it acts as a neurotransmitter. This neuropeptide also has an important role in the neuroendocrine system as an inhibitor of hormone release, the most striking example of which is the inhibition of growth hormone release. The role of somatostatin in eye disease recently became of interest because of its role in proliferative diabetic retinopathy and cystoid macular oedema (1–3). In this paper, we discuss the role of somatostatin in the retina and also present preliminary results of treatment of exudative age-related macular disease with the somatostatin analogue, octreotide.

Somatostatin in the retina

Somatostatin is found in the neuroretina of various species, including humans. Immunoreactive and biologically active somatostatin was first demonstrated in the rat retina in the late 1970s (4–6) and was subsequently found in other species (7, 8). It became clear that somatostatin is locally produced in the retina, because somatostatin immunoreactivity occurs in extracts of frog and rat retinas, even 1 year after transection of the optic nerves. Pre-prosomatostatin was produced in the retinas of all species studied, but a differential expression of somatostatin-14 and somatostatin-28 was observed (9). Loss of somatostatin immunoreactivity was found after degeneration of the ganglion cells (10). These results suggested somatostatin production at the inner part of the retina. In all species studied, somatostatin is located at the inner part of the retina, although there are morphological differences between species. Controversial findings have been reported concerning somatostatin expression in the outer nuclear layer (9). In general, somatostatin has been localised in subclasses of amacrine cells located at the proximal border of the inner nuclear layer. These cells have processes entering the inner plexiform layer (7, 11). We have demonstrated somatostatin-14 mRNA in preparations of normal human retinas – an observation that contributes to the opinion that somatostatin is synthesised in the retina (Fig. 1).

Somatostatin receptors in the retina

The expression of somatostatin receptors (SSTs) has been studied in various species. Autoradiographic studies showed retinal SST expression in C57 black/6J mice using somatostatin-14 and somatostatin-28 ligands (12). Specific binding of both ligands occurred in three maxima: a broad band extending from the retinal ganglion cells to the inner nuclear layers; a narrow, inconstant band over the outer plexiform layer; and a band over the retina pigment epithelium and choroid. The most dense labelling occurred in a broad band over the inner plexiform layer and inner margin of the inner nuclear layer. Differential SST expression was found with RT-PCR of the rat eye (13). SST subtypes 2 and 4 were the major subtypes expressed predominately in the rat iris/ciliary body and retina respectively; SST₁, SST₃ and SST₅ were preferentially expressed in the posterior eye, including the retina. Recently, we performed an immunohistochemical study of human retinas, using a rabbit polyclonal antiserum directed against SST₁ and SST_{2A}. In this study we found SST₁ expression by the retinal ganglion cells, in the inner nuclear layer and retinal pigment epithelium. SST_{2A} expression was found in the inner and outer nuclear and plexiform layers and retinal pigment epithelium layer (RPE). The most intensive staining was found in the inner plexiform layer and inner nuclear layer. An example of SST_{2A} staining of the human retina is shown in Fig. 2. RT-PCR of human retina preparations confirmed the presence of somatostatin and SST_{2A} mRNA and also SST₃ mRNA, but not SST₄ and SST₅ mRNA. These results prove that these receptors are synthesised in the human retina (Fig. 1). Until now, it has not been possible to detect SST₃ by immunohistochemistry. In primary human retinal pigment epithelium cultures, we found SST_{2A} and somatostatin-14 mRNA expression – an observation that suggests an autocrine function for somatostatin-14 on the RPE (unpublished observations).

Physiology of somatostatin in the retina

Until now, the exact role of somatostatin in the retina has remained unresolved. Exogenous somatostatin, when applied in solutions superfusing the retina, has been shown to affect retinal responses to light.

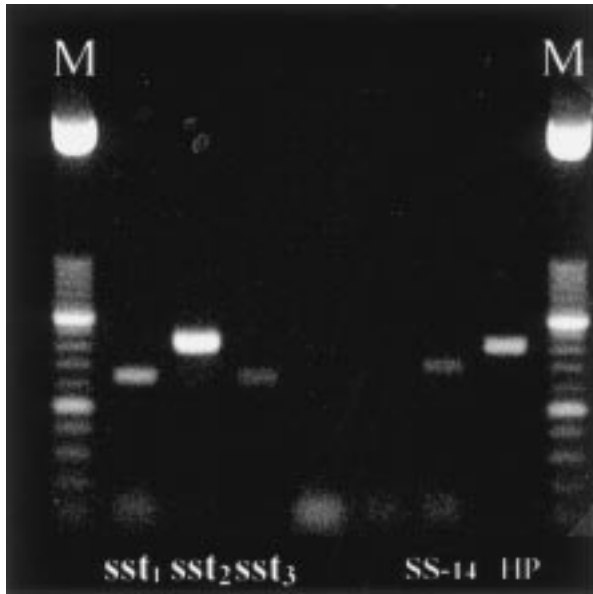


Figure 1 RT-PCR of whole human retina preparations. SST₁, SST_{2A}, SST₃ and somatostatin (SS)-14 are expressed.

Nanomolar concentrations of somatostatin increased the amplitude of extracellularly recorded massed oscillatory potentials of the mudpuppy eyecup preparation. Electroretinograms showed an increased potential 1 min after substitution, increasing to a maximum in 2–5 min (14). Affected retinal ganglion cell responses were also found, by a variety of methods, in rabbits and goldfish (15, 16). In turtle retina, somatostatin excited extracellularly recorded ganglion cells. The somatostatin content in the retina increased during light exposure, whereas extended exposure to dark revealed low concentrations of somatostatin (17). This reduction may be related to an increased release or a lower synthesis of somatostatin. A detailed study of the role of somatostatin was reported by Zalutski & Miller in 1990 (16). The results indicate that somatostatin is a neuromodulator in the rabbit retina, producing long-lasting changes in the signal-to-noise discharge pattern and the centre-surround balance of ganglion cells. All commonly encountered ganglion cell receptive fields were affected by somatostatin in three different ways. The first effect was a slow (seconds) excitation, occurring with a threshold concentration of at least 100 nmol/l. The second effect was an increase in signal-to-noise ratio, because of a decrease in the spontaneous activity and a concomitant increase in light-evoked spiking. The third effect was a shift in centre-surround balance towards a

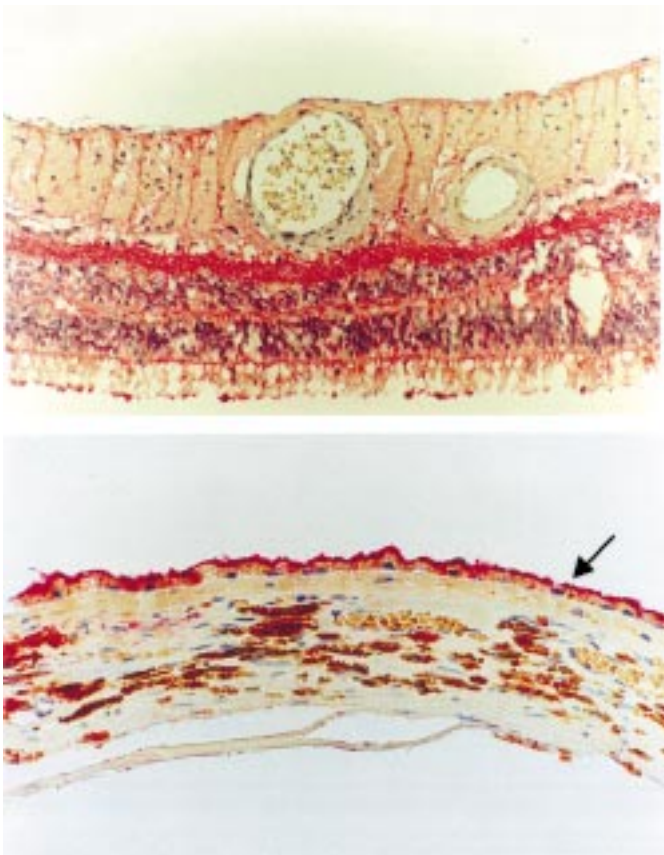


Figure 2 Immunohistochemical staining of the human retina. Top: SST_{2A} (red) is expressed by all cell layers of the neuroretina, but extensively by the inner plexiform layer. Bottom: The retinal pigment epithelium express SST_{2A} on the apical side (arrow).

more dominant centre. The last two observations were evident in the nanomolar range, which is presumed to be physiological because, in this range, somatostatin analogues exert their inhibitory effect on hormone release.

Somatostatin and SSTs in retinal diseases

Cystoid macular oedema

Macular oedema, especially cystoid macular oedema (CME) is a major complication of a variety of ocular diseases. It is most frequently associated with uveitis, retinal vascular disease (diabetic retinopathy, retinal vein occlusion) and retinitis pigmentosa. Hereditary dominant CME is also described, but the prevalence of this disease is very low. CME often results in a decreased visual acuity and this can be irreversible when the oedema is long standing. Macular oedema is an accumulation of fluid within the retinal tissue; it can be seen on ophthalmoscopy and the severity can be evaluated by fluorescein angiography.

Two systems with non-leaky tight junctions between cells are essential for maintaining the fluid homeostasis of the retina: retinal vascular endothelium (inner blood–retinal barrier) and the retinal pigment epithelium (outer blood–retinal barrier). Through these barriers, some molecules such as oxygen pass directly, but others such as albumin are unable to pass. CME may result from a disruption of the inner blood–retinal barrier, leading to an abnormal permeability of the perifoveal retinal capillaries, or from a reduction of the active transport of fluid out of the retina towards the choroid. Dysfunction of the capillary endothelium, with subsequent leakage from the capillaries surrounding the macula may occur in response to inflammation, ischaemia or toxic substances.

Dysfunction of the RPE layer is considered to be an important pathogenic factor in ocular diseases associated with CME. The RPE functions as a permeability barrier between choroid and neurosensory retina by blocking the inward migration of small molecules from the choriocapillaris to the neurosensory retina and by active transport of ions and fluid between retina and choroid. The RPE creates an osmotic pressure gradient between retina and choroid and, as consequence, neuroretinal apposition. As fluid dissects into the nerve fibre layer, it may elevate the inner limiting membrane and displace the nerve fibres to create large accumulations of fluid. The macula becomes thickened and cystic spaces containing a transudate are present in the outer and inner plexiform layer and the inner nuclear layer. The walls of these cystoid spaces are of variable thickness and comprised of fibres (but are not true walls). The macular region is the predilected site for the accumulation of interstitial fluid because of its loose packing of neural cells.

Permanent cystoid spaces may persist even after treatment of the primary disease; moreover, a clinically important complication of CME is irreversible loss of

visual acuity as a result of structural changes in the retina. However, when the disease is treated in an early stage and the vascular integrity is restored, the macula may return to its normal function. No clear consensus is yet available as to the treatment of cystoid macular edema. The main approach is treatment of the underlying disease, such as immune suppression in autoimmune uveitis. Treatment depends on the cause of the disease and is often disappointing. Pharmacological therapy for CME includes carbonic anhydrase inhibitors, prostaglandin inhibitors and topical, periocular, systemic steroids and more laser treatment (18).

Recently, we described the successful treatment of CME with the somatostatin analogue, octreotide, in a patient with dominant CME. In this patient the visual acuity increased significantly after octreotide treatment. Interruption of octreotide treatment resulted subsequently in a decreased visual acuity (3). In addition to dominant CME, we have treated 10 patients with refractory CME secondary to uveitis with subcutaneous octreotide or Sandostatin-LAR. We found diminished macular oedema and improvement of the visual acuity after octreotide treatment in 10 of 16 eyes (RWAM Kuijpers *et al.* unpublished observations). In four patients, it was also possible to taper immunosuppressive therapy, maybe because of an immunomodulating effect of octreotide. During treatment, no serious side effects were observed. The mechanism for the observed improvement of visual acuity in these patients is not clear. We have postulated four different mechanisms through which SST may be involved (19):

1. Direct action of octreotide on the RPE. We found a high expression of SST_{2A} at the apical side of the RPE. Various ion/water transport systems are located at this apical membrane of the RPE adjacent to the subretinal space. The action of octreotide in CME may be linked with these ion transport systems, resulting in a rebalance of the fluid and ion transport.
2. Somatostatin and its analogues have a suppressive effect on the immune response (20). This may support the effect of octreotide treatment in immune-mediated disease such as autoimmune uveitis. A decrease in disease activity in autoimmune uveitis may subsequently diminish macular oedema.
3. Somatostatin binding sites were found on retinal endothelium. Somatostatin has a direct antiproliferative effect on retinal endothelium and SSTs are expressed on activated blood vessels in inflammation (21, 22). Suppression of activated endothelium may help to restore the inner blood–retinal barrier.
4. Improvement of the neuroretinal function as discussed above may contribute to an increase in visual acuity.

Somatostatin in retinal ischaemic disease

Vascular disease affecting the retina can be seen directly on ophthalmoscopy. The signs of retinal

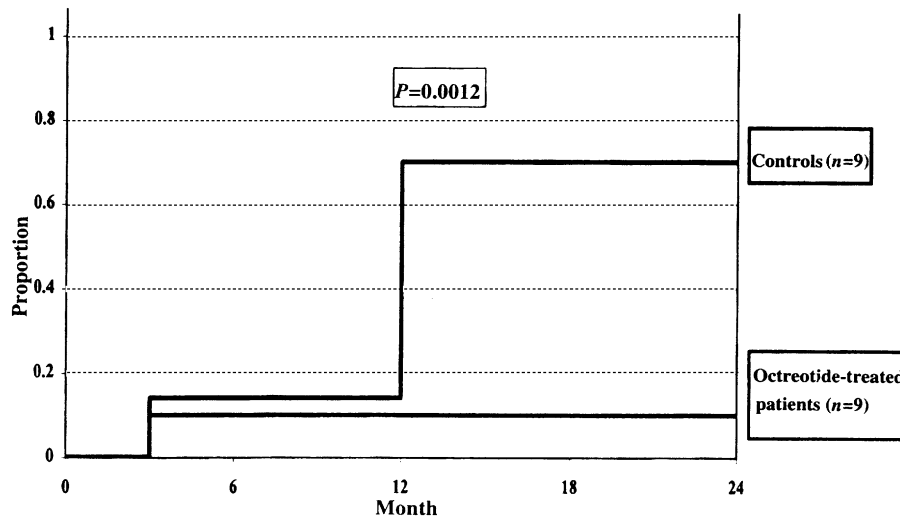


Figure 3 Kaplan–Meier curve. The risk of vitreous haemorrhages was significantly reduced in patients with octreotide treatment ($P = 0.0012$). (Reproduced from (28) with permission.)

vascular disease result from two changes of the retinal circulation – leakage and occlusion of the circulation. Leakage results in haemorrhages, exudates and oedema. Retinal vascular closure produces ischaemia with liberation of vasoproliferative factors, which in turn eventually produces neovascularisation. Ocular neovascularisation and the associated haemorrhages and fibrovascular proliferations are the underlying threats to vision in diverse conditions such as diabetic

retinopathy, retinal vein occlusion, retinopathy of prematurity, exudative age-related macular degeneration, sickle cell retinopathy, radiation retinopathy, and numerous others.

A possible role of growth hormone in the pathogenesis of proliferative retinopathies was originally suggested by the observation of regressing proliferative diabetic retinopathy following infarction of the pituitary after pregnancy (23, 24). This observation led to

Table 1 Clinical features and SST_{2A} staining in ischaemic retinal disease.

Patient	Age (years)	Sex	History	SST _{2A} in (neo)vascular vessels	
1	69	F	Non-PDR	Intraretinal (h) ++	
2	67	M	Non-PDR	Intraretinal (h) +/-	
3	55	F	Early PDR	Intraretinal (h) ++	
4	78	F	Early PDR	Intraretinal (h) +/-	
5	36	F	Early PDR	Intraretinal +/-	Preretinal -
6	29	F	Endstage PDR	Preretinal ++	
7	42	F	Endstage PDR	Preretinal +	
8	60	F	Endstage PDR	Preretinal +/-	
9	51	M	Endstage PDR	Intraretinal (h) +/-	
10	32	M	Endstage PDR	Intraretinal -	Preretinal +/-
11	74	M	Endstage PDR	Preretinal +/-	
12	70	F	Endstage PDR	Intraretinal (h) +/-	Preretinal -
13	60	M	Early CRVO	Intraretinal +	
14	72	M	Early CRVO	Intraretinal (h) -	
15	90	F	Early CRVO	Intraretinal +	
16	67	M	Early CRVO	Intraretinal (h) -	Preretinal -
17	83	F	Early CRVO	Intraretinal (h) +/-	Preretinal +/-
18	79	M	Early CRVO	Intraretinal (h) ++	Preretinal +/-
19	82	F	Early CRVO	Intraretinal (h) +/-	Preretinal +/-
20	47	M	Endstage CRVO	Intraretinal -	Preretinal -
21	74	F	Endstage CRVO	Intraretinal -	Preretinal ++
22	68	M	Endstage CRVO	Intraretinal -	Preretinal +/-
23	77	M	Non-proliferative ischaemia	Intraretinal -	
24	79	F	Proliferative ischaemia	Intraretinal -	

PDR, proliferative diabetic retinopathy; (h), hyalinised; CRVO, central retinal vein occlusion.

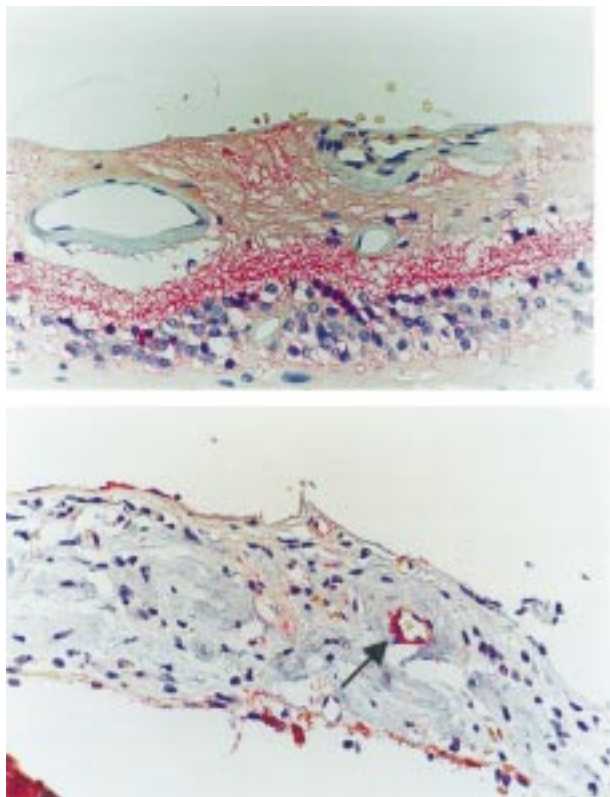


Figure 4 Top: Intraretinal vessels usually stain SST_{2A}-negative. Bottom: Example of SST_{2A} expression by a neovascular vessel in the iris.

the use of hypophysectomy as treatment for diabetic retinopathy (25, 26); the introduction of laser photocoagulation led to the abandonment of this treatment. Various studies have shown the successful treatment of proliferative diabetic retinopathy with somatostatin analogues (1, 2, 27). A cohort study of patients with long-standing diabetes mellitus showed that the risk of recurrent vitreous haemorrhages was significantly reduced in all octreotide-treated patients; the Kaplan–Meier curve (Fig. 3) shows the results after 2 years follow-up (28). A significant difference persisted during an observation period of 12 months.

In order to investigate the SST expression *in vitro*, 42 paraffin blocks of ischaemic retinas were retrieved from eyes with diabetic retinopathy and ischaemic vascular retinopathy. The eyes were enucleated because of refractory pain and total loss of vision. Twelve phthisical eyes, and eyes complicated by endophthalmitis were excluded. In the remaining 24 eyes, we studied (by immunohistochemistry) the expression of SST_{2A} in non-proliferative ($n = 3$), early proliferative ($n = 11$), and endstage proliferative ($n = 10$) stages of ischaemic retinal disease, including diabetic retinopathy (12 eyes) and vascular occlusive disease (12 eyes). Sporadic expression was found in non-proliferative, and variable expression in early proliferative and

endstage proliferative ischaemic retinal disease. The clinical and histological details are summarised in Table 1. Intraretinal neovascularisations stained generally negative, whereas early preretinal neovascularisations stained variably positive (Fig. 4). In endstage preretinal vascularisations, variable but pronounced positive staining was found in the preretinal membranes. In areas of non-perfusion, the intraretinal ghost vessels stained negative. These findings suggest that the anti-angiogenic effects of somatostatin analogues may be expected to be limited. However, we have to concede that the material was highly selected and that the sensitivity of staining in paraffin sections is less sensitive than that in cryostat sections. Our observations are in concordance with the minimal effect of somatostatin analogues on non-proliferative diabetic retinopathy in clinical pilot studies (29, 30) and with the more beneficial effect of somatostatin analogues on advanced proliferative diabetic retinopathy after extensive laser treatment (1, 2, 28).

Age-related macular degeneration

Age-related macular degeneration (ARMD) results in a deterioration of the central retinal function, and is the leading cause of legal blindness in people over 50 years of age in Europe and the USA (31, 32). The clinical aspects of ARMD were recently reviewed in an excellent paper (33). Because the macula is in the central portion of the retina, advanced ARMD often leads to irreversible loss of social skills – for example, the ability to read. The precise pathogenesis of ARMD remains still unclear. Two forms are distinguished: the atrophic form and the neovascular, exudative form. The atrophic form typically involves the choriocapillaris, RPE, and photoreceptor elements (rods and cones) and does not involve leakage of blood or serum; hence, it is called dry ARMD. The neovascular, exudative form includes serous or haemorrhagic detachment of RPE and choroidal neovascularisation, which leads to leakage and subsequent fibrovascular scarring of the macular area. Loss of vision can occur in either form of the disorder. The latter form is more aggressive, with choroidal neovascularisation, and may progressively result in blindness (34, 35). Among patients with severe loss of visual acuity (<0.1 or worse), choroidal neovascularisation is the cause in at least 80% (36). Choroidal neovascularisation can be identified before scarring and extensive leakage cause irreversible loss of vision. Leakage of blood or serum as a result of choroidal neovascularisation may occur precipitously and is often associated with the abrupt loss or distortion of vision.

The prevalence of ARMD increases dramatically with age; in a population over 65 years old it is about 25%, including 4% of patients with an exudative stage (31). The therapeutic options are limited. Laser photocoagulation, as performed in the Macular Photocoagulation Study, is the only treatment for exudative ARMD that

Table 2 Treatment of 13 patients (15 eyes) with exudative ARMD with octreotide (Sandostatin-LAR) for a period of 2 years.

Eye	Sex of patient	ODS	Age (years)	Neovascularization	Visual acuity		
					Baseline	1 year	2 years
1	m	OD	78	Occult	0.5	0.3	0.25
2	m	OS	77	Mixed	0.3	0.4	0.3
3	f	OS	70	Classic	0.8	0.7	0.4
4	m	OD	71	Classic	0.01	0.05	0.05
5	f	OD	69	Mixed	0.02	0.125	0.2
6	f	OS	70	Occult	0.01	0.1	0.05
7	f	OD	69	Mixed	0.1	0.2	0.125
8		OS		Mixed	0.2	0.08	0.1
9	m	OD	68	Occult	0.7	1.0	0.6
10	m	OD	70	Occult	0.8	0.9	
11	m	OS	82	Occult	0.4	0.3	0.3
12	m	OD	69	Occult	0.8	1.0	0.9
13		OS		Classic	0.4	0.5	0.5
14	f	OD	79	Occult	0.25	0.4	0.15
15	m	OS	69	Mixed	0.5	0.1	0.08

OD, oculus dextra; OS, oculus sinistra.

has proven long-term benefit (37). Photodynamic therapy is a non-thermal process leading to the localised production of reactive oxygen species that may mediate local cellular, vascular, and immunological injury, and ultimately result in the partially selective destruction of new blood vessels. Other, still experimental, therapeutic treatment strategies such as radiotherapy, submacular surgery, thalidomide, indocyanine green-guided laser treatment, transplantation of RPE, and retinal translocation are under investigation (33).

Recently, we have treated successfully 13 patients (15 eyes) with exudative ARMD with octreotide (Sandostatin-LAR) in dosage of 20 mg monthly. The patient characteristics and results are summarised in (Table 2). After 6 months, ten of the 15 eyes maintained their vision and even an improvement of visual acuity was observed. Two-year follow-up of these initial treated eyes showed that the visual acuity

remained stable or deteriorated less than three lines in 13 eyes and decreased more than 3 lines in two eyes (Fig. 5). Patient 10 had to withdraw from treatment because of an accident, the other patients were treated for more than 2 years without significant side effects. Although this was a non-controlled pilot study in a diverse patient population, these results are very promising for the long-term stabilisation of visual acuity in patients with exudative macular degeneration. This led us to initiate a prospective randomised trial for the treatment of exudative macular degeneration with octreotide.

In vitro investigation of human eyes with ARMD showed SST_{2A} expression in newly formed neovascular vessels (38). An example of SST_{2A} expression in sub-RPE choroidal neovascular vessels is shown in Fig. 6. We hypothesised that octreotide inhibited neovascular endothelium proliferation directly or indirectly by inhibition of insulin-like growth factor (IGF)-I. However, other possible action of octreotide are also of interest – such as restoration of RPE cell function, which is believed to be affected in exudative ARMD.

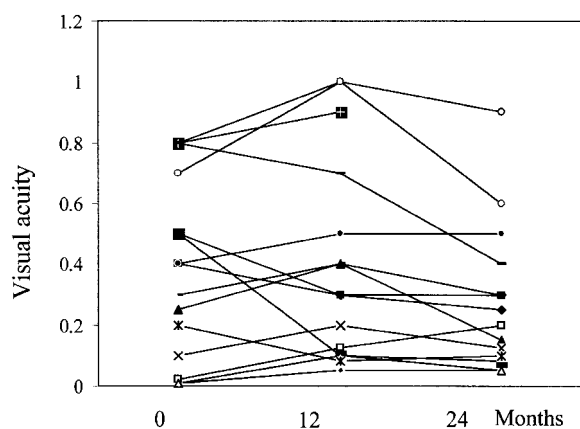


Figure 5 Two-year results of the treatment of 13 patients (15 eyes) with exudative macular degeneration with octreotide (Sandostatin-LAR).

Are the actions of somatostatin analogues direct or mediated through IGF-I in retinal disease?

Growth factors mediate intraocular angiogenesis in ischaemic retinopathies. The potential impact of identifying these mediators of retinal neovascularisation resulted in the investigation of a wide variety of candidate molecules. The growth factor that best suits such a paradigm is vascular endothelial growth factor (VEGF). As already mentioned, a possible role for growth hormone and IGF has been proposed. Growth hormone stimulates the production of IGF-I in the liver and subsequently increases its blood concentration.

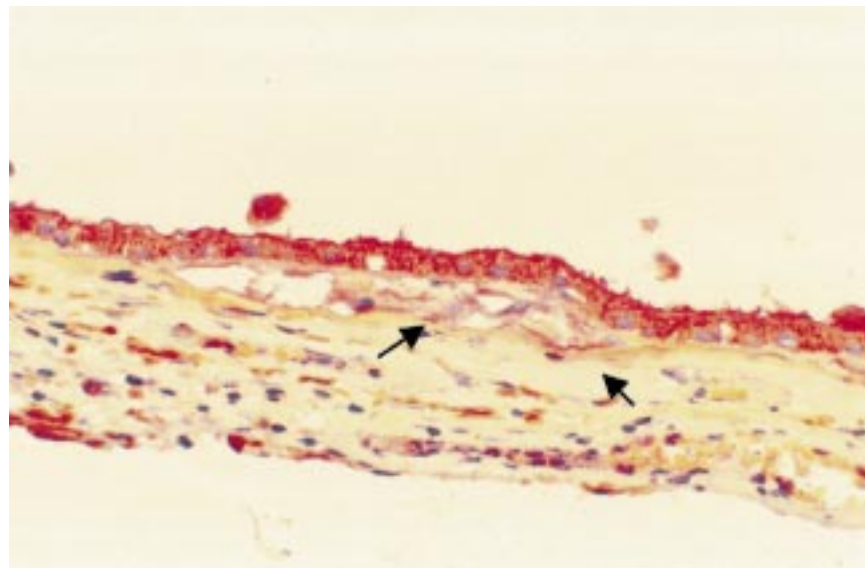


Figure 6 Immunohistochemical staining of sub-RPE neovascular blood vessels in ARMD.

Somatostatin analogues are powerful inhibitors of growth hormone release and therefore decrease the blood IGF-I concentration. IGF-I causes neovascularisation in a rat cornea model, but intraocular neovascularisation has not been demonstrated at physiological concentrations (22). Correlation of increased IGF-I concentrations with an increased frequency of proliferative diabetic retinopathy is controversial (39, 40). In mice treated with an SST₂-selective agonist, and in a transgenic growth hormone antagonist mouse model, ischaemia-induced neovascularisation was inhibited. In this model, neovascularisation could be stimulated after substitution of growth hormone or IGF-I (41). Until recently, there was no direct proof of a relationship between IGF-I and retinal neovascularisation. Only recently it has been shown that an IGF-I receptor antagonist suppresses retinal neovascularisation in a mouse model of proliferative retinopathy (42). VEGF is an essential hypoxia-induced endothelial growth factor in proliferative retinopathy. The IGF-I antagonist inhibits the action of VEGF through inhibition of the second messenger, mitogen-activated protein kinase. These results could also explain the increase in diabetic retinopathy in patients with poorly regulated diabetes. In these patients, a partial resistance to growth hormone exists, resulting in decreased concentrations of IGF-I that prevent the action of VEGF on the endothelium. After insulin substitution, IGF-I concentrations increase, and subsequently the action of VEGF increases, resulting in an increased neovascularisation (42).

Neovascularisation in ischaemic retinas from patients with diabetes and patients with occlusive vessel disease can express SST_{2A}. Also, in retinas from patients with exudative ARMD, SST_{2A} is expressed by

neovascular choroidal vessels (38). The action of somatostatin analogues in these diseases may be mediated through IGF-I as discussed above, or by a direct action of these analogues on neovascular endothelium. However, other pathophysiological factors cannot be excluded. ARMD represents an exaggeration of the ageing changes that takes place within the RPE, photoreceptors and Bruch's membrane (43). The initial event appears to stem from a failure of the RPE to phagocytose spent photoreceptor membranes correctly. This leads to thickening of Bruch's membrane as basal laminar deposits and drusen. Finally, the RPE and overlying photoreceptors undergo atrophy, and closure of the underlying choriocapillaris occurs. The exudative state develops when new choroidal vessels penetrate Bruch's membrane, resulting in choroidal neovascularisation. Functional changes in RPE may be responsible for inappropriate transport and metabolism of degradation products at the basis of this process. SSTs are expressed by the RPE; moreover, somatostatin is produced by the RPE, suggesting a role as an autocrine factor. It is tempting to hypothesise that somatostatin analogues contribute to the recovery of RPE function in ARMD, in addition to exerting a direct effect on neovascularisation and its indirect effect on neovascularisation by decreasing the concentration of IGF-I. The direct role of somatostatin analogues in these retinal diseases, apart from inhibition of IGF-I, remains to be explored.

References

- 1 Mallet B, Vialettes B, Haroche S, Escoffier P, Gastaut P, Taubert JP & Vague P. Stabilization of severe proliferative diabetic retinopathy

- by long-term treatment with SMS 201-995. *Diabetes Metabolism* **18** 1992 438–444.
- 2 McCombe M, Lightman S, Eckland DJ, Hamilton AM & Lightman SL. Effect of a long-acting somatostatin analogue (BIM23014) on proliferative diabetic retinopathy: a pilot study. *Eye* **5** 1991 569–575.
 - 3 Kuijpers RW, Baarsma S & van Hagen PM. Treatment of cystoid macular edema with octreotide [letter]. *New England Journal of Medicine* **338** 1998 624–626.
 - 4 Rorstad OP, Brownstein MJ & Martin JB. Immunoreactive and biologically active somatostatin-like material in rat retina. *PNAS* **76** 1979 3019–3023.
 - 5 Shapiro B, Kronheim S & Pimstone B. The presence of immunoreactive somatostatin in rat retina. *Hormone and Metabolic Research* **11** 1979 79–80.
 - 6 Kirsch B & Leonhardt H. Demonstration of a somatostatin-like activity in retinal cells of the rat. *Cell and Tissue Research* **204** 1979 127–140.
 - 7 Rorstad OP, Senterman MK, Hoyte KM & Martin JB. Immunoreactive and biologically active somatostatin-like material in the human retina. *Brain Research* **199** 1980 488–492.
 - 8 Sagar SM & Marshall PE. Somatostatin-like immunoreactive material in associational ganglion cells of human retina. *Neuroscience* **27** 1988 507–516.
 - 9 Larsen JN. Somatostatin in the retina. *Acta Ophthalmologica Scandinavica Supplement* **218** 1995 1–24.
 - 10 Lake N & Patel YC. Neurotoxic agents reduce retinal somatostatin. *Brain Research* **181** 1980 234–236.
 - 11 Buckerfield M, Oliver J, Chubb IW & Morgan IG. Somatostatin-like immunoreactivity in amacrine cells of the chicken retina. *Neuroscience* **6** 1981 689–695.
 - 12 Kossut M, Yamada T, Aldrich LB & Pinto LH. Localization and characterization of somatostatin binding sites in the mouse retina. *Brain Research* **476** 1989 78–84.
 - 13 Mori M, Aihara M & Shimizu T. Differential expression of somatostatin receptors in the rat eye: SSTR4 is intensely expressed in the iris/ciliary body. *Neuroscience Letters* **223** 1997 185–188.
 - 14 Wachtmeister L. The action of peptides on the Mudpuppy electrogram. *Experimental Eye Research* **33** 1983 429–437.
 - 15 Walker SE & Stell WK. Gonadotropin-releasing hormone (GnRH), molluscan cardioexcitatory peptide (FMRFamide), enkephalin and related neuropeptides affect goldfish retinal ganglion cell activity. *Brain Research* **384** 1986 262–273.
 - 16 Zalutsky RA & Miller RE. The physiology of somatostatin in the rabbit retina. *Journal of Neuroscience* **10** 1990 383–393.
 - 17 Ishimoto I, Millar T, Chubb IW & Morgan IG. Somatostatin-immunoreactive amacrine cells of chicken retina: retinal mosaic, ultrastructural features, and light-driven variations in peptide metabolism. *Neuroscience* **17** 1986 1217–1233.
 - 18 Lardenoye CWTA. Macular edema in intraocular inflammatory disease. PhD Thesis. Erasmus University, Rotterdam, The Netherlands: 1998.
 - 19 van Hagen PM, Kuijpers RWAM, Mooy CM, Froger CL, Kwekkeboom DJ & Baarsma GS. Perspectives on somatostatin and somatostatin receptor expression in autoimmune disease of the eye. In *Octreotide: The Next Decade*, pp. 291–306. [Lamberts SWJ, editor]. Bristol: BioScientifica Ltd, 1999.
 - 20 van Hagen PM, Krenning EP, Kwekkeboom DJ, Reubi JC, van den Anker-Lugtenburg PJ, Löwenberg B & Lamberts SWJ. Somatostatin and the immune and haematopoietic system; a review. *European Journal of Clinical Investigation* **24** 1994 91–99.
 - 21 ten Bokum AMC, Melief MJ, Schonbrunn A, van der Ham F, Lindeman J, Hofland LJ, Lamberts SWJ & van Hagen PM. Immunohistochemical localization of somatostatin receptor sst2A in human rheumatoid synovium. *Journal of Rheumatology* **26** 1999 532–535.
 - 22 Grant MB, Caballero S & Millard WJ. Inhibition of IGF-I and b-FGF stimulated growth of human retinal endothelial cells by the somatostatin analogue, octreotide: a potential treatment for ocular neovascularization. *Regulatory Peptides* **48** 1993 267–278.
 - 23 Poulsen JE. The Houssay phenomenon in man: recovery from retinopathy in a case of diabetes with Simmonds' disease. *Diabetes* **2** 1953 7–12.
 - 24 Poulsen JE. Diabetes and anterior pituitary insufficiency: final course and postpartum study of a diabetic patient with Sheehan's syndrome. *Diabetes* **15** 1966 73–77.
 - 25 Sharp PS, Fallon TJ, Brazier OJ, Sandler L, Joplin GF & Kohner EM. Long-term follow-up of patients who underwent yttrium-90 pituitary implantation for treatment of proliferative diabetic retinopathy. *Diabetologia* **30** 1987 199–207.
 - 26 Merimee TJ. A follow-up study of vascular disease in growth-hormone-deficient dwarfs with diabetes. *New England Journal of Medicine* **298** 1978 1217–1222.
 - 27 Grant MB, Mames RN, Fitzgerald C, Hazariwala KM, Cooper-DeHoff R, Caballero S & Estes KS. The efficacy of octreotide in the therapy of severe nonproliferative and early proliferative diabetic retinopathy: a randomized controlled study [In Process Citation]. *Diabetes Care* **23** 2000 504–509.
 - 28 Boehm BO, Feldmann B, Lang GK & Lang GE. Treatment of diabetic retinopathy with long-acting somatostatin analogues. In *Octreotide: The Next Decade*, pp. 241–257. [Lamberts SWJ, editor]. Bristol: Bioscientifica Ltd, 1999.
 - 29 Shumak SL, Grossman LD, Chew E, Kozousek V, George SR, Singer W, Harris AG & Zinman B. Growth hormone suppression and nonproliferative diabetic retinopathy: a preliminary feasibility study. *Clinical Investigative Medicine* **13** 1990 287–292.
 - 30 Kirkegaard C, Norgaard K, Snorgaard O, Bek T, Larsen M & Lund-Andersen H. Effect of one year continuous subcutaneous infusion of a somatostatin analogue, octreotide, on early retinopathy, metabolic control and thyroid function in Type I (insulin-dependent) diabetes mellitus. *Acta Endocrinologica* **122** 1990 766–772.
 - 31 Vingerling JR, Klaver CC, Hofman A & de Jong PT. Epidemiology of age-related maculopathy. *Epidemiology Reviews* **17** 1995 347–360.
 - 32 Klaver CC, Wolfs RC, Vingerling JR, Hofman A & de Jong PT. Age-specific prevalence and causes of blindness and visual impairment in an older population: the Rotterdam study. *Archives of Ophthalmology* **116** 1998 653–658.
 - 33 Fine SL, Berger JW, Maguire MG & Ho AC. Age-related macular degeneration. *New England Journal of Medicine* **342** 2000 483–492.
 - 34 Sunness JS, Rubin GS, Applegate CA, Bressler NM, Marsh MJ, Hawkins BS & Haselwood D. Visual function abnormalities and prognosis in eyes with age-related geographic atrophy of the macula and good visual acuity. *Ophthalmology* **104** 1997 1677–1691.
 - 35 Steinmetz RL, Haimovici R, Jubb C, Fitzke FW & Bird AC. Symptomatic abnormalities of dark adaptation in patients with age-related Bruch's membrane change. *British Journal of Ophthalmology* **77** 1993 549–554.
 - 36 Ferris FLD, Fine SL & Hyman L. Age-related macular degeneration and blindness due to neovascular maculopathy. *Archives of Ophthalmology* **102** 1984 1640–1642.
 - 37 Treatment of Age-related Macular Degeneration with Photodynamic Therapy (TAP) Study Group. Photodynamic therapy of subfoveal choroidal neovascularization in age-related macular degeneration with verteporfin: one-year results of 2 randomized clinical trials. *Archives of Ophthalmology* **117** 1999 1329–1345.
 - 38 Lambouij AC, Kuijpers RWAM, Lichtenauer-Kaligis EGR, Kliffen M, van Hagen PM & Mooy CM. Somatostatin 2a expression in choroidal neovascularization secondary to age-related macular degeneration. *Investigative Ophthalmology and Visual Science* **41** 2000 2329–2335.
 - 39 Dills DG, Moss SE, Klein R & Klein BE. Association of elevated IGF-I levels with increased retinopathy in late-onset diabetes. *Diabetes* **40** 1991 1725–1730.
 - 40 Wang Q, Dills DG, Klein R, Klein BE & Moss SE. Does insulin-like growth factor I predict incidence and progression of diabetic retinopathy? *Diabetes* **44** 1995 161–164.
 - 41 Smith LE, Kopchick JJ, Chen W, Knapp J, Kinose F, Daley D, Foley

- E.Smith RG.Schaeffer JM. Essential role of growth hormone in ischemia-induced retinal neovascularization. *Science* **276** 1997 1706–1709.
- 42 Smith LE, Shen W, Perruzzi C, Soker S, Kinose F, Xu X, Robinson G, Driver S, Bischoff J, Zhang B, Schaeffer JM & Senger DR. Regulation of vascular endothelial growth factor-dependent retinal neovascularization by insulin-like growth factor-1 receptor. *Nature Medicine* **5** 1999 1390–1395.
- 43 Kliffen M, van der Schaft TL, Mooy CM, de Jong PT. Morphologic changes in age-related maculopathy. *Microscopy Research and Technique* **36** 1997 106–122.
-

Received 1 July 2000

Accepted 19 July 2000