

CLINICAL STUDY

Long-term treatment with the dopamine agonist quinagolide of patients with clinically non-functioning pituitary adenoma

F R E Nobels, W W de Herder, W M van den Brink¹, D J Kwekkeboom², L J Hofland, J Zuyderwijk, F H de Jong and S W J Lamberts

Departments of Medicine, ¹Neurosurgery and ²Nuclear Medicine, University Hospital Dijkzigt, Rotterdam, The Netherlands

(Correspondence should be addressed to F R E Nobels, Department of Endocrinology, Onze Lieve Vrouw Hospital, 164 Moorselbaan, 9300 Aalst, Belgium; Email: frank.nobels@olvz-aalst.be)

Abstract

Objective: This study was performed to evaluate the effect of prolonged treatment with the dopamine agonist quinagolide on serum gonadotropin and α -subunit concentrations and tumor volume in patients with clinically non-functioning pituitary adenomas (CNPA).

Design: Ten patients with CNPA were treated with quinagolide (0.3 mg daily). The median duration of treatment was 57 months (range 36–93 months). Blood samples for measurement of serum gonadotropin and α -subunit concentrations were drawn before treatment, after 5 days, and at each outpatient visit. Computerized tomography or magnetic resonance imaging of the pituitary region and Goldmann perimetry were done before and at regular intervals during treatment.

Results: A significant decrease of serum FSH, LH or α -subunit concentrations was found in nine patients. The levels remained low during the entire treatment period. In two out of three patients with pre-existing visual field defects a slight improvement was shown during the first months of treatment, but eventually deterioration occurred in all three patients. A fourth patient developed unilateral ophthalmoplegia during treatment. During the first year tumor volume decreased in three patients, but in two of them regrowth occurred after a few months. In six patients progressive tumor growth occurred despite sustained suppression of gonadotropin or α -subunit levels.

Conclusions: Long-term treatment of patients with CNPA with high doses of the dopamine agonist quinagolide could not prevent progressive increase in tumor size in most patients. It remains unproven whether quinagolide retards CNPA growth. Additional studies are needed to investigate whether subgroups of patients, e.g. those with positive dopamine receptor scintigraphy or those with marked hypersecretion of intact gonadotropins or subunits, will respond more favorably to treatment with dopamine agonists.

European Journal of Endocrinology 143 615–621

Introduction

Approximately 25–30% of pituitary adenomas are classified as clinically non-functioning (1–5). Because patients harboring these tumors lack clinical signs of hormone excess, the diagnosis is usually made at an advanced stage. Surgical removal is therefore often incomplete and at present there is no established medical treatment available. The majority of these tumors are in fact poorly secreting, rather than completely non-secreting. In cell culture they usually release gonadotropins or their subunits (6–8). Pharmacological suppression of this hormone production could theoretically induce tumor shrinkage, analogous to the effects of dopamine agonists in patients with prolactinomas and somatostatin analogues in patients

with growth hormone (GH)-producing adenomas (9, 10).

In general, clinically non-functioning pituitary adenomas (CNPA) express dopamine D2 receptors on their cell membranes (11, 12). This is confirmed by new *in vivo* dopamine receptor scintigraphy techniques with the iodinated benzamides ¹²³I-IBZM or ¹²³I-epidepride (13–16). The dopamine agonist bromocriptine can suppress the synthesis and secretion of gonadotropins and α -subunits by CNPA cells *in vitro* (17–19). It also reduces α -subunit mRNA accumulation in tumor tissue removed from patients with pure α -subunit secreting tumors (18). Therefore several investigators have tried dopamine agonist therapy, usually bromocriptine, in patients with CNPA. The results are rather disappointing, however, showing improvement of

visual field defects and/or reduction of tumor mass in only a small number of patients (11, 20–24). Since bromocriptine is generally not well tolerated in high doses, rather low doses were used in these studies. In addition, the treatment periods were generally short.

The density of dopamine receptors on CNPA cells is much lower than on prolactinoma cells. Moreover, prolonged incubation with bromocriptine in high concentrations is needed to obtain a significant reduction of gonadotropin and α -subunit release *in vitro* (19). This suggests that sustained treatment with high doses of a dopamine agonist is needed to obtain tumor shrinkage.

The new generation of more powerful and more selective dopamine agonists might provide a useful alternative for bromocriptine (25). These drugs are better tolerated than bromocriptine, allowing the use of higher doses. Our group has published preliminary results with the long-acting non-ergot dopamine agonist quinagolide in five patients with CNPA (26). At a final daily dose of 0.3 mg during 12–18 months a significant decrease in serum follicle-stimulating hormone (FSH) and/or α -subunit concentrations was induced in four patients, tumor shrinkage in one, and improvement in visual field defects in two. The drug was well tolerated.

In order to evaluate the long-term effect of quinagolide *in vivo* we followed serum gonadotropin and α -subunit concentrations and tumor volume in ten patients with CNPA, who were treated with the dopamine agonist for at least 3 years. Tumor volume was carefully measured using a surface to volume summation method and a mathematical method based on the three axes of the tumor.

Subjects and methods

We studied ten patients with CNPA. Short-term (12–18 months) follow-up data of four patients (patients 2, 3, 7, 8) were published previously by Kwekkeboom & Lamberts (26). CNPA was defined as the presence of a solid pituitary tumor without clinical signs of hormonal hypersecretion and lacking clinical and radiological characteristics of non-pituitary tumors (such as craniopharyngiomas, meningiomas, metastases of distant malignant tumors or aneurysms of the internal carotid artery). Patients with pituitary apoplexia or radiological evidence of bleeding, necrosis or cystic structures in the tumor were excluded. None of the patients had received prior medical, surgical or radiation therapy for the pituitary adenoma.

All patients gave informed consent to participate in the study, which was approved by the hospital ethics committee. Medical treatment with quinagolide was started at a daily dose of 0.075 mg. The dose was progressively increased to the final daily dose of 0.3 mg within 1 month. Reasons for choosing quinagolide treatment were either the presence of relative contraindications to surgery or refusal of surgery by the

patient. Patients were regularly followed at the outpatient clinic for at least 3 years.

Pretreatment serum gonadotropin and α -subunit concentrations were determined from samples drawn on a control day hourly for 12 h. In six patients additional hourly sampling for 12 h was performed 5 days after starting quinagolide treatment. Thereafter blood samples were drawn at each visit to the outpatient department. Prolactin (PRL) levels were measured to assess compliance to the treatment.

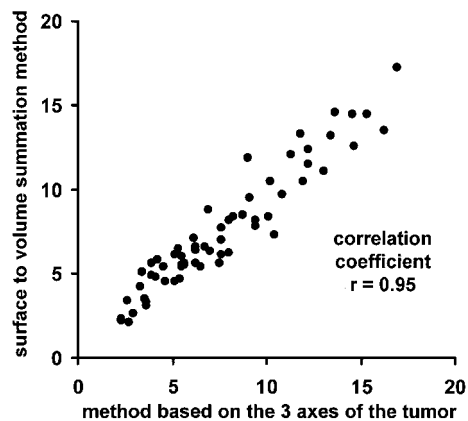
PRL, insulin-like growth factor-I (IGF-I), GH, thyroid-stimulating hormone (TSH) and adrenocorticotrophic hormone (ACTH) were measured using kits obtained, respectively, from IRE-Medgenix, Brussels, Belgium (PRL, IGF-I); Sorin, Milan, Italy; Behring, Marburg, Germany; and Amersham International, Amersham, Bucks, UK. FSH and luteinizing hormone (LH) were measured using IRMA kits supplied by IRE-Medgenix, Brussels, Belgium. The sensitivity of these assays was 0.5 U/l. α -Subunit was measured by RIA, using antibodies purchased from UCB, Brussels, Belgium. The sensitivity of the α -subunit assay was 0.3 μ g/l. The intra- and inter-assay coefficients of variation were respectively <5 and <15% for LH, <3 and <8% for FSH, and <6 and <11% for α -subunit (27).

Computerized tomographic (CT) scans or magnetic resonance imaging (MRI) of the pituitary region and Goldmann perimetry were done before and at regular intervals during treatment. CT scans and/or MRI images were used to estimate tumor volume. The scans were digitized using a Hewlett Packard ScanJet II cx/t flatbed scanner (Hewlett Packard Company, Palo Alto, CA, USA). The scanner was operated by a Macintosh LC 475 20/250 mb computer (Apple Computer Inc., Cupertino, CA, USA), utilizing Desk scan II software (Hewlett Packard). Files were read by the NIH Image 1.27 digital image analysis program (Shareware; National Institutes of Health, Baltimore, MD, USA). The scale was calibrated from pixels to millimeters using the scale bar printed on scans. All measurements were performed by the same observer. Two methods of volume calculation were used: a surface to volume summation method and a method based on the three axes of the tumor (28). In the surface to volume summation method the tumor area was outlined using the computer mouse. The surface of the tumor section was calculated and multiplied with the slice thickness. The total volume of the tumor was calculated by adding up these values. Duong *et al.* (29) published an error analysis of this method, showing acceptable measurement deviations from known volumes. In the other method the x , y and z radii were measured in the frontal, sagittal and coronal planes respectively. Assuming a spherical volume, the formula $4/3\pi r^3$ was used for volume calculation, r being the mean of the x , y and z radii. All measurements of tumor volume were performed

Table 1 Patient data and LH, FSH and α -subunit levels before and during treatment with quinagolide.

Patient	Sex	Age (years)	Total duration of follow-up (months)	Quinagolide treatment (months)	LH (U/l; mean (range))	FSH (U/l; mean (range))	α -subunit (μ g/l; mean (range))
1	M	67	56	Before	1.4 (0.9–1.8)	1.4 (0.6–2.2)	0.4 (0.3–0.6)
				1–3	1.0	0.9	—
				3–12	0.7 (0.4–1.0)*	1.4 (1.0–1.9)	0.6 (0.5–0.6)
2	M	62	91	Before	0.6 (0.5–0.6)	8.0 (6.8–9.4)	0.5 (0.5–0.6)
				1–3	0.5 (0.4–0.6)	1.5 (0.5–2.2)**	0.4 (0.2–0.5)*
				3–12	0.5 (0.4–0.8)	2.0 (1.4–2.7)	0.5 (0.4–0.5)
3	M	57	93	Before	3.8 (3.4–4.7)	6.2 (5.2–7.2)	1.0 (0.9–1.1)
				1–3	2.3 (1.4–3.0)**	2.6 (1.7–3.3)**	0.5 (0.4–0.6)**
				3–12	2.8 (2.3–3.2)	2.9 (1.9–3.3)	0.5 (0.4–0.6)
4	M	62	51	Before	1.7 (0.4–3.1) ^{††}	2.7 (1.6–4.5)	0.5 (0.2–0.7)
				1–3	0.6 (0.4–1.3)	2.9 (2.3–4.4)	1.0 (0.8–1.3)
				3–12	0.4	0.4	0.3
5	M	62	44	Before	0.6 (0.4–1.1)	0.9 (0.4–1.3)**	0.4 (0.3–0.4)**
				1–3	0.5 (0.4–1.0)	0.7 (0.4–1.6)	0.4 (0.2–0.6)
				>12	0.5 (0.4–0.8)	2.2 (1.4–3.6)	0.8 (0.6–1.0)
6	M	70	41	Before	1.6	—	0.9
				1–3	0.5 (0.4–0.7)	2.8 (0.4–6.0)	0.6 (0.5–0.9)
				>12	0.4 (0.4–0.4)	0.6 (0.4–1.0) [†]	0.4 (0.2–0.5)
7	M	81	85	Before	1.1 (1.0–1.2)	2.3 (1.8–3.0)	0.8 (0.6–0.9)
				1–3	—	—	0.9
				3–12	0.7 (0.6–0.7)**	1.7 (1.5–1.9)	0.8 (0.7–0.9)
8	M	78	68	Before	0.5 (0.4–0.8)	1.0 (0.6–1.7)	0.4 (0.2–0.5) ^{††}
				1–3	1.1 (0.9–1.2)	3.3 (3.3–3.3)	1.3 (1.2–1.4)
				3–12	1.5 (1.5–1.5)	1.3 (1.1–1.4)*	0.7 (0.6–0.8)**
9	F	72	57	Before	1.7 (0.6–3.0)	0.9 (0.4–1.9)	0.5 (0.5–0.6)
				1–3	0.8 (0.4–1.5)	1.1 (0.4–2.6)	0.6 (0.4–0.8)
				>12	0.8 (0.4–2.2)	1.9 (0.6–2.9)	0.2 (0.2–0.2)
10	M	67	36	Before	3.3 (2.5–3.9)	5.2 (4.2–6.0)	0.3 (0.2–0.4)
				1–3	0.9 (0.4–1.3)**	0.5 (0.4–0.7)**	0.2 (0.2–0.2)
				3–12	0.8 (0.4–1.6)	1.8 (0.8–3.0)	0.2 (0.2–0.2)
11	F	72	57	Before	0.8 (0.4–2.2)	1.9 (0.6–2.9)	0.2 (0.2–0.6)
				1–3	0.6 (0.4–1.2)	5.1 (4.3–5.8)	0.4 (0.3–0.6)
				3–12	—	—	0.7
12	M	67	36	Before	1.2 (0.6–1.8)	2.7 (1.0–4.3)**	0.6 (0.5–0.7)
				1–3	0.6 (0.4–1.1)	2.6 (1.7–3.5)	0.5 (0.4–0.8)
				>12	0.6 (0.4–1.1)	2.6 (1.7–3.5)	0.5 (0.4–0.8)
13	M	67	36	Before	0.4 (0.4–0.4)	1.1 (0.4–1.6)	0.6 (0.4–0.7)
				1–3	0.4	0.4	0.5
				3–12	—	—	—
14	M	67	36	Before	0.4	1.1	—
				1–3	—	—	—
				>12	0.4	1.1	—

* $P < 0.05$ and ** $P < 0.01$ vs before treatment; [†] $P < 0.05$ and ^{††} $P < 0.01$ vs month 3–12. No statistical evaluation was performed on individual hormone levels. Normal values in men: LH 1.9–9.2 U/l, FSH 1.6–11.1 U/l, α -subunit 0.4–1.1 μ g/l; in postmenopausal women: LH 17.5–86.8 U/l, FSH 26.2–107.7 U/l, α -subunit 1.3–4.0 μ g/l. Pretreatment levels are means of 13 values on a control day. The levels after 1–3, 3–12 and >12 months of therapy are means of 2–5, 2–6 and 4–17 serum samples respectively, except in the few cases when only one value was available.

**Figure 1.** Comparison between two methods of estimation of tumor volume (cm^3).

by the same technician, who was blinded to clinical responses. Measurements were done twice and mean results used.

Individual hormone levels were evaluated using ANOVA. For the comparison of the means the Newman-Keuls method was applied. P values < 0.05 were considered significant.

Results

Patient data and hormone levels are listed in Table 1. No apparent hypersecretion of gonadotropins or α -subunits was shown, except in one patient (patient 7) who had a slightly elevated serum α -subunit level. Serum levels of PRL were slightly elevated in four

Table 2 Tumor volume (cm³) before and during treatment with quinagolide.

Patient	Quinagolide treatment (months)			
	0 (mean)	1–12 (mean (range) and Δ)	12–48 (mean (range) and Δ)	>48 (mean (range) and Δ)
1	5.5	5.6 Δ 1.8	5.8 (5.6–6.1) Δ 5.5	4.2 Δ -23.6*
2	4.7	6.9 (5.4–8.4) Δ 46.8*	7.1 (6.4–7.8) Δ 51.1*	7.5 (7.3–7.7) Δ 59.6*
3	10.5	8.2 Δ -21.9*	11.5 (10.5–12.4) Δ 9.5	12.3 (11.5–13.3) Δ 17.1*
4	7.0	7.6 (7.0–8.2) Δ 8.6	12.1 (9.7–14.5) Δ 72.9*	12.6 Δ 80.0*
5	4.5	2.3 Δ -48.9*	2.2 (2.1–2.4) Δ -51.1*	—
6	3.3	2.9 (2.6–3.1) Δ -12.1*	3.5 Δ 6.1	3.4 Δ 3.0
7	7.1	6.5 Δ -8.5	7.7 (5.8–9.5) Δ 8.5	8.8 Δ 23.9*
8	11.1	14.6 Δ 31.5*	13.9 (13.2–14.5) Δ 25.2*	15.4 (13.5–17.3) Δ 38.7*
9	5.6	6.5 (6.3–6.6) Δ 16.1*	6.0 (5.4–6.6) Δ 7.1	8.4 Δ 50.0*
10	5.5	6.1 Δ 10.9*	6.0 Δ 9.1	—

Δ = Tumor volume (in cm³) change from baseline (in %).

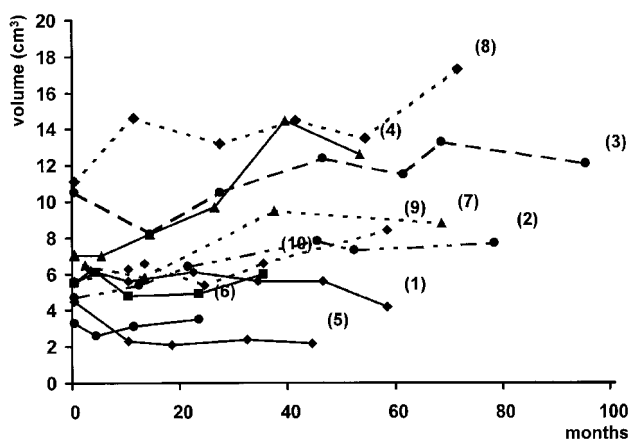
*A change of more than 10% is arbitrarily considered significant.

patients (all <25 µg/l). Serum levels of GH, IGF-I, TSH and ACTH were not elevated in any of the patients. All patients showed hypopituitarism, with deficient adrenal, thyroidal and gonadal function, except patients 3 and 9, who only had deficient gonadal and thyroidal function respectively. All patients had pituitary macroadenomas with suprasellar extension.

The median duration of follow-up under quinagolide treatment was 57 months (range 36–93 months). PRL levels remained lower than 2 µg/l during the entire treatment in all the patients, indicating good compliance. Tolerance of the drug was excellent in this relatively old group of patients. No clinically significant nausea, postural hypotension or psychiatric disturbances were

seen. A significant decrease of serum LH, FSH or α-subunit concentrations was found in nine patients (Table 1). No early decrease was seen in the six patients whose gonadotropin and α-subunit levels were measured 5 days after the beginning of quinagolide treatment (data not shown). Response was shown within the first 12 months of treatment, except in patient 5 whose FSH levels decreased only after more than 12 months. In three patients (2, 3 and 6), who responded within the first year, gonadotropin or α-subunit levels further decreased after a treatment duration of more than 12 months. The suppression was most marked in those patients with the highest pretreatment levels. The levels remained low during the entire treatment period. No apparent escape from treatment was seen, not even in patients 2, 3 and 7, who were followed for more than 7 years.

The two methods of tumor volume calculation showed comparable results (correlation coefficient $r = 0.95$) (Fig. 1). Therefore only the surface summation method was used for evaluating the effect of quinagolide on tumor volume. A volume change of more than 10% was arbitrarily considered significant (Table 2). During the first year tumor volume decreased in three patients (patients 3, 5 and 6), remained stable in three (patients 1, 4, and 7) and increased in four (patients 2, 8, 9 and 10) (Table 2, Fig. 2). In patients 3 and 6, whose tumor initially decreased in volume, regrowth to the pretreatment volume occurred after 10 and 24 months respectively. Of the three patients whose tumor volume initially remained stable, a significant decrease in volume was shown in patient 1 after 56 months of treatment, but significant growth occurred in patients

**Figure 2.** Evolution of tumor volumes (absolute values in cm³).

4 and 7 after 24 and 37 months respectively. At the end of follow-up (range 36–93 months) tumor volume remained significantly below pretreatment volumes in two patients (patients 1 and 5), remained at pretreatment volumes in two (patients 6 and 10) and was significantly increased in six (patients 2, 3, 4, 7, 8 and 9). No relationship between changes in tumor volume and changes in gonadotropin and/or α -subunit levels could be demonstrated.

Patients 1, 2, 3, 4, 5, 9 and 10 had no visual field defects before or during the treatment. In patient 6 a pre-existing discrete left superior temporal quadrant-anopsia slightly deteriorated during treatment with development of bitemporal superior quadrantanopsia, although no significant increase in tumor volume could be detected on MRI. In patients 7 and 8, who had bitemporal superior quadrantanopsia and bitemporal hemianopsia respectively, visual field defects improved in the first 4 months of treatment. When tested after 59 and 35 months of treatment respectively, a slight deterioration was shown in both patients, correlating with a significant increase in tumor volume. Patient 2, whose tumor volume was progressively increasing on successive CT and MRI scans, developed unilateral ophthalmoplegia (6th cranial nerve) after 83 months of quinagolide treatment, which responded favorably to treatment with dexamethasone.

Patients 6 and 10 were eventually operated on. Pathological examination of the resection specimens revealed chromophobic adenoma. Immunohistochemical staining was positive for FSH and α -subunit and negative for PRL and ACTH.

Discussion

Due to advances in immunological and molecular biological techniques to detect hormonal secretion *in vitro*, it has been demonstrated in recent years that the majority of CNPA are in fact poorly secreting, rather than completely non-secreting (6–8). In cell culture they usually synthesize and secrete the gonadotropic hormones FSH and/or LH, and/or their free α - or β -subunits (6–8). Even adenomas that have lost all neuropeptide synthesizing activity (so-called null-cell adenomas) demonstrate typical dense core neurosecretory granules on electron microscopy, while the secretory granule-specific protein chromogranin A can be identified in virtually all cases (30, 31).

The presence of hormonal secretion provides an opportunity for medical treatment. Dopamine agonists are an evident option, since CNPA express dopamine receptors on their cell membranes (11–16), and addition of dopamine agonists to cultures of tumor cells of gonadotroph origin suppresses the release and synthesis of gonadotropins and α -subunits (17–19).

In this study we report on the efficacy of treatment with the potent non-ergot dopamine agonist quinagolide in ten patients with CNPA. The diagnosis was made

on a clinical basis in the presence of a solid pituitary tumor without clinical signs of hormonal hypersecretion and lacking clinical and radiological characteristics of non-pituitary tumors. No biopsy material was available to confirm the diagnosis, because reasons for choosing quinagolide treatment were either the presence of relative contraindications to surgery or refusal of surgery by the patient. The slow growth of the tumors is compatible with the diagnosis of CNPA (32–35). Two patients were eventually operated on, and the diagnosis was confirmed by pathological and immunohistochemical examination.

Quinagolide induced a significant decrease of serum concentrations of LH, FSH or α -subunit in nearly all patients. Since all our patients showed severe hypopituitarism this response is probably not due to an effect on normal gonadotrophs but on gonadotroph production by the tumor cells. Levels only decreased after prolonged treatment, confirming our *in vitro* data showing that it takes an incubation of 2–6 weeks before maximal inhibition of hormonal secretion is attained (19). The serum concentrations of LH, FSH and α -subunit remained low during the entire follow-up period. No escape from treatment was seen, not even in patients followed for more than 7 years.

In patients with PRL- or GH-producing pituitary adenomas, drugs that suppress hormonal activity induce tumor shrinkage in a substantial proportion of tumors (9, 10). One might expect similar effects in patients with CNPA. The reported *in vivo* effects of bromocriptine treatment on tumor size have been variable, however (11, 20–24). In general no reduction in tumor size has been observed, but occasional patients respond to dopaminergic therapy with improvement in visual field defects and/or reduction of tumor mass. In many reports the administered doses were low and the treatment period short. Based on the *in vitro* data, showing suppression of hormone production only when high concentrations of dopaminergic drugs are used for a long time, we hypothesized that long-term treatment with high doses would be needed to obtain tumor shrinkage. For this reason we chose the potent dopamine agonist quinagolide, in a high daily dose of 0.3 mg, comparable to 30 mg bromocriptine. In a preliminary study in five patients, treated for 12–18 months, promising results were obtained with tumor shrinkage in one, and improvement in visual field defects in two (26). Our long-term results in ten patients do not confirm these observations. During the first year tumor volume decreased in three patients, but in two of them regrowth occurred after a few months. In six patients progressive increase in tumor size occurred despite sustained suppression of gonadotropin or α -subunit levels. In two out of three patients with pre-existing visual field defects a slight improvement was shown during the first months of treatment, but eventually deterioration occurred in all three patients. One patient developed unilateral ophthalmoplegia

during treatment. At the end of follow-up (median 56 months, range 36–92 months) tumor volume remained significantly below pretreatment volume in two patients, remained at pretreatment volume in two and was significantly increased in six. Thus a convincing tumor-shrinking effect could not be demonstrated.

In the absence of a control group it is difficult to determine whether quinagolide was effective in slowing down tumor growth or not. Only a long-term large-scale multicenter prospective randomized placebo-controlled trial could give an answer to this question. A large number of patients would be needed to demonstrate small effects on tumor volume. A treatment of several years would be needed because these tumors are usually slow growing (32–35). Our results clearly indicate that such a controlled study is not feasible in non-selected patients with CNPA.

Drugs that suppress hormone production only induce significant shrinkage of active endocrine cells containing a well-developed secretory apparatus (9, 10). Organelles involved in the synthesis and storage of hormones, such as the endoplasmic reticulum and the secretory vesicles, make a substantially smaller contribution to the tumor volume in CNPA than, for example, in prolactinomas. It is therefore not surprising that an improvement of visual field defects or a tumor size reduction during dopamine agonist treatment has been reported in a greater percentage of patients with pituitary adenomas that hypersecrete gonadotropins or α -subunits than in patients without apparent overproduction (11, 20–24). Such hypersecreting CNPA are rare, however, making a randomized controlled study in these selected patients practically impossible.

Another possible explanation for the discrepancy between the efficient suppression of hormone production by quinagolide and the disappointing effects on tumor volume could be the inclusion of tumors with a very low dopamine receptor density. This problem can now be approached by dopamine receptor scintigraphy with ^{123}I -IBZM or preferably with ^{123}I -epidepride (13–16). These nuclear medicine techniques can predict the suppressive effect of dopamine agonists on the growth of prolactinomas. In a recent study we demonstrated tumor shrinkage in two and tumor stabilization in one of three ^{123}I -IBZM single photon emission computed tomography (SPECT)-positive CNPA patients treated with quinagolide, although in one of these patients an additional effect of octreotide could not be excluded (14). In one of four patients without ^{123}I -IBZM uptake in the pituitary fossa tumor growth occurred under quinagolide therapy. Feasibility studies on a larger number of patients with longer follow-up are needed to validate whether SPECT with ^{123}I -IBZM or ^{123}I -epidepride might be of assistance in selecting patients who may potentially benefit from dopaminergic therapy.

In conclusion, long-term treatment of patients with CNPA with high doses of the dopamine agonist

quinagolide could not prevent progressive increase in tumor size in most patients, despite persistent suppression of hormone secretion. It remains unproven whether quinagolide retards CNPA growth. Additional studies are needed to investigate whether subgroups of patients, e.g. those with positive dopamine receptor scintigraphy or those with marked hypersecretion of intact gonadotropins or subunits, will respond more favorably to treatment with dopamine agonists. Feasibility studies in selected subgroups should be performed before large prospective randomized placebo-controlled trials are organized.

Acknowledgement

We are grateful to Miss K van Wessem who performed the tumor volume measurements.

References

- 1 Klibanski A. Nonsecreting pituitary tumors. *Endocrinology and Metabolism Clinics of North America* 1987 **16** 793–804.
- 2 Snyder PJ. Clinically nonfunctioning pituitary adenomas. *Endocrinology and Metabolism Clinics of North America* 1993 **22** 163–175.
- 3 Katznelson L, Alexander JM & Klibanski A. Clinical review 45. Clinically nonfunctioning pituitary adenomas. *Journal of Clinical Endocrinology and Metabolism* 1993 **76** 1089–1094.
- 4 Lamberts SWJL, de Herder WW, Van der Lely AJ & Hofland LJ. Imaging and medical management of clinically nonfunctioning pituitary tumors. *Endocrinologist* 1995 **5** 3–6.
- 5 Snyder PJ. Extensive personal experience: gonadotroph adenomas. *Journal of Clinical Endocrinology and Metabolism* 1995 **80** 1059–1061.
- 6 Snyder PJ, Bashey HM, Phillips JL & Gennarelli TA. Comparison of hormonal secretory behavior of gonadotroph cell adenomas *in vivo* and *in culture*. *Journal of Clinical Endocrinology and Metabolism* 1985 **61** 1061–1065.
- 7 Asa SL, Gerrie BM, Singer W, Horvath E, Kovacs K & Smyth HS. Gonadotropin secretion *in vitro* by human pituitary null cell adenomas and oncocytomas. *Journal of Clinical Endocrinology and Metabolism* 1986 **62** 1011–1019.
- 8 Kwekkeboom DJ, de Jong FH & Lamberts SWJ. Gonadotropin release by clinically nonfunctioning and gonadotroph pituitary adenomas *in vivo* and *in vitro*: relation to sex and effects of TRH, GnRH and bromocriptine. *Journal of Clinical Endocrinology and Metabolism* 1989 **68** 1128–1135.
- 9 Lamberts SWJ. The role of somatostatin in the regulation of anterior pituitary hormone secretion and the use of its analogs in the treatment of human pituitary tumors. *Endocrine Reviews* 1988 **9** 417–436.
- 10 Lamberts SWJ & MacLeod RM. Regulation of prolactin secretion at the level of the lactotroph. *Physiological Reviews* 1990 **70** 279–318.
- 11 Bevan JS & Burke CW. Non-functioning pituitary adenomas do not regress during bromocriptine therapy but possess membrane-bound dopamine receptors which bind bromocriptine. *Clinical Endocrinology* 1986 **25** 561–572.
- 12 Koya M, Nakao H, Arao M, Sato B, Noma K, Morimoto Y *et al*. Demonstration of specific dopamine receptors on human pituitary adenomas. *Acta Endocrinologica* 1987 **114** 595–602.
- 13 Pirker W, Brucke T, Riedl M, Clodi M, Luger A, Asenbaum S *et al*. Iodine-123-IBZM-SPECT: studies in 15 patients with pituitary tumors. *Journal of Neural Transmission, General Section* 1994 **97** 235–244.

- 14 de Herder WW, Reijs AEM, Kwekkeboom DJ, Hofland LJ, Nobels FRE, Oei HY *et al.* *In vivo* imaging of pituitary tumours using a radiolabelled dopamine D₂ receptor radioligand. *Clinical Endocrinology* 1996 **45** 755–767.
- 15 Pirker W, Riedl M, Luger A, Czech T, Rossler K *et al.* Dopamine D₂ receptor imaging in pituitary adenomas using [¹²³I]-epidepride and SPECT. *Journal of Nuclear Medicine* 1996 **37** 1931–1937.
- 16 de Herder WW, Reijs AEM, de Swart J, Kaandorp Y, Lamberts SWJ, Krenning EP *et al.* Comparison of iodine-123-epidepride and iodine-123-IBZM for dopamine D₂ receptor imaging in clinically nonfunctioning pituitary macroadenomas and macroprolactinomas. *European Journal of Nuclear Medicine* 1999 **26** 46–50.
- 17 Lamberts SWJ, Verleun T, Oosterom R, Hofland L, Van Ginkel LA, Van Loeber JG *et al.* The effects of bromocriptine, thyrotropin-releasing hormone, and gonadotropin-releasing hormone on hormone secretion by gonadotropin-secreting pituitary adenomas *in vivo* and *in vitro*. *Journal of Clinical Endocrinology and Metabolism* 1987 **64** 524–530.
- 18 Klibanski A, Shupnik MA, Bikkal HA, Black PMcL, Kliman B & Zervas NT. Dopaminergic regulation of α -subunit secretion and messenger ribonucleic acid levels in α -secreting pituitary tumours. *Journal of Clinical Endocrinology and Metabolism* 1988 **65** 96–102.
- 19 Kwekkeboom DJ, Hofland LJ, Van Koetsveld PM, Singh R, Van den Berge JH & Lamberts SWJ. Bromocriptine increasingly suppresses the *in vitro* gonadotropin and α -subunit release from pituitary adenomas during long term culture. *Journal of Clinical Endocrinology and Metabolism* 1990 **71** 718–725.
- 20 Renner U, Mojto J, Lange M, Müller OA, Von Werder K & Stalla GK. Effect of bromocriptine and SMS 201-995 on growth of human somatotrophic and non-functioning pituitary adenoma cells *in vitro*. *European Journal of Endocrinology* 1994 **130** 80–91.
- 21 Klibanski A, Deutsch PJ, Jameson JL, Ridgway EC, Growley WF, Hsu DW *et al.* Luteinizing hormone-secreting pituitary tumor: biosynthetic characterization and clinical studies. *Journal of Clinical Endocrinology and Metabolism* 1987 **64** 536–542.
- 22 Vance ML, Ridgway BC & Thorner MO. Follicle-stimulating hormone- and α -subunit secreting pituitary tumor treated with bromocriptine. *Journal of Clinical Endocrinology and Metabolism* 1985 **61** 580–584.
- 23 Wood DE, Johnston JM & Johnston DG. Dopamine, the dopamine D₂ receptor and pituitary tumours. *Clinical Endocrinology* 1991 **35** 455–466.
- 24 Bevan JS, Webster J, Burke CW & Scanlon WE. Dopamine agonists and pituitary tumor shrinkage. *Endocrine Reviews* 1992 **13** 220–240.
- 25 Homburg R, West C, Brownell J & Jacobs HS. A double-blind study comparing a new non-ergot, long-acting dopamine agonist, CV 205-502, with bromocriptine in women with hyperprolactinaemia. *Clinical Endocrinology* 1990 **32** 565–571.
- 26 Kwekkeboom DJ & Lamberts SWJ. Long-term treatment with the dopamine agonist CV 205-502 of patients with a clinically nonfunctioning, gonadotroph, or α -subunit secreting pituitary adenoma. *Clinical Endocrinology* 1992 **36** 171–176.
- 27 Kwekkeboom DJ, de Jong FH & Lamberts SWJ. Confounding factors in the interpretation of gonadotropin and gonadotropin-subunit release from cultured human pituitary adenomas. *Journal of Steroid Biochemistry* 1989 **33** 777–782.
- 28 Petersen OF & Espersen JO. Extradural hematomas: measurement of size by volume summation on CT scanning. *Neuroradiology* 1984 **26** 363–367.
- 29 Duong H, Rostomily RC, Haynor DR, Keles GE & Berger MS. Measurement of tumor resection volumes from computerized images. *Journal of Neurosurgery* 1992 **77** 151–154.
- 30 Lloyd RV, Jin L, Fields K, Chandler WF, Horvath E, Stefaneanu L *et al.* Analysis of pituitary hormones and chromogranin A mRNAs in null cell adenomas, oncocytoomas, and gonadotroph adenomas by *in situ* hybridization. *American Journal of Pathology* 1991 **139** 553–564.
- 31 Nobels FRE, Kwekkeboom DJ, Coopmans W, Hoekstra R, Bouillon R & Lamberts SWJ. A comparison between the diagnostic value of the measurement of gonadotropins, α -subunits and chromogranin A and their response to TRH in clinically nonfunctioning, α -subunit secreting and gonadotroph pituitary adenomas. *Journal of Clinical Endocrinology and Metabolism* 1993 **77** 784–789.
- 32 Ciric I, Mikhael M, Stafford T, Lawson L & Garces R. Transsphenoidal microsurgery of pituitary macroadenomas with long-term follow-up results. *Journal of Neurosurgery* 1983 **59** 395–401.
- 33 Ebersold MJ, Quast LM, Laws ER, Scheithauer B & Randall RV. Long-term results in transsphenoidal removal of nonfunctioning pituitary adenomas. *Journal of Neurosurgery* 1986 **64** 713–719.
- 34 Comtois R, Beauregard H, Somma M, Serri O, Aris-Jilwan N & Hardy J. The clinical and endocrine outcome to transsphenoidal microsurgery of nonsecreting pituitary adenomas. *Cancer* 1991 **68** 860–866.
- 35 Gittoes NJL, Bates AS, Tse W, Bullivant B, Sheppard MC, Clayton RN *et al.* Radiotherapy for non-functioning pituitary tumours. *Clinical Endocrinology* 1998 **48** 331–337.

Received 10 April 2000

Accepted 31 July 2000